

Operative Techniques: Spine Surgery

Third Edition

Eli M. Baron, MD

Associate Professor of Neurosurgery
Neurosurgeon
Spine Surgeon
Cedars-Sinai Spine Center
Cedars-Sinai Department of Neurosurgery
Los Angeles, California

Alexander R. Vaccaro, MD, PhD

Professor and Chairman
Department of Orthopaedic Surgery
Thomas Jefferson University and Hospitals
Philadelphia, Pennsylvania

ELSEVIER

ELSEVIER

1600 John F. Kennedy Blvd.
Ste 1800
Philadelphia, PA 19103-2899

OPERATIVE TECHNIQUES: SPINE SURGERY, THIRD EDITION

ISBN: 978-0-323-40066-4

Copyright © 2018 by Elsevier, Inc. All rights reserved.

No part of this publication may be reproduced or transmitted in any form or by any means, electronic or mechanical, including photocopying, recording, or any information storage and retrieval system, without permission in writing from the publisher. Details on how to seek permission, further information about the Publisher's permissions policies and our arrangements with organizations such as the Copyright Clearance Center and the Copyright Licensing Agency, can be found at our website: www.elsevier.com/permissions.

This book and the individual contributions contained in it are protected under copyright by the Publisher (other than as may be noted herein).

Notices

Knowledge and best practice in this field are constantly changing. As new research and experience broaden our understanding, changes in research methods, professional practices, or medical treatment may become necessary.

Practitioners and researchers must always rely on their own experience and knowledge in evaluating and using any information, methods, compounds, or experiments described herein. In using such information or methods they should be mindful of their own safety and the safety of others, including parties for whom they have a professional responsibility.

With respect to any drug or pharmaceutical products identified, readers are advised to check the most current information provided (i) on procedures featured or (ii) by the manufacturer of each product to be administered, to verify the recommended dose or formula, the method and duration of administration, and contraindications. It is the responsibility of practitioners, relying on their own experience and knowledge of their patients, to make diagnoses, to determine dosages and the best treatment for each individual patient, and to take all appropriate safety precautions.

To the fullest extent of the law, neither the Publisher nor the authors, contributors, or editors, assume any liability for any injury and/or damage to persons or property as a matter of products liability, negligence or otherwise, or from any use or operation of any methods, products, instructions, or ideas contained in the material herein.

Previous editions copyright © 2012, 2008

Library of Congress Cataloging-in-Publication Data

Names: Vaccaro, Alexander R., editor. | Baron, Eli M., editor.
Title: Spine surgery / [edited by] Alexander R. Vaccaro, Eli M. Baron.
Other titles: Spine surgery (Vaccaro) | Operative techniques.
Description: Third edition. | Philadelphia, PA : Elsevier, [2018] | Series: Operative techniques | Includes bibliographical references and index.
Identifiers: LCCN 2016037932 | ISBN 9780323400664 (hardcover : alk. paper)
Subjects: | MESH: Spine--surgery | Spinal Diseases--surgery | Orthopedic Procedures--methods | Atlases
Classification: LCC RD768 | NLM WE 17 | DDC 617.5/6059--dc23
LC record available at <https://lcn.loc.gov/2016037932>

Content Strategist: Kayla Wolfe
Content Development Specialist: Laura Schmidt
Publishing Services Manager: Catherine Jackson
Project Manager: Kate Mannix
Design Direction: Amy Buxton

Printed in China

Last digit is the print number: 9 8 7 6 5 4 3 2 1



Working together
to grow libraries in
developing countries

www.elsevier.com • www.bookaid.org

*I would like to dedicate this edition
of the book to my wonderful wife and family
and to my office staff for their continued
support for my surgical endeavors*

Eli M. Baron

*My wife Lauren and I would like to dedicate
this book to the birth of our daughter Mia, who has
provided an inspiration of love to our wonderful
family of Alex Jr., Juliana, and Christian.*

Alexander R. Vaccaro

Contributors

Yuichiro Abe, MD, PhD

Spine Surgeon
Department of Orthopaedic Surgery
Eniwa Hospital
Eniwa, Japan

Kuniyoshi Abumi, MD, PhD

Director
Center for Spinal Disorders
Sapporo Orthopaedic Hospital
Sapporo, Japan

Frank L. Acosta, Jr., MD

Assistant Professor of Neurological
Surgery and Orthopaedic Surgery
University of Southern California
Los Angeles, California

R. Todd Allen, MD

Department of Orthopaedic Surgery
University of California, San Diego
San Diego, California

Fadi Al-Saiegh, MD

Resident Neurosurgeon
Thomas Jefferson University Hospital
Philadelphia, Pennsylvania

Howard S. An, MD

Professor
Orthopaedic Surgery
Rush University Medical Center
Chicago, Illinois

Neel Anand, MD, MchOrth

Clinical Professor
Director, Spine Trauma
Minimally Invasive Spine Surgery
Cedars Sinai Medical Center
Los Angeles, California

David T. Anderson, MD

Orthopedic Spine Surgeon
OrthoCarolina
Charlotte, North Carolina

Lindsay M. Andras, MD

Assistant Professor of Orthopaedic
Surgery
Keck School of Medicine-University of
Southern California
Childrens Hospital Los Angeles
Los Angeles, California

Hyun Bae, MD

Professor of Surgery
The Spine Center at Cedars-Sinai
Medical Center
Los Angeles, California

Mark Bain, MD

Cerebrovascular Center
Cleveland Clinic
Cleveland, Ohio

Eli M. Baron, MD

Associate Professor of Neurosurgery
Neurosurgeon
Spine Surgeon
Cedars-Sinai Spine Center
Cedars-Sinai Department of
Neurosurgery
Los Angeles, California

E. Emily Bennett, MD, MS

Resident
Department of Neurosurgery
Cleveland Clinic
Cleveland, Ohio

Edward C. Benzel, MD

Chairman
Department of Neurosurgery
Center for Spine Health
Cleveland Clinic
Cleveland, Ohio

Sigurd Berven, MD

Department of Orthopedic Surgery
University of California, San Francisco
San Francisco, California

Neil Bhamb, MD

Orthopedic Surgeon
West Hollywood, California

John Birknes, MD

Neurosurgeon
Children's Hospital of the King's Daughter
Norfolk, Virginia

Robert S. Bray, Jr., MD

Board Certified Neurosurgeon
CEO and Founder of Diagnostic &
Interventional Spine and Sports Care
Marina Del Rey, California
Newport Beach, California

Robert M. Campbell, MD

Attending Physician
Division of Orthopaedics
Children's Hospital of Philadelphia
Philadelphia, Pennsylvania

Jimmy J. Chan, BS

Medical Student
Albert Einstein College of Medicine
New York, New York

Woojin Cho, MD

Orthopaedic Spine Service
Montefiore Medical Center;
Assistant Professor
Albert Einstein College of Medicine
New York, New York

David Choi, PhD, FRCS

Consultant Neurosurgeon
Victor Horsley Department of
Neurosurgery
The National Hospital for Neurology and
Neurosurgery
London, Great Britain

Ray Chu, MD

Department of Neurosurgery
Cedars-Sinai Medical Center
Los Angeles, California

Jason Ezra Cohen, MD

Albert Einstein College of Medicine
Bronx, New York

Ryan Baruch Cohen, MD

Cedars-Sinai Spine Center
Orthopedics
Cedars-Sinai
Los Angeles, California

H. Alan Crockard, DSc, FRCS, FDS, FRCP

Consultant Neurosurgeon
Victor Horsley Department of
Neurosurgery
The National Hospital for Neurology and
Neurosurgery
London, Great Britain

Jason M. Cuéllar, MD, PhD

Orthopaedic Spine Surgeon
Department of Medicine
Cedars-Sinai Medical Center
Los Angeles, California

Michael D. Daubs, MD

Professor and Chairman
Department of Orthopaedic Surgery
University of Nevada, Las Vegas School
of Medicine
Las Vegas, Nevada

Timothy Davis, MD

Medical Director
Orthopedic Pain Specialists
Santa Monica, California

Doniel Drazin, MD

Department of Neurosurgery
Cedars-Sinai Medical Center
Los Angeles, California

Michael F. Duffy, MD

Spine Surgeon
Texas Back Institute
Plano, Texas

Mostafa H. El Dafrawy, MD

Resident Physician
Orthopaedic Surgery
Johns Hopkins University
Baltimore, Maryland

Thomas J. Errico, MD

Chief, Division of Spine Surgery
New York University Langone Medical
Center;
Professor of Orthopedic and Neurological
Surgery
New York University School of Medicine
New York, New York

Sean M. Esmende, MD

Orthopedic Spine Surgeon
Bone and Joint Institute
Orthopedic Associates of Hartford
Hartford, Connecticut

Daniel R. Fassett, MD, MBA

Director of Spinal Surgery
Illinois Neurological Institute;
Head of Neurosurgery
University of Illinois College of Medicine,
Peoria
Peoria, Illinois

Richard G. Fessler, MD, PhD

Professor
Department of Neurosurgery
Rush University Medical Center
Chicago, Illinois

Michael A. Finn, MD

Assistant Professor of Neurosurgery
University of Colorado
Denver, Colorado

Peter G. Gabos, MD

Department of Orthopaedic Surgery
University of California, San Diego
San Diego, California

Steven R. Garfin, MD

Department of Orthopaedic Surgery
University of California, San Diego
San Diego, California

John Garlich, MD

Cedars-Sinai Orthopaedic Center
Los Angeles, California

Benjamin J. Geddes, MD

Department of Orthopaedics and
Rehabilitation
Yale University School of Medicine
New Haven, Connecticut

George M. Ghobrial, MD

Spinal Surgery Fellow
Department of Neurological Surgery
University of Miami
Miami, Florida

Yazeed Gussous, MD

Assistant Professor
Orthopedic Surgery
Ohio State University Wexner Medical
Center
Columbus, Ohio

Colin Harris, MD

Assistant Professor
Department of Orthopedics
Rutgers University-New Jersey Medical
School
Newark, New Jersey

Christopher C. Harrod, MD

Spine Surgeon
Bone and Joint Clinic
The Spine Center
Baton Rouge, Louisiana

James S. Harrop, MD

Professor of Neurosurgery and
Orthopedics
Sidney Kimmel Medical College at
Thomas Jefferson University;
Section Chief, Division of Spine and
Peripheral Nerve Disorders
Thomas Jefferson University Hospital
Philadelphia, Pennsylvania

Joshua Heller, MD

Assistant Professor
Neurological Surgery
Thomas Jefferson University
Philadelphia, Pennsylvania

Alan S. Hilibrand, MD

The Joseph and Marie Field Professor of
Spinal Surgery
Vice Chairman, Academic Affairs and
Faculty Development
Sidney Kimmel Medical College
Philadelphia, Pennsylvania

Serena Hu, MD

Department of Orthopedic Surgery
Stanford University
Palo Alto, California

Manabu Ito, MD, PhD

Medical Director
National Hospital Organization
Hokkaido Medical Center
Sapporo, Japan

Andre M. Jakoi, MD

Fellow, Spine Center
University of Southern California
Los Angeles, California

Jack I. Jallo, MD, PhD

Professor of Neurosurgery
Thomas Jefferson University and
Hospitals
Philadelphia, Pennsylvania

Sunil Jeswani, MD

Attending Neurosurgeon
Southern California Institute of
Neurological Surgery
Escondido, California

Avrum Joffe, MD

North Jersey Pediatric Orthopedics
Ridgewood, New Jersey

J. Patrick Johnson, MD, FACS

Neurosurgeon
Co-Director, Cedars-Sinai Spine Center
Director of Spine Education and
Neurosurgery Spine Fellowship
Program
Department of Neurosurgery
Cedars-Sinai Medical Center
Sacramento, California;
The Spine Institute Foundation
Los Angeles, California

Stepan Kasimian, MD

Attending Spine Surgeon
Orthopaedic Surgery
Cedars-Sinai Medical Center
Los Angeles, California

Manish K. Kasliwal, MD, MCh

Director of Minimally Invasive Spine
Surgery
Assistant Professor of Neurological
Surgery
University Hospitals Case Medical
Center
Case Western Reserve University
Cleveland, Ohio

Khaled Kebaish, MD, FRCSC

Associate Professor
Orthopaedic Surgery
Johns Hopkins University
Baltimore, Maryland

Christopher K. Kepler, MD, MBA

Associate Professor
Department of Orthopaedic Surgery
Thomas Jefferson University
Philadelphia, Pennsylvania

Terrence T. Kim, MD

Cedars-Sinai
Los Angeles, California

Paul Kraemer, MD

Orthopaedic Spine Surgeon
Indiana Spine Group
Indianapolis, Indiana

Carlito Lagman, MD

Department of Neurosurgery
Cedars-Sinai Medical Center
Los Angeles, California

Todd Lanman, MD

Cedars-Sinai Medical Center
Los Angeles, California

Joon Y. Lee, MD

University of Pittsburgh Medical Center
Pittsburgh, Pennsylvania

Scott I. Lee, MD

Adventist Health
White Memorial Medical Center
Los Angeles, California;
Glendale Adventist Medical Center
Glendale, California

Howard B. Levene, MD, PhD, FAANS

Assistant Professor of Neurological
Surgery
Neurological Surgery
University of Miami Miller School of
Medicine
Miami, Florida

William W. Long, BA

Research Assistant
Department of Orthopedic Surgery
Rush University Medical Center
Chicago, Illinois

Neil A. Manson, MD, FRCSC

Spine, Sports Medicine, and Orthopaedic
Surgery
Canada East Spine Centre
Horizon Health Network
Saint John, New Brunswick, Canada

Dustin H. Massel, BS

Clinical Research Fellow
Department of Orthopaedic Surgery
Rush University Medical Center
Chicago, Illinois

Benjamin C. Mayo, BA

Clinical Research Fellow
Department of Orthopaedic Surgery
Rush University Medical Center
Chicago, Illinois

Hooman Melamed, MD, FAAOS

Co-Director
Spine Surgery at Diagnostic and
Interventional Spinal Care;
Director of Scoliosis
Marina Del Rey Hospital
Marina Del Rey, California

Krishna Modi, BS

Research Assistant
Department of Orthopedic Surgery
Rush University Medical Center
Chicago, Illinois

Devan B. Moody, BS

Medical Student
Louisiana State University Health
Sciences Center
Shreveport, Louisiana

Charles Moon, MD

Cedars-Sinai Orthopaedic Center
Los Angeles, California

Debraj Mukherjee, MD, MPH

Resident Neurosurgeon
Cedars-Sinai Medical Center
Los Angeles, California

Zachary NaPier, MD

Cedars-Sinai Orthopaedic Center
Los Angeles, California

Rani Nasser, MD

Chief Resident
Department of Neurosurgery
Montefiore Medical Center/Albert Einstein
College of Medicine
New York, New York

Don Y. Park, MD

Assistant Professor, Orthopaedic Spine Surgery
University of California, Los Angeles
Los Angeles, California

Howard Y. Park, MD

Resident Surgeon, Orthopaedic Surgery
University of California, Los Angeles
Los Angeles, California

Alpesh A. Patel, MD

Professor
Department of Orthopaedic Surgery
Northwestern University Feinberg School of Medicine
Chicago, Illinois

Brian Perri, DO

Cedars-Sinai
Los Angeles, California

Tiffany Grace Perry, MD

Department of Neurosurgery
Cedars-Sinai Medical Center
Los Angeles, California

Srinivas K. Prasad, MD

Professor
Radiology Department
MD Anderson Cancer Center
Houston, Texas

John K. Ratliff, MD, FACS

Vice Chair, Operations and Development
Co-Director, Division of Spine and Peripheral Nerve Surgery
Department of Neurosurgery
Stanford University Medical Center
Palo Alto, California

Lindsey Ross, MD

Neurosurgery Resident
Cedars-Sinai Medical Center
Los Angeles, California

Glenn S. Russo, MD, MS

Department of Orthopaedics and Rehabilitation
Yale University School of Medicine
New Haven, Connecticut

Zeeshan M. Sardar, MD

Spine Surgeon
Assistant Professor
Department of Orthopaedic Surgery and Sports Medicine
Temple University, Lewis Katz School of Medicine
Philadelphia, Pennsylvania

Rick C. Sasso, MD

Professor; Chief of Spine Surgery
Orthopaedic Surgery
Indiana University School of Medicine;
Indiana Spine Group
Indianapolis, Indiana

Wouter Schievink, MD

Department of Neurosurgery
Cedars-Sinai Medical Center
Los Angeles, California

Michael Schiraldi, MD, PhD

Neurosurgery Resident
Cedars Sinai Medical Center
Los Angeles, California

Gregory D. Schroeder, MD

The Rothman Institute
Thomas Jefferson University
Philadelphia, Pennsylvania

Suken A. Shah, MD

Division Chief, Spine and Scoliosis Center
Department of Orthopaedic Surgery
Nemours/Alfred I. duPont Hospital for Children
Wilmington, Delaware

Arya Nick Shamie, MD

Professor and Chief, Orthopaedic Spine Surgery
University of California, Los Angeles
Los Angeles, California

Alok D. Sharan, MD, MHCDS

Co-Director
WESTMED Spine Center
New York, New York

Ashwini Sharan, MD, FACS

Professor of Neurosurgery and Neurology
Department of Neurosurgery
Sidney Kimmel Medical College
Thomas Jefferson University
Philadelphia, Pennsylvania

Kern Singh, MD

Associate Professor
Department of Orthopaedic Surgery
Rush University Medical Center
Chicago, Illinois

David L. Skaggs, MD, MMM

Professor
Orthopaedic Surgery
Keck School of Medicine of University of Southern California
Los Angeles, California

John Christos Styliaras, MD, MS

Department of Neurological Surgery
Thomas Jefferson University Hospital
Philadelphia, Pennsylvania

Chadi Tannoury, MD

Assistant Professor
Co-Director of Spine Fellowship Program
Orthopedic Surgery
Boston University Medical Center
Boston, Massachusetts

Oliver Tannous, MD

Orthopaedic Surgeon
University of California San Diego
Medical Center
San Diego, California

Akhil Tawari, MD

Clinical Spine Fellow
Boston Medical Center
Boston, Massachusetts

Vincent C. Traynelis, MD

Professor
Department of Neurosurgery
Rush University Medical Center
Chicago, Illinois

Alexander R. Vaccaro, MD, PhD

Professor and Chairman
Department of Orthopaedic Surgery
Thomas Jefferson University and Hospitals
Philadelphia, Pennsylvania

Christopher F. Villar, MD

Resident
University of Illinois College of Medicine,
Peoria
Peoria, Illinois

Michael J. Vives, MD

Associate Professor and Chief of Spine
Surgery
Department of Orthopedics
Rutger's University-New Jersey Medical
School
Newark, New Jersey

Peter G. Whang, MD, FACS

Associate Professor
Department of Orthopaedics and
Rehabilitation
Yale University School of Medicine
New Haven, Connecticut

Jefferson R. Wilson, MD, PhD, FRCSC

Assistant Professor
Division of Neurosurgery
University of Toronto
St. Michael's Hospital
Toronto, Ontario, Canada

Kamal Woods, MD, FAANS

Medical Director of Spine Center
Loma Linda University Medical Center-
Murrieta
Murrieta, California

Neill M. Wright, MD

Herbert Lourie Professor of Neurological
Surgery
Professor of Orthopaedic Surgery
Co-Director, Neurosurgery Spine
Fellowship
Department of Neurological Surgery
Washington University School of
Medicine
St. Louis, Missouri

Scott Yang, MD

Resident Physician
Orthopaedic Surgery
University of Virginia
Charlottesville, Virginia

Jack E. Zigler, MD

Medical Director, Co-Director of
Fellowship Program
Texas Back Institute
Plano, Texas

Vinko Zlomislic, MD

Assistant Clinical Professor
Department of Orthopaedic Surgery
University of California, San Diego
San Diego, California

Foreword to the First Edition

It seems fair to say that the development of spine surgery over the past 50 years has been nothing short of breathtaking. Advances in mechanical engineering and biomaterials as well as increasing anatomic sophistication have led to a surge of surgical treatment options for patients with spinal disorders. During this period, the care of spinal disorders has matured from a peripheral possibility requiring some improvisational management skills to a highly diversified specialty in its own right. On the publications side, there has been a similar increase in the number of textbooks and journals dealing with spinal disorders. Several of the classic textbooks on the spine have blossomed into multivolume tomes containing highly differentiated discussions on the many complex issues surrounding this subject. The result, borrowing the words of Thomas De Quincey (1785-1859), is that “Worlds of fine thinking lie buried in the vast abyss..., never to be disinterred or restored to human admiration” (from Coleridge’s “Reminiscences of the English Lake Poets”). Indeed, the somewhat overwhelming plethora of spine publications has led to frequently heard inquiries to the tune of “What should I read first?” and “Where can I find a quick description of ...?” by many involved in spine care.

It certainly is a privilege to have been asked to provide introductory words to a refreshingly novel yet thorough approach toward presenting this increasingly large body of knowledge in the world of spinal surgery to a widely differing audience. The editors of *Operative Techniques: Spine Surgery*, Alexander Vaccaro and Eli Baron, draw from an extensive clinical background across surgical specialty lines and have a nearly unparalleled research background, as any Medline search will readily demonstrate. They have taken the challenge of information overflow head-on by providing a meaningful condensation of the myriad surgical techniques available and presenting it in a well-structured and meaningful fashion. The reader will find helpful the organization of each procedure into sections on Surgical Anatomy, Positioning, Portals and Exposures, and step-by-step surgical plans, accompanied by subsections on Pearls and Pitfalls. The open-ended questions of spine surgery are addressed in straightforward fashion in the subsections on Controversies. The latter will pique the interest of even seasoned spine surgeons as they invite thought-provoking deliberations on how to further develop the field of spine surgery. Key references are listed in an evidence-based bibliography, with brief synopses of some of the most relevant publications. The quality of the state-of-the-art illustrations are in a way emblematic of this book, with their concise yet eminently detailed depictions of anatomy providing meaningful assistance for a brief review of a specific area of interest.

Undoubtedly this book will be an asset to a wide array of health providers associated with spine care for the eminently approachable and resource-rich material that it provides.

Jens R. Chapman

Professor

HansJörg Wyss Endowed Chair

Chief of Spine Service

Departments of Orthopaedic and Neurologic Surgery

University of Washington School of Medicine

Seattle, Washington

Preface

A plethora of textbooks on spinal surgery are available today. Most provide an overview of the general science of spinal care or are intended as a reference text for specific spinal procedures. They include the background on a particular topic, its clinical presentation, treatment options, and outcomes. Alternatively, they may provide a review of the nuances of a pathologic condition, including a discussion of the nonoperative and operative treatments with case examples.

This book is intended to serve a much different purpose. Although some atlases of spine surgery exist, none are meant to serve as an operating room companion. We envision this text as an indispensable tool for spine surgeons who want to accent their knowledge and exposure to interesting and commonly performed surgical procedures encountered in daily practice. Within the pages of this book, highly experienced practitioners present 40 of the most commonly performed spinal procedures. Each chapter includes step-by-step illustrations of spinal procedures, along with practical expert advice. Many pearls of wisdom are conveyed by the authors to assist in the learning curve and avoid the commonly experienced pitfalls encountered by many practitioners.

We believe this text represents a source of information that will be used repeatedly by the busy spinal clinician. Surgeons will find they want to consult with this text routinely before embarking on a particular procedure, to feel comfortable and confident regarding their chosen techniques. A collection of videos that illustrates master practitioners performing their trademark surgical procedures as they counsel and guide the reader through each surgical step is available at ExpertConsult.com. This addition wonderfully complements the overall appeal of this learning aid.

We hope this text serves as a valuable resource, not only to orthopaedic surgeons, neurosurgeons, and surgical trainees such as residents and fellows, but also to physician assistants, nursing staff personnel, and anyone involved in the operative care of patients undergoing spinal surgery.

Eli M. Baron, MD
Alexander R. Vaccaro, MD, PhD

Video Contents

Section I Cervical Spine

- PROCEDURE 3** Anterior Odontoid Resection: The Transoral Approach
Video 3.1 Anterior Odontoid Resection
David Choi, H. Alan Crockard
- PROCEDURE 4** Odontoid Screw Fixation
Video 4.1 Odontoid Screw Fixation
Ronald Apfelbaum, Daniel Fassett
- PROCEDURE 8** Cervical Total Disk Replacement
Video 8.1 Lumbar Disk Arthroplasty
Rick Delamarter
- PROCEDURE 14** Posterior Cervical Osteotomy Techniques
Video 14.1 Cervicothoracic Deformity Correction
Leonel A. Hunt, Gabriel E. Hunt, Neel Anand, Brian Perri
- PROCEDURE 16** Posterior Cervical Foraminotomy, Microdiscectomy
Video 16.1 Posterior Cervical Foraminotomy and Microdiscectomy
Lindsay Ross, Hooman Melamed, Eli M. Baron, J. Patrick Johnson, Robert S. Bray, Jr.

Section II Thoracic Spine

- PROCEDURE 20** Operative Management of Scheuermann Kyphosis
Video 20.1 Correction of Scheuermann Kyphosis
Thomas J. Errico
- PROCEDURE 21** Resection of Intradural Intramedullary or Extramedullary Spinal Tumors
Video 21.1 Intramedullary Tumors
George Jallo
- PROCEDURE 22** Endoscopic Thoracic Discectomy
Video 22.1 Endoscopic Thoracic Discectomy
J. Patrick Johnson, Stepan Kasimian

Section III Lumbar Spine

- PROCEDURE 35** Pedicle Subtraction Osteotomy for Fixed Sagittal Imbalance
Video 35.1 Smith Petersen Osteotomy and Lumbar Pedicle Subtraction Osteotomy
Keith Bridwell, Luke Zebala
- PROCEDURE 40** Transforaminal Lumbar Interbody Fusion
Video 40.1 Transforaminal Lumbar Interbody Fusion
Neel Anand, Kamal Woods, Eli M. Baron

MISCELLANEOUS **Video 1 C1-C2 Posterior Cervical Fixation***Christopher Ames, Jae Taek Hong***Video 2 Minimally Invasive Deformity Correction and Fusion***Neel Anand, Eli Baron***Video 3 Unilateral Laminotomy with Bilateral Microdecompression
(Lumbar Internal Laminectomy)***Neel Anand, Sunil Jeswani, Eli M. Baron*

PROCEDURE 1

Closed Cervical Skeletal Tong Placement and Reduction Techniques

Michael J. Vives and Colin Harris

INDICATIONS

Subaxial cervical fractures with malalignment.

Unilateral and bilateral subaxial cervical facet dislocations.

Displaced odontoid fractures, selected types of hangman's fractures, and C1-2 rotary subluxations.

Examination/Imaging

- A thorough neurologic examination should be documented before the procedure.
- High-quality imaging of the cervical spine (including visualization of the occipital-cervical and cervical-thoracic junctions) should be obtained before reduction attempts (Fig. 1.1).

SURGICAL ANATOMY

- Correct pin placement site is 1 cm above the pinna, in line with the external auditory meatus and below the equator of the skull (Figs. 1.2 and 1.3).
- The temporalis muscle and superficial temporal artery and vein are at risk if pins are placed too anterior.

INDICATIONS PITFALLS

- Patient must be awake, alert, and cooperative.
- Coexistence of skull fractures in the areas of pin placement may contraindicate tong placement.

INDICATIONS CONTROVERSIES

- Magnetic resonance imaging (MRI) before closed reduction of dislocated facets, to exclude an associated disk herniation, is advocated by some.
- For awake, alert patients, closed reduction may be attempted without MRI. If closed reduction fails, MRI should be obtained before operative reduction under general anesthesia.

TREATMENT OPTIONS

- Open reduction by anterior or posterior approach
- Anterior (or combined anterior-posterior) approach is commonly recommended if magnetic resonance imaging shows large associated disk herniation at the level of the dislocation.

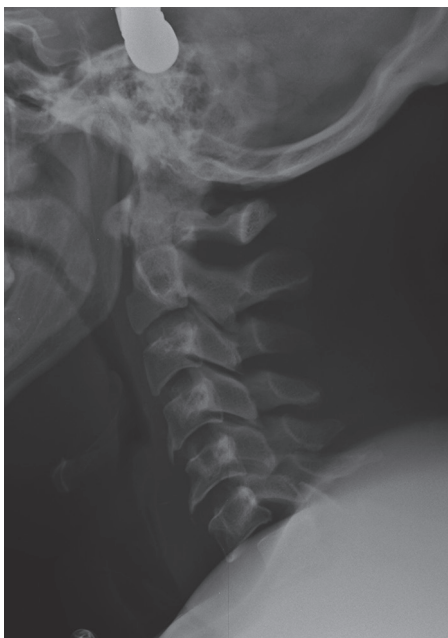

FIGURE 1.1

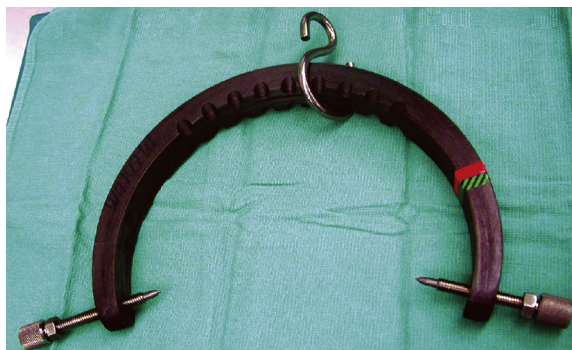

FIGURE 1.2

POSITIONING PEARLS

- Reverse Trendelenburg position or the use of arm and leg weights can help prevent the patient from sliding to the top of the bed as weights are added.
- When the dislocation occurs near the cervicothoracic junction, visualization on lateral imaging may be difficult. Using appropriate lead apron, thyroid shield, and eyewear, a practitioner may need to carefully pull down on the arms from the foot of the bed while the image is taken.

POSITIONING PITFALLS

Because frequent radiographs and close monitoring are necessary during reduction attempts, the emergency room (trauma bay), the operating room, or an intensive care unit are preferred settings.

PLACEMENT PEARLS

- Posterior pin placement will apply a flexion moment to the cervical spine.
- Anterior pin placement will apply an extension moment to the cervical spine.

PLACEMENT PITFALLS

- Placement of the pins too superior (above the equator) increases risk of pullout.
- Placement of the pins too anterior may result in injury to the superficial temporal vessels.

STEP 1 PEARLS

Standing at the head of the bed during tong placement facilitates symmetric positioning of the tongs.

STEP 2 EQUIPMENT

Magnetic resonance imaging-compatible graphite tongs and titanium pins have lower failure loads because of deformation. Stainless steel tongs are therefore recommended if greater than 50 lbs of traction are anticipated.

STEP 2 PITFALLS

- Overtightening can result in penetration of the inner table of the calvarium, leading to cerebral abscess or hemorrhage.
- Check for all proper components before starting the procedure. Occasionally, the spring-loaded pin may be missing from the set!

EQUIPMENT PEARLS

Small doses of intravenous diazepam can be administered to aid in muscle relaxation. The patient should, however, be kept awake and conversive throughout.

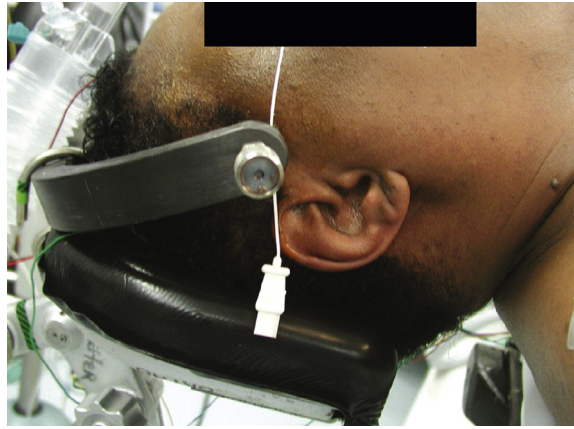

FIGURE 1.3

POSITIONING

- The patient is positioned supine on the operative table, Stryker table, or Roto-Rest bed.

PORTALS/EXPOSURES

- The skin is prepared with a povidone-iodine solution.
- Shaving or skin incisions are not necessary with the use of tapered Gardner-Wells pins.
- Hair, however, can get wrapped around the pin during insertion. Thoroughly soaking the area with the preparation solution facilitates parting long hair in the area and helps prevent this.
- Local anesthetic is used to infiltrate the skin and down to the skull periosteum.

PROCEDURE**Step 1**

- The pins are angled upward slightly and simultaneously tightened until the spring-loaded force indicator (found on one of the two pins) protrudes 1 mm above the flat surface of the pinhead (Fig. 1.4).



FIGURE 1.4

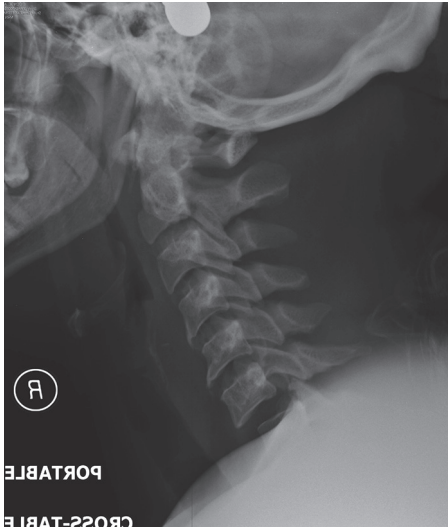

FIGURE 1.5

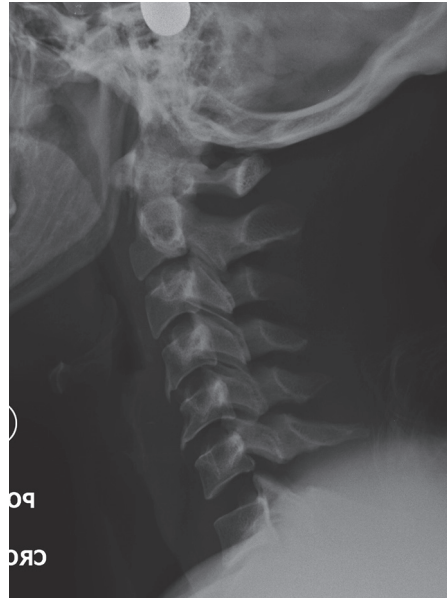

FIGURE 1.6

Step 2

- An initial weight of 10 lbs is applied.
- The neurologic examination is repeated and a lateral radiograph is taken.

Step 3

- Weights are increased at 5- to 10-lb increments at intervals of 20 to 30 min to overcome muscle spasm and to obtain a soft tissue creep effect.
- Serial neurologic examinations and radiographs are obtained after each increase in weight.

Step 4: Reduction of Unilateral Facet Dislocation

- Manipulation may assist in the final reduction of dislocated facets.
- An axial load is applied to the normal facet while the head is rotated 30 to 40 degrees past midline in the direction of the dislocated facet (Fig. 1.7).
- Stop the reduction once resistance is felt, and verify the reduction radiographically.

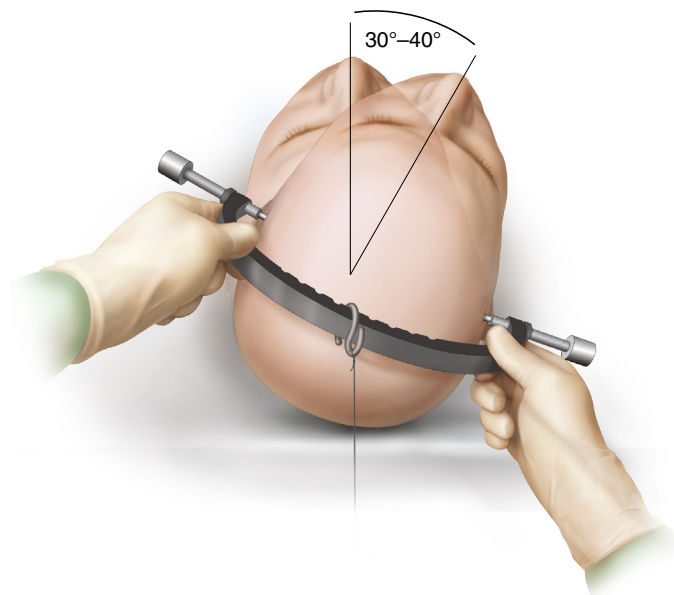


FIGURE 1.7

PITFALLS

A small amount of weight (10 lbs) is used initially to avoid overdistraction of unstable injury patterns, such as occiput instability at the occipital-cervical junction.

STEP 3 PEARLS

- To reduce a facet dislocation that is not associated with a fracture, a flexion moment helps unlock the dislocated facet(s) (Figs. 1.5 and 1.6).
- This can be achieved by posteriorly placed pins or by raising the height of the pulley.

STEP 3 PITFALLS

If overdistraction or neurologic deterioration occurs, the weights should be immediately removed.

STEP 3 EQUIPMENT

- In general, the amount of weight required depends on the level of the injury (5 kg per level).
- More weight is generally required to reduce a unilateral facet dislocation than a bilateral facet dislocation.

STEP 4 CONTROVERSIES

Some authors have recommended weight limits of 66 to 70 lbs. Other authors have reported use of up to 140 lbs.

STEP 4 PEARLS

Facets should be distracted to a perched position before attempting manipulative reduction.

STEP 5 PEARLS

Facets should be distracted to a perched position before attempting manipulative reduction.

STEP 5 PITFALLS

An irreducible bilateral facet dislocation is unstable and should be treated with urgent open reduction (after magnetic resonance imaging evaluation is performed).

POSTOPERATIVE PEARLS

A Rota-Rest bed can be useful at this stage while the patient awaits definitive treatment.

POSTOPERATIVE PITFALLS

- Tongs should be retightened 24 hours after initial application until the indicator again protrudes 1 mm from the flat surface of the pinhead.

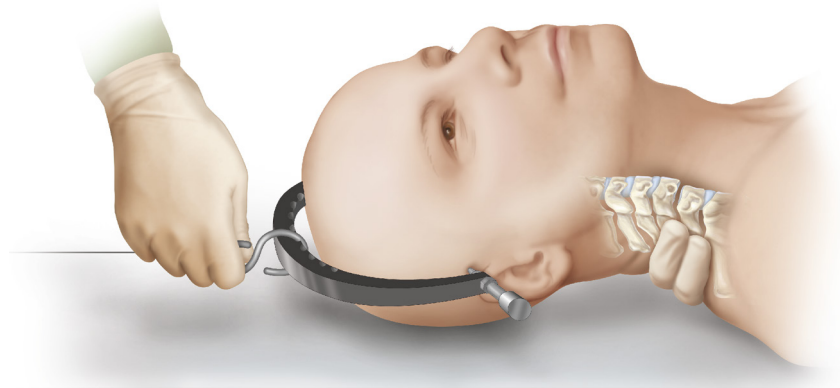


FIGURE 1.8

Step 5: Reduction of Bilateral Facet Dislocation

- An anteriorly directed force is applied just caudal to the level of the dislocation, which is usually palpable as a stepoff in the spinous processes (Fig. 1.8).
- The head is rotated 30 to 40 degrees beyond midline toward one side, and then the maneuver is repeated toward the opposite side if successful.

POSTOPERATIVE CARE AND EXPECTED OUTCOMES

- After reduction is achieved, traction weight typically can be reduced to about 10 to 20 lbs.

EVIDENCE

- Arnold PM, Brodke DS, Rampersaud YR, et al. Differences between neurosurgeons and orthopaedic surgeons in classifying cervical dislocation injuries and making assessment and treatment decisions: a multicenter reliability study. *Am J Orthop*. 2009;38:E156-61.
Twenty-nine spine surgeons reviewed 10 cases of cervical dislocation injuries. Although interpretation of the imaging was similar between spine surgeons of orthopaedic and neurosurgical backgrounds, differences of opinion regarding need for pretreatment magnetic resonance imaging and management were seen between the specialties.
- Cotler HB, Miller LS, DeLucia FA, Cotler JM, Davne SH. Closed reduction of cervical spine dislocations. *Clin Orthop Rel Res*. 1987;214:185-99.
A cadaver study was performed to delineate the anatomy of pin placement, in addition to a review of 24 patients with cervical facet dislocations treated with closed reduction and traction. Ninety percent of patients improved at least one Frankel grade, and 71% were treated successfully with closed reduction.
- Cotler JM, Herbison GJ, Nasuti JF, Ditunno Jr JF, An H, Wolff BE. Closed reduction of traumatic cervical spine dislocation using traction weights up to 140 pounds. *Spine*. 1993;18:386-90.
This review of 24 cases demonstrates that traction weights of up to 140 lbs can be used safely in the reduction of facet dislocations without associated fractures. Seventeen patients in this series required over 50 lbs for successful reduction, with total time to successful reduction ranging from 8 to 187 minutes. None of the patients had worsening neurologic status during or after the procedure.
- Grauer JN, Vaccaro AR, Lee JY, et al. The timing and influence of MRI on the management of patients with cervical facet dislocations remains highly variable: a survey of members of the Spine Trauma Study Group. *J Spinal Disord Tech*. 2009;22:96-9.
Questionnaire study presented to 25 fellowship trained spine surgeons. Substantial variability in the timing and use of magnetic resonance imaging (MRI) and closed reduction techniques for patients with cervical facet dislocations were demonstrated. Neurosurgeons were significantly more likely than orthopaedic surgeons to order an MRI before open or closed treatment.
- Littleton K, Curcin A, Novak V, Belkoff S. Insertion force measurement of cervical traction tongs: a biomechanical study. *J Orthop Trauma*. 2000;14:505-8.
Biomechanical study on cadaver specimens that demonstrated that overtightening of pins can result in substantial increases in force exceeding that needed to penetrate the skull. In addition, the possible complications of tong placement are discussed.

Vaccaro AR, Falatyn SP, Flanders AE, Balderston RA, Northrup BE, Cotler JM. Magnetic resonance evaluation of the intervertebral disc, spinal ligaments, and spinal cord before and after closed traction reduction of cervical spine dislocations. *Spine*. 1998;24:1210-7.

Prospective study using magnetic resonance imaging (MRI) to evaluate the incidence of intervertebral disk herniations and ligamentous injuries before and after closed traction reduction of facet dislocations. Of 11 patients in the study, 9 had successful closed reduction, 2 had disk herniations on pretraction MRI, and 5 had disk herniations on posttraction MRI. None of the patients who sustained disk herniations during the reduction developed neurologic deficits.

Vital J, Gille O, Sénégas J, Pointillart V. Reduction technique for uniarticular and biarticular dislocations of the lower cervical spine. *Spine*. 1998;23:949-54.

This is a review of 168 consecutive cases of lower cervical facet dislocations treated with gradual traction, followed by closed reduction under anesthesia and finally open reduction when necessary. Fifty-nine percent of unilateral dislocations and 73% of bilateral dislocations were treated successfully with closed reduction techniques or traction alone.

Halo Placement in the Pediatric and Adult Patient

Neil A. Manson and Howard S. An

INDICATIONS PITFALLS

- Skull injury
- Skin injury
- Sensory loss (spinal cord injury)
- Associated injury: thoracic, abdominal, musculoskeletal

INDICATIONS

Jefferson fracture
Odontoid fracture: type III or specific type II
Hangman's fracture: type II
One-column bony cervical spine fracture
Fracture in ankylosing spondylitis
Preoperative traction or stabilization
Postoperative stabilization of arthrodesis, infection, tumor resection

Examination/Imaging

- Computed tomography (CT) is required to define fracture morphology and stability and rule out adjacent or noncontiguous injuries (Como et al, 2009) (Fig. 2.1A–C).

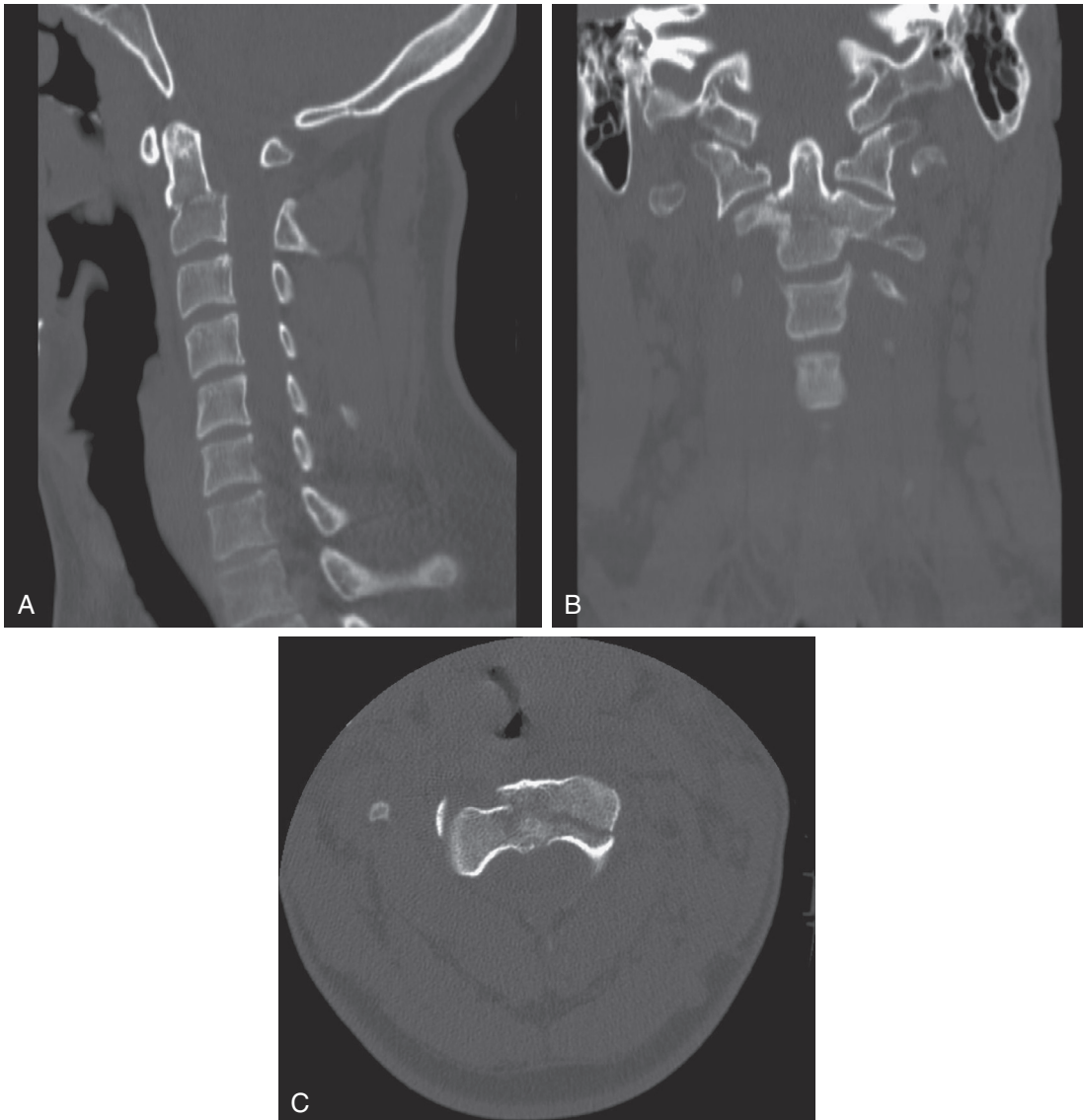


FIGURE 2.1 A to C Courtesy Dr. G. Kolyvas.

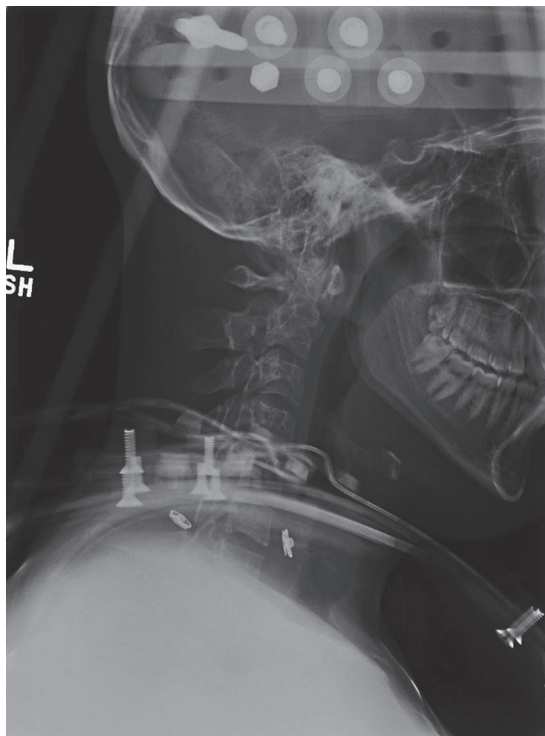


FIGURE 2.2 Courtesy Dr. G. Kolyvas.

- Radiographs confirm fracture reduction and cervical alignment following halo application and maintenance of these parameters during treatment (Fig. 2.2).

SURGICAL ANATOMY

Relevant anatomy pertains to pin placement. Correct placement prevents direct neural or vascular injury, inner calvarial plate penetration, and pin migration, while providing adequate strength of fixation.

Anterior pins

- Safe zone of placement: anterolateral skull, 1 cm superior to the orbital rim (eyebrow), above the lateral two-thirds of the orbit, and below the greatest circumference of the skull
- Structures to avoid (medial to lateral): frontal sinus, supratrochlear nerve, supraorbital nerve, zygomaticotemporal nerve, temporal artery, temporalis muscle (Kang et al, 2003) (Fig. 2.3A–B)

Posterior pins

- Placement: posterolateral skull, at 4 o'clock and 8 o'clock positions or approximately diagonal to the corresponding contralateral anterior pins, below the greatest circumference of the skull and above the upper helix of the ear.
- There are no specific structures to avoid.

POSITIONING

- Typical halo application is performed in the supine position using inline cervical stabilization by a knowledgeable care provider while two providers apply the apparatus.
- For stable fractures or nonfracture treatment, halo application in the upright position is preferred to optimize cranial-cervical-thoracic alignment and patient comfort.
- A cervical collar can provide additional stability until the halo construct is completed.

TREATMENT OPTIONS

- Consider rigid collar immobilization in a compliant, young, healthy patient with a minimally displaced, stable fracture.
- Consider surgical intervention in an elderly or noncompliant patient with an unstable or displaced fracture, a fracture of high nonunion potential, ligamentous injury, or associated injury.
- Move to surgical intervention for failure of halo fixation: loss of fracture alignment, symptomatic nonunion, neurologic deterioration.

PEARLS

- It is preferable if the patient is awake and responsive to report any progression of pain or neurologic loss. Light sedation (midazolam) may be provided for comfort.
- Crash-cart access should be assured during halo application.

EQUIPMENT

Ensure that all necessary equipment is available before halo application (adapted from Botte et al, 1995):

- Sterile halo ring/crown in preselected size
- Sterile halo pins
- Halo torque screwdrivers or breakaway wrenches
- Halo-pin locknuts
- Halo vest in preselected size
- Halo upright post and connecting rods
- Headboard
- Spanners or ratchet wrenches
- Iodine solution
- Iodine ointment
- Sterile gloves
- Syringes
- Needles
- Lidocaine for injection
- Crash cart (including airway supplies, endotracheal tube)

Three people are recommended during application.

Measure head and chest circumference and obtain appropriate size halo and vest before halo application.

POSITIONING PEARLS

Before supine halo application, consider positioning the vest's posterior shell under the patient to minimize movements during the application process. This could take place, for example, when transferring the patient to an operating room table for the application process.

POSITIONING PITFALLS

The patient's eyelids should be closed and relaxed during application. Pin malposition or sliding during insertion may tent the periorbital tissues and limit eyelid closure. This should be avoided.

CONTROVERSIES

The traditional construct utilizes four pins of 8 inch-pounds, torque each. Cadaver and clinical studies have demonstrated improved stability and decreased pin-site complications with six- and eight-pin constructs.

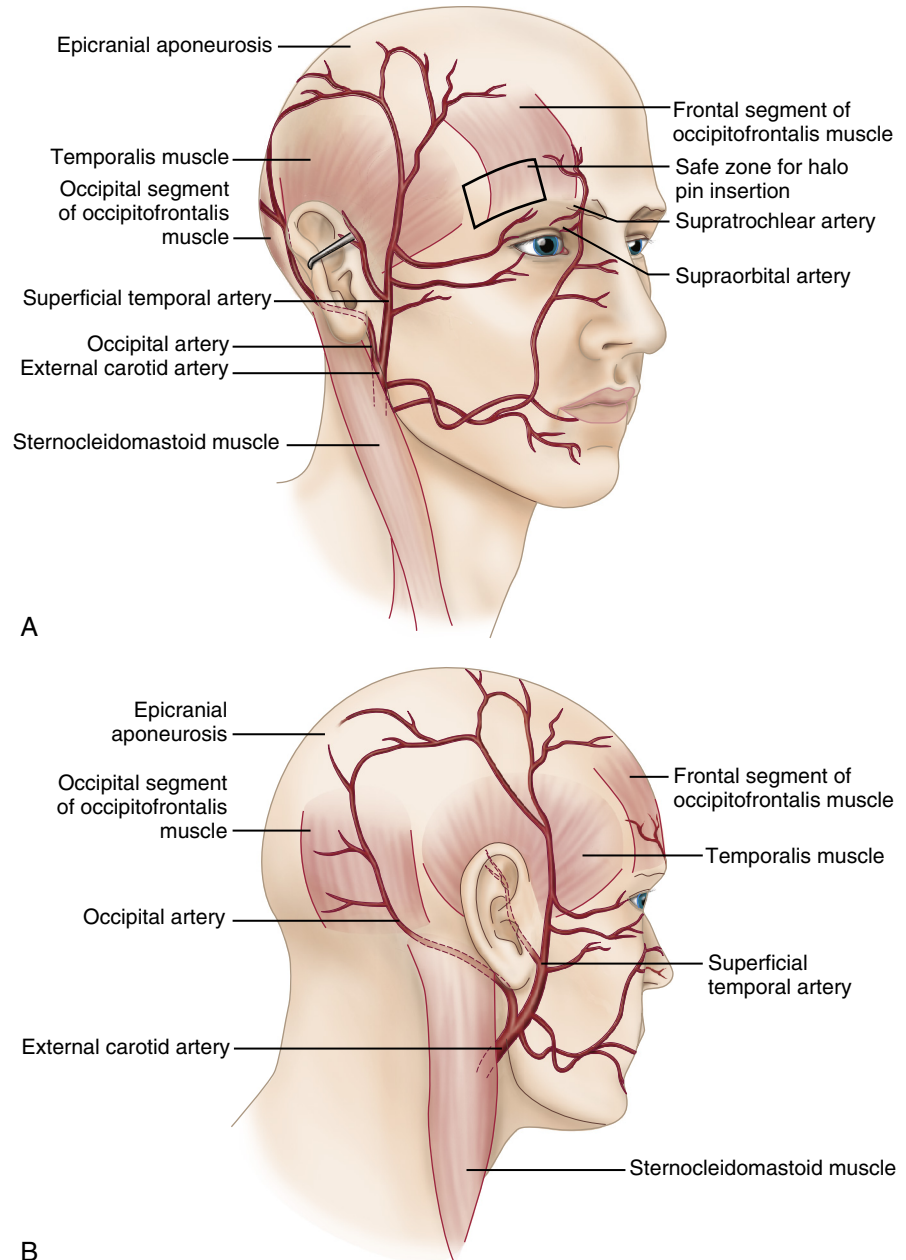
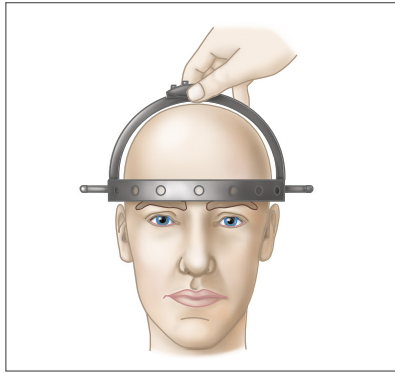


FIGURE 2.3 A, Anterolateral view. B, Posterolateral view.

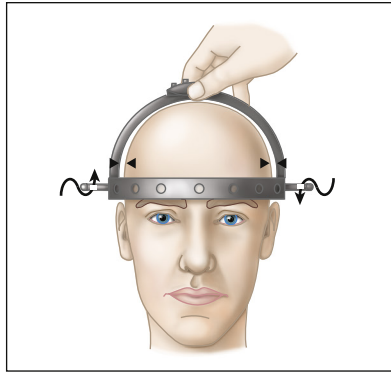
PROCEDURE: HALO APPLICATION

Step 1: Crown and Pin Placement

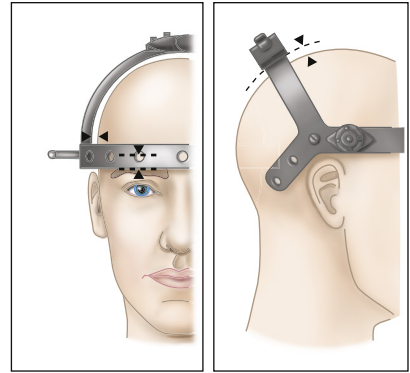
- Identify proper crown size: small for 48- to 58-cm head circumference, large for 58- to 66-cm head circumference. Choose the smallest crown size that allows at least 1 cm of space between head and crown.
- Identify proper pin sites as previously described in the “Surgical Anatomy” section of this chapter.
- Shave hair at posterior sites and cleanse skin at all sites with Betadine or alcohol preparation.
- Instruct patient to keep eyes closed and face musculature relaxed.
- Use positioning pins to align and maintain halo position: 1 cm above eyebrow and top of ear and below largest circumference of the head.
- Inject 1% lidocaine with epinephrine at the intended pin sites. Pass the needle through the pin holes of the halo ring to optimize anesthetic positioning. Inject from skin though to periosteum for patient comfort during pin placement.
- Traditionally, four pins provide halo fixation.



1. Position halo crown on patient's head.

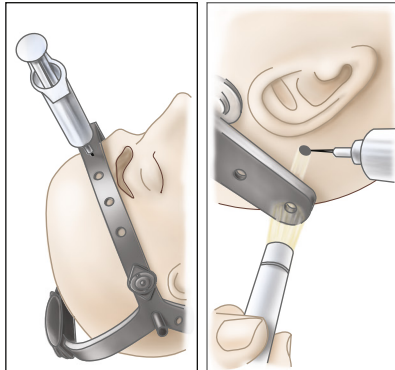


2. Adjust halo crown and positioning pads, ensuring 1-cm separation between the crown and the head at the pin sites.

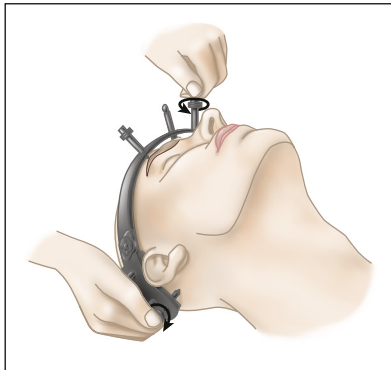


3. Ensure, with the aid of the positioning pads, that the halo crown position and alignment are correct. The crown should be

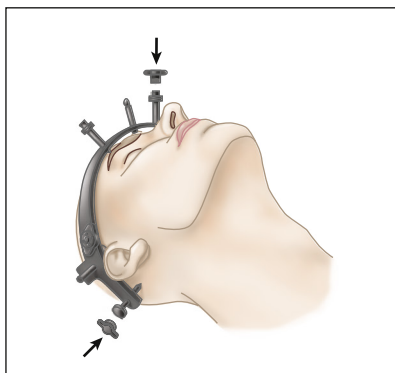
- 1 cm from the skin at the pin sites
- 1 cm above the eyebrows
- Not in contact with the ears
- The posterior pin should be below the equator of the skull.
- If there is a capital arch it should not touch the top of the head.



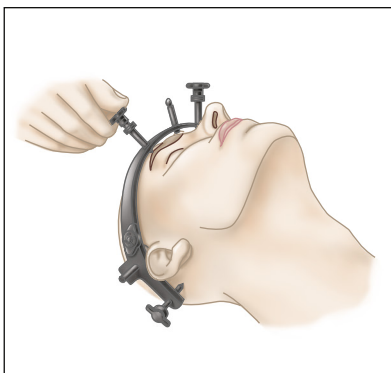
4. A needle should be used through the selected pinholes to provide local anesthetic to the periosteum and skin. Make sure the eyes are closed while injecting through the anterior pin sites.



5. Insert the skull pins in selected holes, tightening opposing pins until they penetrate the skin. The patient's eyes should remain closed and the halo crown should be maintained in position by another person holding the crown. If the crown becomes mispositioned, the pins should be backed out and the crown should be repositioned.



6. Either a torque wrench preset to 8 lbs or manufacturer-supplied torque-limiting cap should be used to tighten opposing pins two turns at a time.



7. For sets with torque-limiting caps, this should be done until the caps break off.

FIGURE 2.4

- Initial skin incision at the pin sites is not necessary and does not influence scar formation.
- Placement of all pins should occur simultaneously to maintain halo position and balance pin forces. Simultaneous advancement to the skin, through the soft tissue, and to the skull should occur, with final security achieved with release of the breakaway torque-limiting caps (Fig. 2.4) (Depuy Spine Bremer Halo Systems technical monograph).

- Confirm torque to 8 inch-pounds utilizing a torque wrench.
- With pins secure to the skull, tighten the locking nuts to secure the pins to the halo ring.
- Areas of tethered or tented skin surrounding the pins can be released using a scalpel as needed.

Step 2: Vest Application

- Identify proper vest size based on chest circumference 5 cm below the xiphoid process and patient height: short vest for circumference of 70 to 97 cm and height less than 170 cm, large vest for circumference up to 112 cm and height greater than 170 cm.
- Inline cervical stabilization is maintained as required.
- Logrolling or trunk elevation allows placement of the posterior shell of the vest ([Magnum and Sunderland, 1993](#)) ([Fig. 2.5](#)).
- The anterior shell is positioned and secured to the posterior shell.
- The vertical bars are secured on the vest and positioned for fixation to the crown.

STEP 2 PITFALLS

Patient obesity may necessitate custom vest sizing or preclude halo management altogether.

STEP 3 PITFALLS

A linear correlation has been demonstrated between increased cervical extension and increased risk of laryngeal penetration and aspiration, secondary to swallowing dysfunction. Optimizing sagittal alignment can limit this significant complication ([Morishima, 2005](#)).

STEP 3 PEARLS

Application tools should be kept at the bedside or taped to the vest in case emergency removal of the vest is required.

Step 3: Construct Alignment

- Each posterior vertical bar is attached to its ipsilateral anterior bar by the horizontal crown connector. Loosen all joints within the construct to allow appropriate alignment of the bars relative to the crown.
- Time spent in optimizing bar position before attachment to the crown will minimize patient discomfort and risk of loss of cervical alignment, which can occur when adjustments are made with the construct secured to the crown ([Magnum and Sunderland, 1993](#)) ([Fig. 2.6](#)).
- Ensure symmetry between left and right bar constructs.
- Final tightening of all joints of the crown and vest construct should provide security with no concern for loosening.
- Only when final stability is obtained may the rigid collar be removed and inline stabilization released.
- Final cranial-cervical-thoracic alignment is crucial to (1) maintain fracture alignment; (2) provide patient comfort; and (3) optimize patient function, specifically concerning normal vision and swallowing ability.

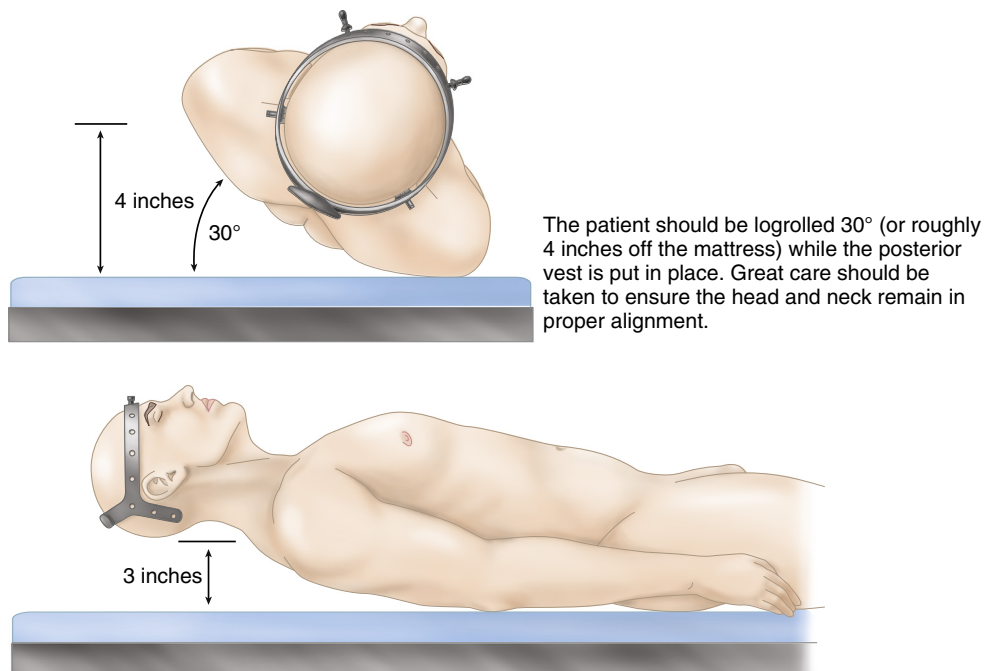


FIGURE 2.5

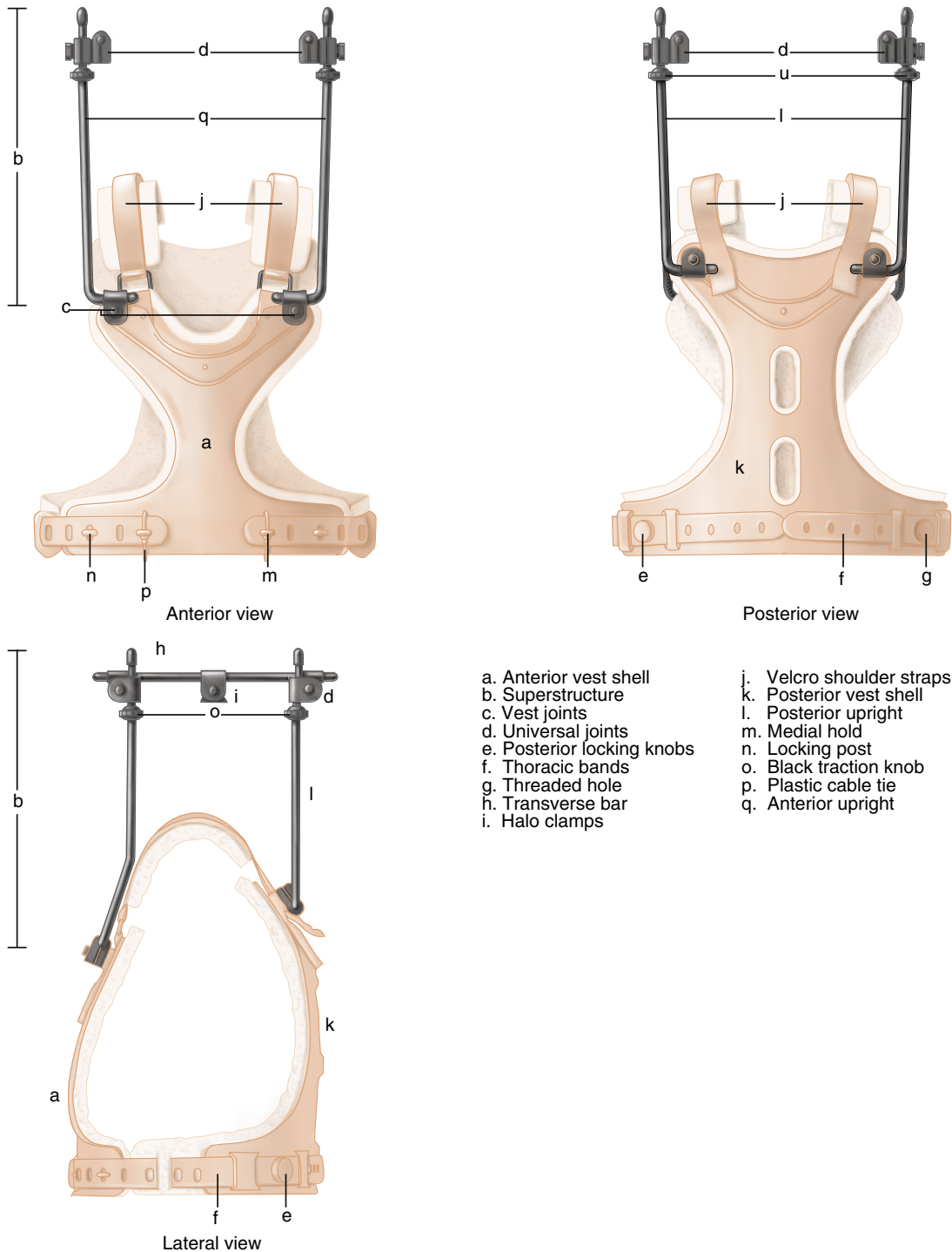
Step 4: Follow Up

Immediate follow up

- Imaging is required to confirm cervical alignment and/or fracture alignment. Lateral radiograph is standard.
- If possible, sit patient upright to assess cervical alignment, construct security, and patient comfort.

Short-term follow up

- Further imaging (radiographs or computed tomography) is obtained as needed.
- Retightening of pins is performed at 24 hours after halo application. Locking nuts are first loosened, and each pin is retightened to 8 inch-pounds utilizing the torque wrench. Locking nuts are retightened. All joints of the crown-vest construct are retightened.



- a. Anterior vest shell
- b. Superstructure
- c. Vest joints
- d. Universal joints
- e. Posterior locking knobs
- f. Thoracic bands
- g. Threaded hole
- h. Transverse bar
- i. Halo clamps
- j. Velcro shoulder straps
- k. Posterior vest shell
- l. Posterior upright
- m. Medial hold
- n. Locking post
- o. Black traction knob
- p. Plastic cable tie
- q. Anterior upright

FIGURE 2.6

PEARLS

- Halo placement has shown effectiveness in children as young as 10 months old (Arkader, 2007).
- Halo-related complication types and rates are similar in adults and children; however, toddlers are at greater risk of falls and thus limited and carefully supervised ambulation is recommended (Caird, 2006; Arkader, 2007).

PITFALLS

Beware of halo use in the extremes of ages. In the very young, skull thickness and frequent falls during typical pediatric ambulation increase complications. In the elderly, cardiopulmonary dysfunction leads to significantly increased morbidity and mortality. Some clinicians question the safety of this tool in the elderly (Majercik et al, 2005).

POSTOPERATIVE PEARLS

- Careful halo application emphasizing pin placement, torque, and reevaluation combined with diligent pin-site care has been proven to decrease the rate of complications associated with halo fixation.
- A retorque regimen should be considered. Pin retorque at 24 and 48 hours and every 2 to 3 weeks thereafter may decrease pin site complications or need for replacement (Fraser, 2015).

POSTOPERATIVE PITFALLS

- Complications, although virtually ensured during the treatment period, are most often minor and can be well controlled with diligent care.
- Complications related to halo application include the following (adapted from Botte et al, 1995):
 - Pin loosening: 36% to 60%
 - Pin-site infection: 20% to 22%
 - Severe pin discomfort: 18%
 - Ring migration: 13%
 - Pressure sores: 4% to 11%
 - Redislocation: 10%
 - Restricted breathing from the vest: 8%
 - Difficulty with arm elevation from the vest: 23%
 - Pneumonia: 5%
 - Nerve injury: 2%
 - Bleeding at pin sites: 1%
 - Dural puncture: 1%
 - Neurologic deterioration: 1%

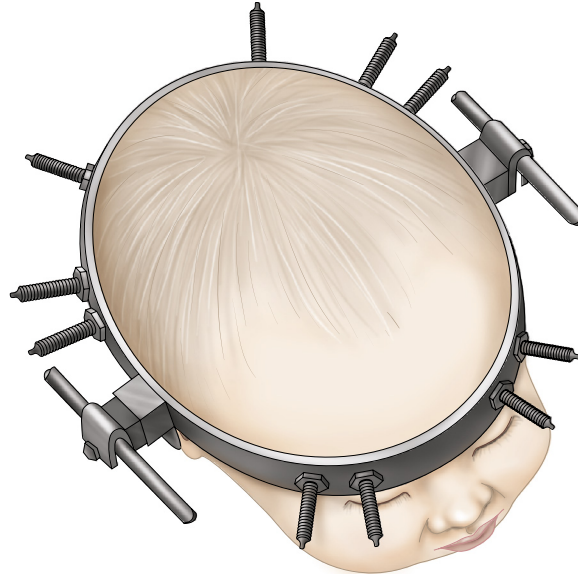


FIGURE 2.7

PROCEDURE: HALO APPLICATION IN THE CHILD OR INFANT

- Relevant differences in halo application in the pediatric population pertain to skull thickness, skull hardness, and the presence of open cranial sutures. Cranial penetration must be avoided.
- Consider general anesthesia depending on age and diagnosis. Although an anesthetized patient cannot provide feedback regarding neurologic status, this may be irrelevant in the very young child or infant.
- A custom crown and vest may be necessary, although pediatric sizes are available.
- Consider preapplication CT to identify skull thickness and cranial suture locations and to plan pin placement (Mubarak et al, 1989) (Fig. 2.7).
- Eight to 10 pins are used to provide stable fixation at lower torque forces.
- Torque to 2 inch-pounds using a torque wrench. Consider torquing to finger tightness only in the very young child or infant.

POSTOPERATIVE CARE AND EXPECTED OUTCOMES**Long-term follow up**

- Pin retightening at 1 week after halo application
 - Pins require removal and replacement at a new site for infection or if no resistance is met within the first few turns during retightening.
- Pin-site care twice daily
- Inspection for crusting, drainage, redness, or swelling
- Cleansing using hydrogen peroxide (full or half strength)
- Reporting any changes to the care team
- Patient education regarding self-care and independence: [Magnum and Sunderland \(1993\)](#) provide valuable information.
- Complications are high but manageable through meticulous care and awareness.

Final care

- One-third of patients regard their pin scars as severe. During removal of the halo, the pin sites should be massaged with peroxide-saturated gauze to loosen adhesions between skin and bone. The patient should move the skin over the pin holes for several days to prevent reattachment of adhesions and thus minimize scarring.

EVIDENCE

Arkader A, Hosalkar HS, Drummond DS, Dormans JP. Analysis of halo-orthoses application in children less than three years old. *J Child Orthop.* 2007;1:337-44.

A retrospective chart review of patients younger than 3 years treated with halo-vest. Pin site complications were observed in 2 patients. Issues pertaining to this age group are discussed.

- Botte MJ, Byrne TP, Abrams RA, Garfin SR. The halo skeletal fixator: current concepts of application and maintenance. *Orthopedics*. 1995;18:463-71.
An excellent review of the halo-vest, including development, pin insertion methods, halo-vest application, biomechanics, complication management, and application in children.
- Como JJ, Diaz JJ, Dunham CM, et al. Practice management guidelines for identification of cervical spine injuries following trauma: update from the Eastern Association for the Surgery of Trauma Practice Management guidelines committee. *J Trauma*. 2009;67:651-9.
Expert consensus regarding care and evaluation of the patient with cervical trauma. If imaging is necessary, CT is required.
- Caird MS, Hensinger RN, Weiss N, Farley FA. Complications and problems in halo treatment of toddlers: limited ambulation is recommended. *J Pediatr Orthop*. 2006;26:750-2.
A retrospective chart review of 13 patients with an average age of 26 months. Falls accounted for 30% of reported complications and are cited as an age-related issue necessitating limited and supervised ambulation for these patients.
- Coffey JP, Fraser S. Does routine pin re-torquing of patients wearing a halo-thoracic orthosis reduce the need for pin replacement? *Prostate Ortho Int*. 2015;39:338-41.
A retrospective review of a pin retorquing protocol demonstrating decreased pin-related complications in 170 patients.
- Kang M, Vives MJ, Vaccaro AR. The halo vest: principles of application and management of complications. *J Spinal Cord Med*. 2003;26:186-92.
An excellent review of the halo-vest, including application, biomechanics, and details regarding complications and their causes and treatments.
- Letts M, Girouard L, Yeadon A. Mechanical evaluation of four versus eight-pin halo fixation. *J Pediatr Orthop*. 1997;17:121-4.
A cadaver study confirming 24.2% increase in stiffness for eight-pin versus four-pin construct. The author advocated for eight-pin construct in infants and young children in light of lower torque used in these patients.
- Magnum S, Sunderland PM. A comprehensive guide to the halo brace. *AORN J*. 1993;58:534-46.
An excellent guide regarding halo-vest application, including vest sizing, application, and positioning, as well as postapplication care and patient instructions.
- Majercik S, Tashjian RZ, Biffi WL, Harrington DT, Coiffi WG. Halo vest immobilization in the elderly: a death sentence? *J Trauma*. 2005;59:350-57.
A retrospective chart review comparing cervical spine fracture patients older than 65 years to those 65 years or younger receiving halo-vest, collar, or surgery. Complication rates were similar for both age groups for collar and surgery, but patients older than 65 years demonstrated a 4 times greater mortality risk with halo-vest use (21% vs 5%). Pneumonia and cardiopulmonary arrest accounted for the mortality at rates not observed in the other treatment groups. Halo-vest use should be used as a last resort in the elderly.
- Manthey DE. Halo traction device. *Emerg Med Clin North Am*. 1994;12:771-8.
A review of halo-vest treatment, including indications, relevant anatomy, complications, and care.
- Morishima N, Ohota K, Miura Y. The influence of halo-vest fixation and cervical hyperextension on swallowing in healthy volunteers. *Spine*. 2005;30:e179-82.
A radiographic and electromyographic evaluation of swallowing function on 6 healthy volunteers. Halo-vest immobilization with 52 degree neck extension led to altered swallowing mechanics in all subjects, laryngeal penetration in two subjects, and aspiration in one case.
- Mubarak SJ, Camp JF, Vuletich W, Wenger DR, Garfin SR. Halo application in the infant. *J Pediatr Orthop*. 1989;9:612-4.
A technique guide for halo-vest application in young children. Greater number of pins, lower pin torque, and preapplication identification of suture location and skull thickness are advised.
- Nemeth JA, Mattingly LG. Six-pin halo fixation and the resulting prevalence of pin-site complications. *J Bone Joint Surg Am*. 2001;83:377-82.
A cadaver study and patient chart review. A 6-pin construct load to failure was 171% greater than that of the 4-pin construct. Pin-bone interface issues accounted for the majority of complications observed.
- Polin RS, Szabo T, Bogaev CA, Replogle RE, Jane JA. Nonoperative management of types II and III odontoid fractures: the Philadelphia collar versus the halo vest. *Neurosurgery*. 1996;38:450-7.
A retrospective review of 54 patients treated nonoperatively for type II or III odontoid fractures. Collar use provided equivalent results to halo-vest use and should be considered as first line nonoperative treatment.
- Product monograph. Bremer Halo Crown Traction Set. Bremer Halo Systems, Raynham, Mass. 2003.
Provides specific halo application instructions.