

Operative Techniques: Hand and Wrist Surgery

Third Edition

Kevin C. Chung, MD, MS

Chief of Hand Surgery, University of Michigan Health System
Charles B. G. de Nancrede Professor of Plastic Surgery and Orthopaedic Surgery
Assistant Dean for Faculty Affairs
Associate Director of Global REACH
University of Michigan Medical School
Ann Arbor, Michigan

ELSEVIER

ELSEVIER

1600 John F. Kennedy Blvd.
Ste 1800
Philadelphia, PA 19103-2899

OPERATIVE TECHNIQUES: HAND AND WRIST SURGERY,
THIRD EDITION

ISBN: 978-0-323-40191-3

Copyright © 2018 by Elsevier, Inc. All rights reserved.

No part of this publication may be reproduced or transmitted in any form or by any means, electronic or mechanical, including photocopying, recording, or any information storage and retrieval system, without permission in writing from the publisher. Details on how to seek permission, further information about the Publisher's permissions policies and our arrangements with organizations such as the Copyright Clearance Center and the Copyright Licensing Agency, can be found at our website: www.elsevier.com/permissions.

This book and the individual contributions contained in it are protected under copyright by the Publisher (other than as may be noted herein).

Notices

Knowledge and best practice in this field are constantly changing. As new research and experience broaden our understanding, changes in research methods, professional practices, or medical treatment may become necessary.

Practitioners and researchers must always rely on their own experience and knowledge in evaluating and using any information, methods, compounds, or experiments described herein. In using such information or methods they should be mindful of their own safety and the safety of others, including parties for whom they have a professional responsibility.

With respect to any drug or pharmaceutical products identified, readers are advised to check the most current information provided (i) on procedures featured or (ii) by the manufacturer of each product to be administered, to verify the recommended dose or formula, the method and duration of administration, and contraindications. It is the responsibility of practitioners, relying on their own experience and knowledge of their patients, to make diagnoses, to determine dosages and the best treatment for each individual patient, and to take all appropriate safety precautions.

To the fullest extent of the law, neither the Publisher nor the authors, contributors, or editors, assume any liability for any injury and/or damage to persons or property as a matter of products liability, negligence or otherwise, or from any use or operation of any methods, products, instructions, or ideas contained in the material herein.

Previous editions © 2012, 2008

Library of Congress Cataloging-in-Publication Data

Names: Chung, Kevin C., editor.

Title: Hand and wrist surgery / [edited by] Kevin C. Chung.

Other titles: Operative techniques.

Description: 3rd edition. | Philadelphia, PA : Elsevier, [2018] | Series:

Operative techniques | Includes bibliographical references and index.

Identifiers: LCCN 2016046027 | ISBN 9780323401913 (hardcover : alk. paper)

Subjects: | MESH: Hand--surgery | Orthopedic Procedures--methods | Atlases

Classification: LCC RD559 | NLM WE 17 | DDC 617.5/75059--dc23

LC record available at <https://lccn.loc.gov/2016046027>

Content Strategist: Kayla Wolfe

Senior Content Development Manager: Taylor Ball

Publishing Services Manager: Catherine Jackson

Project Manager: Kate Mannix

Design Direction: Amy Buxton

Illustrations Manager: Lesley Frazier

Printed in China

Last digit is the print number: 9 8 7 6 5 4 3 2 1



Working together
to grow libraries in
developing countries

www.elsevier.com • www.bookaid.org

*To Chin-Yin and William
and
in memory of my mother-in-law, Chun-Huei*

Contributors

Joshua M. Adkinson, MD

Assistant Professor of Surgery
Division of Plastic Surgery
Riley Children's Hospital
Indiana University School of Medicine
Indianapolis, Indiana

Matthew Brown, MD

Hand Fellow
Section of Plastic Surgery
Department of Surgery
University of Michigan
Ann Arbor, Michigan

Kevin C. Chung, MD, MS

Chief of Hand Surgery
University of Michigan Health System
Charles B. G. de Nancrede
Professor of Plastic Surgery and
Orthopaedic Surgery
Assistant Dean for Faculty Affairs
Associate Director of Global REACH
University of Michigan Medical School
Ann Arbor, Michigan

Yuki Fujihara, MD

International Research Fellow
Section of Plastic Surgery
Department of Surgery
University of Michigan
Ann Arbor, Michigan;
Department of Hand Surgery
Nagoya University Graduate School
of Medicine
Nagoya, Japan

Nasa Fujihara, MD

International Research Fellow
Section of Plastic Surgery
Department of Surgery
University of Michigan
Ann Arbor, Michigan;
Department of Hand Surgery
Nagoya University Graduate School of
Medicine
Nagoya, Japan

Aviram M. Giladi, MD, MS

Resident
Section of Plastic Surgery
Department of Surgery
University of Michigan
Ann Arbor, Michigan

Steven C. Haase, MD, FACS

Associate Professor of Surgery
Section of Plastic Surgery
Associate Professor of Orthopaedic
Surgery
University of Michigan Medical School
Ann Arbor, Michigan

Sirichai Kamnerdnakta, MD

International Research Fellow
Section of Plastic Surgery
Department of Surgery
University of Michigan
Ann Arbor, Michigan;
Division of Plastic Surgery
Department of Surgery
Faculty of Medicine
Siriraj Hospital
Mahidol University
Salaya, Thailand

Brian P. Kelley, MD

Resident
Section of Plastic Surgery
Department of Surgery
University of Michigan
Ann Arbor, Michigan

Brett Michelotti, MD

Hand Fellow
Section of Plastic Surgery
Department of Surgery
University of Michigan
Ann Arbor, Michigan

Taichi Saito, MD, PhD

International Research Fellow
Section of Plastic Surgery
Department of Surgery
University of Michigan
Ann Arbor, Michigan;
Orthopaedic Surgery Section
Okayama University
Okayama, Japan

Erika Davis Sears, MD, MS

Assistant Professor of Surgery
Section of Plastic Surgery
Department of Surgery
University of Michigan Medical School
Ann Arbor, Michigan

Jennifer F. Waljee, MD, MPH, MS

Assistant Professor
Section of Plastic Surgery
Department of Surgery
University of Michigan Medical School
Ann Arbor, Michigan

Guang Yang, MD

Associate Professor
Department of Hand Surgery
China-Japan Union Hospital of
Jilin University
Changchun, Jilin Province, Peoples'
Republic of China

Preface

Welcome to the third edition of this classic treatise on hand and wrist operative techniques. There is a general view that new editions are simply updating current information without structurally changing a textbook. However, this third edition is different because every chapter is rewritten and augmented with new pictures and videos to provide a strong foundation for carrying out operations in a safe and efficient manner. For the past two years, my team and I have meticulously collected pictures and videos in anticipation of refurbishing this entire textbook so that it will be consistently high quality in lieu of a multiauthor textbook that may not have a uniform effort. All the operations were done by me and my colleagues at the University of Michigan and organized by my team of international scholars and staff members. I am certain that this textbook will meet your high expectations of my team's work.

As I travel around the world as a visiting professor, I see this textbook on a number of bookshelves and book stores. Many of you have approached me to share your enthusiasm for this book. With such encouragement and fervor to leverage this textbook to provide the best care for our patients, I have worked intensely for several years to produce this book, which sets the standard for meticulous illustrations and pictures, clear scientific writing, and a dazzling array of more than 100 operative videos to cover all procedures in hand surgery. Even though you may have purchased the first and second editions, this third edition provides incremental knowledge to previous editions that makes all three editions a seamless encyclopedic collection of hand surgical procedures. I hope you will treasure this textbook as much as I do. Ultimately, this textbook was made through your prodding and your enthusiasm.

A textbook like this requires many hours of intense effort by everyone involved. I would like to acknowledge my trusted assistants Brianna Maroukis and Helen Huetteman, who worked together to make this book a reality. Furthermore, my international scholars Nasa Fujihara, Yuki Fujihara, Sirichai Kamnerdnakta, Taichi Saito, and Michiro Yamamoto have meticulously captured every picture and video and spent countless hours to organize the pictures and illustrations, as well as editing the videos to ensure the highest quality possible. I would also like to acknowledge Taylor Ball from Elsevier, who has worked with me on all three editions of this textbook. Without his dedication, the book would not be able to be produced on time and presented to you seamlessly. My thanks go to Elsevier's Dolores Meloni, who vouched to the Elsevier leadership that this third edition represents the most creative and comprehensive product in the publishing world. Finally, my tribute to my patients, who are my best mentors; I learned so much by their entrustment of themselves and their family members under my care. Every patient in my practice has had preoperative, intraoperative, and postoperative pictures taken so that I can review their treatment course to reflect and learn from their outcomes. Someone asked me who my best mentor is. Without hesitation, I responded: my patients.

I am eternally grateful to you for your interest and your support of this textbook series. I look forward to seeing this textbook on your shelves. Please do seek me out at national and international meetings so that I can thank you personally for your friendship and encouragement.

Kevin C. Chung, MD, MS

Foreword

It is with great honor and pleasure that I write the foreword for the third edition of *Operative Techniques: Hand and Wrist Surgery*, written by my friend and colleague Dr. Kevin C. Chung. Current readers of hand surgery and plastic surgery texts all know Dr. Chung, the Charles BG de Nancrede Professor of Surgery, Plastic Surgery, and Orthopaedic Surgery at the University of Michigan. Although he has published more than 400 peer-reviewed papers, 200 book chapters, and 18 textbooks, this may be the prolific Dr. Chung's best work. Why? Because it is consistent, concise, comprehensive, and contemporary—four critical attributes of a classic textbook.

The format and prose are consistent. Although there are excellent coauthors, this is essentially a single author textbook. Dr. Chung's expert voice is present throughout. With prior experience as an editor of the *Journal of Hand Surgery* and *Plastic & Reconstructive Surgery*, Dr. Chung's style of writing is crisp and clear.

A well-used surgical textbook should be concise. The chapters have bullet point sections on Indications, Clinical Examination, and Surgical Anatomy. This is a procedure-based textbook, and each key procedure is outlined as a step-by-step technique guide. I agree with Dr. Chung that operations are best taught in this manner. The extensive video library complements each chapter brilliantly. The figures have been carefully presented with just the key anatomic points, and only the classic articles are referenced for collateral reading.

Most importantly, this textbook is comprehensive and contemporary. The 105 chapters are based on Dr. Chung's vast experience in all aspects of hand surgery. Although many hand surgeons have chosen to focus on one specialized area, Dr. Chung is known at his institution and internationally as adept at “doing it all”—from congenital hand to complex distal radius fractures and microsurgical reconstruction. His practice is dynamic; therefore, this third edition is up-to-date with new techniques such as percutaneous needle aponeurotomy and nerve transfers.

Only a select few have the breadth and depth of clinical experience to present a single primary author textbook of hand surgery. Dr. Kevin Chung has done so in outstanding fashion. This third edition has refined an already classic textbook, one that I have always recommended to my own trainees.

James Chang, MD

Chief, Division of Plastic & Reconstructive Surgery
Johnson & Johnson Distinguished Professor of Surgery & Orthopedic Surgery
Stanford University Medical Center
72nd President of the American Society for Surgery of the Hand (2017-2018)

Anesthesia of the Hand

Aviram M. Giladi and Kevin C. Chung

Indications

- Postoperative pain control
- Aid in functional evaluation of traumatic injuries
- Bedside procedures in the emergency department
- Minor hand surgery procedures (“wide awake” hand surgery)
- Avoidance/reduction of sedation or airway instrumentation in higher risk patients
- Performing procedures that benefit from testing intraoperative movement (tenolysis, trigger finger release, etc.)

Clinical Examination

Anesthetic Agents

- Lidocaine is most widely used—onset approximately 3 to 5 minutes, duration of action 60 to 120 minutes.
- Bupivacaine (Marcaine) is also commonly used for longer durations of pain control (~400–450 minutes); however, onset takes up to 15 minutes or more.
- Use of epinephrine mixed in with the local anesthetic (1:200,000 or even 1:100,000) is not contraindicated in the hand or fingers and may increase duration of anesthetic action while aiding in minimizing blood loss.

Surgical Anatomy

- Fig. 1.1 shows the sensory distribution of the dorsal hand.
- Fig. 1.2 shows the location of the radial, median, and ulnar nerves. The *radial nerve* crosses the wrist in the area of the radial styloid. The purely sensory nerve arborizes proximal to the radial styloid and crosses the wrist divided into a few major branches that travel in subcutaneous tissues anywhere from just volar to the styloid and as far dorsal/ulnar as the area in line with the middle finger metacarpal (Fig. 1.3A and B).
- The *median nerve* crosses the wrist within the carpal tunnel, and the palmar cutaneous branch crosses in a similar region of the wrist but more superficially. The nerve runs between the palmaris longus (PL) and the flexor carpi radialis (FCR) tendons, and for patients with PL this tendon can be used to help landmark for injections.
 - To identify PL, have patient pinch thumb to ring/small finger and see tendon bulge in wrist (Fig. 1.4A and B).
 - If not present or identifiable, the ulnar border of FCR tendon can be used as the landmark.
- The *ulnar nerve* crosses the wrist in the area of the flexor carpi ulnaris tendon, proximal to its insertion on the pisiform (prior to nerve entering Guyon canal).
 - The ulnar artery is radial to the nerve and to the flexor carpi ulnaris (FCU) tendon.
 - The dorsal sensory branch also runs ulnar to FCU at the level of the wrist, more superficial to the major ulnar nerve trunk (Fig. 1.5).
- Common digital nerves travel between the metacarpals. Injection site to perform a block of the common digital nerve to anesthetize multiple fingers at once is at the level of the distal palmar crease, approximately 1 cm proximal to the metacarpophalangeal joint.
- Each finger has a volar and dorsal nerve on the ulnar and radial sides (total four digital nerves). The volar branches are larger, and within the finger will be volar to the corresponding digital artery. The volar branches pass from the common digital nerve proximal to each webspace and enter the finger (Fig. 1.6).

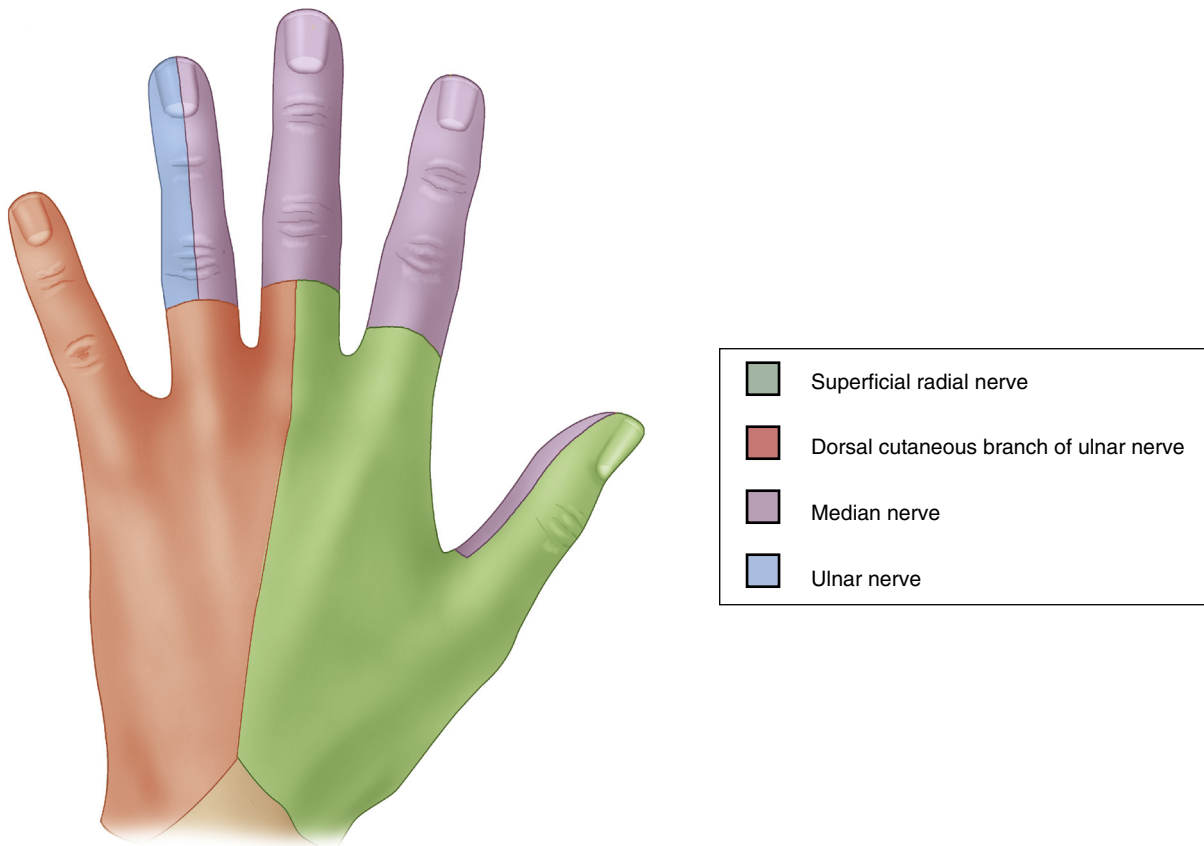


FIGURE 1.1

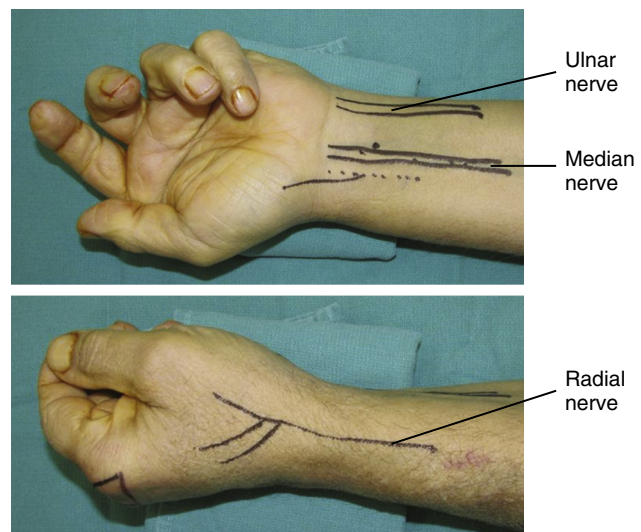
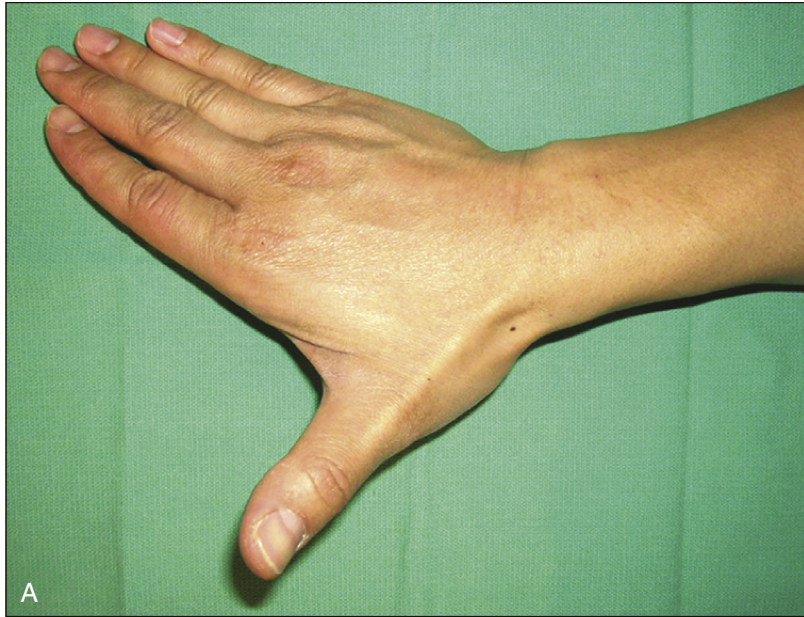

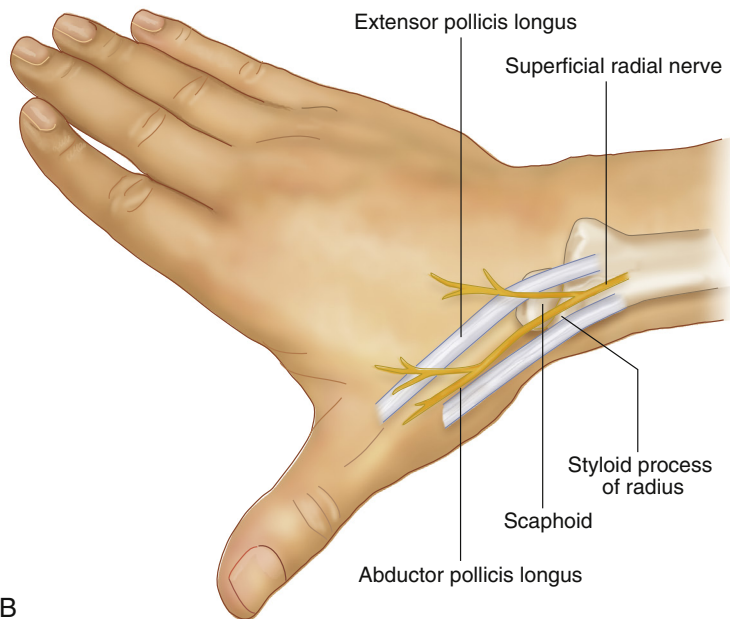
FIGURE 1.2

Positioning

Blocks are most easily performed with patient supine and arm extended out on a hand table with dorsum down. This is especially true for the median nerve block. However, as long as the wrist and elbow are free to be moved, these blocks can generally be performed in a variety of hand and arm positions.



A



B

FIGURE 1.3

Procedure: Radial Nerve Block

Step 1

Begin with volar injection radial to the radial artery (along the radial border of the forearm/wrist), proximal to the radial styloid. Inject in the subcutaneous plane, being sure to aspirate before injecting to confirm no violation of the radial artery that could result in an intraarterial injection (Fig. 1.7).

Step 2

Adjust position and move the needle along the radial border of the radius and then dorsally, to the area of the radial styloid, and inject again into the subcutaneous plane.

Step 3

- Continue these subcutaneous injections along the dorsum, beyond the styloid, as far ulnar as the area inline with the middle finger metacarpal.

RADIAL NERVE BLOCK: STEP 1 PEARLS

- The radial nerve block at the wrist is, in essence, a superficial field block in the area around the radial styloid (Fig. 1.8).
- Block is performed superficial to the first and second extensor compartment as well as the anatomic snuffbox.

RADIAL NERVE BLOCK: STEP 1 PITFALLS

The nerve branches travel in the subcutaneous plane; there is no need for deep injection with this block.

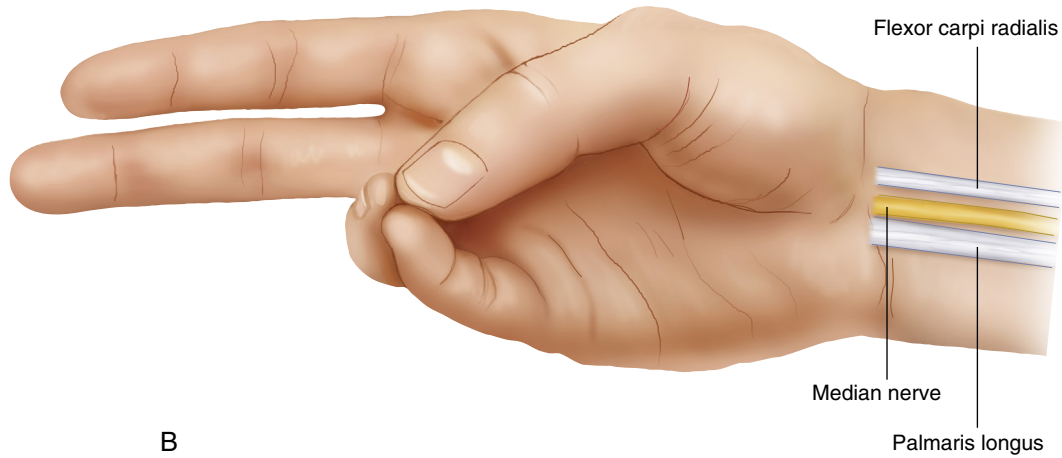
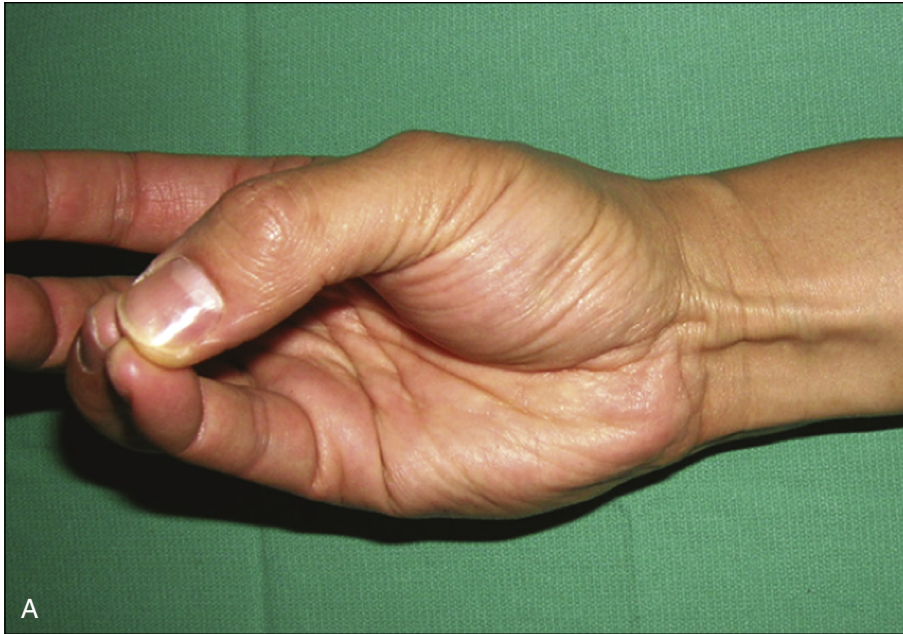
FIGURE 1.4

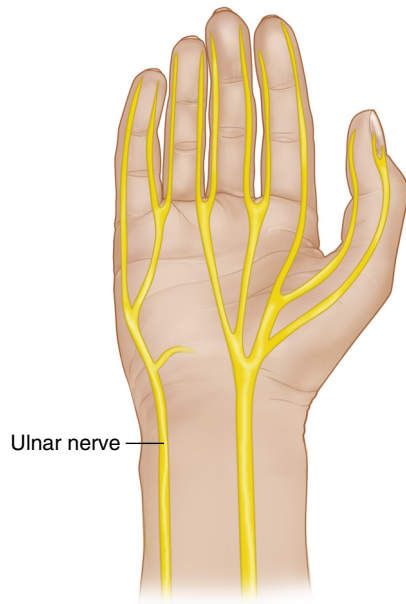


FIGURE 1.5

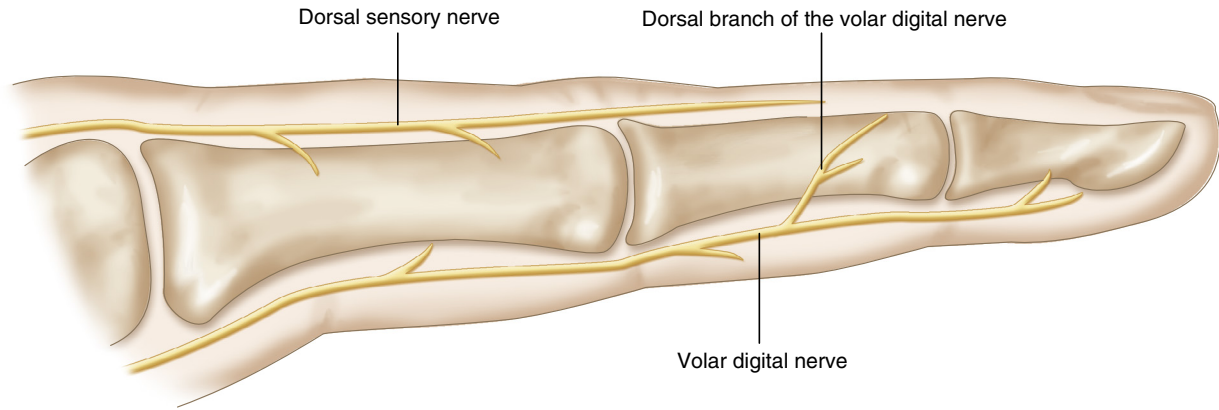


FIGURE 1.6

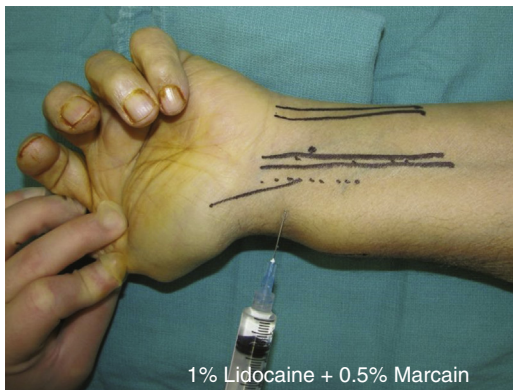

FIGURE 1.7

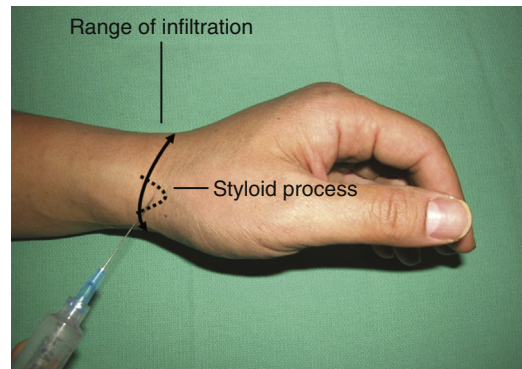


FIGURE 1.8

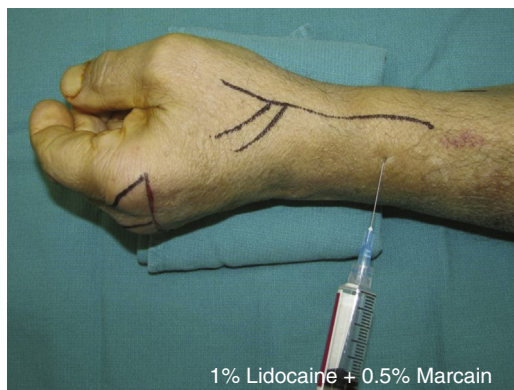

FIGURE 1.9

- One can also move slightly more proximal to confirm adequate anesthesia of the carpus (Fig. 1.9).

Procedure: Median Nerve Block

Step 1

Identify the nerve between PL and FCR (or just ulnar to FCR). Enter approximately 1 cm deep, through the flexor retinaculum, and infiltrate with approximately 5 mL of local anesthetic.

Step 2

Slowly withdraw, and inject another small aliquot superficial to the retinaculum to block the palmar cutaneous branch.

RADIAL NERVE BLOCK: STEP 3 PEARLS

- This technique often requires multiple needle insertion points to cover adequate territory around the curvature of the wrist without injecting too deeply.
- This injection requires more anesthetic than the others, with upwards of 10 mL needed for adequate infiltration of the entire area.

MEDIAN NERVE BLOCK: STEP 1 PEARLS

- The injection is performed at the level of the proximal wrist crease, in line with the ulnar styloid (Fig. 1.10).
- Flex or extend the fingers to see if the needle “bobs.” This confirms localization at the entrance to the carpal tunnel.

MEDIAN NERVE BLOCK: STEP 1 PITFALLS

- The median nerve block is done with injections in a deep as well as superficial plane. The landmarks described in the anatomy section are critical to proper localization of the nerve.

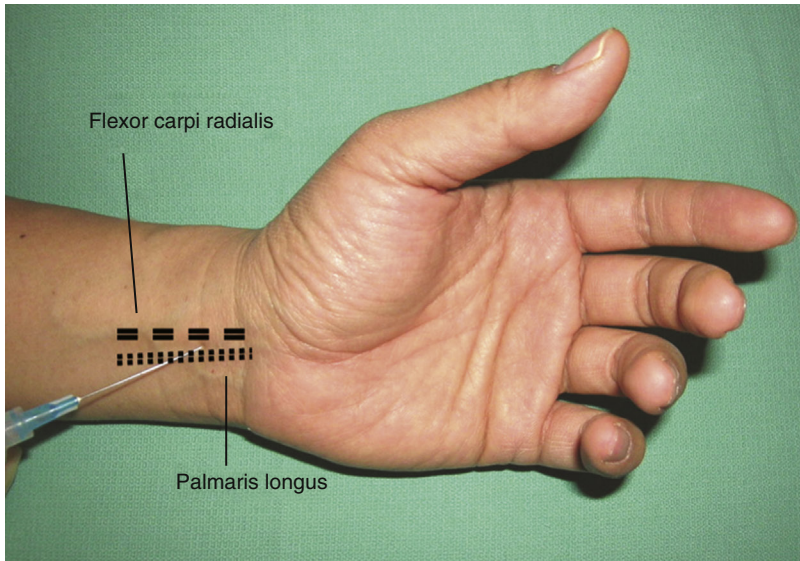


FIGURE 1.10

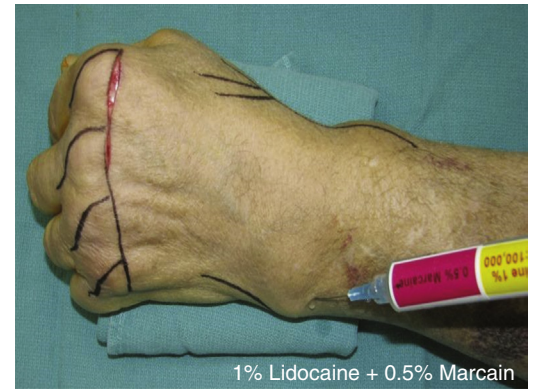

FIGURE 1.11

ULNAR NERVE BLOCK: STEP 1 PEARLS

The ulnar nerve block can be done radial or ulnar to FCU; however, we prefer the ulnar approach to minimize risk of injection into the ulnar artery.

INTERMETACARPAL BLOCK: STEP 1 PEARLS

- Injection site is at the distal palmar crease, proximal to the metacarpophalangeal joint.
- Approach can be volar or dorsal, many report less patient discomfort with a dorsal approach.

SUBCUTANEOUS DIGITAL BLOCK: STEP 1 PEARLS

- If dorsal anesthesia is not required, a single-injection volar technique is preferred by some. This is done with a single injection over the volar aspect, just proximal to the palmodigital crease. The needle can be moved to the radial border webspace and then withdrawn slowly and redirected to the ulnar side to allow injection of both sides with one needlestick.
- However, our preferred technique is to inject a subcutaneous wheal dorsally, and then enter vertically into that anesthetized wheal area to then drive the needle ulnar and then radial from that position (similar to the “single-injection” technique), minimizing the need for additional skin injection sites.

SUBCUTANEOUS DIGITAL BLOCK: STEP 1 PITFALLS

- There is a debate on dorsal versus volar approach, with many preferring dorsal because it is reportedly less painful.
- Volar-only techniques often still require a subcutaneous wheal injected on the dorsum of the finger to block the dorsal digital nerves

INTRATHECAL BLOCK: STEP 1 PEARLS

Intrathecal block offers anesthesia with one injection and reportedly has a faster onset.

Procedure: Ulnar Nerve Block**Step 1**

Identify FCU, and move ulnar and dorsal to the tendon (Fig. 1.11).

Step 2

- At the level of the distal ulna, insert the needle and slide under the area of FCU (dorsal and ulnar to the tendon).
- Inject approximately 5 mL of anesthetic solution in this plane.

Step 3

Withdraw slowly, and inject again in the subcutaneous tissues to block the dorsal sensory branch as well.

Procedure: Digital Nerve Block

Blocking digital nerves can be done with a variety of techniques.

Step 1: Intermetacarpal Block

- If the goal is to block multiple adjacent fingers, an intermetacarpal block (also known as a transmetacarpal block) technique can be used (Figs. 1.12 and 1.13).
- Inject alongside the metacarpal neck to block the common digital nerves to the fingers on either side of the corresponding webspaces (Fig. 1.14).

Step 1: Subcutaneous Digital Block

- To block just one finger, the subcutaneous digital block technique can be used.
- One must infiltrate along the radial and ulnar border of the digit proximally, at the webspace (Fig. 1.15).

Step 1: Intrathecal Block

- Alternatively, a digital block can be performed using an intrathecal block technique, injecting into the flexor tendon sheath.
- Injection is performed at the level of the palmodigital crease (Fig. 1.16).

Step 2: Intrathecal Block

Can insert needle until contact with bone is made; then pull back slowly while injecting until a loss of resistance is felt—this is the plane between periosteum and tendon within the sheath (Fig. 1.17).

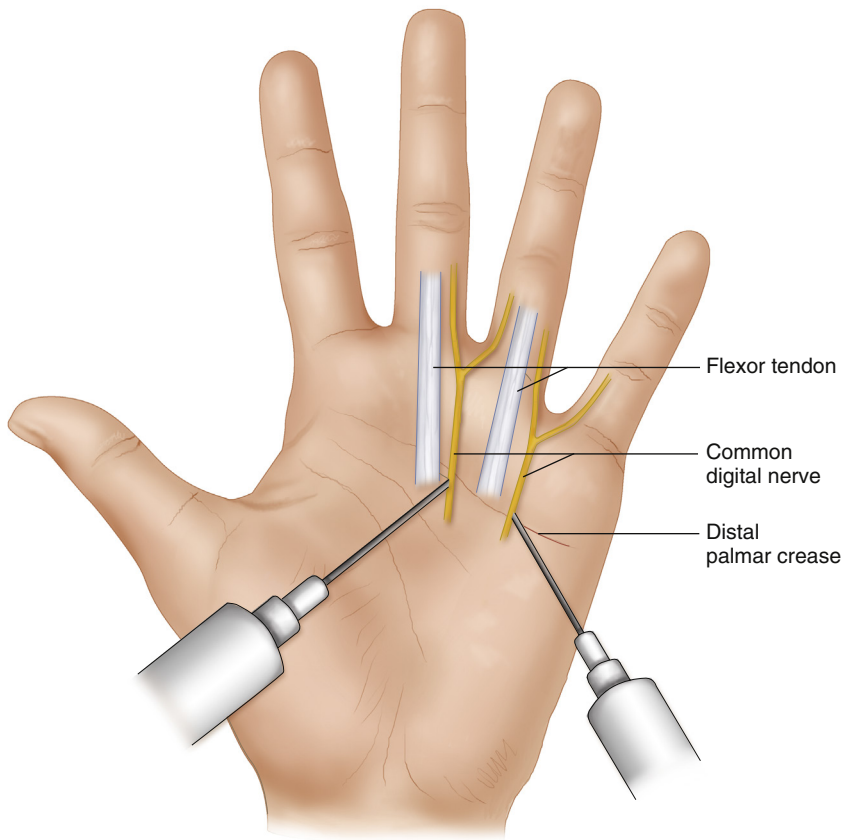


FIGURE 1.12

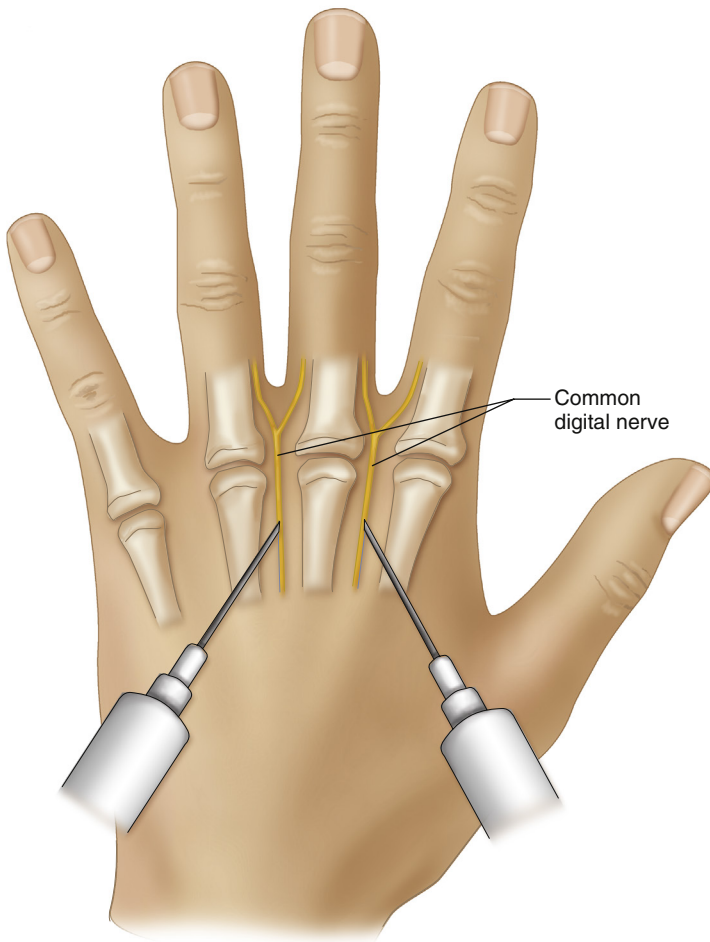


FIGURE 1.13

**INTRATHECAL BLOCK: STEP 1
PITFALLS**

Some patients report more and prolonged discomfort with intrathecal block technique.

INTRATHECAL BLOCK: STEP 2 PEARLS

Also, needing to contact the bone can be avoided by slowly approaching with the volar injection until the sheath is entered and injecting superficial to the tendon; similarly here, injection plunger pressure on the syringe will have a loss of resistance when the injection is entering the tendon sheath space rather than the subcutaneous tissues or the tendon substance itself.

**INTRATHECAL BLOCK: STEP 2
PITFALLS**

Injection superficial to the tendon is often less accurate, and in some cases no intrathecal injection occurs, because the injection is all performed in the subcutaneous space.

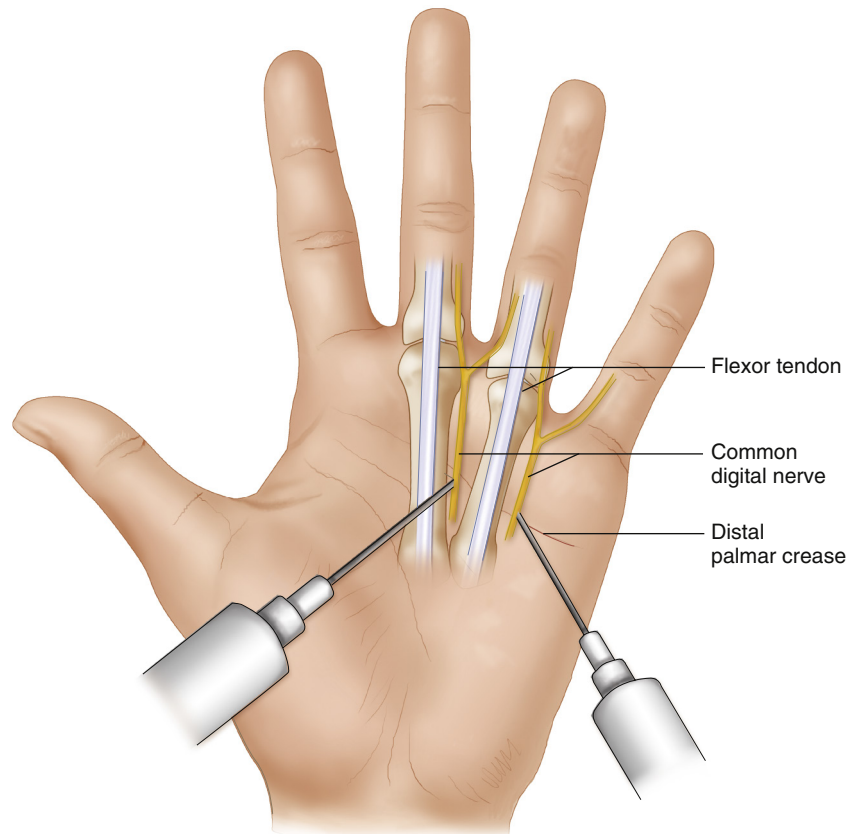


FIGURE 1.14

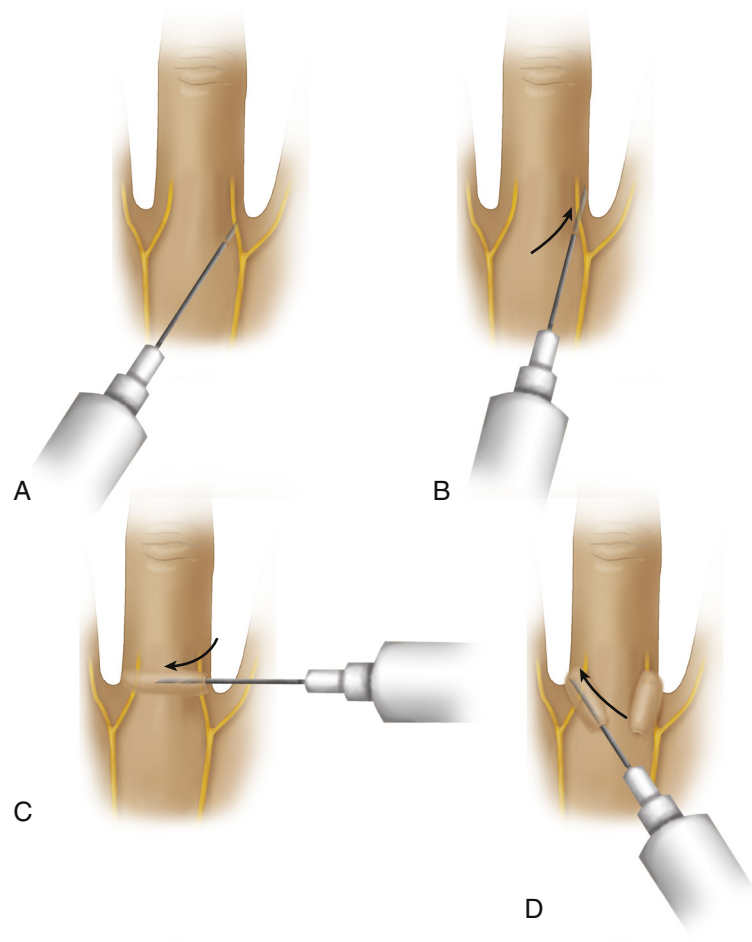


FIGURE 1.15

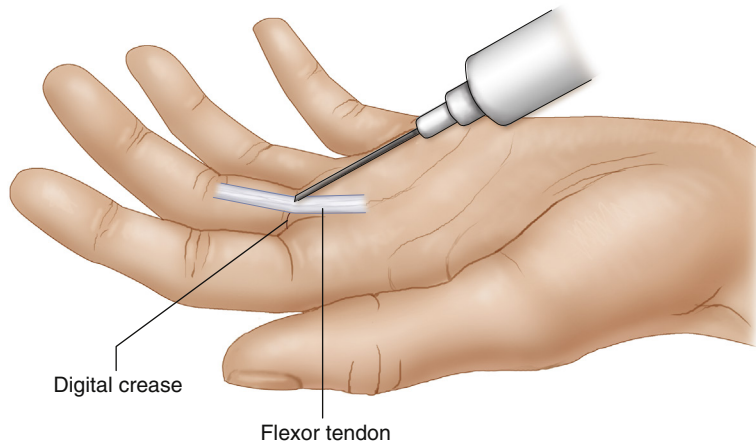


FIGURE 1.16

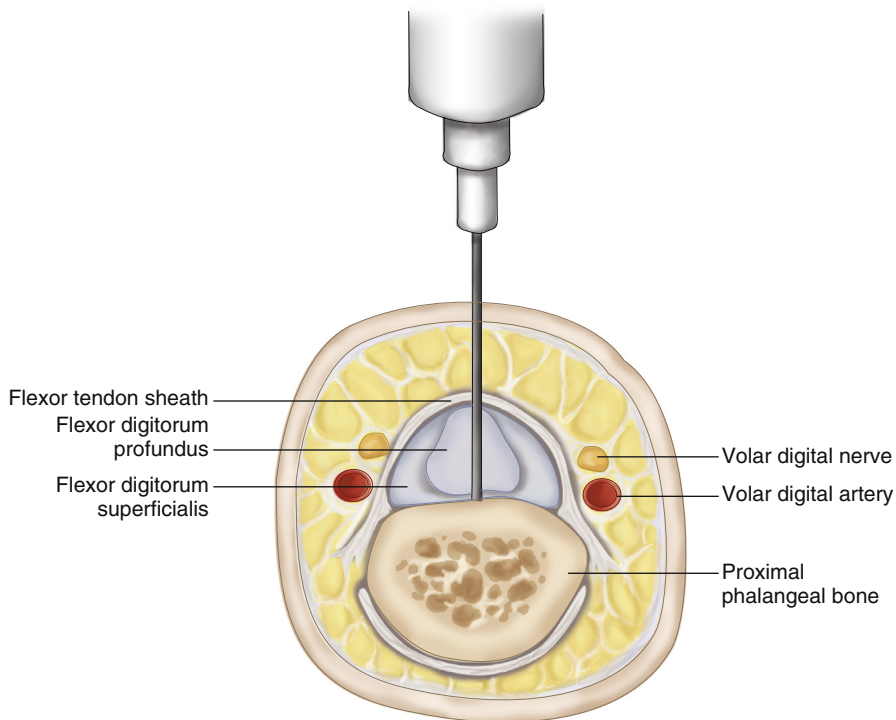


FIGURE 1.17

Postoperative Care and Expected Outcomes

- Most of these blocks can be expected to provide adequate reduction of pain and sharp sensation for the areas targeted.
- Duration of block is based on which anesthetic agent was used, as outlined earlier.

See also Video 1.1, *Anesthesia of the Hand*, on [ExpertConsult.com](https://www.expertconsult.com)

EVIDENCE

Bas H, Kleinert JM. Anatomic variations in sensory innervation of the hand and digits. *J Hand Surg Am* 1999;24:1171-84.

Thirty fresh cadaver hand dissections were performed to investigate the course and interconnection of the sensory nerves. The authors found interconnecting nerves between the median and ulnar nerve just distal to the transverse carpal ligament. The dorsal branch of the volar digital nerve branched out at the proximal level of the A1 pulley in 62% of the specimens. The dorsal sensory nerve extended to the nail level in the thumb and little fingers. (Level IV evidence)

POSTOPERATIVE PITFALLS

- Neuropraxia is uncommon, especially with these distal nerve blocks. However, should they occur, they will often resolve within 4 weeks. Patient support and reassurance is usually the only necessary treatment. In the rare event of complete or near-complete palsy, additional evaluation is warranted to rule out new sources of compression.
- Toxicity from the local anesthetic, although incredibly uncommon with these small doses, should always be considered if patient experiences central neurologic or cardiac changes.

Gebhard RE, Al-Samsam T, Greger J, Khan A, Chelly JE. Distal nerve blocks at the wrist for outpatient carpal tunnel surgery offer intraoperative cardiovascular stability and reduce discharge time. *Anesth Analg* 2002;95:351-5.

This retrospective study of 62 consecutive patients compared Bier block, peripheral nerve (median and ulnar nerve) block, and general anesthesia for carpal tunnel surgery. Peripheral nerve blocks had greater intraoperative cardiovascular stability and earlier postoperative discharge from postanesthesia care unit. (Level IV evidence)

Hung VS, Bodavula VKR, Dubin NH. Digital anesthesia: comparison of the efficacy and pain associated with three digital nerve block techniques. *J Hand Surg Br* 2005;30:581-4.

This is a randomized, controlled, single-blind study of 50 healthy volunteers, comparing time of onset, pain from block, and method of preference of three different digital blocks. The metacarpal block took significantly longer to block the digital nerves than the other two methods. Forty percent of subjects felt discomfort for 24 to 72 hours after the transthecal digital block. Forty-three percent of subjects chose the subcutaneous block as the preferred method. (Level I evidence)

Low CK, Vartany A, Engstrom JW, Poncelet A, Diao E. Comparison of transthecal and subcutaneous single-injection digital block techniques. *J Hand Surg* 1997;22:901-5.

Randomized double-blind study on 142 patients comparing transthecal digital block and subcutaneous digital block. No difference was found in effectiveness, distribution, onset, and duration of action. (Level I evidence)

Sonmez A, Yaman M, Ersoy B, Numanodlu A. Digital blocks with and without adrenalin: a randomised-controlled study of capillary blood parameters. *J Hand Surg Eur* 2008;33:515-8.

Twenty patients were randomized to digital block with 2% lidocaine and 2% lidocaine with 1:80,000 adrenalin. PO₂ and SaO₂ in the digits were not significantly different between the groups. No concerning issues with digital perfusion were reported. Return of sensation in digits without adrenalin returned an average of 4.8 hours later, and with adrenaline occurred 8.1 hours later. (Level II evidence)

Fasciotomy for Compartment Syndrome of the Hand and Forearm

Aviram M. Giladi and Kevin C. Chung

Indications

- Compartment syndrome—when pressure within a fibroosseous space increases to a level that results in a decreased perfusion gradient across tissues
- Reperfusion after prolonged ischemia time, including tourniquet, wraps, casts, compression, and others
- Crush injury with resultant edema, causing increased pressure in the closed muscle space
- Other high-risk causes of compartment syndrome: injection injury, extravasation injury, electrical injury, penetrating trauma, circumferential burns, snake or insect bites
 - Certain injection injuries (air, water, other hydrophilic liquids) can potentially be observed depending on volume, clinical presentation, etc.
 - Injection of paint or other oil-based liquid requires early decompression and additional exploration/debridement as needed. These injection injuries tend to develop ischemia as well as deep space infections and worsen rather than improve with time (Fig. 2.1A and B).

Clinical Examination

- The ischemia caused by compartment syndrome affects nerves and then muscle; irreversible damage can occur within 6 hours for muscle or even less for nerves.
- The diagnosis is generally a clinical one, based on findings of nerve or muscle injury.
- Pain (out of proportion to injury, especially on passive stretch), paresthesia, paralysis, pallor, pulselessness, and inability to regulate limb temperature (poikilothermia).
- Pain out of proportion to injury and paresthesias are the two earliest findings, whereas pulselessness and pallor are often (too) late of findings; they may not occur at all.
- The limb/compartment is often firm to palpation, and overlying skin may become shiny and even develop blisters (Figs. 2.2A and B and 2.3).

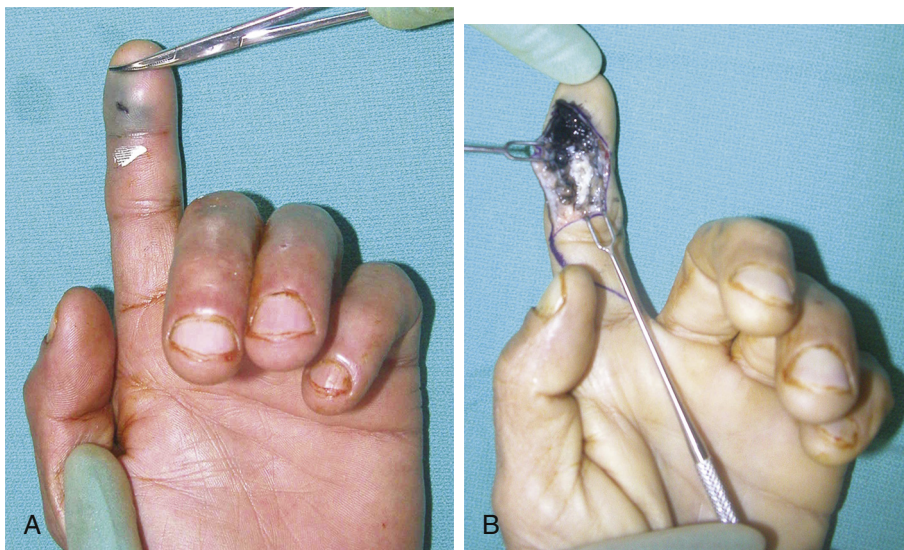


FIGURE 2.1

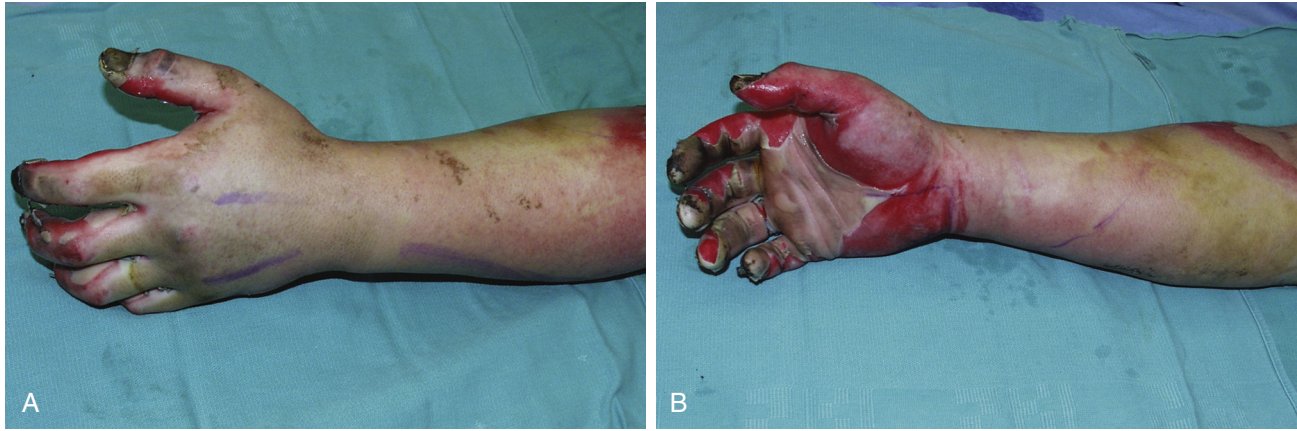

FIGURE 2.2

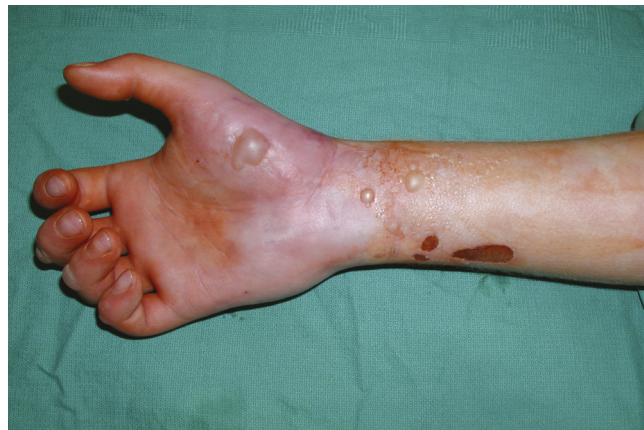

FIGURE 2.3

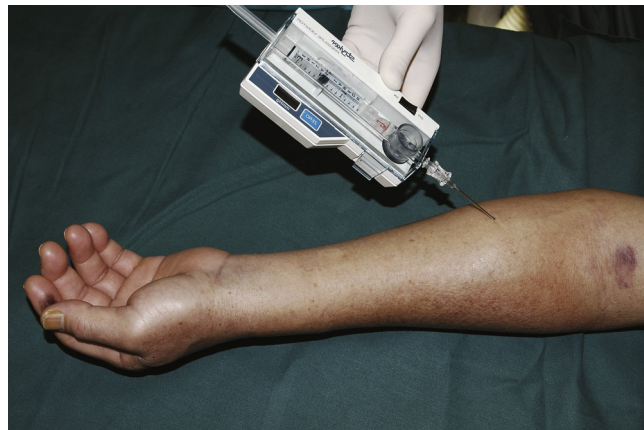

FIGURE 2.4

Imaging

- Often the diagnosis is clinically apparent, and therefore no additional imaging or other workup is needed.
- Most commonly, the diagnosis in less clinically apparent cases is made by measuring compartment pressures. Although many techniques have been described, the Stryker system has been found to be quite accurate, with an arterial line manometer as a more easily accessible secondary option that is quite accurate if used properly (Fig. 2.4).

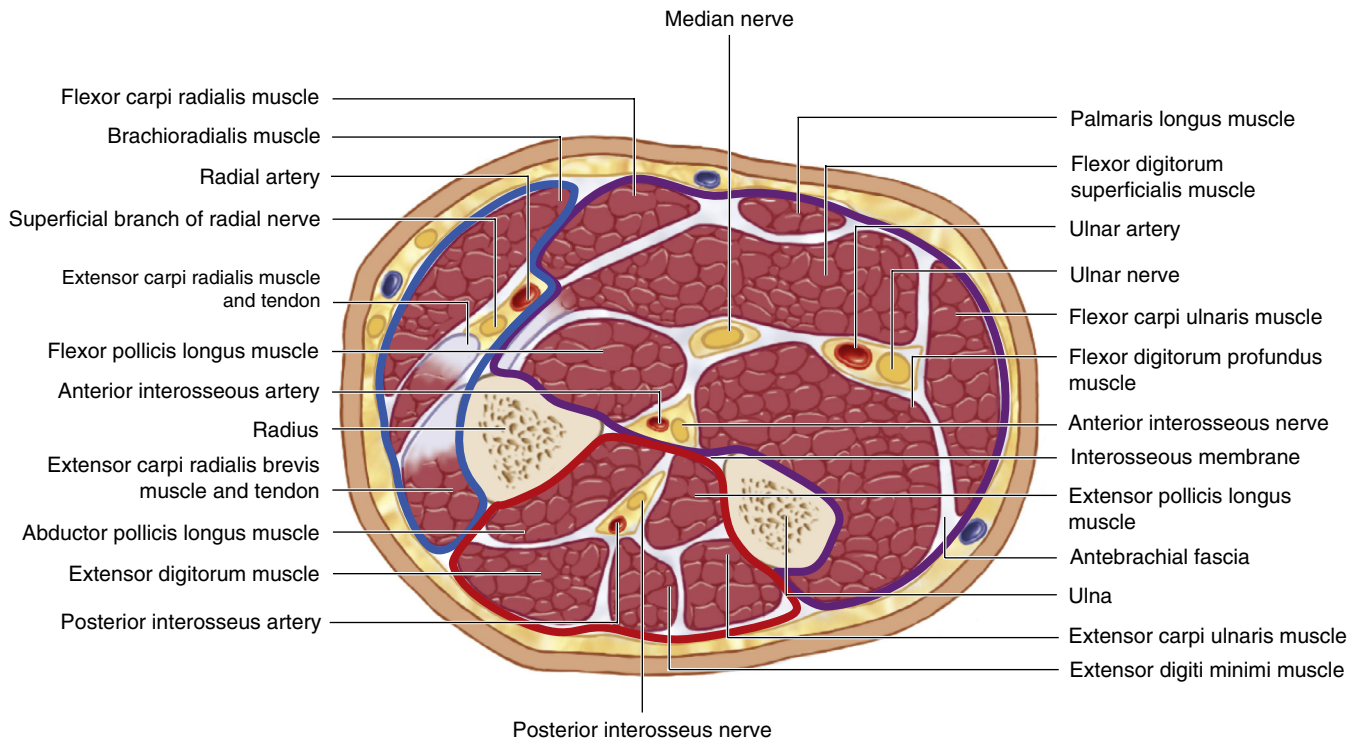


FIGURE 2.5

- Normal tissue pressures range from 0 to 8 mm Hg. Any reading over 30 mm Hg is an indication for urgent fasciotomy, and readings of 20 or above warrant very close monitoring if not early surgical intervention based on the clinical scenario. Additionally, some consider a difference of >20 mm Hg between diastolic pressure and compartment pressure as an indication for fasciotomy as well (hypotensive/septic patients).
- Slit catheters and side port needles are more accurate than straight needles when measuring compartment pressures.

Surgical Anatomy

- The forearm has three major compartments—volar, dorsal, and lateral (mobile wad). Within the volar and dorsal compartments, there are superficial and deep subcompartments. Some consider there to be a third separate volar subcompartment around the pronator quadratus. The deep volar compartment is most susceptible and most often affected by compartment syndrome, whereas the mobile wad is least commonly involved (Fig. 2.5 and Table 2.1).
- The carpal tunnel is susceptible to compressive pressures and is often released when other upper extremity fasciectomy are performed.
- The hand is reported to have as many as 10 compartments, but the clinical significance of each compartment is debated, and most surgeons do not release all compartments in the setting of hand compartment syndrome. The compartments that may need release include thenar, hypothenar, adductor pollicis, dorsal interosseous (4), and volar interosseous (3).
- Digital compartments are also described, bound by Cleland ligament and Grayson ligaments, although the clinical significance of these compartments in the setting of compartment syndrome is debated.
- For high-pressure injection injuries, the surgical approach may need to be adjusted in order to allow for adequate debridement of ischemic tissue in the area of injection (Fig. 2.1A and B).

Table
2.1

Myofascial Compartments of the Upper Extremity and Their Contents

	Compartment	Muscle	Artery	Nerve
Arm	Anterior	Biceps, brachialis, coracobrachialis	Brachial	Musculocutaneous
	Posterior	Triceps	Profunda brachii	Radial
	Deltoid	Deltoid	—	Axillary
Forearm	Volar		Radial and ulnar	Median, ulnar, and anterior interosseous
	Superficial	Pronator teres, flexor carpi radialis, palmaris longus, flexor digitorum superficialis, flexor carpi ulnaris		
	Deep	Flexor pollicis longus, flexor digitorum profundus, pronator quadratus		
	Dorsal		Pos. interosseous	Pos. interosseous
	Superficial	Extensor digitorum communis, extensor digiti minimi, extensor carpi ulnaris		
	Deep	Abductor pollicis longus, extensor pollicis brevis, extensor pollicis longus, extensor indicis proprius, supinator		
	Mobile wad	Brachioradialis, extensor carpi radialis longus, extensor carpi radialis brevis	—	Radial
Hand	Thenar	Abductor pollicis brevis, opponens pollicis, flexor pollicis brevis	Digital	Recurrent motor
	Hypothenar	Abductor digiti minimi, opponens digiti minimi, flexor digiti minimi	—	Ulnar
	Adductor	Adductor pollicis	—	Ulnar
	Interosseous	Four dorsal and three palmar interosseous muscles	—	Ulnar
	Carpal tunnel	Flexor digitorum profundus, flexor digitorum superficialis, flexor pollicis longus	—	Median
	Digit		Digital	Digital

Exposures

- Forearm
 - Volar release is traditionally done via a curvilinear incision from the medial epicondyle to the proximal wrist crease. However, this places the distal flexor tendons and median nerve at risk for exposure and dehiscence, and we disagree with using this approach.
 - We advocate using two longitudinal incisions—one over the volar radial aspect (over the flexor muscles) and the other over the dorsal ulnar aspect of the extensor muscles. This approach decompresses the volar and dorsal compartments without exposing the median nerve or distal forearm tendons (Figs. 2.6 and 2.7).
 - The more traditional dorsal release is performed via a single longitudinal incision along a line between Lister tubercle and an area 4 cm distal to the lateral epicondyle (incision is made in the space between extensor digitorum and extensor carpi radialis brevis; Fig. 2.8). This is an acceptable approach for dorsal release; however, we have found success with the more limited incision shown in Figs. 2.6 and 2.7.
- Hand
 - The carpal tunnel is approached via a single incision between the thenar and hypothenar spaces, in line with the webspace between the middle finger and ring finger (Figs. 2.9–2.11).
 - The thenar compartment is approached via an oblique longitudinal incision along the radial margin of the thenar eminence (Figs. 2.9 and 2.10).
 - The hypothenar compartment is released via a longitudinal incision along the ulnar aspect of the palm (Fig. 2.9).

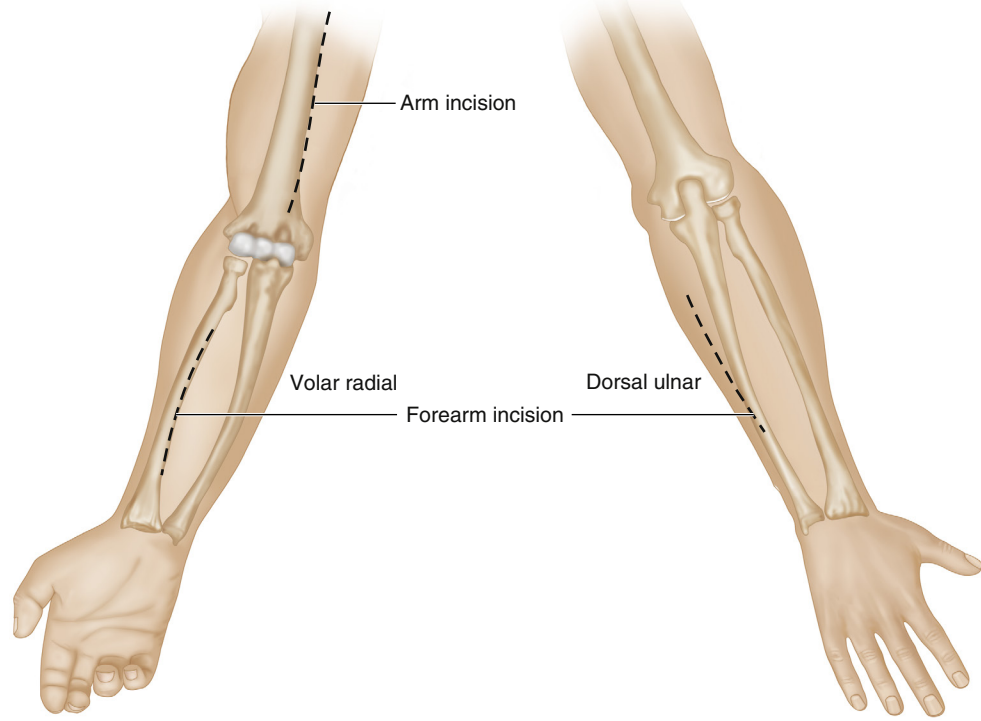


FIGURE 2.6

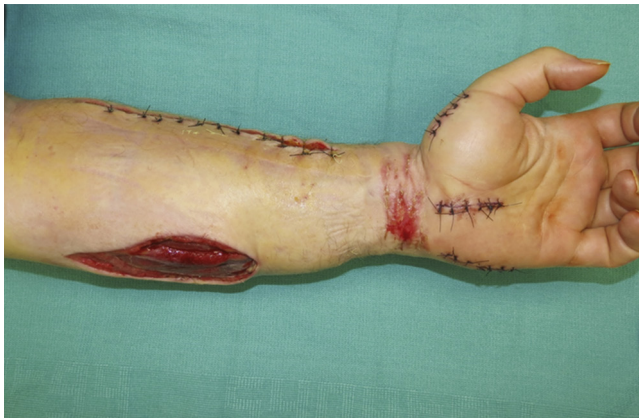

FIGURE 2.7

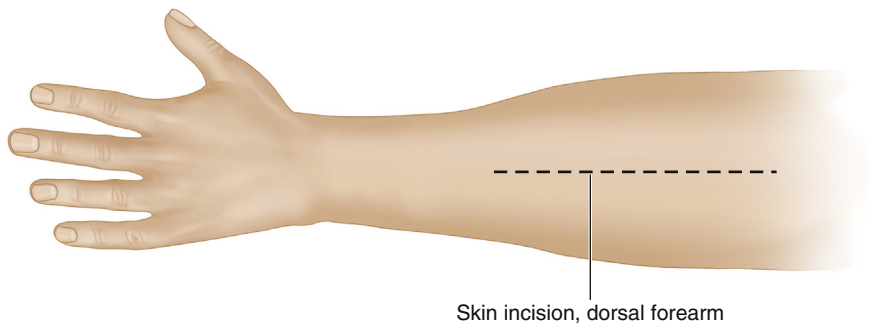


FIGURE 2.8

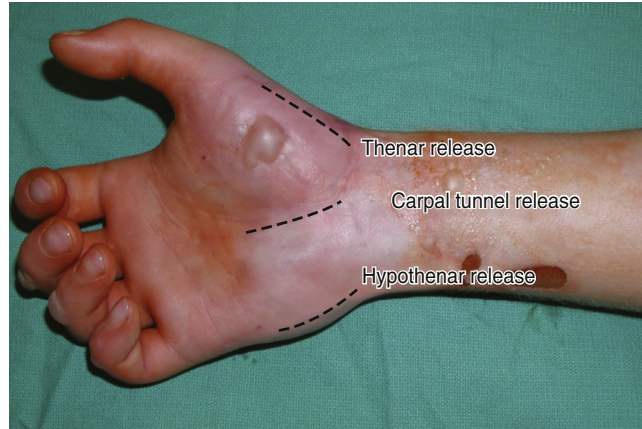


FIGURE 2.9

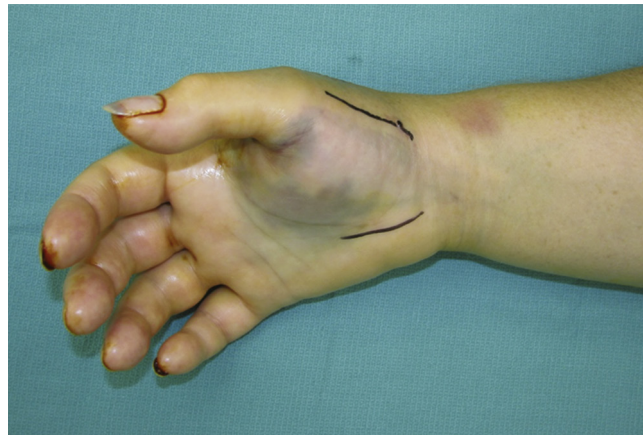


FIGURE 2.10

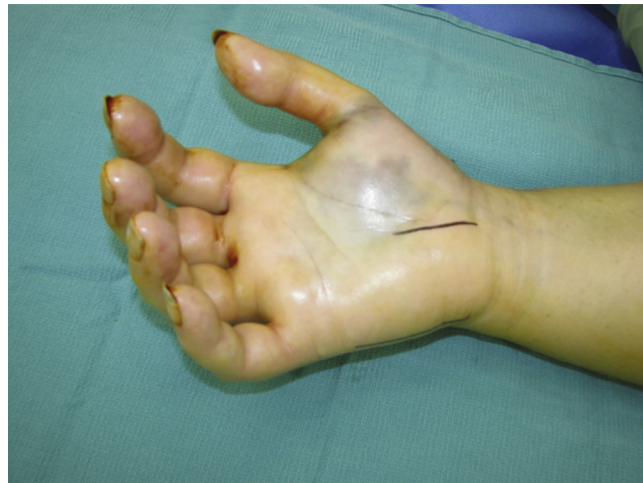

FIGURE 2.11

EXPOSURES PEARLS

- Hypothenar compartment release should not be done directly on the ulnar border, but instead should be slightly radial to the border, so that the scar is not on a direct pressure area of the hand.
- If carpal tunnel decompression is also warranted, there is no reason to use an incision that crosses the wrist, as this increases risk of an open wound exposing the median nerve and flexor tendons.

EXPOSURES PITFALLS

Making release incisions distal in the midvolar forearm that result in exposure of the median nerve or distal flexor tendons is not necessary and risks desiccation and necrosis of these vital structures. Avoid these exposure approaches whenever possible (Fig. 2.16A and B).

- Dorsal hand compartments are released by two longitudinal incisions parallel and radial to the index and ring finger metacarpals (Figs. 2.12–2.14).
- Finger
 - Decompression can be done with a midaxial incision along the noncontact (radial for index and thumb, ulnar for middle, ring, and small) side of the finger (Fig. 2.15).

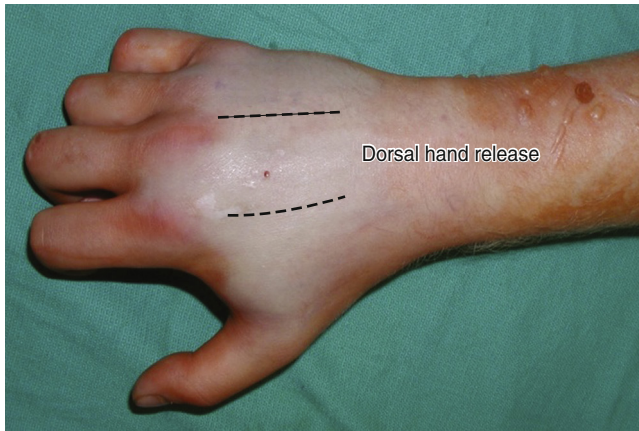

FIGURE 2.12

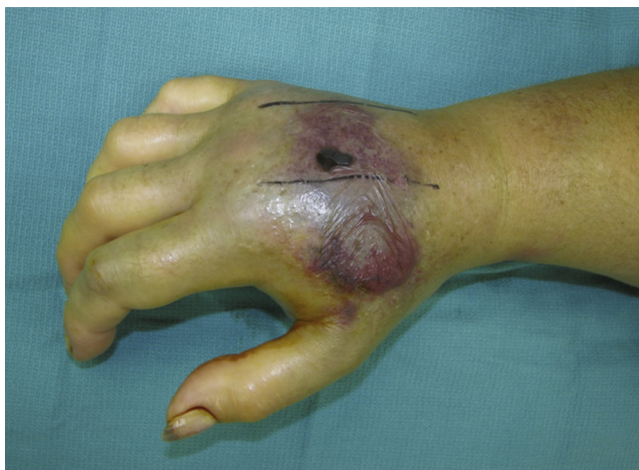

FIGURE 2.13

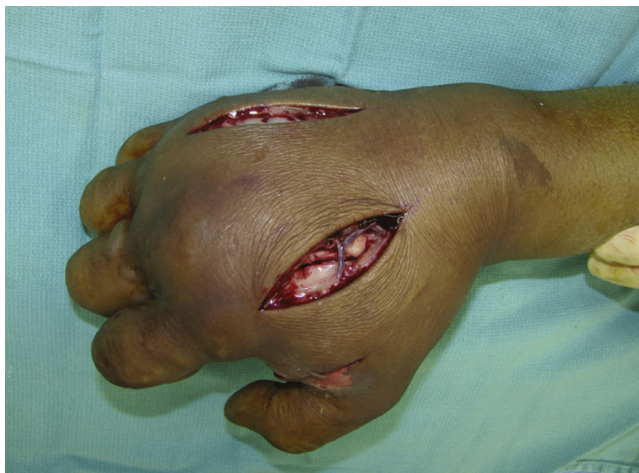

FIGURE 2.14

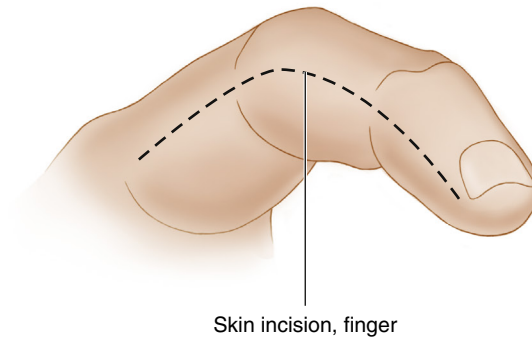


FIGURE 2.15

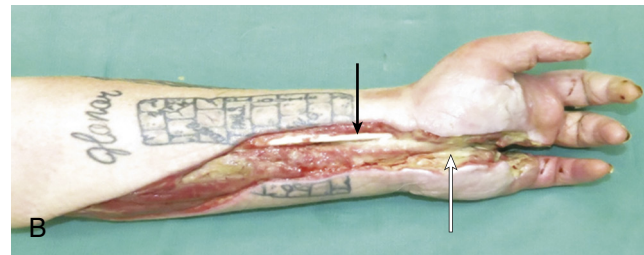
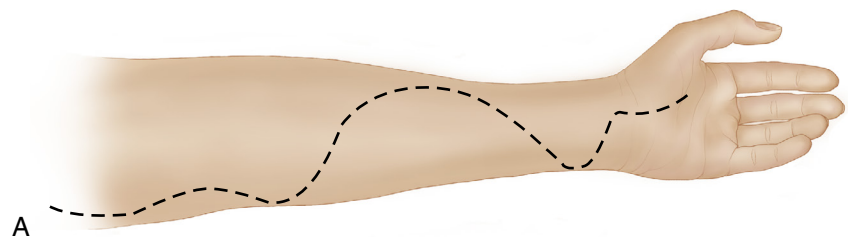


FIGURE 2.16

STEP 1 PEARLS

- If the muscle still appears white after opening fascia, divide the epimysium as well.
 - Prior to approaching deep flexor muscles, identify the median nerve and stay ulnar to it to avoid injury to the palmar cutaneous branch.
- After electrical injury, even if the superficial volar forearm is soft, exposure and release of the deep compartment is often performed because this compartment can be injured from the electrical energy conducted through bone with sparing of the superficial compartment.

STEP 1 PITFALLS

- Avoid exposure of median nerve and distal flexor tendons (Fig. 2.16A and B).
 - Traditional teaching of wide extensile exposure for forearm fasciotomy is shown in Fig. 2.16A.
 - Fig. 2.16B shows the risk of this approach for volar fasciotomy, a nonhealing wound with resulting exposure and desiccation of flexor tendons (black arrow pointing to flexor carpi radialis [FCR] tendon) and median nerve (white arrow); patient required amputation.

Procedure: Fasciotomy of the Forearm**Step 1: Volar Forearm Release**

- The incision (Fig. 2.17) is made through skin and subcutaneous tissues, and the deep fascia investing the muscles of the forearm is divided.
- Subcutaneous flaps can be elevated allowing for mobilization of the incision site and improved exposure in all directions.
- Dissect between flexor carpi radialis and palmaris longus to expose the deep flexors (pronator quadratus, flexor pollicis longus, and flexor digitorum profundus) and decompress as needed with fascial incisions.
 - It is critical to visualize deep compartment flexor muscles.
 - Visualizing the deeper compartment is especially important after electrical injury.

Step 2: Dorsal Forearm Release

- For approaching the dorsal forearm compartment, our preferred incision is longitudinal along the dorsoulnar forearm (Fig. 2.6).
- Alternatively, the incision can safely be made along a line between extensor digitorum and extensor carpi radialis brevis.
- The incision is made through skin and subcutaneous tissues and the deep fascia is exposed and divided (Fig. 2.18).
- Via the same incision, approach the muscles of the mobile wad (brachioradialis, extensor carpi radialis longus, and extensor carpi radialis brevis) and divide the investing fascia to release that compartment.

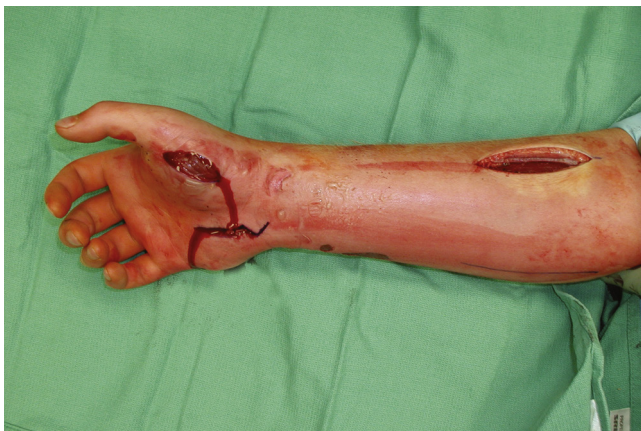

FIGURE 2.17

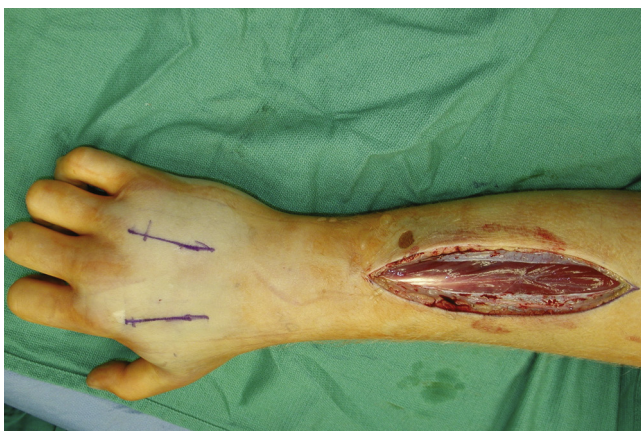

FIGURE 2.18

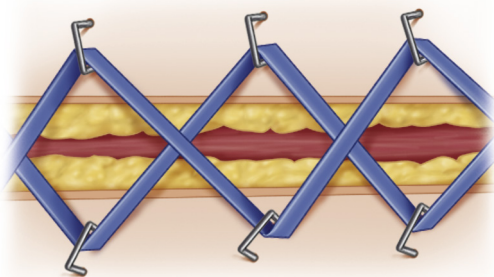


FIGURE 2.19

Step 3

Release tourniquet (if one was used) and obtain hemostasis. Proceed with debridement of nonviable soft tissues back to healthy bleeding tissue.

Step 4: Postrelease

- Place any other soft tissue retention system as appropriate.
- Place bulky moist dressing over any open wounds and fit removable splint in functional position.
- Initiate regular dressing changes to prevent desiccation of exposed muscles and tendons.

STEP 4 PEARLS

- Most of the incision sites should be left open, but closure over vital structures should be done. Although using our approach should not put these structures at risk, if median nerve and flexor carpi radialis tendons are exposed, place a few tacking sutures to secure soft tissue over them.
- Closure of the wounds immediately post-release risks additional ischemia, and is technically difficult due to the edema causing large gaps between wound edges; however, retention systems can be used (e.g., staples and vessel loops; Fig. 2.19) to minimize wound gaps spreading and making reconstruction more challenging.

STEP 1 PEARLS

After releasing the carpal tunnel, close skin to prevent desiccation and necrosis of tunnel structures.

STEP 2 PITFALLS

Use caution with the distal extension of the incision so as not to expose metacarpophalangeal joint.

STEP 3 PITFALLS

Be careful not to divide the ulnar digital nerve to the small finger.

STEP 4 PEARLS

To fully decompress the dorsal interossei, one must incise the overlying muscle fascia, which requires the extensor tendons be mobilized and retracted to adequately access this fascia in each intermetacarpal space.

STEP 4 PITFALLS

Be cautious of the branches of the superficial radial nerve and dorsal branches of the ulnar nerve.

POSTOP PEARLS

If the patient can tolerate it, one may elevate the area by putting a stockinette on the arm and slinging the arm on an IV pole. If this is attempted, be sure to support the elbow with pillows.

Procedure: Fasciotomy of the Hand

Step 1: Carpal Tunnel Release

- The incision is made between the thenar and hypothenar spaces in line with the webspace between middle finger and ring finger.
- Dissect down to and through the longitudinal aponeurotic fibers and identify the transverse fibers of the transverse carpal ligament.
- Divide the transverse carpal ligament across the full distal and proximal extent of the ligament to completely free the carpal tunnel.

Step 2: Thenar Decompression

- Deepen incision until abductor pollicis brevis is encountered.
- Divide fascia over abductor pollicis brevis.

Step 3: Hypothenar Decompression

- Deepen the incision until abductor digiti minimi is visualized.
- Divide fascia over abductor digiti minimi.

Step 4: Dorsal Decompression

- Incision along index finger metacarpal is used to decompress the first dorsal interosseous, adductor pollicis, as well as second dorsal interosseous.
- Incision along the ring finger metacarpal is used to decompress the third and fourth dorsal interossei.

Step 5

Release tourniquet (if one was used) and obtain hemostasis. Proceed with debridement of nonviable soft tissues back to healthy bleeding tissue.

Step 6: Postrelease

- Place a few tacking sutures to secure soft tissue over the carpal tunnel and other exposed critical structures.
- Place bulky moist dressing over remaining open wounds, and fit a removable splint in functional position.
- Initiate regular dressing changes to prevent desiccation of exposed muscles and tendons.

Postoperative Care and Expected Outcomes

- Elevation of the extremity postoperatively is critical in reducing edema and improving pain control.
- Reexamine the extremity within 12 to 24 hours to evaluate need for additional debridement.
- If there is any concern for muscle viability, plan on return to OR approximately 48 hours after initial surgery for examination and additional debridement.
- Wound care with regular moist gauze dressing changes (or petroleum-based dressings) is important in preventing desiccation of any open wounds.
- Attempt closure of open wounds (whether primary wound closure or skin graft) within 3 to 5 days when tissues are still somewhat pliable and in order to limit infection risk.
- If fasciotomy was performed within 4 to 6 hours of compartment syndrome onset, patient may regain full function and sensation; however, any delay beyond 3 to 4 hours may result in some degree of permanent nerve and/or muscle damage.

See also Video 2.1, *Fasciotomy for Compartment Syndrome of the Hand and Forearm*, on ExpertConsult.com.

EVIDENCE

Bae DS, Kadiyala RK, Waters PM. Acute compartment syndrome in children: contemporary diagnosis, treatment, and outcome. *J Pediatr Orthop* 2001;21:680–8.
Retrospective study of 33 pediatric patients. Seventy-five percent developed compartment syndrome due to fracture. "Traditional" signs and symptoms of pain, pallor, paresthesia, paralysis, and pulselessness were not reliable for early diagnosis. However, with early diagnosis and intervention, >90% achieved full restoration of function (Level IV evidence).

Chan PSH, Steinberg DR, Pepe MD, Beredjikian PK. The significance of the three volar spaces in forearm compartment syndrome: A clinical and cadaveric correlation. *J Hand Surg* 1998;23A:1077–81.

On seven arms, all three volar spaces (superficial, deep, pronator quadratus) were evaluated for relief of pressure after compartment release. In six arms, superficial release was adequate to relieve pressure in deep and PQ spaces; in the seventh arm the PQ space needed independent release. Authors advocate release of superficial volar compartment and rechecking pressures in deep and PQ before additional dissection and release (Level V evidence).

Ouellette EA, Kelly R. Compartment syndromes of the hand. *J Bone Joint Surg* 1996;78:1515–22.

This is a retrospective review of 17 patients after fasciotomy for compartment syndrome of the hand. All patients were diagnosed based on tense, swollen hand and pressure elevation in at least one interosseous compartment. Full hand decompression as well as carpal tunnel release was performed for all 17 patients; 13 of 17 had satisfactory results, 4 patients had poor results (Level IV evidence).

Prasarn ML, Ouellette EA. Acute compartment syndrome of the upper extremity. *J Am Acad Orthop Surg* 2011;19:49–58.

This is a review of the pathophysiology of compartment syndrome, pertinent surgical anatomy, surgical approaches, and care recommendations based on up-to-date evidence (Level III evidence).

Verhoeven N, Hierner R. High-pressure injection injury of the hand: an often underestimated trauma.

Case report with study of the literature. *Strat Traum Limb Recon* 2008;3:27–33.

This article is a case report and discussion on management of oil and paint gun injection injuries in the hand. The authors discuss the need for early debridement due to the ischemia and in some cases infection that results from delayed treatment.

Finger Amputations

Aviram M. Giladi and Kevin C. Chung

Indications

- Amputation does not indicate failure of salvage; rather, it is part of the treatment algorithm for helping patients return to optimal function after extensive traumatic injuries.
- Injury that damages a digit to a degree that vascularity and function cannot be restored (unsuccessful or unfeasible revascularization).
- Complete amputation of digit(s) that cannot successfully be replanted—either due to degree of injury to the digit, or to the likely impairment that a poorly functioning replanted digit would cause for the rest of the hand.
- Finger injury that substantially destroys structural and/or functional integrity beyond ability to adequately reconstruct—this includes multisegment injuries, avulsions that cause traction injury to the vessels and nerves, and loss of bone segment(s).
- Patient preference after substantial trauma to digit(s). For injuries in which the prognosis for return of function is poor (joint destruction, need for extensive soft tissue reconstruction, etc.), patients may prefer amputation to prolonged therapy with only moderate return of function.
- Ischemic necrosis of the finger(s)
- Malignancy requiring adequate resection margins
- Goal is to preserve functional length with durable soft tissue coverage.
 - For the thumb, it is important to preserve the carpometacarpal joint so that a toe transfer remains an available option.
 - In multidigit injuries, it is important to consider using tissues from a digit requiring amputation to provide coverage for an adjacent digit or hand wound.
 - Create soft tissue flaps for viable and potentially sensate coverage of other injured sites.
 - Use bone, tendon, vessel, or nerve for grafting in reconstruction of other injured digits.

Clinical Examination

- Check perfusion of the finger, looking at capillary refill, color, and turgor (Fig. 3.1). Note the color difference between the pink, vascularized finger (upper finger) and the white devascularized finger (lower finger).
 - Check that refill takes approximately 2 seconds. This is most easily done by compression and release at the nail bed if available (especially in patients with darker skin tone).
 - If the finger feels soft and compressible, vascular inflow may have been lost resulting in this loss of turgor.

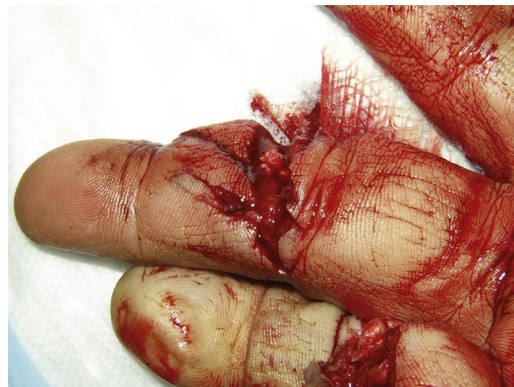

FIG. 3.1

- Evaluate sensation.
 - Check response to sharp stimulus at fingertip—use a sterile needle to test sharp sensation.
 - Examine two-point discrimination (although often difficult in the recently injured patient). Can be done using a premade device if available, or by opening up a paper clip to the desired prong width. Can also gently press using the tips of sharp iris scissors opened to various widths. The objective is to test at what width between the two points the patient is able to distinguish two points from feeling like one point of pressure.
- Examine the structural integrity of each involved finger—test the function of flexion (superficialis and profundus) and extension against gravity and resistance.

Imaging

- X-ray is generally the only modality used to evaluate traumatized digits when deciding about structural integrity and potential for long-term function if salvaged.

Surgical Anatomy

In general, revision finger amputations are done through the bony shaft, rather than at joint level. Knowing the anatomy of the fingers is important for maintaining attachments of flexor and extensor tendons if possible, as well as contouring bone appropriately for the revision stump (Fig. 3.2A and B).

For metacarpal amputations, one must decide between a transmetacarpal amputation and a ray amputation.

- For border digits, one often can do a transmetacarpal (neck or shaft) amputation, with the distal remaining bone cut at a 45-degree angle to preserve hand curvature and shape.
- For central digits, and for border digits in patients unhappy with hand function/appearance after border amputation, one often will do complete ray amputation with removal of the metacarpal.
 - For index and middle fingers, one must keep the metacarpal base to preserve the extensor carpi radialis longus (ECRL)/extensor carpi radialis brevis (ECRB) attachments (respectively).

Although some advocate leaving cartilage in place, it is our general practice to denude cartilage at the amputation site. Denuding cartilage has remained standard teaching in hand surgery; however, there is no clear evidence to support leaving the cartilage cap versus denuding it.

Identify the neurovascular bundles on radial and ulnar sides of digit. Ligate/cauterize the vessel for hemostasis and appropriately manage the nerve to prevent neuroma (discussed later) (Fig. 3.3).

In a ray amputation, identify and protect the common (palmar) digital vessel and nerve so as not to injure inflow or sensation to the bordering digit (Fig. 3.4).

The A1 pulley must be divided to identify the flexor tendons during transmetacarpal/ray amputation (Fig. 3.4).

Positioning

With an adequate digital block, a revision finger amputation can often be performed in the emergency department or in a small procedure room rather than the operating room.

Exposures

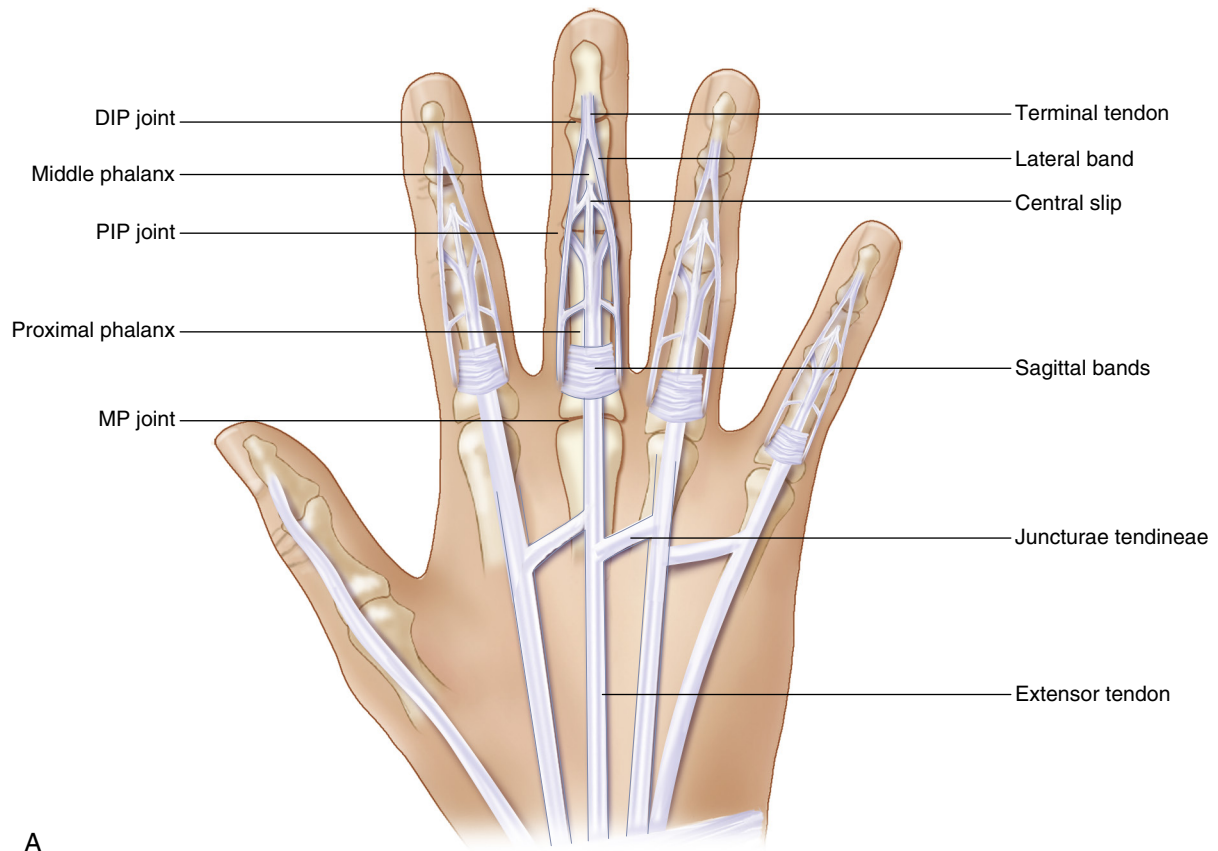
Thoroughly clean the hand during examination and evaluation. This will aid in visualization of skin color and perfusion, as well as the extent of deformity and soft tissue injury. Often, once the sensory examination has been completed, it is easiest to place the digital block and then thoroughly clean the anesthetized finger(s) (see Chapter 1).

EXPOSURES PEARLS

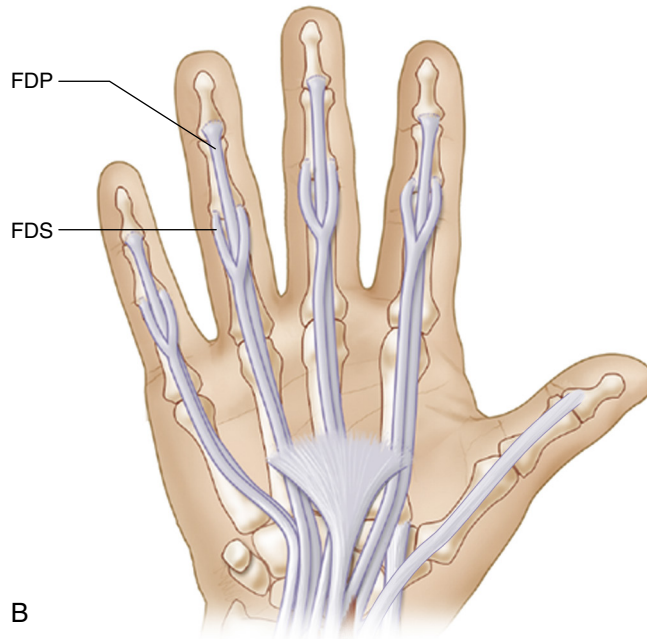
- Peroxide soak/wash can be helpful in cleaning off dried blood.
- Use of a finger tourniquet facilitates operating in a dry field. An extra glove can be used if no prefabricated finger tourniquet option is available (Fig. 3.5).
- Put a clamp on the finger tourniquet so that the surgeon has a reminder to remove the tourniquet after surgery. In the chaotic environment of the emergency room, the surgeon may forget the tourniquet is still on without a reminder. In the anesthetized finger, the patient may not feel tourniquet pain until it is too late.

EXPOSURES PITFALLS

One should not stop active bleeding from the injured finger before the examination has been performed, as tourniquet/pressure on the digital bundles can potentially alter sensory examination—attempt to use direct pressure on the bleeding site if necessary.



A



B

FIG. 3.2

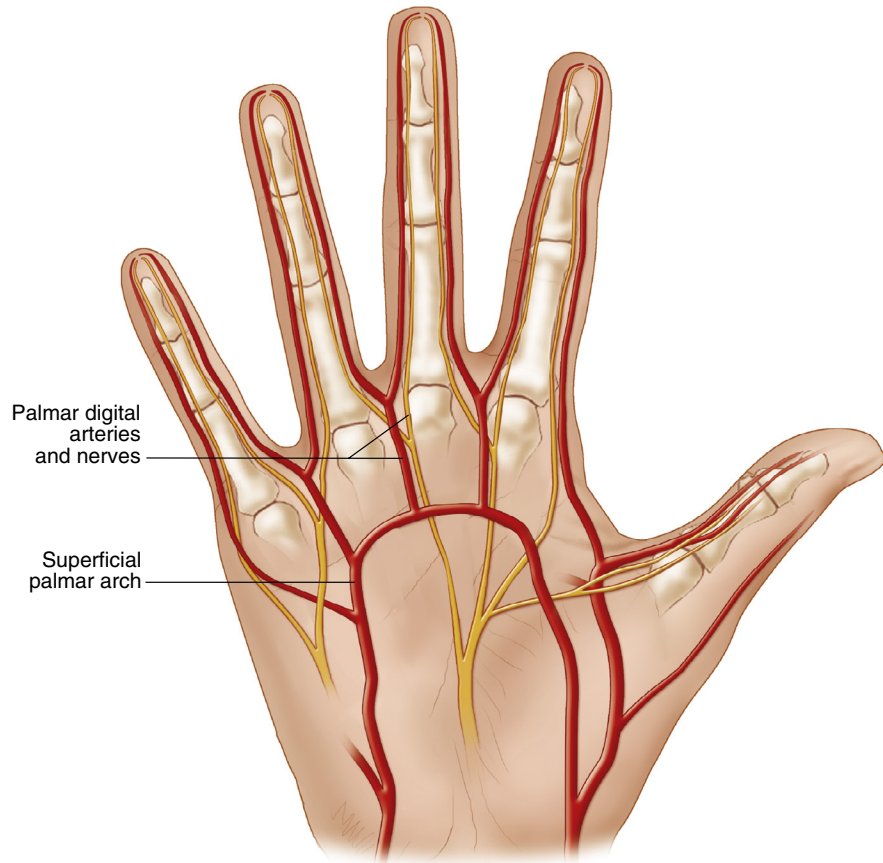


FIG. 3.3

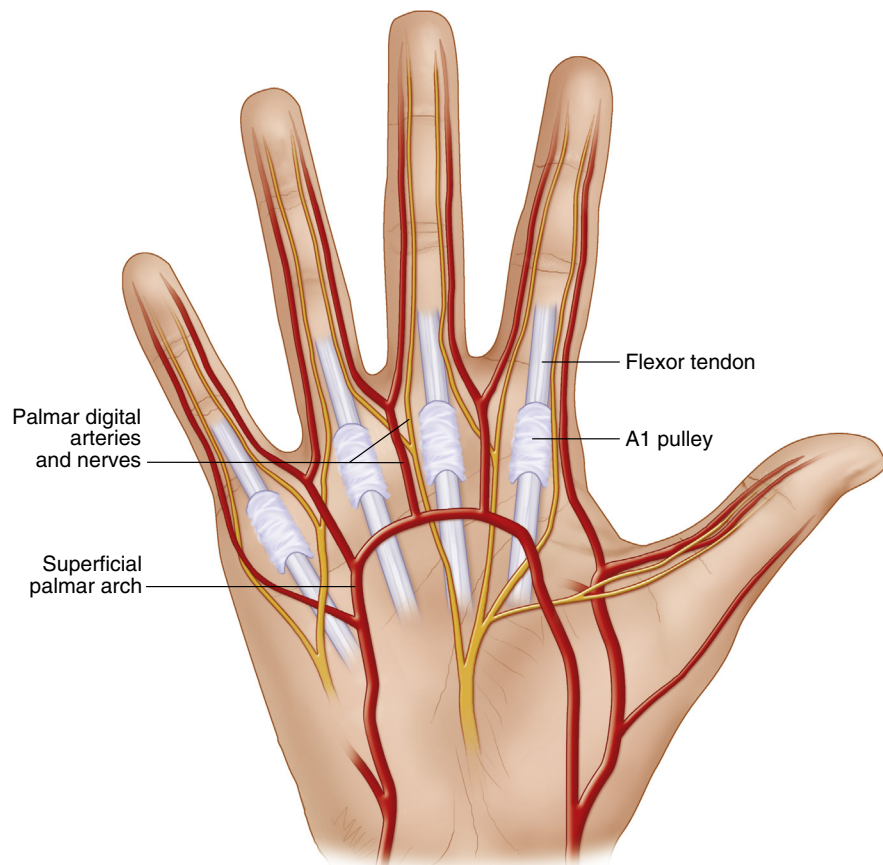


FIG. 3.4

STEP 1 PEARLS

- Allow adequate time for the block to set in. It is often easiest to place the block early, even before thorough cleaning, so the block has time to set in.
- If possible, mark any areas of clearly nonviable soft tissue before placing the tourniquet.

STEP 1 PITFALLS

Be sure the tourniquet is tight enough to prevent any arterial inflow—if tourniquet is somewhat lax (especially if using a makeshift tourniquet, e.g., rubber glove) then congestion and backflow bleeding will make the procedure more difficult.

STEP 2 PEARLS

Attempt to preserve volar skin to cover distal bone. This will move the scar to a noncontact surface, and likely will improve sensation of the stump (Fig. 3.6).

STEP 2 PITFALLS

Caution overresection—adequate length and thickness of soft tissue flaps is required to cover over the distal bony stump.

Procedure: Revision Amputation**Step 1: Set Up for the Procedure: Thoroughly Clean, Anesthetize, and Place Tourniquet**

- After the injury, the surgical site is often bloody and dirty from manual labor at the time of the injury. Cleaning with peroxide can help clear away blood and grime.
- For most posttraumatic revision amputations, the only required anesthesia is a digital block (see Chapter 1). After the sensory examination is completed, the block can be placed to facilitate more thorough cleaning and functional testing.
- Mark out the areas of clearly nonviable skin.
- Use a finger tourniquet for hemostasis, placed at the base of the finger after adequately anesthetized (Fig. 3.5).
- If finger amputation is performed in the operating room under anesthesia, one can use a standard arm tourniquet. Use the standard tourniquet for transmetacarpal/ray amputation.

Step 2: Confirm Viability of Skin and Debride Away Any Clearly Nonviable Tissue

- Devitalized skin should be sharply excised (scalpel preferable).
- Even under tourniquet, the transition to healthier, more viable tissue can be seen.
- In general, all skin and soft tissue proximal to laceration sites should be preserved even if traumatized, unless it is clearly no longer viable. This extra soft tissue length will be needed to provide adequate durable coverage over the bony stump.
 - Bone will need to be resected proximal to the injury site to provide adequate soft tissue to close over the bone. This tissue therefore must be dissected off of the bone with minimal injury to preserve viability.
 - With sharp scissors or elevator directly on the phalanx, elevate the soft tissue envelope off of the bone.
 - If the flexor or extensor tendon remains attached to the distal bone segment that will be excised, pull on the tendon and divide as proximally as possible and allow to retract into the palm. This prevents the tendon from being tethered distally, which could restrict tendon excursion of the other fingers.

Step 3: Identify and Treat the Neurovascular Bundles

- Bundles are identified along volar region of radial and ulnar borders of the injured digit.
 - If soft tissue connections remain between the distal segment and the remaining digit, the neurovascular bundles may be in that soft tissue. Closely examine before transecting these soft tissue connections.
- In the finger, the nerve is volar to the artery; in the palm, artery is volar to nerve.
- In amputated digits, confirm arterial end of each digital vessel is coagulated or ligated.

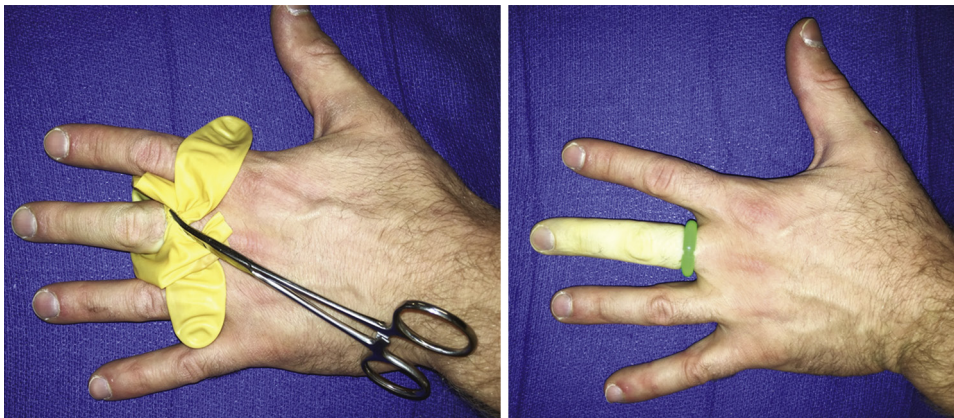


FIG. 3.5

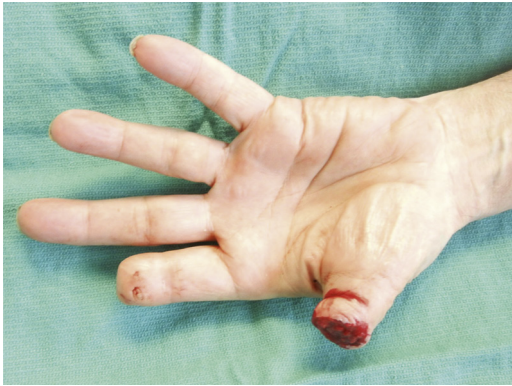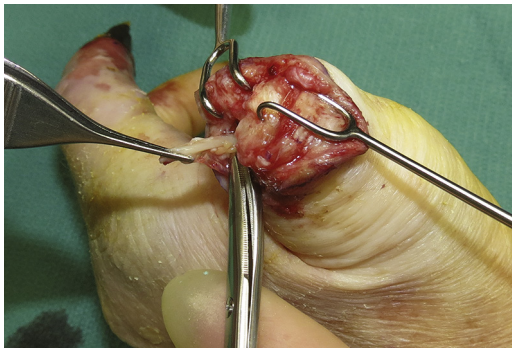
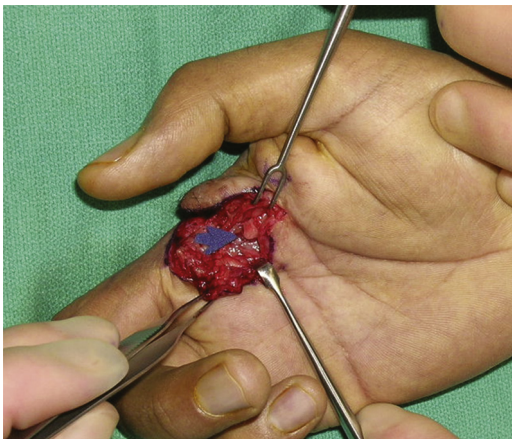
- In amputated digits, the nerve should be placed on traction (**Fig. 3.7**) and then transected with sharp scissors so it can retract proximally away from the scar site. Nerves trapped in the sutured skin cause debilitating pain, whereas a nerve retracted into the palm shields the nerve end from contact.
- In metacarpal-level amputations, management of the primary neurovascular bundles is a more delicate matter, as the common branches in the palm also feed the adjacent digits and therefore must be preserved (**Fig. 3.8**). The blue arrow indicates the common branch in the palm.
- Identifying the digital nerve distally in the finger can aid in finding it proximally in the intermetacarpal space. Putting traction on the digital nerve in the finger can help identify the branch-point in the webspace or the common nerve in the palm, showing a safe transection point for the nerve to the finger being amputated
- When approaching the metacarpal, approach over the bone and peel soft tissue off to either side, protecting the neurovascular bundles.

STEP 3 PEARLS

If the nerve does not adequately retract after transection, attempt to tunnel the nerve end into soft tissue or potentially into bone to prevent painful neuroma. All nerves will form a neuroma, but nerves trapped in contact areas and not buried may cause painful neuromas.

STEP 3 PITFALLS

If controlling bleeding from the digital artery is difficult before tourniquet placement, use pressure to control the bleeding rather than trying to control bleeding before isolating the nerve.

**FIG. 3.6****FIG. 3.7****FIG. 3.8**

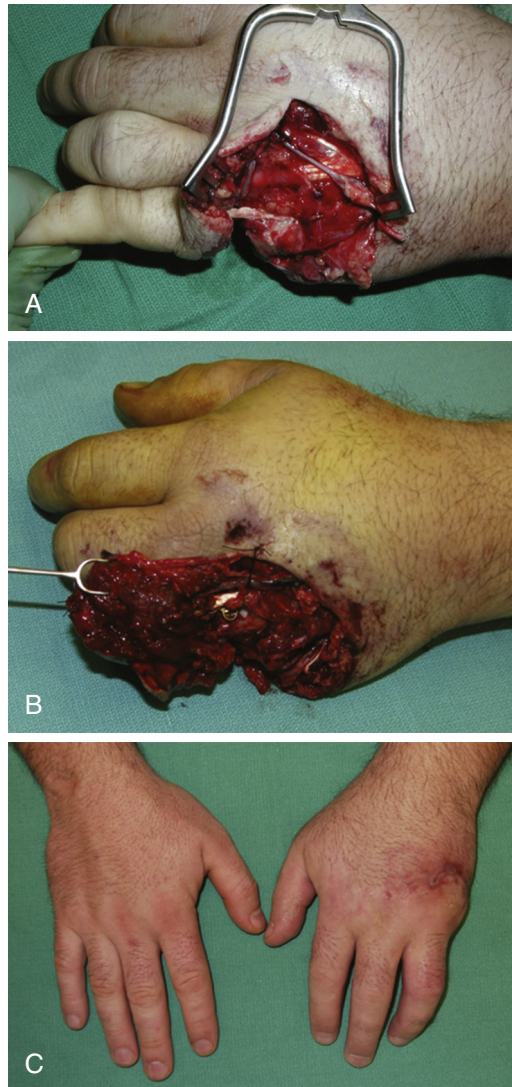


FIG. 3.9

Step 4: Perform the Bony Amputation Based on Level of Injury and Available Soft Tissue

- Level of amputation is determined by available soft tissue.
 - After trauma to multiple digits, one may need to use soft tissue from one digit to cover wounds on neighboring digits or the hand (Fig. 3.9A–C).
- Level of amputation also can be guided by level of fracture or bony injury.
- In the fingers, perform amputation through phalangeal shaft if possible.
- If possible, aim to preserve the attachments of flexor digitorum superficialis (FDS), flexor digitorum profundus (FDP), and extensor digitorum communis (EDC) tendons (see Fig. 3.3).
- If amputation occurs through the joint, then denude the cartilage along the distal aspect of the remaining phalanx.
- Contour the distal bone (Fig. 3.10).
 - For digits, do not leave sharp edges, and avoid leaving flared/boxy distal aspect just proximal to the joint.
 - For metacarpals, angle distal osteotomy of border digits to be approximately 45 degrees angled toward the hand, providing natural curved contour to match the rest of the hand (Fig. 3.11).
 - For ray amputations, leave the base of index and middle finger metacarpals to preserve the insertion of ECRL/ERCB.

STEP 4 PEARLS

Attempt to trim any bony spicules or radial/ulnar prominence to avoid leaving the stump with abnormally wide or prominent edges.

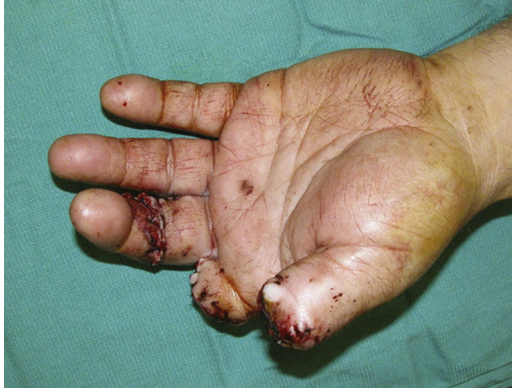

FIG. 3.10

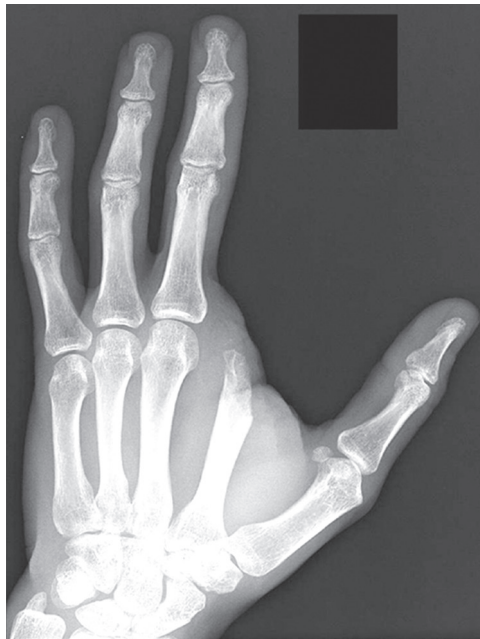

FIG. 3.11

Step 5: Close the Skin Flaps Over the Distal Bone

- No buried sutures are needed. Place interrupted nylons in the skin (Fig. 3.10).
- Do not suture the flexor tendon to the extensor tendon or tack the tendons down as this can substantially limit function of the hand.
- Consider loosely closing the skin flaps to allow drainage of any contaminated fluid as the wounds heal (rather than tight closure of all wound margins).
- In children, consider closing with chromic suture that does not need removal, as compliance with suture removal may be a challenge.

Procedure: Elective Amputation (Transmetacarpal or Ray Amputation)

If performing transmetacarpal or ray amputations to remove nonfunctional digit after revision finger amputation or for ischemia/malignancy, consider these additional steps.

Step 1

The base/metacarpophalangeal joint of the finger to be amputated should be marked with a curvilinear teardrop-shaped incision on the volar aspect, and a Y-shaped incision more proximal over the metacarpal on the dorsal aspect (Fig. 3.13A and B).

STEP 5 PEARLS

If there is a question of viability of remaining soft tissues, examine again in approximately 48 hours to determine whether additional debridement is required or if it can be treated with local wound care.

STEP 5 PITFALLS

- Suturing the flexor tendon to the extensor tendon, or otherwise tethering the flexor tendon to the finger during closure, risks developing quadregia.
- Avoid volar-based wound closure if possible, as this risks painful scars on the functional surface of remaining fingers (Fig. 3.12).

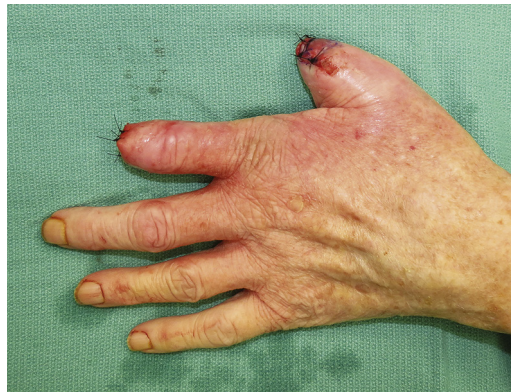

FIG. 3.12

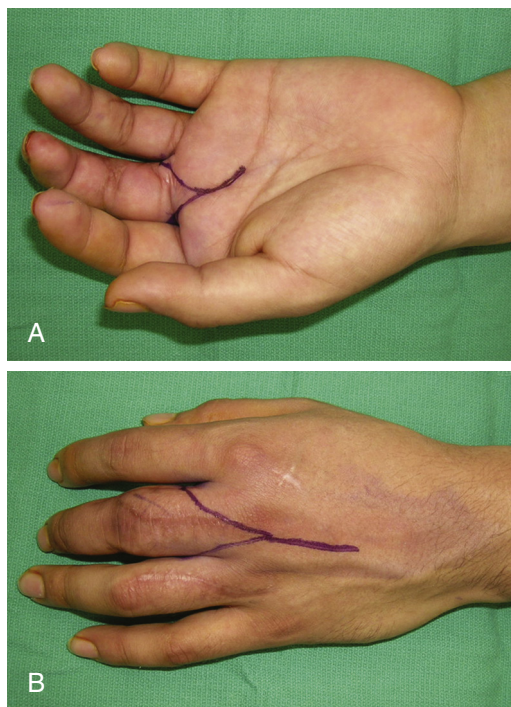


FIG. 3.13

Step 2

- Start with volar incision, and identify the digital neurovascular bundles to the finger (Fig. 3.14).
 - After identifying a nerve, place on slight traction and see if it pulls in the webspace; if there is a tethering in the webspace, this is the proper digital nerve and it can be transected. If not, one may have the common digital nerve and need to explore further so as not to damage sensation of the adjacent digit.
- Identify the A1 pulley, divide it, and transect the flexor tendons to the digit.

Step 3

Cut down to bone, and elevate whatever volar soft tissues are tethered to bone, protecting soft tissues on either side of the metacarpal.

Step 4

- Turn to the dorsal side, make the Y incision overlying the bone.
- Cut down, divide the extensor tendon to that digit, and continue down to bone before using elevator to lift interosseous muscles off the metacarpal.
 - Again, mobilize soft tissues to each side, protecting the neurovascular bundles, and avoid unnecessary trauma to the muscles and intermetacarpal ligaments.

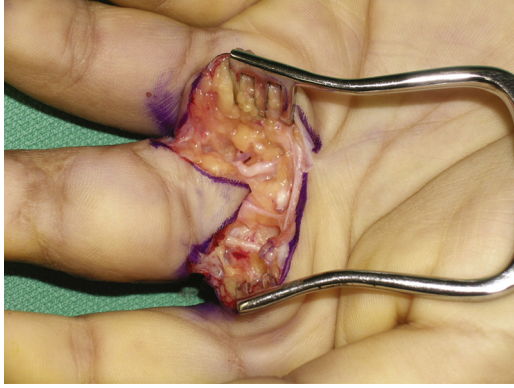


FIG. 3.14

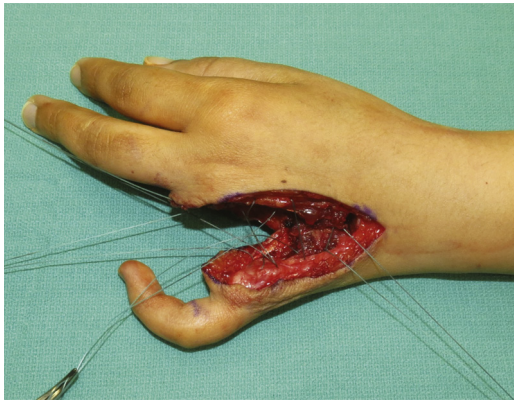


FIG. 3.15

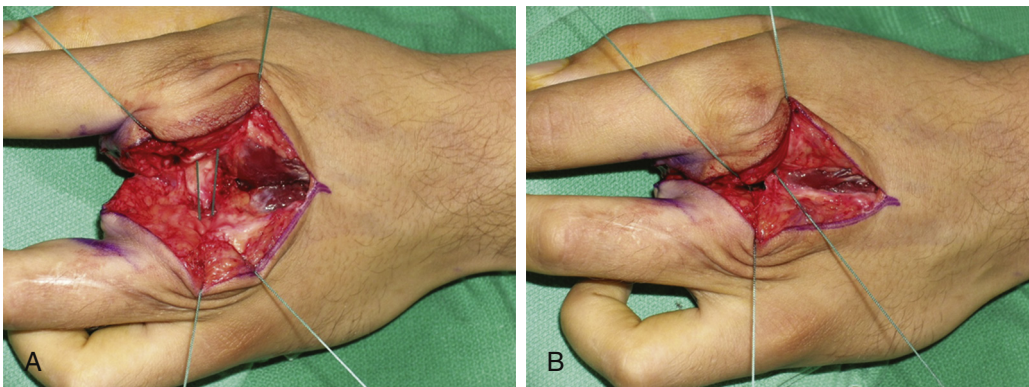


FIG. 3.16

Step 5

- Divide the transmetacarpal ligaments, preserving as much length as possible.
- Use saw to cut through metacarpal and remove the finger and metacarpal (see [Step 4: Revision Amputation](#) for additional information about the bony cut).

Step 6

- Use 2-0 Ethibond (or other braided suture of choice) to bring transmetacarpal ligaments together and close down the open space ([Figs. 3.15 and 3.16A and B](#)).
 - Be cautious not to overtighten this suture because it can pull in the adjacent fingers and they can end up crossing over each other.
- One can use buried absorbable suture to loosely bring soft tissues together, close down dead space, and cover the permanent suture.
- Close overlying soft tissue with interrupted nylon suture ([Fig. 3.17A and B](#)).

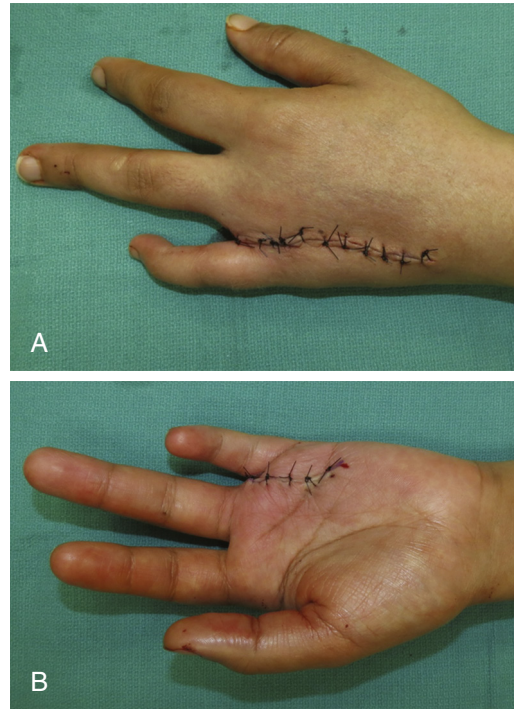


FIG. 3.17

Postoperative Care and Expected Outcomes

- Often the patient with finger amputations is discharged with only a soft dressing unless other more proximal injuries are also identified.
- After 48 hours, begin standard wound care with gentle cleansing and dressing changes (our preference is Xeroform daily or bacitracin twice a day).
- With dressings in place, we encourage wrapping and elevation to control edema.
- Once the wounds heal, patients are cleared to return to activities gradually. It is often a much more rapid recovery than if complex reconstruction was performed.
- After metacarpal-level amputations, we often will place patient in intrinsic-plus volar splint while healing to prevent collapse of border metacarpals and abnormal remaining finger cascade.

See Video 3.1, *Revision Amputation and Treatment of Painful Neuroma*, on [Expert Consult.com](#).

EVIDENCE

Blazar PE, Garon MT. Ray resections of the fingers: indications, techniques, and outcomes. *J Am Acad Orthop Surg* 2015;23:476–84.

Review of ray amputation. Major negative outcome reported is 15% to 30% loss of grip and pinch strength, otherwise patients with overall high satisfaction and successful long-term function.

Chow SP, Ng C. Hand function after digital amputation. *J Hand Surg Br* 1993;18:125–8.

This article is a review of outcomes after finger amputations. Power grip and key pinch returned to 70% of unaffected side by 1 year. Multiple finger amputation injuries resulted in weaker grip and key pinch. Twenty-five percent of patients had to change jobs and 20% expressed concerns regarding the appearance of their injured hand.

Wang K, Sears ED, Shauver MJ, Chung KC. A systematic review of outcomes of revision amputation treatment for fingertip amputations. *Hand (NY)* 2013;8:139–45.

This article is a review of outcomes after revision amputation for fingertip injuries. The authors reviewed 38 studies, and concluded that near-normal sensation could be restored with satisfactory motion. Return to work took an average of 7 weeks.

Whitaker LA, Graham 3rd WP, Riser WH, Kilgore E. Retaining the articular cartilage in finger joint amputations. *Plast Reconstr Surg* 1972;49:542–7.

This article presents an experiment in cats that evaluated disarticulation amputation vs. cartilage removal at distal amputation site. Inflammation and remodeling occurred more quickly in the disarticulation model with longer recovery time in cases where the cartilage had been denuded.

Yuan F, McGlinn EP, Giladi AM, Chung KC. A systematic review of outcomes after revision amputation for treatment of traumatic finger amputation. *Plast Reconstr Surg* 2015;136:99–113.

This is a systematic review of treatment for revision amputation injuries. The mean static two-point discrimination was 5 mm, with total active motion 93% of normal (slightly better after revision amputation compared with local flap coverage). Seventy-seven percent of patients report cold intolerance. Ninety-one percent reported satisfactory or good/excellent overall function regardless of treatment.

Drainage of Septic Arthritis (Including Fight Bite) and Septic Tenosynovitis

Aviram M. Giladi and Kevin C. Chung

Drainage of Septic Arthritis (Including Fight Bite)

Indications

- Clinical diagnosis of infective arthritis—purulent exudate within the closed joint space.
- Associated with painful, erythematous, and swollen joint (Fig. 4-1). Many patients will hold the finger in slight flexion. Pain with axial loading is a telling finding. May see soft tissue injury/puncture along dorsum of joint (inoculation site).
- Higher concern in diabetic or immunocompromised patients.
- For concerns about septic arthritis of the wrist, one may use joint aspiration to aid in diagnosis. Aspiration is also an option for infection in smaller joints of the hand, although fluid yield from such small joints is not as consistently reliable.
- Fight bite injury is a unique presentation of a septic arthritis, in which dorsal metacarpal injury occurs from closed-fist contact with teeth, causing an inoculating puncture wound with possible tendon injury (often proximal to the joint once fingers are extended) and high incidence of subsequent septic arthritis (Fig. 4.2A and B).
- Low threshold to operate on these patients even before fulminant pyogenic infection develops.

Imaging

- X-ray to rule out associated osteomyelitis, gas in the joint, or any retained foreign body (especially in the setting of fight bite injury).

Surgical Anatomy

- If attempting to aspirate fluid from the wrist, Lister tubercle on the dorsum of the distal radius is the landmark. The radiocarpal joint can be approached 1 cm distal to Lister tubercle, with an 18-gauge needle directed in a slightly proximal direction to account for the tilt of the distal radius (Fig. 4.3).

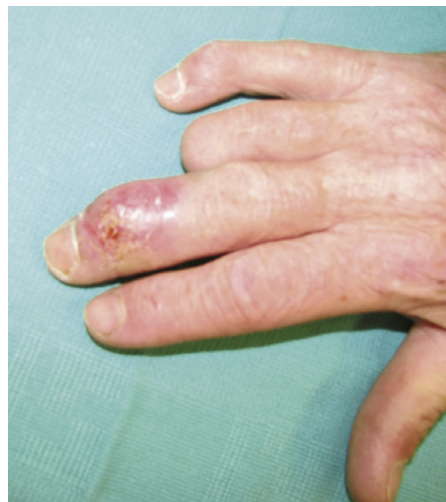

Fig. 4.1

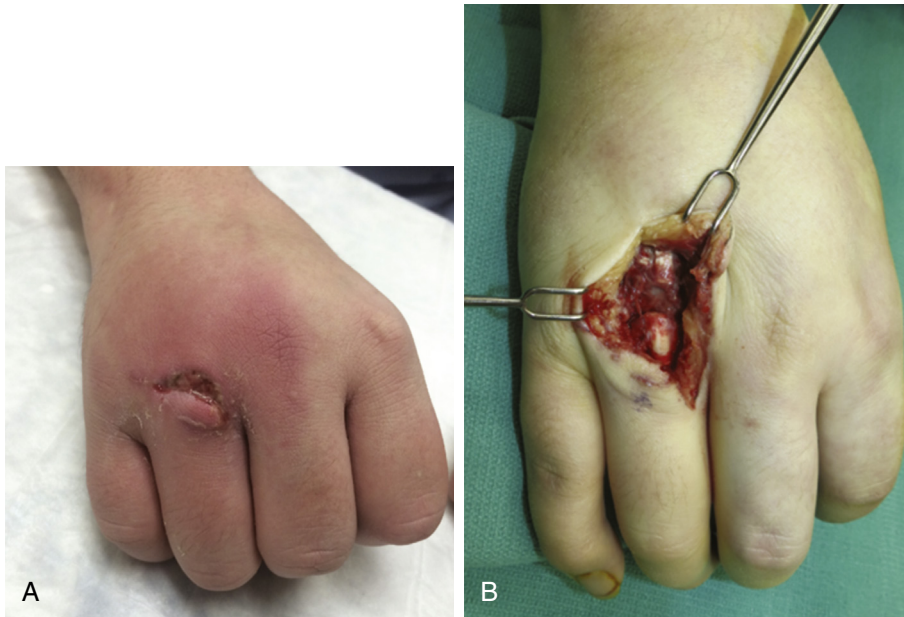


Fig. 4.2 A-B

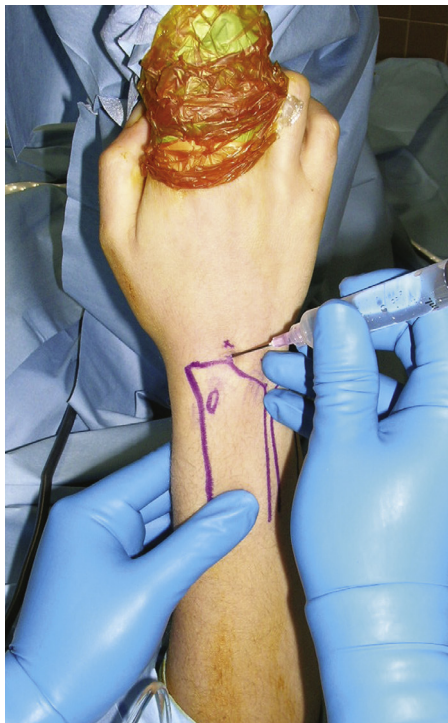


Fig. 4.3

- If aspiration of the midcarpal joint is required, this can be done approximately 1 cm distal to the approach for the radiocarpal joint.
- Approaching the infected metacarpophalangeal (MCP) joint is done with a dorsal approach. The joint can be accessed either by splitting the extensor tendon longitudinally, or by making an incision through the sagittal band adjacent to the extensor tendon.
- In approaching the proximal interphalangeal (PIP) joint, a midaxial approach is used. One must divide the transverse retinacular ligament and then make a window in the accessory collateral ligament to access the joint (Fig. 4.4). Digital bundle is retracted volarly into the volar skin flap.

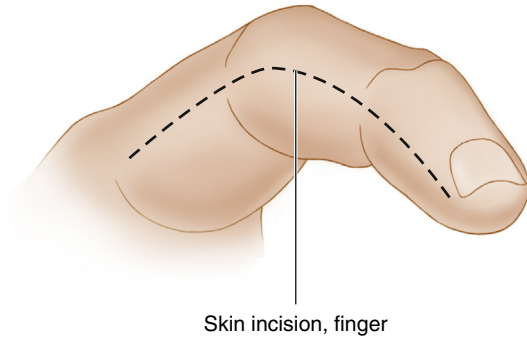


Fig. 4.4

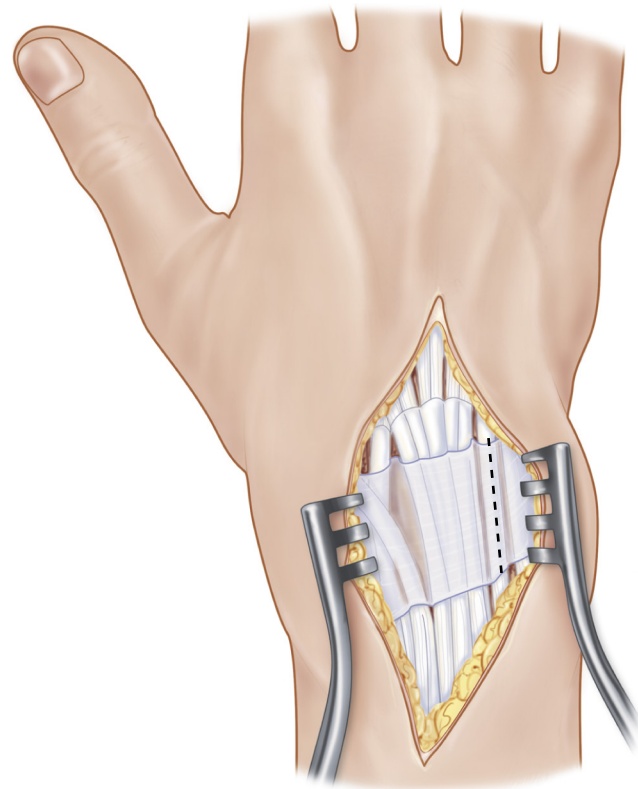


Fig. 4.5

- The distal interphalangeal (DIP) joint is approached dorsally. The terminal aspect of the extensor tendon should be retracted, avoiding any injury. This will allow access to the joint.

Positioning

- If using a tourniquet, avoid compression/wrap before inflation so that the infected materials are not milked proximally. Use gravity to augment venous drainage before tourniquet inflation.

Exposures

- Surgical incision to approach the wrist is made in relation to Lister tubercle. This incision is made longitudinally, just ulnar to the tubercle. This allows for a dorsal wrist approach between the third and fourth dorsal compartments (Fig. 4.5).
- Approaching the PIP joint is done through a midaxial incision. This incision allows the surgeon to mobilize the digital bundle volarly; however, dorsal sensory branches can still be injured especially if any dorsal elevation is performed (Fig. 4.4).

- The incision approach to the PIP joint can be extended as far proximal as the web-space, and as far distal as the DIP joint.
- DIP joint is approached dorsally, usually through an H-shaped incision or a T-shaped incision.

Procedure

Step 1: Approach

Septic Arthritis of the Wrist

- Approach via dorsal incision.
- Longitudinal incision is made ulnar to Lister tubercle.
- Avoid injury to dorsal veins and radial sensory branches.
- Identify interval between third (extensor pollicis longus [EPL]) and fourth (extensor digitorum) dorsal compartments and divide it to approach the joint. Retract EPL radially to protect it.
- Divide dorsal joint capsule with a longitudinal incision. This may require exposure of proximal radiocarpal joint as well as midcarpal joint if the proximal joint does not appear to be infected.

Septic Arthritis of the MCP Joint

- Approach via dorsal incision.
- Longitudinal or S-shaped incision directly over the joint.
- Identify the extensor tendon.
 - One can split the tendon longitudinally for access to the joint.
 - Alternatively, one can split the sagittal band to the side of the extensor tendon.
- Divide the joint capsule (if it was not divided with the previous incision, which may occur).

Septic Arthritis of the PIP Joint

- Approach via midaxial incision.
- Incision is made along midaxial line.
- Retract soft tissue bundle volarly, protecting the neurovascular bundle.
- Divide transverse retinacular ligament.
- Excise window of accessory collateral ligament.
- Perform capsulectomy to access the joint space.

Septic Arthritis of the DIP Joint

- Approach via dorsal H-shaped incision.
- Make the dorsal incision over the joint.
- Identify the distal extensor tendon attachments to the base of the distal phalanx.
- Retract the extensor tendon to expose the dorsal joint space.

Step 2: Copious Irrigation of the Infected Joint

- Use TUR tubing or other gentle flow washout to clear infected fluid. Avoid pulse irrigation as this can damage the weakened cartilage.
- Put joint on traction to open up the space.
- Flex/extend the joint to open up the space and clear infected material.

Step 3: Debridement

- Any area of necrotic tissue or inflammatory synovium should be debrided.
- Send specimens of debrided tissue for culture and pathology examination.
- Inspect joint surfaces and avoid debridement of these areas unless the areas are frankly infected and risk development of osteomyelitis.
 - This is especially important for fight bite injury, as a tooth fragment can be trapped within the joint cartilage, or an injury to the joint may have occurred that requires debridement (Fig. 4.6).

Step 4: Closure

- To prevent early closure of the capsulotomy site, a wick should be placed to allow continued drainage.

EXPOSURES PEARLS

- For index finger, incision should be on ulnar aspect to avoid the contact surface.
- For small finger, incision should be on radial aspect.
- For middle and ring fingers, incision can be placed on either side.

STEP 1 PEARLS

- Septic arthritis of the PIP joint
 - Avoid dorsal soft tissue elevation in the area of the PIP joint; this may damage dorsal sensory branches or dorsal veins.
- Septic arthritis of the DIP joint
 - Incision should be made superficial; the tendon is very superficial at this level and can easily be injured.

STEP 1 PITFALLS

- Septic arthritis of the DIP joint
 - Any injury to the extensor tendon insertion must be addressed; an untreated injury can lead to mallet deformity.

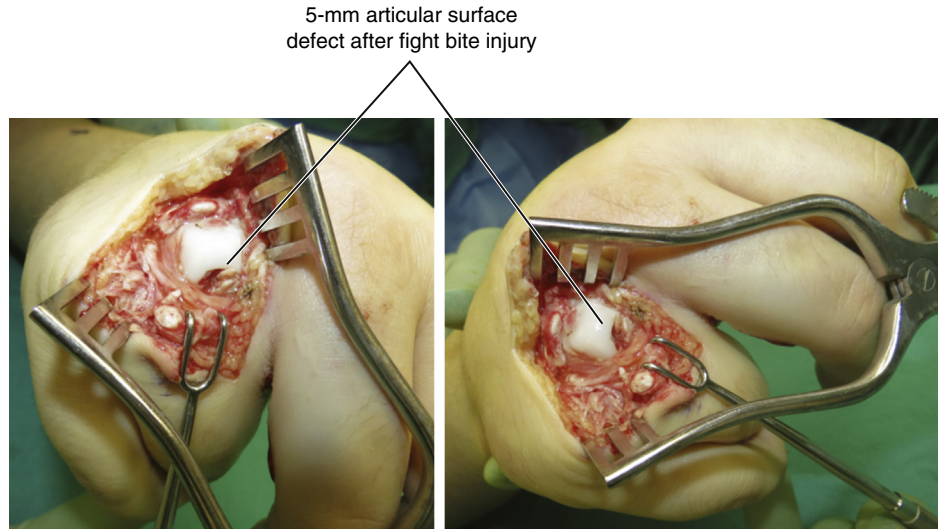


Fig. 4.6

- There is no need to close the dorsal wrist capsule after debridement, but skin should be tacked together loosely using nylon suture, with the wick in place.
- For MCP, if tendon was split during the approach, the tendon should be repaired with absorbable suture. Similarly, the sagittal band should be repaired if it was divided. Tack overlying skin closed loosely with nylon suture.
- For PIP and DIP, loosely tack skin closed with nylon suture.
- On all of these closures, the loosely tacked wounds should be dressed with moist gauze that is changed three times daily starting on postoperative day 1 (POD 1).
- Remove wicks at 36 to 48 hours postoperative.
- Plan for return to operating room (OR) for additional washout and debridement within 48 hours if there is any concern for retained infectious material after first debridement.

Postoperative Care and Expected Outcomes

- Moist dressings overlying the loosely closed wounds should be changed three times daily.
- On POD 1 the patient can begin with soaks three times a day, along with dressing changes. These can be done in a 1:1 mix of peroxide and water. Active and passive range-of-motion (ROM) exercises should be done during the soaking.
- If wick does not fall out with soaks, it should be removed within 36 hours.
- Removable splints should be used for elevation and resting, but patient should come out for early ROM exercises to help clear retained infectious fluid and prevent additional stiffness.
- Intravenous (IV) antibiotics should be used, tailored to culture results. Can transition to oral antibiotics once appropriate organism is identified.

POSTOPERATIVE PEARLS

Duration of IV and oral therapy is debated. We use IV antibiotics for approximately 2 weeks, or until symptom improvement if that takes slightly longer. Then oral antibiotics are used to complete a total of 6 weeks of therapy.

Drainage of Septic Tenosynovitis

Indications

Clinical diagnosis of acute infective tenosynovitis

Indicated by Kanavel's signs—fusiform digit swelling, pain with passive extension, tenderness over the flexor tendon, and/or finger held in slight flexion (Fig. 4.7A and B). Many believe that pain along the tendon and pain with passive extension are the most indicative. For mild cases a course of admission with IV antibiotics before surgery is warranted. Consider washout especially when symptoms have been present for over 24 hours and are worsening.

May see volar soft tissue injury as inoculation site (Fig. 4.8).

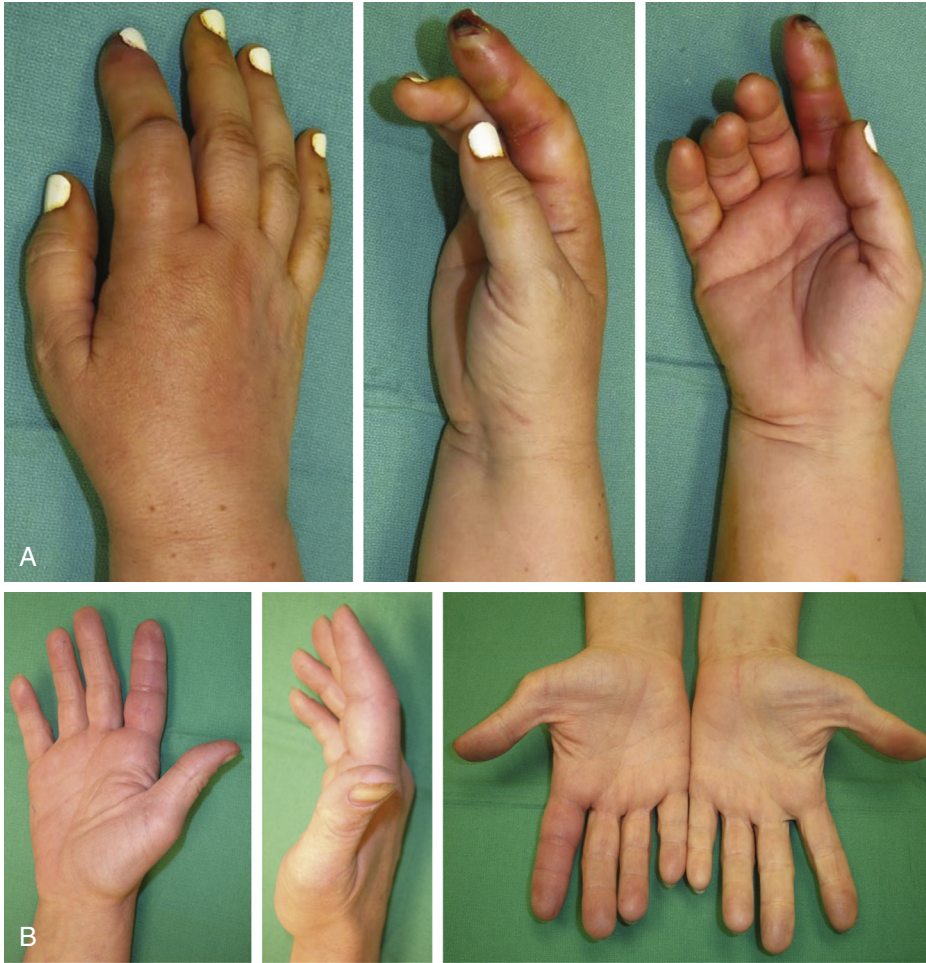

Fig. 4.7 A-B

The abscess at incision
of trigger finger release.

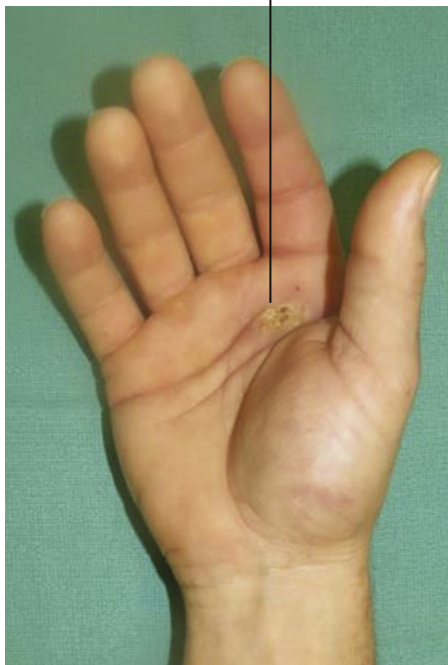


Fig. 4.8