

# Oncoplastic Breast Surgery Techniques for the General Surgeon

V. Suzanne Klimberg  
Tibor Kovacs  
Isabel T. Rubio  
*Editors*

 Springer

*Editors*

V. Suzanne Klimberg, Tibor Kovacs and Isabel T. Rubio

# **Oncoplastic Breast Surgery Techniques for the General Surgeon**



---

*Editors*

V. Suzanne Klimberg  
University of Texas Medical Branch, Galveston, TX, USA  
MD Anderson Cancer Center, Houston, TX, USA

Tibor Kovacs  
Breast Surgery, Guy's and St. Thomas' Hospital, King's College London Guy's and St. Thomas' Hospital, London, UK

Isabel T. Rubio  
Clinica Universidad de Navarra, Universidad de Navarra, Madrid, Spain

ISBN 978-3-030-40195-5 e-ISBN 978-3-030-40196-2  
<https://doi.org/10.1007/978-3-030-40196-2>

© Springer Nature Switzerland AG 2020

This work is subject to copyright. All rights are reserved by the Publisher, whether the whole or part of the material is concerned, specifically the rights of translation, reprinting, reuse of illustrations, recitation, broadcasting, reproduction on microfilms or in any other physical way, and transmission or information storage and retrieval, electronic adaptation, computer software, or by similar or dissimilar methodology now known or hereafter developed.

The use of general descriptive names, registered names, trademarks, service marks, etc. in this publication does not imply, even in the absence of a specific statement, that such names are exempt from the relevant protective laws and regulations and therefore free for general use.

The publisher, the authors and the editors are safe to assume that the advice and information in this book are believed to be true and accurate at the date of publication. Neither the publisher nor the authors or the editors give a warranty, express or implied, with respect to the material contained herein or for any errors or omissions that may have been made. The publisher remains neutral with regard to jurisdictional claims in published maps and institutional affiliations.

This Springer imprint is published by the registered company Springer Nature Switzerland AG  
The registered company address is: Gewerbestrasse 11, 6330 Cham, Switzerland

---

*To our family, friends, colleagues, and mentors with appreciation for their generous support of our careers which has allowed the development of this book. Most of all to our patients who have been our constant and faithful partners as we struggle to improve their outcomes from breast disease.*

---

## **Preface**

This book covers an up-to-date review of advances in the management strategies for patients with breast cancer and their comorbidities. The goal of this book is to increase the competencies and performance of healthcare professionals involved in treating this patient population, which will ultimately improve the aesthetic outcomes, quality of life, and overall survival of patients with breast disease and breast cancer. Oncoplastic breast surgery represents a “third pathway” between standard breast conservation and mastectomy. It allows wide excisions and removal of large portions of the breast without compromising the natural shape of the breast. It combines plastic surgery techniques for immediate breast reshaping with techniques of oncological resectional surgery. Surgical breast deformities are avoidable and unnecessary with preoperatively planned oncoplastic procedures.

Oncoplastic breast surgery combines tumor removal with breast reconstruction techniques. Oncoplasty became standard of care for breast conservation surgery and can lead to improving aesthetic outcomes of breast cancer surgery, without compromising oncological outcomes. Its goal is to avoid the breast distortion that accompanies breast cancer surgery and tumor removal. This type of surgery allows for immediate remodeling techniques to rebuild breast shape as breast tissue is being removed. Oncoplastic procedures may include breast lift, breast reduction, utilization of the skin and tissue flaps, and nipple skin-sparing techniques, all of which are covered in this book and performed or optimized by the general surgeon.

Advanced oncoplastic reconstruction should allow for coordinated efforts between the general surgeon and the plastic surgeon to include planned imaging in a multidisciplinary fashion. This book will help the general surgeon to provide improved oncologic as well as aesthetic results for patients.

**V. Suzanne Klimberg**

**Tibor Kovacs**

**Isabel T. Rubio**

**Galveston, TX, USA, London, UK, Madrid, Spain**

---

## Acknowledgments

We, the editors of the inaugural edition *Oncoplastic Techniques for the General Surgeon* are indebted to each contributor for their invaluable time and efforts taken from their already busy academic and clinical practices to provide us with intraoperative photos and depictions of their oncoplastic techniques used in the breast. The authors have detailed not only best practices for conventional procedures but new and evolving techniques that are not found in the usual textbooks and atlases. We are very appreciative of the efforts of the contributors to detail the step-by-step instruction and that of the artists and illustrators at *Springer Nature* in developing precise illustrations. Collectively, this collection of work is usable from the medical students and general surgeons seeking to improve results in private practice to professors learning and teaching new breast surgery techniques.

We would also like to thank the staff members of Springer Nature, Richard Hruska, Executive Editor, and Lillie Gaurano, Assistant Editor, both in Medicine & Life Science, Books, who have made the publication of this *inaugural* oncoplastic book possible. In particular, we would like to thank Prakash Jagannathan, Project Coordinator for Development/Production, for his helpful day-to-day editorial exchanges with the contributing authors, artists, and editors, ensuring quality, accuracy, and coordination in the development of this book.

We and our authors are grateful to the multiple residents, fellows, students, and participating colleagues and patients who have supported our efforts with their insightful contributions, questions, and support in the treatment of breast disease that has been the basis for this book.

---

# Contents

## **1 Concept, Principles and Indication of Oncoplastic Breast Surgery: Fashion or Necessity**

Stergios E. Douvetzemis and Tibor Kovacs

## **2 Topographic Anatomical Relationships of the Breast, Chest Wall, Axilla, and Related Sites of Metastases**

Kirby I. Bland

## **3 Imaging for Oncoplastic Procedures**

Gwendolyn Bryant-Smith and Ronda S. Henry-Tillman

## **4 Measurement and Optimizing Cosmetic Outcomes for Breast Excisions/Factors Influencing Aesthetic Outcomes of Breast Conservation Surgery**

Joerg Heil, Fabian Riedel, Michael Golatta and André Hennigs

## **5 Quadrant by Quadrant Preoperative Planning for Oncoplastic Resections**

Walter P. Weber, Christian Kurzeder and Martin Haug

## **6 Oncoplastic Surgery**

Yoav Barnea and Moshe Papa

## **7 Crescent Mastopexy**

Michael Knauer

## **8 Round Block or Donut Mastopexy**

Michael Knauer

## **9 Batwing and Hemibatwing Mammoplasty**

Dennis Ricky Holmes

## **10 Grisotti Flap Mammoplasty**

Abby Geletzke, Erik Hoy and Jennifer S. Gass

## **11 Reduction Mammoplasty Marking**

Paul Thiruchelvam and Shadi Ghali

## **12 Superior Pedicle Oncoplasty**

Fabien Reyat, Enora Laas, Gabrielle Aubry, Julie Labrosse, Apolline Bout-Roumazelles, Anne Sabaila, Léa Rossi, Jean-Guillaume Feron, Jean-Philippe Binder and Benoit Couturaud

## **13 Inferior Pedicle Reduction Mammoplasty or Reconstruction of Tumor Defects Following Partial Breast Resection**

Peter Schrenk and Florian Fitzal

## **14 V Mammoplasty**

Peter A. Barry and Pooja Padmanabhan

## **15 Thoraco-Epigastric Pedicled Flap for Partial Breast Reconstruction**

Laszlo Romics, Eva Weiler-Mithoff and Elizabeth Morrow

## **16 Lateral Pedicle Mammoplasty**

Cicero Urban, Flávia Kuroda and Vanessa Amoroso

## **17 Oncoplastic Breast Reconstruction: Extreme Oncoplasty and Split Reduction Techniques**

Sadia Khan, Nirav B. Savalia and Melvin J. Silverstein

## **18 Skin-Reducing Mastectomy: Dermal Sling**

Maurizio Bruno Nava, Nicola Rocco and Giuseppe Catanuto

## **19 Simple and Skin Sparing Mastectomy**

Stephanie A. Valente and Stephen R. Grobmyer

## **20 Total or Nipple Skin-Sparing Mastectomy**

Isabel T. Rubio

## **21 Staged Nipple-Sparing Mastectomy for Patients with Large or Ptotic Breasts**

Shawna C. Willey, Troy A. Pittman and James M. Economides

## **22 Donut Mastectomy**

V. Suzanne Klimberg

## **23 Technology-Assisted Mastectomy: Robotic- and Endoscopic-Assisted Mastectomy**

Benjamin Sarfati and Giuseppe Sanese

## **24 Goldilocks Mastectomy**

Heather Richardson

## **25 Nipple–Areola Complex Reconstruction**

Zoltán Mátrai

## **26 Free Nipple Graft**

Stergios E. Douvetzemis and Tibor Kovacs

## **27 Subpectoral Implant-Based Breast Reconstruction**

Neil S. Sachanandani, Benny K. Tan and James C. Yuen

**28 Pre-pectoral Implant Breast Reconstruction: The Better Option?**

Ashutosh Kothari, Hisham Hamed and Tibor Kovacs

**29 TAP, LICAP, SAAP, and AICAP Flaps**

Elise Mecham, Julie Park and Linda Phillips

**30 Surgical Resection and Utilization of Fasciocutaneous Advancement Flaps for Locally Advanced Breast Cancer: The Closure**

Daniela Ochoa and Ronda S. Henry-Tillman

**31 Surgery Following Primary Systemic Therapy: How to Increase Breast Conservation Rate**

Rosa Di Micco and Oreste Davide Gentilini

**32 Using Oncoplastic Techniques to Salvage Poor Outcomes of Breast Conservation**

Maurizio Bruno Nava, Giuseppe Catanuto and Nicola Rocco

**33 Oncological Outcomes and Safety of Oncoplastic Breast Conservation**

Laszlo Romics and Esther Jennifer Campbell

**34 Treating Complications of Oncoplastic Breast Surgery**

Maurizio Bruno Nava, Giuseppe Catanuto and Nicola Rocco

**35 Education and Training in Oncoplastic Breast Surgery**

Gustavo Zucca-Matthes

**36 Oncoplastic Breast Surgery Techniques for the General Surgeon**

Gustavo Zucca-Matthes

**Index**



---

## Contributors

### **Vanessa Amoroso, MD**

Department of Breast Surgery, Our Lady of Grace Hospital and Little Prince Medical School, Curitiba, Paraná, Brazil

### **Gabrielle Aubry, MD**

Department of Surgery, Institut Curie, Paris, France

### **Yoav Barnea, MD**

Tel Aviv University Medical School, Tel Aviv-Yafo, Israel

Department of Plastic and Reconstructive Surgery, 'Sourasky' Tel Aviv Medical Center, Tel Aviv-Yafo, Israel

Department of Breast Surgery "Assuta" Medical Center, Tel Aviv-Yafo, Israel

Peres Academic Center, Rehovot, Israel

### **Peter A. Barry, FRACS, MPhil**

Breast Unit, Royal Marsden NHS Foundation Trust, London, UK

### **Jean-Philippe Binder, MD**

Department of Surgery, Institut Curie, Paris, France

### **Kirby I. Bland, MD, FACS**

UAB Hospitals and Clinics, Birmingham, AL, USA

University of Alabama in Birmingham, School of Medicine, Birmingham, AL, USA

UAB O'Neal Comprehensive Cancer Center, Birmingham, AL, USA

### **Apolline Bout-Roumazelles, MD**

Department of Surgery, Institut Curie, Paris, France

### **Gwendolyn Bryant-Smith, MD**

Breast Imaging, University of Arkansas for Medical Sciences, Little Rock, AR, USA

### **Esther Jennifer Campbell, MD**

Department of Surgery, University Hospital Crosshouse, Crosshouse, Kilmarnock, UK

### **Giuseppe Catanuto, MD**

Group for Reconstructive and Therapeutic Advancements, G.RE.T.A, Milan, Naples, Catania, Italy

Multidisciplinary Breast Unit, Azienda Ospedaliera Cannizzaro, Catania, Italy

Department of Clinical Medicine and Surgery, University of Naples "Federico II", Naples, Italy

### **Benoit Couturaud, MD**

Department of Surgery, Institut Curie, Paris, France

### **Stergios E. Douvetzemis, MD**

Breast Surgery, Guy's and St Thomas' NHS Foundation Trust, London, UK

King's College, London, UK

Department of Anatomy and Surgical Anatomy, Medical School, University of Athens, Athens, Greece

### **Rosa Di Micco, MD**

Breast Unit, San Raffaele University and Research Hospital, Milan, Italy

Department of Clinical Medicine and Surgery, University of Naples Federico II, Naples, Italy

### **James M. Economides, MD**

Private Practice, Arlington, VA, USA

Private Practice, Washington, DC, USA

### **Jean-Guillaume Feron, MD**

Department of Surgery, Institut Curie, Paris, France

### **Florian Fitzal, MBA, FEBS**

University Clinic for Surgery, Comprehensive Cancer Center Vienna, Medizinische Universität Wien 21A, Wien, Austria

### **Jennifer S. Gass, MD, FACS**

Women and Infants' Hospital, Providence, RI, USA

Alpert Medical School, Brown University, Providence, RI, USA

### **Abby Geletzke, MD**

University of Pittsburgh Medical Center, Pinnacle, Lancaster, PA, USA

### **Oreste Davide Gentilini, MD**

Breast Unit, San Raffaele University and Research Hospital, Milan, Italy

**Shadi Ghali, MD, FRCS (Plast)**

University College London, University of London, The Royal Free Hospital Foundation Trust, London, UK

**Michael Golatta, MD**

University Hospital Heidelberg, Department of Obstetrics and Gynecology, Heidelberg, Germany

**Stephen R. Grobmyer, MD, FACS**

Cleveland Clinic Abu Dhabi, Abu Dhabi, UAE

**Hisham Hamed, MD**

Department of Breast Surgery, Guy's & St. Thomas NHS Foundation Trust, London, UK  
King's College, London, UK

**Martin Haug, MD**

Breast Center, University Hospital Basel, Basel, Switzerland

**Joerg Heil, MD**

University Hospital Heidelberg, Department of Obstetrics and Gynecology, Heidelberg, Germany

**André Hennigs, MD**

University Hospital Heidelberg, Department of Obstetrics and Gynecology, Heidelberg, Germany

**Ronda S. Henry-Tillman, MD, FACS**

Department of Surgery, University of Arkansas for Medical Sciences and the Winthrop P. Rockefeller Institute, Little Rock, AR, USA

**Dennis Ricky Holmes, MD**

Department of Surgery, John Wayne Cancer Institute, Santa Monica, CA, USA

**Erik Hoy, MD, MBA**

Division of Plastic Surgery, Women and Infants' Hospital, Providence, RI, USA

**Sadia Khan, DO, FACS**

Hoag Memorial Hospital Presbyterian, Newport Beach, CA, USA  
Department of Surgery, Keck School of Medicine, University of Southern California, Los Angeles, CA, USA

**V. Suzanne Klimberg, MD, PhD**

University of Texas Medical Branch, Galveston, TX, USA  
MD Anderson Cancer Center, Houston, TX, USA

**Michael Knauer, MD, PhD, FEBS**

Breast Center Eastern Switzerland, St. Gallen, Switzerland

**Ashutosh Kothari, MD**

Department of Breast Surgery, Guy's & St. Thomas NHS Foundation Trust, London, UK  
King's College, London, UK

**Tibor Kovacs, MD, PhD**

Breast Surgery, Guy's & St. Thomas NHS Foundation Trust, London, UK  
King's College, London, UK

**Flávia Kuroda, MD**

Department of Breast Surgery, Our Lady of Grace Hospital, Curitiba, Paraná, Brazil

**Christian Kurzeder, MD**

Breast Center, University Hospital Basel, Basel, Switzerland

**Enora Laas, MD**

Department of Surgery, Institut Curie, Paris, France

**Julie Labrosse, MD**

Department of Surgery, Institut Curie, Paris, France

**Zoltán Mátrai, MD, PhD, med habil, FEBS**

Department of Breast and Sarcoma Surgery, National Institute of Oncology, Budapest, Hungary

**Elise Mecham, MD**

University of Texas MD Anderson Cancer Center of Houston, Houston, TX, USA

**Elizabeth Morrow, MD**

Department of Academic Surgery, University of Glasgow, Glasgow, UK

**Maurizio Bruno Nava, MD**

School of Plastic Surgery, University of Milan, Milan, Italy  
Group for Reconstructive and Therapeutic Advancements, G.RE.T.A, Milan, Naples, Catania, Italy

**Daniela Ochoa, MD, FACS**

Department of Surgery, University of Arkansas for Medical Sciences and the Winthrop P. Rockefeller Institute, Little Rock, AR, USA

**Pooja Padmanabhan, MRCSEd, DNB (Gen. Surg.), FEBSQ**

Breast Unit, Royal Marsden NHS Foundation Trust, London, UK

**Moshe Papa, FACS, FICS**

Tel Aviv University Medical School, Tel Aviv-Yafo, Israel  
Department of Breast Surgery "Assuta" Medical Center, Tel Aviv-Yafo, Israel

**Julie Park, MD**

Utah Surgical Associates, Provo, UT, USA

**Linda Phillips, MD, FACS**

Utah Surgical Associates, Provo, UT, USA

**Troy A. Pittman, MD**

Private Practice, Washington, DC, USA

**Fabien Reyat, MD, PhD**

Department of Surgery, Institut Curie, Paris, France  
Translational Research Department, RT2Lab Team, Institut Curie, Paris, France

**Heather Richardson, MD**

Bedford Breast Center, Beverly Hills, CA, USA

**Fabian Riedel, MD**

University Hospital Heidelberg, Department of Obstetrics and Gynecology, Heidelberg, Germany

**Nicola Rocco, MD**

Group for Reconstructive and Therapeutic Advancements, G.RE.T.A, Milan, Naples, Catania, Italy  
Department of Clinical Medicine and Surgery, University of Naples "Federico II", Naples, Italy  
Multidisciplinary Breast Unit, Azienda Ospedaliera Cannizzaro, Catania, Italy

**Laszlo Romics, MD**

Department of Surgery, New Victoria Hospital, Glasgow, UK  
Department of Academic Surgery, University of Glasgow, Glasgow, UK

**Léa Rossi, MD**

Department of Surgery, Institut Curie, Paris, France

**Isabel T. Rubio, MD, PhD**

Clinica Universidad de Navarra, Universidad de Navarra, Madrid, Spain

**Anne Sabaila, MD**

Department of Surgery, Institut Curie, Paris, France

**Neil S. Sachanandani, MD, FACS**

Beaumont Plastic and Reconstructive Surgery, Department of Surgery, Beaumont Health System, Royal Oak, MI, USA

**Giuseppe Sanese, MD**

PhD School on Medical-Surgical Applied Sciences-Plastic Regenerative research area, "Tor Vergata" University of Rome;  
Federated Specialization School on Plastic, Reconstructive and Aesthetic Surgery, "Sapienza", University of Rome and "Tor Vergata" University of Rome, School of Medicine, Rome, Italy

**Benjamin Sarfati, MD**

Service de Chirurgie Plastique et Reconstructrice, Gustave Roussy, Villejuif, France

**Nirav B. Savalia, MD**

Hoag Memorial Hospital Presbyterian, Newport Beach, CA, USA  
Department of Surgery, Keck School of Medicine, University of Southern California, Los Angeles, CA, USA

**Peter Schrenk, MD**

Kepler University Clinic Surgery, Linz, Austria

**Melvin J. Silverstein, MD, FACS**

Hoag Memorial Hospital Presbyterian, Newport Beach, CA, USA

Department of Surgery, Keck School of Medicine, University of Southern California, Los Angeles, CA, USA

**Benny K. Tan, MD**

Department of Plastic and Reconstructive Surgery, Johns Hopkins, Baltimore, MD, USA

**Paul Thiruchelvam, BSc, MD, PhD, FRCS**

Imperial College Healthcare, London, UK

Imperial College, London, London, UK

**Cicero Urban, MD, PhD**

Department of Breast Surgery, Our Lady of Grace Hospital, Positivo University Medical School, Curitiba, Paraná, Brazil

**Stephanie A. Valente, DO, FACS**

Lerner College of Medicine, Cleveland Clinic, Cleveland, OH, USA

**Walter P. Weber, MD**

University Hospital Basel and University of Basel, Basel, Switzerland

**Eva Weiler-Mithoff, MD**

Canniesburn Plastic Surgical Unit, Glasgow Royal Infirmary, Glasgow, UK

**Shawna C. Willey, MD, FACS**

Peterson Chair of Breast Cancer Research, Inova Schar Cancer Institute, Inova Fairfax Hospital, Fairfax, VA, USA

**James C. Yuen, MD, FACS**

Division of Plastic Surgery, University of Arkansas for Medical Sciences, Little Rock, AR, USA

**Gustavo Zucca-Matthes, MD, PhD**

Head of Breast and Reconstruction Surgery Department, Breast Unit Barretos – Barretos Cancer Hospital, Barretos, SP, Brazil

# 1. Concept, Principles and Indication of Oncoplastic Breast Surgery: Fashion or Necessity

Stergios E. Douvetzemis<sup>1,2,3</sup> and Tibor Kovacs<sup>1,2</sup>✉

(1) Breast Surgery, Guy's and St Thomas' NHS Foundation Trust, London, UK

(2) King's College, London, UK

(3) Department of Anatomy and Surgical Anatomy, Medical School, University of Athens, Athens, Greece

✉ **Tibor Kovacs**

**Keywords** Oncoplastic – Breast – Cancer – Conservation – Reconstruction – Cosmesis – Deformity

## Introduction

The breast is an aesthetic and functional organ and a symbol of motherhood, femininity, and sexuality, which typifies the central focus of a woman's anatomy. For those reasons, breast surgery should take into account its importance to each woman's identity [1].

It is undeniable that Halsted's radical mastectomy has altered breast cancer prognosis. On the other hand, there is no doubt that both surgeons and their patients struggled to accept this method as the best possible solution, because of the profound physical and psychological impact on women who decide to undergo this presumed "life-saving" surgery. Growing consciousness of screening made the diagnosis of smaller cancers possible and this altered the entire surgical approach [2].

Breast-conserving surgery (BCS) combined with radiotherapy (RT) has become the gold standard for the majority of women presenting with primary breast cancer over the last 20 years [3].

A number of prospective randomized trials have compared BCS with mastectomy, showing a survival rate that is unrelated to the type of surgery performed [4–7] and also showed that the risk of local recurrence (LR) following BCT is significantly increased when surgical margins are involved [8–10].

On the other hand, trials including patients with clear margins [11–16] did not show significant differences between BCS and mastectomy regarding local control.

The risk of LR is related to several factors, including positive margins, tumor grade, extent of in situ component, lymphovascular invasion, and age [17].

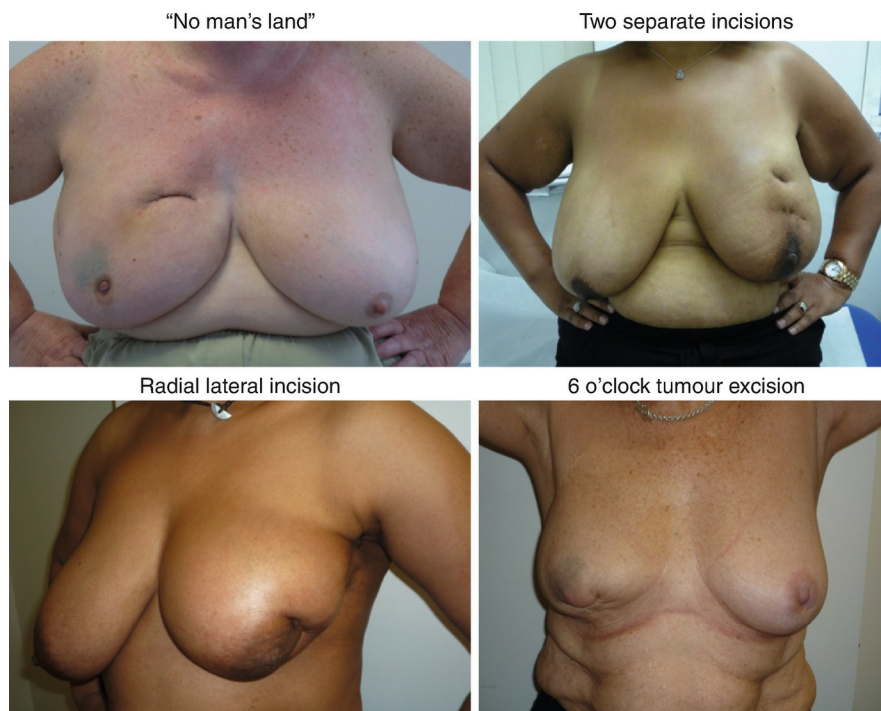In any case, the wider the margin of clearance, the less the risk of incomplete excision and thus potentially of LR, but the greater the amount of tissue excised, the higher the risk of visible deformity leading to an unacceptable cosmetic result [18].

This clash of interests is even more evident when attempting BCS in patients with smaller breast-tumor ratios [19].

Shape deformity leading to an inferior cosmetic outcome is due to the amount of breast tissue excised, the size of the breast (tumor to breast size ratio), whether or not skin is resected with the tumor, the location of the tumor in the breast, orientation of surgical incisions, and postoperative RT [20, 21].

Compromised cosmetic outcome is more often occurring when the tumor is located centrally, medially, or inferiorly into the breast [22, 23].

Residual deformities noticed after BCS and RT can either be seen immediately after surgery or develop over time and might be: glandular tissue deficiency, skin retraction or indent, nipple-areola complex (NAC) malposition, change of inframammary fold (IMF) position, and loss of natural ptosis. Cosmetic failure is more common than generally appreciated, affecting up to half of the patients undergoing BCS [24–27] (Fig. 1.1).



**Fig. 1.1** Deformities noticed after BCS and RT

Here comes the role of oncoplastic breast surgery, which allows women who may otherwise have an unacceptable cosmetic result, to avoid the above-mentioned deformities. Oncoplastic breast surgery refers to resection of the tumor with adequately free margins to achieve locoregional control (either partial or total mastectomy) and reconstruction of the defect using plastic surgical techniques, to improve the cosmetic result, immediate and late reconstruction after mastectomy, contralateral breast symmetrization, and reconstruction of the NAC, when needed.

Oncoplastic breast-conserving surgery (OBCS) allows women who may otherwise have mastectomy and immediate reconstruction the choice to conserve their breast and to avoid deformity and consists of various techniques [28].

A study that compared OBCS with mastectomy and immediate breast reconstruction, taking into consideration body image scale (BIS) scores of psychosocial function- and patient-reported outcome measures for breast appearance and return to function, showed that results significantly favored OBCS. It is interesting that case-matched women with larger breasts treated by OBCS reported better BIS scores and self-rated breast appearance than mastectomy and immediate reconstruction, whereas no significant difference was observed for smaller breasts. BIS and appearance favored OBCS, regardless of whether radiotherapy would have been avoided if treated by mastectomy and immediate reconstruction [29].

At this point a question arises. Which is the ideal breast conservation surgery? Is it conventional BCS or OBCS? Is there always a need for OBCS? Are complex oncoplastic procedures bringing the supposed benefit (less re-excisions, better aesthetics, better patient satisfaction)? The answer is that we don't really know. OBCS with adjuvant RT is an emerging area of clinical investigation, and future studies might benefit from adopting a more consistent and standardized reporting of data, for patients undergoing OBCS [28].

There is a lack of randomized controlled trials and well-designed, prospective multicenter studies comparing OBCS to conventional BCS, following a predefined algorithm. However, a large body of observational evidence consistently indicates that OBCS is oncologically safe [30].

A systematic review was done to establish the completeness of reporting of key patient, tumor, treatment, and outcomes information in the randomized-controlled trials (RCTs) of standard BCS considered to be the "gold-standard," and to compare this with the reporting of the same key criteria for all published studies for OBCS. It is interesting that there is no RCT for OBCS. 16 RCT of BCS ( $n = 11,767$  pts) were reviewed, together with 53 OBCS studies ( $n = 3236$  pts). In BCS, a mean 64% of key criteria is routinely reported, compared to OBCS, where a mean of 54% of key criteria is reported. It is obvious that there is much room for improvement in reporting key criteria and also in quality of information recorded. This publication proposed some standards to give future studies of BCS a framework for reporting key information and outcomes [31] (Table 1.1).

1. Number of patients included
2. Patient age
3. Breast age
4. Resection weight
5. Tumor size (mean, range)
6. Tumor type
7. Presence of lymphovascular invasion
8. Tumor grade
9. Estrogen receptor status
10. HER2 positivity
11. Regional lymph node involvement
12. Study definition of clear pathological margins
13. Width of closest margin (mean, range)
14. Incomplete excision rate

15. Rate of conversion to mastectomy
16. Whole breast radiotherapy given
17. Neoadjuvant chemotherapy given
18. Other adjuvant treatment given
19. Tumor bed boost radiotherapy
20. Tumor bed marking (and method)
21. Resultant breast size after radiotherapy
22. Duration of follow-up (mean, range)
23. Radiological follow-up
24. Local recurrence rate
25. Distant recurrence rate
26. Breast cancer-related mortality rate
27. Need for any procedure to exclude recurrences
28. Cosmetic outcome (preferably including patient-reported outcomes)
29. Secondary revisions

**Table 1.1** Framework for reporting key information and outcomes regarding BCS

Key reporting and additional important criteria	
Key reporting criteria	
Demographic and tumor data	Number of patients included Patient age Tumor size Tumor type Estrogen receptor status Tumor focality Tumor grade Nodal status
Surgical data	Minimum clear excision margin Number of incomplete excisions Study definition of a microscopic clear margin Number of procedures converted to mastectomy
Follow-up data	Mean follow-up Number of local and distant recurrences Mortality rate
Adjuvant therapy data	Whole breast radiotherapy delivery and dose Boost radiotherapy delivery and dose Marking of tumor bed and method used Other adjuvant treatments given
Additional important criteria	
Surgical data	Breast size Resection weight Resultant breast size after radiotherapy
Follow-up data	Radiological follow-up Need for any procedure to exclude recurrence Cosmetic outcomes Secondary revisions

## Indications

### Role of Oncoplastic Surgery

Until now, surgical options have been limited to BCS or mastectomy. BCS has focused attention on new oncoplastic techniques that can avoid unacceptable cosmetic results.

The aim was to improve long-term cosmetic outcomes following breast conservation and radiotherapy, facilitating conservation surgery where significant relative volume needs to be excised or where the location of the tumor is adverse. The interrelationship between breast-tumor ratio, volume loss, cosmetic outcome, and margins of clearance is complex [32].

OBCS avoids the need for mastectomy in selected patients and can influence the outcome of BCS in three respects:

- Oncoplastic techniques allow removal of larger tumors, without risking major local deformity.
- The use of oncoplastic techniques can extend the indication of BCS to include patients when more than 20% of breast volume needs to be excised, without compromising the adequacy of resection or the cosmetic outcome.
- OBCS can be used after previous BCS and radiotherapy to correct unacceptable deformity [33].

As previously mentioned, current trend is to reduce over-surgery for invasive breast cancer. The aim is for high-quality breast conservation where possible, with reduced re-excision rates. This is facilitated with the use of oncoplastic techniques and with the use of primary systemic therapy, as a surgical tool, to minimize the excised breast volume.

Multidisciplinary approach of each case is essential to allow multimodality treatment, which facilitates safe and less radical surgery. Cautious use of new technologies to assess disease extent, such as Breast MRI and margin “probes” is essential.

Another issue that needs to be mentioned is the need to stop performing bilateral mastectomy for unilateral disease, when there is no oncological benefit from that [34].

## Indications for OBCS

1. Patients with primary breast cancer, scheduled for BCS, when a poor cosmetic result is expected if standard BCS is used.
  - Unfavorable tumor volume to breast volume ratio is an indication for OBCS. Resection of more than 20% of breast volume is likely to result in asymmetry and poor cosmetic outcomes [21] with patient satisfaction rates of over 90% if only 5% or less of breast volume was excised, compared to 25%, when 20% of breast volume is excised [35].

OBCS in these cases permits BCS for large lesions for which a standard excision would be either impossible or lead to major deformity.
  - Unfavorable tumor location is if the tumor is in the medial, superomedial, inferior, central, or inferior parts of the breast. Excision of tumors located in the upper inner quadrant may lead to scarring in the cleavage area and indentation, if there is less breast parenchymal volume. Excision of tumors from these areas may also result in nipple malposition due to scar retraction. Resection of inferiorly sited tumors may also cause a bird's beak deformity. Centrally located tumors may require nipple sacrifice [32].
  - Multifocal or multicentric disease. There is emerging evidence that breast conservation in multifocal (MF) disease is oncologically safe [36] but may result in a slightly inferior outcomes. The use of OBCS is also emerging in the treatment of multicentric disease, where BCS was considered to be a contraindication, until recently. However, evidence supporting the oncological safety of this approach is still weak, although a number of case series show acceptable oncological outcomes [37, 38].
  - Extensive DCIS or invasive lobular carcinoma and partial or poor responses to neoadjuvant chemotherapy are other possible indications for OBCS.
  - Macromastia. OBCS may be seen as an opportunity for simultaneous bilateral breast reduction, which may have considerable appeal in their quality of life. They can obtain oncologically safe and cosmetically excellent outcomes with therapeutic reduction mammoplasty. The tumor may be excised en bloc with the reduction tissue, provided that margin marking and orientation is meticulously done. Rates of LR with this technique are acceptable [39–41]. However, there is a lack of randomized controlled trials.
2. OBCS has a role following standard BCS:
  - Patients who need re-excision for involved margins and where a simple re-excision may end up in a shape deformity [42].

In these cases, the use of OBCS is the means to avoid total mastectomy and achieve an acceptable aesthetic result.
  - Patients with free margins but who seek correction of defects for cosmetic reasons, following BCS. It is important to remember that BCS followed by radiotherapy is associated with increased morbidity due to radiation and inferior long-term cosmesis.
3. Patients scheduled for mastectomy:

Patients with primary breast cancer scheduled for total mastectomy, who seek immediate breast reconstruction with implants or autologous flaps.

## Contraindications for OBCS

There are oncological and cosmetic contraindications for OBCS. When breast conservation is unlikely to result in an acceptable cosmetic outcome, due to unfavorable tumor to breast size ratio or when tumor-free margins cannot be obtained, even with the use of OBCS techniques, then breast conservation is not recommended. In these cases, there is a clear indication either for upfront mastectomy and immediate or delayed reconstruction or for primary systemic treatment, with a view to BCS, based on the tumor biology and response [32]. Even in the cases where neoadjuvant chemotherapy (NACT) is given, if there is no response or if progression is noted, breast preservation cannot be considered as a safe possibility, if a patient was not eligible for BCS initially.

In the past, multifocal and multicentric breast cancer were not considered appropriate to be treated with BCS. Now this contraindication does not exist anymore, provided that clear margins can be achieved. BCS in multifocal disease is oncologically safe [43], but with slightly inferior outcome compared with BCS for unifocal disease and with a higher 10-year LR rate (0.6% vs. 6.1%,  $p < 0.001$ ) [36] but with little or no impact on survival [44].

Evidence, however, for BCS for multicentric cancers is still relatively weak. Usually multicentric invasive lobular disease is not ideal for an oncoplastic procedure due to the higher risk of margin involvement and to the poorer response to neoadjuvant chemotherapy.

Nevertheless, patients with recurrent cancer following BCS and whole breast or chest wall RT are at high risk for complications, due to the previous RT [32]. Moreover, patients with inflammatory breast cancer are not candidates for BCS.

Finally, patients with specific comorbidities, such as diabetes, heavy smoking, obesity, and concomitant physical and psychological illness are not ideal candidates for OBCS. Those patients have to be aware that they are in increased risk of complications.

## Contraindications for Immediate Reconstruction, Following Mastectomy

Contraindications for immediate reconstruction, following mastectomy are: inflammatory breast carcinoma, locally advanced disease, or when significant comorbidities exist, such as diabetes, heavy smoking, obesity, and concomitant physical and psychological illness.

## Limitations of OBCS

Limitations of OBCS depend on patient characteristics, tumor size, and increased operative time.

Patient considerations including breast size and comorbidities are important. Although level I procedures can be applied to



the vast majority of patients, level II techniques are not helpful for women with small breast size. For these patients with small breasts who require excision of greater than 20% of the breast volume, implant based or autologous flap reconstruction should be considered.

Comorbidities that increase the risk of tissue necrosis, such as history of smoking, diabetes, and obesity, must also be taken into serious consideration during surgical planning.

Tumor characteristics, such as size and location in the breast, have to be considered while forming the appropriate surgical plan. Tumors in unfavorable locations in the breast have few volume redistribution solutions.

Finally, additional operation time is required for advanced level II OBCS. This may be a disadvantage; however, this can be balanced by the rest of the factors.

---

## Preoperative Evaluation and Planning

The principles of OBCS within the multidisciplinary framework for preoperative assessment of patients can be summarized as follows:

- Primary diagnosis and evaluation of the extent of disease prior to surgical intervention
- Patient's psychosocial needs and expectations
- Evaluation of need for primary systemic treatment
- Precise surgical planning to include resection and reconstruction options
- En bloc tumor resection and intra-operative margin assessment if possible
- Marking of tumor bed margins for adjuvant radiation and follow-up
- Evaluation of need for sentinel lymph node biopsy (SLNB) or axillary node clearance (ANC)
- Evaluation of need for adjuvant treatment (type and timing) [2]

The success of OBS depends on meticulous preoperative planning and on the choice of the appropriate technique. There are several factors that play a crucial role in this planning.

### Tumor Size

The size of the tumor is analogical to the predicted defect if BCS is performed. The first and most important decision to make, when planning breast surgery, is whether a patient is eligible for BCS or needs a mastectomy. This is determined by the tumor size in relation to the breast size [45].

Some tumor parameters are associated with a higher risk for involved surgical margins, and a larger resection volume is likely to be necessary, in cases of large tumors, palpable tumors, or presence of DCIS.

For that reason, accurate preoperative breast imaging is important and breast MRI may be helpful to evaluate tumor size, to identify possible satellite lesions, to exclude multicentricity and multifocality, and to plan the access to the tumor. On the other hand, it is well known that breast MRI may lead to unnecessary investigations for incidentally detected lesions [46].

*Neoadjuvant chemotherapy (NACT)* has an increasingly important role in the treatment of breast cancer and has several advantages over traditional adjuvant chemotherapy. NACT may help decrease tumor size and is being used for conversion of some cases to BCS, where a mastectomy was initially necessary. Interestingly, however, BCS rates have not significantly increased, despite the increase in the use of NACT. Surgical overtreatment of breast cancer still happens, despite the fact that neoadjuvant and adjuvant therapies have remarkably improved outcomes and responses. Data are making more clear the role of BCS in patients who respond to NACT [47]. Despite higher complete pathologic response (pCR) rates due to more efficient drugs leading to better outcomes, there is still a high rate of mastectomy, in fact even higher than decades past when therapies were less robust. This apparent paradox might be explained by both surgeon and patient variables, such as the difficulty to determine radiologically the extent of residual disease post-NACT. Moreover, surgeons haven't yet overcome their perception for risk of recurrence. In several cases, surgical plan is wrongly based on prechemo imaging, which eliminates some of the advantages of NACT. What is more, it cannot be ignored that a significant number of patients opts for mastectomy, even though they might be eligible for BCS and regardless the fact that there is no survival benefit from mastectomy after NACT.

Except from down-staging breast disease, NACT also has the advantage of early administration of systemic treatment, and it also allows tailoring of further treatment using information about response to NACT.

It is evident that there is no consensus on the surgical management of either the breast or axilla in patients following NACT. Thus, the importance of multidisciplinary approach, communication, and cooperation between the medical and surgical teams is crucial in the NACT setting [47].

### Tumor Location

The location of the tumor in the breast determines the technique used for OBCS. This will be analyzed in further details in a following chapter.

### Operative Access

Access to the tumor and the axilla is something that has to be accurately planned preoperatively. Direct access to the tumor is preferable, as it makes resection more straightforward. The possibility of performing axillary surgery from the same incision is ideal, as it reduces the number of scars and pain. Finally, it is advisable, when planning an incision for BCS, to keep in mind the possible need of a mastectomy, in case of involved margins. For that reason, before performing the initial incision, its location should be carefully planned, keeping in mind that a re-operation might eventually be necessary.

### Re-excision

In the case of involved margins, re-excision is necessary. This can be either excision of the involved margins or a mastectomy, depending on the residual breast size [48].

If a re-excision of margins is decided, this might be more technically demanding, after level II OBCS, and is better if it is

performed by the surgeon who did the initial procedure, as after volume displacement tumor bed may be in a different position than expected.

## Radiotherapy

BCS followed by radiotherapy is associated with increased morbidity due to radiation and inferior long-term cosmesis. RT following OBCS is not straightforward, because of the parenchymal rearrangement that is routinely involved in oncoplastic techniques. The targeted tissue can be relocated, thus posing a challenge to localize the tumor bed for breast radiotherapy boost [28, 32].

Following OBCS marking of the pectoral muscle as well as the superior, inferior, medial, and lateral tissue around the tumor cavity with clips is necessary, before it is shifted to the final location. These clips allow more accurate radiotherapy planning.

Immediate reconstruction after mastectomy, when postoperative radiation is considered, is due to a higher risk for complications and inferior cosmetic results [49]. However, evidence support that this is feasible and safe.

## Shifting of the Original Tumor Bed After OBCS

OBCS may lead to local recurrences in areas within the breast that are different from the original tumor, because of volume displacement. Knowledge of the oncoplastic surgical procedure performed, together with the original and the new location of the tumor site, is important.

## Frozen Section

Intraoperative evaluation of the resection margins with frozen section is preferable in patients with invasive breast cancer. This allows immediate re-excision in case of close or involved margins. Frozen sections are not helpful in patients with DCIS, since information provided about margin status is not reliable. In patients with no palpable tumors, assessment of its excision is crucial, whether it is by intraoperative specimen X-rays or other techniques.

## Specimen Marking

As in BCS, specimen orientation is crucial and inadequate marking consists malpractice. OBCS specimens are more likely to be complex, including large, multifocal, or multicentric tumors, a known area of impalpable DCIS, cases post neoadjuvant chemotherapy, where only a marker clip may indicate the original primary location. The pathologist must be made aware of these. Any intraoperative cavity shaves must be similarly marked [32].

Accurate marking ensures that only the involved margin needs to be re-excised and not re-excision of the whole cavity. Despite the importance of specimen marking and orientation, there is no universally accepted specimen marking system. The most common protocol seems to be the method with different length or number of sutures and clips on three of the six margins [50, 51].

It is interesting that the presence of the skin or muscle on the specimen does not contribute to better orientation [52].

## Cavity Marking

Knowing the exact position of the tumor bed has always been important for the radiation oncologists for the planning of boost radiotherapy, although there are no data to support that accurate tumor bed delineation leads to less LR. There are data, however, that this may improve cosmesis [53].

The most widely accepted and efficient cavity marking method is the placement of metallic surgical clips to the tumor bed, for each margin of the cavity [33] straight after resection and before volume displacement [54].

## The Contralateral Breast

Patients can undergo bilateral single-staged surgery to achieve breast symmetry in one operation. This requires more accurate preoperative planning with the contralateral breast made slightly smaller and the nipple placed higher than that on the breast cancer site. A delayed symmetrization procedure (6–12 months after primary surgery) has the advantage that there is no possibility of any further re-excisions and the radiated breast has reached its final position.

## Preoperative Consultation

The approach to OBCS includes careful patient selection. It is important to make the patient aware that although OBCS procedures may save the need for mastectomy and can provide greater satisfaction with a better cosmetic outcome, outcomes do vary. Candidates for OBCS should be informed that they will end up possibly with longer and multiple scars. The position of incisions should be described in advance. The patient should also be aware of the possible asymmetry that will follow OBCS and that a contralateral symmetrization could be performed either simultaneously or preferably as a second-stage procedure, 6–9 months, following radiotherapy. Finally, they should be aware that mastectomy might eventually not be avoided, if clear margins cannot be obtained after multiple re-excisions.

## Marking and Positioning of the Patient

All oncoplastic procedures begin with preoperative marking of the patient standing. All appropriate arrangements should have been made, before the skin incision, so that patient can be moved from the supine to the upright position during the operation. Both arms need be extended, especially if any axillary surgery is planned.

---

## Surgical Technique

### Choice of Oncoplastic Technique

Reshaping of the breast is required after any tumor excision in order to recreate a normal breast shape in one operative procedure. In most cases, this can be achieved with a simple unilateral approach following lumpectomy, with small parenchymal rotations, mobilizing glandular flaps to close the defect. More complex breast reduction techniques, repositioning

the nipple-areola complex (NAC) and local skin rotation flaps, might be necessary in other instances. In the second case, bilateral approach incorporating a contralateral symmetrization is unavoidable, in order to perform a wide excision with no asymmetry and deformity [55].

There are two categories of techniques to reconstruct the defect, following excision of parenchyma: volume displacement and volume replacement techniques.

1. *Volume displacement techniques* : Local breast parenchymal dermoglandular flaps are transpositioned to fill the defect of the resection site. These can be further subdivided in two categories of techniques, using either simple advancement (level I OBCS techniques) or more complex pedicles (level II OBCS techniques), which can also be termed therapeutic mammoplasty techniques [56–58].
2. *Volume replacement techniques* : Importing volume from elsewhere to replace the amount of tissue resected. Distant autologous flaps, such as muscle or dermofascial flaps, or heterologous material, such as silicone prostheses (fixed volume implants or expanders) or fat grafting (Lipomodelling), are used to substitute for tissue loss [32].

Classification of volume displacement OBCS techniques is based upon the level of surgical difficulty.

Level I techniques should be able to be performed by all breast surgeons. A level I approach includes skin and glandular undermining, including the NAC and NAC mobilization.

Level II techniques encompass more complex procedures that involve skin excision and glandular mobilization to allow major volume resection. Those techniques are inspired by breast reduction mammoplasty and require oncoplastic training.

If less than 20% of the breast volume is excised, then a level II approach is not usually necessary. In that case, a level I procedure is usually adequate. When 20–50% of breast volume is to be excised or the cancer is in an unfavorable location, then a level II procedure is ideal. Large-volume excisions usually require concurrent skin excision.

As a general rule, it is much easier to prevent than to correct a deformity that has developed. A major advantage of OBCS is eliminating secondary reconstruction by preventing major breast deformities [59]. Especially the results of postoperative repair of BCS defects in irradiated tissue are poor, regardless of the surgical procedure [60, 61].

Volume displacement techniques require less extensive surgery, avoid donor-site problems, and have quicker recovery. On the other hand, volume replacement techniques can reconstruct the breast, achieving symmetry and excellent cosmesis, usually without the need for contralateral surgery.

The choice of technique depends on a number of factors, such as the extent of resection, position of the tumor, timing of surgery, experience of the surgeon, patient's comorbidities, general condition, and last but not least expectations of the patient. The last one must be taken into serious consideration. Patient's expectations and not surgeon's will is the main factor that should guide the decision for the most appropriate technique.

OBCS can be also divided into four categories: Conventional tumorectomy, oncoplastic mastopexy, oncoplastic tumorectomy, and oncoplastic reduction mammoplasty. An indication algorithm based on the size and shape of the breast as well as the size and location of the tumor suggests a selection of suitable tailored flaps and pedicles based on tumor location and vascular supply of the breast. This helpful algorithm tailors every operation to the individual patient, in a standardized manner [62] (Fig. 1.2).

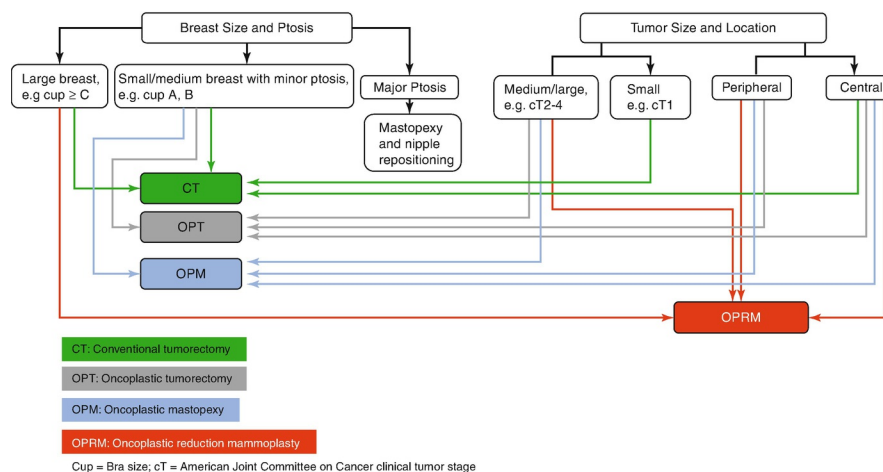


Fig. 1.2 Indication algorithm for conventional BCS and OBCS

## Ultrasound-Guided BCS

Ultrasound (USS)-guided BCS has shown advantages for the localization of nonpalpable tumors. A randomized control trial, COBALT, showed significant reduction in margin involvement (3.1% vs. 13%) and significantly reduced specimen volumes (38 cc vs. 53 cc) for the USS-guided cohort, compared to the palpation-guided cohort. No loco-regional recurrence was noted within 41 months, and in both cohorts the overall survival rate was 94–97%, with no difference between the two groups.

Better overall cosmetic outcomes were noticed for the USS-guided cohort (poor outcomes 11% vs. 21%), with poor outcomes being almost twice more often in the palpation group. Significant difference was noted in patient satisfaction in favor of the USS-guided cohort at 3 years postoperatively. This trial also showed that resection of more than 40 cc of breast volume had a 2.65 odds of worse cosmetic outcomes.

The outcomes of this trial were that USS-guided BCS could help reduce excision volume and improve cosmetic outcome and that complex (level II) OBCS should be reserved where higher excision volume/breast volume ration is expected as an option to avoid mastectomy [63].

## Timing of Procedures

Immediate reconstruction at the time of mastectomy is associated with clear surgical [64], financial [65, 66], and psychological [67] benefits, and similar benefits are seen in patients undergoing immediate breast-sparing reconstruction after partial mastectomy. Thus, it can be easily explained why OBCS is becoming increasingly popular.

For the above reasons, reconstruction of the partial or total mastectomy defect should ideally be performed immediately after the tumor resection, in order to prevent deformity rather than to correct it later. Immediate reconstruction is associated with fewer technical problems and complications, than delayed. On the other hand, reconstruction may be compromised by previous or future radiotherapy.

### Deformities Following Breast-Conserving Therapy

Until recently, little attention has been paid to the cosmetic outcome of BCS, as most patients are relieved just not to lose their breast. What is more, many surgeons are unfamiliar with OBCS techniques, recommending delayed reconstruction, following recovery from radiotherapy. Although this is possible, reconstruction of the breast after surgery and radiotherapy is technically challenging, with cosmetic results that are often inferior.

Surgical approach of patients that already had BCS is challenging. Clough et al. [68, 69] published a simple classification, which divides the patients to three groups, as a guide for choosing the optimal reconstructive technique and as a predictor of the final cosmetic result after surgery [21, 70].

- Type I deformities: Patients following BCS with a good cosmetic outcome, but with asymmetry between the two breasts.
- Type II deformities: Patients have a deformity of the treated breast. This deformity can be corrected with OBCS, with the irradiated breast tissue being spared.
- Type III deformities: Patients have a major distortion of the treated breast, or diffuse painful fibrosis, so severe, that only a mastectomy and reconstruction with either implants or autologous flaps can be considered [68].

### Oncoplastic Considerations

Oncoplastic breast surgeons should always choose the simplest procedure that will maintain or improve the aesthetics. Three factors are significant for the identification of patients who would benefit from OBCS. When considered together, they provide a sound basis for determining when and what type of OBCS to perform. These are:

- Excision volume
- Tumor location [71]
- Glandular density
- Volume

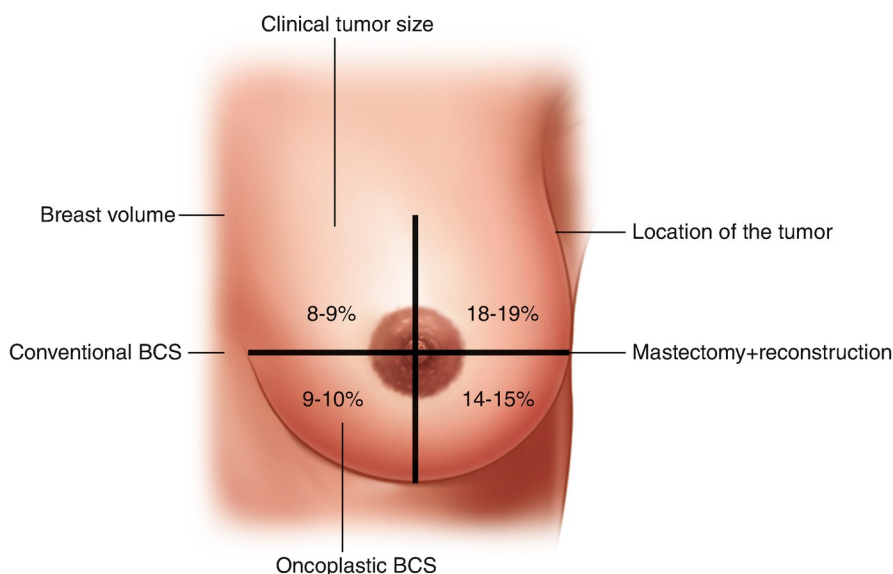
The first and most important determining element is volume that will be excised. This is the most predictive factor for cosmetic surgical outcome, thus deformity. Once 10–20% of the breast volume is excised, there is a clear risk of deformity [72].

Excision volume compared to the total breast volume has to be estimated preoperatively, since tumor size is known from preoperative imaging. The average specimen from BCS should weigh between 20 g and 40 g, and as a general rule 80 g of breast tissue is the maximum weight that can be removed from a medium-sized breast without resulting in deformity. Of course this largely depends on the size of the breast, as excision of even 20 g of breast tissue might cause an unacceptable deformity to a very small breast.

OBCS allows for significantly greater excision volumes while preserving the natural breast shape. Reshaping of the breast is based upon rearrangement of the breast parenchyma to correct volume loss. This can be achieved through either the displacement of breast tissue flaps into excision defects or volume replacement [71].

A publication from D. Pukancsik et al. gives a guidance regarding the maximum tolerable volume loss, per breast quadrant [73] (Fig. 1.3).

- Tumor location



**Fig. 1.3** Maximum tolerable volume loss per breast quadrant

High-risk zones in the breast are centrally located tumors and tumors in the lower pole and the upper inner quadrant.

Excision of masses from these areas is more likely to be followed by deformity after BCS.

On the other hand, tumors located in the upper outer quadrant of the breast are more suitable for larger volume excisions, with the use of OBCS.

- Glandular density

Breast density estimates the amount of fat in the breast and determines the possibility to safely perform extensive breast undermining and reshaping. Glandular density can be evaluated both clinically and radiologically. Although clinical examination provides reliable information, mammographic evaluation is more accurate and certainly is a more reproducible approach. Breast density can be classified into four categories based on the Breast Imaging Reporting and Data System (BI-RADS).

- Fatty
- Scattered fibroglandular
- Heterogeneously dense
- Extremely dense breast tissue [74]

Denser breast tissue (BI-RADS 3/4) can be mobilized easily, without risk of fat necrosis, compared to a less dense breast with a more fatty component (BI-RADS 1/2). Thus, procedures that require extensive skin undermining are not ideal for a patient with a predominantly fatty breast. In these cases, some level II OBCS techniques, which require less skin undermining, compared to Level I techniques, can be considered as a safer alternative. As a general rule, level I OBCS includes undermining the breast from both the skin and pectoralis fascia, so they are less appropriate for less dense breasts with a more fatty component. These techniques are best performed on women with dense breasts, especially if significant parenchymal mobilization is used [32].

Thus, breast density is a predictor of long-term cosmetic outcomes. Volumetric breast density (VBD) and percentage of breast volume excised (PBVE) can be calculated with image analysis software. Breasts with a VBD that is more than 15% (more fatty breasts) and PBVE that is less than 10% are considered not only to predict better cosmetic outcome after BCS alone, but also to be an indication for immediate breast reconstruction. PBVE is more responsible for early-stage cosmetic outcome, while VBD is associated with later-stage cosmetic outcomes. Low breast density was associated with loss of adipose tissue volume, thus increased fibro-glandular tissue volume and fibrosis after BCS [75].

## Volume Replacement Techniques

Several different approaches to volume replacement have been developed. Volume replacement should always be considered when adequate local tumor excision is expected to lead to an unacceptable degree of local deformity. Resection of more than 20% of breast volume, particularly from central, medial, or inferior locations, increases the possibility of a significant local deformity [21]. In these patients, volume replacement can extend the role of BCS and avoid mastectomy when resecting up to 70% of the breast. It is particularly suitable for patients who wish to avoid volume loss and contralateral symmetrization surgery. It is also suitable for patients who wish a delayed reconstruction and is the method of choice for correcting severe postradiotherapy deformity. In the possibility when a mastectomy will be necessary, volume replacement is also the technique of choice. Patients must be consented for the possibility of complications that may result in prolonged convalescence.

Immediate or delayed lipofilling is a relatively new volume replacement technique that improves cosmetic outcomes. Especially following a wide local excision in patients with small breasts, where excision of even a small cancer is predicted to produce a poor cosmetic outcome.

## Volume Displacement Techniques

### Level I OBCS

What made level I OBCS techniques so popular is the ability of the majority of surgeons to adopt them into their surgical practice.

In level I OBCS, skin incision is followed by undermining of the skin and/or NAC. OBCS is not minimally invasive surgery. The concepts of oncoplastic surgery are not based on minimizing incision length. Short incision lengths limit mobilization of the gland, which is a key component in achieving a natural breast shape and do not allow creation of adequate glandular flaps to fill excision defects.

Incisions that follow Kraissl's lines minimize scarring [76]. Then excision of cancer follows (from subcutaneous fat, usually down to pectoralis fascia), surrounded by healthy breast tissue. A specimen X-ray to demonstrate complete radiological excision is always necessary, and at this stage further cavity shaves are resected, if necessary. The next step is re-approximation of breast parenchyma to close the glandular defect. In BCS, breast tissue is either re-approximated or left open allowing for seroma formation. However, seroma formation does not always result in predictable long-term cosmetic results, and the excision cavity contracts due to fibrosis, creating a noticeable defect. For this reason, redistribution of the remaining breast volume is advisable. Finally, if NAC repositioning is required (in cases where NAC displaces toward the site of excision and is no longer positioned in the center of the breast mound), a crescent de-epithelialization surrounding the areola is performed. Avoiding NAC displacement is a key element for both level I and II OBCS. The level of NAC sensitivity is reduced by extensive mobilization [77]. Caution must always be taken, not to compromise NAC's vascular supply. This, however, is not compromised by careful de-epithelialization [78].

### Level II OBCS

Level II techniques are generally preferred when volume excisions between 20% and 50% are required. They allow large volume resection without cosmetic deformity and can be based on modifications of the superior or inferior pedicle and round-block therapeutic mammoplasty techniques. There is a wide range of level II OBCS techniques that can be adapted and modified to deal with tumors in any quadrant or to avoid a preexisting scar [32].

For many of these techniques, the nipple is repositioned with the use of a pedicle, which may arise inferiorly or superiorly usually, or even a combination of several pedicles. Vascular supply of several pedicles has been described by O'Dey et al. [78].

## Atlas Principles

The concept of the oncoplastic atlas is based primarily on tumor location. OBCS has evolved to allow resection of breast lesions located almost anywhere in the breast [79].

Level II OBCS will generally result in a smaller breast that is placed higher on the chest wall, compared to the contralateral breast. Either immediate or delayed symmetrization can be performed, depending on patient's will. In a series of 175 women having OBCS, a contralateral breast reduction was performed in 25% of patients (19% immediate and 6% delayed). A higher rate of contralateral surgery was performed in patients who had an inverted-T mammoplasty (50% vs. 14% with other techniques;  $P < 0.001$ ) [80].

There are multiple "atlases" of techniques for tumors located in different breast quadrants [35], and surgeons should be familiar with a range of methods and also have the efficiency and ability to modify them when necessary.

There is a profound need to developing a universally accepted OBCS classification and quadrant-by-quadrant atlas, which will improve communication between oncoplastic surgeons and patients.

The diagrams below are representative examples for the more appropriate OBCS technique according to tumor location. It is noticeable that an extremely heterogeneous group of therapeutic mammoplasties is available, with different complication rates and long-term outcomes [81, 82] (Figs. 1.4, 1.5, and 1.6).

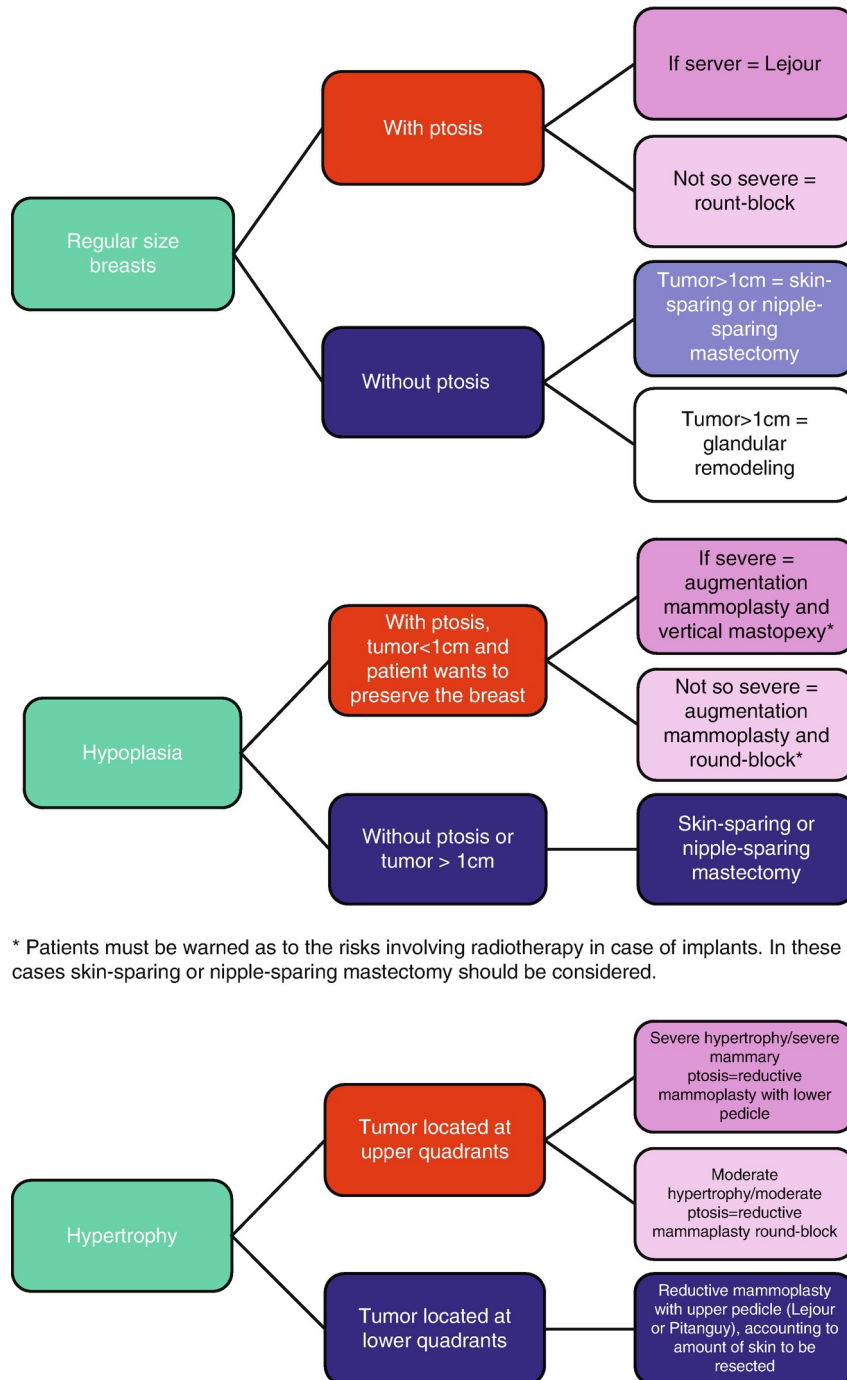


Fig. 1.4 OBCS technique according to tumor location [1]

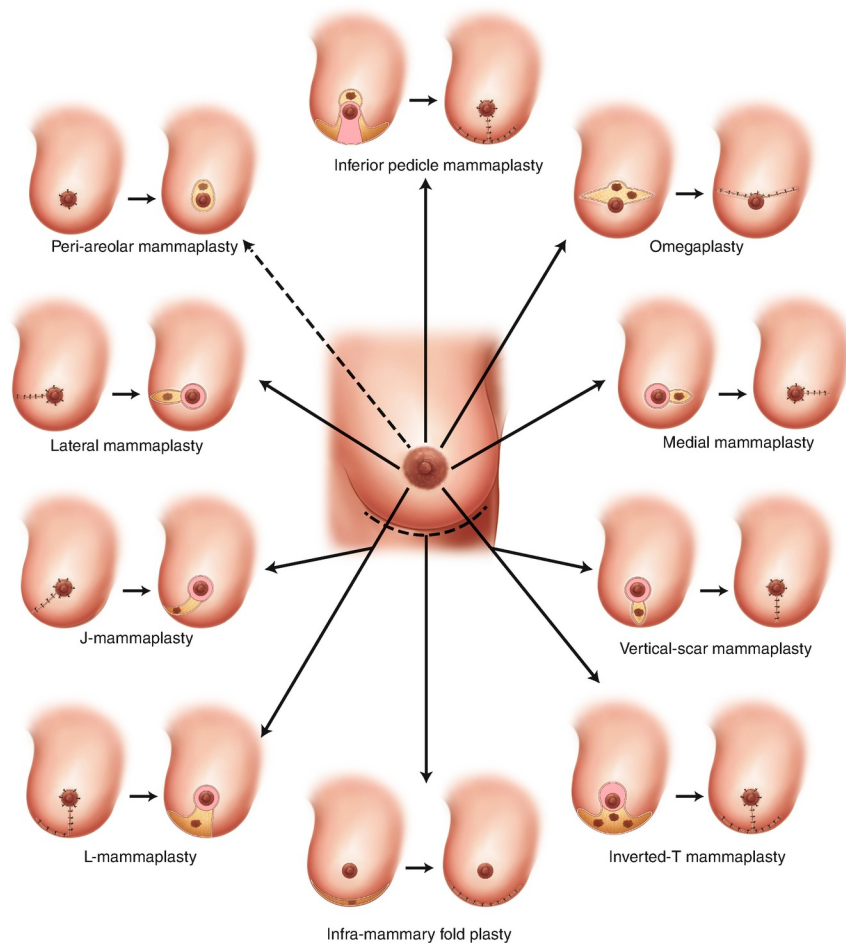


Fig. 1.5 OBCS technique according to tumor location [2]

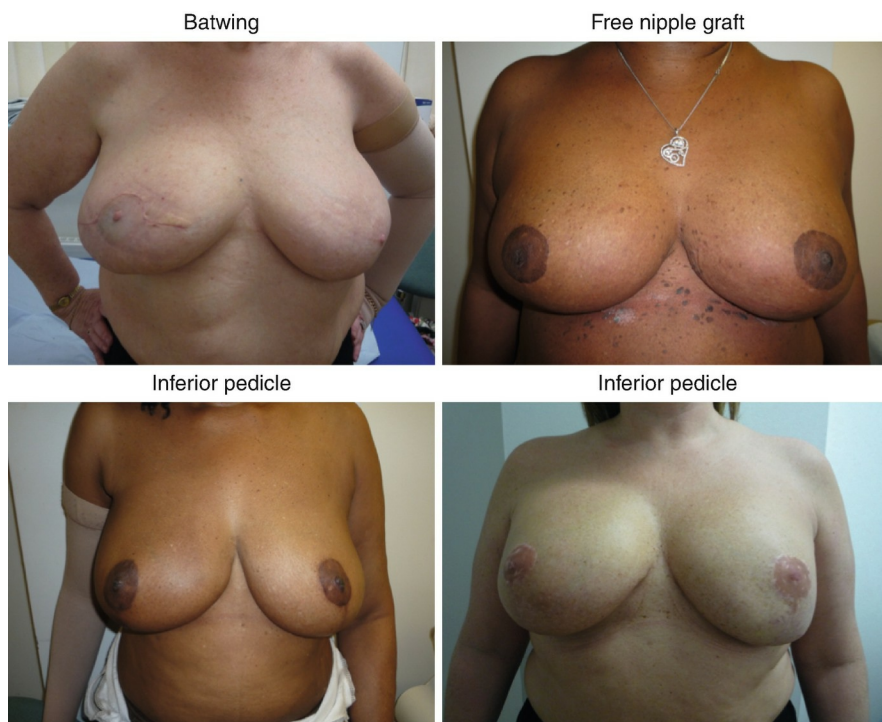

Fig. 1.6 Cosmetic outcomes of different therapeutic mammoplasty techniques [1]

### Surgical Complications and Solutions

We know that mammoplasty techniques for cosmetic breast reduction have acceptable complication rates. Early complications include scarring, asymmetry, seroma, hematoma, bleeding, wound infection, skin or nipple necrosis, and delayed healing. Late complications may involve fat necrosis, loss of nipple sensitivity, and NAC necrosis [83]. Extensive data are not available on complication rates specifically for OBCS, however.

Volume displacement techniques may be complicated by necrosis of the dermoglandular flaps, and routinely contralateral surgery is required to restore symmetry. On the other hand, volume replacement techniques require additional theater time and may be complicated by donor-site morbidity, skin flap or nipple necrosis, flap loss, implant loss, capsular contracture, and

longer convalescence. Glandular necrosis is the most challenging complication. Patient selection and careful surgical technique will avoid this. Areas of fat necrosis can become infected and cause wound dehiscence resulting in postoperative treatment delay. If fat necrosis occurs, multiple sessions of lipomodelling can result in good long-term results.

Breast reconstruction may be compromised by previous radiotherapy, leading to reduced tissue viability and an increased risk of fat necrosis, higher infection rates, delayed wound healing, and failure of reconstruction. Immediate implant-based reconstruction, following mastectomy, in the cases when radiotherapy to the chest wall is predicted to follow, is associated with increased morbidity, however, when performed by a skilled and fully trained oncoplastic breast surgeon, and if the patient lacks significant comorbidities, such as diabetes and obesity and provided that patient is not a smoker, it can be considered as a safe option.

---

## Results (Literature and Data)

The increasing number of OBSCS publications in the medical literature is a proof of the advantages and gained popularity of OBSCS.

### Advantages of OBSCS

The first advantage of OBSCS is the possibility of resection of wider free margins, since there is a possibility of resection of larger breast volumes (level III evidence) and of better cosmetic results (level IV evidence). Thus, fewer patients may need reoperations for any reason (level IV evidence) [84–86].

Moreover, OBSCS extends the indications for BCS, and patients with larger tumors may avoid mastectomy (level IV evidence) [87].

There are also some relative advantages of OBSCS that cannot be considered as indications, such as the fact that contralateral procedures done for symmetrization may detect previously unknown cancer [20] and that contralateral reduction mammoplasty may reduce the risk of breast cancer, as breast volume is excised [88].

### Disadvantages of OBSCS

Longer duration of surgery is a disadvantage of OBSCS and especially of level II OBSCS techniques. Another disadvantage is more visible and larger scars; however, the position of the scars may be an advantage, if they are periareolar or in the inframammary fold. What is more, there is a higher complication rate, because of more complex procedures or contralateral surgery, but it has been proven that there is no delay of adjuvant treatment [87].

More than one procedure might be necessary, if contralateral symmetrization is not done in one stage and possibility complications might occur in the breast that was not affected with cancer, if contralateral symmetrization is decided. Surgical training in oncoplastic and reconstructive breast surgery is necessary, and this limits the availability of OBSCS [87].

Finally, advances in OBSCS have been restricted by the diversity of techniques used, the lack of uniformity in classifying oncoplastic techniques, and the limited guidelines of the optimum OBSCS procedures in the surgical literature. This causes confusion and difficulty in technique selection.

### Oncological Safety of OBSCS Compared to Standard BCS

Concerns have been raised about whether OBSCS procedures are oncologically safe. There are no randomized trials to compare the outcomes of standard BCS or mastectomy with OBSCS [30, 32].

On the other hand, there is growing evidence that OBSCS techniques offer patients safe and effective surgical treatment.

There have been numerous large cohort studies, which show that OBSCS has acceptable LR rates [89–93].

Acceptable rates of LR are seen even in cases with large primary tumors [90]. This is also confirmed by a recent systematic review [91].

Another large comparison study of consecutive series of 454 OBSCS cases including volume displacement and replacement techniques, with a median follow-up of 7.2 years, didn't show any statistically significant difference in overall survival (OS) or disease-free survival (DFS). It demonstrated a slight increase in LR rates in the OBSCS group (3.2 vs. 1.8% in 5 years). Re-excision rate was 15.4% for the OBSCS cohort and 28.6% for the BCS cohort [94].

Similarly, A. Chakravorty et al. found a re-excision rate of 2.7% and an LR rate of 2.7% for OBSCS versus 13.4% and 2.2% for BCS, respectively [92].

A prospective analysis of over 100 patients undergoing OBSCS demonstrated 5-year OS and DFS rates of 95.7% and 82.8%, respectively [89].

The cosmetic results at a median follow-up of 49 months in a recent series of 175 patients were favorable in 85% of patients. Delay in adjuvant treatment was related to slow wound healing in only four patients, but all patients were able to receive appropriate postoperative radiotherapy and chemotherapy during the study [80].

A more recent retrospective review of 298 patients treated with OPS demonstrated a 5-year recurrence-free rate of 93.7% and 94.6% OS. This large review confirms the equivalent outcomes of OBSCS and standard BCS [95]. Rietjens et al. have reported long-term results from the European Institute of Oncology indicating no local relapse in the pT1 cohort. The pT2 and pT3 combined group had a 5-year LR rate of 8% and a mortality rate of 15%. The overall LR rate was determined to be 3% [93].

Final cosmetic outcomes and complication rates are not altered in patients undergoing neoadjuvant chemotherapy.

A prospective randomized study [87] compared standard BCS to OBSCS. OBSCS allowed resection of significantly larger breast volumes, yielded wider free surgical margins, and a lower, however, nonsignificant, number of patients requiring re-excision of margins or conversion to mastectomy. These results were also seen by other authors [84, 86, 89].

Numerous studies regarding OBSCS showed that the results are safe from the oncological perspective [89–93], and it has been proven that OBSCS does not lead to delay in adjuvant treatment [96] (Table 1.2).

**Table 1.2** OBSCS does not lead to delay in adjuvant treatment

**Summary of evidence for delivery of adjuvant chemotherapy after OBSCS**



Year	First author	Country/institution	No. of patients	Tumor size	Adjuvant chemotherapy received No. of patients (% of patients)	Delay in adjuvant therapy	Delayed adjuvant therapy No. of patients (% of patients)
1998	Nos et al.	France/Institut Curie Paris	50	Tis - T4	5 (10%)	Yes	3 (6%)
2002	Losken et al.	USA/Emory University Hospital	20	Tis - n/d, benign	n/d	No	0
2003	Clough et al.	France/Institut Curie Paris	101	T1 - T4	0	Yes	4 (4%)
2003	Spear et al.	USA/Georgetown University Hospital	22	n/d	22 (100%)	No	0
2005	McCulley et al.	UK/Nottingham City Hospital	50	Tis - n/d	23 (46%)	No	0
2006	Munhoz et al.	Brazil/University of Sao Paulo	74	T1 - T2	22 (29.7%)	No	0
2006	Thornton et al.	USA/University of Kentucky	6	T1 - T2	0	No	0
2007	Kronowitz et al.	USA/M.D. Anderson Cancer Ctr.	41	Tis - T2	18 (44%)	No.	0
2007	Losken et al.	USA/Emory University Hospital	63	Tis - n/d, benign		No	0
2007	Rietjens et al.	Italy/European Institute of Oncology	148	T1 - T3	89 (60%)	No	0
2010	Meretoja et al.	Finland, Helsinki Univ. Ctr. Hosp.	90	Tis - T3	60 (67%)	Yes	2 (2%)
2010	Fitoussi et al.	France/Institut Curie Paris	540	T1 - T3	n/d	Yes	10 (1.9%)
2010	Song et al.	USA/Emory University Hospital	28	Tis	n/a	No	0
2012	Romics Jr. et al.	UK/Glasgow University Hospitals	31	T1 - T3	31 (100%)	No delay compared to adequate control arms	

*n/d* not disclosed, *n/a* not applicable

Do we consequently have enough evidence to make OBCS be the standard of care? It is evident that we lack of level 1 evidence comparing OBCS with traditional BCS. The fact that many different techniques are used makes a randomized trial difficult.

## Cosmetic Outcomes

Assessing cosmetic outcomes is complex. Initial assessments were subjective and mainly relying on the surgeons' and not on the patients' opinion [55, 89, 96].

However, it was soon realized that this should be less biased and also that patient's satisfaction cannot be ignored, since this is the final goal. Assessing cosmetic outcomes, nowadays, has become more objective and takes into major consideration patient's opinion and satisfaction regarding the look and feel of the cancer-affected and cancer-treated breast, together with the contralateral breast and its influence on the quality of life of the patient.

With the introduction of objective analysis tools, OBCS seems to improve symmetry [97]. Interestingly the patients judged their aesthetic outcome more positively than the software [98, 99].

Breast symmetry doesn't seem to be a major factor for a patient's quality of life and breast self-esteem. Patients consider the oncological outcome of the disease as of immense importance [100].

This can be explained by the so-called "response shift," which is an adaptation process, where patients with a severe disease accommodate their illness. This explains why women with mastectomy and immediate reconstruction for DCIS reported better physical functioning and less bodily pain, not only compared to women who had just undergone wide local excision, but also compared to healthy women as well [101].

Finally, it is important not to evaluate only the immediate results. Oncoplastic breast surgeons, together with their patients, have to be aware that the aesthetic outcome is likely to be altered in time, and while most women feel pleased with the aesthetic results at 6 months postoperatively [54], the impact of scarring, indentation, and radiotherapy may lead to suboptimal results at 5 or even 10 years of follow-up [102] (Fig. 1.7).