

Difficult Conditions in Laparoscopic Urologic Surgery

Second Edition

Ahmed Al-Kandari
Arvind P. Ganpule
Raed A. Azhar
Inderbir S. Gill
Editors

 Springer

Difficult Conditions in Laparoscopic Urologic Surgery

Ahmed Al-Kandari • Arvind P. Ganpule
Raed A. Azhar • Inderbir S. Gill
Editors

Difficult Conditions in Laparoscopic Urologic Surgery

Second Edition

 Springer

Editors

Ahmed Al-Kandari
Department of Surgery
Kuwait University
Kuwait
Kuwait

Arvind P. Ganpule
Department of Urology
Muljibhai Patel Urological Hospital
Nadiad, Gujarat
India

Raed A. Azhar
Urology Department, Faculty of Medicine
King Abdulaziz University
Jeddah
Saudi Arabia

Inderbir S. Gill
USC Institute of Urology
Keck School of Medicine
University of Southern California
Los Angeles, CA
USA

USC Institute of Urology
Keck School of Medicine
University of Southern California
Los Angeles, CA
USA

ISBN 978-3-319-52580-8

ISBN 978-3-319-52581-5 (eBook)

<https://doi.org/10.1007/978-3-319-52581-5>

Library of Congress Control Number: 2017964118

© Springer International Publishing AG 2011, 2018

This work is subject to copyright. All rights are reserved by the Publisher, whether the whole or part of the material is concerned, specifically the rights of translation, reprinting, reuse of illustrations, recitation, broadcasting, reproduction on microfilms or in any other physical way, and transmission or information storage and retrieval, electronic adaptation, computer software, or by similar or dissimilar methodology now known or hereafter developed.

The use of general descriptive names, registered names, trademarks, service marks, etc. in this publication does not imply, even in the absence of a specific statement, that such names are exempt from the relevant protective laws and regulations and therefore free for general use.

The publisher, the authors and the editors are safe to assume that the advice and information in this book are believed to be true and accurate at the date of publication. Neither the publisher nor the authors or the editors give a warranty, express or implied, with respect to the material contained herein or for any errors or omissions that may have been made. The publisher remains neutral with regard to jurisdictional claims in published maps and institutional affiliations.

Printed on acid-free paper

This Springer imprint is published by Springer Nature

The registered company is Springer International Publishing AG

The registered company address is: Gewerbestrasse 11, 6330 Cham, Switzerland

Contents

1 Introduction	1
Ahmed Al-Kandari and Inderbir S. Gill	
2 Difficulties in Laparoscopic Access	7
Hamdy M. Ibrahim, Hani S. Shaaban, Ahmed Al-Kandari, and Inderbir S. Gill	
3 Difficulties in Anesthesia for Urologic Laparoscopy	19
Amr M. Sayed	
4 Difficulties in Urologic Laparoscopic Instrumentation	35
Ahmed Al-Kandari and Inderbir S. Gill	
5 Cost-Reductive Measures in Laparoscopy: Tips and Tricks for Developing Countries	47
Ahmed M. Mansour, Khurshid A. Guru, and Ahmed A. Shokeir	
6 Difficulties in Laparoscopic Simple Nephrectomy	57
Ahmed M. Harraz, Ahmed R. El-Nahas, and Ahmed A. Shokeir	
7 Difficulties in Transperitoneal Laparoscopic Radical Nephrectomy	73
Rakesh V. Khanna and Robert J. Stein	
8 Difficulties in Retroperitoneal Laparoscopic Radical Nephrectomy	81
Ricardo Brandina, Andre Berger, Robert J. Stein, and Inderbir S. Gill	
9 Difficulties in Laparoscopic Live Donor Nephrectomy	93
Jihad H. Kaouk and Wesley M. White	
10 Difficulties in Laparoscopic Nephroureterectomy	105
Hamdy M. Ibrahim, Ahmed Al-Kandari, Robert J. Stein, and Inderbir S. Gill	
11 Difficulties in Laparoscopic Partial Nephrectomy	119
Ahmed Al-Kandari, Ricardo Brandina, Robert J. Stein, and Inderbir S. Gill	

12	Difficulties in Laparoscopic Adrenalectomy	139
	Mahesh R. Desai and Arvind P. Ganpule	
13	Difficulties in Laparoscopic Renal Cyst Removal and Giant Hydronephrosis Nephrectomy	151
	Hamdy M. Ibrahim, Ahmed Al-Kandari, Hani S. Shaaban, and Inderbir S. Gill	
14	Difficulties in Laparoscopic Simple Prostatectomy	163
	Rene J. Sotelo Noguera, Juan C. Astigueta Pérez, and David Canes	
15	Difficulties in Laparoscopic Radical Prostatectomy	183
	Rene J. Sotelo Noguera, Juan C. Astigueta Pérez, and Camilo Andrés Giedelman Cuevas	
16	Difficulties in Robotic Radical Prostatectomy	211
	Manoj B. Patel, Sanket Chauhan, Kenneth J. Palmer, and Vipul R. Patel	
17	Difficulties in Laparoscopic Surgery for Urinary Stones	231
	Nasser Simforoosh, Alireza Aminsharifi, and Akbar Nouralizadeh	
18	Difficulties in Robotic-Assisted Nerve-Sparing Radical Prostatectomy	245
	Gerald Y. Tan, Philip J. Dorsey Jr., and Ashutosh K. Tewari	
19	Robotic Transplants: Point of Technique	265
	Arvind P. Ganpule, Abhishek Singh, Ravindra Sabnis, Mahesh Desai, and Mihir Desai	
20	Robotic Pyeloplasty in Infants and Toddlers	277
	Arvind P. Ganpule	
21	Difficulties in Laparoscopic Urologic Surgery in Kidney Transplant Patients and Obese Patients	285
	Mahesh R. Desai and Arvind P. Ganpule	
22	Difficulties in Laparoscopic Retroperitoneal Lymph Node Dissection	297
	Ahmed E. Ghazi and Günter Janetschek	
23	Robotic Ureteral and Bladder Reconstruction	321
	Carlos Eduardo Schio Fay, Daniel Melecchi Freitas, and Andre Kives Berger	
24	Difficulties in Laparoscopic Radical Cystectomy	337
	Amr M. Abdel-Hakim, Ahmed S. El-Feel, and Mahmoud A. Abdel-Hakim	
25	Difficulties in Laparoscopic Pyeloplasty	347
	Arvind P. Ganpule, Shashikant Mishra, and Mahesh R. Desai	

26	Difficulties in Laparoscopic Surgery for Urinary Stones	357
	Nasser Simforoosh, Alireza Aminsharifi, and Akbar Nouralizadeh	
27	Difficulties in Laparoscopic and Robotic Living Donor Nephrectomy	373
	Wesley M. White and Jihad H. Kaouk	
28	Difficulties in Laparoscopic Ureteral and Bladder Reconstruction	385
	Rakesh V. Khanna, Ricardo Brandina, Andre Berger, Robert J. Stein, and Inderbir S. Gill	
29	Difficulties in Laparoscopic Ureterolysis and Retroperitoneal Lymph Node Dissection.	409
	Mohamed A. Atalla, Eboni J. Woodard, and Louis R. Kavoussi	
30	Difficulties in Laparoscopic Management of Vesicovaginal Fistula	421
	Shrenik Shah	
31	Difficulties in the Laparoscopic Treatment of Female Genital Prolapse	433
	Ahmed E. Ghazi and Günter Janetschek	
32	Difficulties in Pediatric Laparoscopic Urologic Surgery.	449
	Angus G. Alexander and Walid A. Farhat	
33	Difficulties in Single-Port Laparoscopic Procedures.	461
	Raj K. Goel and Jihad H. Kaouk	
34	Difficulties in Urologic Laparoscopy Complications.	473
	Rene J. Sotelo Noguera, Camilo Andrés Giedelman Cuevas, Golena Fernández Moncaleano, and David Canes	
35	Difficulties in Laparoscopic Training, Mentoring, and Medico-Legal Issues	501
	Ahmed Al-Kandari and Inderbir S. Gill	
	Index.	519

Contributors

Amr M. Abdel-Hakim, MBBCh, MSc (Urol), MD (Urol) Department of Urology, Cairo University, Cairo, Egypt

Mahmoud A. Abdel-Hakim, MD, Dr. Med. PhD, FEBU Department of Urology, Cairo University, Sahafeen, Cairo, Egypt

Angus G. Alexander, MBBCh FCS Cert.Paed.Surg.(UCT) Department of Pediatric Urology, The Hospital for Sick Children, Toronto, ON, Canada

Ahmed Al-Kandari, BM BCh, FRCS(C) Department of Surgery (Urology), Faculty of Medicine, Kuwait University, Jabriyah, Kuwait

Alireza Aminsharifi, MD Department of Urology, Shiraz University of Medical Sciences, Shiraz, Fars, Iran

Juan C. Astigueta Pérez, MD Department of Urology, Instituto Regional de Enfermedades Neoplasicas Norte, Trujillo, La Libertad, Peru

Mohamed A. Atalla, MD The Arthur Smith Institute for Urology, Hofstra University Medical School, North Shore LIJ Health System, New Hyde Park, New York, USA

Andre Berger, MD Department of Urology, University of Southern California, Los Angeles, CA, USA

Ricardo Brandina, MD Department of Urology, University of Southern California, Los Angeles, CA, USA

David Canes, MD Department of Urology, Lahey Clinic Hospital, Burlington, MA, USA

Sanket Chauhan, MD Department of Urologic Surgery, Global Robotics Institute, Florida Hospital-Celebration Health, Celebration, FL, USA

Mahesh R. Desai, MS, FRCS (Edin), FRCS (Eng) Department of Urology, Muljibhai Patel Urological Hospital, Nadlad, Gujarat, India

Philip J. Dorsey Jr., MD MPH Department of Urology, Tulane University School of Medicine New Orleans, LA, USA

Ahmed S. El-Feel, MD, Dr. Med. PhD, FEBU Department of Urology, Cairo University, Dokki, Cairo, Egypt

Ahmed R. El-Nahas, MD Department of Urology, Urology and Nephrology Center, Mansoura, Dakahlia, Egypt

Walid A. Farhat, MD, FRCS(C) Department of Surgery, Sickkids Hospital, University of Toronto, Toronto, ON, Canada

Golena Fernández Moncaleano, MD Department of Urology, Fundación Universitaria de Ciencias de la Salud—Hospital de San José (University Foundation of Health Science—Saint Joseph Hospital), Bogotá, Colombia

Arvind P. Ganpule, MS(Sur.) DNB(GU sur.) MNAMS Division of Laparoscopic Surgery, Department of Urology, Muljibhai Patel Urological Hospital, Nadlad, Gujarat, India

Ahmed E. Ghazi, MD, MSc, FEBU Department of Urology, University of Rochester Medical Center, University of Rochester, Rochester, New York, USA

Camilo Andrés Giedelman Cuevas, MD Department of Urology, Centro de Cirugía Robotica y de Invasión Mínima, Instituto Medico La Floresta, Caracas, Venezuela

Inderbir S. Gill, MD USC Institute of Urology, Keck School of Medicine, University of Southern California, Los Angeles, CA, USA

Raj K. Goel, MD Department of Urology, Schulich School of Medicine, University of Western Ontario, Windsor, ON, Canada

Khurshid A. Guru, MD Department of Urology, Roswell Park Cancer Institute, Buffalo, NY, USA

Ahmed M. Harraz, MD Department of Urology, Urology and Nephrology Center, Mansoura, Dakahlia, Egypt

Hamdy M. Ibrahim, MD Department of Urology, Fayoum University, Fayoum, Egypt

Günter Janetschek, MD Department of Urology, Medical University of Salzburg, Salzburg, Austria

Jihad H. Kaouk, MD Center for Laparoscopic and Robotic Surgery, Cleveland, OH, USA

Louis R. Kavoussi, MD The Arthur Smith Institute for Urology, Hofstra University Medical School, North Shore LIJ Health System, New Hyde Park, NY, USA

Rakesh V. Khanna, MD Glickman Urological and Kidney Institute, Cleveland Clinic, Cleveland, OH, USA

Ahmed M. Mansour, MD, MRCS Department of Urology, Roswell Park Cancer Institute, Buffalo, NY, USA

Shashikant Mishra, MD Department of Urology, Muljibhai Patel Urological Hospital, Nadlad, Gujarat, India

Akbar Nouralizadeh, MD Department of Urology, Shahid Labbafi nejad Hospital, Urology and Nephrology Research Center, Shahid Beheshti University of Medical Sciences, Tehran, Iran

Kenneth J. Palmer, MD Department of Urologic Surgery, Global Robotics Institute, Florida Hospital-Celebration Health, Celebration, FL, USA

Manoj B. Patel, MD Department of Urologic Surgery, Global Robotics Institute, Florida Hospital-Celebration Health, Celebration, FL, USA

Vipul R. Patel, MD Department of Urologic Surgery, Global Robotics Institute, Florida Hospital-Celebration Health, Celebration, FL, USA

Amr M. Sayed, MD Department of Anesthesia, Intensive Care Medicine and Pain Management, Ain Shams University, Cairo, Egypt

Hani S. Shaaban, MD, MSc Department of Urology, Ahmadi Hospital, Ahmadi, Kuwait

Shrenik Shah, MCh Department of Urology, Civil Hospital and B J Medical College, Ahmedabad, Gujarat, India

Ahmed A. Shokeir, MD, PhD, FEBU Department of Urology, Urology and Nephrology Center, Mansoura, Egypt

Nasser Simforoosh, MD Department of Urology, Shahid Labbafinejad Hospital, Urology and Nephrology Research Center, Shahid Beheshti University of Medical Sciences, Tehran, Iran

Rene J. Sotelo Noguera, MD Department of Urology, University of Southern California Keck School of Medicine, Los Angeles, USA

Robert J. Stein, MD Center for Laparoscopic and Robotic Surgery, Glickman Urological and Kidney Institute, Cleveland Clinic, Cleveland, OH, USA

Gerald Y. Tan, MB, ChB, MRCS, M Med, FAMS, FICS Department of Urology, Tan Tock Seng Hospital, Jalan Tan Tock Seng, Singapore

Ashutosh K. Tewari, MD, MCh Chairman of the Milton and Carroll Petrie Department of Urology at the Icahn School of Medicine at Mount Sinai, Department of Urology at the Icahn School of Medicine at Mount Sinai, New York, USA

Wesley M. White, MD Division of Urologic Surgery, The University of Tennessee Medical Center, Knoxville, TN, USA

Eboni J. Woodard, MD The Arthur Smith Institute for Urology, Hofstra University Medical School, North Shore LIJ Health System, New Hyde Park, NY, USA

Ahmed Al-Kandari and Inderbir S. Gill

Minimally invasive therapy is evolving as a newly accepted modality for different surgical specialties. This is due to improvements in equipment and techniques of different procedures. Urology has been at the forefront of developing these minimally invasive surgical procedures.

Laparoscopic urologic procedures are now the result of decades of improvements, starting with inspection, ablation, and reconstruction, and moving towards robotic-assisted and single-port techniques. The learning curve for each procedure is an important aspect of improvement and mastering.

It is essential that beginners in laparoscopic urologic procedures know all the steps and laparoscopic anatomy for common, straightforward cases. They should master these procedures before doing more difficult ones. In each laparoscopic urologic procedure, there are some difficult steps that the surgeon must be aware of and understand how to deal with in order to accomplish the procedure safely.

In this second book edition, the editors aim to collect the experience of worldwide experts in laparoscopic and robotic urologic procedures. The format of the chapters is easy-to-read, with an introduction and description of the difficulties, and then examples illustrated with pictures. The solutions that the authors have used to overcome difficulties are also discussed. Finally, a conclusion summarizes the chapter. The purpose of this book is to serve as a practical guide for residents, fellows, and urologists at the beginning of their experience in laparoscopy. It may also be useful to experienced laparoscopic urologists who wish to learn more about what their colleagues from different institutions and different countries are doing.

A. Al-Kandari, BM BCh, FRCS(C) (✉)
Department of Surgery (Urology), Faculty of Medicine, Kuwait University, Jabriyah, Kuwait
e-mail: drakandari@hotmail.com

I.S. Gill, MD
USC Institute of Urology, Keck School of Medicine, University of Southern California,
Los Angeles, CA, USA

It is the editors' hope that the illustrations, in addition to the website with samples of video materials, will be a great help in fully understanding the material included in this book.

In this introductory chapter, we provide comments to supplement the information provided in other chapters in order to enhance the book's insights.

Chapter 3: Difficulties in Anesthesia for Urologic Laparoscopy

- The urologist willing to start or advance in their laparoscopic procedure should develop a good relationship with the anesthetist. Communication with the anesthetist during lengthy laparoscopic surgery is important, especially during the initial learning curve.
- Careful preoperative general medical evaluation, especially for patients with pre-existing medical problems, is essential for a successful and safe post laparoscopic outcome.
- Careful patient positioning and padding of pressure areas are important to avoid postoperative position-related complications.

Chapter 4: Difficulties in Urologic Laparoscopic Instrumentation

- Detailed knowledge of all the necessary laparoscopic instruments should be completely mastered by the surgeon and the surgical team to prevent avoidable instrument problems.
- Access-related problems can be safely avoided with thorough surgical anatomical knowledge and specific preparation for each case.
- Particular care is required when obtaining laparoscopic access in obese, thin, and pediatric cases.
- Good laparoscopic access should allow for easy visualization and reach of the target organs with ergonomic instrument handling.

Chapter 7: Laparoscopic Radical Nephrectomy

- Preoperative preparation of vascular anatomy and a tumor in relation to adjacent structures is a helpful method to avoid difficulties.
- The use of all possible helpful equipment and respect for oncological principles is essential for safe surgery.

Chapter 11: Robotic Partial Nephrectomy

- Robotic partial nephrectomy has the advantage of being minimally invasive and has proven the test of time to be technically efficient and oncologically safe.
- Different techniques to reduce warm ischemia time has been done using robotic approach.

Chapter 9: Difficulties in Laparoscopic Live Donor Nephrectomy

- Preoperative planning with computed tomography (CT) angiography is essential for safe surgery.
- The editors prefer the transperitoneal access, which provides more operative room.

- Hem-o-lok[®] (Teleflex Medical, Research Triangle Park, NC) clipping for the artery is safe and the editors use the endovascular stapler for the vein after complete kidney mobilization.
Careful dissection of the ureter with the gonadal vessels is important to avoid ischemic damage to the ureter.

Chapter 19: Robotic Assisted Kidney Transplantation (RAKT)

- In this chapter a new technique will be described which is robotic assisted kidney transplantation.
- Robotic assisted kidney transplantation is being attempted by several doctors and in several ways. The high cost of the technology is limiting the widespread use of it

Chapter 12: Difficulties in Laparoscopic Adrenalectomy

- Both retroperitoneal and transperitoneal accesses are used; one must choose their preference according to experience and comfort level with the approach.
- In the transperitoneal approach, full mobilization of the spleen on the left side and the liver on the right side are important and helpful movements that will expose the adrenal efficiently.
- Thermal energy instruments are helpful tools for adrenal dissection and mobilization.

Chapter 14: Difficulties in Laparoscopic Simple Prostatectomy

- This technique is definitely less invasive than open prostatectomy.
- Intraperitoneal, extraperitoneal, and transvesical techniques can be used in this procedure.
- Traction on the middle lobe with traction suture is helpful in facilitating the enucleation.
- The use of thermal energy devices, such as ultrasonic devices, can be helpful in minimizing oozing when enucleating the adenoma.

Chapter 16: Difficulties in Robotic Radical Prostatectomy

- The transperitoneal approach is preferred because it provides a larger working space.
- The editors prefer the descending approach, in which seminal vesicles and vas are dissected first.
- Managing the dorsal vein complex can be done with suture as well as an endovascular stapler.
- Avoiding thermal sources in nerve sparing cases is essential for better potency outcomes.
- Currently more robotic-assisted radical prostatectomies are done in the USA, which suggests that they may replace standard laparoscopy.

Chapter 22: Difficulties in Laparoscopic Retroperitoneal Lymph Node Dissection

- This technique should be performed by experienced laparoscopic surgeons.
- This technique is far less invasive than open surgery, and the patient should be offered this option when an experienced surgeon is available.

Chapter 24: Robotic Assisted Radical Cystectomy and Ileal Neobladder

This procedure was found technically feasible but challenging, details of the technique and possible difficulties will be addressed.

Chapter 25: Difficulties in Laparoscopic Pyeloplasty

- The editors prefer transperitoneal access, which allows more operative room to suture, although the retroperitoneal route is quite acceptable if the surgeon feels comfortable with it.
- In thin individuals and on the left side, the transmesocolic approach is very helpful.
- Careful dissection of the ureteropelvic junction (UPJ) and handling of the important crossing vessels are essential.
- Traction suture on the pelvis can be a helpful trick for good exposure.
- Delicate handling of the UPJ is important while suturing to avoid ischemic injury due to tissue crushing.
- Pre- or intra-operative ureteral stenting is equally acceptable and depends on the surgeon's experience.

Chapter 20: Difficulties in Robotic Pyeloplasty

- The steps of robotic pyeloplasty are illustrated.
- The position of the patient as well as trocar sites are mentioned.
- The technique of dismembering the ureteropelvic junction are mentioned.
- The technique of suturing and well as stenting are illustrated.

Chapter 26: Difficulties in Laparoscopic Surgery for Urinary Stones

- Most stone interventions utilize shockwave lithotripsy, percutaneous nephrolithotomy or ureteroscopy, and to lesser extent laparoscopy, and, rarely, in some centers, open surgery.

Complete stone removal with careful dissection of the ureter or renal pelvis and accurate incision are important technical issues in laparoscopic stone surgery to minimize postoperative difficulties and morbidities.

Chapter 31: Laparoscopic and Robotic Surgery for Female Pelvic Organ Prolapse

This technique is used by urologists and gynecologists. The detailed steps will be revised and the technical difficulties will be described.

Chapter 28: Laparoscopic and Robotic Surgery for Ureteral Stricture

Ureteral reconstruction starting from pyeloplasty to Boari flap and ileal interposition can be done laparoscopically and further facilitated by robotic technique.

Chapter 32: Difficulties in Laparoscopic Pediatric Urologic Surgery

- It is important to know that not all laparoscopic surgeons will deal with pediatric cases. However, if one decides to take on pediatric cases, then knowledge of the detailed technical steps and instruments is crucial.
- Inserting trocars in children should be carefully assessed to avoid trocar-related injuries since children have small organ anatomy with shorter distances in comparison to adults.

Chapter 35: Difficulties in Laparoscopic Training, Mentoring, and Medico-Legal Issues

- If a surgeon is keen to learn laparoscopy and has the required skills, then it is not too late.
- Various worldwide courses of laparoscopy are very helpful in learning about laparoscopy, from beginner to advanced levels.
- Visiting experts or inviting them to your institution and assisting them while performing laparoscopic procedures can help one to learn important steps. These are just a few comments about some of the aspects of laparoscopic urologic procedures that the editors wanted to share with readers. It is our hope that, by adding them, readers will find the book more informative and helpful.

Hamdy M. Ibrahim, Hani S. Shaaban, Ahmed Al-Kandari,
and Inderbir S. Gill

Introduction

Laparoscopic surgery has developed rapidly over the last few years, and many surgical procedures formerly carried out through large abdominal incisions are now performed laparoscopically. Reduction of the trauma of access by avoidance of large wounds has been the driving force for such development [1]. However, the insertion of needles and trocars necessary for the pneumoperitoneum and the performance of the procedure are not without risk [2]. The technical modifications imposed by surgical laparoscopy are obvious (e.g., number and size of trocars, location of insertion sites, specimen retrieval), and therefore morbidity may be substantially modified. Complications such as retroperitoneal vascular injury, intestinal perforation, wound herniation, wound infection, abdominal wall hematoma, and trocar site metastasis have been reported [3].

Laparoscopy currently plays a key role in urological surgery. Its applications are expanding with experience and evolving data confirming equivalent long-term outcome. Although significant port-site complications are uncommon, their occurrence impacts significantly on perioperative morbidity and rate of recovery. The incidence of such complications is inversely related to surgeon experience. Ports now utilize bladeless tips to reduce the incidence of vascular and visceral injuries, and subsequently

H.M. Ibrahim, MD (✉)

Department of Urology, Fayoum University, Fayoum, Egypt

e-mail: hamdyibrahim4@yahoo.com

H.S. Shaaban, MD, MSc

Department of Urology, Ahmadi Hospital, Ahmadi, Kuwait

A. Al-Kandari, BM BCh, FRCS(C)

Department of Surgery (Urology), Faculty of Medicine, Kuwait University, Jabriyah, Kuwait

I.S. Gill, MD

USC Institute of Urology, Keck School of Medicine, University of Southern California, Los Angeles, CA, USA

port-site herniation. Metastases occurring at the port site are preventable by adhering to certain measures. Whether performing standard or robot-assisted laparoscopy, port-site creation and maintenance is critical in ensuring minimal invasiveness in laparoscopic urological surgery. Although patient factors can be optimized perioperatively and port design continues to improve, it is clear that adequate training is central in the prevention, early recognition, and treatment of complications related to laparoscopic access [4]. Despite numerous recent technical advances in minimally invasive surgical technique, the potential exists for serious morbidity during initial laparoscopic access. Laparoscopic access entry injuries are reported at rates of 0.05–0.3%. Such injuries likely occur more frequently than reported and carry a mortality rate as high as 13% [5, 6]. Studies have shown that no trocar design, including safety shields and direct-view trocars, can completely prevent serious injuries [6–8]. Safe access depends on adhering to well-recognized principles of trocar insertion, knowledge of abdominal anatomy, and recognition of the hazards imposed by previous surgery [9].

Anatomical Considerations

Abdominal wall anatomy should receive special attention prior to laparoscopy because many laparoscopic complications result from trocar placement.

Abdominal Scars

Previous surgery is associated with a greater than 20% risk of adhesions of bowel or omentum to the anterior abdominal wall. Of special concern are incisional scars immediately adjacent to the umbilicus because bowel adherent underneath the umbilicus may be at risk for injury, regardless of the technique used. In addition to location, the width and depth of the scar should be evaluated because a wide or retracted scar may be associated with an increased risk of intra-abdominal adhesion formation, although no data are available to support this observation. If the dome of the bladder is involved, there is increased risk of bladder injury at the time of supra-pubic trocar placement [10].

Abdominal Wall Thickness

Although abdominal thickness correlates with patient weight, short stature or truncal obesity may increase abdominal wall thickness out of proportion to patient weight. Routine evaluation of the abdominal wall prior to laparoscopy is important because the success of trocar insertion may depend on altering the technique based on abdominal wall thickness [11].

Umbilicus

The umbilicus should be examined for signs of umbilical hernia. Techniques for trocar insertion should be adjusted, and closure of the defect should be considered. In the absence of incarcerated bowel, the skin over the hernia can be carefully incised and the peritoneal cavity entered using an open technique.

Abdominal Wall Vessels

The anterior abdominal wall contains two sets of bilateral vessels: the superficial and the inferior (deep) epigastric vessels. These arteries originate from the femoral and external iliac arteries, respectively, and are accompanied by a large vein in most cases. Immediately above the symphysis pubis, they are both located an average of 5.5 cm from the midline and course either laterally or cephalad. In order to avoid injuring these vessels during lateral trocar placement, the superficial vessels should be visualized by transillumination and the inferior vessels should be laparoscopically visualized whenever possible [12].

Port Design

Port design has also improved significantly since the beginning of urological laparoscopy. Initially pyramidal cutting trocars were the mainstay. Trocars with shielded blades were then developed and are still the preferred port type in many centers. More recently, nonbladed trocars are increasingly being used as a growing number of studies suggest reduced complication rates. These ports spread muscle and fascia rather than incise it and theoretically allow spontaneous re-approximation after trocar removal. A randomized prospective multicenter trial comparing radially expanding trocars to standard cutting trocars, in gastrointestinal surgery, has shown significantly reduced wound complications in the radial expansion group [13, 14].

Two primary entry systems are available in laparoscopy: the first-generation conventional entry method where the push-through spike principle is applied, and the second-generation entry method where the Archimedes spin principle is employed.

Conventional entry, irrespective of make or model of instrument, requires two components, a central trocar with a sharp cutting, or pointed, distal end and an encasing cannula. Surgeons palm the access instrument with the dominant hand and apply considerable penetration force (PF), generated through the dominant upper arm muscles, axially at port site, to push the spike across different tissue layers towards the intended body cavity. Several versions, modifications, and models have attempted to render this entry system less hazardous while maintaining the spike and cannula design.

The second-generation entry method uses the spin principle, where the entry instrument comprises a threaded cannula only, which ends in a notched blunt tip. No central trocar is required as a laparoscope is mounted into the cannula during insertion and removal. No axial PF is applied; tissue layers part radially and the visually guided cannula pulls tissue up along its outside thread using Archimedes' principle [15].

Conventional primary port insertion requires application of considerable axial PF to the push through the trocar cannula access unit. The anterior abdominal wall dents towards the viscera; entry is blind and uncontrolled with the probability of overshoot. The compilation of these potentially dangerous performance shaping factors (PSFs) during primary port insertion renders access less forgiving and sets the stage for inadvertent injury.

Second-generation entry systems cushion human error through system redesign and avoid integration of identified PSF. Error recognition is likely when mishaps occur and error recovery is possible before the situation evolves and harms the patient. When specific PSFs of conventional entry are eliminated during primary entry, port placement becomes less hazardous. Interactive and real-time visual entry avoids application of axial force at port site, requires no sharp or pointed trocars, and allows for controlled port placement [16].

Port Insertion Techniques

Laparoscopic approaches to the urological organs and the prostate can be performed using the retroperitoneal or transperitoneal approach. Each approach has distinct advantages and disadvantages. Laparoscopic radical nephrectomy and adrenalectomy have been performed most commonly via the transperitoneal approach. In general, the retroperitoneal approach is used less frequently because the working space is smaller, landmarks are less easily identified, and the operative strategy requires a steeper learning curve. However, the retroperitoneal location of the kidney and adrenal allows a more direct approach without the need to mobilize or retract the viscera. In addition, it provides greater direct access to the vasculature and drainage systems of the urological organs [17].

The Transperitoneal Approach

There are three main options for initial port insertion: closed access using the Verres needle, open Hasson technique, or use of an optical port. The site of insertion depends on the procedure and whether the site is approached trans- or retroperitoneally. To avoid the epigastric vessels, the site is generally located lateral to the rectus abdominus or just below the tip of the 12th rib, respectively, in upper renal tract laparoscopy. In pelvic laparoscopy, the site is para- or infraumbilical, according to the type of approach.

Closed Access

Using the Veress Needle

This procedure involves blind insertion of the Veress needle to create a pneumoperitoneum. The needle design allows tactile feedback as it passes through various

layers of the abdominal wall. Intra-abdominal pressure is initially set at 15–20 mm Hg for primary port insertion, which is done via inserting a separate port-site system. In upper-tract laparoscopy with the patient in the flank position, the needle can be inserted in the iliac fossa or upper quadrant [18].

The insertion site should always be away from previous surgical scars to reduce the risk of visceral injury. The Veress needle is placed in the midclavicular line at the level of the umbilicus in patients without previous open abdominal surgery, while in those with previous open surgery the needle is placed in the ipsilateral abdominal quadrant farthest from the previous incision. After placing the Veress needle into the peritoneal cavity, insufflation to 15 mmHg pneumoperitoneum is established. Certain safety steps are used to confirm entry into the peritoneal cavity, including absence of gas or blood at aspiration of a syringe through the Veress needle, injection of 5 cc saline that cannot be aspirated, low initial intraperitoneal pressure, and no rapid increase in intraperitoneal pressure at the commencement of insufflation. If any of these steps are not satisfactory, the Veress needle is removed and reinserted. No more than three attempts are made with the Veress needle. If still unsuccessful, open trocar placement or a nonbladed visualizing trocar entry technique is used for direct vision into the peritoneal cavity. Radially expandable sheaths are the most commonly used trocars [19, 20].

Open Access

Using the Hasson Technique

The open procedure is carried out as follows: A 1.5-cm semicircular incision in the inferior border of the umbilicus is made and the subcutaneous tissue dissected. The fascia is then grasped with two Kocher clamps and lifted to separate these layers from the underlying viscera. The fascia and peritoneum are incised with scissors to gain access to the peritoneal cavity. The fascial defect is secured by passing two single stitches on both sides of the incision, aiming to avoid any gas leak. Afterward, the Hasson's blunt tip trocar is inserted and attached to both sutures. Subsequently, the insufflator is connected to the trocar and pneumoperitoneum is established [2].

Using the Bailez Technique

A variation of the Hasson technique for laparoscopic access has been developed in children. Access to the peritoneal cavity is obtained using the following approach: a semicircumferential incision is made in the inferior part of the umbilicus and the umbilical skin lifted and dissection carried out underneath to expose the area of the umbilical scar where the peritoneum and the skin meet. On separating the skin from the peritoneum, the abdominal cavity is opened without an incision. The opening is sometimes enlarged with a hemostat to allow the introduction of a blunt nonarmed 5- or 10-mm trocar into the peritoneal cavity without forceful manipulation (Fig. 2.1). The rest of the procedure is accomplished as usual. At the end of the

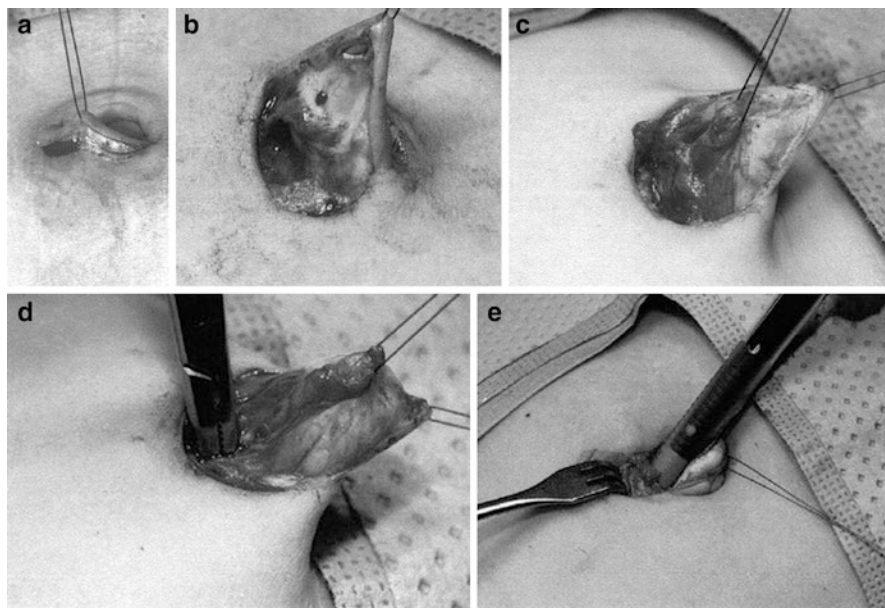


Fig. 2.1 (a) A semicircumferential incision is made in the inferior part of the umbilicus. (b) Umbilical skin lifted and dissection carried out underneath to expose the area of the umbilical scar. (c) Figure illustrating where the peritoneum and the skin meet. (d) The opening is sometimes enlarged with a hemostat. (e) The introduction of a blunt nonarmed 5 mm trocar

procedure, the opening is closed with a polydioxanone figure-of-8 stitch and the skin reapproximated with 5-0 polyglactin subcuticular sutures [21].

The open technique using a peritoneal cut-down and trocar insertion under direct visualization is associated with fewer problems than blind insertion of the Veress needle and primary trocar. Nevertheless, the Hasson technique, believed to be safer than blind insertion of the Veress needle, also carries the risk of potential complications. Hasson's experience with open laparoscopic access demonstrates complications related to primary access in 0.5% of patients [22]. In an effort to decrease the complications associated with the introduction of the first trocar, many variations of the Hasson technique have been proposed. Suggested alternatives include modifications to the traditional open approach, as well as techniques using a blunt tip trocar, a visualizing trocar, and a finger to gain initial access to the peritoneal cavity [8, 23, 24]. Others have suggested using an alternative site of entry for laparoscopy in patients with previous abdominal surgery [25]. The incision made in the Hasson technique is done infraumbilically where a considerable amount of subcutaneous fat can be encountered, while the technique described herein takes advantage of the fact that at the umbilicus the skin and peritoneum are in contact with each other without interposed fat. Therefore, this approach is believed to be advantageous for obese patients [21].

Optical Access

Optical access trocars have been developed as an alternative method of peritoneal entry. The theoretical advantage of these trocars is that each layer can be identified prior to transection. Two visual entry systems are available: one system retains the conventional trocar and cannula push-through design, where the visual trocar transects abdominal myofascial layers by applying axial PF generated by the surgeon's dominant upper body muscles, while the second visual cannula system applies radial PF generated by the surgeon's much weaker dominant wrist muscles to part the abdominal myofascial layers.

The First Disposable Visual Entry System

This system retains a push-through trocar and cannula design where the spike principle recruits considerable PF thrust, denting tissues towards viscera. After pneumoperitoneum is established with the Veress needle, the pressure is increased to 20 mm Hg. A Visiport™ (Covidien, Mansfield, MA), a disposable device consists of an optical obturator with a blunt, clear window at its distal tip and a recessed knife blade. Following the skin incision and blunt dissection into the fascia, the trocar connected to a 0° laparoscope is inserted. Under constant visualization, it is moved into the abdomen by activating the retracted blade at the instrument tip. The subcutaneous fatty tissue, anterior fascia of the rectus muscles, rectus muscles, posterior fascia of the rectus muscles, transversalis fascia, and peritoneum are traversed with slight rotating movements and moderate pressure. The trigger is activated when passing through fascia and peritoneum. The trocar advances by dilating the tissue planes and the correct position in the abdomen of the instrument can be recognized easily. After the peritoneal cavity is entered and pneumoperitoneum is started, the handpiece of the optical access trocar is removed and the 0° laparoscope is replaced with a 30° endoscope. All secondary trocars are placed under direct vision [26].

The Second Reusable Visual Entry System

The Endoscopic Threaded Imaging Port (EndoTIP™) (Karl Storz, Tuttlingen, Germany), is a reusable visual entry cannula that may be used as a primary and ancillary port and may be used to perform intra- or retroperitoneal operations. It consists of a stainless steel proximal valve and distal hollow cannula section. A single thread winds diagonally on the cannula's outer surface, which ends distally in a blunt notched tip. EndoTIP™ is available in different lengths and diameters for different surgical applications. The reusable retaining ring, or Telescope Stopper (TS), keeps the mounted telescope from sliding out of focus during insertion. This system has no trocar and is a hollow threaded cannula with a blunt distal tip to engage abdominal tissue layers. It uses the Archimedes spin principle to tent tissue

away from viscera, while relaying clear real-time monitor images of the port site. In addition, the outer thread avoids overshoot and renders port insertion and removal incremental and less forceful [27]. Despite visualization of tissue layers, these ports cannot prevent serious injuries as outlined by the review of the Food and Drug Administration's database by Sharp et al. [28]

The Retroperitoneal Approach

The retroperitoneoscopic approach to the kidney and adrenal has been described in detail previously [29, 30]. Briefly, patients are given gentle bowel preparation and are positioned on the operative table in the full 90° flank position with the table flexed and the kidney rest elevated. The technique used is a three-port approach. A 1.5-cm incision is made at the tip of the 12th rib and the retroperitoneum is entered. A trocar-mounted 800-cc balloon is used to create a working space outside and posterior to Gerota's fascia. A 10-mm 30° laparoscope is used to visualize proper dilation through the balloon. Following balloon deflation, a 10-mm blunt port is inserted and CO₂ pneumoretroperitoneum is established under high flow at a patient pressure of 15 mm Hg [17].

Two ancillary ports are then placed, of which the size depends on the indications; they may be 5 or 12 mm. One port is placed at the junction of the paraspinal muscles and the 12th rib, while the other is placed in the midaxillary line 2 cm above the anterior superior iliac crest. The psoas muscle is identified, the intermediate stratum of the transversalis fascia is divided, and the kidney and adrenal are retracted antero-medial. Mobilization remains completely posterior to the kidney and/or adrenal until vascular control is complete. Further steps involving ablative techniques, radical or partial nephrectomy, ureterectomy, or adrenalectomy have been previously described [17, 31].

Laparoscopic Access Difficulties

Factors that cause difficulties in laparoscopic entry to the peritoneal cavity or the retroperitoneal space are mainly related to patient factors and to some extent to surgeon factors.

Patient Factors

Obesity

Obesity is an ever-increasing problem. A thick layer of adipose subcutaneous tissue limits access, especially in the insertion of the initial camera port. The angle of insertion is more critical as this adipose layer limits free rotational movement of working ports. Patients who are grossly obese are at a significantly greater risk of complications when undergoing laparoscopic surgery. It is generally recommended

that an open (Hasson) technique should be performed for primary entry in patients who are morbidly obese, although even this technique may be difficult. If a Veress needle approach is used in the patient who is morbidly obese, it is important to make the vertical incision as deep as possible in the base of the umbilicus, since this is the area where skin, deep fascia, and parietal peritoneum of the anterior abdominal wall will meet. In this area, there is little opportunity for the parietal peritoneum to tent away from the Veress needle and allow preperitoneal insufflation and surgical emphysema. If the needle is inserted vertically, the mean distance from the lower margin of the umbilicus to the peritoneum is 6 cm (± 3 cm). This allows placement of a standard length needle even in extremely obese women. Insertion at 45° , even from within the umbilicus, means that the needle has to traverse distances of 11–16 cm, which is too long for a standard Veress needle [11, 32].

Ports need to be placed closer to the operation site, or longer ports and instruments must be used. The potential risk of misplacement of ports with associated injury is also higher for those choosing initial Verres needle insufflation. Open Hasson access requires a larger skin incision to see in the obese patient, and the overall operation time is generally prolonged. If the surgeon realizes intraoperatively that he or she is far away or aiming with difficult angle to the target organ, then new ports should be inserted, which will make the procedure more efficient and close the previous ports.

Very thin patients are also potentially at risk of trocar-related injury, mainly with the primary port, as adjacent organs and major vessels are much closer to the abdominal wall. Great care, therefore, must be taken when performing first entry and a Hasson approach or insertion at Palmer's point is preferable in this situation [11, 33]. Care and caution are essential when doing laparoscopy in children where open access may be advised and even continuous monitoring of all the laparoscopic instruments is essential to avoid inadvertent injury during the surgery.

Previous Surgery in the Area of Interest

Previous surgery can influence laparoscopy in many ways. It may cause difficulty in placing a Verres needle because of abdominal wall adhesions and limitations in proper insufflation. In retroperitoneal laparoscopy, a previous significant breach of the retroperitoneum increases the potential for significant adhesions and limitations in creating a sufficient working space [34].

The rate of adhesion formation at the umbilicus may be up to 50% following midline laparotomy and 23% following low transverse incision [35]. The umbilicus may not, therefore, be the most appropriate site for primary trocar insertion following previous abdominal surgery. The most usual alternative site is in the left upper quadrant, where adhesions rarely form, although even this may be inappropriate if there has been previous surgery in this area or splenomegaly. The preferred point of entry is 3 cm below the left costal margin in the mid-clavicular line (Palmer's point). A small incision is made and a sharp Veress needle inserted vertically. A check for correct placement using the pressure/flow test is performed. CO_2 is then insufflated to 20 mmHg pressure and a 2–5 mm endoscope is used to inspect the undersurface of the anterior abdominal wall in the area beneath the umbilicus.

If this is free of adhesions, the trocar and cannula can be inserted under direct laparoscopic vision. If there are many adhesions present, it is possible to dissect these free via secondary ports in the lower left abdomen or an alternative entry site can be selected visually [33].

If the initial intraperitoneal pressure is high (>10 mm Hg) and there is no rapid increase in intraperitoneal pressure at the commencement of insufflation, the Veress needle is removed and reinserted. No more than three attempts are made with the Veress needle. If still unsuccessful, open trocar placement or a nonbladed visualizing trocar entry technique is used for direct vision into the peritoneal cavity [20].

Anatomical Variations

Patients with a large degree of hydronephrosis or giant hydronephrosis that crosses the midline and causes significant anatomic distortion are at risk of injury to the intra-abdominal organs. Open (Hasson) access into the peritoneum is performed to avoid injury to the already displaced abdominal contents [36]. Prelaparoscopic deflation of the hydronephrotic kidney with intraoperative or preoperative nephrostomy tube insertion may also be performed. Variation in the course and size of parietal vessels attributable to inferior vena caval obstruction or portal hypertension are also susceptible to provoking unexpected injuries to parietal vessels [37].

Surgeon Factors

It is well established that both the retroperitoneal and transperitoneal approaches have distinct advantages and disadvantages with regard to urological laparoscopic surgery. In practical terms, the selection of one approach over the other depends on an individual surgeon's experience and training [29]. Surgeon experience is paramount in getting a safe, versatile access and in reducing the rate of port-site and other complications. With experience comes skill at accurate port placement, preventing inadvertent injury as well as maximizing surgical ergonomics, and, therefore, reducing fatigue [30].

Conclusion

Gaining safe and accurate access is the first and most important step in achieving a safe and efficient laparoscopic surgery. Detailed knowledge of the organ anatomy and prior surgical history with availability of all the important surgical tools is an important requirement to do safe laparoscopy.

Caution is vital in laparoscopic access and especially in children and thin or obese patients, and also in patients with previous surgeries. Open access is always an alternative for safe laparoscopy in difficult case scenarios.

References

1. Cuschieri A. Minimal access surgery and the future of interventional laparoscopy. *Am J Surg.* 1991;161:404–7.