

Christian de Virgilio  
*Editor*

Areg Grigorian  
*Associate Editor*

# Surgery

A Case Based Clinical Review  
*Second Edition*

 Springer

Surgery

Christian de Virgilio  
*Editor*

Areg Grigorian  
*Associate Editor*

# Surgery

A Case Based Clinical Review

Second Edition

*Editor*

**Christian de Virgilio**  
Department of Surgery  
Harbor-UCLA Medical Center  
Torrance, CA  
USA

*Associate Editor*

**Areg Grigorian**  
Department of Surgery, Suite 1600  
University of California, Irvine  
Orange, CA  
USA

ISBN 978-3-030-05386-4      ISBN 978-3-030-05387-1 (eBook)  
<https://doi.org/10.1007/978-3-030-05387-1>

© Springer Nature Switzerland AG 2020

This work is subject to copyright. All rights are reserved by the Publisher, whether the whole or part of the material is concerned, specifically the rights of translation, reprinting, reuse of illustrations, recitation, broadcasting, reproduction on microfilms or in any other physical way, and transmission or information storage and retrieval, electronic adaptation, computer software, or by similar or dissimilar methodology now known or hereafter developed.

The use of general descriptive names, registered names, trademarks, service marks, etc. in this publication does not imply, even in the absence of a specific statement, that such names are exempt from the relevant protective laws and regulations and therefore free for general use.

The publisher, the authors, and the editors are safe to assume that the advice and information in this book are believed to be true and accurate at the date of publication. Neither the publisher nor the authors or the editors give a warranty, expressed or implied, with respect to the material contained herein or for any errors or omissions that may have been made. The publisher remains neutral with regard to jurisdictional claims in published maps and institutional affiliations.

This Springer imprint is published by the registered company Springer Nature Switzerland AG  
The registered company address is: Gewerbestrasse 11, 6330 Cham, Switzerland

*To my wonderful wife and fellow surgeon, Kelly, who has always supported me; to my five children, Nick, Michael, Emma, Sophia, and Andrew, who have always made coming home a pleasure; and to all the students over the last two decades who have inspired me to teach.*

Christian de Virgilio

*To my two biggest mentors – Dr. Christian de Virgilio and Dr. Jeffry Nahmias – thank you both for your instrumental roles in shaping my career and allowing me to truly enjoy waking up everyday to come to the hospital. To my amazing wife, Rebecca, and my future little surgeon, Ella Sophia, thank you for being my biggest supporters.*

Areg Grigorian

## Foreword

---

I am delighted to write the foreword for the second edition of *Surgery: A Case Based Clinical Review* edited by Christian de Virgilio and Areg Grigorian.

I was honored to write the first one, and the book has had such impact since its publication in 2015 – it has been adopted by several medical schools, and it is in the top five of Springer’s medical books and among the top seven on Amazon! The book is meant for short chapter reads organized into sections with shelf questions at the end of each section to quickly assess one’s understanding of the important content.

Dr. de Virgilio was a third-year medical student on a pediatric surgical rotation when I was the senior resident. He was a fabulous student and went on to be a vascular surgeon – just like I did! He is a fabulous teacher and role model. Now, he is professor of Surgery, UCLA School of Medicine, chair of the Department of Surgery at Harbor-UCLA Medical Center, as well as co-chair of the College of Applied Anatomy.

This medical school textbook is such a treasure for medical students. The chapters begin with a patient

story followed by the pertinent facts needed on the history and physical examination – and, then, the student can learn to design the work-up, make the diagnosis, and manage the surgical problem. The preparation is essential to be able to answer the shelf examination questions which follow – all of this getting the medical student ready to master the information and do well on their examination in surgery.

As a dean of a medical school and a vascular surgeon, I am delighted that this book has served the medical students so well. I still see patients, perform surgery, and teach medical students, and, therefore, a book like this one is perfect! Someone taught us – therefore, we should teach as well!

» Life is an opportunity for us to contribute something that outlasts us and makes the world a better place.

–Apoorve Dubey

Teaching makes the world a better place. Go do that!

**Julie Ann Freischlag, MD**  
Winston-Salem, USA

## Preface

---

We are grateful to have heard from students around the country that our first edition was valuable for their surgery clerkship. As we are always striving to improve, we thank students for their valuable comments and have incorporated their feedback into the second edition to make it even better. At the same time, we've been sensitive to maintaining our goal of making the entire book "readable" over the course of a relatively brief third-year surgery clerkship. Thus, for this second addition, we've added several key chapters while condensing and combining others. As with the first edition, we've assembled a team of collaborators that include numerous surgery program directors, surgery clerkship directors, and various award-winning surgical educators. We've also included several medical students who were handpicked for their outstanding performance.

The goal of our book is to help you learn the essentials of surgery in the most efficient way possible. We feel our book will help you excel on the shelf exam, shine on the wards, think through the most commonly tested clinical vignettes, and develop your own deductive reasoning so that you make a great impression on your surgery clerkship. Additionally, each section is now followed by a series of questions that are intended to mimic the style of questions you will find on the actual NBME shelf exam.

The start of the third year of medical school is terrifying. You're suddenly thrust into a hospital, where you meet a new team of residents and faculty, meet patients, learn a new language (medical abbreviations), learn an electronic health system, and are expected to somehow shine even though you're the least experienced and least knowledgeable. Once you finally get acclimated, you might get moved to another rotation in another specialty (sometimes even to another hospital), forced to start the orientation once again. At the same time, you're required to attend lectures and prepare for a final examination that may influence your ability to get a future residency. It's no doubt an extremely stressful time, but, at the end of the year, you will marvel at your professional growth and realize that being in the hospital with real patients is far better than being in a classroom all day. Also, you can

take solace in the fact that all your evaluators (e.g., residents and attendings) were at one point in their careers medical students like you. We hope our book gives you all the high-yield, test-relevant facts in an efficient and easy-to-understand manner so you can focus on what is important – how to be a great doctor!

Before discussing how to use our book, we want to share a few pearls about the surgery clerkship. First the "dos." Surgery is a team-based discipline. Always look for ways to help your team. Take an active role. Strive to make yourself irreplaceable, but do so with humility. Treat others like you would your family (assuming you get along with them). Be an effective communicator. Ask a lot of questions (but make it clear from your questions that you've been reading). Ask how you can help. Now the "don'ts." Don't be arrogant. Don't try to upstage your co-student or intern. And finally, don't worry! If you work hard, display enthusiasm, and take an active role, people will notice! You'll also be surprised to discover that most surgeons enjoy teaching (and aren't as mean as portrayed on TV). And you may even get bit by the surgery bug (we hope)!

Now let's move on to how to use this book. The book is case-based and is in a short question-and-answer format. A risk of a case-based book is that you only learn that one specific case. To prevent falling into such a pitfall, we've also included pertinent differential diagnoses for each case and discuss how to distinguish them. We've tried to limit anatomy and pathophysiology to those that are clinically relevant. We've tried to exclude most cancer staging systems, as these constantly change, are hard to memorize, and are infrequently tested. We've tried to arrange the management in a "what's the next step" format, as such questions are frequently asked. We've purposely avoided too many details about specific aspects of surgical procedures as those are beyond the scope of a student. For those that want a bit more, we've added "areas where you can get in trouble," which are pitfalls in the diagnosis or management, and "areas of controversy." At the end of each chapter, there is a Summary of Essentials that permits a quick review. Finally, we've created questions and answers to follow

each section (with an emphasis on why the wrong answers are wrong). It's important to realize that the questions are *not* intended to test your understanding of the reading. Rather, many of the questions are meant to supplement the reading by testing important topics that couldn't be covered (so don't be discouraged if you miss a lot of them!).

Our advice is to strive to read the whole book during your rotation. Read all the chapters in one section, and then do the supplement questions for that section. We've purposely made each chapter relatively short, so that you should be able to read

each one in 20–30 min (or less). And, you should be able to read four to five chapters per week.

We're confident our book will help you during your surgery clerkship as well as for the shelf exam. We also realize that no single resource can do it all (including this book).

We hope you enjoy our book as much as we enjoyed writing it! We'd love to get your feedback. Feel free to email us on [cdevirgilio@lundquist.org](mailto:cdevirgilio@lundquist.org) and [agrigori@uci.edu](mailto:agrigori@uci.edu) or follow on Twitter @[drdevirgilio](https://twitter.com/drdevirgilio). Best of luck on your rotation and in your (surgical) career!

**Christian de Virgilio**

Los Angeles, USA

**Areg Grigorian**

Orange, USA



## Acknowledgments

---

Our book project could never have come to fruition without the assistance of several individuals. We would like to acknowledge Richard Hruska, Senior Editor at Springer, who demonstrated belief

in our book project and quickly embraced it, and Connie Walsh, Developmental Editor at Springer, who patiently put up with our constant emails, phone calls, and numerous revisions.

**Christian de Virgilio**

**Areg Grigorian**

# Contents

---

## I Acute Care Surgery

- 1 **Fever and Hypotension in the Intensive Care Unit** ..... 3  
*Monica Lee, Areg Grigorian, Christian de Virgilio, and Joanne M. Bando*
- 2 **Nausea, Vomiting, and Left Groin Mass** ..... 11  
*Areg Grigorian, Christian de Virgilio, and David C. Chen*
- 3 **Abdominal Pain, Nausea, and Vomiting** ..... 21  
*Jill Q. Klausner and David C. Chen*
- 4 **Right Leg Pain, Swelling, and Erythema for Two Days** ..... 29  
*Monica Lee, David C. Chen, Areg Grigorian, Paul N. Frank, and Christian de Virgilio*

## I Question Set: Acute Care Surgery

## II Breast and Skin

- 5 **Abnormal Screening Mammogram** ..... 43  
*Areg Grigorian, Christian de Virgilio, and Danielle M. Hari*
- 6 **New Palpable Mass in the Right Breast** ..... 51  
*Areg Grigorian, Christian de Virgilio, and Danielle M. Hari*
- 7 **Recently Changed Skin Lesion** ..... 63  
*Arezou Yaghoubian and Junko Ozao-Choy*

## II Question Set: Breast and Skin

## III Cardiothoracic

- 8 **Chest Pain, Diaphoresis, and Nausea** ..... 85  
*Areg Grigorian, Ryan Ou, Paul N. Frank, and Peyman Benharash*
- 9 **Chest and Back Pain** ..... 95  
*Ryan Ou, Paul N. Frank, and Peyman Benharash*
- 10 **Hemoptysis, Cough, and Weight Loss** ..... 103  
*Ryan Ou and Peyman Benharash*

## III Question Set: Cardiothoracic

## IV Endocrine

- 11 **Incidentally Discovered Adrenal Mass on CT Scan** ..... 119  
*Eugene J. Park, Masha J. Livhits, and Michael W. Yeh*

12	<b>Fatigue, Constipation, and Depressed Mood</b> .....	127
	<i>James X. Wu, Paul N. Frank, and Michael W. Yeh</i>	
13	<b>Intermittent Episodes of Sweating, Palpitations, and Hypertension</b> .....	139
	<i>Eugene J. Park, Masha J. Livhits, Areg Grigorian, and Michael W. Yeh</i>	
14	<b>Neck Mass that Moves with Swallowing</b> .....	149
	<i>James X. Wu and Michael W. Yeh</i>	
 <b>IV Question Set: Endocrine</b>		
 <b>V Head and Neck</b>		
15	<b>Progressively Hoarse Voice</b> .....	175
	<i>Kevin A. Peng, Irene A. Kim, and Vishad Nabili</i>	
16	<b>Lump on the Neck Increasing in Size</b> .....	181
	<i>Jon Mallen-St. Clair, Aaron J. Feinstein, and Vishad Nabili</i>	
17	<b>Aural Fullness, Hearing Loss, and Tinnitus</b> .....	191
	<i>Andrew M. Vahabzadeh-Hagh, Edward C. Kuan, and Vishad Nabili</i>	
 <b>V Question Set: Head and Neck</b>		
 <b>VI Hepatopancreaticobiliary</b>		
18	<b>Postprandial Right Upper Quadrant Pain</b> .....	209
	<i>Manan P. Shah, Matthew Y. C. Lin, and Christian de Virgilio</i>	
19	<b>Right Upper Quadrant Pain, Fever, Nausea, and Vomiting</b> .....	221
	<i>Manan P. Shah, Matthew Y. C. Lin, Paul N. Frank, and Christian de Virgilio</i>	
20	<b>Severe Epigastric Pain with Nausea and Vomiting</b> .....	227
	<i>Areg Grigorian, Matthew Y. C. Lin, and Christian de Virgilio</i>	
21	<b>New Onset of Painless Jaundice</b> .....	239
	<i>James X. Wu, Christian de Virgilio, Matthew Y. C. Lin, and Danielle M. Hari</i>	
 <b>VI Question Set: Hepatopancreaticobiliary</b>		
 <b>VII Lower Gastrointestinal</b>		
22	<b>Bright Red Blood per Rectum</b> .....	261
	<i>Tracey D. Arnell and Beverley A. Petrie</i>	
23	<b>Right Lower Quadrant Abdominal Pain</b> .....	269
	<i>Christian de Virgilio, Areg Grigorian, Beverley A. Petrie, and Tracey D. Arnell</i>	
24	<b>Pencil-Thin Stools and Intermittent Constipation</b> .....	279
	<i>Areg Grigorian, Christian de Virgilio, Tracey D. Arnell, and Beverley A. Petrie</i>	

25	<b>Chronic Constipation Presenting with Severe Abdominal Pain</b> .....	289
	<i>Beverley A. Petrie and Tracey D. Arnell</i>	
26	<b>Left Lower Quadrant Pain and Fever</b> .....	297
	<i>Christian de Virgilio, Tracey D. Arnell, Paul N. Frank, and Beverley A. Petrie</i>	
27	<b>Fatigue and Bloody Diarrhea</b> .....	303
	<i>Sarath Sujatha-Bhaskar, Areg Grigorian, and Christian de Virgilio</i>	
<b>VII Question Set: Lower Gastrointestinal</b>		
<b>VIII Neurosurgery</b>		
28	<b>Neck Pain and Extremity Weakness Following Trauma</b> .....	323
	<i>Richard G. Everson, Jose Manuel Sarmiento, and Isaac Yang</i>	
29	<b>Loss of Consciousness Following Head Trauma</b> .....	331
	<i>Isaac Yang and Richard G. Everson</i>	
<b>VIII Question Set: Neurosurgery</b>		
<b>IX Orthopedic</b>		
30	<b>Multiple Extremity Injuries After Motorcycle Accident</b> .....	349
	<i>Areg Grigorian, C. Max Hoshino, Spencer Albertson, and Kevin W. Rolfe</i>	
31	<b>Immediate Swelling After Trauma to the Knee</b> .....	357
	<i>D' Ann E. Arthur, Spencer Albertson, and Kevin W. Rolfe</i>	
32	<b>Adolescent Male with Right Groin Pain and Limp</b> .....	367
	<i>John F. Fleming III, Tracy Kim Kovach, and Kevin W. Rolfe</i>	
33	<b>Chronic Right-Hand Pain</b> .....	377
	<i>Arezou Yaghoubian and Kevin W. Rolfe</i>	
<b>IX Question Set: Orthopedic Surgery</b>		
<b>X Pediatric</b>		
34	<b>Full-Term Male Infant with Respiratory Distress</b> .....	399
	<i>Veronica F. Sullins, Rivfka Shenoy, and Steven L. Lee</i>	
35	<b>Infant with Bilious Emesis</b> .....	405
	<i>Rivfka Shenoy, Veronica F. Sullins, and Steven L. Lee</i>	
36	<b>Infant with Nonbilious Emesis</b> .....	411
	<i>Veronica F. Sullins, Rivfka Shenoy, and Steven L. Lee</i>	
37	<b>Infant Born with Abdominal Wall Defect</b> .....	417
	<i>Justin P. Wagner, Rivfka Shenoy, and Steven L. Lee</i>	

38 **Excessive Drooling in a Newborn** ..... 423  
*Veronica F. Sullins, Rivfka Shenoy, and Steven L. Lee*

## X Question Set: Pediatric Surgery

## XI Surgical Complications

39 **Postoperative Bleeding** ..... 439  
*Areg Grigorian, Christian de Virgilio, Dennis Y. Kim, Paul N. Frank, and Jeffry Nahmias*

40 **Postoperative Decreased Urine Output** ..... 449  
*Dean Spencer, Dennis Y. Kim, Christian de Virgilio, Areg Grigorian, and Jeffry Nahmias*

41 **Shortness of Breath 5 Days After Surgery** ..... 455  
*Jacquelyn L. Phillips, Christian de Virgilio, Areg Grigorian, Paul N. Frank, and Jeffry Nahmias*

## XI Question Set: Surgical Complications

## XII Trauma

42 **Abdominal Pain Following Motor Vehicle Collision** ..... 475  
*Areg Grigorian, Alexis L. Woods, Christian de Virgilio, and Dennis Y. Kim*

43 **Penetrating Abdominal Trauma** ..... 485  
*Jeffry Nahmias, Areg Grigorian, and Dennis Y. Kim*

44 **Pedestrian Struck by Motor Vehicle** ..... 493  
*Zane W. Ashman, Areg Grigorian, Christian de Virgilio, and Dennis Y. Kim*

45 **Gunshot Wound to the Left Neck** ..... 501  
*Sebastian D. Schubl, Alexis L. Woods, Christian de Virgilio, and Dennis Y. Kim*

46 **Stab Wound to the Chest** ..... 509  
*Patrick T. Delaplain, Christian de Virgilio, Areg Grigorian, and Dennis Y. Kim*

47 **Burns to the Face, Trunk, and Extremities** ..... 519  
*Victor C. Joe, Areg Grigorian, Christian de Virgilio, and Dennis Y. Kim*

48 **Severe Right Leg Pain After Tibia Fracture** ..... 529  
*Austin R. Dosch, Areg Grigorian, Christian de Virgilio, and Dennis Y. Kim*

## XII Question Set: Trauma

## XIII Upper Gastrointestinal Bleeding

49 **Bloody Emesis** ..... 553  
*Areg Grigorian, Viktor Gabriel, Christian de Virgilio, and Brian R. Smith*

50 **Severe Epigastric Abdominal Pain** ..... 563  
*Viktor Gabriel, Sahil Aggarwal, and Brian R. Smith*

51	<b>Weight Loss and Early Satiety</b> .....	569
	<i>Sahil B. Gambhir and Brian R. Smith</i>	
52	<b>Chest Pain After Vomiting</b> .....	577
	<i>Tiffany T. Pham and Brian R. Smith</i>	
 <b>XIII Question Set: Upper Gastrointestinal</b>		
 <b>XIV Urology</b>		
53	<b>Scrotal Pain</b> .....	593
	<i>Areg Grigorian, Fuad F. Elkhoury, and Jeremy M. Blumberg</i>	
54	<b>Scrotal Mass</b> .....	599
	<i>Areg Grigorian, Fuad F. Elkhoury, and Jeremy M. Blumberg</i>	
55	<b>Blood in Urine</b> .....	607
	<i>Jeremy M. Blumberg, Fuad F. Elkhoury, and Kiran Gollapudi</i>	
 <b>XIV Question Set: Urology</b>		
 <b>XV Vascular</b>		
56	<b>Transient Loss of Vision in the Right Eye</b> .....	627
	<i>Areg Grigorian, Jessica Beth O'Connell, and Christian de Virgilio</i>	
57	<b>Right Calf Pain with Walking</b> .....	635
	<i>Divya Ramakrishnan and Christian de Virgilio</i>	
58	<b>Sudden Onset of Severe Left-Sided Abdominal Pain</b> .....	645
	<i>Michael de Virgilio and Nina M. Bowens</i>	
59	<b>Cold, Painful Right Lower Extremity</b> .....	653
	<i>Manan P. Shah, Nina M. Bowens, and Christian de Virgilio</i>	
 <b>XV Question Set: Vascular</b>		
	<b>Supplementary Information</b>	
	Index.....	675

# Contributors

---

## **Sahil Aggarwal, BS**

School of Medicine, University of California,  
Irvine School of Medicine  
Irvine, CA, USA  
[sahila@uci.edu](mailto:sahila@uci.edu)

## **Spencer Albertson, BS**

University of California, Irvine  
Irvine, CA, USA  
[salberts@uci.edu](mailto:salberts@uci.edu)

## **Tracey D. Arnell, MD**

Department of Surgery, NY Presbyterian Columbia  
New York, NY, USA  
[ta2107@cumc.columbia.edu](mailto:ta2107@cumc.columbia.edu)

## **D' Ann E. Arthur, MD**

Department of Orthopaedics  
Harbor-UCLA Medical Center  
Torrance, CA, USA  
[darthur@dhs.lacounty.gov](mailto:darthur@dhs.lacounty.gov)

## **Zane W. Ashman, MD, MA**

Department of Surgery, Harbor-UCLA Medical Center  
Torrance, CA, USA  
[zane.ashman@gmail.com](mailto:zane.ashman@gmail.com)

## **Joanne M. Bando, MD**

Pulmonary and Critical Care Medicine,  
UCLA Medical Center  
Los Angeles, CA, USA  
[jbando@mednet.ucla.edu](mailto:jbando@mednet.ucla.edu)

## **Peyman Benharash, MD**

Division of Cardiac Surgery  
University of California at Los Angeles  
Los Angeles, CA, USA  
[Pbenharash@mednet.ucla.edu](mailto:Pbenharash@mednet.ucla.edu)

## **Jeremy M. Blumberg**

Urology, Department of Surgery  
Harbor-UCLA Medical Center  
Torrance, CA, USA  
[JBlumberg@mednet.ucla.edu](mailto:JBlumberg@mednet.ucla.edu)

## **Nina M. Bowens, MD**

Vascular and Endovascular Surgery  
Harbor UCLA Medical Center  
Torrance, CA, USA  
[nbowens@dhs.lacounty.gov](mailto:nbowens@dhs.lacounty.gov)

## **David C. Chen, MD**

Department of Surgery  
University of California at Los Angeles  
Los Angeles, CA, USA  
[dcchen@mednet.ucla.edu](mailto:dcchen@mednet.ucla.edu)

## **Jon Mallen-St. Clair**

Department of Surgery, Division of Otolaryngology –  
Head and Neck Surgery, Cedars-Sinai Medical Center  
Los Angeles, CA, USA  
[jon.mallen-stclair@cshs.org](mailto:jon.mallen-stclair@cshs.org)

## **Patrick T. Delaplain, MD**

Pediatric Surgery, Children's Hospital of Los Angeles  
Los Angeles, CA, USA

Department of Surgery,  
University of California, Irvine Medical Center  
Orange, CA, USA  
[pdelapla@uci.edu](mailto:pdelapla@uci.edu)

## **Christian de Virgilio, MD**

Department of Surgery, Harbor-UCLA Medical Center  
Torrance, CA, USA

College of Applied Anatomy  
Department of Surgery, UCLA School of Medicine  
Los Angeles, CA, USA  
[cdevirgilio@lundquist.org](mailto:cdevirgilio@lundquist.org)

## **Michael de Virgilio, BS**

Boston University School of Medicine  
Boston, MA, USA  
[mdevir@bu.edu](mailto:mdevir@bu.edu)

## **Austin R. Dosch, MD**

Department of Surgery  
University of California, Irvine Medical Center  
Orange, CA, USA  
[adosch@uci.edu](mailto:adosch@uci.edu)

## **Fuad F. Elkhoury**

Department of Urology,  
University of California, Los Angeles  
Los Angeles, CA, USA  
[FFEkhoury@mednet.ucla.edu](mailto:FFEkhoury@mednet.ucla.edu)

## **Richard G. Everson, MD**

Department of Neurosurgery  
David Geffen School of Medicine of the  
University of California, Los Angeles  
Los Angeles, CA, USA

Division of Neurosurgery, Department of Surgery  
Harbor-UCLA Medical Center  
Torrance, CA, USA  
[reverson@mednet.ucla.edu](mailto:reverson@mednet.ucla.edu)

#### **Aaron J. Feinstein, MD, MHS**

Head and Neck Surgery  
University of California Los Angeles Medical Center  
Los Angeles, CA, USA  
[aaronfeinstein@gmail.com](mailto:aaronfeinstein@gmail.com)

#### **John F. Fleming III**

Spinal Reconstruction, Orthopaedic Surgery,  
Rancho Los Amigos/LA County Hospital  
Los Angeles, CA, USA  
[jffleming@gmail.com](mailto:jffleming@gmail.com)

#### **Paul N. Frank, MD**

Los Angeles, CA, USA  
[paulfrank521@gmail.com](mailto:paulfrank521@gmail.com)

#### **Viktor Gabriel, MD**

General Surgery, University of California, Irvine  
Orange, CA, USA  
[viktorg@uci.edu](mailto:viktorg@uci.edu)

#### **Sahil B. Gambhir, BSc, MD**

Department of Surgery  
University of California, Irvine Medical Center  
Orange, CA, USA  
[sgambhi1@uci.edu](mailto:sgambhi1@uci.edu)

#### **Kiran Gollapudi**

Department of Surgery, Division of Urology  
Harbor-UCLA Medical Center,  
David Geffen School of Medicine at UCLA  
Torrance, CA, USA  
[Kiran.gollapudi@mednet.ucla.edu](mailto:Kiran.gollapudi@mednet.ucla.edu)

#### **Areg Grigorian, MD**

Department of Surgery, University of California, Irvine  
Orange, CA, USA  
[agrigori@uci.edu](mailto:agrigori@uci.edu)

#### **Danielle M. Hari, MD**

Department of Surgery, Division of Surgical Oncology  
Harbor-UCLA Medical Center  
Torrance, CA, USA  
[hari@dhs.lacounty.gov](mailto:hari@dhs.lacounty.gov);  
[dhari@dhs.lacounty.gov](mailto:dhari@dhs.lacounty.gov)

#### **C. Max Hoshino**

Orthopedic Surgery, Harbor-UCLA Medical Center  
Torrance, CA, USA  
  
Rancho Los Amigos Rehabilitation Center  
Torrance, CA, USA  
[hoshinomax@gmail.com](mailto:hoshinomax@gmail.com)

#### **Victor C. Joe, MD, FACS**

UC Irvine Department of Surgery  
UC Irvine Health Regional Burn Center  
Orange, CA, USA  
[vcjoe@uci.edu](mailto:vcjoe@uci.edu)

#### **Dennis Y. Kim, MD**

Department of Surgery, Harbor-UCLA Medical Center  
Torrance, CA, USA  
[dekim@dhs.lacounty.gov](mailto:dekim@dhs.lacounty.gov)

#### **Irene A. Kim**

Department of Head and Neck Surgery  
University of California, Los Angeles  
Santa Monica, CA, USA  
[iakim@mednet.ucla.edu](mailto:iakim@mednet.ucla.edu)

#### **Jill Q. Klausner, MD, MS**

Department of Surgery  
David Geffen School of Medicine at UCLA  
Los Angeles, CA, USA  
[JKlausner@mednet.ucla.edu](mailto:JKlausner@mednet.ucla.edu)

#### **Tracy Kim Kovach, MD**

Orthopaedic Surgery, Harbor-UCLA  
Torrance, CA, USA  
[tracykovach@gmail.com](mailto:tracykovach@gmail.com)

#### **Edward C. Kuan, MD, MBA**

Otolaryngology-Head and Neck Surgery  
University of California, Irvine Medical Center  
Orange, CA, USA  
[eckuan@uci.edu](mailto:eckuan@uci.edu)

#### **Monica Lee, BA**

Department of Surgery, University of California, Irvine  
Orange, CA, USA  
[monicdl1@uci.edu](mailto:monicdl1@uci.edu)

#### **Steven L. Lee, MD**

Pediatric Surgery, Department of Surgery  
UCLA Mattel Children's Hospital  
Los Angeles, CA, USA  
[StevenLee@mednet.ucla.edu](mailto:StevenLee@mednet.ucla.edu)

#### **Matthew Y. C. Lin, MD**

Clinical Surgery, University of California San Francisco  
San Francisco, CA, USA  
[matthew.lin@ucsf.org](mailto:matthew.lin@ucsf.org)

#### **Masha J. Livhits, MD**

Surgery, David Geffen School of Medicine,  
University of California, Los Angeles  
Los Angeles, CA, USA  
[mlivhits@mednet.ucla.edu](mailto:mlivhits@mednet.ucla.edu)



**Vishad Nabili**

Department of Head and Neck Surgery  
UCLA Medical Center, David Geffen  
School of Medicine at UCLA  
Los Angeles, CA, USA  
[vnabili@mednet.ucla.edu](mailto:vnabili@mednet.ucla.edu)

**Jeffry Nahmias, MD, MHPE**

Department of Surgery, University of California, Irvine  
Orange, CA, USA  
[jnahmias@uci.edu](mailto:jnahmias@uci.edu)

**Jessica Beth O'Connell, MD**

Department of Surgery  
University of California Los Angeles  
Los Angeles, CA, USA

Department of Vascular Surgery  
Greater Los Angeles VA Healthcare System  
Los Angeles, CA, USA  
[joconnell@mednet.ucla.edu](mailto:joconnell@mednet.ucla.edu)

**Ryan Ou, MD**

Department of Surgery  
Kaiser Permanente Los Angeles Medical Center  
Los Angeles, CA, USA  
[ryanou@gmail.com](mailto:ryanou@gmail.com)

**Junko Ozao-Choy, MD**

Division of Surgical Oncology  
Harbor-UCLA Medical Center  
Torrance, CA, USA  
[jozao-choy@dhs.lacounty.gov](mailto:jozao-choy@dhs.lacounty.gov)

**Eugene J. Park, BA**

David Geffen School of Medicine,  
University of California, Los Angeles  
Los Angeles, CA, USA  
[eugenepark@mednet.ucla.edu](mailto:eugenepark@mednet.ucla.edu)

**Kevin A. Peng, MD**

House Clinic  
Los Angeles, CA, USA  
[kpeng@houseclinic.com](mailto:kpeng@houseclinic.com)

**Beverley A. Petrie, MD**

Department of Surgery, Division of Colon and Rectal  
Surgery, Harbor-UCLA Medical Center  
Torrance, CA, USA  
[bpetrie@dhs.lacounty.gov](mailto:bpetrie@dhs.lacounty.gov)

**Tiffany T. Pham, MS**

Department of Surgery, University of California, Irvine  
Orange, CA, USA  
[tiffantp@uci.edu](mailto:tiffantp@uci.edu)

**Jacquelyn L. Phillips, BS**

School of Medicine, UC Irvine Medical Center  
Irvine, CA, USA  
[jlphillips@alumni.caltech.edu](mailto:jlphillips@alumni.caltech.edu)

**Divya Ramakrishnan, BS**

Department of Surgery, UC Irvine School of Medicine  
Irvine, CA, USA  
[divyar@uci.edu](mailto:divyar@uci.edu)

**Kevin W. Rolfe, MD, MPH**

Orthopedic Surgery, Harbor-UCLA Medical  
Center and Rancho Los Amigos Rehabilitation Center  
Torrance, CA, USA  
[kwrolfe@gmail.com](mailto:kwrolfe@gmail.com)

**Jose Manuel Sarmiento, MD, MPH**

Department of Neurosurgery  
Cedars-Sinai Medical Center  
Los Angeles, CA, USA  
[j.manuel.sarmiento@cshs.org](mailto:j.manuel.sarmiento@cshs.org)

**Sebastian D. Schubl, MD**

Emergency General Surgery, Department of Surgery  
University of California, Irvine  
Orange, CA, USA  
[sschubl@uci.edu](mailto:sschubl@uci.edu)

**Manan P. Shah, BS**

David Geffen School of Medicine,  
University of California, Los Angeles  
Los Angeles, CA, USA  
[MPShah@mednet.ucla.edu](mailto:MPShah@mednet.ucla.edu)

**Rivfka Shenoy, MD**

Department of General Surgery, UCLA  
Los Angeles, CA, USA  
[rivfakashenoy@mednet.ucla.edu](mailto:rivfakashenoy@mednet.ucla.edu)

**Brian R. Smith, MD**

Department of Surgery and General Surgery Residency  
Program, University of California Irvine Medical Center  
Orange, CA, USA  
[smithbr@uci.edu](mailto:smithbr@uci.edu)

**Dean Spencer, MD**

Department of Surgery  
University of California Irvine Medical Center  
Orange, CA, USA  
[deansr@uci.edu](mailto:deansr@uci.edu)

**Sarath Sujatha-Bhaskar, MD**

Department of Surgery  
University of California Irvine Medical Center  
Orange, CA, USA  
[ssujatha@uci.edu](mailto:ssujatha@uci.edu)

**Veronica F. Sullins, MD**

Pediatric Surgery, UCLA Mattel Children's Hospital  
Los Angeles, CA, USA  
[ronniesullins@gmail.com](mailto:ronniesullins@gmail.com)

**Andrew M. Vahabzadeh-Hagh, MD**

Head and Neck Surgery, David Geffen School of  
Medicine, University of California, Los Angeles  
Los Angeles, CA, USA  
[avahabzadehhagh@mednet.ucla.edu](mailto:avahabzadehhagh@mednet.ucla.edu)

**Justin P. Wagner, MD**

Department of Pediatric Surgery  
University of Nebraska Medical,  
Children's Hospital and Medical Center of Omaha  
Omaha, NE, USA  
[justin.wagner@unmc.edu](mailto:justin.wagner@unmc.edu)

**Alexis L. Woods, MD**

UC Davis Medical Center  
Sacramento, CA, USA  
[alwoods@mednet.ucla.edu](mailto:alwoods@mednet.ucla.edu)

**James X. Wu, MD**

Department of Surgery, David Geffen School of  
Medicine, University of California, Los Angeles  
Los Angeles, CA, USA  
[jamesthewu@gmail.com](mailto:jamesthewu@gmail.com)

**Arezou Yaghoubian, MD**

Plastic Surgery, University of California, Los Angeles  
Los Angeles, CA, USA  
[ayaghoub@ucla.edu](mailto:ayaghoub@ucla.edu)

**Isaac Yang, MD, FAANS, FACS**

Department of Neurosurgery  
Reagan UCLA Medical Center  
Los Angeles, CA, USA

Department of Surgery  
Ronald Harbor UCLA Medical Center  
Los Angeles, CA, USA

Radiation Oncology  
UCLA Jonsson Comprehensive Cancer Center Institute  
Los Angeles, CA, USA

Head and Neck Surgery  
Geffen School of Medicine at UCLA  
Los Angeles, CA, USA  
[iyang@mednet.ucla.edu](mailto:iyang@mednet.ucla.edu)

**Michael W. Yeh, MD, FACS**

Surgery and Medicine, Section of Endocrine Surgery  
UCLA David Geffen School of Medicine  
Los Angeles, CA, USA  
[myeh@mednet.ucla.edu](mailto:myeh@mednet.ucla.edu)

# Acute Care Surgery

*David C. Chen*

## Contents

**Chapter 1 Fever and Hypotension in the Intensive Care Unit – 3**

*Monica Lee, Areg Grigorian, Christian de Virgilio,  
and Joanne M. Bando*

**Chapter 2 Nausea, Vomiting, and Left Groin Mass – 11**

*Areg Grigorian, Christian de Virgilio, and David C. Chen*

**Chapter 3 Abdominal Pain, Nausea, and Vomiting – 21**

*Jill Q. Klausner and David C. Chen*

**Chapter 4 Right Leg Pain, Swelling, and Erythema  
for Two Days – 29**

*Monica Lee, David C. Chen, Areg Grigorian, Paul N. Frank,  
and Christian de Virgilio*



# Fever and Hypotension in the Intensive Care Unit

*Monica Lee, Areg Grigorian, Christian de Virgilio, and Joanne M. Bando*

## Case Study

A 57-year-old male patient develops confusion and lethargy in the intensive care unit. He is 4 days status post emergent surgery for a perforated gastric ulcer that developed as a result of daily nonsteroidal anti-inflammatory drug (NSAID) use for chronic lower back pain. He was treated with an exploratory laparotomy and an omental (Graham) patch closure of the ulcer. On physical examination, his temperature is 39.2 °C, heart rate is 96

beats per minute, respiratory rate of is 24/minute, and blood pressure is 82/62 mmHg. Oxygen saturation is 92% on room air. The surgical incisions appear clean and intact, and the abdomen is nontender. There are diminished breath sounds on the right. His urine output has been 10 cc/hour for the last 6 hours, and the urine appears dark. Laboratory values reveal a white blood cell count of  $18 \times 10^3/\mu\text{L}$  (normal  $4.1\text{--}10.9 \times 10^3/\mu\text{L}$ ),

serum creatinine of 3.2 mg/dL (from a baseline of 1.1 three days earlier), and a blood pH of 7.1. Chest x-ray demonstrates a large area of consolidation in the right lower lobe. Given his lethargy, tachypnea, and low oxygen saturation, he is intubated by way of rapid sequence intubation. He is given several IV fluid boluses; however, the blood pressure does not improve. A vasopressor is initiated. Blood cultures are sent.

## Diagnosis

### What Is the Differential Diagnosis for a Post-op Patient with Fever?

Table 1.1

Diagnosis	Comments
<i>Aspiration pneumonitis</i>	Symptoms may consist of cough, wheezing, and shortness of breath
<i>Atelectasis</i>	Partial or complete collapse of a lung, often bibasilar, from obstruction or extrathoracic restriction (including pain); causes shortness of breath and hypoxemia; debatable whether it actually causes fever (may be coincidental as opposed to causal)
<i>Drug reaction</i>	Usually a diagnosis of exclusion if no other symptoms are present; may have a rash
<i>Pneumonia</i>	Productive cough, dyspnea, chest pain, and respiratory distress
<i>Surgical site infection</i>	Tenderness, erythema, swelling, warmth, delayed healing, purulent discharge
<i>Urinary tract infection</i>	Minimize catheter use and duration (less than 2 days, if possible)
<i>Venous thromboembolism</i>	Includes deep vein thrombosis and pulmonary embolism; prevented with chemical prophylaxis, sequential compression, and ambulation
<i>Adrenal insufficiency</i>	Hypotensive despite fluid resuscitation and vasopressors; may have fever, hyponatremia, hyperkalemia, hypoglycemia

### What Is the Classic Timing for the Different Causes of Postoperative Fever (the Five Ws)?

Table 1.2

W	Comment	Occurs
<i>Wind</i>	Atelectasis or pneumonia	POD 1
<i>Water</i>	Urinary tract infection	POD 3
<i>Walk</i>	Venous thromboembolism	POD 5
<i>Wound</i>	Infection	POD 7
<i>Wonder drugs</i>	Drug reaction	Anytime

POD postoperative day

#### Watch Out

Necrotizing postoperative wound infections (due to *Clostridia* or *beta-hemolytic Streptococcus*) can rarely occur within 12 hours of surgery. Such infections need prompt broad spectrum IV antibiotics and return to the operating room for debridement.

### What Is the Most Likely Diagnosis in This Patient?

The combination of fever and leukocytosis strongly suggests a diagnosis of sepsis, and given the diminished breath sounds and chest x-ray findings, the sepsis is most likely due to pneumonia. The addition of hypotension indicates that the patient is in shock. Although the differential of shock is broad (see below), with these findings, sepsis is the most likely cause.

In addition, a rising creatinine, decreased urine output, and mental status changes indicate that there is end-organ damage.

### What Other Diagnoses Should Be Considered in a Postoperative Patient with Fever and Hypotension?

Pulmonary embolism can also cause fever and hypotension (although the chest x-ray will generally be negative). Rarely, acute adrenal insufficiency can develop postoperatively (most often in patients with a history of steroid use), with a classic combination of fever, hyponatremia, hyperkalemia, hypoglycemia, and hypotension that is refractory to fluids and pressors.

### History and Physical

#### What Clues Are Expected on History and Physical for a Patient in Sepsis?

The history and physical examination should provide clinical clues so as to have a targeted approach to work up a septic patient. Always examine surgical wounds. Inspect the skin at the port of entry and all indwelling catheters (IV's, central lines) for evidence of infection. Look for other indwelling catheters (such as a bladder catheter) that might be a source of sepsis. If the patient progresses to shock, inflammatory mediators can lead to organ damage, which can present as oliguria, increased BUN and creatinine, and mental status changes. The skin is often warm and flushed from the increased peripheral vasodilation as total systemic vascular resistance drops similar to neurogenic shock, whereas other types of shock lead to cold, clammy skin. Confusion, disorientation, agitation, and anxiety are common in septic patients (septic encephalopathy). While fever is a common presentation for infection, an afebrile patient does not exclude sepsis. Patient populations who may not present with fevers include the very young, the elderly, those with dialysis-dependent renal failure, and the immunocompromised.

### What Is the Sequential Organ Failure Assessment (SOFA) and Quick SOFA (qSOFA) Score?

In 2016, the *Third International Consensus Definitions for Sepsis and Septic Shock* redefined the current definition used for sepsis and septic shock. The previously used definition of sepsis (2+ Systemic Inflammatory Response Syndrome criteria and a source of infection) was thought to be too nonspecific and generally unhelpful in the identification of patients at increased risk of mortality from infection. Sepsis is currently defined as life-threatening organ dysfunction caused by a dysregulated

host response to infection. A bedside screening tool called the qSOFA identifies patients likely to have a poor outcome as the result of an infection. A patient who meets two of the three criteria (respiratory rate  $\geq 22$ /min, altered mental status, and systolic blood pressure  $\leq 100$  mmHg) (such as the patient presented) has a higher risk for sepsis-related mortality.

The more detailed SOFA score takes objective criteria from multiple organ systems and assigns a score based on the amount of organ dysfunction. The score includes PaO<sub>2</sub>/FiO<sub>2</sub> ratio, platelet count, Glasgow Coma Scale (GCS), bilirubin, blood pressure, and creatinine.

Finally, the term septic shock has been redefined as sepsis that, despite adequate fluid resuscitation, requires vasopressors to keep the mean arterial pressure (MAP)  $\geq 65$  mmHg and have a lactate  $> 2.0$  mmol/L. The term "severe sepsis" is no longer being encouraged as a formal diagnosis.

### What Physical Exam Findings Suggest that a Patient Is Unable to Protect Their Airway?

A patient who is obtunded, has a GCS score of 8 or less, has an absent gag reflex, or has an inability to swallow is unable to protect his or her airway.

#### Watch Out

If the GCS is less than 8, intub8.

### Pathophysiology

#### What Are the Different Types of Shock?

Table 1.3

Type of shock	Causes	Pre-load	Cardiac output	After-load
Cardiogenic	MI, cardiac injury, arrhythmias, myocarditis	↑	↓	↑
Distributive (septic)	Anaphylaxis, sepsis, neurogenic shock	↓	↑	↓
Hypovolemic	Hemorrhage, dehydration, burns	↓	↓	↑
Obstructive	Cardiac tamponade, tension pneumothorax, pulmonary embolism	↑	↓	↓

## 1 What Is the Pathophysiology of Septic Shock?

Sepsis is an inflammatory cascade that attempts to control a noxious stimulus (such as bacterial invasion). The core problem of septic shock is not poor perfusion but the poor *utilization* of oxygen. Therefore, hypotension is a sequelae and marker of the inflammation, and not a contributing factor to the pathophysiology of sepsis. Inflammatory mediators chiefly impair mitochondrial oxidation by inhibiting pyruvate dehydrogenase and cytochrome oxidase, and thus destroy the cell's ability to produce adenosine triphosphate. Additionally, inflammatory mediators induce production of nitrous oxide resulting in systemic vascular dilation and high cardiac output (from increased heart rate). As stroke volume continues to decrease and stress on the cardiovascular system increases in untreated sepsis, compensatory tachycardia is unable to maintain cardiac output. The systemic venodilation sequesters the majority of the intravascular volume in the venous system, which is the basis of why fluid resuscitation is essential early in septic shock. However, to avoid the mortality associated with a large positive fluid balance, fluids should be titrated to an adequate urine output. Lastly, although there is systemic vascular dilation, there is relative splanchnic vasoconstriction resulting in gut ischemia and mucosal injury. This allows for enteric pathogen translocation and additional subsequent inflammation; this self-sustaining process of continued inflammation is known as the “motor” of multi-organ failure.

### What Is Acute Respiratory Distress Syndrome (ARDS)?

ARDS is an acute, diffuse inflammatory lung injury that was redefined in 2012 under the Berlin definition into a three-tiered grading system consisting of mild, moderate, and severe ARDS. Patients with ARDS have acute onset of respiratory symptoms and bilateral radiographic opacities not fully explained by heart failure. Trauma, sepsis, infection, or an inflammatory trigger leads to the release of pro-inflammatory cytokines which recruit and activate neutrophils, which cause diffuse alveolar epithelial and endothelial damage. The resulting vascular leakage leads to diffuse pulmonary edema with fibrin secretion, hyaline membrane formation, loss of aerated lung tissue, and remodeling. There is resulting hypoxemia, increased physiological dead space, and decreased lung compliance.

## If the Patient Were to Become Pulseless, What Are the Hs and Ts to Consider?

Table 1.4

H	Hypovolemia, hypoxia, hydrogen ion (acidosis), hypokalemia, hyperkalemia, hypothermia
T	Toxins (cocaine, tricyclics, digitoxin, beta blockers, calcium channel blockers), tamponade, tension pneumothorax, thrombosis (MI or PE)

### Workup

#### What Are the Initial Laboratory Studies to Order for a Patient in Septic Shock?

Order a complete blood count with differential, comprehensive metabolic panel, coagulation studies, serum lactate, arterial blood gas (ABG), peripheral blood cultures, and a urinalysis. If the patient has an indwelling central venous catheter, obtain a culture from that site as well. The peripheral blood should be cultured for aerobes and anaerobes from at least two different sites.

#### What Is the Significance of Increased Serum Creatinine and Oliguria?

A patient with increased serum creatinine and oliguria has impaired kidney function and is at risk for acute kidney injury. The resulting metabolic acidosis may lead to worsening hypotension. Indications for acute renal replacement therapy are acidosis, hyperkalemia, uremia, and fluid overload. Such renal replacement should be considered early on in patients with septic shock and acute kidney injury.

#### What Is the Difference Between the Two Types of Renal Replacement Therapy: Hemodialysis (HD) and Continuous Renal Replacement Therapy (CRRT)?

CRRT and HD both provide fluid or solute removal through diffusion (dialysis), convection (filtration), or a combination of both. CRRT can be used as a continuous therapy, while

HD occurs over 3–6 hours 2–3×/week. The hourly rates of fluid and solute removal with CRRT are lower per hour than with intermittent HD and may be better tolerated by hypotensive patients. Because CRRT is continuous, this can allow for larger net solute and fluid removal over time. For the above patient in septic shock with acute kidney injury, the preferred option is CRRT.

### What Are the Initial Imaging Studies to Order for a Postoperative Patient Believed to Be in Septic Shock?

Pneumonia should be suspected in patients with productive cough, respiratory distress, and prolonged ICU stay, and a chest x-ray should be ordered, as well as sputum cultures. Obtain abdominal plain films if there is suspicion for a bowel obstruction or perforation (keep in mind that a small amount of free air may persist for a few days after laparotomy). If there is clinical suspicion for an intra-abdominal source of infection, obtain a CT scan of the abdomen and pelvis (bearing in mind that intravenous contrast should be avoided with acute kidney injury). Ultrasound can be used to detect acute cholecystitis.

#### Watch Out

Intermittent bacteremia is common, so the blood culture may be negative. Continuous bacteremia is usually seen in a persistent endovascular infection such as endocarditis or those with an infected ventral venous catheter.

## Management

### What Are the Initial Management Goals for a Patient in Septic Shock?

The essential management of the septic patient includes early recognition, fluid resuscitation, blood cultures, broad-spectrum IV antibiotics, and vasopressors (norepinephrine first; then vasopressin). There is a notable absence of large randomized, controlled trials demonstrating improved survival of adjunctive treatment options aside from the above essentials. Urine output can be a surrogate for targeted fluid resuscitation with a goal of 0.5–1.0 mL/kg/h for adults. Blood products are only indicated if hemoglobin is <7.0 g/dL or if the patient is actively bleeding.

Send cultures from the suspected source of infection before starting antibiotics if it will not delay treatment. If the source is not known, obtain aerobic and anaerobic blood

cultures from two venipuncture sites. Start broad-spectrum IV antibiotics, and consider adding antifungal coverage if the patient is immunocompromised.

### What Is Rapid Sequence Intubation (RSI)?

RSI is used to rapidly secure tracheal intubation in patients who have not fasted and as such are at high risk of vomiting and aspiration. The patient is medicated with weight based, full dose (rather than titrated) sedative and neuromuscular agents to allow intubation within several minutes. The patient should be pre-oxygenated for a minimum of 3 min prior to the administration of an induction agent (such as ketamine or etomidate) without bag-valve-mask ventilation. This is followed immediately by a neuromuscular blocking agent (such as rocuronium or succinylcholine).

#### Watch Out

Etomidate can rarely lead to Addisonian crisis within 24 hours after administration and result in persistent hypotension and fever.

#### Watch Out

Succinylcholine is a depolarizing agent that may lead to life-threatening hyperkalemia and should not be used acutely in patients with crush injury, burns, multiple trauma, or baseline hyperkalemia.

### What Drugs Are Ideal to Use for Sedation in a Critically Ill and Intubated Patient?

Propofol (gamma-aminobutyric acid antagonist) is commonly used for sedation because it has a rapid onset and is short acting (effects continue for only 5–8 min). It is also useful in patients with head injury because it reduces intracranial pressure. Dexmedetomidine (alpha-2 agonist) is also commonly used as it allows for cooperative sedation and has a mild analgesic effect. It has also been demonstrated to reduce ICU delirium. Both propofol and dexmedetomidine can have potential side effects of hypotension and bradycardia. Benzodiazepines can also be used for sedation but have largely been replaced because they seep into adipose tissue, which can lead to prolonged effect even after discontinuation of the drug and make weaning from the ventilator difficult. Propofol and benzodiazepines have no analgesic effect.



## What Drugs Are Ideal to Use for Analgesia in a Critically Ill and Intubated Patient?

Opioids are the most widely used medications for analgesia in the hospital. Of the available opioid drugs, fentanyl is the most commonly used in critically ill patients because it has a fast onset (highly lipid soluble) and low risk of hypotension (not associated with histamine release) and does not have highly active metabolites (does not need to be renally dosed). Two non-opioid analgesics commonly used in the ICU are acetaminophen and NSAIDs (ketorolac, ibuprofen.) These drugs can help decrease the amount of opioid use.

## How Should the Patient's Oliguria Be Managed?

Oliguria in the presence of adequate fluid resuscitation indicates acute kidney injury (AKI). Patients in the ICU with AKI and septic shock may require renal replacement therapy. The slower rate of fluid and solute clearance per unit time of CRRT compared to intermittent HD may be better tolerated in patients with septic shock and hemodynamic instability.

## What Is the Significance of a Low pH?

As tissue oxygenation decreases, anaerobic energy production increases and creates lactic acid as a byproduct. The acidosis activates potassium channel pumps and nitric oxide synthases to hyperpolarize and vasodilate vascular smooth muscle cells. The local effect of low pH coupled with the vasodilatory effects of inflammatory mediators perpetuates the hypotension in sepsis.

## How Are Glucose Levels Managed in the Septic Patient?

Due to the high metabolic demand of a septic patient, insulin regimens are initiated when two consecutive blood glucose levels are  $>180$  mg/dL. Intensive glycemic control is no longer favored as this has been shown to cause more morbidity than maintaining more moderate glycemic control (see NICE-SUGAR trial).

## If the Patient Became Pulseless, How Should ACLS Be Executed?

For any emergency patient, assess the ABCs: airway, breathing, and circulation. Scan for breathing while firmly tapping and asking the patient to speak to check their airway. If there is no palpable carotid pulse, begin chest compressions immediately at a rate of 100 compressions/minute.

Attach the monitor and defibrillator to the patient, and continue chest compressions for 2 min. Then, check for a pulse and determine if the rhythm is shockable (pulseless ventricular tachycardia and ventricular fibrillation). If it is, shock the patient and resume chest compressions. After 2 min, recheck the pulse and rhythm and shock again if warranted. If the patient does not respond after this second cycle of chest compressions and defibrillation, give 1.0 mg epinephrine. Continue to recheck pulse and rhythm, shock if warranted, and give epinephrine every 3–5 min. If the patient continues to remain in ventricular tachycardia or ventricular fibrillation, amiodarone may replace epinephrine only for the second dose.

If the rhythm is not shockable (pulseless electrical activity or asystole), resume chest compressions for 2 min, and administer 1.0 mg epinephrine. Continue CPR and epinephrine boluses every 3–5 min until the underlying cause is treated or the rhythm becomes shockable.

## What Is the Difference Between Synchronized and Desynchronized Shock?

Synchronized shock (cardioversion) is the delivery of a low-energy shock which synchronizes to the QRS complex. There is a delay after the shock button is pressed to allow synchronization to the heart's natural electrical beat to avoid shocking during the T wave, which can initiate ventricular fibrillation. It is used for unstable atrial fibrillation, atrial flutter, and supraventricular tachycardias unresponsive to medication.

Desynchronized shock (defibrillation) is the delivery of a random high-energy shock as soon as the shock button is pressed irrespective of the QRS complex. It is used when there is uncoordinated intrinsic electrical activity in the heart, such as pulseless ventricular tachycardia or ventricular fibrillation.

## Summary of Essentials

### History and Physical

- Sepsis is defined as life-threatening organ dysfunction caused by a dysregulated host response to infection.
- A qSOFA score  $\geq 2$  identifies patients likely to have a poor outcome as the result of an infection.
- Signs of infection: fever, warm and flushed skin, and leukocytosis
  - Check for end-organ damage as evidenced by increased creatinine, decreased urine output, decreased platelet level, elevated bilirubin, increased oxygen requirements, and mental status changes.
  - Shock: Vasopressors needed despite adequate fluids and a lactate  $>2.0$  mmol/L.

## Pathophysiology

---

- Septic shock is systemic inflammation characterized by poor utilization of oxygen
- Inflammatory mediators inhibit the body's ability to produce energy and cause vasodilation
  - Cardiac output initially increases with the increased heart rate but is eventually compromised as venodilation pools venous return.

## Workup

---

- CBC, CMP, coagulation studies, lactate, ABG, blood cultures, and urinalysis
- Check for sources of infection based on patient's presentation and history

## Management

---

- IVF, broad-spectrum antibiotics, and vasopressors if needed
  - Tailor the antibiotics based on cultures and sensitivities
- ABCs: check airway, breathing, and circulation
  - Intubate if GCS <8
  - Achieve rapid sequence intubation with an induction agent (such as etomidate) and a paralytic (such as succinylcholine)

- Use propofol or dexmedetomidine for sedation in a critically ill and intubated patient
- Pulseless patient: start CPR
  - Ventricular tachycardia or ventricular fibrillation: shock ->. If patient remains unresponsive after two cycles of defibrillations, continue CPR with epinephrine.
  - Pulseless electrical activity or asystole: CPR with epinephrine and correct underlying cause (Hs and Ts)
- If renal replacement therapy is indicated for AKI, start CRRT in ICU patients who are hemodynamically unstable and requiring vasopressors despite adequate fluid resuscitation.
- Target blood sugars above 180 mg/dL

## Suggested Reading

---

- ARDS Definition Task Force, Ranieri VM, Rubenfeld GD, Thompson BT, et al. Acute respiratory distress syndrome: the Berlin definition. *JAMA*. 2012;30(23):2526–33.
- Landry DW, Oliver JA. The pathogenesis of vasodilatory shock. *N Engl J Med*. 2001;345(8):588–95.
- Nash DM, Przech S, Wald R, O'Reilly D. Systematic review and meta-analysis of renal replacement therapy modalities for acute kidney injury in the intensive care unit. *J Crit Care*. 2017;41:138–44.
- Rhodes A, Evans LE, Alhazzani W, et al. Surviving sepsis campaign: international guidelines for management of sepsis and septic shock. *Crit Care Med*. 2017;45(3):486–552.
- Russell JA, Rush B, Boyd J. Pathophysiology of septic shock. *Crit Care Clin*. 2018;34(1):43–61.



# Nausea, Vomiting, and Left Groin Mass

*Areg Grigorian, Christian de Virgilio, and David C. Chen*

### Case Study

A 65-year-old obese woman presents to the emergency department with nausea and vomiting for the past day. The frequency of vomiting has increased despite the fact that she has not eaten for the past 12-h. Over the last few months, she has noticed a painful “lump” in her left groin that protrudes upon straining (i.e., coughing, bowel movements) but quickly disappears after lying down. She reports that the lump

reappeared a few days ago but she can no longer push it back in. She has had no bowel movement and no flatus per rectum for the past 24-h. Her temperature is 37.9 °C, blood pressure 120/80 mmHg, and heart rate 120/min. She appears ill and uncomfortable with dry mucous membranes. Lung sounds are clear bilaterally. Her abdomen is mildly distended. Bowel sounds are high pitched with tinkles and

rushes. Her abdomen is non-tender to palpation. There is a 2 × 2 cm mass in the left groin inferior to the inguinal ligament that is very painful to palpation. The overlying skin is slightly erythematous. The bulge is just medial to her femoral pulse, extending toward her thigh compartment. Laboratory studies are significant for white blood count of  $14.7 \times 10^3/\mu\text{L}$  (normal  $4.1\text{--}10.9 \times 10^3/\mu\text{L}$ ).

## Diagnosis

### What Is the Differential Diagnosis for a Groin Mass (Use *MINT* Mnemonic)?

Table 2.1

Type	Examples	Comments
Malformation	Undescended testicle, varicocele, hydrocele, hernias	Hernias will protrude with straining and may reduce with pressure
Infectious/inflammatory	Lymphadenopathy (reactive), mononucleosis (EBV), abscess, sarcoidosis, lymphogranuloma venereum	“Shotty,” tender lymph nodes are typically reactive from local minor infections, scrapes, or cuts
Neoplastic	Lymphoma, lipoma, lymphadenopathy, metastatic cancer (anal, skin, genital)	Large non-tender lymph nodes limited to the inguinal region suggest metastatic cancer (melanoma, anal, or genital cancer) (testicular cancer does not usually metastasize to the groin; it more commonly travels to the retroperitoneum)
Traumatic	Hematoma, femoral aneurysm, or pseudoaneurysm	Inquire about a history of recent trauma or intervention

EBV Epstein-Barr virus

### What Is the Diagnosis for This Patient?

The diagnosis for this patient is small bowel obstruction (SBO) secondary to a strangulated hernia. The presence of abdominal distention, a groin mass (below the inguinal ligament), and high-pitched bowel sounds in a patient with progressive nausea with vomiting is highly suggestive of acute intestinal obstruction from a femoral hernia. The addition of systemic signs of inflammation or infection (fever, tachycardia, leukocytosis) and localized pain and redness of the skin overlying the hernia strongly suggests that the bowel within the hernia sac is ischemic or gangrenous. In this setting, emergent surgical intervention is necessary.

### History and Physical

#### Why Is It Important to Examine for Inguinal Lymphadenopathy?

Most often, a mass in the inguinal region in men and women will represent enlarged lymph nodes. Lymph nodes may enlarge either due to autoimmune disease, malignancy, or as a response to a localized or systemic infection. It is relatively common for adults to have small “shotty” (resembling lead pellets) lymph nodes in the inguinal region representing “reactive” lymphadenopathy with follicular hyperplasia in response to minor infections, cuts, or scrapes in the groin, perineum,

or lower extremity. Reactive nodes are usually sub-centimeter, mobile, tender, and firm. If nodes are very large, tender, and limited to the inguinal region, one must consider syphilis, chancroid, and lymphogranuloma venereum. Large non-tender inguinal lymphadenopathy limited to the inguinal region suggests metastatic cancer from a local source (melanoma, anal, or genital cancer). Large non-tender inguinal lymph nodes associated with diffuse lymphadenopathy suggest a systemic process (infectious, malignant, or autoimmune) such as tuberculosis, lymphoma, leukemia, HIV, or sarcoidosis.

### Why Is It Important to Ask if a Groin Mass Protrudes with Straining?

A groin mass that protrudes with straining (Valsalva) and reduces in the supine position is highly suggestive of a hernia. Acquired hernias develop as a result of structural weakness of the abdominal wall in conjunction with increased intra-abdominal pressure. Contributing factors include prior incisions, heredity, constipation, multiple pregnancies, obesity, and liver disease with ascites. History should include conditions that lead to chronic straining, as these may provide clues to underlying untreated conditions such as a chronic cough (chronic bronchitis, lung cancer), constipation (colon cancer), or urinary straining (benign prostatic hypertrophy, prostate cancer). It is also important to inquire about work- and activity-related issues such as heavy lifting and physical exertion.

## Pathophysiology

### What Is a Hernia?

A hernia is a protrusion of tissue or organ(s) through a defect, most commonly in the abdominal wall. In abdominal hernias, peritoneal contents, such as the omentum and/or bowel, may protrude through a defect or weakness in the muscle/fascia. Hernias have three components: the abdominal wall defect, the hernia sac which protrudes through the defect, and the contents within the sac. The neck of a hernia is the part of the hernia sac adjacent to the abdominal wall defect. If the neck is narrow (as is the case for most femoral hernias), the bowel herniates less frequently, but once it does enter, it has a higher chance of becoming constricted by the narrow neck and becoming incarcerated.

### What Is the Difference Between a Reducible and an Incarcerated Hernia? Between an Incarcerated and a Strangulated One?

A hernia can be described as *reducible* if the contents within the sac can be pushed back through the defect into the peritoneal cavity, whereas with an *incarcerated* hernia, the contents are stuck in the hernia sac. A *strangulated* hernia is a type of

incarcerated hernia in which there is compromised blood flow to the herniated organ (usually the small intestine but can also be the omentum, large bowel, or ovary). Strangulation more frequently occurs when the hernia defect is narrow. A loop of bowel protrudes through the hernia and becomes entrapped by the narrow neck. This may lead to a closed-loop bowel obstruction with both ends of the bowel blocked and nowhere for fluid and gas to egress. As the bowel continues to produce gas and secrete fluid, the progressive distention leads to a compromise of the blood flow. A strangulated hernia requires prompt surgical intervention as delays lead to worsening sepsis and death. The overall incidence of strangulation in inguinal hernias is much less than 1%. This risk, however, is increased in symptomatic patients and those with significant comorbidities. Predisposing risk factors include older age, duration of hernia (shorter is worse), type (femoral), and comorbidities. Some hernias (particularly those with large defects) can be chronically incarcerated (and therefore irreducible) for years without causing major symptoms (e.g., a large scrotal or large incisional hernia). Others (particularly with narrow necks) are at higher risk of progressing to strangulation.

### What Is the Pathophysiology of an Indirect Inguinal Hernia? A Direct Inguinal Hernia?

In general, indirect inguinal hernias are congenital, whereas direct hernias are acquired. *Indirect inguinal hernias* are caused by a persistent (patent) processus vaginalis. During embryologic development, the processus vaginalis, an out-pouching of the peritoneum, descends into the scrotum, bringing along the testicle with it. It subsequently closes prior to birth. If the processus remains patent (open), peritoneal fluid can fill the scrotum (communicating hydrocele), or the bowel can pass through the patent processus vaginalis into the scrotum (indirect hernia). In men, the indirect hernia sac travels along with the spermatic cord through the internal ring and into the scrotum. In women, it follows the tract of the round ligament toward the pubic tubercle. *Direct inguinal hernias* are due to a weakness in the floor (transversalis fascia) of the inguinal canal, directly through Hesselbach's triangle medial to the inferior epigastric vessels. They typically manifest after years of chronic straining, causing wear and tear to the abdominal wall musculature. Since they are acquired, it is unusual to find a direct inguinal hernia in a young person. The neck of an indirect inguinal hernia is relatively narrow as it passes through a relatively rigid and inflexible space (the internal ring), whereas direct inguinal hernias typically have a more broad-based neck, making strangulation less likely to occur.

#### Watch Out

Indirect inguinal hernias traverse the deep ring and the superficial ring, while direct inguinal hernias *only* pass through the superficial ring.

## What Are the Borders of Hesselbach's Triangle?

The lateral border is formed by the inferior epigastric vessels, the medial border by the rectus sheath, and the base by the posterior wall of the inguinal ligament.

## What Are the Other Types of Hernias?

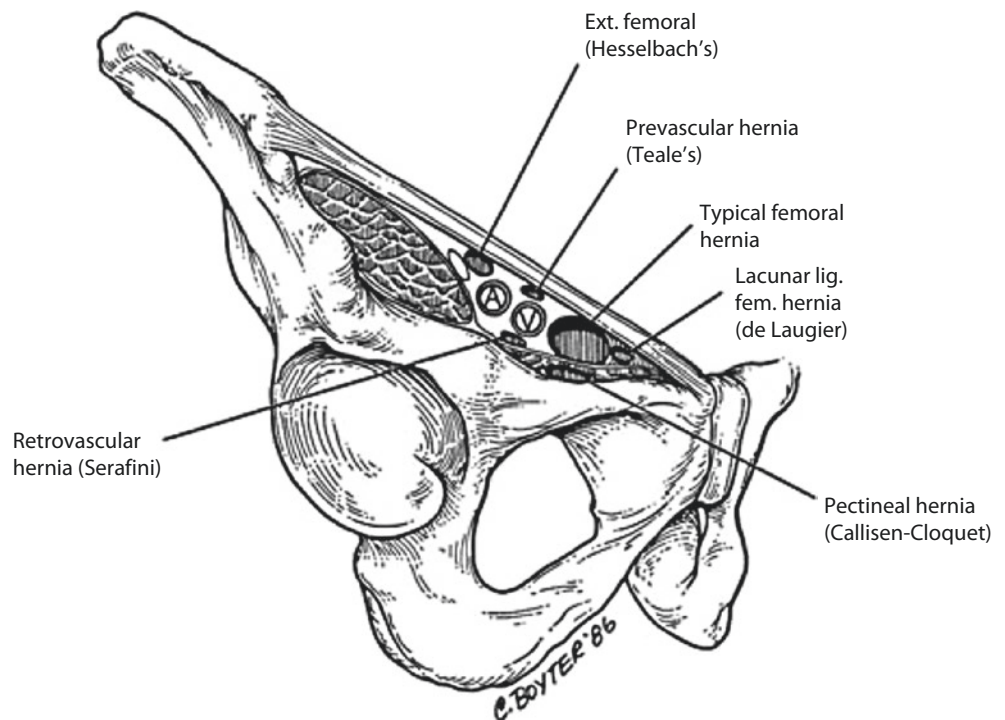
*Femoral hernias* occur in the femoral canal (■ Fig. 2.1), inferior to the inguinal ligament traversing the empty space medial to the femoral vein. Although they appear infrequently in patients (10% of all hernias), they are much more common in women (particularly multiparous women) and have the *highest* rate of strangulation (■ Table 2.2). *Umbilical hernias*

(■ Fig. 2.2) are prevalent in the pediatric population and common with congenital hypothyroidism. In children, most are asymptomatic and close spontaneously with no intervention (surgery if persists beyond age 4). In adults, umbilical hernias are associated with increased intra-abdominal pressure (pregnancy, ascites, weight gain). Surgery is recommended if symptomatic. *Ventral or incisional hernias* appear most commonly in the midline or at the site of a previous surgical incision and can occur weeks, months, or even years after the procedure.

### Watch Out

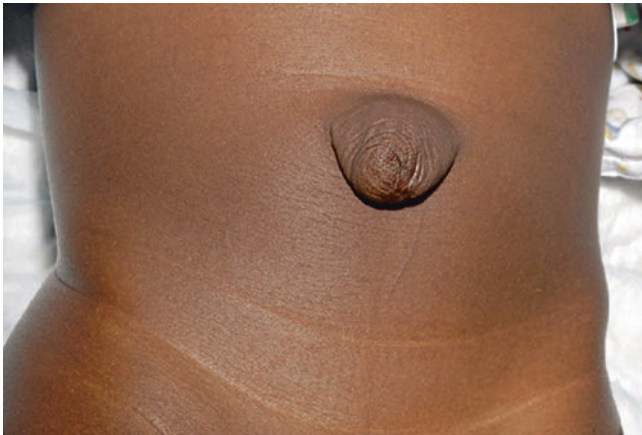Recall the mnemonic "NAVEL" for a femoral hernia; from lateral to medial: femoral nerve, artery, vein, empty space (hernia protrudes), and lymphatic.

■ Fig. 2.1 Femoral hernia. (From: Ates M, et al. First laparoscopic totally extraperitoneal repair of Laugier's hernia: a case report. *Hernia*. 2013;17(1):121–3. Reprinted with permission from Springer Nature)



■ Table 2.2 Inguinal hernia

Type	Anatomy	Pathophysiology	Hernia sac lining	Other
<i>Direct inguinal hernia</i>	Protrudes through the abdominal wall (Hesselbach's triangle), <i>medial</i> to the inferior epigastric artery	Acquired weakness in the abdominal floor, chronic straining	Peritoneum	Least likely to incarcerate, more common in men
<i>Indirect inguinal hernia</i>	Protrudes through the internal inguinal ring <i>lateral</i> to the inferior epigastric artery	Congenital	Patent processus vaginalis, peritoneum	The most common hernia in men, women, and children
<i>Femoral hernia</i>	Passes through the femoral canal, into empty space medial to femoral vein	Multiple pregnancies increase risk for hernia though narrow femoral neck	Peritoneum	More common in women, most likely to incarcerate/strangulate



**Fig. 2.2** Umbilical hernia. (From Miller R, et al. Umbilical hernia in babies and children. In: LeBlanc K, Kingsnorth A, Sanders D, editors. *Management of abdominal hernias*. Cham: Springer; 2018. Reprinted with permission from Springer Nature)

### Why Are Femoral Hernias More Prone to Incarceration?

Bowel entering a femoral hernia passes down the narrow femoral canal. The femoral ring, which serves as the entrance to the femoral canal, is very rigid and unyielding. Thus, the fixed neck of a femoral hernia is prone to pinching off the bowel, putting the patient at risk for incarceration.

### What Is the Significance of a Suspected Hernia Being Below as Opposed to Above the Inguinal Ligament?

A hernia below the inguinal ligament indicates that it is a femoral hernia, which passes under (posterior to) the inguinal ligament.

### What Is a Richter's Hernia?

It is a type of hernia that occurs when only *part of the circumference* of the bowel wall is trapped within the hernia sac. The herniated segment can become strangulated and result in ischemia/gangrene. Since only part of the wall of the small intestine is herniated, patients do not have signs or symptoms suggestive of bowel obstruction. The absence of obstruction may mislead the clinician into thinking that the bowel is not at risk for strangulation.

### What Is a Sliding Hernia?

A sliding hernia is a type of indirect hernia that occurs when a retroperitoneal organ (usually colon or bladder) typically herniates with the sac and essentially makes up the posterior wall of the sac. It usually occurs in males and more often on the left side. A sliding hernia should be suspected when the posterior

wall of the hernia sac feels thickened. It is particularly dangerous because if it is not recognized, the bowel can easily be injured or transected when dividing the hernia sac. An indirect hernia sac should always be opened anteriorly as this will prevent making a hole in the bowel or bladder if a sliding hernia is present.

#### Watch Out

A hernia containing the appendix is termed Amyand hernia, while one containing small bowel with a Meckel diverticulum is termed Littre hernia. Remember, Amyand for appendix and Littre for little kids (Meckel).

## Workup

### How Do You Diagnose a Hernia in an Adult?

Hernias are considered a clinical diagnosis. A good history (of a reducible mass that protrudes with straining) and a good physical exam are typically all that is needed. For both men and women, the patient is asked to stand. In men, the examiner's index finger is inserted in a cephalad direction through the scrotum, inverting it, and placed at the level of the external ring. The patient is asked to Valsalva or cough. If a hernia is present, a bulge will be palpated.

### How Do You Diagnose a Hernia in an Infant?

Both indirect inguinal hernias and umbilical hernias are common in infants. The physical exam may be challenging as the infant cannot cough or strain on command. Thus, the history from the parent of a noticeable bulge with crying is important. Raising the infant's arms will make the infant struggle, increasing intra-abdominal pressure, often permitting visualization of the hernia bulge.

### How Do You Distinguish Between a Direct and an Indirect Inguinal Hernia Intraoperatively?

Indirect inguinal hernias originate lateral to the inferior epigastric vessels, while direct inguinal hernias pass medial within Hesselbach's triangle. Indirect inguinal hernias travel through the internal ring along with the spermatic cord.

### What Is the Role of Imaging Studies in the Diagnosis of Hernia?

Abdominal hernias are typically diagnosed on the basis of a history and physical exam. However, at times, physical exam will be nondiagnostic despite a history that is strongly suggestive of a hernia. In particular, hernias may be difficult to appreciate in the morbidly obese, due to abundant subcutaneous fat. In these circumstances, adjunctive imaging studies may

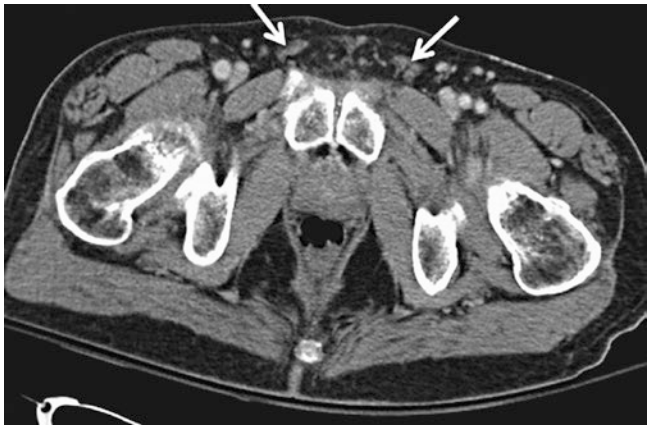aid in the diagnosis. Ultrasound with Valsalva is cost-effective and will often demonstrate an inguinal hernia but has limited efficacy in the obese patient. Cross-sectional imaging including computed tomography (CT) scan or magnetic resonance imaging (MRI) may be helpful. CT scan and MRI are also useful for rare abdominal wall hernias (such as Spigelian hernias) as they lie in between two layers of the abdominal wall, making these difficult if not impossible to palpate. CT is more cost-effective and convenient than MRI, but both provide similar information. In addition, a CT scan is an important diagnostic tool in the setting of a bowel obstruction, as it may demonstrate an undiagnosed hernia as the cause (■ Figs. 2.3 and 2.4).

## Management

### What Is the Principle Component of the Operative Management of an Indirect Inguinal Hernia in an Adult? How About a Direct Inguinal Hernia?

For an indirect hernia, the main goal is to open the sac (anteriorly), assess viability of the intestine, reduce any contents, and then perform a high ligation (at the internal

ring) of the hernia sac. This eliminates the patent processus vaginalis. This is all that needs to be done in pediatric cases. The distal sac can be excised if small or left in situ if large. In addition, in adults, the long-standing protrusion of the hernia through the internal ring weakens the surrounding muscle. As such, the floor of inguinal canal is reinforced with a tension-free mesh repair (Lichtenstein repair). With a direct hernia, since there is no patent processus vaginalis, the sac is not opened nor ligated. Since the sac consists of peritoneum and protrudes through the weakened floor of the inguinal canal, the sac is just reduced, and the floor of the inguinal canal is reinforced similarly to indirect hernias with a Lichtenstein repair. An alternative to using mesh is to close the hernia defect and strengthen the floor by sewing the elements of the floor together as a tissue-based repair (Bassini, Shouldice, McVay). Such repairs (without mesh) have the disadvantage of being under tension, and as such the hernia recurrence rates are significantly higher. These repairs are typically reserved for situations where mesh is unavailable, contraindicated (infection, gangrenous bowel), or declined (pain, preference, sensitivity). Laparoscopic inguinal hernia repair may be used to repair indirect, direct, and femoral hernias utilizing a posterior approach to the myopectineal orifice with mesh reinforcement.

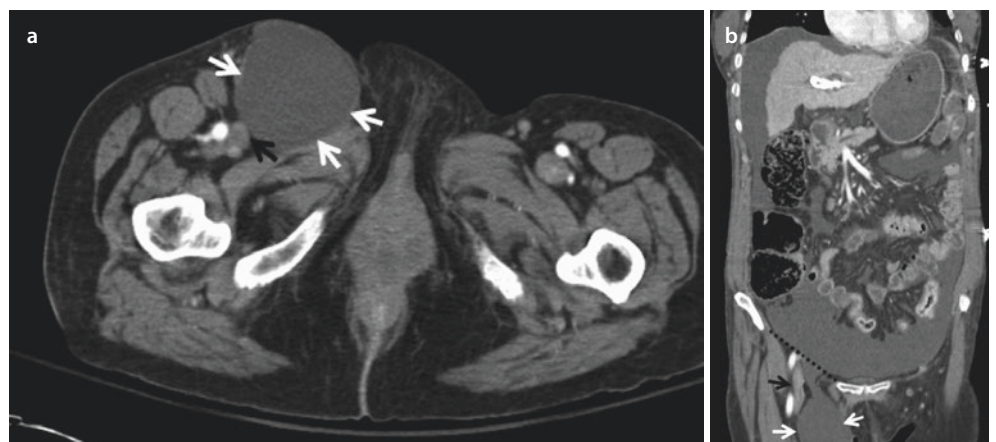


■ Fig. 2.3 Normal pelvic CT without hernia. White arrows: normal inguinal canals

### What Are the Principles of the Management of an Incarcerated Hernia?

Acutely incarcerated hernias are at risk of progressing to strangulation and require prompt attention. Provided there is no evidence of strangulation already, an attempt should be made to reduce the incarcerated hernia. This is typically done by placing the patient in slight Trendelenburg position, providing some sedation and analgesia, applying a cold compress, and then attempting gentle manual compression. The advantage of reduction is that it converts an emergent procedure into a semi-elective one and makes the operation easier as there will be less inflammation. If the hernia is not reducible, urgent surgical intervention is required.

■ Fig. 2.4 Axial a and coronal b CT scans showing a right-sided femoral hernia. Note that it is medial to the femoral vein and inferior to the inguinal ligament. White arrows: hernia sac. Black arrows: femoral vein. Black dotted line: location of inguinal ligament





## What Is the Recommendation for Inguinal Hernia Repair in Older Infants/Children?

The vast majority of hernias in infants are indirect hernias. Thus, high ligation of the hernia sac alone adequately corrects this defect. Since pediatric hernias typically have a smaller internal ring relative to its final adult size, the internal ring and the floor of the inguinal canal do not need reinforcement.

## What Is the Recommended Management for an Umbilical Hernia in an Infant?

Umbilical hernias are very common in newborns. They rarely incarcerate and most close spontaneously by age 2. Indications for surgery are persistence beyond age 4, hernia defect larger than 2 cm in diameter (unlikely to close spontaneously), strangulation, or progressive enlargement after 1–2 years of age.

## Complications

### What Nerves Can Be Injured During Hernia Repair? What Is the Mechanism of Injury? What Are the Consequences?

Table 2.3

Injury	Deficit
<i>Genital branch of the genitofemoral nerve</i>	Loss of cremaster reflex and pain or loss of sensation in the anterior scrotum/labia majora (genital branch)
<i>Ilioinguinal nerve</i>	Pain or loss of sensation at the base of the penis, mons pubis, and inner thigh
<i>Iliohypogastric nerve</i>	Pain or loss of sensation in the suprapubic region
<i>Lateral femoral cutaneous nerve (meralgia paresthetica)</i>	Pain or loss of sensation in the lateral side of the thigh, commonly extending to the knee, more common during laparoscopic repair

#### Watch Out

The most common nerve injured during open hernia repair is the *ilioinguinal nerve*. The most common nerve injured during laparoscopic repair is the *lateral femoral cutaneous nerve*.

## Areas Where You Can Get in Trouble

### Attempting to Reduce a Strangulated Hernia

Strangulated hernias imply that the bowel is compromised. Although the goal is to quickly restore blood flow to avoid bowel necrosis, this is not always possible, and the bowel may already be gangrenous upon presentation. If reduced, the gangrenous bowel will be pushed back into the peritoneal cavity, leading to sepsis and peritonitis. The only safe approach to reducing a strangulated hernia is in the operating room after confirming the bowel is not dead.

### Dissecting and Excising the Distal End of a Large Indirect Hernia Sac

The primary goal of indirect hernia repair is division of the hernia sac with proximal ligation near the internal ring. The distal sac, if small, is typically excised. However, if the indirect hernia sac is large, it will extend into and be adherent to the scrotum. In this situation the distal hernia sac may be left in situ. Attempting to remove the entire sac requires extensive dissection and carries an increased risk of disrupting the venous drainage of the testicle which is the leading cause of testicular ischemia.

### Chronically Reducible Hernia with SBO

Some patients may have a reducible hernia for years, and as long as it does not cause pain, episodes of obstruction, or decreased quality of life, they may elect to continue with watchful waiting. However, repeatedly reducing the hernia sac can lead to fibrosis of the hernia sac and surrounding tissue increasing increase risk for “reduction *en masse* of inguinal hernia.” In this condition, the hernia sac is reduced into the preperitoneal space, but the bowel is still strangulated within the fibrosed, trabeculated hernia sac leading to bowel obstruction and ischemia *without* an incarcerated or strangulated hernia appreciated on exam. CT scan can help demonstrate bowel obstruction in the preperitoneal hernia sac.

## Areas of Controversy

### Do You Repair or Observe Asymptomatic Inguinal Hernias?

There is ongoing debate as to whether asymptomatic inguinal (direct and indirect) hernias in adults should be repaired or whether one should wait for symptoms to develop. A large

prospective randomized controlled trial supports the premise of “watchful waiting,” provided no symptoms develop. More recent studies confirm the safety of watchful waiting but suggest that the majority of asymptomatic patients eventually do become symptomatic. Most surgeons will offer elective repair of asymptomatic inguinal hernias. Since femoral hernias are at higher risk of incarceration, repair is routinely recommended.

### What Is the Recommended Management for an Inguinal Hernia in a Premature Infant?

Premature infants are at higher risk of incarceration, with bowel necrosis and gonadal ischemia. However, premature infants are also at much higher risk of complications from surgery (pulmonary from general anesthesia, injury to the vas deferens due to small size). Data regarding optimal timing of repair are conflicting. Most pediatric surgeons agree that optimal management is to delay surgery until infant is out of the ICU.

### Do You Repair Asymptomatic Ventral/Incisional Hernias? Is Mesh Needed for Repair?

Incisional hernias typically develop after prior abdominal surgery. De novo ventral hernias will typically arise in the midline linea alba. Most surgeons will offer watchful waiting for asymptomatic incisional/ventral hernias. Incisional hernia repairs, due to the fact that they are re-operative, have more risk, as adhesions may be encountered with potential bowel injury during surgery. Depending upon the size of the hernia defect, mesh is generally used for repair. Mesh decreases the chances of hernia recurrence compared to sutures alone. However, there are several potential mesh-related complications that arise including mesh infection, recurrence, adhesions, pain, and erosion into the bowel with fistula formation. Preferred techniques involve placing the mesh in an extra-peritoneal position, to avoid contact with the bowel.

### Do You Repair Inguinal Hernias Laparoscopically or Open?

Laparoscopic inguinal hernia repair has a slightly higher recurrence rate than open. However, most recurrences occur early in the learning curve for an individual surgeon, whereas outcomes are excellent with experienced laparoscopic surgeons. Conversely, open repair is associated with slightly more postoperative pain. Both are considered acceptable alternatives with similar results. Current recommendations define a clear benefit for laparoscopic hernia repair in cases of bilateral inguinal hernias (less pain) and for recurrent inguinal hernias after prior open repair (less pain, similar results). Primary unilateral hernias may be repaired by either method.

## Summary of Essentials

### History and Physical

- Must differentiate between inguinal and scrotal masses
- With hernias, look for factors that increase intra-abdominal pressure (straining with urination, cough, constipation, ascites, pregnancy)

### Differential Diagnosis

- MINT: Malformation, infectious/inflammatory, neoplastic, traumatic
  - The most common inguinal mass: enlarged lymph nodes or Cloquet’s nodes (femoral triangle)
  - Autoimmune disease, malignancy, or as a response to a localized or systemic infection

### Pathology/Pathophysiology

- Reducible hernia: contents can be pushed back through the defect into the peritoneal cavity.
- Incarcerated hernia: contents are stuck in the hernia sac.
- Strangulated hernia: a subset of incarcerated hernia with compromised blood flow to the bowel leading to ischemia.
- Ventral or incisional hernia: at the site of a previous surgery.
- Femoral hernias:
  - Rare, more common in multiparous women and more prone to incarceration/strangulation.
  - Posterior and inferior to the inguinal ligament and medial to the femoral vein.
- Indirect inguinal hernia:
  - The most common hernia in men, women, and children.
  - Congenital (patent processus vaginalis), lateral to inferior epigastric vessels, and through the deep and superficial ring.
- Direct inguinal hernia:
  - More common in older men.
  - Acquired weakness in Hesselbach’s triangle, medial to inferior epigastric vessels, and only through the superficial ring.

### Workup

- Inquire about sources of increased straining/intra-abdominal pressure:
  - Urinary retention, constipation, heavy lifting, chronic cough, ascites, and weight gain
- A hernia is considered a clinical diagnosis:
  - No imaging usually needed
- In morbidly obese, diagnosis can be difficult:
  - CT scan when diagnosis unclear

## Management

---

- Asymptomatic hernias can be observed:
  - Exception: femoral hernias.
  - Exception: inguinal hernias in infancy.
    - Wait until preemie is out of the ICU.
- Most inguinal hernias eventually become symptomatic.
- Indirect hernia (most common):
  - Infants: Open the sac (anteriorly), reduce any contents, and perform a high ligation (at the internal ring) of the hernia sac.
  - Adults: Same and add Lichtenstein repair.
- Direct hernia (older men):
  - Do not open sac (no patent processus vaginalis), and reinforce floor with mesh (Lichtenstein) repair or laparoscopic repair.
- Femoral hernia (women):
  - Medial to the femoral vein
  - Inferior to the inguinal ligament
  - High incarceration risk
- Incarcerated hernia:
  - Attempt reduction and then repair semi-electively.
- Strangulated hernia:
  - Urgent surgery
- Umbilical hernia in children:

- Repair if persists > age 4, defect > 2 cm, and progressive enlargement after age 2.
- In adults, definitive treatment of inguinal and femoral hernias typically includes strengthening the floor of the inguinal canal with mesh.

## Complications

---

- Persistent pain from nerve injury is common.
- Recurrence.
- Testicular ischemia:
  - Swollen painful testicle following surgery followed later by testicular atrophy.

## Suggested Reading

---

- Abi-Haidar Y, Sanchez V, Itani KM. Risk factors and outcomes of acute versus elective groin hernia surgery. *J Am Coll Surg.* 2011;213:363.
- Eklund A, Rudberg C, Leijonmarck CE, et al. Recurrent inguinal hernia: randomized multicenter trial comparing laparoscopic and Lichtenstein repair. *Surg Endosc.* 2007;21:634.
- Society for Surgery of the Alimentary Tract. SSAT patient care guidelines. Surgical repair of groin hernias. *J Gastrointest Surg.* 2007;11:1228.
- Wijsmuller AR, van Veen RN, Bosch JL, et al. Nerve management during open hernia repair. *Br J Surg.* 2007;94:17.



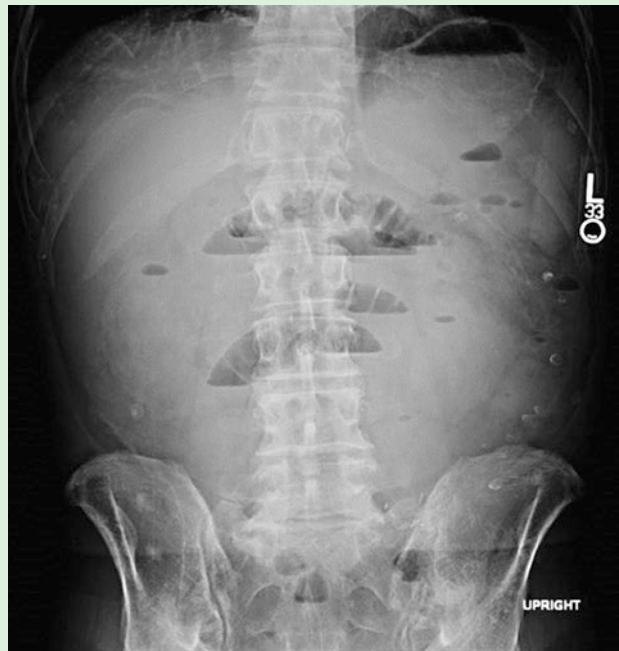# Abdominal Pain, Nausea, and Vomiting

*Jill Q. Klausner and David C. Chen*

## Case Study

A 38-year-old woman presents to the emergency department with colicky abdominal pain, nausea, and vomiting for the past day. She has had at least ten episodes of green, bilious emesis without blood. She has had no passage of stool or flatus per rectum since yesterday morning and has not eaten in 24 hours due to the vomiting and abdominal pain. She denies a history of similar symptoms and has no other medical problems. Past surgical history is significant for a cesarean section 2 years ago. Her temperature is 37.8 °C, heart rate is 122/min, blood pressure is 124/78 mmHg, and respiratory rate is 14/min. Her mucous membranes are dry and her abdomen is distended, with a well-healed low transverse abdominal incision. Auscultation reveals high-pitched tinkling bowel sounds. She has mild tenderness throughout the abdomen, but there is no rebound, guarding, or rigidity. No masses or hernias are identified. Rectal examination reveals normal tone, no gross blood, no masses, and no stool in the rectal vault. Laboratory examination is significant for a white blood cell count of  $8.2 \times 10^3/\mu\text{L}$  (normal 4.1– $10.9 \times 10^3/\mu\text{L}$ ), hemoglobin 17 g/dL (12.3–15.7 g/dL), hematocrit 51% (37–46%), sodium 141 mEq/L (135–145 mEq/L), potassium 2.9 mEq/L (3.5–5.0 mEq/L), chloride 93 mEq/L (98–106 mEq/L), bicarbonate 34 mEq/L (24–30 mEq/L), BUN 36 mg/dL (7–22 mg/dL), and creatinine 1.2 mg/dL (0.56–1.0 mg/dL). Urinalysis demonstrates aciduria. Abdominal x-ray is provided in

■ Fig. 3.1.



■ Fig. 3.1 Upright abdominal x-ray with air-fluid levels

3

## Diagnosis

## What Is the Differential Diagnosis?

■ Table 3.1

Diagnosis	History and physical
<i>Small bowel obstruction</i>	Colicky abdominal pain, nausea, bilious vomiting, obstipation, abdominal distention, hyperactive bowel sounds (early) or hypoactive bowel sounds (late), prior abdominal surgery
<i>Gastroenteritis</i>	Cramping abdominal pain, fever, nausea, vomiting, diarrhea, hyperactive bowel sounds
<i>Ileus</i>	Diffuse abdominal discomfort but no sharp colicky pain, hypoactive bowel sounds, stool in the rectum, may pass flatus and diarrhea, associated with recent surgery, narcotic use
<i>Large bowel obstruction</i>	Gradually increasing abdominal pain with longer intervals between episodes of pain, abdominal distention, obstipation, less vomiting (feculent), more common in the elderly
<i>Colonic pseudo-obstruction (Ogilvie's syndrome)</i>	Debilitated hospitalized medical or surgical patients; abdominal pain, nausea, vomiting, may continue to pass flatus, massive abdominal distention without mechanical obstruction; idiopathic
<i>Acute mesenteric ischemia</i>	Pain out of proportion to physical exam; nausea, vomiting, anorexia, atrial fibrillation

## What Is the Most Likely Diagnosis?

The history of acute onset of colicky abdominal pain, nausea, vomiting, and obstipation in a young patient with prior abdominal or pelvic surgery is highly suggestive of simple mechanical *small bowel obstruction* (SBO) due to adhesions from prior surgery. This patient presents with uncomplicated or *simple* SBO. Treatment is necessary in order to avoid progression and potential complications such as strangulation, bowel necrosis, sepsis, and even death. This patient also presents with severe volume depletion as evidenced by dry mucous membranes, prerenal azotemia (BUN/creatinine ratio >20), and a *hypochloremic, hypokalemic metabolic alkalosis* as a result of volume losses from recurrent emesis and third spacing secondary to SBO.

## Watch Out

A high bicarbonate level in the setting of vomiting is highly suggestive of metabolic acidosis.

## History and Physical Exam

## What Is the Significance of SBO in the Absence of an Abdominal Scar?

The absence of an abdominal scar markedly lowers the likelihood of adhesions, the most common etiology of SBO in the USA. Adhesions typically result from prior surgeries but may

rarely form due to prior abdominal infections, such as pelvic inflammatory disease or intestinal perforation. The majority of SBOs due to intra-abdominal adhesions will resolve with conservative treatment. On the other hand, most other causes of SBO are very likely to require surgical intervention and often emergently. Thus, without an abdominal scar, there's a high likelihood the patient will need surgical intervention.

#### Watch Out

Hernias are the most common cause of SBO worldwide. Always make sure to examine the groins, the umbilicus, and the femoral region for masses in patients presenting with signs/symptoms suggestive of SBO.

#### Watch Out

In a patient presenting with a history and exam suggestive of SBO, make sure to ask or look for abdominal scars from prior surgery (e.g., C-section scar may be under the belt line or small incisions from laparoscopic procedures).

### What Is the Howship-Romberg Sign?

This is suggestive of an obturator hernia and consists of pain in the medial aspect of the thigh with abduction, extension, or internal rotation of the hip due to compression of the obturator nerve by an obturator hernia (pelvic hernias seen mostly in elderly multiparous females and in those with significant weight loss).

### What Is the Significance of Severe Abdominal Pain and Localized Tenderness in Association with an SBO?

Severe abdominal pain and/or localized tenderness in association with SBO are suggestive of complicated or *strangulated* SBO. In contrast to a simple SBO where blood flow to the bowel remains intact, strangulated obstruction occurs when vascular perfusion is impaired, leading to intestinal ischemia and ultimately necrosis and perforation. Strangulation accounts for almost half of all deaths due to SBO and increases the morbidity rate significantly. Early surgical intervention is essential to avoid morbidity and poor outcomes. Strangulated obstruction typically presents with continuous (as opposed to intermittent) abdominal pain, signs of a systemic response (fever, tachycardia, leukocytosis), peritoneal signs, acidosis,

absence of bowel sounds, and localized abdominal tenderness. Occasionally, a painful mass or blood in the stool may be found. Unfortunately, these signs are not particularly sensitive or specific for early strangulation, but they should alert one to the possibility of strangulation and the need for early surgical intervention.

#### Watch Out

The four cardinal signs of strangulated bowel: fever, tachycardia, leukocytosis, and localized abdominal tenderness.

## Pathophysiology

### What Is a Closed Loop Obstruction?

A *closed loop obstruction* is a particularly dangerous form of bowel obstruction in which a segment of intestine is obstructed both proximally and distally. Vomiting will not relieve the obstruction nor will a nasogastric tube, as gas and fluid accumulates within this segment of bowel and cannot escape. This progresses rapidly to strangulation with risk of ischemia and perforation.

### What Is the Pathophysiology of SBO?

In SBO, gas and fluid accumulate proximal to the site of obstruction, causing dilation of the bowel followed by increased diffuse motility in attempt to overcome the obstruction. The increased peristaltic activity that attempts to overcome the obstruction in the early course of SBO causes the characteristic colicky pain. Since the increased motility is not localized, patients with SBO can present with diarrhea. The small bowel distention stretches visceral peritoneum, resulting in autonomic stimulation with progressive nausea and emesis. Failure to pass gas or stool per rectum is typically due to a complete mechanical obstruction of the small intestine.

### Are Bowel Sounds Helping in Diagnosing SBO?

Theoretically, bowel sounds are initially increased and should have a high-pitched, tinkling sound. As the bowel distends and intramural pressures rise, intestinal motility decreases, and bowel sounds diminish. Clinically, auscultation of bowel is not as useful in clinical practice when differentiating normal versus pathologic bowel sounds. In the presence of intestinal ischemia or perforated bowel, the bowel sounds may become absent.

## What Are the Most Common Causes of an SBO?

Table 3.2

Cause of SBO	Distinguishing features
<i>Intra-abdominal adhesions</i>	Most common cause <i>in the USA</i> ; associated with prior abdominal or pelvic surgery
<i>Hernia</i>	Most common cause <i>worldwide</i> (newly immigrated patient); bulge in groin or abdominal wall
<i>Crohns</i>	Terminal ileitis, strictures, perianal fistula, abscess, fissures; aphthous ulcers
<i>Gallstone ileus</i>	Elderly female; pneumobilia (air within biliary tree) seen on CT, possible large calcification (gallstone) on plain film in RLQ near the ileocecal valve
<i>Intussusception</i>	Target sign seen on CT; in adults, lead point is often a mass or tumor
<i>Neoplasm</i>	History of cancer; mass seen on CT
<i>Volvulus</i>	Whirl sign seen on CT
<i>Radiation-induced stricture</i>	History of pelvic radiation (e.g., prostate, gynecologic cancers)

RLQ right lower quadrant, CT computed-tomography

## What Is the Risk of Developing SBO After Different Operations?

In general, lower abdominal operations have higher risk for SBO, compared to upper abdominal operations. Adhesions after pelvic operations are responsible for more than 60% of all SBOs in the USA, with appendectomy being the most common cause, followed by colorectal resection, and then gynecologic procedures. Adhesions are caused by infection, foreign material (sutures), tissue ischemia, or handling of the bowel. Inflammatory processes such as appendicitis and diverticulitis create adhesions as surrounding intestinal loops attempt to contain the source of inflammation and infection. Disruption of the visceral and parietal peritoneum with pelvic operations leads to adhesions, especially in the dependent positions where the loops of the small intestine rest. Another possible explanation for the higher rate of SBOs after pelvic operations compared to abdominal operations is that the bowel is more mobile in the pelvis than in the upper abdomen and thus more likely to produce an obstructing torsion.

## Does Laparoscopic Surgery Have a Lower Risk for SBO Compared to Open Surgery?

Not always. One would expect the smaller incisions and minimally invasive dissections involved in laparoscopic surgery to be associated with a lower rate of postoperative adhesions and subsequent SBO. However, SBO following laparoscopic abdominal surgery can occur irrespective of the type of operation with the highest being in those undergoing laparoscopic cholecystectomy and appendectomy. In some cases, laparoscopic repair has a higher risk for subsequent SBO, compared to an open repair (e.g., hernias).

## What Are the Mechanisms of Fluid Loss in SBO?

Volume depletion is a common finding in SBO, but the mechanisms of fluid loss differ depending on the site and degree of obstruction. With proximal obstructions, repeated episodes of emesis as well as refusal of oral intake due to anorexia contribute to volume depletion and electrolyte abnormalities. With a complete obstruction, there is a transudative loss of fluid into the peritoneal cavity. The intestine proximal to the site of obstruction becomes distended due to the accumulation of gastrointestinal secretions and gas. Stasis in the intestinal lumen results in bacterial overgrowth, which causes even more dilation due to bacterial fermentation. As the hydrostatic pressure within the intestinal lumen increases, fluid accumulates in the bowel wall, altering the Starling forces of capillary fluid exchange such that there is a net filtration of fluid, electrolytes, and protein into the bowel wall and lumen. This loss of fluid from the intravascular space is termed *third spacing* and contributes to volume depletion in both proximal and distal SBO.

## What Is the Mechanism of Aciduria in Patients with Ongoing Emesis?

The above patient presents with a hypochloremic, hypokalemic metabolic alkalosis as a result of volume losses from recurrent emesis. The volume loss activates the renin-angiotensin-aldosterone system to increase sodium and water absorption from the distal convoluted tubules in the kidneys. In order to maintain ion balance, potassium is excreted in exchange for sodium. As the patient becomes progressively more hypokalemic (which can lead to arrhythmias), the kidney will eventually excrete hydrogen ions instead of potassium ions, which perpetuates the systemic metabolic alkalosis and results in a *paradoxical aciduria*. This occurs in all processes that involve persistent emesis/volume loss (e.g., pyloric stenosis).

## Workup

### What Laboratory Tests Should Be Obtained in the Initial Workup for SBO?

When working up SBO, it is important to obtain a complete blood count, chemistry panel, and serum lactate. While laboratory values do not play a significant role in the diagnosis of SBO, they are essential in assessing the degree of volume depletion and may raise the suspicion of bowel ischemia. Volume-depleted patients may exhibit hemoconcentration, as evidenced by elevated hemoglobin and hematocrit. A ratio of BUN/creatinine >20 is suggestive of prerenal azotemia, which can be caused by decreased blood flow to the kidneys. A chemistry panel can also assess for hypochloremic, hypokalemic metabolic alkalosis, which often results from repeated bouts of emesis. Leukocytosis raises the possibility of an infectious etiology or bowel compromise, changing the management algorithm of a simple SBO. An elevated serum lactate (or low serum bicarbonate), particularly associated with a non-anion gap metabolic acidosis, may indicate an ischemic bowel, as does hyponatremia.

### What Imaging Is Recommended for an SBO?

When SBO is suspected, initial imaging should include an abdominal series (Table 3.3), generally followed by an abdominal and pelvic CT with oral and intravenous contrast.

#### Watch Out

Remember what three films comprise an abdominal series (upright chest x-ray, upright abdominal x-ray, and supine abdominal X-ray {also termed KUB}). If the patient is critically ill and unable to sit upright, a left lateral decubitus film is substituted.

Table 3.3 Abdominal series

Films	Purpose
Upright chest radiograph	Rule out free air
Upright abdominal radiograph	Look for air-fluid levels
Supine abdominal radiograph	Determine amount of distention (width of small bowel)

### How Do You Differentiate Large and Small Bowel on Radiographs?

The small bowel has lines (plicae circulares) going all the way around the circumference of the bowel. The large bowel has lines (haustra) traversing only *halfway* through the bowel.

### What Are the Different Radiologic Findings Associated with SBO?

Table 3.4

Radiologic finding	Radiologic appearance	Associated pathology in context of SBO
SBO (abdominal series)	Dilated loops of small intestine (plicae circulares), air-fluid levels, bowel stacking	Classic radiographic findings of SBO
Target sign (CT)	Three concentric circles, with hyperdense inner and outer rings and a hypodense middle ring	Intussusception
Whirl sign (CT)	Twist of bowel wrapped around a single constrictive foci of mesentery or adhesion	Small bowel volvulus
Pneumatosis (CT)	Presence of gas within the wall of the intestine	Strangulated obstruction leading to intestinal ischemia and necrosis
Portal venous gas (CT)	Air in the periphery of the liver due to centrifugal portal flow	Late presentation of pneumatosis with air passing via portal venous circulation

### How Is a Complete SBO Different from a Partial SBO? Why Is It Important to Distinguish Between the Two?

In a *complete* SBO, the intestinal lumen is entirely occluded, and there is no passage of gas or fluid. In a *partial* SBO, gas and fluid are able to pass. Patients with a complete SBO present with colicky abdominal pain, nausea, vomiting, and obstipation. Those with a partial SBO develop similar symptoms, but more slowly, and continue to pass gas and stool beyond 6–12 hours after symptom onset. While plain films of a patient with complete SBO show dilated loops of bowel with air-fluid levels and no gas in the rectum, those with partial SBO *will show residual colonic gas*. Sometimes plain films will be equivocal, and CT



will be necessary in order to visualize the amount of residual air and fluid in the distal intestine. It is important to distinguish between a complete and partial SBO because the management of these two conditions is different. The risk of strangulation is minimal for patients with partial obstruction, whereas the risk is substantial for those with complete obstruction. Thus, a partial SBO can typically be managed nonoperatively, while complete SBO may require earlier surgical intervention.

### How Do You Distinguish SBO from LBO?

The clinical presentation of large bowel obstruction (LBO) is dependent upon location and etiology of obstruction. If the proximal colon is involved, it is more likely to be mistaken for SBO (assuming the ileocecal valve is incompetent) as the small intestine will become dilated too causing a similar clinical presentation. If a tumor is the cause of LBO, the course may be more insidious in onset, and symptoms may be chronic with less likelihood of confusion with SBO. In general, LBO causes gradually increasing abdominal pain, progressive distention, constipation, and occasionally feculent vomiting. There are longer intervals between episodes of cramping pain, and there is more pain in the suprapubic area with LBO than with SBO. Common causes of LBO include colon cancer, diverticular disease, and volvulus. On imaging, an “apple-core” lesion is characteristic of colon cancer, and a “coffee-bean” or “omega sign” tapering down toward the left lower quadrant is characteristic of sigmoid volvulus.

#### Watch Out

An obstructing sigmoid colon cancer can lead to a closed loop obstruction if the ileocecal valve is functional, as gas cannot exit into the small bowel or from rectum. A functional ileocecal valve is present in up to 80% of the population.

### How Do You Distinguish Between Postoperative Ileus and SBO?

In the early postoperative period, it is important to distinguish between an obstruction, which occurs in less than 1% of those undergoing laparotomy, and an ileus, which is considered as the most common postoperative complication. After abdominal surgery, GI motility is reduced due to a number of factors including a stress-induced sympathetic response, the release of inflammatory mediators, and the use of anesthetic and analgesic agents. The small intestine usually regains normal motility within the first 24 hours after surgery, the stomach takes 48 hours, and the colon can take as long as 3–5 days. This phenomenon is physiologic and is referred to as *postoperative ileus*. It may be difficult to distinguish postoperative ileus from early SBO, since postoperative ileus also presents with

abdominal pain, nausea, vomiting, and abdominal distention. Ileus, however, usually presents with absent or hypoactive bowel sounds, and the pain is described as dull and constant. One should suspect SBO if bowel function initially returned and subsequently the patient developed obstructive symptoms. Plain films should reveal dilated loops of bowel but no air-fluid levels in ileus. If x-rays are nondiagnostic, CT is very effective in differentiating SBO from postoperative ileus and will often reveal the etiology of postoperative SBO in many cases.

#### Watch Out

*Gallstone ileus* is a misnomer as this is a type of mechanical SBO where a large gallstone travels through a cholecystoduodenal fistula and becomes impacted in the narrower caliber distal small bowel near the ileocecal valve.

## Management

### What Are the Initial Steps in the Management of an SBO?

Patients with SBO are often significantly volume depleted. Aggressive fluid resuscitation (with an isotonic intravenous fluid such as normal saline) and electrolyte repletion are critical initial steps in the management. Additionally, early placement of a nasogastric (NG) tube to evacuate air and fluid is important because gastric decompression will decrease nausea, vomiting, distention, and the risk of aspiration. The more significantly ill patient should have an indwelling bladder catheter placed to monitor hourly urine output.

### What Is the Role of Gastrografin in the Management of SBO?

Early administration of oral contrast has been used for diagnostic and therapeutic purposes in the management of SBO. Passage of contrast to the large intestine predicts resolution and expedites the course of nonoperative management. Lack of passage predicts failure of conservative management, and early intervention improves outcomes and expedites management. The high osmotic load of oral contrast may help to resolve early partial SBO, as Gastrografin increases intraluminal water content and decreases bowel wall edema. Evidence is limited, but results from a recent multi-institutional, prospective observational study suggest that patients with SBO due to adhesions may benefit from Gastrografin, with lower rates of operative intervention and shorter length of stay in the hospital.

#### Watch Out

Gastrografin enema is also useful in resolving meconium obstruction in neonates.

## Operative Versus Nonoperative Management of SBO

---

In the absence of peritonitis or evidence of bowel ischemia, patients with an SBO due to adhesions should first undergo an initial period of NG tube decompression and fluid and electrolyte resuscitation. If the patient develops symptoms or signs of bowel compromise (increasing abdominal pain and tenderness on exam), the patient should then promptly be taken to the operating room. In the absence of such signs, it should be determined whether the SBO is partial or complete. The management of partial SBO is an initial trial of nonoperative management due to the fact that progression to strangulation is unlikely. Studies have shown that 60–85% of patients with partial obstruction will have resolution of symptoms without the need for surgery. However, if a patient with partial SBO begins to clinically deteriorate, prompt operative intervention may be necessary. The management of complete SBO or of a patient with evidence of ischemic bowel is urgent surgical intervention.

## What Should You Do if You Suspect Nonviable Bowel During Laparotomy for SBO?

---

Necrotic bowel generally does not occur in association with an SBO unless there is a closed loop obstruction. Any bowel that is obviously nonviable needs to be resected. If there are segments of bowel of questionable viability, there are several methods to assess viability. These methods include looking at the color (pink versus pale or bluish), peristalsis versus no peristalsis, and presence/absence of arterial pulsations in the mesentery. In addition, the bowel can be interrogated using a hand-held Doppler to detect audible arterial signals on the antimesenteric border of the questionable bowel. Finally, intravenous fluorescein dye can be administered. Viable bowel will take up the dye, which can then be seen using an ultraviolet (Wood's) lamp. If the viability remains in question, and it is a small segment, the segment should be resected. If there is a large segment of questionable viability (where resecting it could lead to short gut syndrome), the bowel can be left intact, the abdomen is kept open (with a negative pressure wound covering), and a second-look operation is performed to assess viability the following day after the patient has been warmed and further resuscitated.

## What Is the Management of Early Postoperative SBO?

---

Early postoperative SBO is uncommon, and most can be managed nonoperatively. If the diagnosis of acute postoperative SBO is made, an attempt to classify it as partial or complete is needed. Although most early postoperative SBO are partial obstructions, one must be able to detect complete obstruction

to prevent serious complication or bowel compromise. Partial obstruction should be managed conservatively, and in the postoperative setting, up to 3 weeks of nonoperative therapy may be acceptable. If there is a complete obstruction, one may initiate a trial of conservative management, only proceeding to the operating room for cases of suspected strangulation or lack of improvement after 24 hours of conservative management. Unique to the management of the postoperative SBO is the issue of timing. Traditionally, unless there is clear evidence of peritonitis or bowel compromise, reoperation is avoided until after 10–14 days postoperatively because early adhesions tend to be very dense and highly vascularized, making reoperation difficult and dangerous (with a high likelihood of injuring the bowel). Successful conservative management in these cases will ideally push elective intervention out 4–6 weeks when adhesions will remodel, making reoperation less morbid or allowing for avoidance of reoperation altogether.

## Areas Where You Can Get in Trouble

---

### Nausea and Vomiting Months to Years After Gastric Bypass

---

Although intra-abdominal adhesions are the most common cause of SBO in the USA, this is not true for patients following gastric bypass surgery. The most common cause of SBO in these patients is an *internal hernia*. Internal hernias most commonly form when bowel herniates through defects in the mesentery. Gastric bypass involves creating a Roux limb of small bowel that is connected to the stomach. A defect in the mesentery is created to pass the limb. This type of internal hernia is called a Petersen's space hernia. They may or may not present with abdominal distention. Laparoscopic gastric bypass repair has higher risk for internal herniation compared to its open gastric bypass. This may seem counterintuitive because laparoscopic surgery leads to a lower rate of postoperative adhesions. However, in the case of internal herniation, the formation of adhesions may serve as a protective role in preventing bowel mobility and the potential herniation into Petersen's space. Patients suspected of an internal hernia that are stable should be worked up with a CT abdomen/pelvis and undergo urgent surgical intervention. If the patient has evidence of peritonitis, the patient should go directly to surgery.

## Abdominal Complaints in Opioid Drug Users

---

Patients that abuse opioids (e.g., IV heroin, oral narcotics, etc.) often have abdominal complaints ranging from bloating, distention, constipation, and diarrhea to generalized vague abdominal pain or discomfort. Chronic opioid users develop opioid-induced constipation, which is the most common adverse effect associated with prolonged use of opioids. In contrast, opioid users going through withdrawal

may have increased GI motility and present with diarrhea. This may make it difficult to discern if serious abdominal pathology (e.g., small bowel obstruction, mesenteric ischemia) is present in a patient that may be abusing opioids or is in withdrawal. Physical exam findings that will help differentiate opioid withdrawal from an acute abdominal process include the presence of *mydriasis*, *rhinorrhea*, and *diaphoresis* in those presenting with opioid withdrawal.

## Summary of Essentials

### History and Physical Exam

- Acute onset of colicky abdominal pain, nausea, vomiting, and obstipation
- History of previous pelvic or abdominal operations
- Examine for hernias

### Pathophysiology

- Most common cause of SBO in the USA is intra-abdominal adhesions from prior surgery.
- Gas and fluid accumulate proximal to the site of obstruction.
- Ongoing emesis and third spacing lead to volume depletion, prerenal azotemia, and hypochloremic, hypokalemic metabolic alkalosis.

### Diagnosis

- Classic radiographic findings of SBO: dilated loops of small intestine, air-fluid levels, bowel stacking.
- CT can distinguish between postoperative ileus and SBO and can reveal the etiology of SBO.

## Management

- Initial treatment includes fluid resuscitation, electrolyte repletion, and placement of a nasogastric tube.
- Majority of patients with partial obstruction will not need surgery.
- Patients with complete obstruction may manage conservatively for 12–24 hours, but if no clinical improvement, surgical intervention is warranted.
- Immediately proceed to operating room if any signs or symptoms of peritonitis or bowel ischemia.
- Nonviable bowel must be resected.
- Avoid reoperation on early postoperative SBO unless clear evidence of peritonitis or bowel compromise.

## Suggested Reading

- Cheadle WG, Garr EE, Richardson JD. The importance of early diagnosis of small bowel obstruction. *Am Surg.* 1988;54:565.
- Duron JJ, Hay JM, Msika S, Gaschard D, Domergue J, et al. Prevalence and mechanisms of small intestinal obstruction following laparoscopic abdominal surgery: a retrospective multicenter study. *Arch Surg.* 2000;135(2):208–12.
- Felder S, Margel D, Murrell Z, Fleshner P. Usefulness of bowel sound auscultation: a prospective evaluation. *J Surg Educ.* 2014;71(5):768–73.
- Kozol R. Mechanical bowel obstruction: a tale of 2 eras. *Arch Surg.* 2012;147:180.
- Markogiannakis H, Messaris E, Dardamanis D, et al. Acute mechanical bowel obstruction: clinical presentation, etiology, management and outcome. *World J Gastroenterol.* 2007;13:432.
- Miller G, Boman J, Shrier I, Gordon PH. Natural history of patients with adhesive small bowel obstruction. *Br J Surg.* 2000;87:1240.
- Taylor MR, Lalani N. Adult small bowel obstruction. *Acad Emerg Med.* 2013;20:528.



# Right Leg Pain, Swelling, and Erythema for Two Days

*Monica Lee, David C. Chen, Areg Grigorian, Paul N. Frank,  
and Christian de Virgilio*

## Case Study

A 40-year-old male with diabetes mellitus and hepatitis C-related cirrhosis presents to the emergency department with a 2-day history of right leg pain, redness, and swelling. He states that he thinks he may have been bitten in the leg by a bug while sleeping. On physical examination, his temperature is 37.8 °C, heart rate is 110/min, blood pressure is

90/60 mmHg, and respiratory rate is 18/min. His right leg is markedly swollen as compared to the left. The skin overlying the calf region is erythematous, with one 3 cm bullae, and an area of violaceous skin. There is no palpable crepitus. Plain X-ray of the leg demonstrates gas bubbles within the soft tissue in the calf. The foot itself is pink and warm, with normal

pulses. Laboratory values are significant for a BUN of 40 mg/dL (normal 7–20 mg/dL), serum glucose of 200 mg/dL (70–100 mg/dL), creatinine of 1.6 mg/dL (0.8–1.4 mg/dL), white blood cell (WBC) count of  $24 \times 10^3/\mu\text{L}$  ( $4.1\text{--}10.9 \times 10^3/\mu\text{L}$ ), hemoglobin of 9.5 g/dL (13.8–17.2 g/dL), and a serum sodium of 128 mEq/L (136–144 mEq/L).

4

## Diagnosis

## What Is the Differential Diagnosis?

Table 4.1

Condition	Comments
<i>Necrotizing soft tissue infection (NSTI)</i>	Acute infection of the deep fascia, often with crepitus, bullae, and necrosis of the subcutaneous tissue, mixed flora
<i>Cellulitis</i>	Infection of the deep dermis and subcutaneous fat presenting with redness and erythema without the tissue destruction characteristics of NSTI
<i>Cutaneous anthrax</i>	Painless or pruritic eschar surrounded by edema
<i>Hypersensitivity reaction</i>	No fever or leukocytosis; history of exposure to plants or animals
<i>DVT</i>	Usually involves the leg, look for history of hypercoagulability, immobility, and/or inflammatory state (e.g., postsurgical, malignancy)
<i>Sweet's syndrome (acute febrile neutrophilic dermatosis)</i>	Acute eruption of tender erythematous plaques with vesicles, fever, and neutrophilia; classically caused by treatment with G-CSF; may involve almost any other organ system, particularly respiratory and GI tracts; also associated with pregnancy and malignancy
<i>Pyoderma gangrenosum</i>	Neutrophilic infiltration of the skin; exquisitely painful lesions; may involve almost any other organ system, associated with inflammatory bowel disease
<i>Erythema multiforme</i>	Erythematous or purpuric plaques and bullae with central clearing; involves the extremities, palms, and soles; associated with herpes simplex virus, mycoplasma, and malignancy
<i>Stasis dermatitis</i>	Dermal fibrosis and brawny edema secondary to venous incompetence; may become acutely inflamed with crusting and exudate; look for evidence or history of venous incompetence and DVT

G-CSF granulocyte colony-stimulating factor, DVT deep vein thrombosis, GI gastrointestinal, NSTI necrotizing soft tissue infection

## What Is the Most Likely Diagnosis?

In a diabetic patient presenting with a painful, erythematous, swollen leg with bullae and violaceous skin along with radiographic evidence of gas bubbles within the soft tissues of the leg, the most likely diagnosis is necrotizing soft tissue infection (NSTI).

## History and Physical

## What Is the Implication of Crepitus?

Crepitus implies the presence of gas within the tissues, most likely due to the presence of gas-forming organisms.

## What Are the Risk Factors for NSTI?

Factors that depress immunity and/or decrease tissue perfusion increase the risk for NSTI including diabetes mellitus, malnutrition, intravenous (IV) drug abuse, obesity, chronic alcohol abuse, chronic lymphocytic leukemia, chronic steroid use, renal failure, peripheral arterial disease, and cirrhosis.

## Watch Out

NSTI can also develop in postsurgical wounds, as well as following traumatic extremity injuries, particularly in association with gross wound contamination.

## What Is the Implication of Bullae? Violaceous Skin?

The presence of bullae implies partial tissue death within the layers of the skin that allows for the collection of fluid between tissue layers. Violaceous skin (a violet or purple discoloration) implies ischemia.