

BRACKMANN  
SHELTON  
ARRIAGA

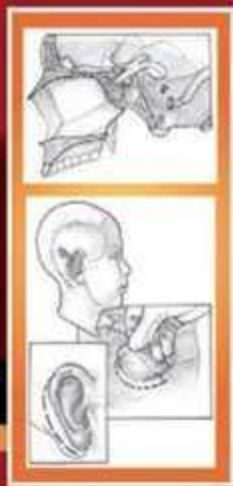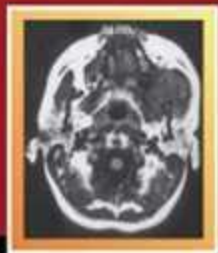
# OTOLOGIC SURGERY

3<sup>rd</sup>  
Edition

BRACKMANN • SHELTON • ARRIAGA

OTOLOGIC  
SURGERY

3<sup>rd</sup>  
Edition



SAUNDERS

SAUNDERS  
ELSEVIER

Copyrighted Material

**SAUNDERS**  
ELSEVIER

1600 John F. Kennedy Blvd.  
Ste 1800  
Philadelphia, PA 19103-2899

OTOLOGIC SURGERY

ISBN: 978-1-4160-4665-3

Copyright © 2010, 2001, 1994 by Saunders, an imprint of Elsevier Inc.

**All rights reserved.** No part of this publication may be reproduced or transmitted in any form or by any means, electronic or mechanical, including photocopying, recording, or any information storage and retrieval system, without permission in writing from the publisher. Permissions may be sought directly from Elsevier's Health Sciences Rights Department in Philadelphia, PA, USA: phone: (+1) 215 239 3804, fax: (+1) 215 239 3805, e-mail: [healthpermissions@elsevier.com](mailto:healthpermissions@elsevier.com). You may also complete your request on-line via the Elsevier homepage (<http://www.elsevier.com>), by selecting "Customer Support" and then "Obtaining Permissions".

**Notice**

Knowledge and best practice in this field are constantly changing. As new research and experience broaden our knowledge, changes in practice, treatment and drug therapy may become necessary or appropriate. Readers are advised to check the most current information provided (i) on procedures featured or (ii) by the manufacturer of each product to be administered, to verify the recommended dose or formula, the method and duration of administration, and contraindications. It is the responsibility of the practitioner, relying on his or her own experience and knowledge of the patient, to make diagnoses, to determine dosages and the best treatment for each individual patient, and to take all appropriate safety precautions. To the fullest extent of the law, neither the Publisher nor the Editors assume any liability for any injury and/or damage to persons or property arising out of or related to any use of the material contained in this book.

The Publisher

**Library of Congress Cataloging-in-Publication Data**

Otologic surgery / [edited by] Derald E. Brackmann, Clough Shelton, Moisés A. Arriaga. — 3rd ed.

p. ; cm.

Includes bibliographical references and index.

ISBN 978-1-4160-4665-3

1. Ear—Surgery. I. Brackmann, Derald E. II. Shelton, Clough. III. Arriaga, Moises A.  
[DNLM: 1. Ear—surgery. 2. Otologic Surgical Procedures. WV 200 O878 2010]

RF126.O87 2010

617.8'059—dc22

2009032119

*Acquisitions Editor:* Stefanie Jewell-Thomas  
*Developmental Editor:* Rachel Yard  
*Project Manager:* Jagannathan Varadarajan  
*Design Direction:* Ellen Zanolle  
*Publishing Services Manager:* Hemamalini Rajendrababu

Printed in the United States of America

Last digit is the print number: 9 8 7 6 5 4 3 2 1

Working together to grow  
libraries in developing countries

[www.elsevier.com](http://www.elsevier.com) | [www.bookaid.org](http://www.bookaid.org) | [www.sabre.org](http://www.sabre.org)

ELSEVIER



BOOK AID  
International

Sabre Foundation

# Dedication

This book is dedicated to our mentors and teachers, Drs. Howard P. House, William F. House, and James L. Sheehy. Each of these outstanding physicians has special talents and characteristics that, when melded together, resulted in an outstanding clinical, research, and educational facility, The House Ear Clinic and Institute. Regrettably, Drs. Howard House and James Sheehy have passed away since the publication of the previous edition of this book.


Howard House, the founder of our institution, was among the first to concentrate his activities in the field of otology. He devoted his career to the treatment of otosclerosis. In addition to his surgical genius, Howard was recognized as an outstanding statesman and fundraiser. Without him the House Ear Institute, which has provided so many opportunities for all of us, would not exist. He died in 2003 at the age of 95. At the time of his death, he was still coming to the office regularly and was active in development work for the Institute.



William F. House joined his brother in practice after completing his residency. A creative genius, Bill recognized that the future of otology lay in the diagnosis and treatment of diseases of the inner ear. He introduced the operating microscope and microsurgical techniques to the field of neurosurgery and revolutionized the treatment of acoustic tumors and other neurotologic problems. Bill is also recognized as instrumental in bringing the cochlear implant to the state of a practical clinical device that is now widely applied. Bill is now retired from clinical practice but, at the age of 86, remains extremely creative and is currently pursuing a number of new innovations in otology and audiology.

The final link in the chain that resulted in the success of the House Ear Clinic and Institute was Dr. James L. Sheehy. His special interest was in the field of chronic otitis media. In addition to his outstanding surgical ability, Jim possessed exceptional talent in organizational ability and teaching. Jim was responsible for developing all the patient educational materials as well as serving as the editor for all of the many publications produced by members of the House Ear Clinic. His course development, panel discussions, and slide preparation techniques became standards for our specialty. Jim had been a member of the House Ear Clinic for 48 years and died in 2006.

It was our great privilege to be under the personal tutelage of each of these outstanding men. In addition to all the attributes enumerated above, first and foremost each was an outstanding physician. They practiced the art and science of surgery in the finest fashion, making it most appropriate that this book on surgical technique be dedicated to them.




*Derald E. Brackmann, MD*  
*Clough Shelton, MD*  
*Moisés A. Arriaga, MD*

## In Memoriam

---

On October 19, 1996, the field of otology lost one of its most influential leaders of modern times. Harold Frederick Schuknecht, MD, Professor Emeritus of the Department of Otology and Laryngology at the Harvard Medical School and Chief Emeritus of the Department of Otolaryngology at the Massachusetts Eye and Ear Infirmary, was a world-renowned clinical otologist, otopathologist, teacher, and scholar. His contribution to human otopathology is unparalleled. His book, *Pathology of the Ear*, which he solely authored, is without question the most complete and comprehensive thesis on the subject. His clinical approach and technical innovations were based on scientific principle, and he unabashedly held others to the same standard. His influence as a teacher and role model is evidenced by the unprecedented number of his students who have followed in his footsteps and have risen as leaders in our specialty. Through his life's work and through the lives of those he has touched, his influence lives on.



**Harold Frederick Schuknecht**



**Mendell Robinson**

Mendell Robinson, MD, known for his eponymous stapes prosthesis, passed away on September 29, 2007. A sketch on a napkin during an air flight in 1960 led to the development of this popular and successful prosthesis. Dr. Robinson was an internationally renowned otosclerosis surgeon and had a successful otologic practice in Providence, Rhode Island, for almost 50 years. He was so appreciated that the mayor of Providence officially declared “Mendell Robinson Day” on two separate occasions. We have chosen to leave his chapter unchanged from the previous edition.

As this edition of *Otologic Surgery* was going to press, we were saddened by the sudden death of our dear colleague Antonio De la Cruz. He succumbed to a malignant lymphoma after a very brief illness.

Antonio was a member of the House Ear Clinic and Institute for 34 years and director of the Institute's Department of Education. He directed hundreds of temporal bone dissection courses at the Institute and was responsible for teaching otologic surgery to thousands of physicians. His colleagues recognized him by election to the presidency of the American Academy of Otolaryngology–Head and Neck Surgery and the American Otologic Society.

Antonio participated in more national and international courses than any physician in the history of our specialty. All of us marveled at his tireless energy, which allowed him to travel at least on a monthly basis to courses around the world. In addition to his teaching activities, Antonio maintained an active otologic and neurotologic practice, benefiting many patients with his expertise. He contributed greatly in many areas, particularly in the surgical correction of congenital atresia of the external auditory canal. His techniques are described in the chapter that he contributed to this volume.

A former House Fellow wrote the following: “I am saddened to hear of Antonio's passing. He had a unique ability to encourage others to perceive the skills of the expert to be achievable by them. His humble style, though, belied a high level of skill and savvy. His focused energy, his keen intellect, and his eagerness to teach all made him a great mentor and colleague, roles that touched so many of us over the last 30+ years. I am sure many, many will miss him but will forever cherish the perspective, skills, and tips he gave so freely. His contributions will live on.”



**Antonio De la Cruz**

# Contributors

## **Oliver F. Adunka, MD**

Assistant Professor, Department of Otolaryngology–Head and Neck Surgery, University of North Carolina School of Medicine, Chapel Hill, North Carolina

*Translabyrinthine Vestibular Neurectomy*

## **Moisés A. Arriaga, MD, MBA, FACS**

Clinical Professor of Otolaryngology and Neurosurgery, and Director of Otology and Neurotology, Department of Otorhinolaryngology–Head and Neck Surgery, Louisiana State University Health Science Center, New Orleans; Medical Director, Hearing and Balance Center, Our Lady of the Lake Regional Medical Center, Baton Rouge, Louisiana

*Malignancies of the Temporal Bone—Limited Temporal Bone Resection; Mastoidectomy—Canal Wall Down Procedure; Overview of Transtemporal Skull Base Surgery; Surgery for Glomus Tumors and Other Lesions of the Jugular Foramen; Anterior and Subtemporal Approaches to the Infratemporal Fossa*

## **Gregory A. Ator, MD**

Associate Professor, Department of Otolaryngology–Head and Neck Surgery; Director, Division of Otology/Neurotology, University of Kansas Medical Center, Kansas City, Kansas

*Traumatic Facial Paralysis*

## **James E. Benecke, Jr., MD**

Clinical Professor, Otolaryngology–Head and Neck Surgery, St. Louis University School of Medicine; Section Chief, Otolaryngology, Missouri Baptist Medical Center; Director, Otology Associates, Inc. St. Louis, Missouri

*Otologic Instrumentation*

## **Leonard P. Berenholz, MD**

Trumbull Memorial Hospital, Department of Otolaryngology, Warren, Ohio

*Special Problems of Otosclerosis Surgery*

## **K. Paul Boyev, MD**

Assistant Professor, Department of Otolaryngology–Head and Neck Surgery; Director, Division of Otology/Neurotology, and Director, Hearing and Balance Center, University of South Florida College of Medicine, Tampa, Florida

*Cochleosacculotomy*

## **Derald E. Brackmann, MD, FACS**

Clinical Professor, Otolaryngology–Head and Neck Surgery and Neurological Surgery, University of Southern California School of Medicine; President, House Ear Clinic, and Board of Directors, House Ear Institute, Los Angeles, California

*Drainage Procedures for Petrous Apex Lesions; Surgery for Glomus Tumors and Other Lesions of the Jugular Foramen; Middle Fossa Approach; Auditory Implants for the Central Nervous System; Management of Postoperative Cerebrospinal Fluid Leaks*

## **Craig A. Buchman, MD, FACS**

Professor and Chief, Division of Otology, Neurotology, and Skull Base Surgery, Department of Otolaryngology–Head and Neck Surgery, University of North Carolina School of Medicine, Chapel Hill, North Carolina

*Translabyrinthine Vestibular Neurectomy*

## **John P. Carey, MD**

Associate Professor, Otolaryngology–Head and Neck Surgery, Johns Hopkins University School of Medicine; Attending, The Johns Hopkins Hospital, Baltimore, Maryland

*Superior Semicircular Canal Dehiscence Syndrome*

## **Ricardo L. Carrau, MD**

Professor, Departments of Neurological Surgery and Otolaryngology, University of Pittsburgh School of Medicine; Minimally Invasive EndoNeurosurgery Center and Center for Skull Base Surgery, University of Pittsburgh Medical Center, Pittsburgh, Pennsylvania

*Anterior and Subtemporal Approaches to the Infratemporal Fossa; Endoscopic Endonasal Approaches to the Skull Base and Paranasal Sinuses*

## **Stephen P. Cass, MD**

Associate Professor, Department of Otolaryngology, University of Colorado, Denver, Colorado

*Chemical Treatment of the Labyrinth*

## **Ray C. Chang, MD**

Department of Otolaryngology, University of Miami; Department of Otolaryngology, Jackson Memorial Hospital/University of Miami, Miami, Florida

*Intraoperative Neurophysiologic Monitoring*



**Douglas A. Chen, MD**

Adjunct Associate Professor of Surgery, Allegheny University of the Health Sciences; Director, Division of Neurology, Hearing and Balance Center, Allegheny General Hospital, Pittsburgh, Pennsylvania

*Dural Herniation and Cerebrospinal Fluid Leak*

**Henry H. Chen, MD, MBA**

Resident Physician, Department of Otolaryngology, University of Colorado Health Sciences Center, Denver, Colorado

*Traumatic Facial Paralysis*

**Joseph M. Chen, MD, FRCS(C)**

Associate Professor, Department of Otolaryngology, University of Toronto; Staff Surgeon, Sunnybrook and Women's College Health Science Center, Toronto, Ontario, Canada

*Middle Cranial Fossa—Vestibular Neurectomy; Transotic Approach*

**Sarah S. Connell, MD**

Neuro-otology Fellow, Department of Otolaryngology, University of Miami Ear Institute, Miami, Florida; Physician, Otolaryngology, Kaiser Permanente, Walnut Creek, California

*Intraoperative Neurophysiologic Monitoring*

**Benjamin T. Crane, MD, PhD**

Assistant Professor, Department of Otolaryngology, University of Rochester; Assistant Professor, Otolaryngology, Strong Memorial Hospital, Rochester, New York

*Superior Semicircular Canal Dehiscence Syndrome*

**Antonio De la Cruz, MD†**

Formerly Clinical Professor, Otolaryngology-Head and Neck Surgery, University of Southern California, Los Angeles, California

*Congenital Malformation of the External Auditory Canal and Middle Ear; Transcochlear Approach to Cerebellopontine Angle Lesions*

**Robert D. Cullen, MD**

Otologic Center, Inc., and Midwest Ear Institute, Kansas City, Missouri

*Surgery for Cochlear Implantation; Translabyrinthine Approach*

**Calhoun D. Cunningham III, MD**

Consultant Clinical Professor of Otolaryngology-Head and Neck Surgery, Duke University School of Medicine; Vice-President of Carolina Ear and Hearing Clinic, and Co-Director of Carolina Research Institute, Raleigh, North Carolina

*Ossicular Reconstruction*

**Shervin R. Dashti, MD, PhD**

Neurosurgical Institute of Kentucky, Norton Neuroscience Institute, Louisville, Kentucky

*Vascular Considerations in Neurotologic Surgery*

**M. Jennifer Derebery, MD**

Clinical Professor of Otolaryngology, University of Southern California School of Medicine; Staff, St. Vincent's Medical Center, and Associate, House Ear Clinic, Los Angeles, California

*Surgery of Ventilation and Mucosal Disease*

**Shaun C. Desai, MD**

The George Washington University Medical Center, Washington, DC

*Vascular Considerations in Neurotologic Surgery*

**Vivek R. Deshmukh, MD**

Director, Cerebrovascular and Endovascular Neurosurgery, Department of Neurosurgery, George Washington University, Washington, DC

*Vascular Considerations in Neurotologic Surgery*

**John L. Dornhoffer, MD, FACS**

Professor and Director, Division of Neurotology, Department of Otolaryngology-Head and Neck Surgery; Professor, Department of Neurobiology and Developmental Sciences; and Medical Director, ENT Clinic and Audiology Services, University of Arkansas for Medical Sciences, Little Rock, Arkansas

*Cartilage Tympanoplasty*

**Adrien A. Eshraghi, MD**

Associate Professor, Department of Otolaryngology, University of Miami, Miller School of Medicine, Miami, Florida

*Intraoperative Neurophysiologic Monitoring*

**Jose N. Fayad, MD**

Associate Professor, Clinical Otolaryngology, University of Southern California; Associate, Otolaryngology/Neurotology, House Ear Clinic, Los Angeles, California

*Otologic Instrumentation; Tympanoplasty—Outer Surface Grafting Technique; Auditory Implants for the Central Nervous System*

**Ugo Fisch, MD**

Professor Emeritus of Otolaryngology, University of Zurich; Head of ENT and Skull Base Surgery, University Hospital, Zurich, Switzerland

*Middle Cranial Fossa—Vestibular Neurectomy; Transotic Approach*

**David R. Friedland, MD, PhD**

Associate Professor and Chief, Division of Otolaryngology and Neuro-otologic Skull Base Surgery, Department of Otolaryngology and Communication Sciences, Medical College of Wisconsin; Attending Physician, Division of Pediatric Otolaryngology, Children's Hospital of Wisconsin; Attending Physician, Department of Otolaryngology-Head and Neck Surgery, Froedtert and The Medical College of Wisconsin Hospital, Milwaukee, Wisconsin

*Stereotactic Radiosurgery of Skull Base Tumors*

**Rick A. Friedman, MD, PhD**

Associate Professor, Otolaryngology, University of Southern California; Chief, Division of Skull Base Surgery, Cedars-Sinai Medical Center; Chief, Section on Hereditary Disorders, Cell and Biology Genetics Division, House Ear Clinic/House Ear Institute, Los Angeles, California

*Surgery of Ventilation and Mucosal Disease; Translabyrinthine Approach; Extended Middle Cranial Fossa Approach*

**Takanori Fukushima, MD, MMSc**

Consulting Professor, Department of Neurosurgery, Duke University Medical Center, Durham, North Carolina; Professor, Department of Neurosurgery, West Virginia University, Morgantown, West Virginia

*Extreme Lateral Infratemporal Transcondylar Approach for Resection of Skull Base Tumors*

**Bruce J. Gantz, MD, FACS**

Professor and Department Head, Otolaryngology-Head and Neck Surgery, University of Iowa; Professor and Department Head, Otolaryngology-Head and Neck Surgery, University of Iowa Hospitals and Clinics, Iowa City, Iowa

*Canal Wall Reconstruction Tympanomastoidectomy; Management of Bell's Palsy and Ramsay Hunt Syndrome*

**Gale Gardner, MD**

Clinical Professor, Otolaryngology/Head and Neck Surgery, Louisiana State University Health Science Center-Shreveport; Active Staff, Otolaryngology-Head and Neck Surgery, Louisiana State University Medical Center, Shreveport, Louisiana

*Tympanoplasty—Undersurface Graft Technique: Transcanal Approach*

**Paul A. Gardner, MD**

Department of Neurological Surgery, University of Pittsburgh School of Medicine, Pittsburgh, Pennsylvania

*Tympanoplasty—Undersurface Graft Technique: Transcanal Approach; Endoscopic Endonasal Approaches to the Skull Base and Paranasal Sinuses*

**Neil A. Giddings, MD**

Sacred Heart Medical Center and Deaconess Medical Center, Spokane, Washington

*Drainage Procedures for Petrous Apex Lesions*

**Michael E. Glasscock III, MD, FACS**

Adjunct Professor, Otolaryngology—Otology, Vanderbilt University Medical Center, Nashville, Tennessee

*Tympanoplasty—Undersurface Graft Technique: Postauricular Approach*

**Samuel P. Gubbels, MD**

Assistant Professor, Surgery, Division of Otolaryngology, University of Wisconsin—Madison, Madison, Wisconsin

*Canal Wall Reconstruction Tympanomastoidectomy; Management of Bell's Palsy and Ramsay Hunt Syndrome*

**Ophir Handzel, MD, LLB**

Department of Otolaryngology and Laryngology, Harvard Medical School; Fellow, Otology/Neurotology, Otolaryngology, Massachusetts Eye and Ear Infirmary, Boston, Massachusetts

*Diagnosis and Management of the Patulous Eustachian Tube*

**Steven A. Harvey, MD**

Clinical Assistant Professor, Department of Otolaryngology, Medical College of Wisconsin, Milwaukee, Wisconsin

*Complications of Surgery for Chronic Otitis Media*

**Todd A. Hillman, MD**

Adjunct Clinical Faculty, Otolaryngology, Louisiana State University, New Orleans, Louisiana; Associate, Pittsburgh Ear Associates, and Staff, Division of Neurotology, Allegheny General Hospital, Pittsburgh, Pennsylvania

*Petrosal Approach*

**William E. Hitselberger, MD**

Neurosurgery, St. Vincent's Hospital, Los Angeles, California

*Auditory Implants for the Central Nervous System*

**Barbara Stahl Hoskins, RN, BSN**

Allied Health Practitioner, Doheny Surgery, St. Vincent's Medical Center, Los Angeles; Allied Health Practitioner, Surgery, Kaiser Sunset, Hollywood; Private Scrub Nurse, Neurosurgical Department, St. Vincent's Medical Center, Los Angeles, California

*Otologic Instrumentation*



**Howard P. House, MD<sup>†</sup>**

Formerly Professor Emeritus, University of Southern California; Founder and Chairman Emeritus, House Ear Institute, St. Vincent's Medical Center, Los Angeles, California

*Total Stapedectomy*

**John W. House, MD**

Clinical Professor, Department of Otolaryngology, University of Southern California School of Medicine; President, House Ear Institute, Los Angeles, California

*Translabyrinthine Approach*

**William F. House, MD**

Formerly at Hoog Hospital, Newport Beach, California

*Middle Fossa Approach*

**Brandon B. Isaacson, MD**

Assistant Professor, Otolaryngology-Head and Neck Surgery, University of Texas Southwestern Medical Center at Dallas; Attending, Otolaryngology-Head and Neck Surgery, Zale Lipshy University Hospital, Dallas, Texas

*Office Management of Tympanic Membrane Perforation and the Draining Ear*

**Robert K. Jackler, MD**

Sewall Professor and Chair and Associate Dean (CME), Otolaryngology-Head and Neck Surgery, Stanford University School of Medicine, Stanford, California

*Retrosigmoid Approach to Tumors of the Cerebellopontine Angle*

**C. Gary Jackson, MD, FACS**

Clinical Professor, Department of Surgery, University of North Carolina School of Medicine, Chapel Hill, North Carolina

*Tympanoplasty—Undersurface Graft Technique: Postauricular Approach*

**Ivo P. Janecka, MD, FACS**

Professor, Harvard Medical School; Director, Skull Base International; Staff, Children's Hospital, Brigham and Women's Hospital, Boston, Massachusetts

*Malignancies of the Temporal Bone—Radical Temporal Bone Resection*

**Peter J. Jannetta, MD**

Professor of Neurosurgery, Department of Neurosurgery, Drexel University College of Medicine, Philadelphia; Vice Chairman, Department of Neurosurgery, Allegheny General Hospital, Pittsburgh, Pennsylvania

*Operations for Vascular Compressive Syndromes*

**Herman A. Jenkins, MD**

Professor and Chairman, Department of Otolaryngology, University of Colorado Health Sciences Center; Chief, Otolaryngology Service, University of Colorado Hospital, Denver, Colorado

*Traumatic Facial Paralysis*

**Amin B. Kassam, MD, FRCS(C)**

Associate Professor, Department of Neurological Surgery, University of Pittsburgh School of Medicine; Director, Minimally Invasive EndoNeurosurgery Center, and Co-Director, Center for Skull Base Surgery, University of Pittsburgh Medical Center, Pittsburgh, Pennsylvania

*Anterior and Subtemporal Approaches to the Infratemporal Fossa; Endoscopic Endonasal Approaches to the Skull Base and Paranasal Sinuses*

**David M. Kaylie, MD**

Associate Professor, Department of Surgery, Division of Otolaryngology, Duke University Medical Center, Durham, North Carolina

*Tympanoplasty—Undersurface Graft Technique: Postauricular Approach*

**Bradley W. Kesser, MD**

Assistant Professor, Department of Otolaryngology-Head and Neck Surgery, University of Virginia Health System, Charlottesville, Virginia

*Surgery of Ventilation and Mucosal Disease*

**Joe W. Kutz, MD**

Assistant Professor, Otolaryngology-Head and Neck Surgery, University of Texas Southwestern Medical Center at Dallas; Attending, Otolaryngology-Head and Neck Surgery, Zale Lipshy University Hospital, Dallas, Texas

*Office Management of Tympanic Membrane Perforation and the Draining Ear*

**Jed A. Kwartler, MD, MBA**

Clinical Associate Professor, Division of Otolaryngology, University of Medicine and Dentistry of New Jersey, Newark, New Jersey

*Total Stapedectomy*

**John P. Leonetti, MD**

Otolaryngology-Head and Neck Surgery, Loyola University Medical Center, Maywood, Illinois

*Malignancies of the Temporal Bone—Limited Temporal Bone Resection*

**Robert E. Levine, MD**

Clinical Professor, Ophthalmology, University of Southern California Keck School of Medicine; Co-Founder and Co-Director, Facial Nerve Clinic, House Ear Clinic, Los Angeles, California,

*Care of the Eye in Facial Paralysis*

**James Lin, MD**

Assistant Professor, Department of Otolaryngology, Louisiana State University Health Sciences Center, New Orleans, Louisiana

*Translabyrinthine Approach*

**William H. Lippy, MD, FACS**

Chief Physician/Surgeon, Otolaryngology, The Lippy Group for Ear, Nose, and Throat; Physician, Otolaryngology, Trumbull Memorial Hospital, Warren, Ohio

*Special Problems of Otosclerosis Surgery*

**Philip D. Littlefield, MD**

Otology and Neurotology, Department of Otolaryngology, Walter Reed Army Medical Center, Washington, DC

*Complications of Surgery for Chronic Otitis Media*

**Teresa M. Lo, MD**

Department of Otolaryngology, The Southeast Permanente Medical Group, Atlanta, Georgia

*Perilymphatic Fistula*

**Larry B. Lundy, MD**

Associate Professor, Otolaryngology-Head and Neck Surgery, Mayo Clinic, Jacksonville, Florida,

*Laser Revision Stapedectomy*

**William M. Luxford, MD**

Clinical Professor, Otolaryngology, University of Southern California Keck School of Medicine; Associate, House Clinic, Los Angeles, California

*Hypoglossal Facial Anastomosis Surgery for Cochlear Implantation*

**John T. McElveen, Jr., MD**

Consultant Clinical Professor of Otolaryngology-Head and Neck Surgery, Duke University School of Medicine; President of Carolina Ear and Hearing Clinic, and Director of Carolina Research Institute, Raleigh, North Carolina

*Ossicular Reconstruction*

**Michael J. McKenna, MD**

Professor of Otology and Laryngology, Department of Otology and Laryngology, Harvard Medical School; Surgeon in Otolaryngology, Department of Otolaryngology, Massachusetts Eye and Ear Infirmary, Boston, Massachusetts

*Cochleosacculotomy; Transcanal Labyrinthectomy*

**Lloyd B. Minor, MD**

Andelot Professor and Director, Department of Otolaryngology-Head and Neck Surgery, The Johns Hopkins University School of Medicine, Baltimore, Maryland

*Superior Semicircular Canal Dehiscence Syndrome*

**Edwin M. Monsell, MD, PhD**

Professor, Otolaryngology-Head and Neck Surgery, Wayne State University, Detroit, Michigan

*Chemical Treatment of the Labyrinth*

**Joseph B. Nadol, Jr., MD**

Walter Augustus Lecompte Professor and Chair, Department of Otology and Laryngology, Harvard Medical School; Chief of Otolaryngology, Department of Otolaryngology, Massachusetts Eye and Ear Infirmary, Boston, Massachusetts

*Transcanal Labyrinthectomy*

**Julian M. Nedzelski, MD, FRCS**

Professor Emeritus, Department of Otolaryngology-Head and Neck Surgery, University of Toronto; Consultant, Department of Otolaryngology-Head and Neck Surgery, Sunnybrook Health Sciences Centre, Toronto, Ontario, Canada

*Chemical Treatment of the Labyrinth*

**J. Gail Neely, MD, FACS**

Professor and Director, Otology/Neurotology/Base of Skull Surgery; Director of Research, Department of Otolaryngology-Head and Neck Surgery, Washington University School of Medicine; Attending, Otolaryngology-Head and Neck Surgery, Barnes-Jewish Hospital and St. Louis Children's Hospital, St. Louis, Missouri

*Surgery of Acute Infections and Their Complications*

**James L. Netterville, MD**

The Mark C. Smith Professor, and Director of Head and Neck Surgery, Vanderbilt Department of Otolaryngology-Head and Neck Surgery, Vanderbilt Medical Center, Nashville, Tennessee

*Rehabilitation of Lower Cranial Nerve Deficits after Neurotologic Skull Base Surgery*

**Steven R. Otto, MA**

Chief Audiologist and Coordinator, ABI Program, Department of Auditory Implants and Perception, House Ear Institute, Los Angeles, California

*Auditory Implants for the Central Nervous System*

**Mark D. Packer, MD**

Neurotology Fellow, Otolaryngology, The Ohio State University; Lieutenant Colonel, United States Air Force, Columbus, Ohio

*Surgery of the Endolymphatic Sac*

**Lorne S. Parnes, MD, FRCS(C)**

Professor, Otolaryngology and Clinical Neurological Sciences, University of Western Ontario; Site Chief, Otolaryngology, University Hospital–London Health Sciences Centre, London, Ontario, Canada

*Posterior Semicircular Canal Occlusion for Benign Paroxysmal Positional Vertigo*

**Rodney Perkins, MD**

Clinical Professor of Surgery, Stanford University, Palo Alto, California

*Canalplasty for Exostoses of the External Auditory Canal and Miscellaneous Auditory Canal Problems*

**Brian P. Perry, MD, FACS**

Clinical Associate Professor, The University of Texas, Health Science Center–San Antonio, San Antonio, Texas

*Management of Bell's Palsy and Ramsay Hunt Syndrome*

**Thomas M. Pilkington, MD**

Resident Physician, Division of Otolaryngology-Head and Neck Surgery, Department of Surgery, Duke University Medical Center, Durham, North Carolina

*Extreme Lateral Infratemporal Transcondylar Approach for Resection of Skull Base Tumors*

**Dennis S. Poe, MD**

Associate Professor, Otology and Laryngology, Harvard Medical School; Associate Surgeon, Otolaryngology, Children's Hospital, Boston, Massachusetts

*Diagnosis and Management of the Patulous Eustachian Tube*

**Sanjay Prasad, MD**

Clinical Assistant Professor, Department of Otolaryngology-Head and Neck Surgery, Georgetown University Medical Center, Washington, DC; President and Founder, Metropolitan Ear Group, Bethesda, Maryland

*Malignancies of the Temporal Bone—Radical Temporal Bone Resection*

**Daniel M. Prevedello, MD**

Department of Neurological Surgery, University of Pittsburgh School of Medicine; Minimally Invasive EndoNeurosurgery Center and Center for Skull Base Surgery, University of Pittsburgh Medical Center, Pittsburgh, Pennsylvania

*Endoscopic Endonasal Approaches to the Skull Base and Paranasal Sinuses*

**Miriam I. Redleaf, MD**

Assistant Professor, Otolaryngology, University of Chicago and University of Chicago Medical Center, Chicago, Illinois

*Management of Bell's Palsy and Ramsay Hunt Syndrome*

**Joseph B. Roberson, Jr., MD**

Stanford University Hospital, Palo Alto, and San Ramon Regional Medical Center, San Ramon, California

*Canalplasty for Exostoses of the External Auditory Canal and Miscellaneous Auditory Canal Problems; Avoidance and Management of Complications of Otosclerosis Surgery*

**Michael A. Roberts, MD**

Comprehensive Ophthalmologist, St. Vincent's Medical Center, Los Angeles, California

*Care of the Eye in Facial Paralysis*

**Mendell Robinson, MD<sup>†</sup>**

Formerly Clinical Associate Professor, Brown University School of Medicine; Senior Surgeon, Miriam Hospital, Rhode Island Hospital, Providence, Rhode Island

*Partial Stapedectomy*

**Grayson K. Rodgers, MD**

Birmingham Hearing and Balance Center, Birmingham, Alabama

*Management of Postoperative Cerebrospinal Fluid Leaks*

**Peter S. Roland, MD**

Professor and Chairman, Otolaryngology-Head and Neck Surgery, University of Texas Southwestern Medical Center at Dallas; Chief of Service, Otolaryngology-Head and Neck Surgery, Zale Lipshy University Hospital, Dallas, Texas

*Office Management of Tympanic Membrane Perforation and the Draining Ear*

**Christina L. Runge-Samuelson, PhD**

Associate Professor and Co-Director, Koss Cochlear Implant Program, Department of Otolaryngology and Communication Sciences, Medical College of Wisconsin; Division of Pediatric Otolaryngology, Children's Hospital of Wisconsin, and Department of Otolaryngology-Head and Neck Surgery, Froedtert and The Medical College of Wisconsin Hospital, Milwaukee, Wisconsin

*Stereotactic Radiosurgery of Skull Base Tumors*

**Leonard P. Rybak, MD, PhD**

Professor of Surgery, Southern Illinois University; Memorial Medical Center and St. John's Hospital, Springfield, Illinois

*Chemical Treatment of the Labyrinth*

**Barry M. Schaitkin, MD**

Professor, Department of Otolaryngology,  
University of Pittsburgh School of Medicine,  
University of Pittsburgh Medical Center Shadyside,  
Pittsburgh, Pennsylvania

*Facial Reanimation Techniques*

**Harlod F. Schuknecht, MD†**

Formerly Professor and Chairman Emeritus, Department of  
Otology and Laryngology, Harvard Medical School; Emeritus  
Chief of Otolaryngology, Department of Otolaryngology,  
Massachusetts General Hospital, Boston, Massachusetts

*Cochleosacculotomy*

**Raymond F. Sekula, Jr., MD**

Assistant Professor Neurological Surgery, Department of  
Neurological Surgery, Allegheny General Hospital, Pittsburgh,  
Pennsylvania

*Operations for Vascular Compressive Syndromes*

**Robert V. Shannon, PhD**

Adjunct Professor, Biomedical Engineering, University of  
Southern California; **Department Head, Auditory Implants and  
Perception**, House Ear Institute, Los Angeles, California

*Auditory Implants for the Central Nervous System*

**M. Coyle Shea, Jr., MD**

Associate Clinical Professor, Department of Otolaryngology-Head  
and Neck Surgery, University of Tennessee Center for the Health  
Sciences; Active Staff, Baptist Memorial Hospitals; Courtesy  
Staff, Methodist Hospitals, Memphis, Tennessee

*Tympanoplasty—Undersurface Graft Technique:  
Transcanal Approach*

**James L. Sheehy, MD†**

Formerly Clinical Professor of Surgery and Otolaryngology,  
University of Southern California School of Medicine, Los  
Angeles, California

*Tympanoplasty—Outer Surface Grafting Technique;  
Ossicular Reconstruction; Mastoidectomy—Intact Canal Wall  
Procedure; Tympanoplasty—Staging and Use of Plastic*

**Clough Shelton, MD, FACS**

C. Charles Hetzel, Jr., MD and Alice Barker Hetzel  
Presidential Endowed Chair in Otolaryngology;  
Professor, Otology, Neuro-Otology and Skull Base Surgery;  
Chief, Otolaryngology-Head and Neck Surgery, University  
of Utah; Medical Director, Otolaryngology-Head and Neck  
Surgery and Otology/Neuro-Otology Surgeon, University of  
Utah Hospital and Clinics, Salt Lake City, Utah

*Tympanoplasty—Staging and Use of Plastic; Laser  
Stapedotomy, Facial Nerve Tumors; Middle Fossa Approach*

**David W. Sim, FRCS Ed (URL)**

Clinical Tutor, University of Edinburgh, Edinburgh, Scotland

*Retrosigmoid Approach to Tumors of the Cerebellopontine  
Angle*

**George T. Singleton, MD**

Professor Emeritus, Otolaryngology-Head and Neck Surgery,  
University of Florida College of Medicine; Otolaryngology-  
Head and Neck Surgery, Shands Teaching Hospital;  
Otolaryngology-Head and Neck Surgery, Malcolm Randall  
VA Medical Center, Gainesville, Florida

*Perilymphatic Fistula*

**William H. Slattery III, MD**

Clinical Professor, University of Southern California; **Director**,  
Clinical Studies, House Ear Institute; Associate, House Ear  
Clinic, Los Angeles, California

*Implantable Hearing Devices; Neurofibromatosis*

**Carl H. Snyderman, MD**

Departments of Neurological Surgery and Otolaryngology,  
University of Pittsburgh School of Medicine;  
Minimally Invasive EndoNeurosurgery Center and  
Center for Skull Base Surgery, University of Pittsburgh  
Medical Center, Pittsburgh, Pennsylvania

*Endoscopic Endonasal Approaches to the Skull Base  
and Paranasal Sinuses*

**Robert F. Spetzler, MD**

Professor, Department of Surgery, Section of Neurosurgery,  
University of Arizona College of Medicine, Tucson; **Director**  
and J. N. Harber Chairman of Neurological Surgery, Barrow  
Neurological Institute, Phoenix, Arizona

*Vascular Consideration in Neurologic Surgery*

**Barry Strasnick, MD, FACS**

Professor and Chairman, Department of Otolaryngology-Head  
and Neck Surgery, Eastern Virginia Medical School, Norfolk,  
Virginia

*Tympanoplasty—Undersurface Graft Technique:  
Postauricular Approach*

**Christopher A. Sullivan, MD**

Assistant Professor, Otolaryngology-Head and Neck Surgery,  
Wake Forest University School of Medicine; Staff Surgeon,  
Otolaryngology-Head and Neck Surgery,  
North Carolina Baptist Hospital; Assistant Professor,  
Regenerative Medicine, Wake Forest Institute for Regenerative  
Medicine, Winston Salem, North Carolina

*Rehabilitation of Lower Cranial Nerve Deficits after  
Neurotologic Skull Base Surgery*

**Mark J. Syms, MD**

Neurologist, Section of Neurotology, Department of Neurosurgery, Barrow Neurological Institute, Phoenix, Arizona

*Mastoidectomy—Intact Canal Wall Procedure*

**Charles A. Syms III, MD**

Clinical Professor, Department of Otolaryngology-Head and Neck Surgery, University of Texas Health Science Center, San Antonio; President, Ear Medical Group, San Antonio, Texas

*Mastoidectomy—Intact Canal Wall Procedure*

**Steven A. Telian, MD**

John L. Kemink Professor of Otorhinolaryngology; Director, Division of Otolaryngology, Neurology, and Skull Base Surgery; and Medical Director, Cochlear Implant Program, Department of Otolaryngology-Head and Neck Surgery, University of Michigan, Ann Arbor, Michigan

*Retrolabyrinthine and Retrosigmoid Vestibular Neurectomy*

**Fred F. Telischi, MEE, MD, FACS**

Professor, Neurological Surgery, Biomedical Engineering, and Otolaryngology, University of Miami Miller School of Medicine; Vice Chairman and Director, University of Miami Ear Institute, Miami, Florida

*Intraoperative Neurophysiologic Monitoring*

**Karen B. Teufert, MD**

House Ear Institute, Los Angeles, California

*Congenital Malformation of the External Auditory Canal and Middle Ear; Transcochlear Approach to Cerebellopontine Angle Lesions*

**Anders M.R. Tjellström, MD, PhD**

Department of Otolaryngology, Sahlgrenska University Hospital, Göteborg, Sweden

*The Bone-Anchored Cochlea Stimulator (Baha)*

**Debara L. Tucci, MD**

Associate Professor, Division of Otolaryngology-Head and Neck Surgery, Department of Surgery, Duke University Medical Center, Durham, North Carolina

*Extreme Lateral Infratemporal Transcondylar Approach for Resection of Skull Base Tumors*

**P. Ashley Wackym, MD, FACS, FAAP**

John C. Koss Professor and Chairman, Department of Otolaryngology and Communication Sciences, Medical College of Wisconsin; Chief, Section of Otolaryngology, Division of Pediatric Otolaryngology, Children's Hospital of Wisconsin; Chief, Department of Otolaryngology-Head and Neck Surgery, Froedtert and The Medical College of Wisconsin Hospital, Milwaukee, Wisconsin; Vice President for Research, Legacy Health System, Portland, Oregon

*Stereotactic Radiosurgery of Skull Base Tumors*

**P. Daniel Ward, MD, MS**

Resident, Department of Otolaryngology-Head and Neck Surgery, University of Michigan, Ann Arbor, Michigan

*Retrolabyrinthine and Retrosigmoid Vestibular Neurectomy*

**Frank M. Warren, MD**

Assistant Professor, Otolaryngology-Head and Neck Surgery, University of Utah, Salt Lake City, Utah

*Facial Nerve Tumors*

**D. Bradley Welling, MD, PhD, FACS**

Professor and Chair, Otolaryngology-Head and Neck Surgery, The Ohio State University, Columbus, Ohio

*Surgery of the Endolymphatic Sac*

**Richard J. Wiet, MD**

Professor of Clinical Otolaryngology and Neurosurgery, Northwestern University, and Ear Institute of Chicago, Chicago, Illinois

*Complications of Surgery for Chronic Otitis Media*

**Eric P. Wilkinson, MD**

Clinical Assistant Professor of Otolaryngology, University of Southern California Keck School of Medicine; Associate, House Clinic, Los Angeles, California

*Canal Wall Reconstruction Tympanomastoidectomy; Drainage Procedures for Petrous Apex Lesions; Management of Postoperative Cerebrospinal Fluid Leaks; Hypoglossal Facial Anastomosis*

# Acknowledgements

---

Publication of a book of this scope requires a tremendous effort on the part of many, all of whom I wish to sincerely thank.

First, my thanks to my lovely wife, Charlotte, who supports all my efforts and forgave my absence for the time devoted to this project. No less supportive are our four sons, David, Douglas, Mark, and Steven, who provide diversion and pleasure by taking me hunting and fishing.

Since the publication of the second edition, four additional grandchildren have blessed Charlotte and me. Lauren, Nicholas, Sammy, Kaylee Daniel, and Megan provide immeasurable pleasure to us. What we have been told about the joy of grandparenting was underemphasized.

My associate editors, Dr. Shelton and Dr. Arriaga, worked tirelessly to bring this volume to fruition.

Anthony Pazos deserves special recognition. He spent countless hours in the temporal bone laboratory learning at first hand the various operations that he then illustrated. All the authors have appreciated his attention to detail and willingness to work with them until everything was “just right.”

The publishers have been extremely supportive throughout the development of this book. From the beginning, they made a major commitment to ensure that this volume would be of the highest quality. I wish to thank particularly Rachel Yard and Scott Scheidt.

Finally, I wish to thank our office staff, who work tirelessly on behalf of our patients and us. I would particularly like to thank Rita Koechowski, my surgery counselor, who not only schedules my surgery but also offers tremendous encouragement and support to all my patients. Her assistant, Patricia McGrath, has been a tremendous help to both of us in supporting our patients.

Finally, I wish to thank my surgical assistants, Matthew Layner and Nancy Aguilar, and my executive assistant, Cathy Weise. She maintains my focus and orientation on a daily basis, and her efforts are greatly appreciated.

DERALD E. BRACKMANN, MD

My family’s patience and support in this book and all my academic projects continues to motivate and encourage me. My wife Rosemary and children (Becca, Moi, and Toby) participated in this and my other professional activities through tolerating my time away, enduring family moves, and now even offering occasional editorial suggestions on substance and form. Moisés Agosto and Leticia are a continued inspiration.

I particularly want to thank Derald Brackmann for his mentorship and stellar example of skill in otologic surgery and graceful balance of complex competing demands. The physicians and alumni of the House Ear Clinic provide an active network of otologic innovation whose concepts serve as a thread of continuity in this book.

My Louisiana State University residents and partners have provided insightful questions and suggestions that have prompted some of the changes in this edition. Additionally, they have shown that even in the terrific upheaval of post-Katrina Louisiana, calm focus on basic principles ensures quality education and superb patient care as long as we remain flexible to use all resources available.

MOISÉS A. ARRIAGA, MD, MBA, FACS

# 1

## Otologic Instrumentation

Jose N. Fayad, Barbara Stahl Hoskins, and James E. Benecke, Jr.

Sophisticated micro-otosurgical techniques mandate that the otologic surgeon and surgical team have an in-depth understanding of the operating room (OR) layout and surgical instrumentation. This chapter describes in detail different surgical procedures. The OR setup and instruments necessary for the various types of otologic procedures are described. Appendix 1 provides a comprehensive list of instruments and equipment.

### OPERATING ROOM

The OR for otologic surgery requires features that differ from ORs used for nonotologic surgery. The following sections elaborate on the general environment of the OR designed for ear surgery. A word about the sterile field is in order. Respecting the sterile field is vital during routine otologic surgery, and takes on special significance during neurotologic procedures. Maintaining the proper environment means limiting traffic through the OR, and keeping the number of visitors to a minimum. It is preferable for observers to be in a remote room watching the procedures on video. Individuals allowed in the OR should be experienced in sterile technique and should wear jackets over scrubs so that all skin surfaces are covered (Fig. 1-1).

Before entering the OR, the patient identifies the operative site. The correct ear is marked using a marking pen. The psychological environment of the OR must be respected because many otologic procedures are performed on awake patients under local anesthesia. Members of the surgical team and visitors must use discretion when making comments during surgery.

The first piece of OR equipment to be discussed is the operating table. The surgeon must be comfortable while performing microsurgery. Adequate leg room under the table can be achieved with older OR tables by placing the patient 180 degrees opposite the usual position; in other words, the patient's head is where the feet would normally be (Fig. 1-2). Newer electric tables easily accommodate the patient and surgeon. Because most otologists spin the OR table 180 degrees after the

induction of anesthesia, the new tables allow for spinning the table without unlocking it. Nonetheless, after the patient is properly positioned, the table must be firmly locked in place.

All ORs are equipped with wall suction. Standard suction devices are acceptable for otologic surgery. It is preferable, however, to use a multiple-canister suction setup, minimizing the number of times the bottles must be emptied (Fig. 1-3). Suction systems have several locations where the amount of suction can be varied, but the surgeon should also employ a control clamp on the suction tubing on the sterile field (Fig. 1-4).

The tubing that is attached to the suction tips and suction irrigators should be highly flexible. The readily available disposable tubing is not flexible enough for microsurgery, and places awkward torque on the surgeon's hands. Suction setup problems are common in every OR. The prudent team troubleshoots the system in advance and has access to backup equipment.

Electrocautery equipment should be in a ready-to-use state on all procedures except perhaps stapes surgery. The patient must be properly grounded. It is advantageous to have unipolar and bipolar cautery on the field for all chronic ear and neurotologic procedures. Polytef (Teflon) tips are available for most cautery devices and are desirable. Surgeons have at their disposal a wide array of safe cautery devices, but they must be thoroughly familiar with these electric instruments before use.

The surgical drill is another essential piece of equipment for otologic surgery. The vast array of available drills precludes an in-depth discussion of each system. Generally, otologic drills fall into two categories: air driven and electric. There are advantages and disadvantages to each type, and most surgeons have a distinct preference based on training and experience. For surgeons using air-driven drills, it is preferable to use a central source of nitrogen to power the drill, instead of using room tanks of the gas. Using a central source eliminates the need for changing tanks during long cases.

High-speed drills capable of doing most of the bone work in the temporal bone include the Fisch, Midas Rex, and Anspach drill systems. These drills generally are





FIGURE 1-1. Observer in jacket.



FIGURE 1-3. Multiple-canister suction setup.

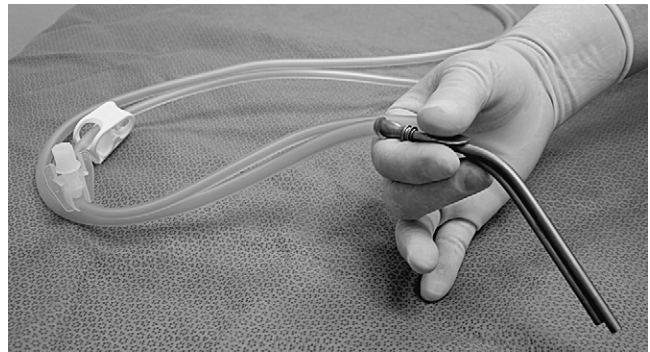

FIGURE 1-4. Suction tubing with control clamp.

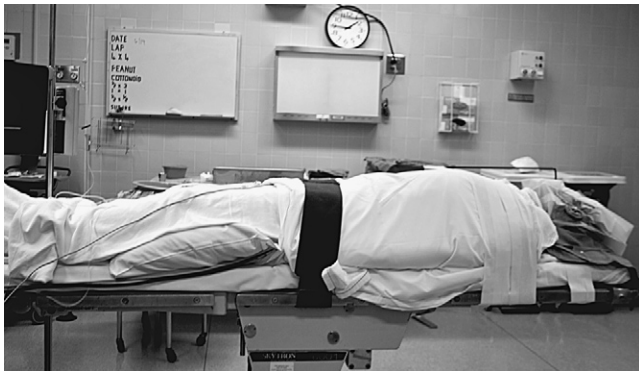

FIGURE 1-2. Operating table with patient's head at foot of bed.



FIGURE 1-5. Synergy microdrill for footplate work.

unsuitable for work in the middle ear, especially around the stapes footplate. For the latter purposes, a microdrill, such as the Skeeter drill or Synergy, is suitable (Fig. 1-5). Whatever drill is used in the middle ear, it must have a variable speed control and a wide array of drill bits.

Most larger otologic drills are equipped with straight and angled handpieces. Most surgeons prefer straight handpieces for early gross removal of the mastoid cortex, switching to angled handpieces for working deeper in the temporal bone. The Anspach drill system has a handpiece that can be converted from straight to angled simply by rotating the connection. A full complement

of cutting and diamond burs is mandatory. Figure 1-6 shows the Anspach drill system. Most drill systems have attachments that vary in shape, diameter, and length. It is the surgeon's responsibility to be intimately familiar with the drill system and to have all of the attachments and burs that might be needed.

The otologic drill should be held in the hand like a pencil, with the hand resting comfortably on the sterile field. The side of the burr should be used to provide maximum contact between the bone and the flutes of the burr, affording safer and more efficient drilling (Fig. 1-7). The newer drills are remarkably reliable, but, similar



**FIGURE 1-6.** Anspach drill system.



**FIGURE 1-7.** Proper holding of the drill.

to other tools, may malfunction. Drill systems require proper care and inspection before use. A backup system should be readily available.

The introduction of the operating microscope revolutionized otologic surgery. Most otolaryngologists are familiar with the use of the microscope. Several brands of optically superior instruments are available; most are sufficiently similar to share the same general principles.

The otologic surgeon must be familiar with the adjustments on the microscope, and must be prepared to troubleshoot the problems that may arise with the scope. The focal length of the objective lens is a matter of personal preference. Most otologists use a 200 mm or 250 mm objective. If a laser is attached to the microscope, one might consider a 300 mm objective. The objective lens should be selected, confirmed, and properly mounted before draping the microscope. Other adjustments, such as the most comfortable interpupillary distance, also should be done before the scope is draped. Par focal vision should be established so that the surgeon can change magnification without having to change focus. This is accomplished by first setting the diopter setting of both eyepieces to zero. The 40 $\times$  magnification (or highest available setting) is selected. The locked microscope

is focused on a towel using the focus knob only. Without disturbing any of the settings, the magnification is now set at 6 $\times$  (or the lowest available setting). The eyepieces are individually adjusted to obtain the sharpest possible image. The diopter readings are recorded for future use. The surgeon should have par focal vision when these appropriate eyepieces are used.

The microscope should move easily. All connections should be adjusted so that the microscope does not wander by itself, yet permits movement to any position with minimal effort. Wrestling with the microscope during microsurgery is an extreme distraction.

Proper posture at the operating table is crucial. To perform microsurgical procedures, rule number one is that the surgeon must be comfortable. The surgeon should be seated comfortably in a proper chair with the back support at the correct height. Both feet should be resting comfortably on the floor. Fatigue is avoided by assuming a restful position in the chair, rather than a rigid upright posture (Fig. 1-8).

The overall OR setup for routine otologic surgery is shown in Figure 1-9. For neurotologic surgery, more space must be available for additional equipment. Middle cranial fossa procedures require some modifications to the OR setup (Fig. 1-10). Basically, the surgeon and the microscope trade places such that the surgeon is seated at the head of the table. Cooperation and careful orchestration between the surgeon, nursing personnel, and anesthesiologist are required for otologic surgery. The needs of the otologist are best served by having the anesthesiologist at the foot of the bed and the scrub nurse opposite the surgeon. Space for the facial nerve monitoring equipment and personnel is reserved.

## STAPES SURGERY

The following description of the instrumentation and operative setup for stapes surgery also provides information useful for other middle ear procedures. Under most circumstances, it is preferable to perform stapes surgery under local anesthesia, and surgeons who do so usually employ some type of preoperative sedation. Numerous regimens are available, and their description is beyond the scope of this text. If sedation is administered by the surgeon or nursing personnel, without the assistance of an anesthetist or anesthesiologist, the agents used should be short-acting and reversible.

It is far safer for the patient to be psychologically prepared for the procedure than to be oversedated. At the House Clinic, the associates prefer to perform all local anesthesia cases (including stapes surgery) under monitored anesthesia care. This approach requires the presence of anesthesia personnel in the OR to sedate the patient, as is required for the operation, and to monitor vital functions. The surgeon is relieved from this duty, allowing total concentration on the microsurgery.

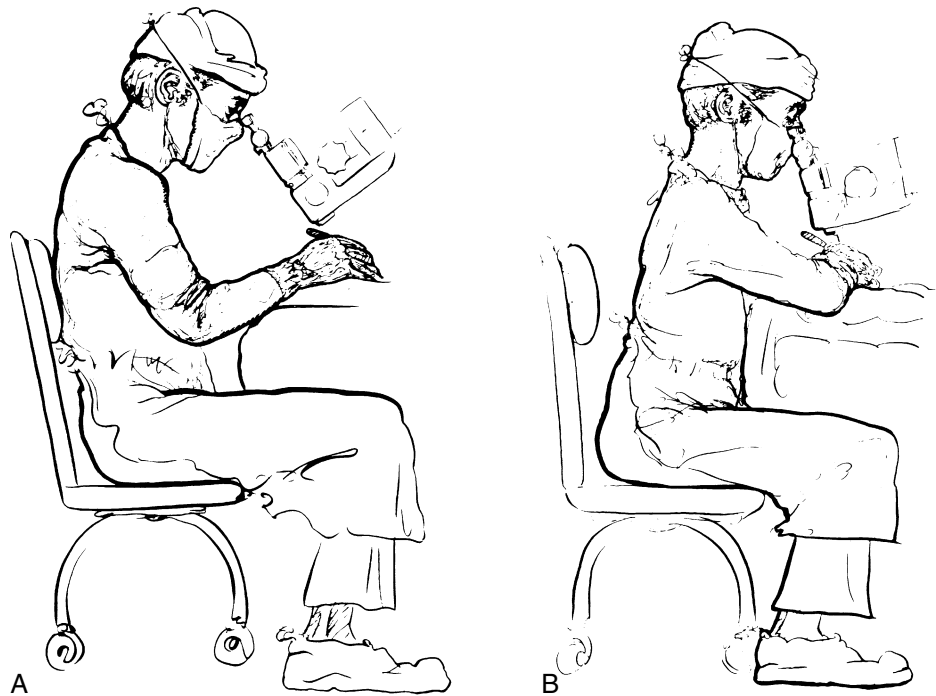

FIGURE 1-8. **A**, Proper posture for the surgeon. **B**, Wrong posture for the surgeon.

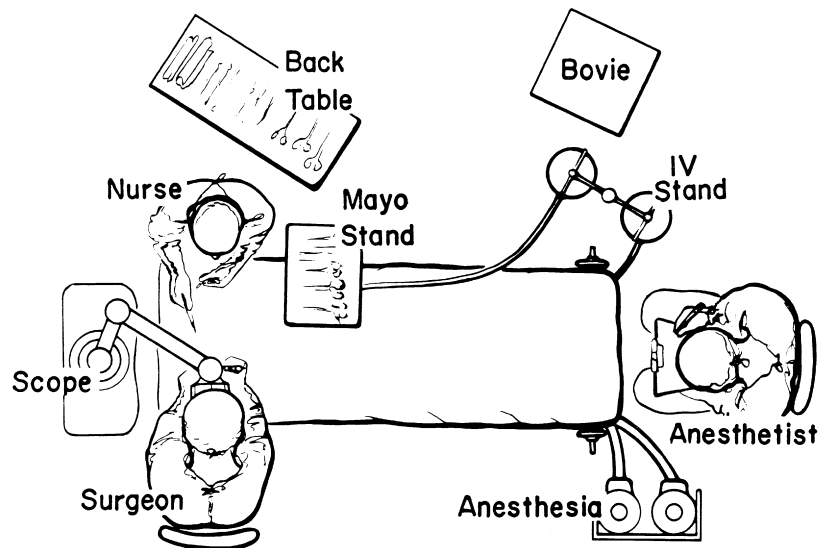


FIGURE 1-9. Usual otologic/neurotologic operating room setup.

About 30 minutes before the operation, the patient is brought to the preoperative holding area. If the surgeon routinely harvests a postauricular graft, this area is now shaved. A plastic aperture drape is applied to the operative site and trimmed so as not to cover the patient's face (Fig. 1-11). An intravenous line is started, and the patient is now ready to go to the OR. When the patient is on the OR table, the monitors are placed on the patient by the nursing or anesthesia staff. Minimal monitoring includes pulse oximetry, automatic blood pressure cuff, and electrocardiogram electrodes. The ear and plastic drape are scrubbed

with an iodine-containing solution, unless the patient is allergic to iodine. A head drape is applied, and the ear is draped with sterile towels so as not to cover the patient's face; this can be facilitated by supporting the drapes with a metal bar attached to the OR table, or by fixing the drapes to the scrub nurse's Mayo stand (Fig. 1-12).

The patient's head is now gently rotated as far away from the ipsilateral shoulder as possible, and the table is placed in slight Trendelenburg position. These maneuvers increase the surgeon's working room and help to straighten the external auditory canal (EAC). The EAC



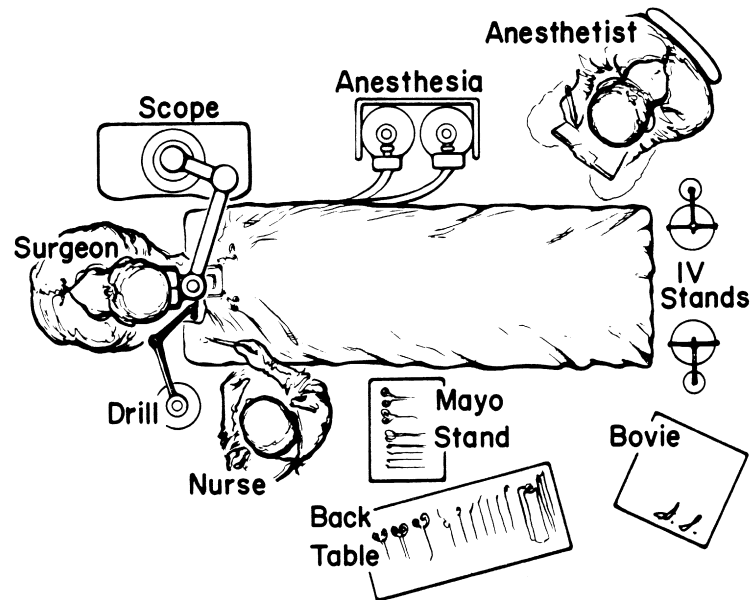


FIGURE 1-10. Operating room layout for middle fossa surgery.



FIGURE 1-11. Plastic drape applied for stapes surgery.

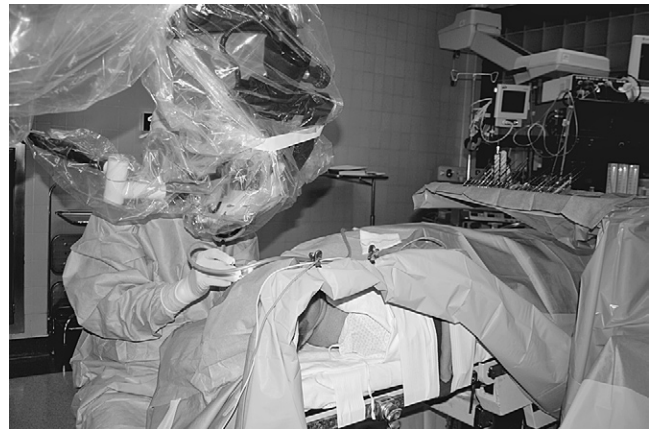

FIGURE 1-12. Patient draped in the operating room for stapes surgery.

is gently irrigated with saline heated to body temperature. Vigorous cleaning of the canal is avoided until the ear is anesthetized. The local anesthesia is administered with a plastic Luer-Lok syringe that has finger and thumb control holes. A 1½ inch, 27 gauge needle is firmly attached to the syringe. If the ear is injected slowly and strategically, excellent anesthesia and hemostasis can be achieved with a solution of 1% lidocaine with 1:100,000 epinephrine (e.g., 1:40,000). When using stronger concentrations of epinephrine, the patient's blood pressure and cardiac status must be considered, in addition to the possibility of mixing errors.

The canal is injected slowly in four quadrants starting lateral to the bony-cartilaginous junction. The final injection is in the vascular strip. If one routinely harvests fascia or tragal perichondrium, these areas are now injected.

Before describing stapes surgical instruments, a few general comments are in order. All microsurgical

instruments should be periodically inspected to ensure sharp points and cutting surfaces. The instruments for delicate work should have malleable shanks, enabling the surgeon to bend the instruments to meet the demands of the situation.

If the surgeon prefers a total stapedectomy over the small fenestra technique, an oval window seal must be selected. If fascia is used, the tissue is harvested before exposing the middle ear. The tissue is placed on a Teflon block or fascia press to dry. If perichondrium is preferred, this may be harvested immediately before footplate removal. For the small fenestra technique, a small sample of venous blood is obtained when the intravenous line is started. This blood sample is passed to the scrub nurse and placed in a vial on the sterile field.

Various ear specula should be available in oval and round configurations. Sizes typically range from 4.5 to 6.5 mm (Fig. 1-13). It is desirable always to work

through the largest speculum that the meatus permits, without lacerating canal skin. Some surgeons prefer to use a speculum holder for stapes and other middle ear procedures. The tympanomeatal flap is started with incisions made at the 6 and 12 o'clock positions with the No. 1, or sickle, knife. These incisions are united with the No. 2, or lancet, knife. This instrument actually undermines the vascular strip instead of cutting it. The strip is cut with the Bellucci scissors. The defined flap is elevated to the tympanic annulus with the large round knife, known as the large "weapon." When properly identified, the annulus is elevated superiorly with the Rosen needle, and inferiorly with the annulus elevator,




FIGURE 1-13. Speculum array.

or gimmick. Figure 1-14 shows a typical set of stapes instruments, including suction tips.

Adequate exposure usually requires removal of the bony ledge in the posterosuperior quadrant. This can be initiated with the Skeeter microdrill and completed with a stapes curette (Fig. 1-15).

From this point on, the steps differ depending on the technique preferred by the surgeon. The diagnosis of otosclerosis should be confirmed on entering the middle ear, and a measurement should be taken from the long process of the incus to the stapes footplate with a measuring stick. The next step is to make a control hole in the footplate with a sharp pick-needle (Barbara needle) or the laser. The incudostapedial joint is separated with the joint knife, the tendon is cut with scissors or laser, and the superstructure is fractured inferiorly and extracted.

For work on the footplate, the surgeon must have a variety of suitable instruments available. A stapedotomy can be created with a microdrill, laser, or needles and hooks. The 0.3 mm obtuse hook is useful for enlarging the fenestra.

For total footplate extraction, a right angle hook or excavator (Hough hoe) is used. The harvested graft is guided into place with a footplate chisel. The prosthesis is grasped with a smooth alligator or strut forceps and placed on the incus. It is positioned on the graft, or into the fenestra, with a strut guide. The wire is secured onto the incus with a crimper, or wire-closing forceps. The McGee crimper is useful, especially if followed by a fine



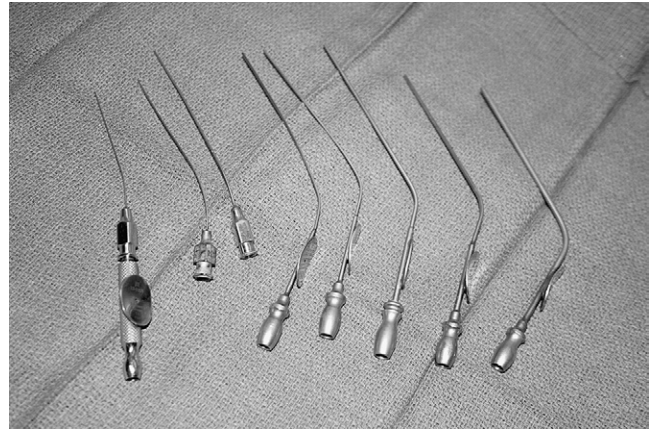


FIGURE 1-14. Stapes instruments

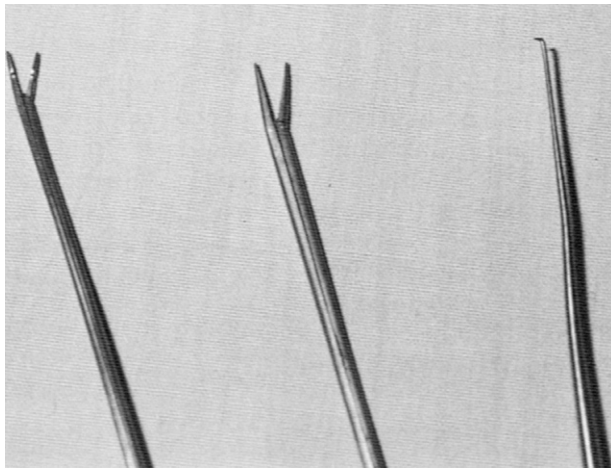




**FIGURE 1-15.** Stapes curette.



**FIGURE 1-17.** Rosen suction tubes with House adapter; Baron tubes.



**FIGURE 1-16.** Crimpers and footplate hook.

alligator forceps for the last gentle squeeze. A small right angle hook may be necessary to fine-tune the position of the prosthesis (Fig. 1-16).

Suction tubes for stapes surgery include Nos. 3 to 7 Fr Baron suction tubes plus Rosen needle suction tips (18 to 24 gauge) with the House adapter (Fig. 1-17). The Rosen tips are useful when working near the oval window, with the surgeon's thumb off the thumb port.

Ear packing after stapes surgery is accomplished with an antibiotic ointment to hold the flap in place. A piece of cotton suffices as a dressing, unless a postauricular incision has been made, in which case a mastoid dressing is applied.

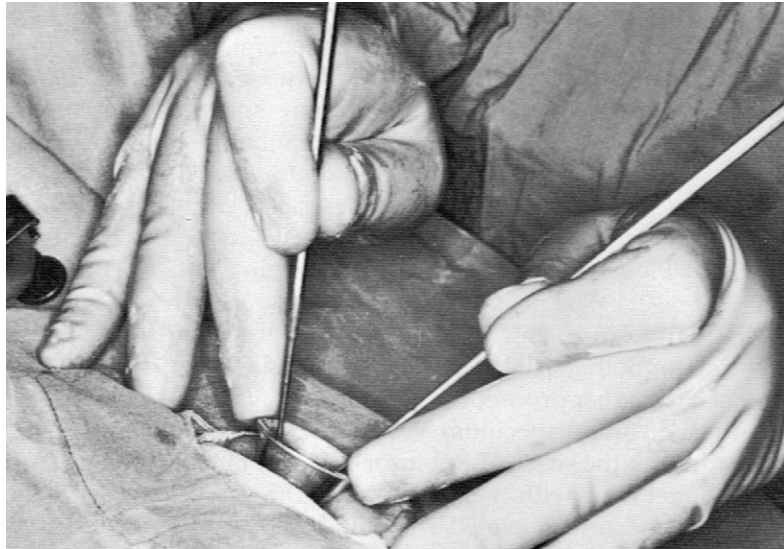
For all middle ear procedures, the surgeon should hold the instruments properly. The instrument should rest, like a pencil, between the index finger and thumb, allowing easy rotation around the shank. The hands should always be resting on the patient and the OR table. The middle and ring fingers should rest on the speculum so that the hand moves as a unit with the patient. Proper hand position and holding of instruments should afford the surgeon an unimpeded view (Fig. 1-18).

## **TYMPANOPLASTY AND TYMPANOPLASTY WITH MASTOIDECTOMY**

The preparation and draping for tympanoplasty with or without mastoidectomy are much the same as for stapes surgery. The major difference is the amount of hair shaved before draping. Usually, enough hair is shaved to expose about 3 to 4 cm of skin behind the postauricular sulcus. The plastic drape is applied to cover the remaining hair (Fig. 1-19).

The patient is positioned on the OR table as described earlier. Whether the procedure is performed under local or general anesthesia depends on the extent of the surgery, the surgeon's preference, and the desire of the patient. After appropriate sedation or induction of anesthesia, the ear and plastic drape are scrubbed with the proper soap or solution. Some surgeons place a cotton ball in the meatus if a perforation exists, preferring not to allow the preparation solution to enter the middle ear. The field is draped as described earlier, the head is rotated toward the contralateral shoulder, and the table is placed in slight Trendelenburg position (Fig. 1-20). The postauricular area, canal, and tragus (if necessary) are injected with 1% lidocaine with 1:100,000 epinephrine for local and general anesthesia cases.

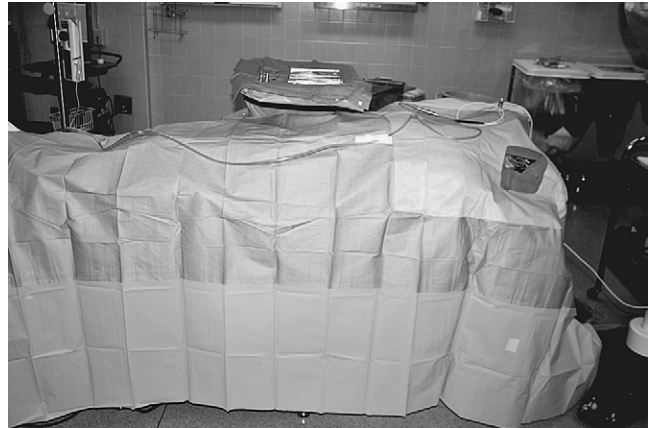Most chronic ear procedures begin in a similar fashion. Through an ear speculum, vascular strip incisions are made with the sickle or Robinson knife and united along the annulus with the lancet knife. The vascular strip incisions are completed with a No. 64 or 67 Beaver blade. This same blade can be used to transect the anterior canal skin just medial to the bony-cartilaginous junction. The postauricular incision is made with a No. 15 Bard-Parker blade behind the sulcus. The level of the temporalis fascia is identified, and a small self-retaining (Weitlaner) retractor is inserted. The fascia is cleared of areolar tissue and incised. A generous area of fascia is undermined and removed with Metzenbaum scissors. The scrub nurse can assist by using a Senn retractor to elevate skin and soft tissues away from the



**FIGURE 1-18.** Proper holding of instruments as shown by Dr. William House.



**FIGURE 1-19.** Drape (3M 1020) applied for chronic ear surgery.



**FIGURE 1-20.** Chronic ear surgery draping for local anesthesia.

fascia. The fascia is thinned on the Teflon block and dehydrated by placing it under an incandescent bulb, carefully monitoring its progress. The fascia may also be dehydrated by placing it on a large piece of Gelfoam and compressing this complex in a fascia press. [Figure 1-21](#) shows the instruments used in the initial stages of chronic ear surgery.

Continued postauricular exposure is obtained by incising along the linea temporalis with a knife or with the electrocautery. A perpendicular incision is made down to the mastoid tip. Soft tissues and periosteum are elevated with a Lempert elevator ([Fig. 1-22](#)), the vascular strip is identified, and a large self-retaining retractor is inserted. A very large retractor, such as an Adson cerebellar retractor with sharp prongs, is preferred.

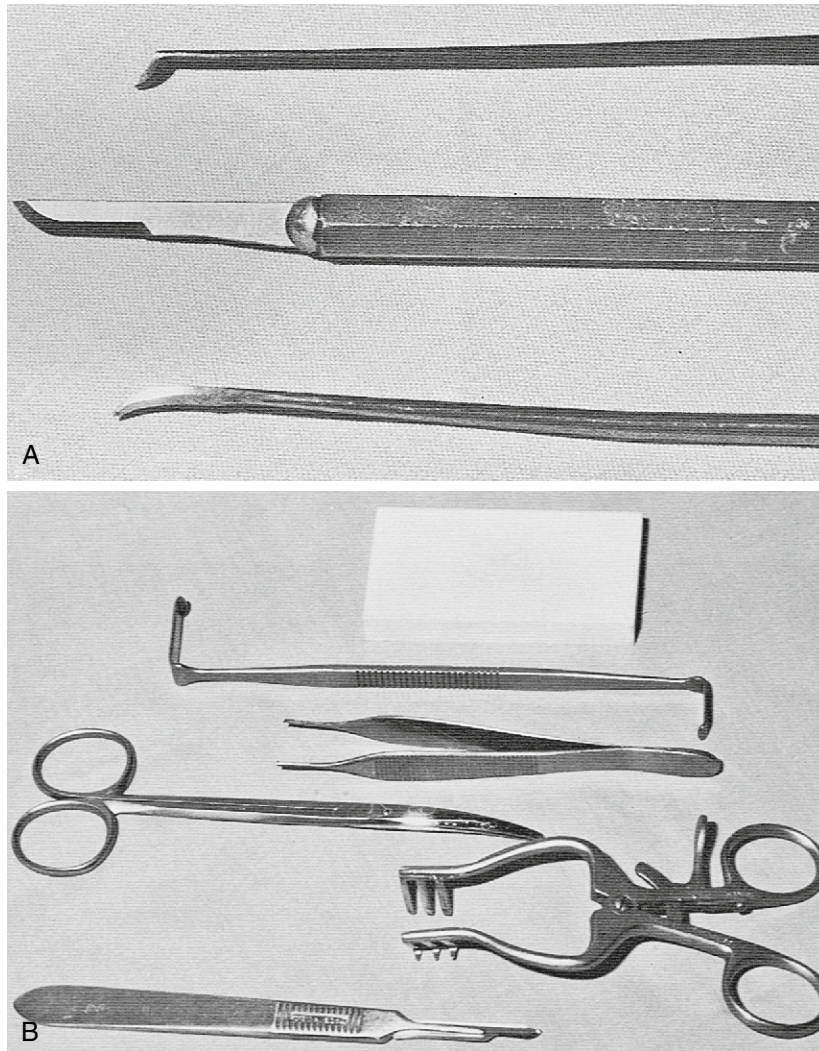
Next, under the microscope, the anterior canal skin is removed down to the level of the annulus with the large weapon. The plane between the fibrous layer of the drum remnant and the epithelium is developed with a sickle knife, and the skin is pulled free with a cup forceps. The

anterior canal skin is placed in saline for later use as a free graft. The ear canal is enlarged with the drill and suction-irrigators. An angled handpiece and medium to small cutting burr are used. Irrigation through the suction-irrigators is done with a physiologic solution such as Tis-U-Wol, lactated Ringer, or saline. Two large (3000 mL) bags of irrigant are hung and connected by way of a three-way stopcock to the delivery system ([Fig. 1-23](#)).

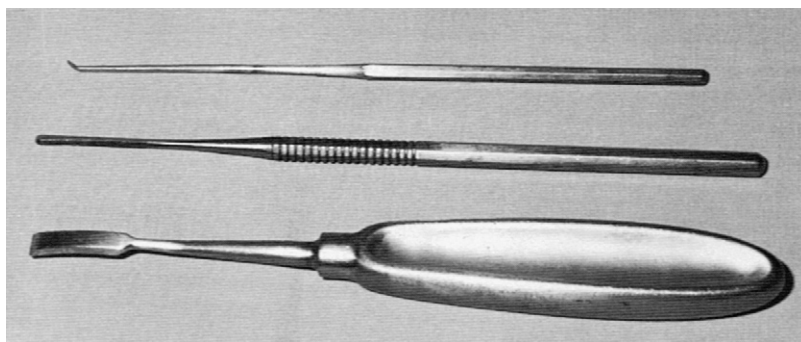
For mastoidectomy surgery, the surgeon must have a full array of cutting and diamond burrs, and a complete set of suction-irrigators. It is advisable to have bone wax and absorbable knitted fabric (Surgicel) readily available. Cholesteatoma removal can be accomplished with middle ear instruments such as the gimmick, weapon, and fine scissors.

Although the setup for closing and packing after chronic ear surgery varies with the specifics of the situation, a few generalities should cover most situations encountered by the otologist. To maintain the middle ear space, silicone elastomer (Silastic) sheeting works





**FIGURE 1-21.** A, Instruments for making a canal incision. B, Instruments for handling fascia.



**FIGURE 1-22.** Periosteal elevators.

well and is still readily available. This sheeting comes in various thicknesses, with and without reinforcement. For middle ear packing, absorbable gelatin sponge (Surgifoam) is the usual choice, soaked in saline or an antibiotic otic preparation. Surgifoam is also used to pack the EAC, although some surgeons prefer an antibiotic ointment, as described in the section on stapes surgery. For meatoplasty packing, 1-inch nonadhesive Curity packing

strip or nasal packing gauze is saturated with an antibiotic ointment and rolled around the tip of a bayonet forceps; this creates a plug that conforms to the new meatus and is easily removed (Fig. 1-24).

Wound closure is accomplished in two layers with absorbable sutures. The skin is closed with a running intradermal suture of 1-0 polyglactin 910 (Vicryl) or polyglycolic acid (Dexon) on a cutting needle. Steri-Strips are

applied, and the wound is covered with a standard mastoid dressing.

Some additional instruments that prove to be handy in many chronic ear procedures include an ossicles holder, Crabtree dissectors, Zini mirror, right angle hooks, and the House-Dieter malleus nipper (Fig. 1-25). It is impossible to describe instruments for every conceivable situation, but the foregoing should cover most of the needs of the otologist.

## ENDOLYMPHATIC SAC SURGERY

There are many well-described procedures on the endolymphatic sac. The purpose of this chapter is not to outline the surgical options, but rather to discuss the

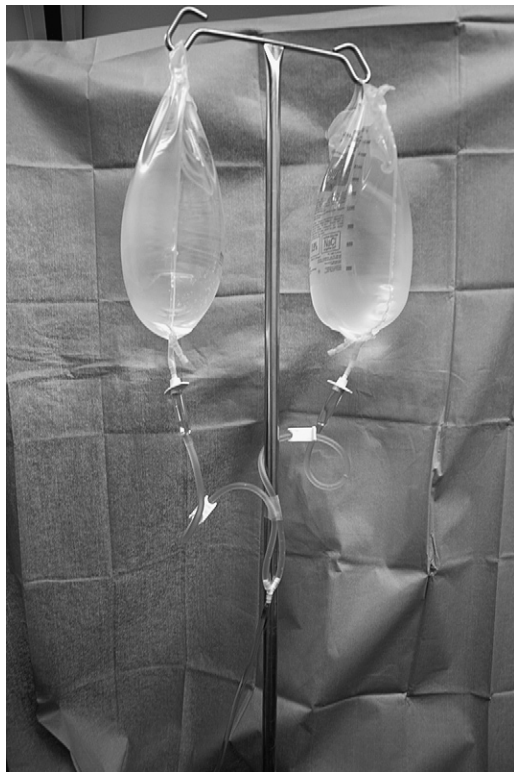

FIGURE 1-23. Suction irrigation setup.

methodology for performing sac surgery. The preparation and draping of the patient for endolymphatic sac surgery are essentially the same as for tympanoplasty with mastoidectomy surgery. In the preoperative holding area, the postauricular area is shaved, exposing at least 4 cm of skin behind the sulcus. Plastic adhesive drapes are applied, and the patient is transported to OR.

Endolymphatic sac surgery is performed under general anesthesia. The field is scrubbed in the usual manner, and the patient is positioned as described for chronic ear surgery.

This is a good time to mention briefly the use of intraoperative facial nerve monitoring and other forms of physiologic monitoring, including eighth cranial nerve and cochlear potentials. Many surgeons use facial nerve monitoring whenever the facial nerve might be in jeopardy. Electrodes for facial nerve monitoring or other forms of monitoring should be positioned before the preparation.

After the preparation for endolymphatic sac surgery, the planned incision is injected with 1% lidocaine with 1:100,000 epinephrine. The incision is made 2 to 3 cm behind the sulcus. Periosteal incisions are made sharply or with the electrocautery. A Lempert elevator elevates soft tissues and periosteum up to the level of the spine of Henle. A House narrow (canal) elevator is used to delineate the EAC, and a large self-retaining retractor is inserted. With drill and suction-irrigator, a complete mastoidectomy is performed. The antrum is *not* widely opened, but is instead blocked with a large piece of absorbable gelatin sponge (Gelfoam) to prevent bone debris from entering the middle ear.

Bone over the sigmoid sinus and posterior fossa dura is thinned with diamond burrs. The retrofacial air tract is opened widely to locate the endolymphatic sac. The sac is decompressed with a diamond burr. A stapes curette can be used to remove bone over the proximal sac. The occasional bleeding that occurs over the surface of the sac or surrounding dura is best controlled with bipolar cautery. Alternatively, unipolar cautery at a very low setting can be used. The cautery tip is touched to an insulated Rosen or gimmick that is in contact with the offending vessel (Fig. 1-26). Another

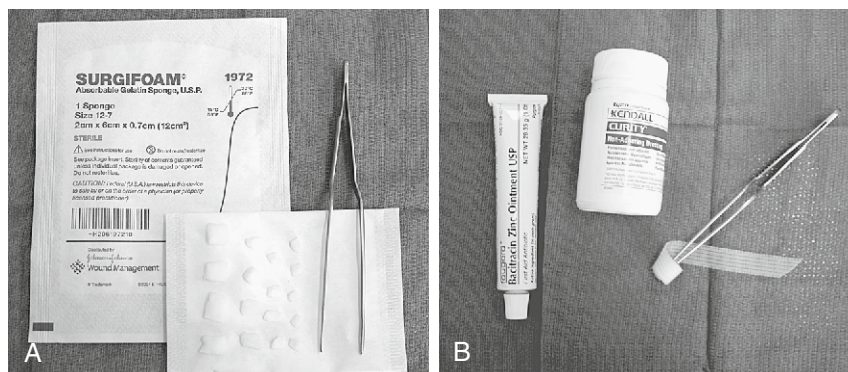
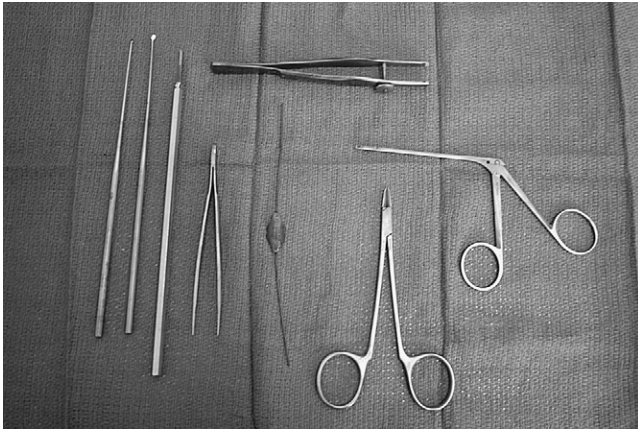
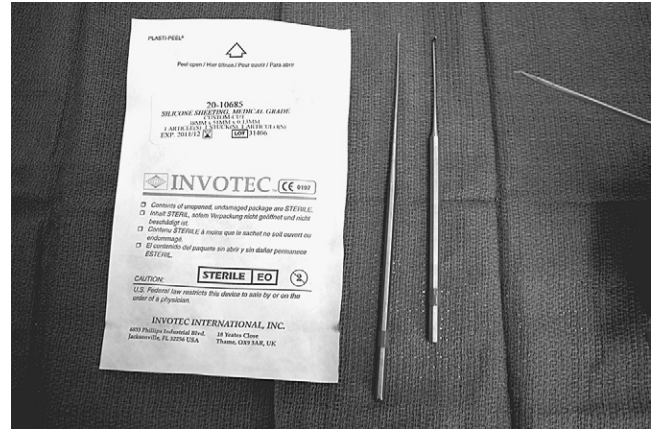


FIGURE 1-24. A, Surgifoam packing. B, Meatoplasty packing.






**FIGURE 1-25.** Additional instruments used in chronic ear procedures (see text).



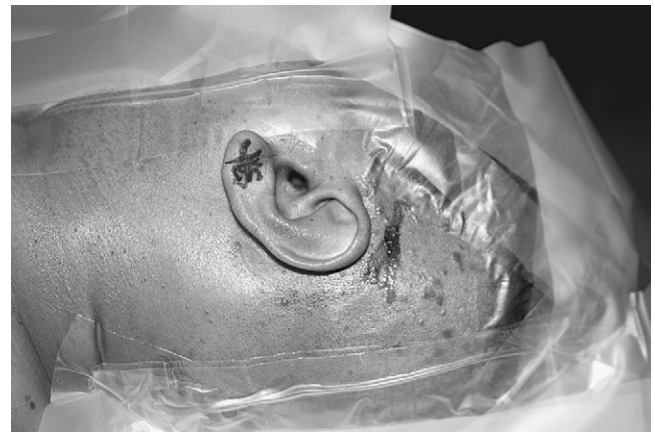**FIGURE 1-27.** Endolymphatic sac instruments and materials.



**FIGURE 1-26.** Insulated gimmick (*top*) and Rosen (*bottom*).

method used to control small areas of bleeding in endolymphatic sac and chronic ear surgery is to cover the area with pledgets of Gelfoam that have been soaked in topical thrombin.

Before opening the sac, the wound is copiously irrigated with saline or bacitracin solution. Fresh towels are placed around the field. The sac is opened with a disposable Beaver ophthalmic blade (No. 59S, 5910, or 5920). The lumen is probed with a blunt hook or gimmick. The shunt tube preferred by the surgeon is now inserted. Thin Silastic sheeting (0.005 inch) can be used to fashion a shunt. **Figure 1-27** shows the materials for the latter steps of endolymphatic sac surgery. As with chronic ear procedures, the wound is closed in layers, usually beginning with 2-0 chromic and finishing with 4-0 Vicryl or Dexon. A standard mastoid dressing is applied. This dressing either is prepared in the OR or is obtained as a prepackaged dressing (e.g., Glasscock dressing).



**FIGURE 1-28.** Drapes (3M 1000) applied for neurotologic surgery.

## NEUROTOLOGIC PROCEDURES

This section describes the OR layout for neurotologic procedures, the only exception being middle fossa surgery, which is discussed separately. For procedures involving intracranial structures, extraordinarily meticulous attention to detail is mandatory. The preparation for neurotologic surgery may begin the evening before surgery by having the patient wash his or her hair and scalp with an antiseptic shampoo. The day of surgery, the patient is seen by the surgeon in the holding area so that the ear to be operated on is positively identified. The surgical site is shaved so that at least 6 cm of postauricular scalp is exposed. The area is sprayed with an adhesive, and the plastic drapes are applied (**Fig. 1-28**). At the same time, the abdomen is shaved from below the umbilicus to the inguinal ligaments, in preparation for harvesting a fat graft. The fat donor site is surrounded by plastic drapes (**Fig. 1-29**).

After anesthetic induction, a catheter is inserted, and arterial and central venous lines are placed when indicated. Electrodes for monitoring CN VII and VIII






FIGURE 1-29. Abdominal area prepared.

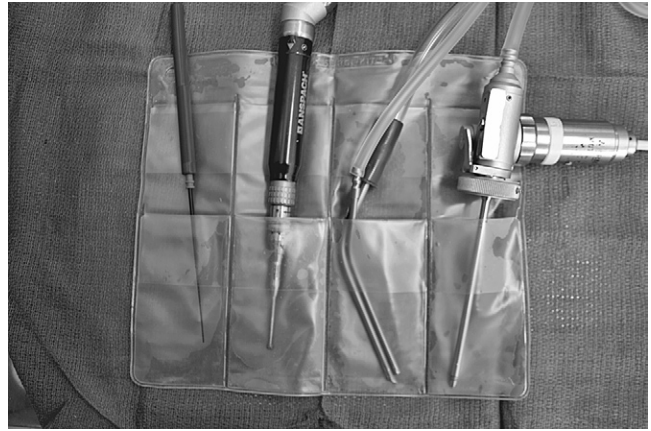

FIGURE 1-31. SK-100 Surgi-kit for holding instruments.

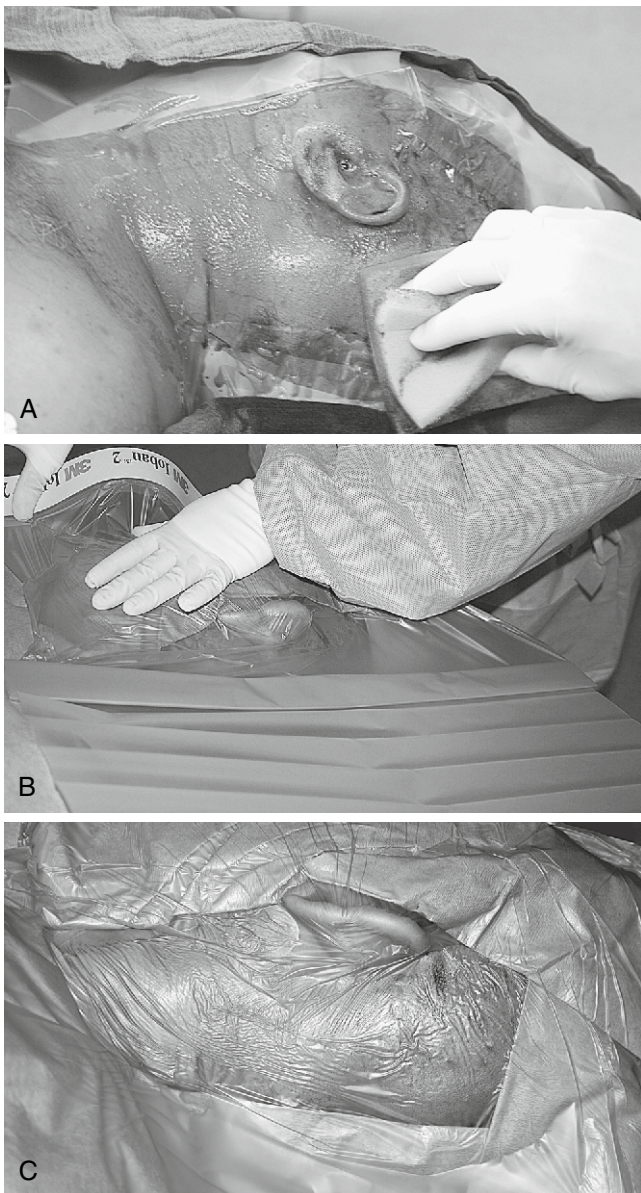


FIGURE 1-30. A-C, Draping sequence for neurotologic surgery.

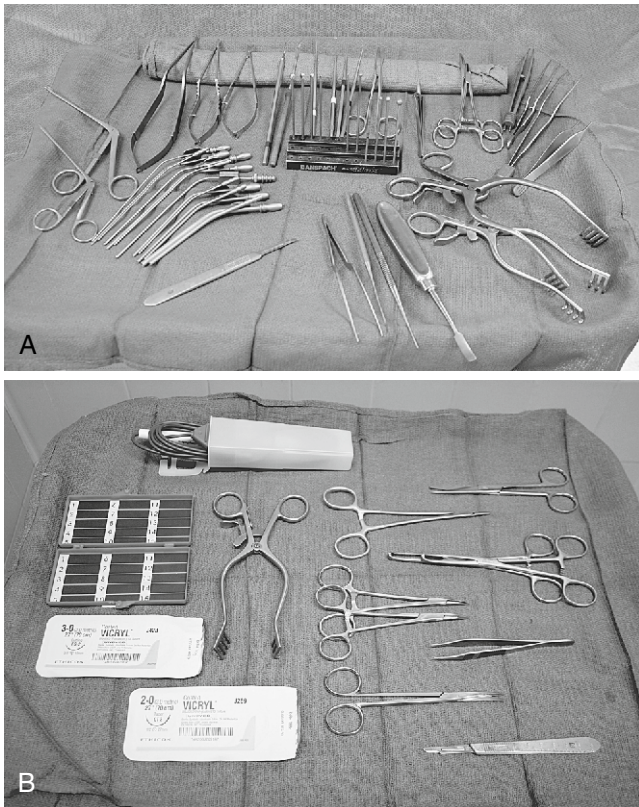
(and possibly other nerves) are positioned. The patient's head is supported on towels or a "donut" as needed, and rotated toward the contralateral shoulder. The surgical sites are scrubbed, then blotted dry with a sterile towel. The areas are draped off with towels and then covered with plastic adhesive drapes (e.g., Steri-Drape, Ioban, Cranial-Incise). Some surgeons prefer to include another layer of towels around the cranial site, followed by either sheets or a disposable split sheet. It is important to have several layers of draping to prevent saturation of the drapes with fluids down to the level of the patient (Fig. 1-30).

Because the scrub nurse must handle numerous items attached to tubes and cords, it is helpful to have fastened to the field a plastic pouch into which the drill, suction, and cautery tips can be placed (Fig. 1-31). Two Mayo stands are kept near the field: one for the neurotologic instruments and the other for the fat-harvesting tools (Fig. 1-32).

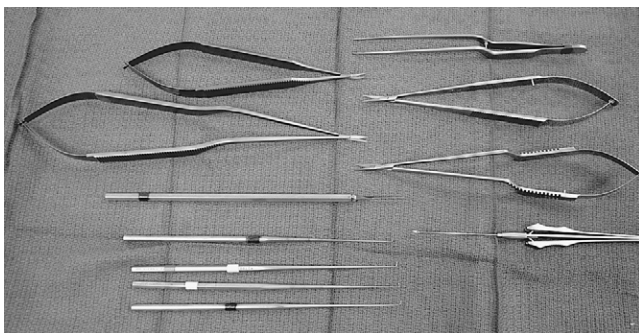
The postauricular area is injected with the usual local anesthetic, and the plastic drape is cut away with scissors to expose the mastoid and lateral subocciput. As with other procedures, a skin incision is made, hemostasis is obtained, soft tissues and periosteum are elevated, and a large self-retaining retractor is inserted. Bone removal is accomplished using a drill and suction-irrigation. For neurotologic cases, bone removal is more extensive, exposing the sigmoid sinus and a considerable amount of posterior fossa dura behind the sigmoid. It is imperative that the surgeon has immediate access to bone wax and Surgicel. Many surgeons also insist on having immediate access to hemoclips and thrombin-soaked Gelfoam.

The extent of bone removal varies depending on the surgeon's preference and the nature of the procedure. Some surgeons decompress the sigmoid completely, whereas others leave a thin shell of bone over the sinus (Bill's island). After appropriate bone removal, the retractor is removed, and the field is vigorously irrigated with bacitracin solution. Bacitracin solution can be prepared






**FIGURE 1-32.** A, Mayo stand setup for tumor. B, Mayo stand setup for fat graft.



**FIGURE 1-33.** Brackmann neurotologic instruments.

by dissolving 50,000 U of bacitracin in 1 L of normal saline. After wound irrigation, fresh towels are placed around the field.

With a wound free of bone dust and debris, the dura can now be opened with a No. 11 Bard-Parker scalpel blade or with the tips of Jacobson scissors. The dura can be pulled away from underlying structures by using a corkscrew-like instrument included in some neurotologic instrument sets (Fig. 1-33). The subdural space is entered, taking care not to violate the arachnoid; this helps to avoid injury to vessels before adequate exposure. The dural flap is carefully developed with Jacobson scissors. Hemostasis is controlled with bipolar cautery. The arachnoid is carefully opened with a sharp hook or the



**FIGURE 1-34.** Brackmann fenestrated suction-irrigators.

tips of the scissors, allowing the egress of cerebrospinal fluid. Figure 1-33 shows the instruments for dural and arachnoid opening. After opening the arachnoid, one should switch to fenestrated (Brackmann) suction tips (Fig. 1-34). The cerebellum and other intracranial structures should be protected with moist neurosurgical cottonoids. A variety of cottonoids should always be on the stand.

For vestibular neurectomy procedures, the plane between the cochlear and vestibular nerves can be developed with a blunt hook, or the gimmick. The nerve section itself can be completed with a sharp hook or microscissors (Fig. 1-35). The same instruments can be used to define the plane between an acoustic neuroma and the facial nerve. A sharp right angle hook palpates Bill's bar and sections the superior vestibular nerve fibers along with the vestibulofacial fibers. After establishing the proper plane between the tumor and facial nerve, a blunt hook is used to continue the dissection, avoiding stretching of the facial nerve. Facial nerve monitoring has greatly assisted this part of the dissection. For small tumors, the previously mentioned technique might suffice for total tumor removal. Larger tumors are removed by gutting the tumor extensively, mobilizing the capsule, and removing the capsule in a piecemeal fashion; this is accomplished by morcellizing the tumor with a large crushing forceps, such as the Decker. The Urban rotary suction-dissector is used to extract the pieces (Fig. 1-36). Bayonet forceps direct the tumor into the suction port of the Urban suction-dissector. As the tumor is gutted, the capsule collapses and can be dissected from the brainstem.

The Selector ultrasonic aspirator (Fig. 1-37) is another instrument that some surgeons prefer for gutting the tumor. Whatever tool is used, proper use of these sophisticated, potentially dangerous instruments must be learned from user manuals and appropriate training and courses.

Hemostasis is vital during neurotologic surgery, and the surgeon must have immediate access to all possible items necessary to control bleeding from whatever the source. In addition to unipolar and bipolar cautery, bone wax and pre-cut pieces of Surgicel should be on the Mayo stand. Microfibrillar collagen (Avitene) is another preferred hemostatic agent to have available. Pledgets