

SECOND EDITION

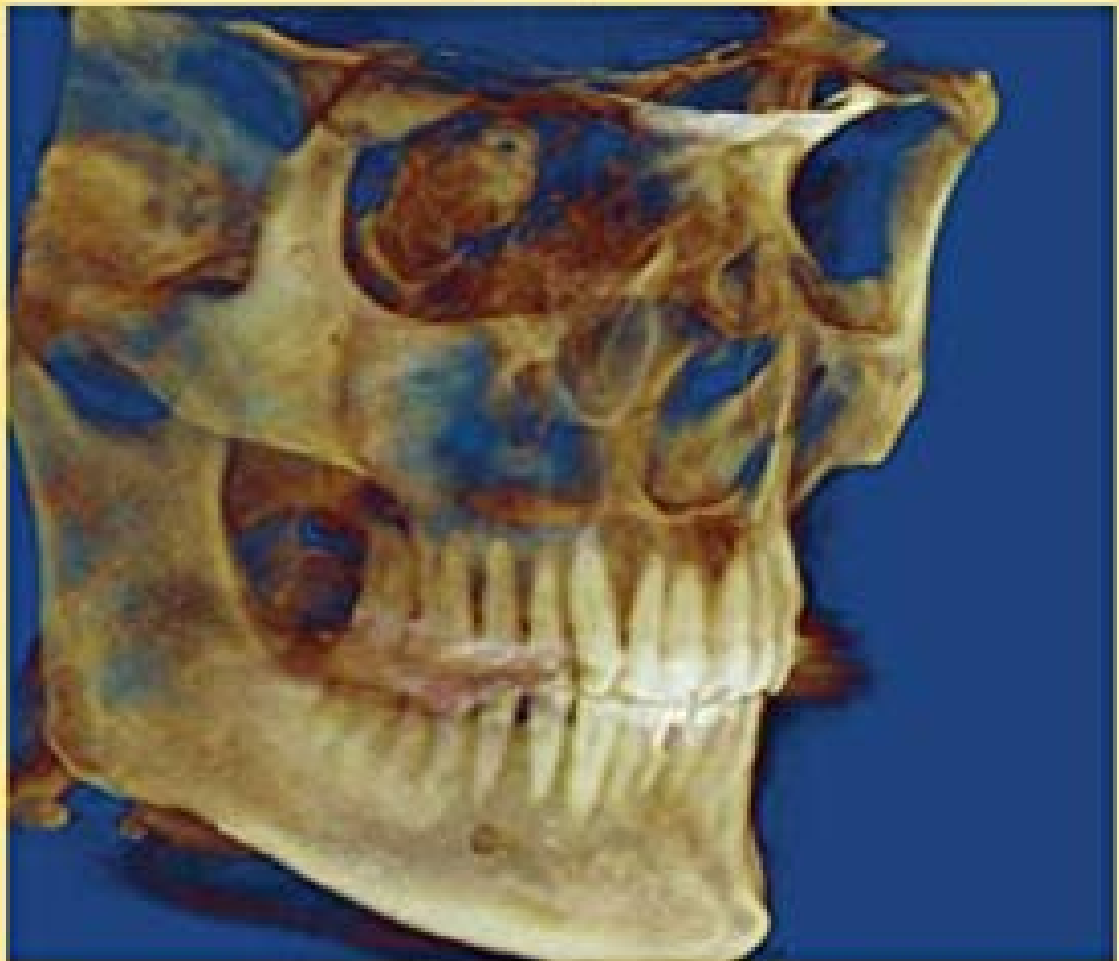
# Oral and Maxillofacial Radiology

A DIAGNOSTIC APPROACH

---

DAVID M<sup>AC</sup>DONALD

Editor



WILEY Blackwell

**ORAL AND  
MAXILLOFACIAL  
RADIOLOGY**

# ORAL AND MAXILLOFACIAL RADIOLOGY

## *A DIAGNOSTIC APPROACH*

**Second Edition**

**Edited by**

**David MacDonald BDS, BSc (Hons.), LLB (Hons.),  
MSc(Lond.), DDS (Edin.), DDRRCR, FDSRCPS, FRCDC**

Professor & Chair, Oral and Maxillofacial Radiology  
University of British Columbia  
British Columbia, Canada

**WILEY** Blackwell

This edition first published 2020  
© 2020 John Wiley & Sons, Inc.

*Edition History*

John Wiley and Sons (1e, 2011)

All rights reserved. No part of this publication may be reproduced, stored in a retrieval system, or transmitted, in any form or by any means, electronic, mechanical, photocopying, recording or otherwise, except as permitted by law. Advice on how to obtain permission to reuse material from this title is available at <http://www.wiley.com/go/permissions>.

The right of David MacDonald to be identified as the author of the editorial material in this work has been asserted in accordance with law.

*Registered Office*

John Wiley & Sons, Inc., 111 River Street, Hoboken, NJ 07030, USA

*Editorial Office*

111 River Street, Hoboken, NJ 07030, USA

For details of our global editorial offices, customer services, and more information about Wiley products visit us at [www.wiley.com](http://www.wiley.com).

Wiley also publishes its books in a variety of electronic formats and by print-on-demand. Some content that appears in standard print versions of this book may not be available in other formats.

*Limit of Liability/Disclaimer of Warranty*

The contents of this work are intended to further general scientific research, understanding, and discussion only and are not intended and should not be relied upon as recommending or promoting scientific method, diagnosis, or treatment by physicians for any particular patient. In view of ongoing research, equipment modifications, changes in governmental regulations, and the constant flow of information relating to the use of medicines, equipment, and devices, the reader is urged to review and evaluate the information provided in the package insert or instructions for each medicine, equipment, or device for, among other things, any changes in the instructions or indication of usage and for added warnings and precautions. While the publisher and authors have used their best efforts in preparing this work, they make no representations or warranties with respect to the accuracy or completeness of the contents of this work and specifically disclaim all warranties, including without limitation any implied warranties of merchantability or fitness for a particular purpose. No warranty may be created or extended by sales representatives, written sales materials or promotional statements for this work. The fact that an organization, website, or product is referred to in this work as a citation and/or potential source of further information does not mean that the publisher and authors endorse the information or services the organization, website, or product may provide or recommendations it may make. This work is sold with the understanding that the publisher is not engaged in rendering professional services. The advice and strategies contained herein may not be suitable for your situation. You should consult with a specialist where appropriate. Further, readers should be aware that websites listed in this work may have changed or disappeared between when this work was written and when it is read. Neither the publisher nor authors shall be liable for any loss of profit or any other commercial damages, including but not limited to special, incidental, consequential, or other damages.

*Library of Congress Cataloging-in-Publication Data*

Names: MacDonald, David, 1955– author.

Title: Oral and maxillofacial radiology : a diagnostic approach / David MacDonald.

Description: Second edition. | Hoboken, NJ : Wiley-Blackwell, 2020. |

Includes bibliographical references and index. |

Identifiers: LCCN 2019006680 (print) | LCCN 2019007237 (ebook) | ISBN 9781119218715 (Adobe PDF) |

ISBN 9781119218722 (ePub) | ISBN 9781119218708 (hardback)

Subjects: | MESH: Diagnostic Imaging | Stomatognathic System–pathology | Diagnosis, Oral

Classification: LCC RC78.7.D53 (ebook) | LCC RC78.7.D53 (print) | NLM WN 230 | DDC 616.07/54–dc23

LC record available at <https://lcn.loc.gov/2019006680>

Cover image: © Babak Chehroudi

Cover design: Wiley

10.5/12.5pt Slimbach by SPi Global, Pondicherry, India

To my parents, my daughters, Amy and Alicia, and my wife

# Contents

List of contributors	ix
Preface	xi
<b>Part 1 Introduction</b>	<b>1</b>
Chapter 1 Basics of radiological diagnosis	3
Chapter 2 Viewing conditions and physiological phenomena and radiological interpretation	47
Chapter 3 Evidence-based radiology	63
<b>Part 2 Advanced imaging modalities</b>	<b>73</b>
Chapter 4 Computed tomography	75
Chapter 5 Cone-beam computed tomography	89
Chapter 6 Magnetic resonance imaging	111
Chapter 7 Positron emission tomography	135
Chapter 8 Basics of ultrasound	151
<b>Part 3 Radiological pathology of the jaws</b>	<b>159</b>
Chapter 9 Radiolucencies	161
Chapter 10 Radiopacities	273
Chapter 11 Maxillary sinus	341
Chapter 12 Lesions within the soft tissues	387
Chapter 13 Imaging of the salivary glands	415
Chapter 14 Oral and maxillofacial vascular lesions	447
Chapter 15 Fractures of the face and jaws	473
Chapter 16 Temporomandibular joint diseases	493

<b>Part 4 Extragnathic lesions</b>	<b>517</b>
Chapter 17 Introduction to extragnathic lesions	519
Chapter 18 Benign lesions	529
Chapter 19 Malignant lesions	555
<b>Part 5 Osseointegrated implants</b>	<b>611</b>
Chapter 20 Osseointegrated implants	613
Index	631

# List of contributors

## **Jackie Brown**

BDS, MSc (Lond.), FDSRCPS, DDRRCR  
Senior Lecturer, Dental and Maxillofacial  
Radiologist, King's College London,  
London, UK

## **Manraj Heran**

MD, FRCPC  
President, Society for Pediatric  
Interventional Radiology  
Associate Professor, Diagnostic &  
Therapeutic Neuroradiology, Vancouver  
General Hospital  
Pediatric and Interventional Radiology,  
British Columbia's Children's Hospital,  
University of British Columbia,  
Canada

## **Pedro Lourenco**

MD, FRCPC  
Interventional Radiology Fellow,  
Department of Radiology,  
University of British Columbia  
and McGill University, Canada

## **David MacDonald**

BDS, BSc(Hons.), LLB(Hons.), MSc  
(Lond.), DDS(Edin.), DDRRCR, FDSRCPS,  
FRCDC  
Professor & Chair, Oral & Maxillofacial  
Radiology, University of British Columbia,  
British Columbia, Canada  
Senator, University of British Columbia  
Consultant, British Columbia Cancer Agency  
Regional Director (North America),  
International Association of Dento-  
Maxillo-Facial Radiology

## **Montgomery Martin**

MD, FRCPC  
Medical Director & Provincial Lead,  
Radiology, British Columbia Cancer Agency,  
Clinical Assistant Professor,  
University of British Columbia,  
British Columbia, Canada

## **Savvas Nicolaou**

MD, FRCPC  
Professor of Radiology, Vancouver  
General Hospital, University of British  
Columbia, British Columbia, Canada  
Vice Chair of CPD & Education Director  
of Emergency Trauma Imaging  
Diplomate of the American  
Board of Radiology  
Fellow of American College of  
Emergency Radiology  
Fellow of the Royal College of Surgeons  
and Physicians of Canada

## **Michael O'Keefe**

MB Bch BAO, MRCSI, FFRCRCSI  
Assistant Professor of Radiology,  
University of Toronto  
Staff Radiologist in Emergency and  
Trauma Radiology, Sunnybrook Health  
Sciences Center, Toronto, Ontario, Canada.

## **Li Ka Lun Thomas**

BDS(HK), MSc(London), DDRRCR,  
DGDP(UK), FCDSHK, FHKAM(DS),  
Private Practitioner  
Honorary Clinical Associate Professor,  
Faculty of Dentistry,  
The University of Hong Kong, Hong Kong



**Donald Wilson**

BSc, MD, FRCPC  
Provincial Lead, Functional Imaging,  
British Columbia Cancer Agency,  
Vancouver Centre  
Clinical Assistant Professor,  
Department of Surgery,  
University of British Columbia,  
British Columbia, Canada

**Jonn Wu**

BMSc, MD, FRCPC  
Fellow of the Royal College of Physicians  
and Surgeons, Canada  
Chair, Provincial Head and Neck Tumour  
Group, British Columbia Cancer Agency  
Radiation Oncologist, British Columbia  
Cancer Agency,  
Clinical Associate Professor, Faculty of  
Medicine, University of British Columbia,  
British Columbia, Canada

# Preface

The primary purpose of this second edition follows that of the first. Although now written to address the medical radiologists' needs in addition to those of dental, oral, and maxillofacial clinicians, some excerpts of reviews of the first edition reveal the core around which this edition has been built: "The purpose of this textbook is to guide diagnosticians of all skill levels in generating a diagnosis of lesions affecting the face and jaws" and it has been "thoroughly accomplished. [1]" Furthermore, "All chapters include high-quality illustrations with concise, readable legends, along with excellent decision-making flow charts to help guide the reader through the interpretive process" [1]. "The superb image quality and succinct texts make it easy to recommend to dental practitioners, maxillofacial specialists and residents embarking on their careers" [2]. This edition has increased the number of diagnostic flowcharts. Moreover, "Each topic is well referenced with current evidence-based studies and epidemiological data that can be useful in identifying radiographic lesions and developing differential diagnoses" [2].

Importantly, "This is not a traditional textbook in [oral and maxillofacial] radiology since there is an emphasis on description of high-tech imaging techniques such as CT scanning, magnetic resonance, positron emission tomography and ultrasound" [3]. This edition has not only expanded its coverage of these cross-sectional imaging modalities, but

has included interventional radiography, which here has made a substantial debut in the oral and maxillofacial textbook literature.

These developments have been accompanied by expanding the co-authorship to include leading specialists in trauma, interventional radiology, salivary gland radiology, functional imaging, and radiation oncology. The last two emphasize the continued role of the radiologist in the management and follow-up of head and neck cancers. All these innovations allow this edition to dovetail better with other texts that the dental or medical reader is likely to be familiar with, bridging the gaps between them.

This second edition also supports the continuing transition of dentists, with their traditional focus on the oral cavity, to oral physicians, who are more fully integrated into general health-care provision and enhancement of wellness. The new chapter on soft-tissue calcifications reinforces the dentists' role in the detection of possible carotid artery atheromas and details the radiologists' role in their management.

This new edition continues the first edition's harmonization of terminology between the specialties that operate in and around the face and jaws.

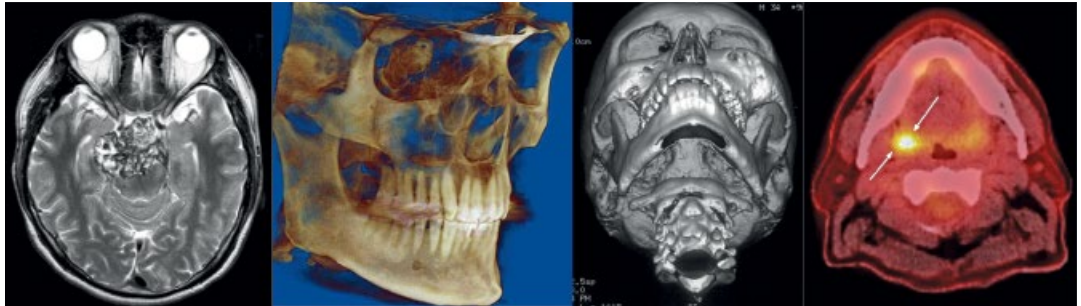In conclusion, this textbook will enable quick and accurate pattern recognition using up-to-date flowcharts, written by experts, and will translate both into the clinic and into the undergraduate's, the graduate's, and the resident's examination halls.

## **References**

1. Danforth, R.A. and Mah, J. (2012). Book review: Oral & Maxillofacial Radiology: A Diagnostic Approach. *J. Clin. Orthod.* 46: 506.
2. Tong, A. (2012). Book review: Oral & Maxillofacial Radiology: A Diagnostic Approach. *J. Oral Maxillofac. Surg.* 41: 1451.
3. Wenzel, A. (2011). A fresh innovative approach to radiology disorders. *Tandlaegebladet* Oct 6. (Danish).

# Part 1

## Introduction



## Chapter 1

# Basics of radiological diagnosis

### 1.1 Introduction

Although lesions that primarily affect the face and jaws may not hitherto have substantially impacted the practice of most radiologists save that of the head and neck specialist, the recent advent of *cone-beam computed tomography* (CBCT) and its increasingly widespread use in dentistry have begun to change this. As noted elsewhere, “The main downside of this technology’s widespread availability is that the radiological knowledge of many of the dentists who own and operate these units may not yet be adequate enough for interpretation of a CBCT dataset. Therefore, until dental education catches up, medical radiologists may be approached to interpret some datasets, particularly where the availability of oral and maxillofacial radiologists is sparse or nonexistent” [1]. Therefore, it is the primary aim of this textbook to enhance the radiological knowledge of both the radiologist and oral clinician (all dentists and oral and maxillofacial specialists), so that the former may be able to optimally assist and the latter in turn to minimize the already heavy workload of most radiologists, by referring only those cases that need a radiologist’s expertise.

Although the medical reader of this textbook, particularly the radiologist, will find much that is familiar, such as the

imaging of malignancies and those lesions immediately adjacent to the jaws, the reader will equally find that there is much that is different. This difference goes beyond simply the pre-eminence of conventional radiography in imaging disease of the face and jaws owing to the fact that much of the pathology that affects them is unique to the jaws. The three main reasons for this are set out in Table 1.1. One purpose of this textbook is to attempt to harmonize the medical and dental terminologies so as to enhance the quality of communication between clinicians to optimize patient care. To this end two new chapters have been added, one addressing vascular anomalies and the other calcifications occurring in the soft tissues. In the course of writing this second edition, the World Health Organization’s (WHO) 2017 edition on the *Classification of Head and Neck Tumours* was published [2]. Although this publication is very welcome, as it brings our understanding of lesions affecting the maxillofacial region up to date, unfortunately it has taken a step backward with regard to some important lesions peculiar to the jaws. These will be discussed at appropriate junctures, beginning later in this chapter. This edition will now be referred to as the “WHO’s 2017 edition” throughout.

Conventional radiography (CR) of the face and jaws, despite the recent advent of CBCT, is still central to diagnosis of the

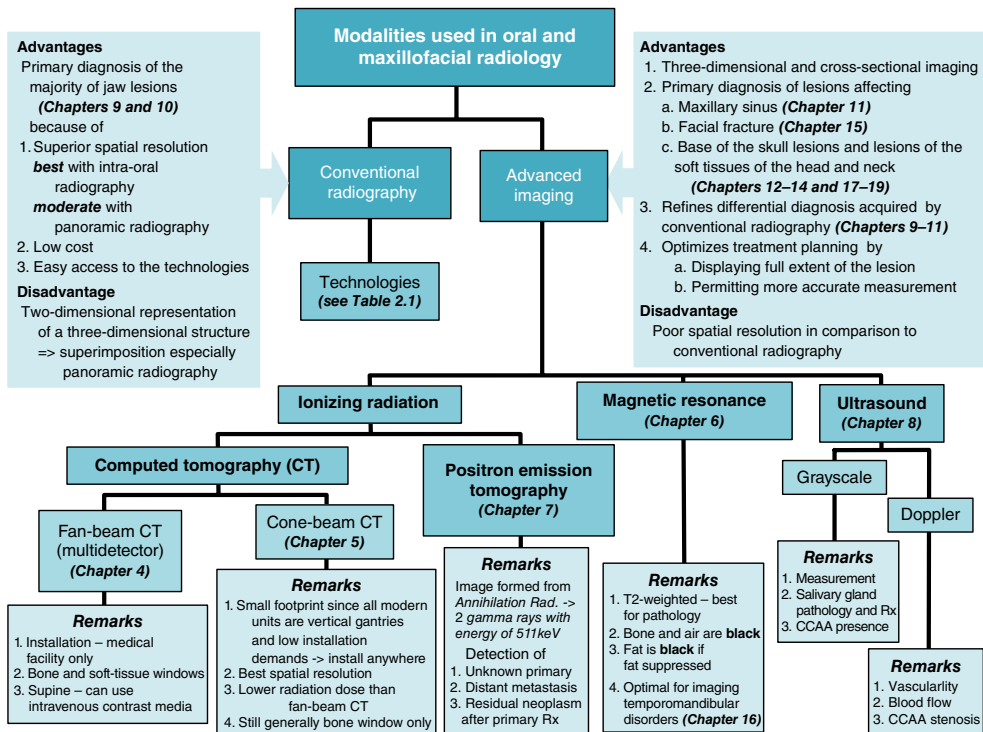
**Table 1.1** The three main differences that underline the most important and/or frequent lesions that affect the face and jaws in comparison to those in the extragnathic skeleton.

Difference	Implications
<p><b>1</b> Bones of the face and jaws come from a different origin to the extragnathic skeleton.</p>	<p>The bones of the face and jaws are derived from <b>membrane ossification</b> rather than from <b>endochondrial ossification</b> in the extragnathic skeleton. <i>This difference may explain why fibrous dysplasia occurring in the jaws is different to that of the extragnathic skeleton.</i></p>
<p><b>2</b> Epithelium is buried with the jaw bones. It is derived from two sources.</p>	<p>First, from the <b>ectoderm-covering prominences which form the face</b>. Failure of these prominences to fuse results in facial clefts, including that of the palate. <i>Epithelial rests remaining after successful fusion may result in the nasopalatine cyst, the only nonodontogenic cyst of the jaws.</i></p> <p>Second, from the <b>dental lamina from which the teeth originate</b>. From these rests are derived the odontogenic neoplasms and cysts. <i>The odontogenic neoplasms have, as observed by their higher placement in the scale of severity of outcomes in Table 1.3, an enhanced likelihood of recurrence after primary surgery.</i></p>
<p><b>3</b> The jaw bones have a unique capacity to resist infection.</p>	<p>If this were not so, nearly every dental infection that extended into the bone would result in osteomyelitis.</p>

face and jaws. Nevertheless, as exhibited in Figure 1.1, almost every imaging modality available to the medical radiologist can play its part in the diagnosis and further evaluation of a particular lesion or a patient's complaint. The radiologist can influence the selection of the appropriate modality. The radiologist will find the oral clinician appreciative, as knowledge of most advanced modalities is still limited in most dental programs. Nevertheless, the clinician, regardless of training, should have at least a basic understanding of how the image is made and the normal anatomy and its variants in order to be able to identify artifacts, particularly those that can mimic the appearance of disease. This enhances medical–dental communication. Figure 1.1 outlines the main attributes of the imaging modalities that are featured in

this textbook. These imaging modalities have been broadly divided into conventional radiography and advanced imaging.

Diagnosis in oral and maxillofacial radiology is most frequently based both on the clinical findings (including presenting complaint and history) and on the features observed on conventional radiographs. A definitive diagnosis is possible for a large proportion of lesion types that present to the primary care dentist. These lesions do not include just those lesions of inflammatory origin, mainly the sequelae of dental caries, that present as periapical radiolucencies (histologically periapical granulomas, cysts, and abscesses) or radiopacities (*condensing osteitis*), but also *dentigerous cysts* and *dense bone islands* (DBIs, also known as idiopathic osteosclerosis [IOS]). They are not only the most



**Figure 1.1** The modalities used in oral and maxillofacial radiology. This is an overview of the main imaging modalities, including remarks concerning their clearest clinical uses, relative advantages over other modalities, and limitations of use. CCAA, calcified carotid artery atheroma; keV, kiloelectron volts; Rx, recipe!, treatment.

frequently occurring lesions affecting the jaws, but a majority of them also have distinctive clinical and radiological presentations. Some other lesions such as *florid osseous dysplasia*, the *cementoblastoma*, the *compound odontoma*, and some cases of *odontogenic myxoma* can be definitively diagnosed solely on their radiological appearance. In those situations where a definitive diagnosis is not possible, a differential diagnosis should be developed. This will consist of two or more lesions. Such cases are frequently referred to a specialist as much for a diagnosis as for treatment. In order to assist readers in their diagnosis, this textbook is illustrated throughout with diagnostic flowcharts.

There is an expectation that the images created should adequately display the area of clinical interest, with the purpose of addressing those clinical questions that indicated the need for the investigations. Thus, the image or images should display the entire area of pathology and be free of artifacts. Therefore, an unerupted third molar should not only include the entire tooth and its follicle, but also at least a clear margin of 1 mm around them. This would allow the clinician to determine whether it is close to the mandibular canal or any other adjacent structure.

An example of inadequacy of radiography resulted in a Canadian dental malpractice case that continued for 12 years through at least five courts before it was concluded, presumably settled [3]. The only positive result of this failure to include only 98% of a third molar was its not insignificant contribution to Canadian law specifically and common law in general. From reading the case, it is abundantly clear that if an adequate radiograph or radiographs had been taken in the first instance, this case would have had little ground upon which to proceed, and the spilling of so much

legal ink and personal and professional distress would have been avoided.

Radiographs are prescribed for three reasons: diagnosis, presurgical planning, and follow-up. Those prescribed for the purpose of diagnosis and/or presurgical planning should be made prior to biopsy, because this can change the radiology of the lesion appreciably. This is particularly so with regard to advanced imaging such as *fan-beam computed tomography* (CT, installed in most medical hospitals) and *magnetic resonance imaging* (MRI). Two cases demonstrate the effects of biopsy prior to CT.

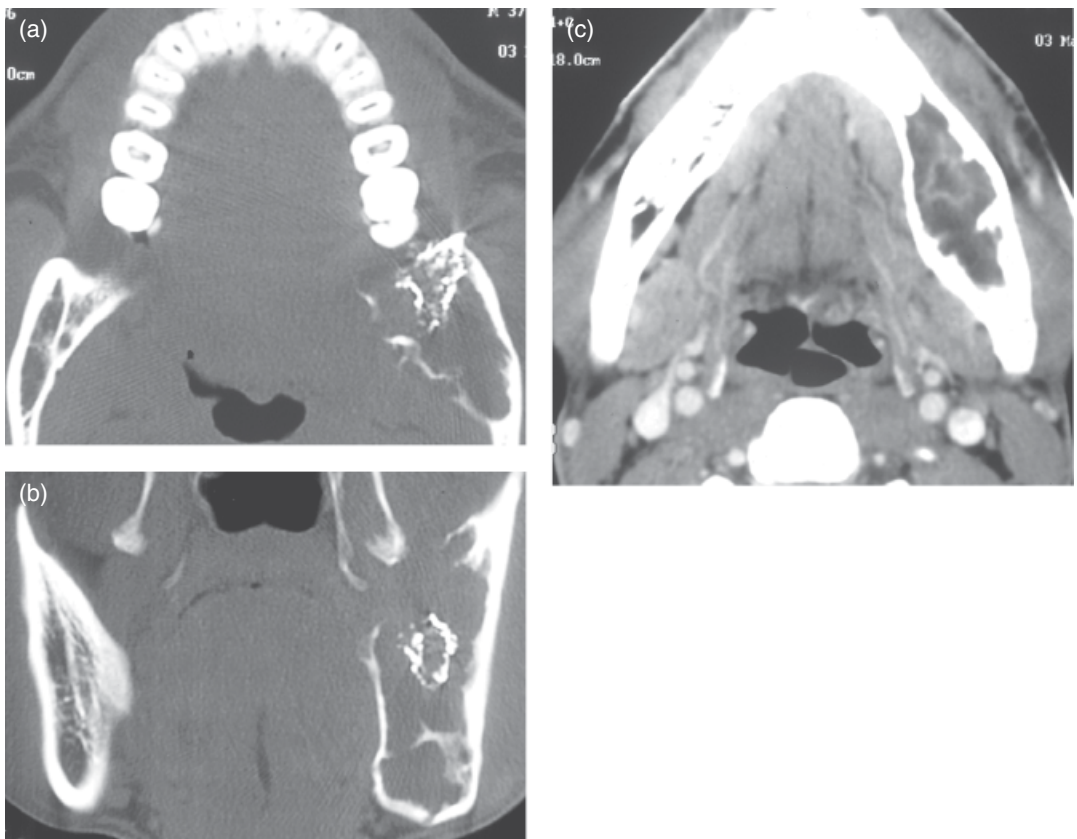The biopsy of an odontogenic myxoma, a locally invasive benign neoplasm, prior to CT, provoked an inflammatory response within the depth of the lesion, which was enhanced by the intravenous contrast (Figure 1.2). Contrast is recommended for lesions which include a neoplasm or a vascular lesion in their differential diagnosis. With regard to neoplasms, this is important to determine local invasion of adjacent soft tissues, which would need to be resected along with the rest of the neoplasm.

Figure 1.3 displays a case of *fibrous dysplasia*, which caused a substantial expansion of the affected mandible. When it was first seen by general surgeons unfamiliar with its manifestation in the jaws, they performed multiple biopsies. These biopsies created their own artifacts on a subsequent CT. These artifacts were loss of cortex and dysplastic tissue exuding through a biopsy site.

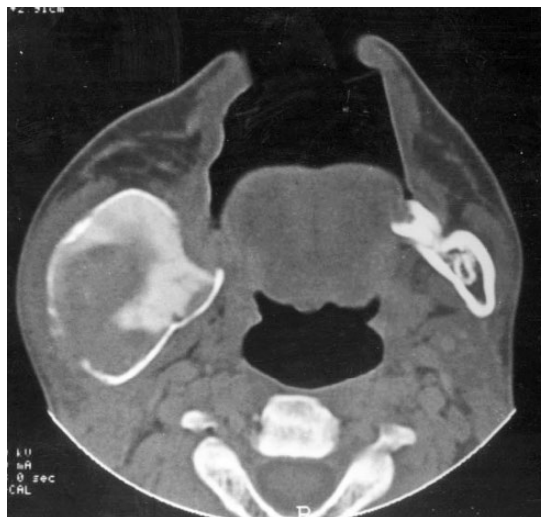## 1.2 Introduction to Conventional Radiography

All prescriptions for a radiological investigation must be based upon a thorough clinical examination. CR will be the first





**Figure 1.2** Computed tomography of an odontogenic myxoma carried out after the lesion had been biopsied. The biopsy site still has its dressing in place (a and b). As a result there was enhancement (c) by the intravenous contrast at the site biopsied that is more likely to reflect hyperemia in response to the trauma of surgery. Note: All the major blood vessels including the facial and lingual arteries are enhanced in Figure 1.2c. Source: Reproduced with permission from MacDonald-Jankowski, D.S., Yeung, R., Li, T.K., and Lee, K.M. (2004). Computed tomography of odontogenic myxoma. *Clin. Radiol.* 59: 281–287.



**Figure 1.3** Bone-window axial computed tomography of fibrous dysplasia affecting the vertical ramus of the mandible. The cortical defects are the result of several biopsies performed prior to referral for computed tomography. Such operations can largely invalidate any clinically important radiological findings because these, if erroneous, could lead to a wrong diagnosis and inappropriate treatment. Note: Radiology is very central to the diagnosis of specific fibro-osseous lesions, discussed later.

imaging modality to be prescribed to investigate further a lesion occurring within the bony jaws obvious to or suspected by the clinical history and/or examination. For the majority of lesions affecting the jaws, CR is likely to be the sole imaging modality deemed clinically necessary. The principal advantages of CR are its superior spatial resolution (especially of the intraoral technologies), low radiation dose, and low cost. It is also available in the dental office or surgery. It is most likely that this prescription will include a panoramic radiograph that may be accompanied by intraoral radiographs. These images may be in either analog (film) or digital format. An overview of the various conventional radiographic technologies is set out in Table 2.1. The panoramic radiograph permits an overview of the jaws from condyle to condyle. It also permits comparison between sides. These premises can be valid only if the patient is properly positioned within the panoramic radiographic unit, exposed by the most appropriate exposure factors, and the image is properly developed. Finally, it is also expected that the resultant image is properly reviewed (read) under optimal viewing conditions (see Chapter 2).

Although there is little, if no, place for routine radiographic screening in the modern practice of dentistry, every image should be carefully reviewed to identify any pathology that may be incidental to the patient's complaint and the results of the clinical examination. The fairly widespread practice of prescribing panoramic radiographs prior to the fabrication of complete removable prostheses in the completely edentulous patient was again recently questioned [4].

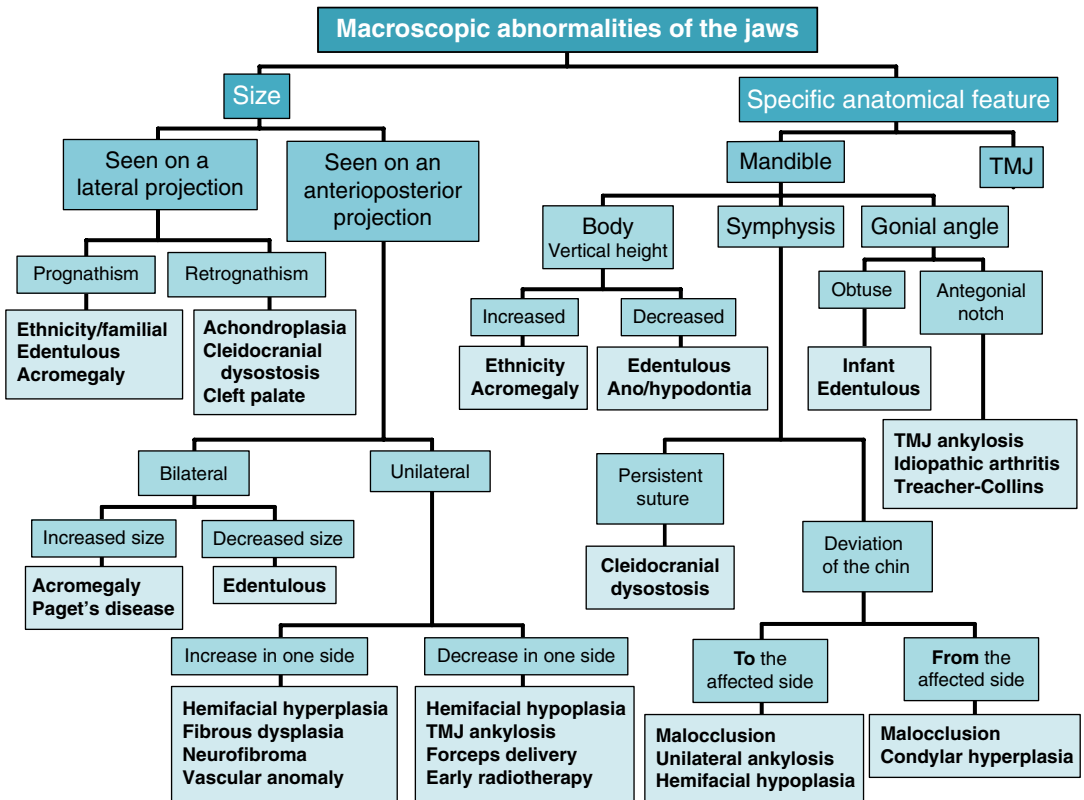
The panoramic radiograph, in addition to permitting determination of the specific features of the lesion or suspected

lesion that prompted its making, can also reveal macroscopic abnormalities such as size differences and changes in a specific anatomical location (Figure 1.4). Macroscopic anomalies (Table 1.2), such as craniofacial anomalies with or without cleft lip and palate, are now investigated by cross-sectional imaging modalities *multidetector computed tomography* (MDCT) (Figure 1.5) or CBCT (Figure 1.6). Although the use of CBCT for assessments for orthodontic reasons has so far no evidence basis, it may be called upon in the case of severe symmetry in order to facilitate optimal treatment planning. Figure 1.7 displays the results of such a case.

Medical readers will be aware that their dental colleagues will to a substantial degree be concerned with those diseases that principally affect the teeth and oral mucosa. In addition to caries and periodontal disease, some of the other important disease and radiological features the dentist will consider are set out in Figure 1.8. The reader should be aware that taurodontism, which is the increase in the vertical height of the pulp, like that observed in ungulates rather than the usual cynodont pattern of the typical human dentition, has been reported normally in some East Asian communities and is not wholly reliable as a marker of disruption in dental development [5].

Furthermore, CR can complement the clinical examination by confirming defects in the dental development, such as the number, eruption, size (Figure 1.9), and even structure of the teeth (Figure 1.10). Because these features have been fully addressed in other basic texts and are generally well understood, space constraints preclude offering images of them here.

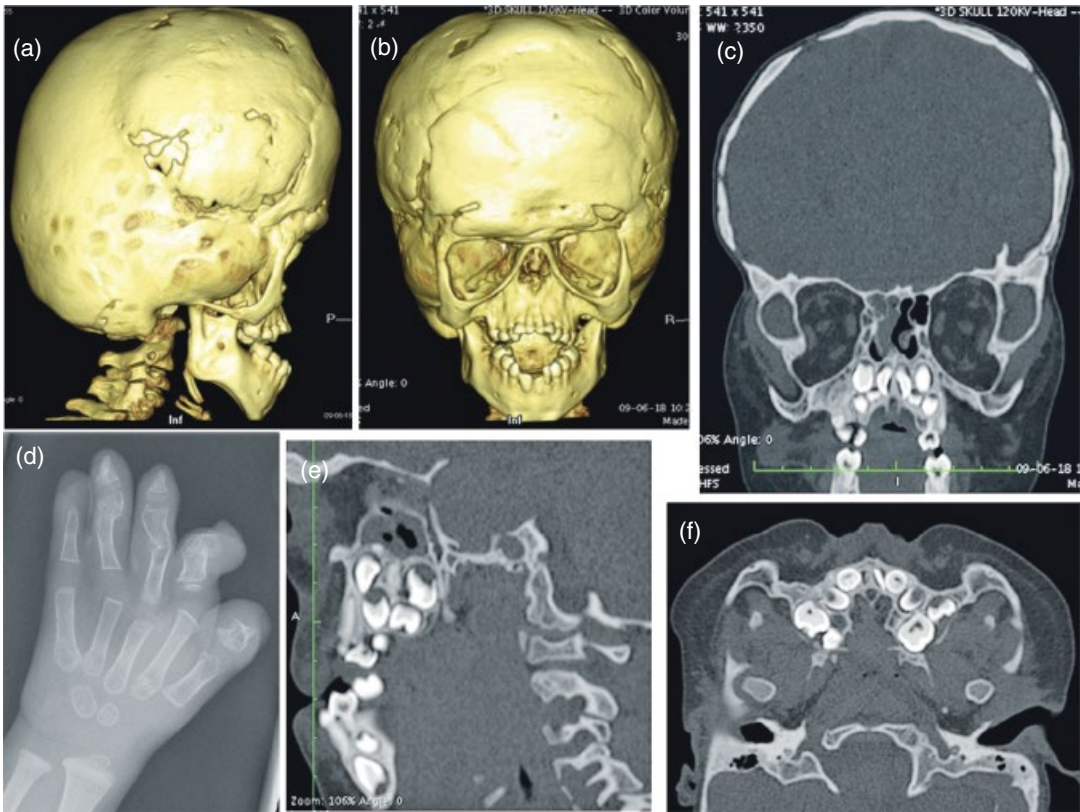
The various lesions occurring within the face and jaws often present with similar features at certain stages. Most will at some stage present as a radiolucency as they



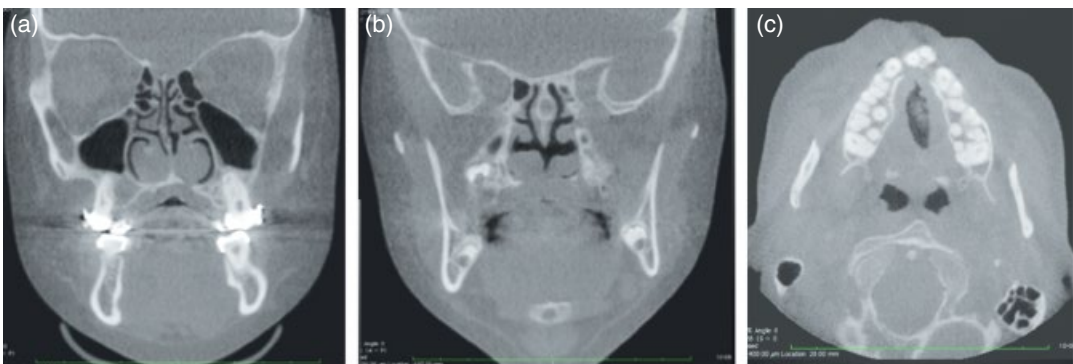**Figure 1.4** Classification of macroscopic abnormalities. TMJ, temporomandibular joint.

**Table 1.2** Classification of the main developmental syndromes that cleft or deform the face and the jaws.

		Specific feature/syndrome
Cleft lip and palate	Nonsyndromic	Bilateral cleft lip and palate
		Isolated cleft lip and palate
		Incomplete cleft lip
		Subcutaneous cleft palate
	Syndromic	22 deletion syndrome
		Stickler syndrome
		Pierre Robin syndrome
		Nevoid basal cell carcinoma syndrome
Craniofacial anomalies	Craniosynostosis	Apert syndrome
		Crouzon syndrome
		Pfeiffer syndrome
	Face and jaws alone	Hemifacial microstomia
		Facial clefting
		Moebius syndrome
		Treacher-Collins syndrome

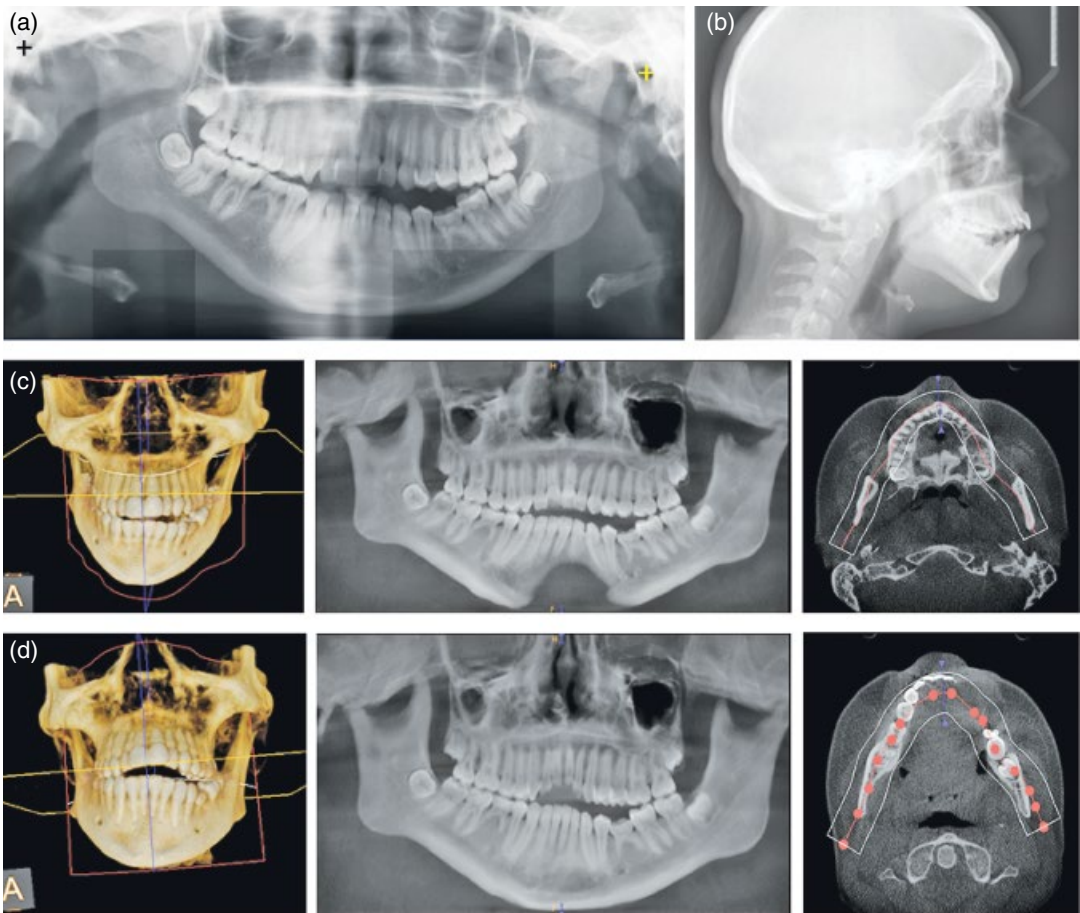


**Figure 1.5** Multidetector computed tomography and plane film of the hand of a patient with Apert's syndrome, an acrocephalosyndactyly characterized by malformations of the skull, face, hands, and feet. The first three are displayed in this figure. The coronal sutures of the skull in this case are prematurely closed, resulting in a brachycephalic skull which is short, but high (a and b). This shape is termed acrocephaly. The growing brain, though markedly constrained, is causing variable thinning of the skull (c). (d) Displays deformity of the hand. The mandible and maxilla are hypoplastic because the first brachial arch from which they develop is affected (a and b). The hypoplastic maxilla results in overcrowding of the developing teeth (c–f).

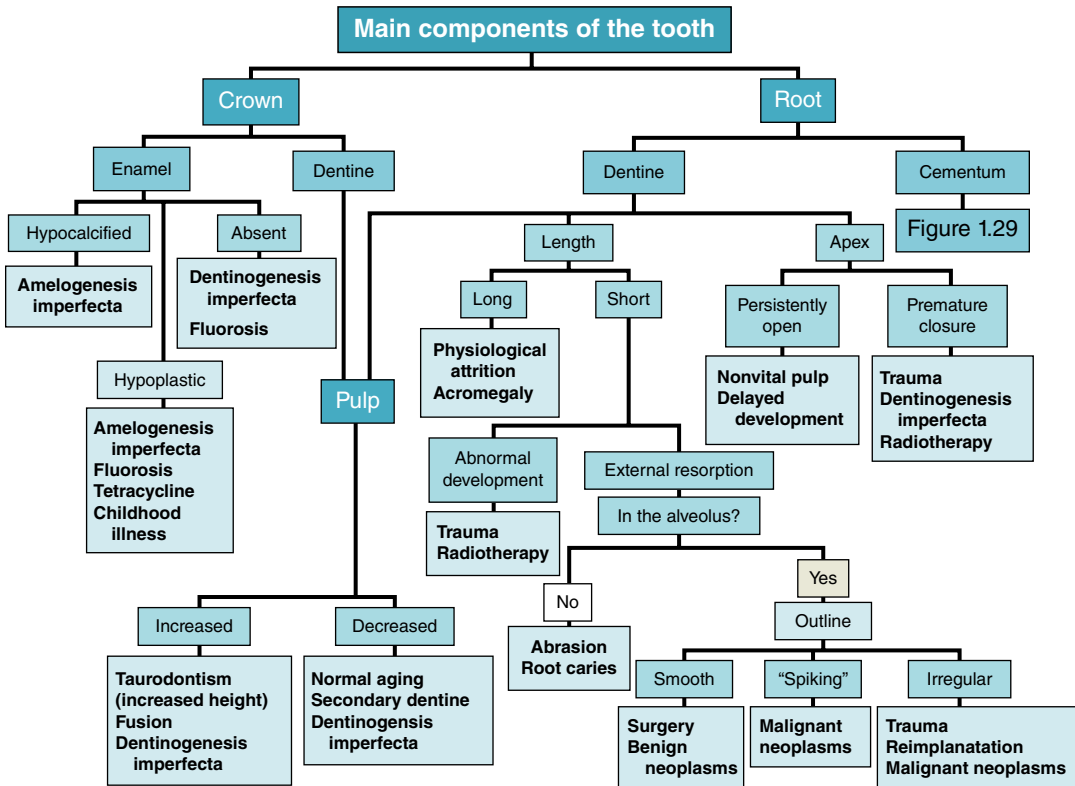


**Figure 1.6** Large field-of-view cone-beam computed tomography (CBCT) displaying cleft palates. (a) Coronal reconstruction of the CBCT dataset displaying a cleft on the left side. This reconstruction is at the level of the first molar. The nasal septum has fused normally with the normal part of the hard palate (HP). The patient is wearing an orthodontic appliance. Its metal clasps have created a metal artifact at the level of the crowns of the maxillary teeth. (b) Coronal reconstruction of the CBCT dataset through the apex of the orbit, displaying a bilateral cleft which has created a large defect in the middle of the HP. (c) The axial reconstruction of the same dataset as (b) exhibits the bilateral clefts passing through the alveolar ridge in the lateral incisor position. The shape of the soft tissue denoting the upper lip reveals a repaired bilateral cleft lip.





**Figure 1.7** Investigation of marked asymmetry of the jaws using conventional panoramic radiography, lateral cephalometry, and large field-of-view cone-beam computed tomography. (a) The marked asymmetry of the jaws on the panoramic radiograph is real and not due to defective technique. The crosses mark the position of the external acoustic meatus (a black cross on the right side and a yellow cross on the left side). (b) A lateral cephalogram displaying the lateral soft-tissue profile of the face in addition to that of the facial skeleton. The top of the skull has been cropped, reflecting the current protocol recently approved by the American Board of Orthodontics in order to reduce the radiation to children. (Credit to the University of British Columbia’s Dr. David Kennedy, deputy director of the Graduate Orthodontic program, and Ms. Sabina Reitzik, Oral and Maxillofacial Radiology faculty, for driving this issue forward.) The line of images at (c) represent the three-dimensional (3D) reconstruction, the panoramic reconstruction, and the axial reconstruction of the maxilla at the level of the hard palate, displaying asymmetry. The “defect” in the anterior mandible is due to the thickness chosen for the panoramic reconstruction of the maxilla not including that part of the mandible. The line of images at (d) represent the 3D reconstruction, the panoramic reconstruction, and the axial reconstruction of the mandible at the level of the atlantoaxial joint. The “absent” crowns of the maxillary incisors reflect the narrow thickness of this panoramic reconstruction of the mandible. The whole examination reveals hypoplasia of both the maxilla and the mandible on the right side.



**Figure 1.8** Those lesions other than caries which affect the main components of the tooth, namely the enamel, dentine, and pulp. Some important radiological features such as a root resorption are also displayed.

create space for further growth within the bony jaws. The borders of this radiolucency give a further clue to their intrinsic behavior. Encapsulated benign neoplasms and many uninfected cysts grow at a moderate pace and are generally well defined. They may even have a cortex. Infected lesions and malignancies are generally associated with a poorly defined margin, reflecting their more aggressive infiltrative expansion into previously normal bone. Sometimes, if the infected lesion becomes less virulent, the adjacent bone may respond by laying down more bone on the trabeculae, thickening them, thus resulting in sclerosis.

Slow-growing lesions, such as most cysts and encapsulated neoplasms, can displace teeth and adjacent structures such

as the mandibular canal and cortices. More aggressive lesions are more likely to resorb them. Some malignancies, such as a *squamous cell carcinoma*, will destroy structures with very little displacement, whereas others will provoke a periosteal reaction, such as the onion layer typical of *osteogenic sarcoma* or *Ewing's tumor*. Such a periosteal reaction can also occur in *chronic osteomyelitis*. These periosteal reactions are frequently seen in the extragnathic skeleton [6], but are infrequently seen in the jaws.

After the lesion has been properly imaged and reviewed, clinicians reach the point at which they want to identify the lesion. Because the aim at this stage is to achieve, if possible, a definitive diagnosis,

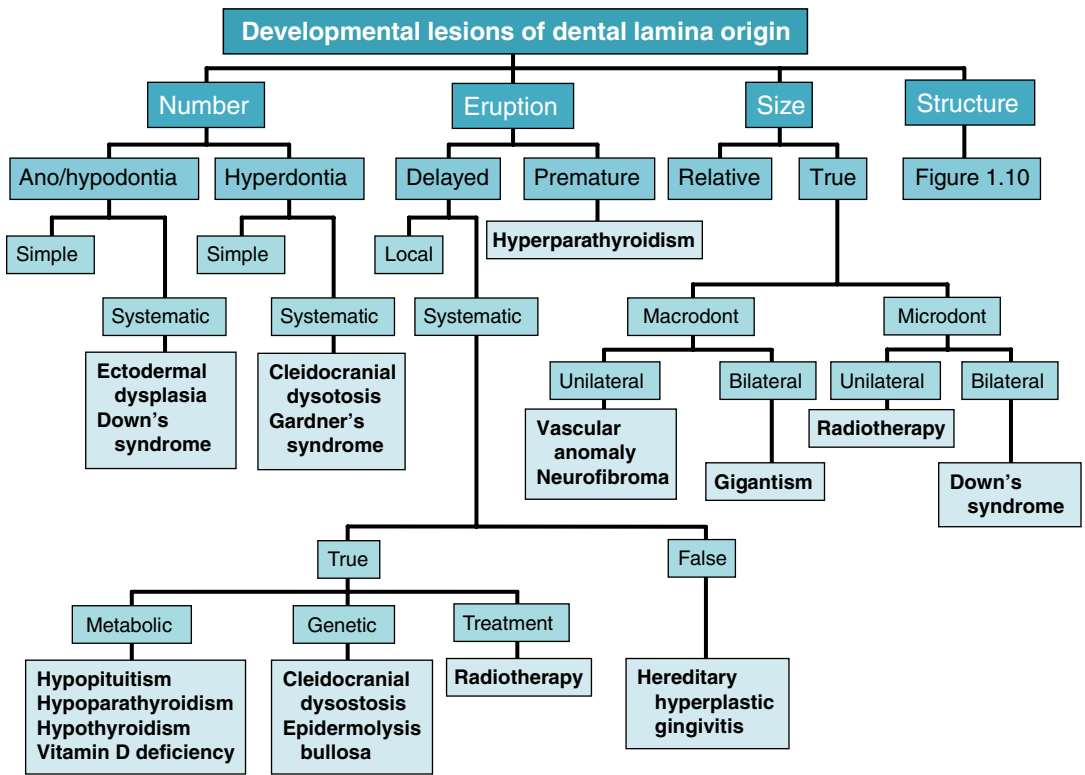


Figure 1.9 Classification of developmental lesions of dental lamina origin – number and size of teeth and their eruption.

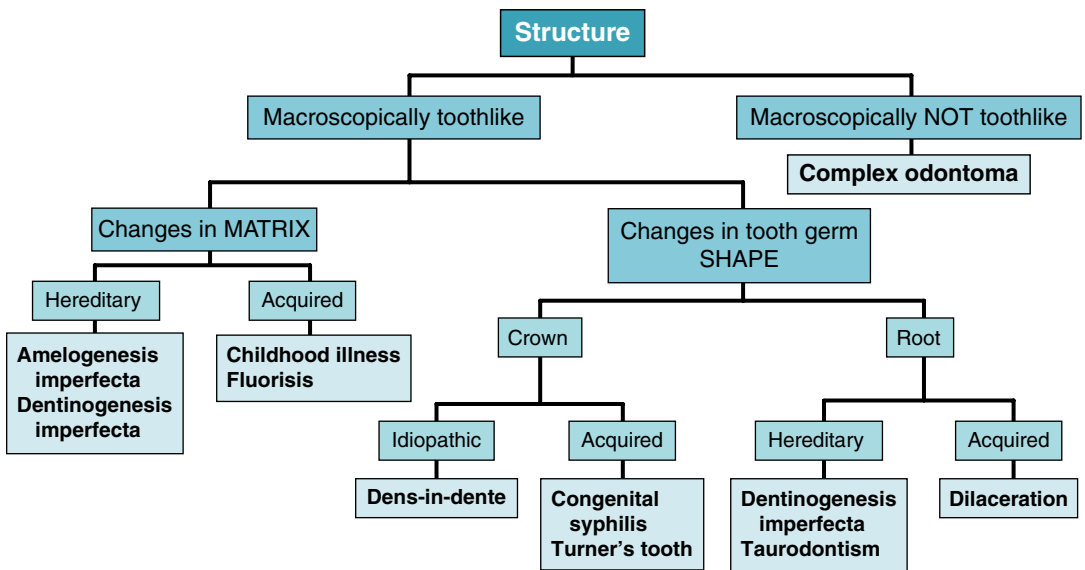


Figure 1.10 Classification of developmental lesions of dental lamina origin – structure.

it follows that this is best accomplished if the images of the lesion have been scrupulously reviewed. To this end, I developed the rule of the “Five Ss” (shade, shape, site, size, and surroundings) and its ancillary “Three Ds” (diameter, density, and displacement). There are many lesions that can be definitively diagnosed at this stage, but some require further investigation, which could include advanced imaging. Although a radiological feature as distinctive as the ‘tennis-racket’ pattern (Figure 1.32) has a high specificity for the odontogenic myxoma, not all myxomas display it. Predictive values (sensitivity, specificity, positive predictive value and negative predictive value) [7] will be considered later in Chapter 3. Therefore, most lesions require two or more radiological and/or clinical features for a provisional diagnosis.

In order to ensure that the most appropriate investigations are applied, the provisional diagnosis should be restricted to no more than three lesions if possible, placing the most likely in the first position so that the most appropriate investigation can be performed to determine whether it is that lesion. An important exception to this “most likely” rule is the potential seriousness of outcome of the lesions. Table 1.3 compares clinical outcomes according to a 10-step (0 through 9) hierarchy of seriousness of outcomes. The higher-placed lesions have the more serious outcomes.

The selection of lesions can vary among clinicians, depending upon that particular lesion’s presentation and frequency within a particular clinician’s patient pool. The age, gender, and ethnic origin of the individual patient and site of predilection are perhaps overemphasized in most teaching programs. The main problem with this is that many lesions frequently present first outside their

expected age ranges. Occasionally, this expected age range may simply be out of date. An example is fibrous dysplasia: the majority in a recent systematic review first presented in the third decade and older.

The *relative period prevalence* (RPP) [8] was developed to indicate better to the clinician reader of a report the likelihood of a particular lesion presenting within the reported community per year of that report. This has been set out for the most frequent lesions registered in the pathology files of a major center in the United Kingdom in Table 9.1. This is an average for that particular report, depending upon the total number reported and the number of years covered by the report. The RPP of most of the most important and/or frequent lesions affecting the face and jaws in this textbook is included in all accompanying tables more descriptively as “mean number per year per report.”

Another source of inaccuracy is that lesions are often superficially reported not only dependent upon their RPP, but on the proportion or percentages of the other lesions within the same group of lesions, such as odontogenic neoplasms [9]. The latter is substantially dependent upon the edition of the WHO classification of odontogenic neoplasms used. Many previously classified odontogenic neoplasms are no longer formally considered as such. An example is the cementifying fibroma (then later combined with the “ossifying fibroma,” previously considered to be a separate lesion, as the *cemento-ossifying fibroma*), once considered by the WHO’s 1971 edition [10] to be an odontogenic neoplasm, is now considered to be a wholly osseous neoplasm, the ossifying fibroma. Some other lesions have since been reclassified as neoplasms, only to subsequently again be classified as cysts. The *parakeratotic variant of the odontogenic keratocyst*, a cyst according to the



**Table 1.3** Scale of severity of outcomes/potential severity of outcomes of oral maxillofacial radiology.<sup>a</sup>

<p><b>9 Resection, but high likelihood of recurrence or metastasis</b>            Poorly differentiated squamous cell carcinoma            Osteosarcoma            Fibrosarcoma            Adenoid cystic carcinoma (neural spread)</p>
<p><b>8 Resection and lower likelihood of recurrence or metastasis</b>            Well-differentiated squamous cell carcinoma (qualified by site)            Chondrosarcoma            Ameloblastic carcinoma            Mucoepidermoid carcinoma</p>
<p><b>7 Resection and likelihood of recurrence or metastasis rare</b>            Verrucous carcinoma            Solid ameloblastoma            Odontogenic myxoma            Dentinogenic ghost cell tumor (DGCT)</p>
<p><b>6 Enucleation and cytotoxic treatment (Carnoy's solution)</b>            Unicystic ameloblastoma (provided not affecting posterior maxilla)            Keratocystic odontogenic tumor (KCOT)</p>
<p><b>5 Simple enucleation and high chance of recurrence (recurrence rate of 10% and over)</b>            Aneurysmal bone cyst (ABC)            Ameloblastic fibroma            Ossifying fibroma (OF)            Glandular odontogenic cyst (GOC)            Cementoblastoma            Pleomorphic (salivary) adenoma (PSA)            Calcifying epithelial odontogenic tumor (CEOT)            Calcifying odontogenic cyst (COC)</p>
<p><b>4 Simple enucleation and little chance of recurrence</b>            Adenomatoid odontogenic tumor (AOT)            Osteoblastoma/osteoid osteoma            Orthokeratinized odontogenic cyst (OOC)            Giant cell lesions (large ones may need resection)            Complex odontoma, including ameloblastic fibro-odontoma (AFO)            Squamous odontogenic tumor (SOC)            Primordial odontogenic tumor (POT)            Warthin's tumor</p>
<p><b>3 Simple enucleation and no chance of recurrence (in a neoplastic fashion)</b>            Periapical radiolucencies of inflammatory origin (PRIO)            Nasopalatine duct cyst (NDC)            Dentigerous cyst            Compound odontoma</p>
<p><b>2 Conservative surgery may be required only to improve esthetics</b>            Fibrous dysplasia (surgery not indicated unless compelled by esthetics or by risk of blindness)            Cherubism            Condensing/sclerosing osteitis (treatment of the affected tooth may result in regression)</p>
<p><b>1 No treatment generally required</b>            Lingual bone defect (LBD)            Osseous dysplasia (florid and focal, but <i>not</i> expanding forms, which require treatment)            Mucosal antral pseudocyst            Osteoma – solitary, nonsyndromal (ivory type could be surgically difficult)            Simple bone cyst (SBC)            Idiopathic osteosclerosis/dense bone island</p>

<sup>a</sup> This table was inspired by the Richter scale for earthquakes. The scale is based on the general current treatment paradigms for each lesion.