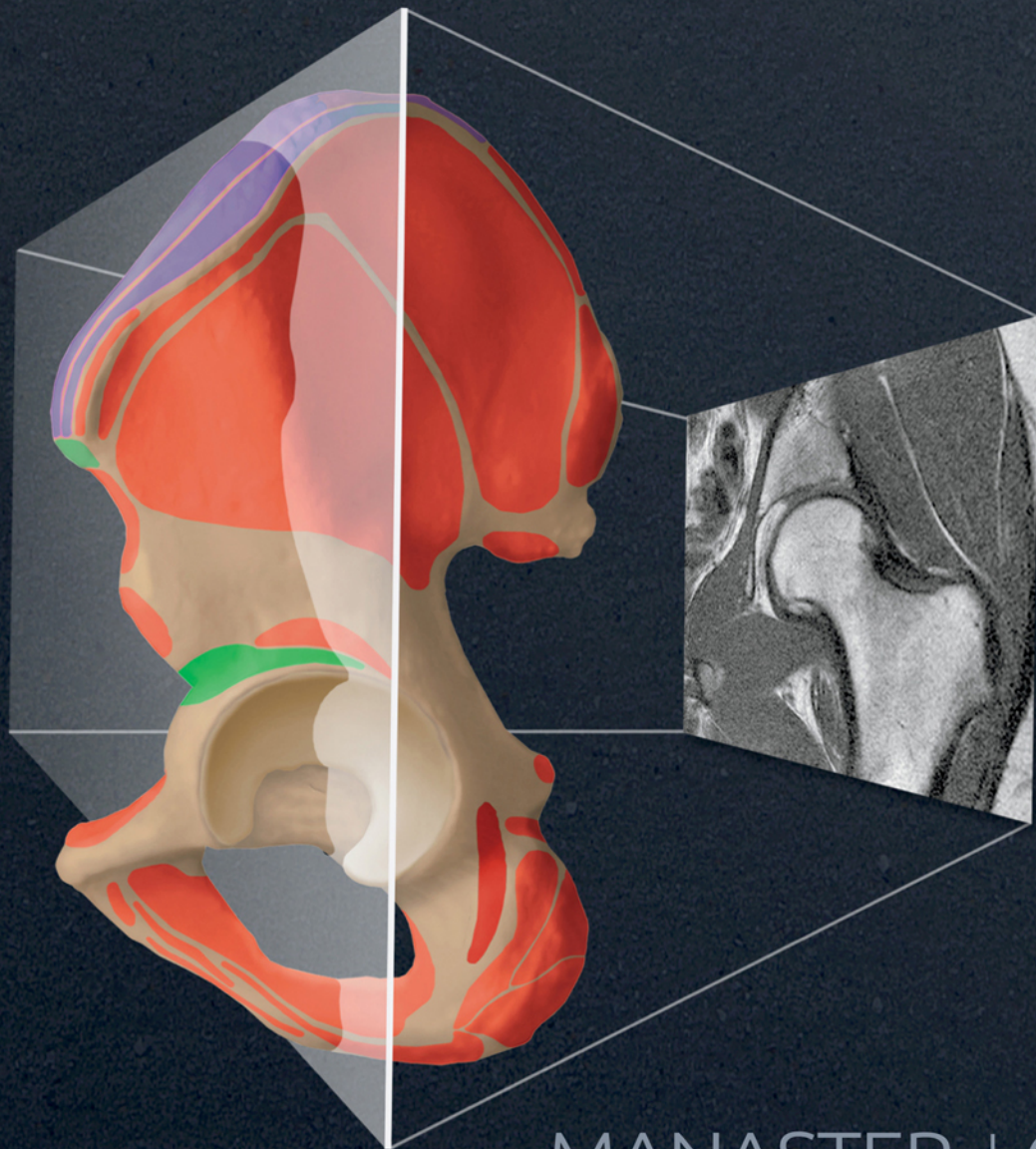


Get Full Access and More at

ExpertConsult.com

IMAGING ANATOMY
Musculoskeletal

SECOND EDITION



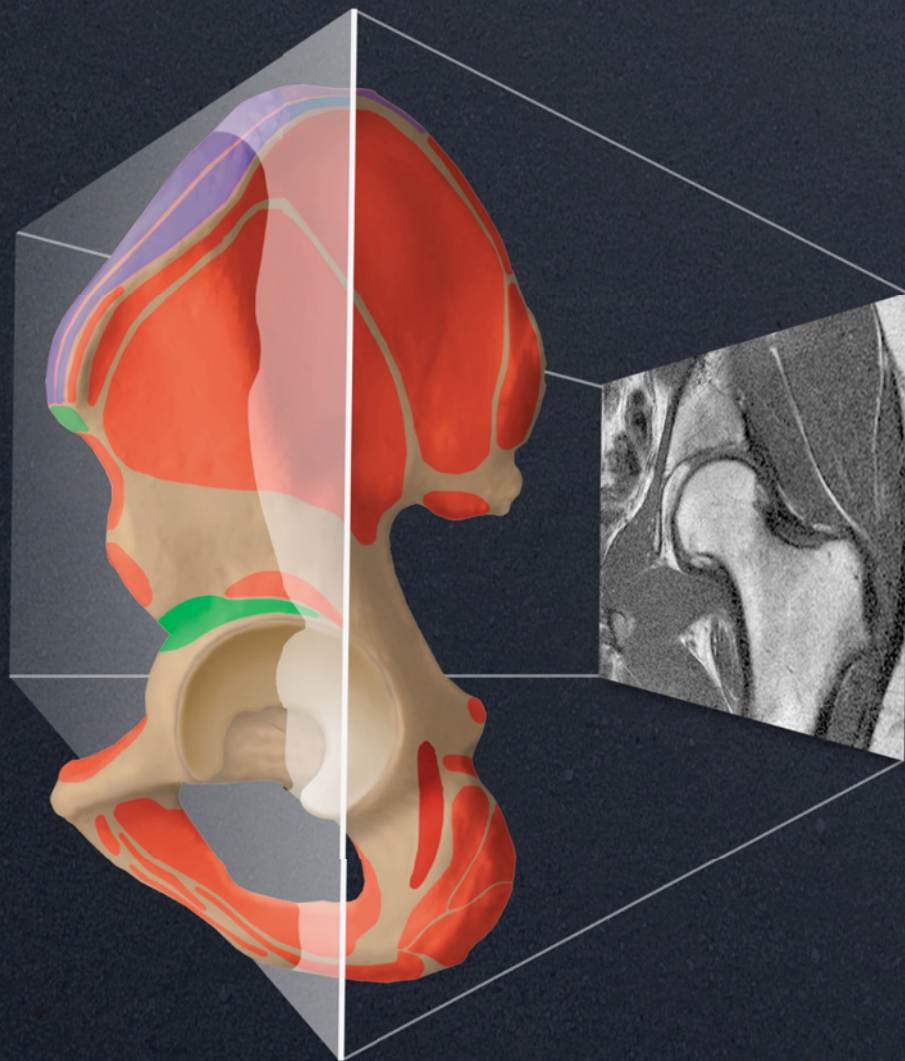
AMIRSYS®
ELSEVIER

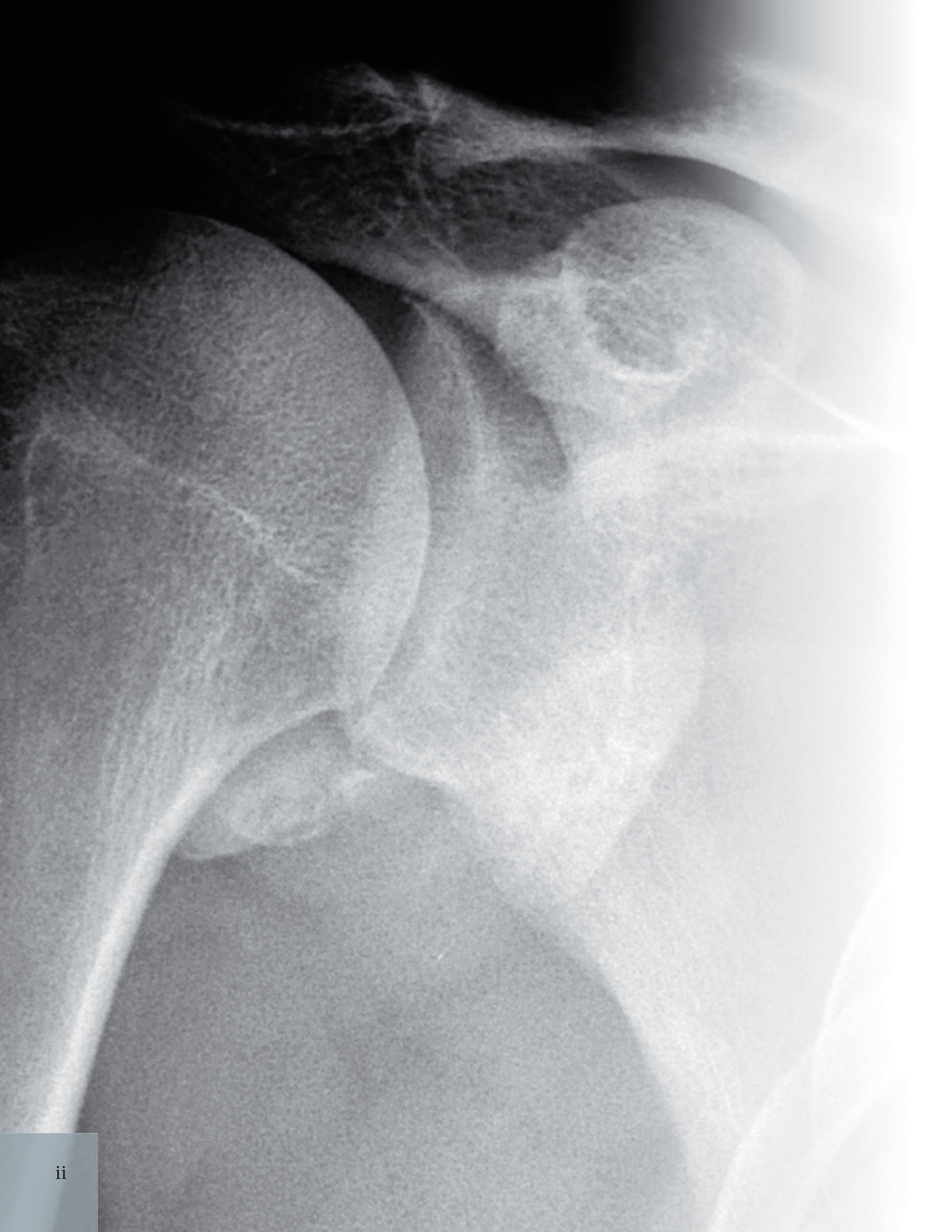
MANASTER | CRIM

IMAGING ANATOMY
Musculoskeletal

SECOND EDITION

MANASTER | CRIM





IMAGING ANATOMY
Musculoskeletal

SECOND EDITION

B.J. Manaster, MD, PhD, FACR

Emeritus Professor
Department of Radiology
University of Utah School of Medicine
Salt Lake City, Utah

Julia Crim, MD

Chief of Musculoskeletal Radiology
Department of Radiology
University of Missouri
Columbia, Missouri

Copyright © 2016 by Elsevier. All rights reserved.

No part of this publication may be reproduced or transmitted in any form or by any means, electronic or mechanical, including photocopying, recording, or any information storage and retrieval system, without permission in writing from the publisher. Details on how to seek permission, further information about the Publisher's permissions policies and our arrangements with organizations such as the Copyright Clearance Center and the Copyright Licensing Agency, can be found at our website: www.elsevier.com/permissions.

This book and the individual contributions contained in it are protected under copyright by the Publisher (other than as may be noted herein).

Notices

Knowledge and best practice in this field are constantly changing. As new research and experience broaden our understanding, changes in research methods, professional practices, or medical treatment may become necessary.

Practitioners and researchers must always rely on their own experience and knowledge in evaluating and using any information, methods, compounds, or experiments described herein. In using such information or methods they should be mindful of their own safety and the safety of others, including parties for whom they have a professional responsibility.

With respect to any drug or pharmaceutical products identified, readers are advised to check the most current information provided (i) on procedures featured or (ii) by the manufacturer of each product to be administered, to verify the recommended dose or formula, the method and duration of administration, and contraindications. It is the responsibility of practitioners, relying on their own experience and knowledge of their patients, to make diagnoses, to determine dosages and the best treatment for each individual patient, and to take all appropriate safety precautions.

To the fullest extent of the law, neither the Publisher nor the authors, contributors, or editors, assume any liability for any injury and/or damage to persons or property as a matter of products liability, negligence or otherwise, or from any use or operation of any methods, products, instructions, or ideas contained in the material herein.

Publisher Cataloging-in-Publication Data

Imaging anatomy. Musculoskeletal / [edited by] B.J. Manaster and Julia Crim.
2nd edition.
pages ; cm
Musculoskeletal
Includes bibliographical references and index.
ISBN 978-0-323-37756-0 (hardback)
1. Musculoskeletal system--Imaging--Handbooks, manuals, etc.
I. Manaster, B. J. II. Crim, Julia. III. Title: Musculoskeletal.
[DNLM: 1. Musculoskeletal Diseases--diagnosis--Atlases. 2. Musculoskeletal System--injuries--Atlases. 3. Musculoskeletal System--radiography--Atlases.
WE 141]
RC925.7 .I434 2015
616.7/0754--dc23

International Standard Book Number: 978-0-323-37756-0

Cover Designer: Tom M. Olson, BA
Cover Art: Richard Coombs, MS

Printed in Canada by Friesens, Altona, Manitoba, Canada

Last digit is the print number: 9 8 7 6 5 4 3 2 1

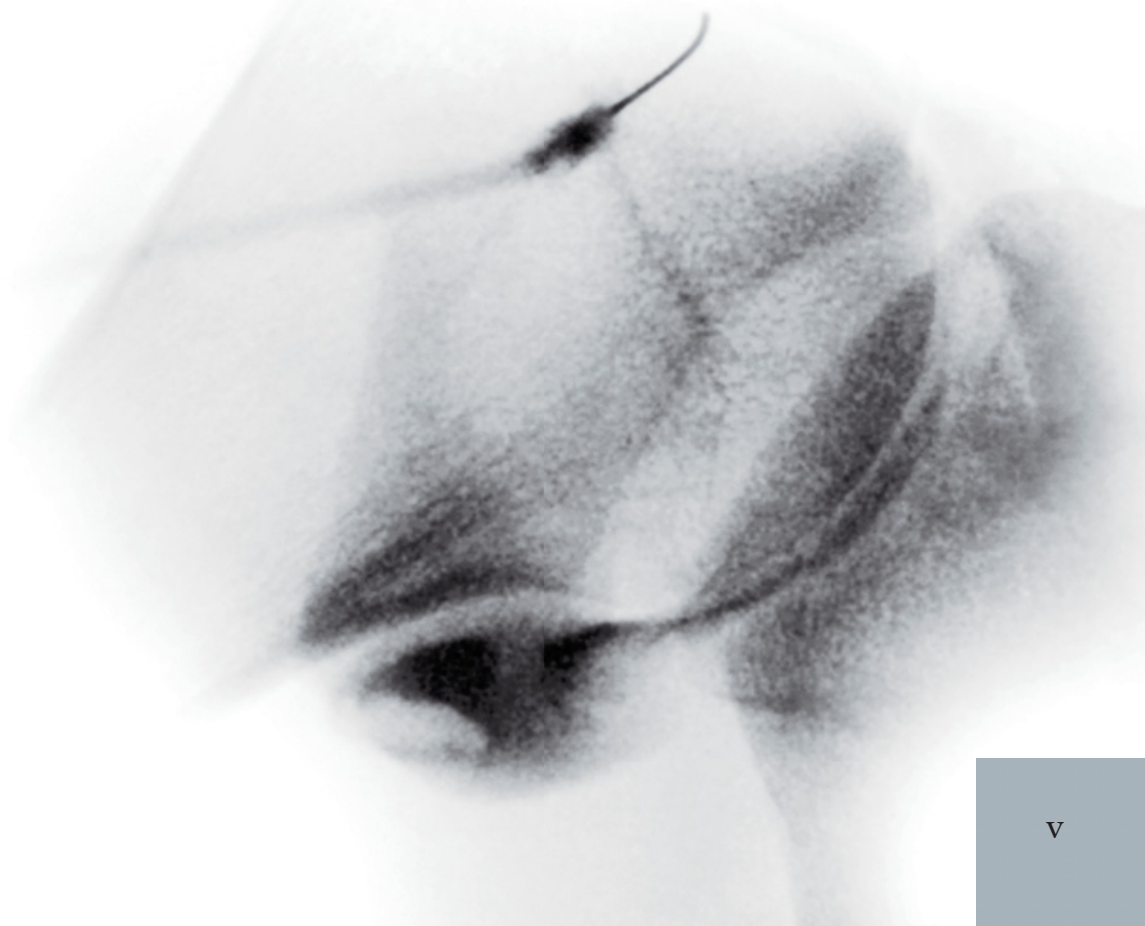


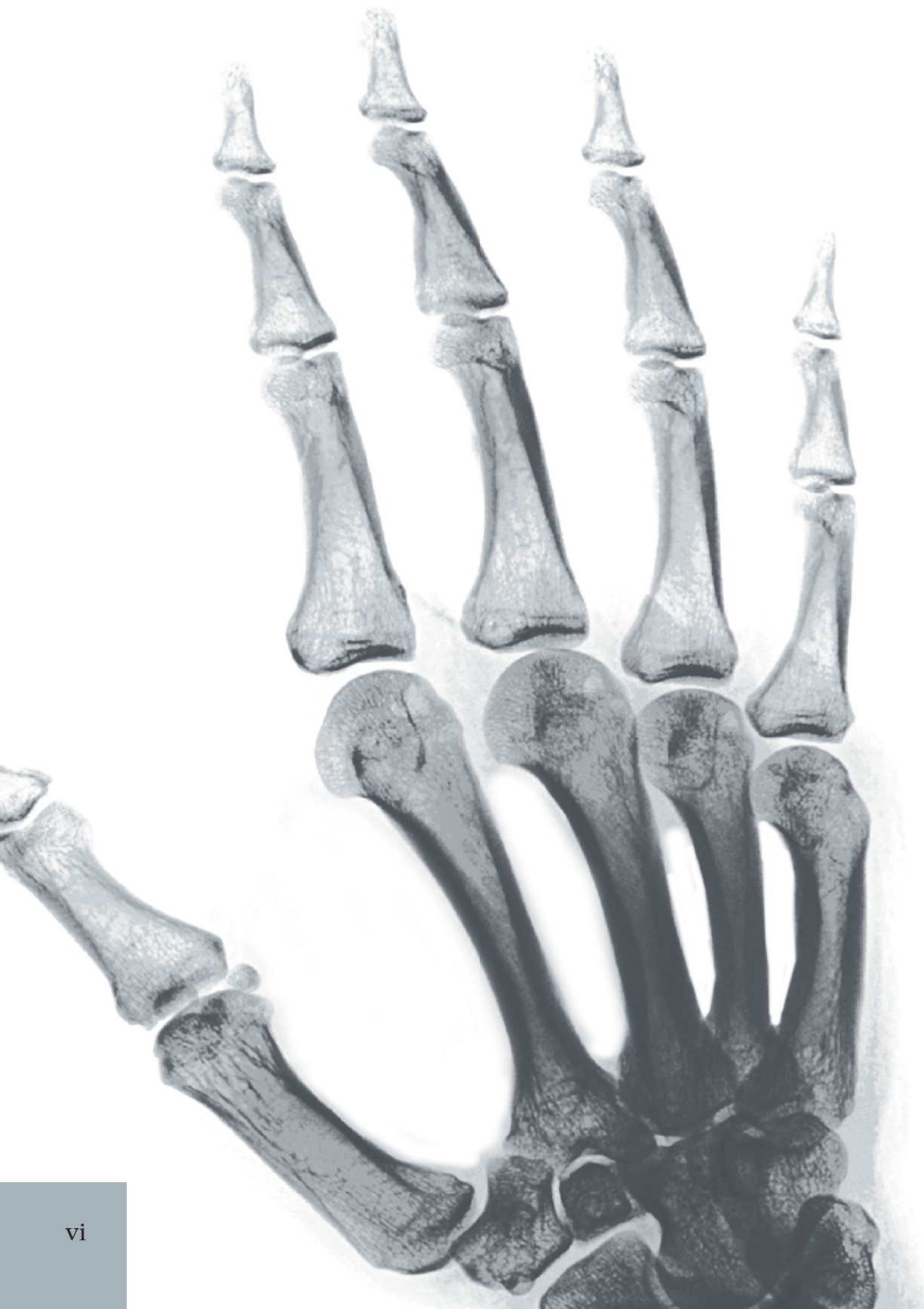Dedications

This book is dedicated to the residents and fellows with whom we have worked over the past many years. It is a joy to have been your teachers, mentors, and friends.

*As we wrote the second edition of *Imaging Anatomy: Musculoskeletal*, we thought about you and tried to clearly answer all the anatomy questions you have asked; we hope the book is useful to you and to all scholars studying the musculoskeletal system.*

BJM and JRC





Contributing Authors

Catherine C. Roberts, MD

Professor of Radiology
Mayo Clinic
Scottsdale, Arizona

Theodore T. Miller, MD, FACR

Chief, Division of Ultrasound
Hospital for Special Surgery
Professor of Radiology
Weill Medical College of Cornell University
New York, New York

Cheryl Petersilge, MD, MBA

Clinical Professor of Radiology
Cleveland Clinic Lerner College of Medicine
Case Western Reserve University
Cleveland, Ohio

William B. Morrison, MD

Professor of Radiology
Director, Division of Musculoskeletal Imaging and Intervention
Department of Radiology
Thomas Jefferson University Hospital
Philadelphia, Pennsylvania

Carol L. Andrews, MD

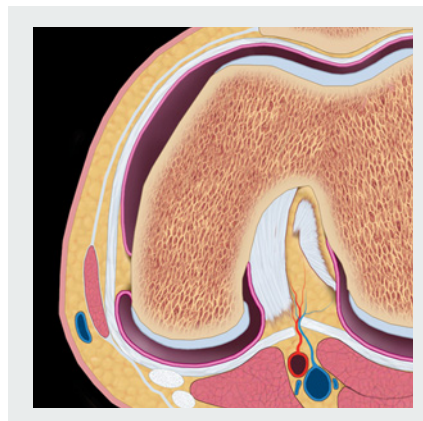
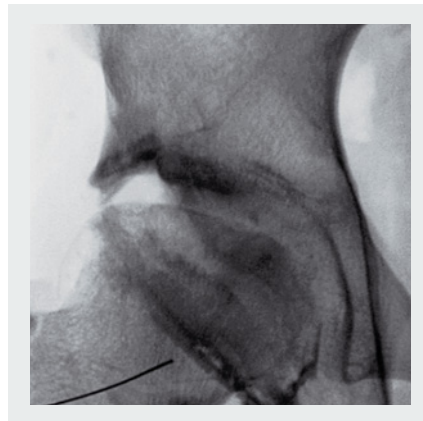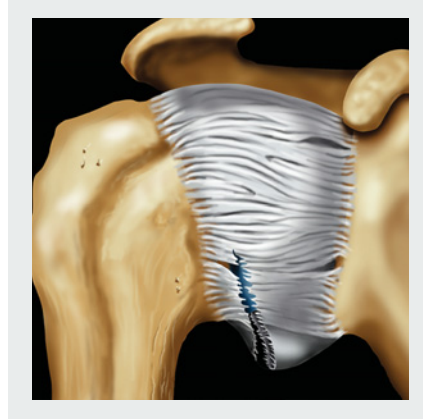
Associate Professor
Division Chief, Musculoskeletal Radiology
University of Pittsburgh Medical Center
Pittsburgh, Pennsylvania

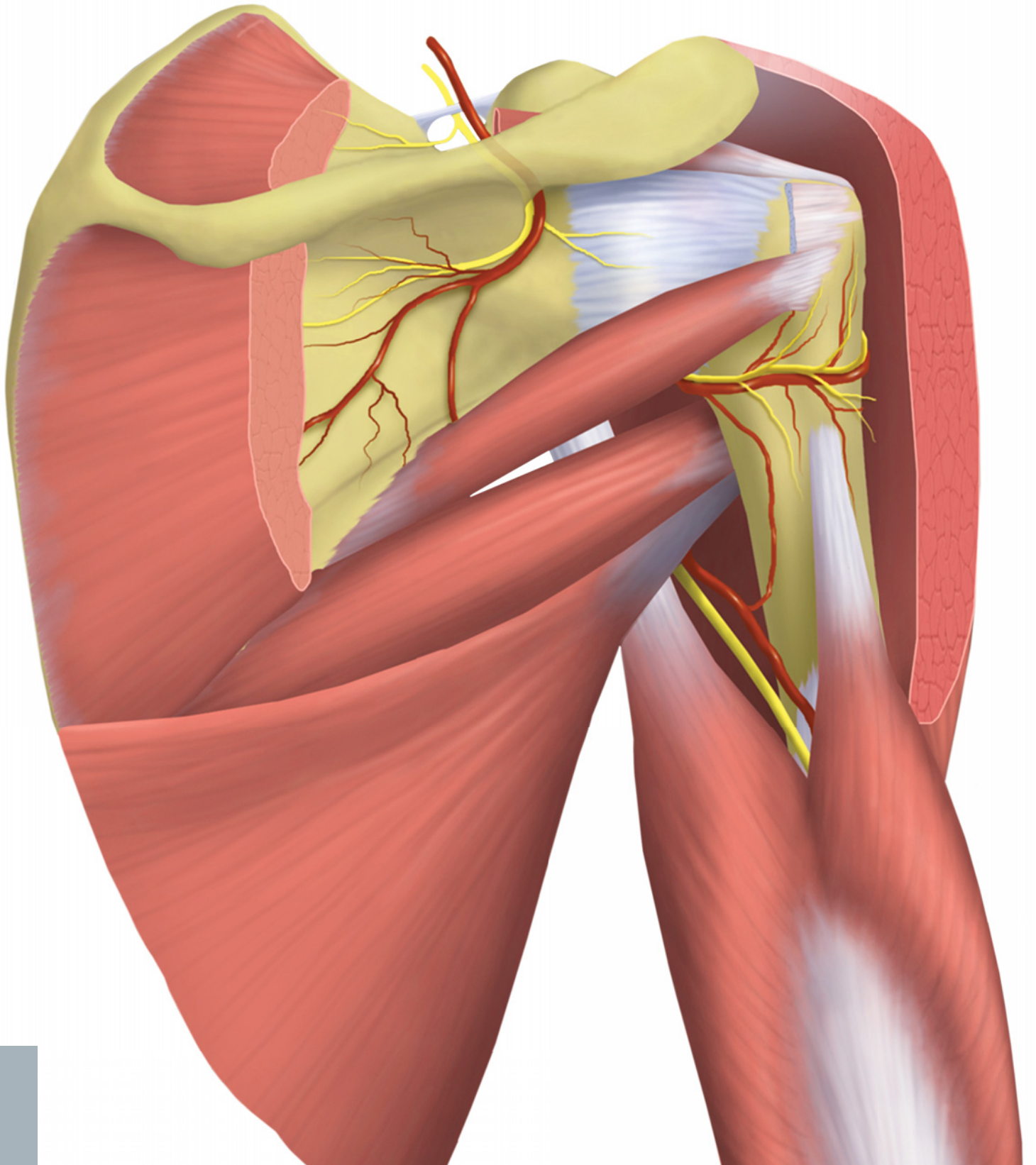
Jeffrey W. Grossman, MD

Owner/Manager
Bonehead Radiology, PLLC
Eagle, Idaho

Zehava Sadka Rosenberg, MD

Professor of Radiology and Orthopedic Surgery
NYU School of Medicine
NYU Langone Medical Center
New York, New York





Preface

This second edition of *Imaging Anatomy: Musculoskeletal* retains features that made the first edition widely popular. Images are extensively labeled in 3 planes and include long bones as well as joints. Coronal and axial images of right and left sides are placed on facing pages. Anatomy is described with attention to issues of clinical importance. So, what is new that justifies a new edition? We have made numerous changes that we believe will make this work more complete and easier to use.

The chapter organization has been made more uniform in the second edition. The overview chapter for each anatomic region contains a written text supplemented by color anatomy illustrations. The overview is followed by a chapter describing radiographic and arthrographic anatomy, as well as an MR Atlas chapter. In the MR Atlas, the scout images are larger, making correlation easier. Additional chapters detailing uniquely difficult anatomic or functional regions follow the MR Atlas. Additional material has been added to better explicate the complex anatomy of the hip, hand, thumb, ankle, and foot.

We have standardized and expanded sections describing standard imaging lines, angles, and measurements to make it easy for radiologists to reference both methodology and normal values. In addition, chapters featuring normal variants and imaging pitfalls have been added. And last but not least, we discovered and corrected some labeling errors from the first edition.

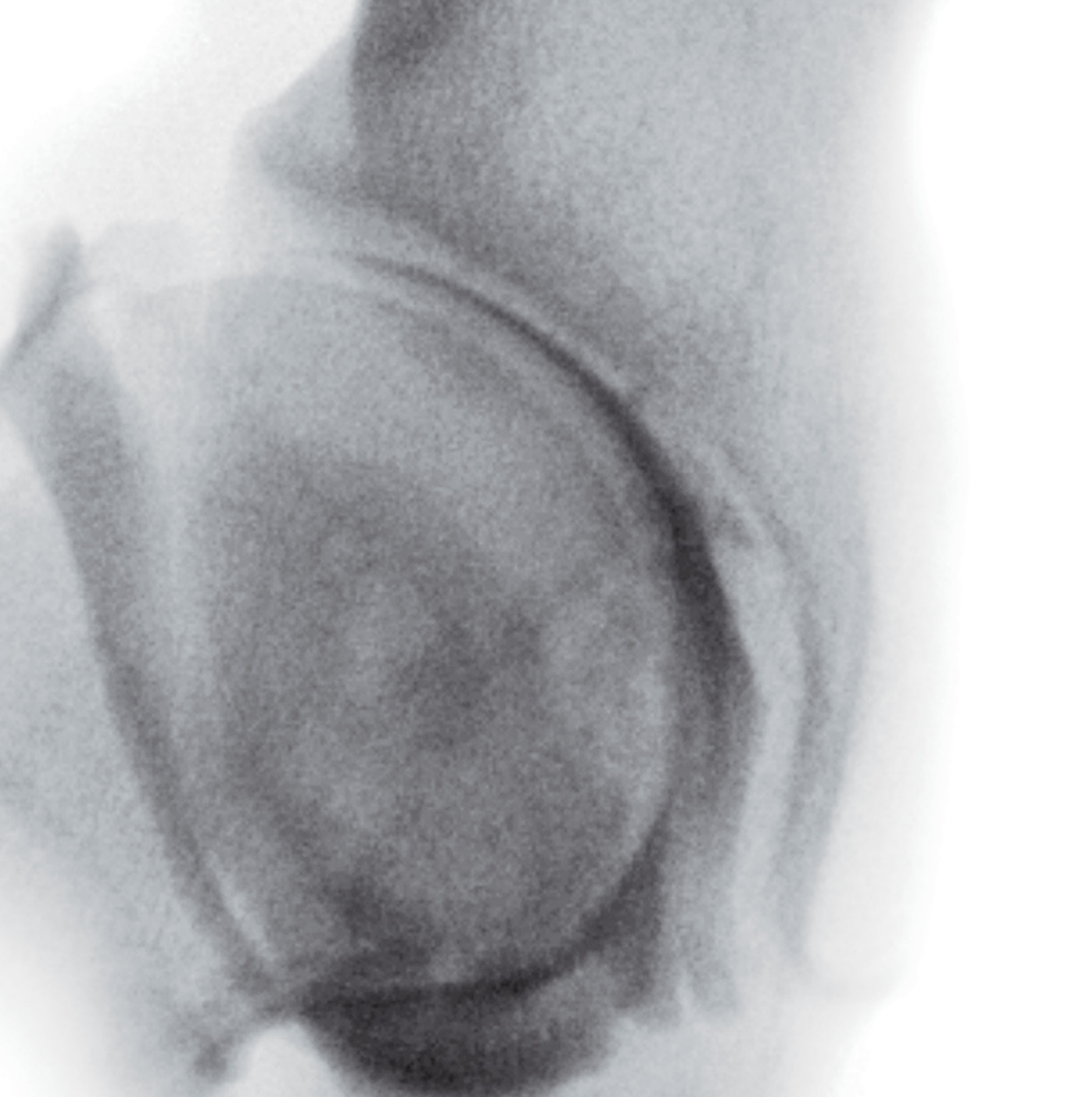
We hope and expect the users, our colleagues, will find the improvements made in this edition to be useful in their practice.

B.J. Manaster, MD, PhD, FACR

Emeritus Professor
Department of Radiology
University of Utah School of Medicine
Salt Lake City, Utah

Julia Crim, MD

Chief of Musculoskeletal Radiology
Department of Radiology
University of Missouri
Columbia, Missouri



Acknowledgements

Text Editors

Dave L. Chance, MA, ELS
Arthur G. Gelsinger, MA
Nina I. Bennett, BA
Sarah J. Connor, BA
Tricia L. Cannon, BA
Terry W. Ferrell, MS

Image Editors

Jeffrey J. Marmorstone, BS
Lisa A. M. Steadman, BS

Medical Editor

Megan K. Mills, MD

Illustrations

Richard Coombs, MS
Lane R. Bennion, MS
Laura C. Sesto, MA

Art Direction and Design

Tom M. Olson, BA
Laura C. Sesto, MA

Lead Editors

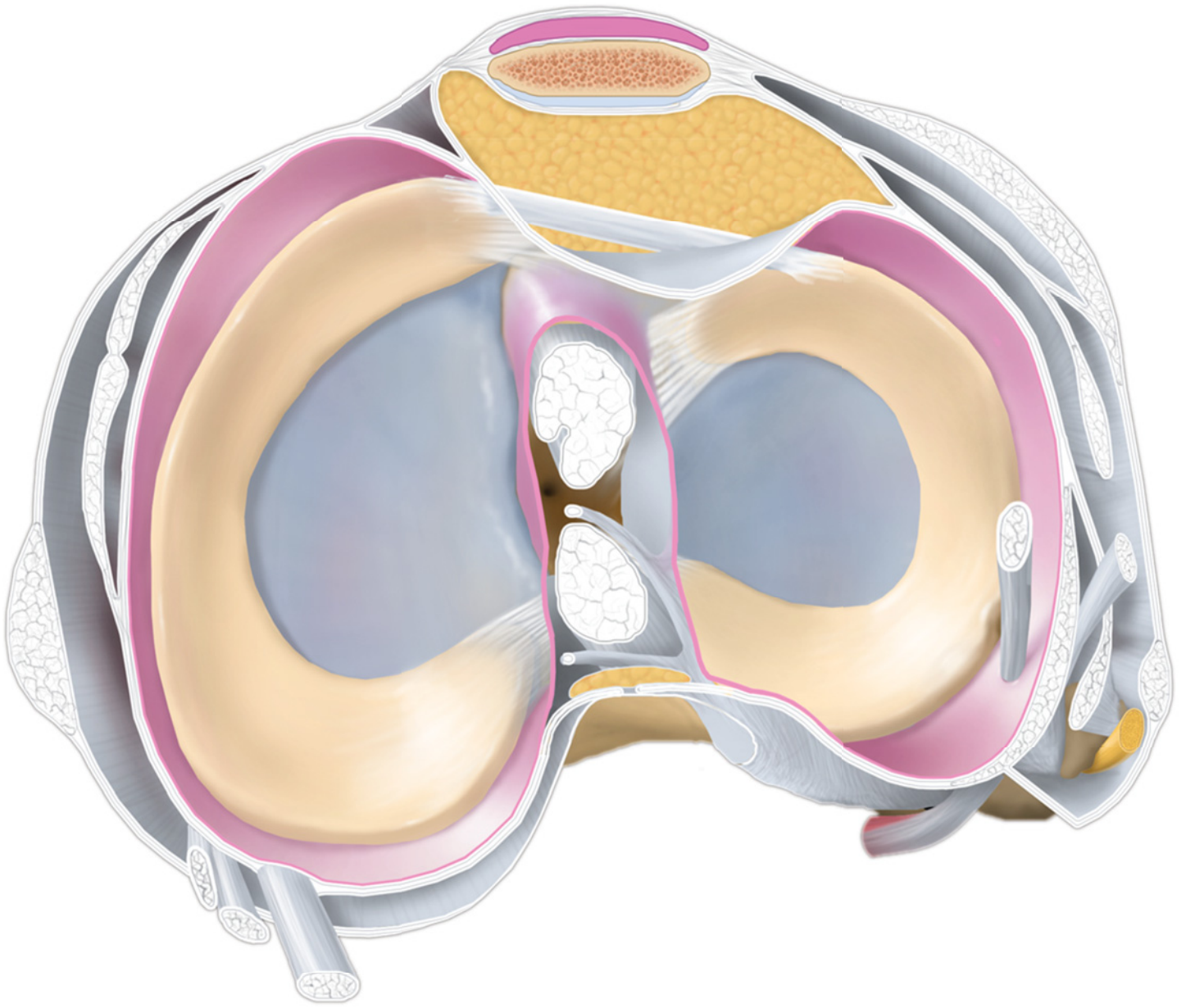
Rebecca L. Hutchinson, BA
Lisa A. Gervais, BS

Production Coordinators

Angela M.G. Terry, BA
Rebecca L. Hutchinson, BA

ELSEVIER





Sections

SECTION 1: SHOULDER

SECTION 2: ARM

SECTION 3: ELBOW

SECTION 4: FOREARM

SECTION 5: WRIST

SECTION 6: HAND

SECTION 7: PELVIS AND HIP

SECTION 8: THIGH

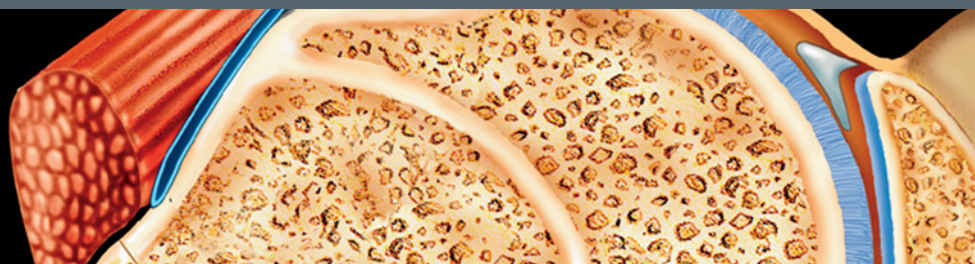SECTION 9: KNEE

SECTION 10: LEG

SECTION 11: ANKLE

SECTION 12: FOOT

TABLE OF CONTENTS



SECTION 1: SHOULDER

- 4 Shoulder Overview**
B.J. Manaster, MD, PhD, FACR and Catherine C. Roberts, MD
- 14 Shoulder Radiographic and Arthrographic Anatomy**
B.J. Manaster, MD, PhD, FACR and Julia Crim, MD
- 36 Shoulder MR Atlas**
B.J. Manaster, MD, PhD, FACR and Catherine C. Roberts, MD
- 86 Shoulder Abduction-External Rotation (ABER) Plane**
B.J. Manaster, MD, PhD, FACR and Catherine C. Roberts, MD
- 94 Shoulder: Rotator Cuff and Biceps Tendon**
B.J. Manaster, MD, PhD, FACR and Catherine C. Roberts, MD
- 102 Shoulder: Rotator Interval**
B.J. Manaster, MD, PhD, FACR and Catherine C. Roberts, MD
- 112 Shoulder Ligaments**
B.J. Manaster, MD, PhD, FACR and Catherine C. Roberts, MD
- 126 Shoulder Labrum**
B.J. Manaster, MD, PhD, FACR and Catherine C. Roberts, MD
- 138 Shoulder Normal Variants and Imaging Pitfalls**
B.J. Manaster, MD, PhD, FACR

SECTION 2: ARM

- 154 Arm Radiographic Anatomy and MR Atlas**
B.J. Manaster, MD, PhD, FACR and Catherine C. Roberts, MD

SECTION 3: ELBOW

- 194 Elbow Overview**
B.J. Manaster, MD, PhD, FACR and Theodore T. Miller, MD, FACR
- 200 Elbow Radiographic and Arthrographic Anatomy**
B.J. Manaster, MD, PhD, FACR and Julia Crim, MD
- 214 Elbow MR Atlas**
B.J. Manaster, MD, PhD, FACR and Theodore T. Miller, MD, FACR
- 248 Elbow Muscles and Tendons**
B.J. Manaster, MD, PhD, FACR and Theodore T. Miller, MD, FACR
- 270 Elbow Ligaments**
B.J. Manaster, MD, PhD, FACR and Theodore T. Miller, MD, FACR

- 280 Elbow Normal Variants and Imaging Pitfalls**

B.J. Manaster, MD, PhD, FACR

- 292 Elbow Measurements and Lines**

B.J. Manaster, MD, PhD, FACR

SECTION 4: FOREARM

- 298 Forearm Radiographic Anatomy and MR Atlas**

B.J. Manaster, MD, PhD, FACR and Theodore T. Miller, MD, FACR

SECTION 5: WRIST

- 326 Wrist Overview**

Julia Crim, MD and Carol L. Andrews, MD

- 334 Wrist Radiographic and Arthrographic Anatomy**

Julia Crim, MD

- 342 Wrist MR Atlas**

Julia Crim, MD and Carol L. Andrews, MD

- 388 Wrist Ligaments**

Julia Crim, MD and Carol L. Andrews, MD

- 398 Wrist Tendons**

Julia Crim, MD and Carol L. Andrews, MD

- 418 Wrist and Hand Normal Variants and Imaging Pitfalls**

Julia Crim, MD

- 428 Wrist Measurements and Lines**

Julia Crim, MD and Carol L. Andrews, MD

SECTION 6: HAND

- 436 Hand Overview**

Julia Crim, MD and Jeffrey W. Grossman, MD

- 444 Thumb Anatomy**

Julia Crim, MD

- 452 Hand Radiographic Anatomy**

Julia Crim, MD and Jeffrey W. Grossman, MD

- 456 Hand MR Atlas**

Julia Crim, MD and Jeffrey W. Grossman, MD

- 472 Flexor and Extensor Mechanisms of Hand**

Julia Crim, MD

SECTION 7: PELVIS AND HIP

- 486 Pelvis Overview**

Julia Crim, MD and Cheryl A. Petersilge, MD, MBA

- 494 Pelvis MR Atlas**

Julia Crim, MD and Cheryl A. Petersilge, MD, MBA

- 528 Anterior Pelvis**

Julia Crim, MD and Cheryl A. Petersilge, MD, MBA

- 554 Hip Overview**

Julia Crim, MD

- 558 Hip MR Anatomy**

Julia Crim, MD and Cheryl A. Petersilge, MD, MBA

TABLE OF CONTENTS

- 574 **Pelvis and Hip Radiographic and Arthrographic Anatomy**
Julia Crim, MD
- 590 **Pelvis and Hip Normal Variants and Imaging Pitfalls**
Julia Crim, MD
- 598 **Pelvis and Hip Measurements and Lines**
Julia Crim, MD and Cheryl A. Petersilge, MD, MBA

SECTION 8: THIGH

- 606 **Thigh Radiographic Anatomy and MR Atlas**
Julia Crim, MD and Cheryl A. Petersilge, MD, MBA

SECTION 9: KNEE

- 662 **Knee Overview**
B.J. Manaster, MD, PhD, FACR
- 670 **Knee Radiographic and Arthrographic Anatomy**
B.J. Manaster, MD, PhD, FACR and William B. Morrison, MD
- 686 **Knee MR Atlas**
B.J. Manaster, MD, PhD, FACR
- 734 **Knee Extensor Mechanism and Retinacula**
B.J. Manaster, MD, PhD, FACR
- 742 **Menisci**
B.J. Manaster, MD, PhD, FACR
- 768 **Cruciate Ligaments/Posterior Capsule**
B.J. Manaster, MD, PhD, FACR
- 786 **Knee Medial Supporting Structures**
B.J. Manaster, MD, PhD, FACR
- 796 **Knee Lateral Supporting Structures**
B.J. Manaster, MD, PhD, FACR
- 812 **Knee and Leg Normal Variants and Imaging Pitfalls**
B.J. Manaster, MD, PhD, FACR
- 858 **Knee and Leg Measurements and Lines**
B.J. Manaster, MD, PhD, FACR

SECTION 10: LEG

- 878 **Leg Radiographic Anatomy and MR Atlas**
B.J. Manaster, MD, PhD, FACR

SECTION 11: ANKLE

- 918 **Ankle Overview**
Julia Crim, MD and Zehava Sadka Rosenberg, MD
- 934 **Ankle Radiographic and Arthrographic Anatomy**
Julia Crim, MD
- 946 **Ankle MR Atlas**
Julia Crim, MD and Zehava Sadka Rosenberg, MD
- 980 **Ankle Tendons**
Julia Crim, MD and Zehava Sadka Rosenberg, MD
- 1004 **Ankle Ligaments**
Julia Crim, MD and Zehava Sadka Rosenberg, MD

SECTION 12: FOOT

- 1034 **Foot Overview**
Julia Crim, MD
- 1042 **Foot Radiographic and Arthrographic Anatomy**
Julia Crim, MD
- 1054 **Foot MR Atlas**
Julia Crim, MD

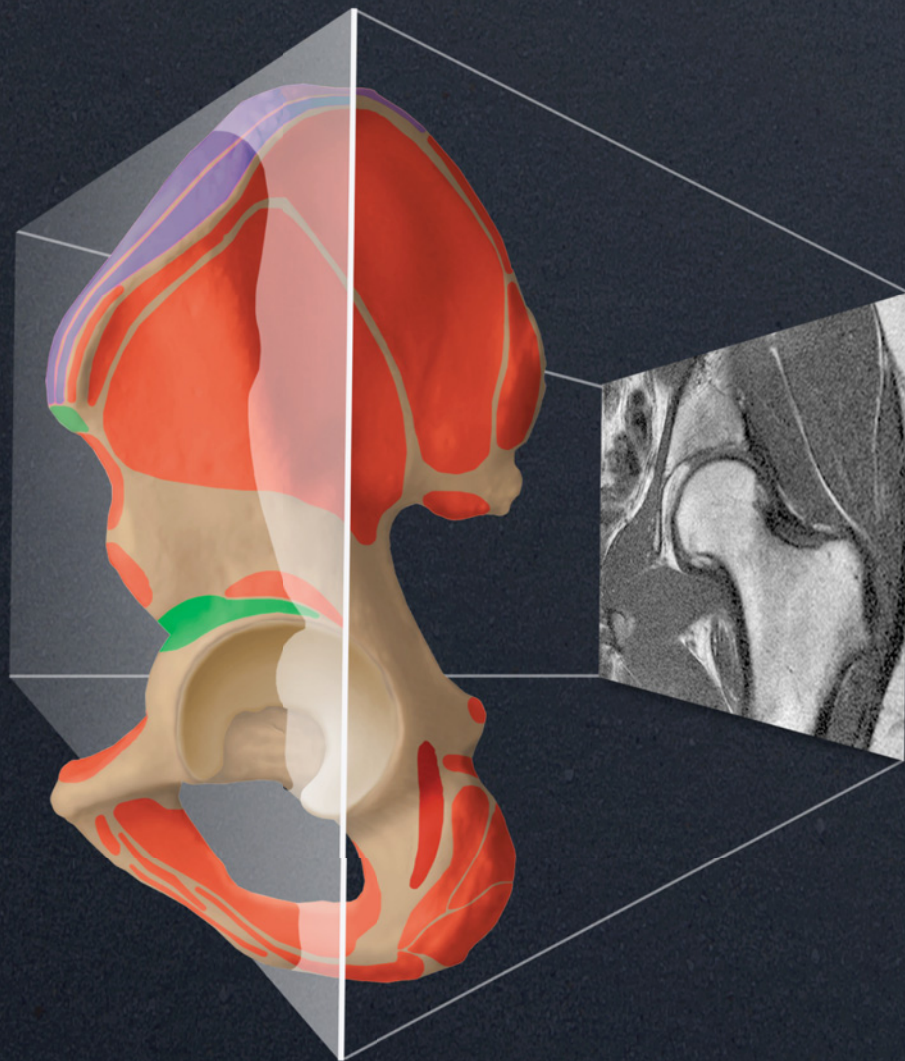
- 1084 **Intrinsic Muscles of Foot**
Julia Crim, MD
- 1090 **Tarsometatarsal Joint**
Julia Crim, MD
- 1096 **Metatarsophalangeal Joints**
Julia Crim, MD
- 1100 **Foot and Ankle Normal Variants and Imaging Pitfalls**
Julia Crim, MD and Zehava Sadka Rosenberg, MD
- 1128 **Foot and Ankle Measurements and Lines**
Julia Crim, MD

This page intentionally left blank

IMAGING ANATOMY
Musculoskeletal

SECOND EDITION

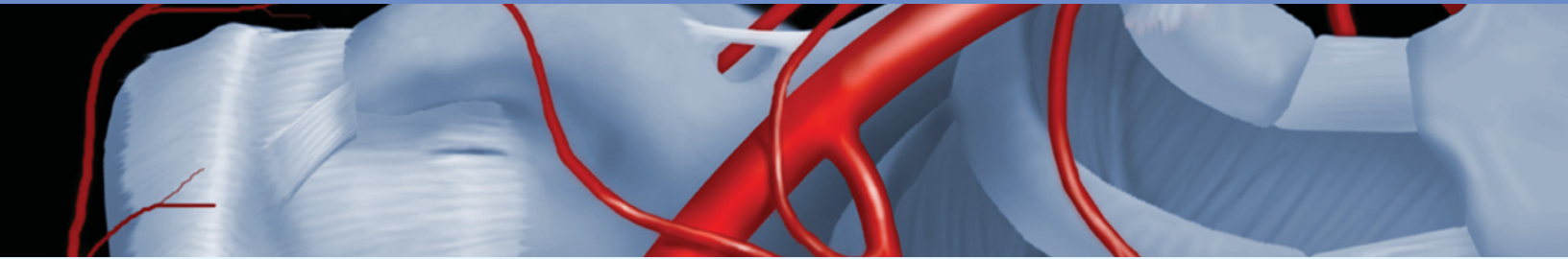
MANASTER | CRIM



This page intentionally left blank

SECTION 1

Shoulder



Shoulder Overview	4
Shoulder Radiographic and Arthrographic Anatomy	14
Shoulder MR Atlas	36
Shoulder Abduction-External Rotation (ABER) Plane	86
Shoulder: Rotator Cuff and Biceps Tendon	94
Shoulder: Rotator Interval	102
Shoulder Ligaments	112
Shoulder Labrum	126
Shoulder Normal Variants and Imaging Pitfalls	138

GROSS ANATOMY

Overview

- Multiaxial ball-and-socket joint
- Hemispheric humeral head articulates with shallow pear-shaped glenoid fossa
 - Joint surrounded by synovial-lined fibrous capsule
 - Glenoid deepened by labrum, a fibrocartilage rim of tissue
 - Cartilage thins in central glenoid and in periphery of humeral head
- **Range of motion:** Flexion, extension, abduction, adduction, circumduction, medial rotation, and lateral rotation
 - **Flexion:** Pectoralis major, deltoid, coracobrachialis, & biceps muscles
 - **Extension:** Deltoid & teres major muscles
 - If against resistance, also latissimus dorsi & pectoralis major
 - **Abduction:** Deltoid & supraspinatus muscles
 - Subscapularis, infraspinatus, & teres minor exert downward traction
 - Supraspinatus contribution controversial
 - **Medial rotation:** Pectoralis major, deltoid, latissimus dorsi, & teres major muscles
 - Subscapularis when arm at side
 - **Lateral rotation:** Infraspinatus, deltoid, & teres minor muscles
- **Joint stabilizers**
 - Skeletally unstable joint
 - Superior support by coracoacromial arch
 - Anterior support by subscapularis tendon, anterior capsule, synovial membrane, anterior labrum and superior, middle, & inferior glenohumeral ligaments
 - Posterior support by infraspinatus and teres minor tendons, posterior capsule, synovial membrane, posterior labrum, & inferior glenohumeral ligament
- **Vascular supply**
 - Articular branches of anterior and posterior humeral circumflex arteries and transverse scapular artery
- **Innervation**
 - Axillary and suprascapular nerves

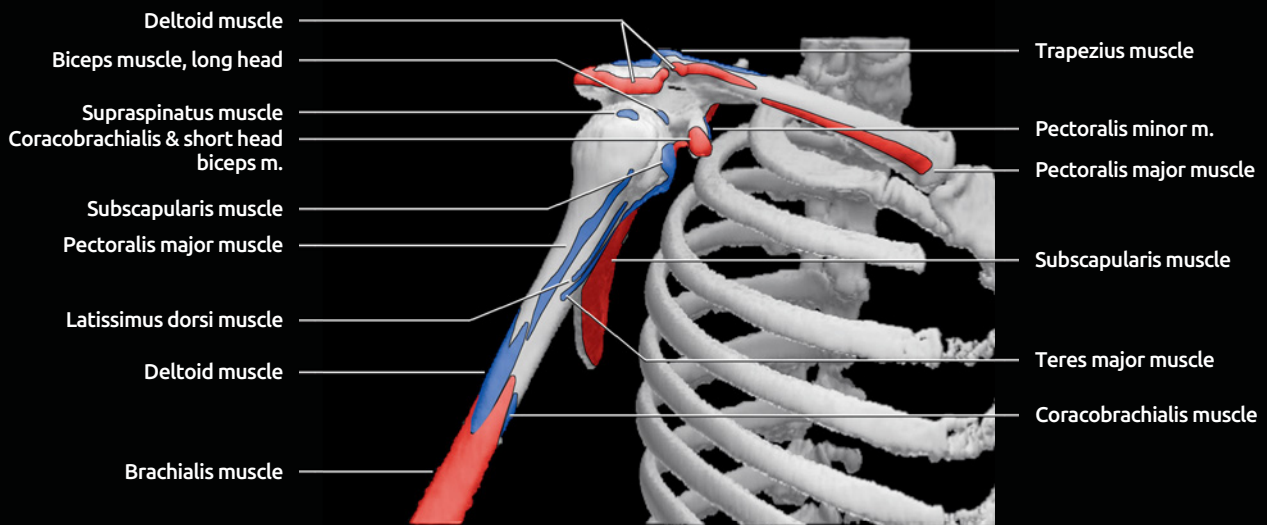
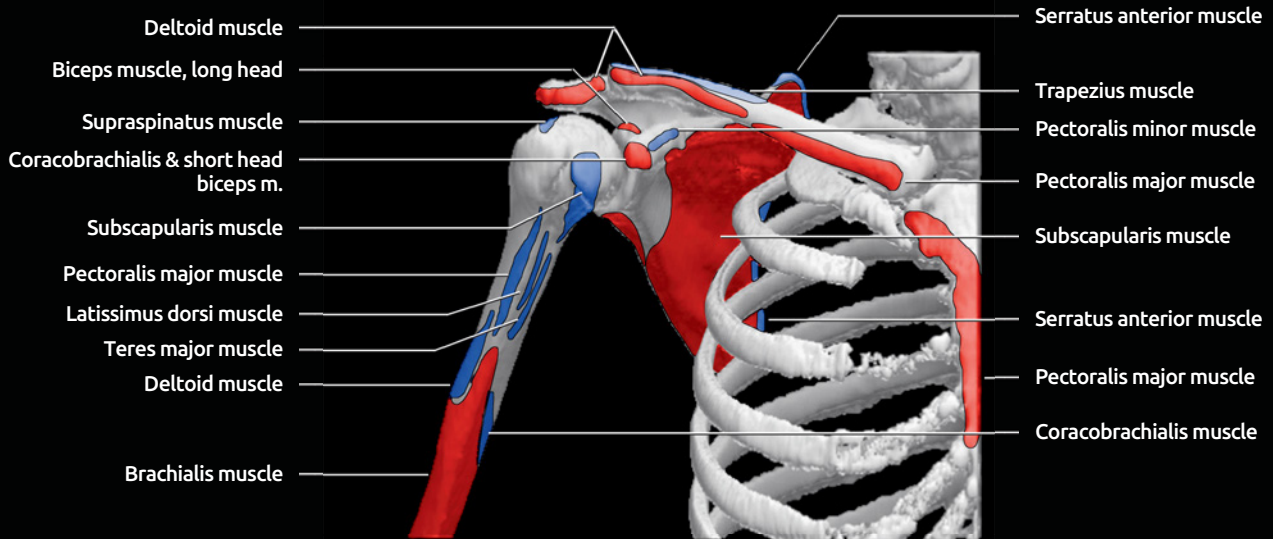
IMAGING ANATOMY

Overview

- **Humerus**
 - 8 ossification centers: Shaft, head, greater tuberosity, lesser tuberosity, capitulum, trochlea, medial, & lateral epicondyles
 - Anatomic neck located along base of articular surface, region of fused epiphyseal plate, and attachment of joint capsule
 - Surgical neck located 2 cm distal to anatomic neck, below greater and lesser tuberosities, extracapsular, most common site of fracture
 - **Greater tuberosity** anterolateral on humeral head
 - Attachment of supraspinatus, infraspinatus, & teres minor tendons
 - **Lesser tuberosity** located along proximal anterior humeral head, medial to greater tuberosity
 - Attachment of subscapularis tendon
- Intertubercular or bicipital groove
 - Between greater and lesser tuberosities
 - Transverse ligament, an extension of subscapularis tendon, forms roof of groove
 - Contains long head of biceps tendon & anterolateral branch of anterior circumflex humeral artery and vein
- **Scapula**
 - **Acromion**
 - Acromion orientation ranges from flat to sloping, mediolaterally
 - Roughly classified into 4 types based on posterior to anterior shape
 - Type I: Flat
 - Type II: Curved, paralleling humeral head
 - Type III: Anterior hooked
 - Type IV: Convex undersurface
 - Low-lying, anterior downsloping or inferolateral tilt decreases volume of coracoacromial outlet
 - **Os acromiale**
 - Ununited acromial ossification center
 - Should fuse by 25 years of age
 - Incidence of persistent ossicle: 2-10%
 - 60% bilateral
 - Four types: Mesoacromion, metaacromion, preacromion, basi-acromion
 - **Glenoid**
 - Shallow, oval recess
 - Fibrocartilage labrum increases depth
 - **Coracoid process**
 - May extend lateral to plane of glenoid
 - Normal distance between coracoid and lesser tuberosity > 11 mm with arm in internal rotation
- **Clavicle**
 - Acromioclavicular joint between distal clavicle & acromion
 - 20° range of motion
 - Synovial-lined joint capsule
 - Fibrocartilage-covered ends of bone & central fibrocartilage disk
- **Bone marrow**
 - Predominantly yellow marrow in adults with residual hematopoietic red marrow in glenoid and proximal humeral metaphysis
 - Often strikingly heterogeneous in distribution
- **Glenohumeral joint space**
 - 1-2 ml synovial fluid
 - Normal communication with biceps tendon sheath
 - Normal communication with subscapular recess
 - Posterior joint capsule typically inserts on base of labrum
 - Anterior joint capsule has variable insertion
- **Anterior joint capsule insertion**
 - Type 1: Inserts at tip or base of labrum
 - Type 2: Inserts scapular neck < 1 cm from labrum
 - Type 3: Inserts scapular neck > 1 cm from labrum
- **Subscapular recess**
 - Between scapula & subscapularis muscle and tendon
 - Joint communication via foramen of Weitbrecht: Between superior and middle glenohumeral ligaments
 - Joint communication via foramen of Rouvière: Between middle and inferior glenohumeral ligaments

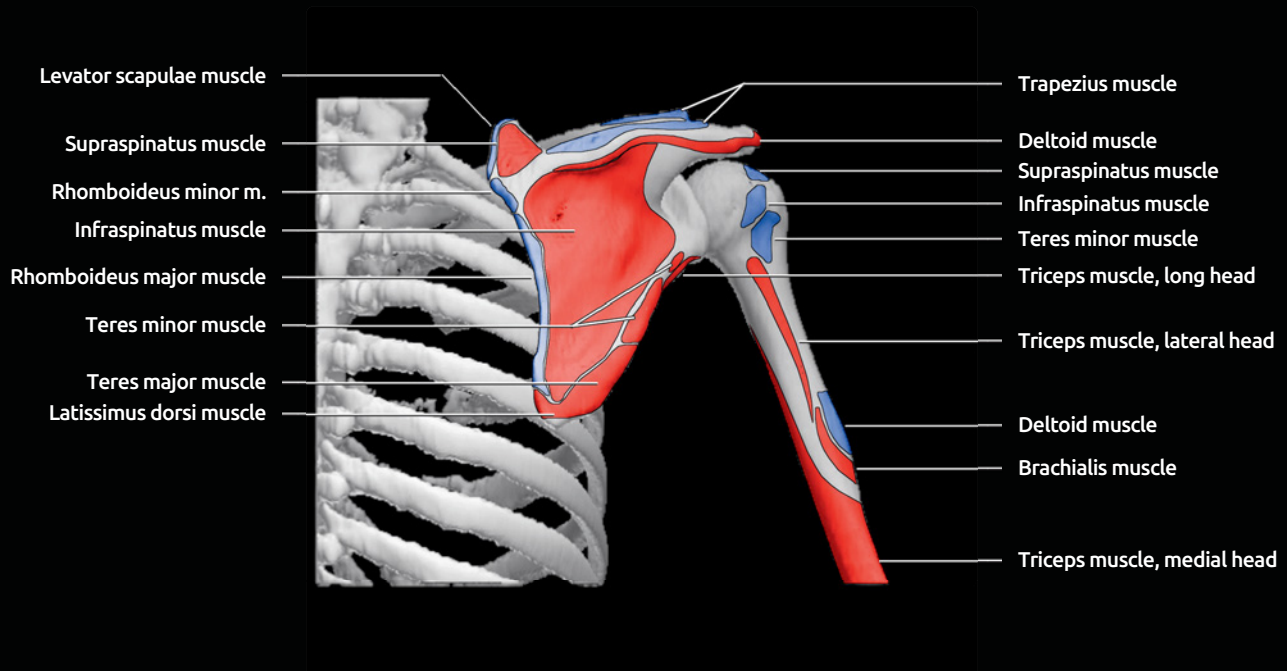
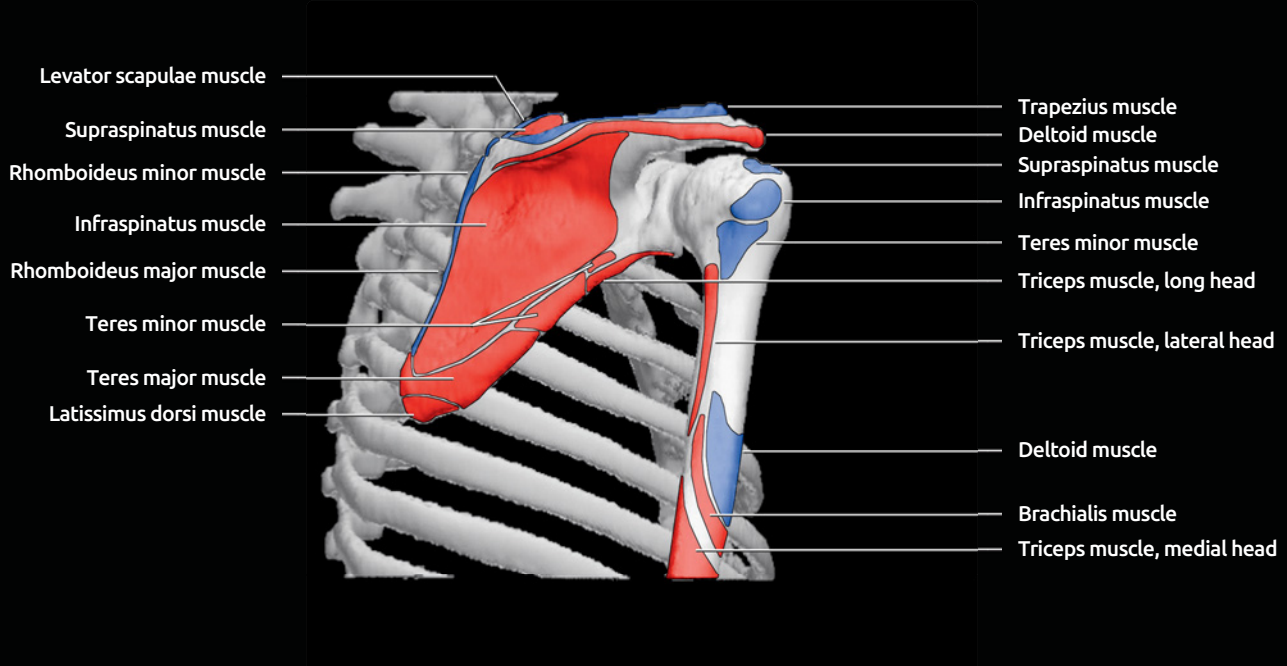
- Normally opacified during arthrography
 - **Rotator cuff**
 - Supraspinatus, infraspinatus, subscapularis, and teres minor
 - Tendons interdigitate forming continuous band at attachment to humerus
 - **Origins**
 - Supraspinatus: Supraspinatus fossa of scapula
 - Infraspinatus: Infraspinatus fossa of scapula
 - Teres minor: Lateral scapular border
 - Subscapularis: Anterior scapular surface (subscapular fossa)
 - **Insertions**
 - Supraspinatus, infraspinatus, and teres minor insert on the greater tuberosity
 - Supraspinatus has a direct component that inserts on anterior portion of tuberosity and posterior oblique component that undercuts the infraspinatus at posterior portion of tuberosity
 - Subscapularis inserts on lesser tuberosity
 - **Ligaments**
 - Coracoacromial ligament
 - Anterior 2/3 of coracoid to tip of acromion
 - Coracoclavicular ligament
 - Stabilizes acromioclavicular joint
 - Base of coracoid process to clavicle
 - Conoid (medial) & trapezoid (lateral) bands have common origin on coracoid, diverge to clavicle
 - Coracohumeral ligament
 - Lateral base of coracoid to lesser & greater tuberosities
 - Blends with subscapularis tendon, supraspinatus tendon, joint capsule, & superior glenohumeral ligament
 - Superior & inferior acromioclavicular ligaments
 - Superior, middle, & inferior glenohumeral ligaments
 - Superior and middle glenohumeral ligaments extend from superior glenoid region to lesser tuberosity
 - Congenitally absent or diminutive middle glenohumeral ligament in 30% of population
 - Inferior glenohumeral ligament (anterior band, posterior band, & axillary pouch) extends from inferior labrum to humeral anatomic neck
 - **Capsulolabral complex**
 - Labrum
 - Oval fibrocartilage tissue along glenoid rim
 - Hyaline cartilage may lie between labrum & bone (undercutting labrum)
 - Varies in shape, size, and appearance
 - Anatomic variants, most common in anterosuperior region, include sublabral foramen & Buford complex
 - Biceps tendon
 - Long head arises from supraglenoid tubercle or superior labrum
 - Long head may be congenitally absent
 - Long head may arise from intertubercular groove or joint capsule
 - Short head originates at coracoid process as conjoined tendon with coracobrachialis
 - Additional heads are rarely present and arise from brachialis muscle, intertubercular groove or greater tubercle
 - **Bursae**
 - Subacromial-subdeltoid bursa
 - Normally contains a minimal amount of fluid
 - Adherent to undersurface of acromion
 - Lies superficial to rotator cuff
 - Subcoracoid bursa
 - Separate from normal subscapular recess of joint
 - Between subscapularis tendon and coracobrachialis/short head of biceps tendon
 - Can communicate with subacromial-subdeltoid bursa
 - Does not normally communicate with joint
 - Infraspinatus bursa
 - Between infraspinatus tendon and joint capsule
 - Can rarely communicate with joint
 - Other less common bursae
 - Deep to coracobrachialis muscle
 - Between teres major & long head of triceps
 - Anterior & posterior to latissimus dorsi tendon
 - Superior to acromion
 - **Additional muscles of upper arm**
 - Deltoid, biceps, coracobrachialis, triceps
 - **Extrinsic shoulder muscles**
 - Trapezius, latissimus dorsi, levator scapulae, major & minor rhomboids, serratus anterior, subclavius, omohyoid, pectoralis major, pectoralis minor
- ### Internal Contents
- **Quadrilateral or quadrangular space**
 - Teres minor, superior border
 - Teres major, inferior border
 - Humerus, lateral border
 - Long head triceps, medial border
 - Contains axillary nerve and posterior circumflex humeral artery
 - **Coracoacromial arch**
 - Acromion, superior border
 - Humeral head, posterior border
 - Coracoid process and coracoacromial ligament, anterior border
 - Contains subacromial-subdeltoid bursa, supraspinatus muscle/tendon, long head of biceps
 - **Rotator interval**
 - Triangular space between inferior border of supraspinatus muscle/tendon and superior border of subscapularis muscle/tendon
 - Medially bordered by coracoid process
 - Laterally bordered by transverse humeral ligament
 - Anterior border formed by coracohumeral ligament, superior glenohumeral ligament, & joint capsule

3D CT RECONSTRUCTION, MUSCLE ORIGINS & INSERTIONS



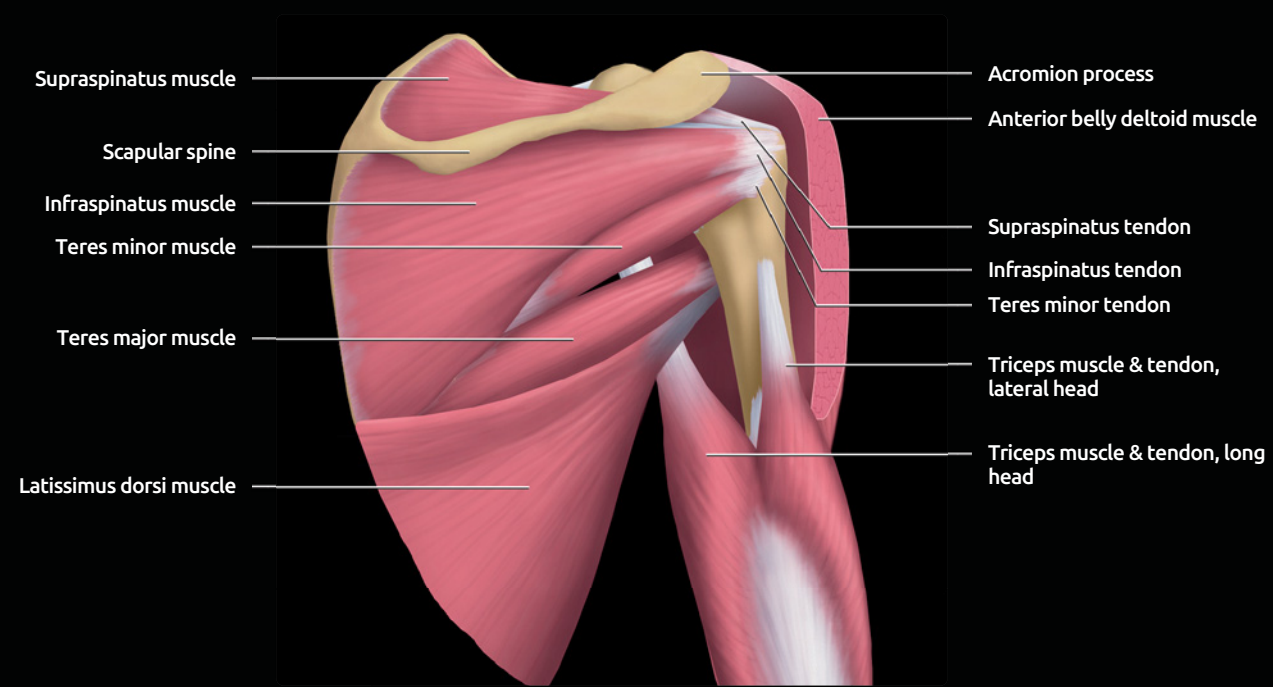
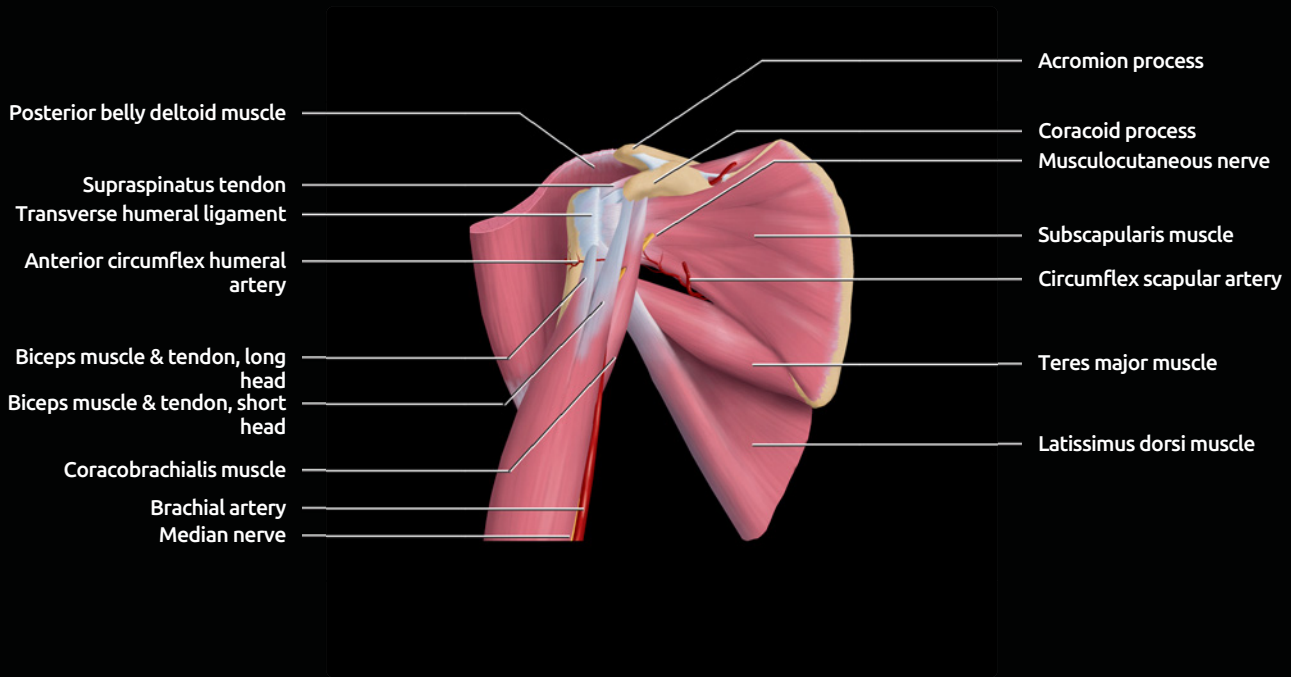
(Top) Anterior view of the right shoulder from a 3D CT reconstruction is shown. Muscle origins are shown in red. Muscle insertions are shown in blue. **(Bottom)** Anterior oblique view of the shoulder is shown.

3D CT RECONSTRUCTION, MUSCLE ORIGINS & INSERTIONS



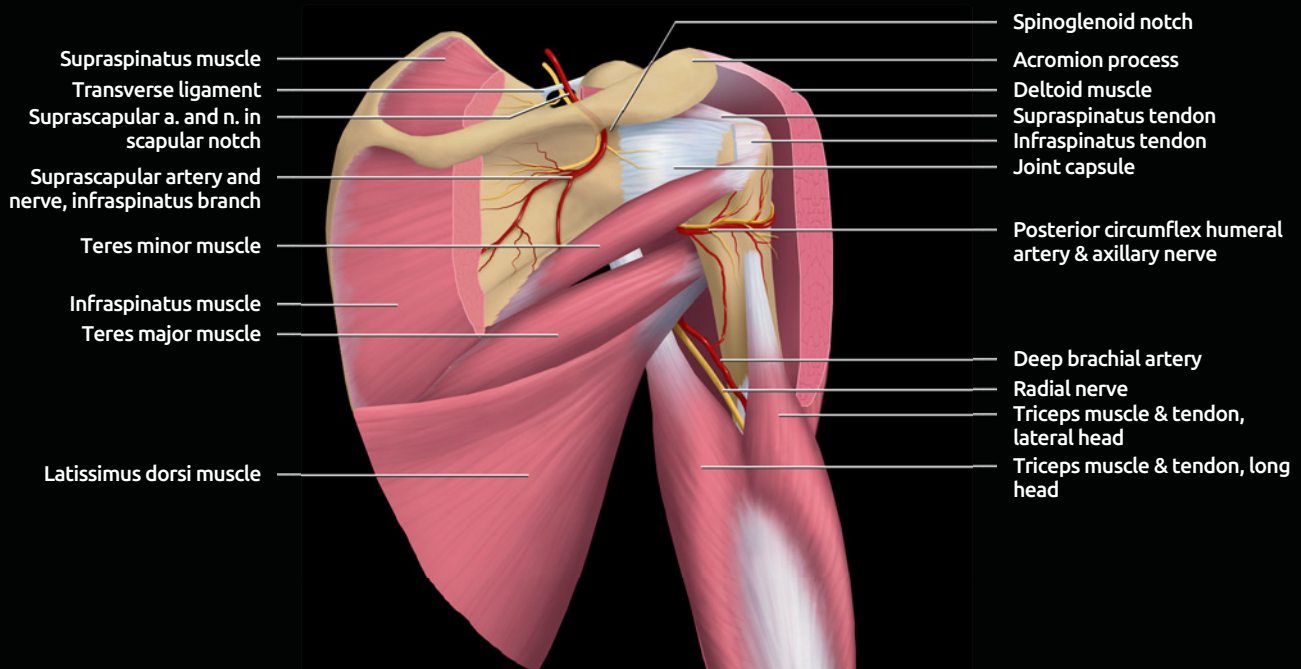
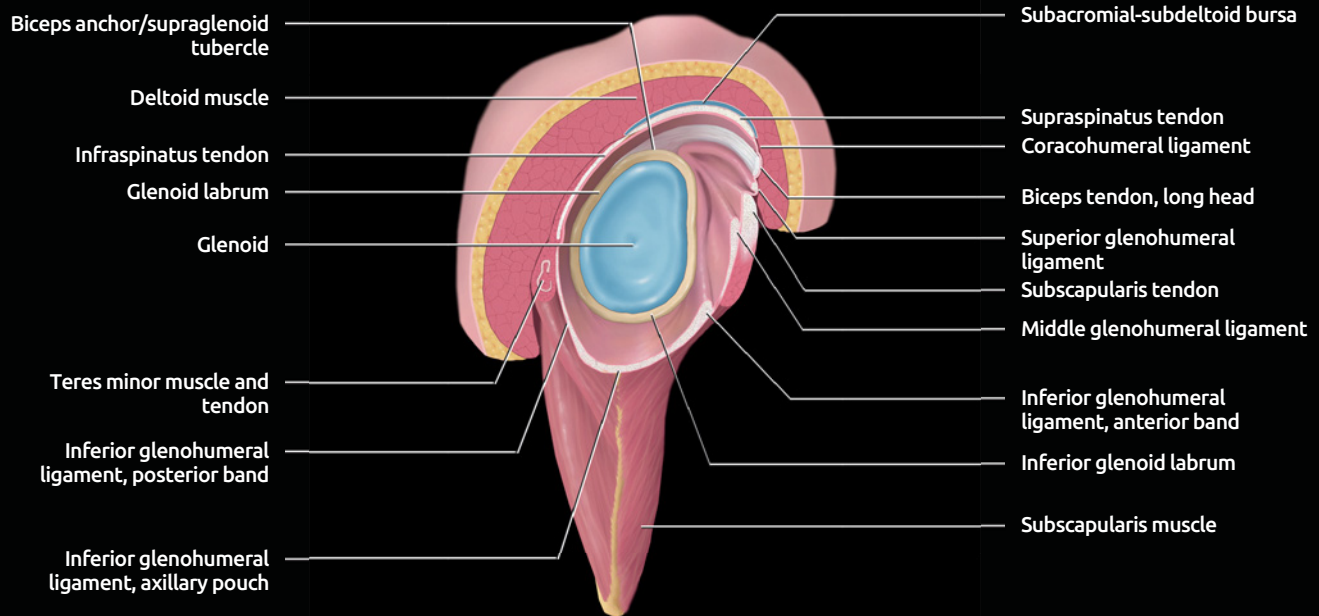
(Top) Posterior oblique view of the shoulder from a 3D CT reconstruction is shown. Muscle origins are shown in red. Muscle insertions are shown in blue. **(Bottom)** Posterior view of the shoulder is shown.

GRAPHICS: ANTERIOR, POSTERIOR SHOULDER MUSCULATURE



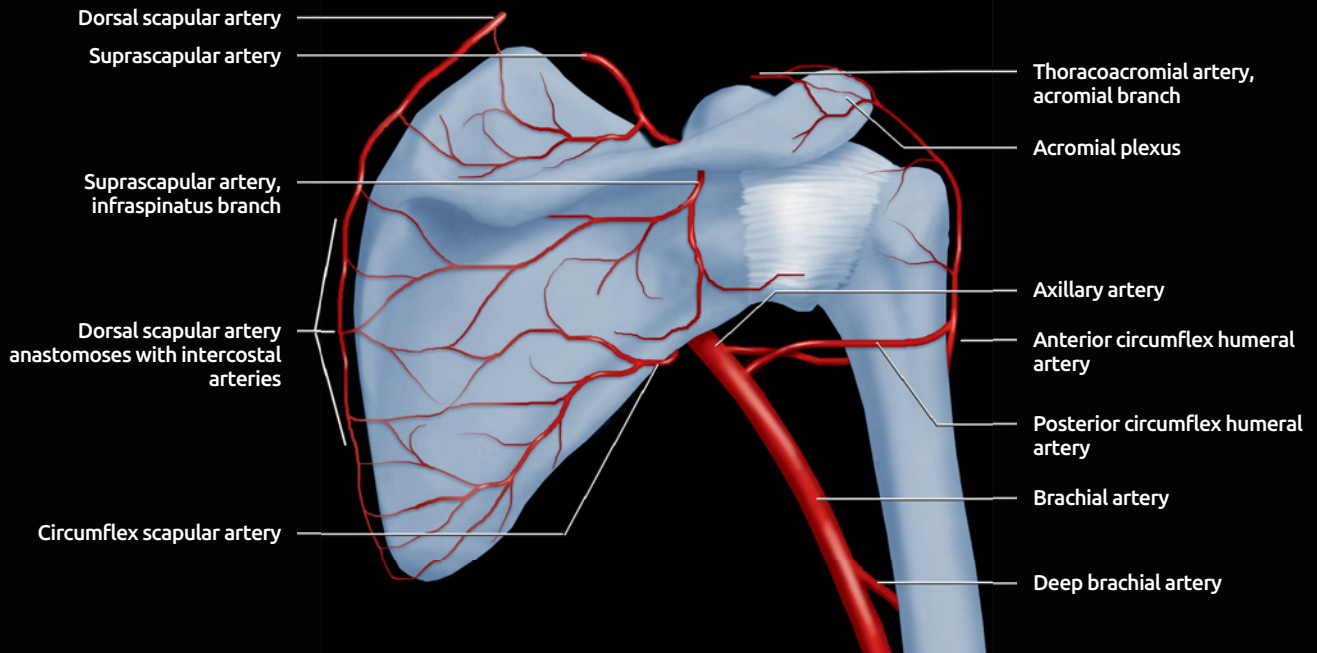
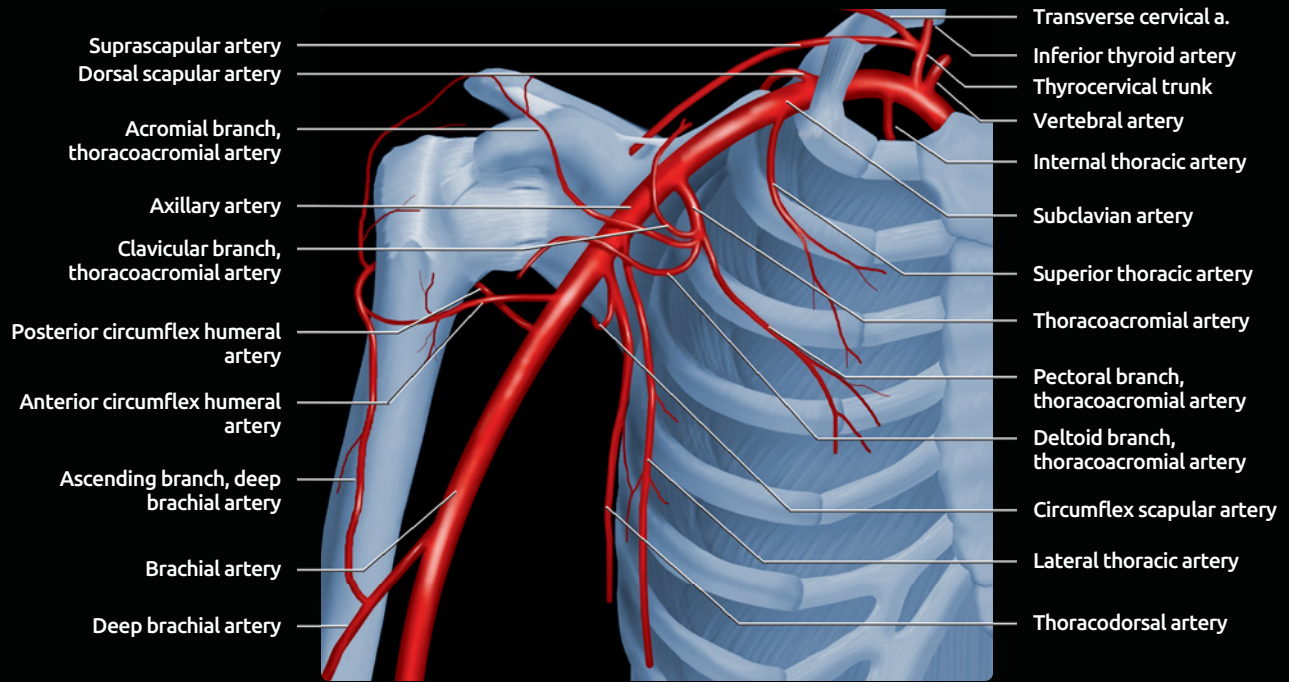
(Top) Anterior graphic of the shoulder shows a superficial scapulohumeral dissection. **(Bottom)** Posterior graphic of the shoulder shows superficial scapulohumeral dissection demonstrating the musculature.

GRAPHICS: ROTATOR CUFF & NEUROVASCULAR STRUCTURES



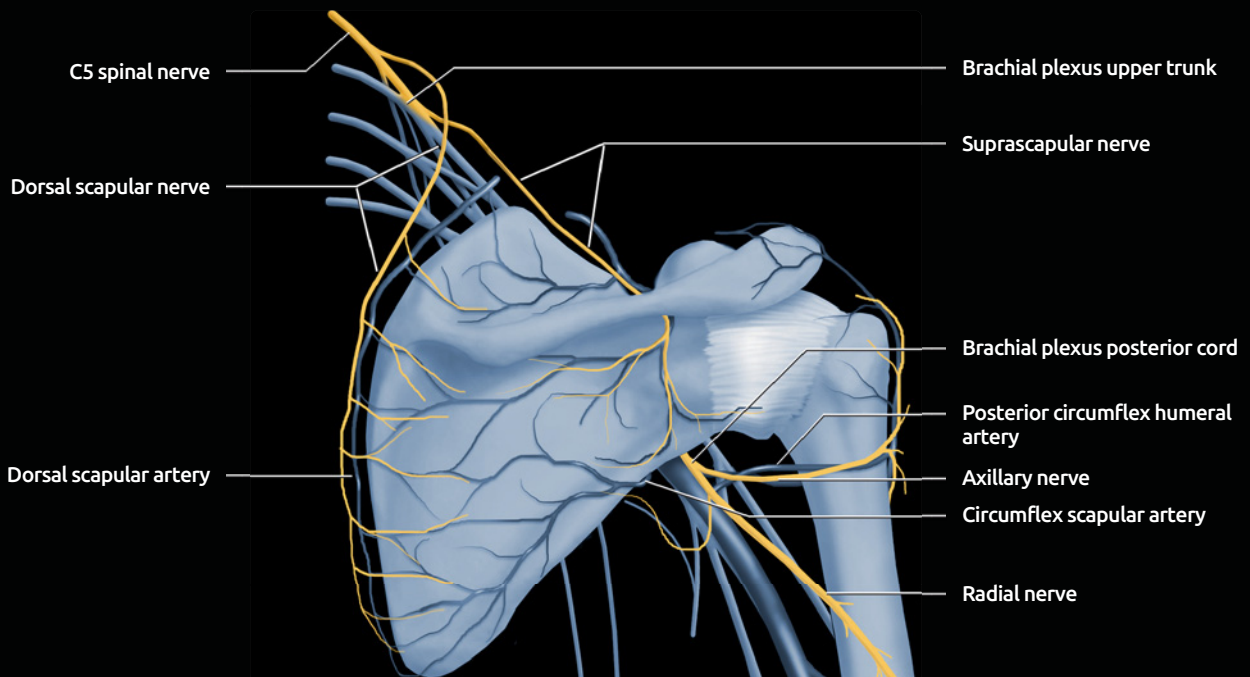
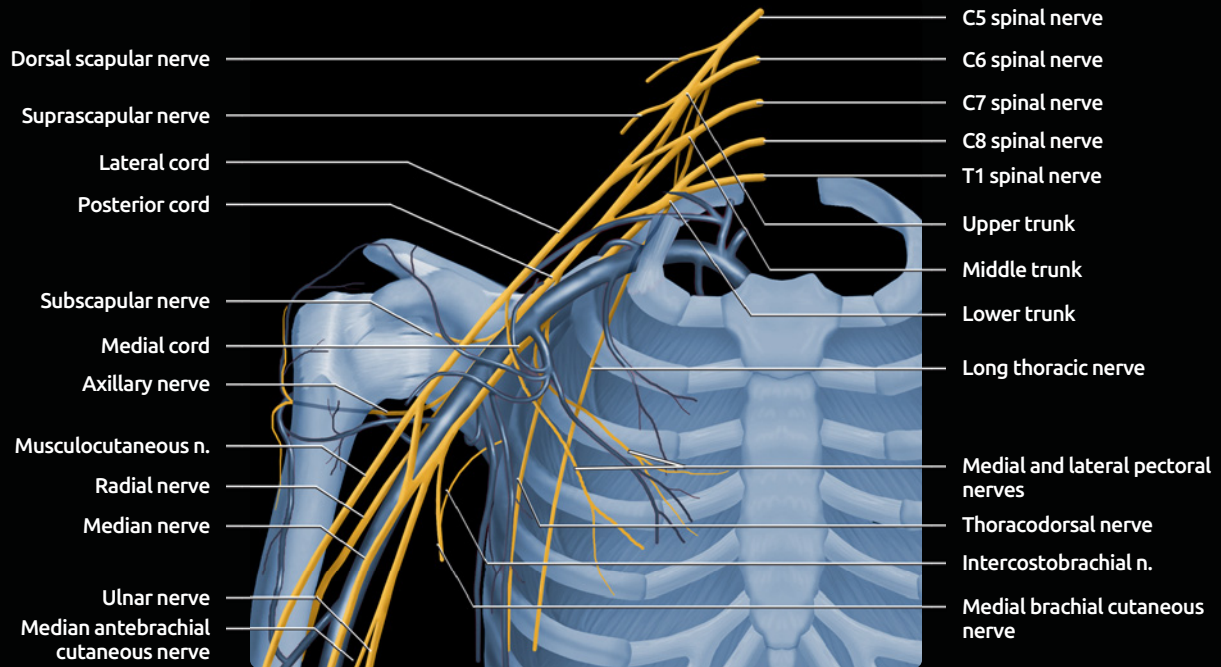
(Top) Sagittal graphic of the shoulder shows the humerus removed. (Bottom) Deep scapulohumeral dissection demonstrates the major neurovascular structures.

GRAPHICS: VASCULAR STRUCTURES



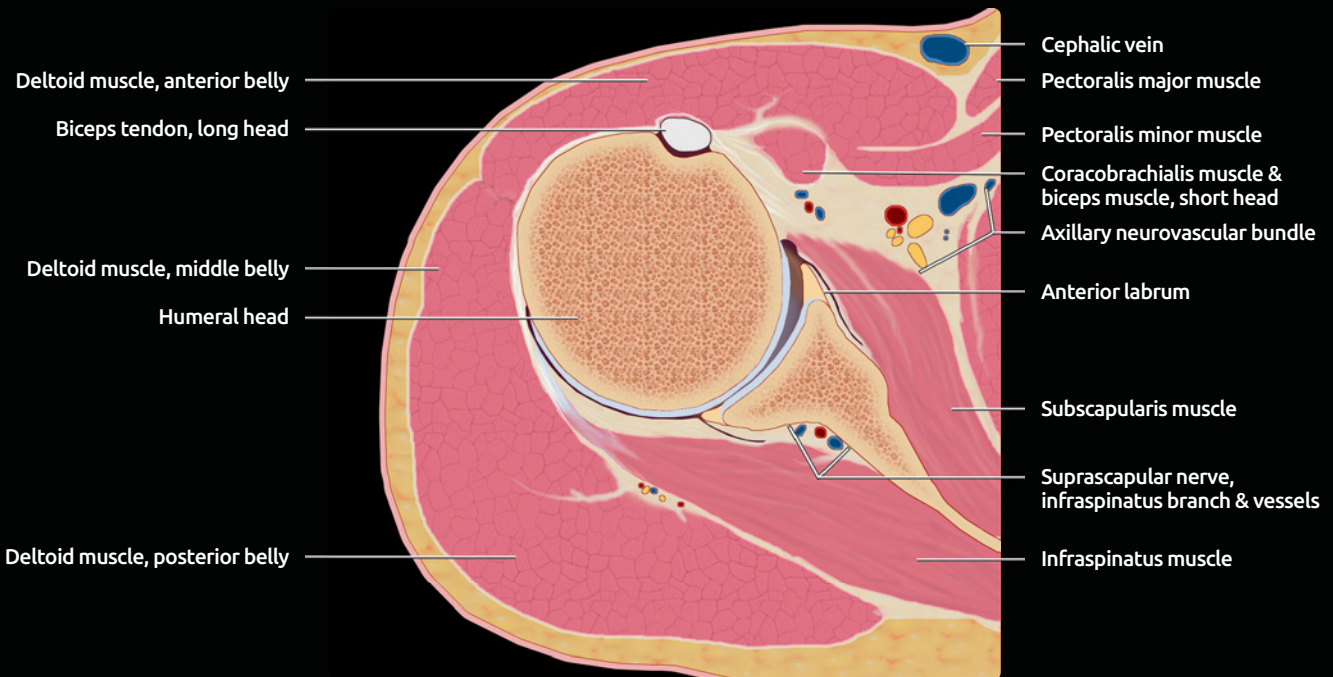
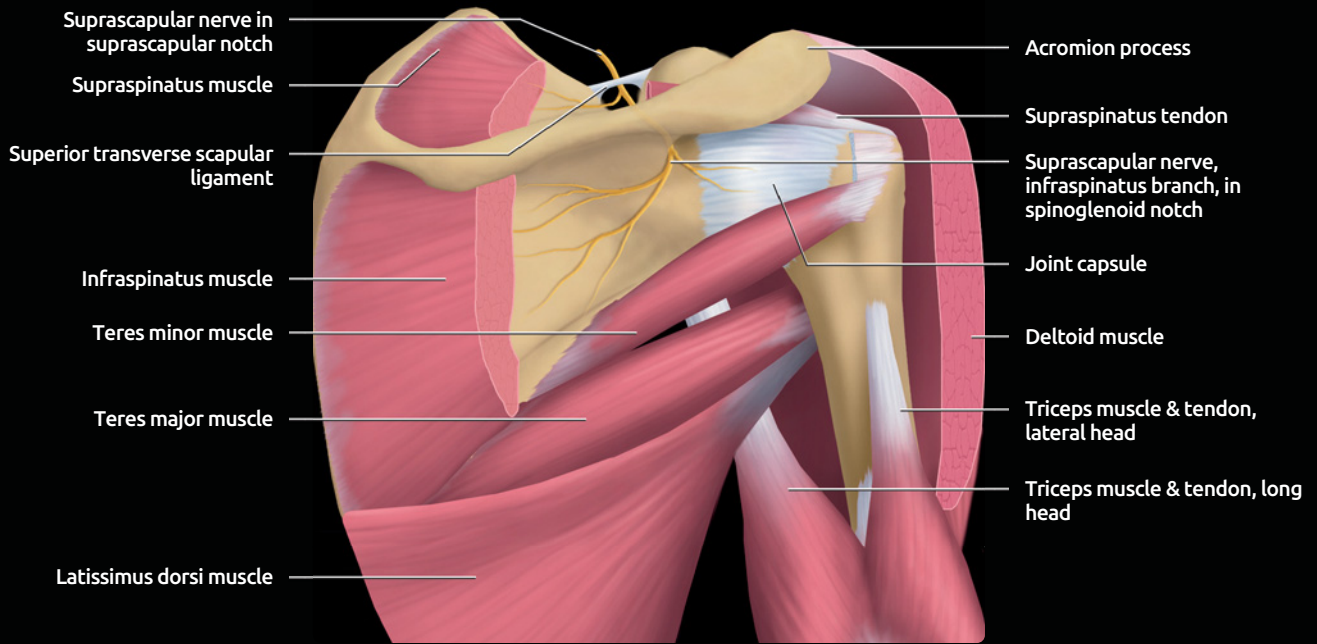
(Top) Anterior graphic of arterial supply to shoulder is shown. The shoulder is predominantly supplied by anterior and posterior circumflex humeral, suprascapular and circumflex scapular arteries. **(Bottom)** Posterior graphic of arterial supply to shoulder is shown. Extensive collateral blood vessels include anastomoses with intercostal arteries.

GRAPHICS: NEURAL STRUCTURES



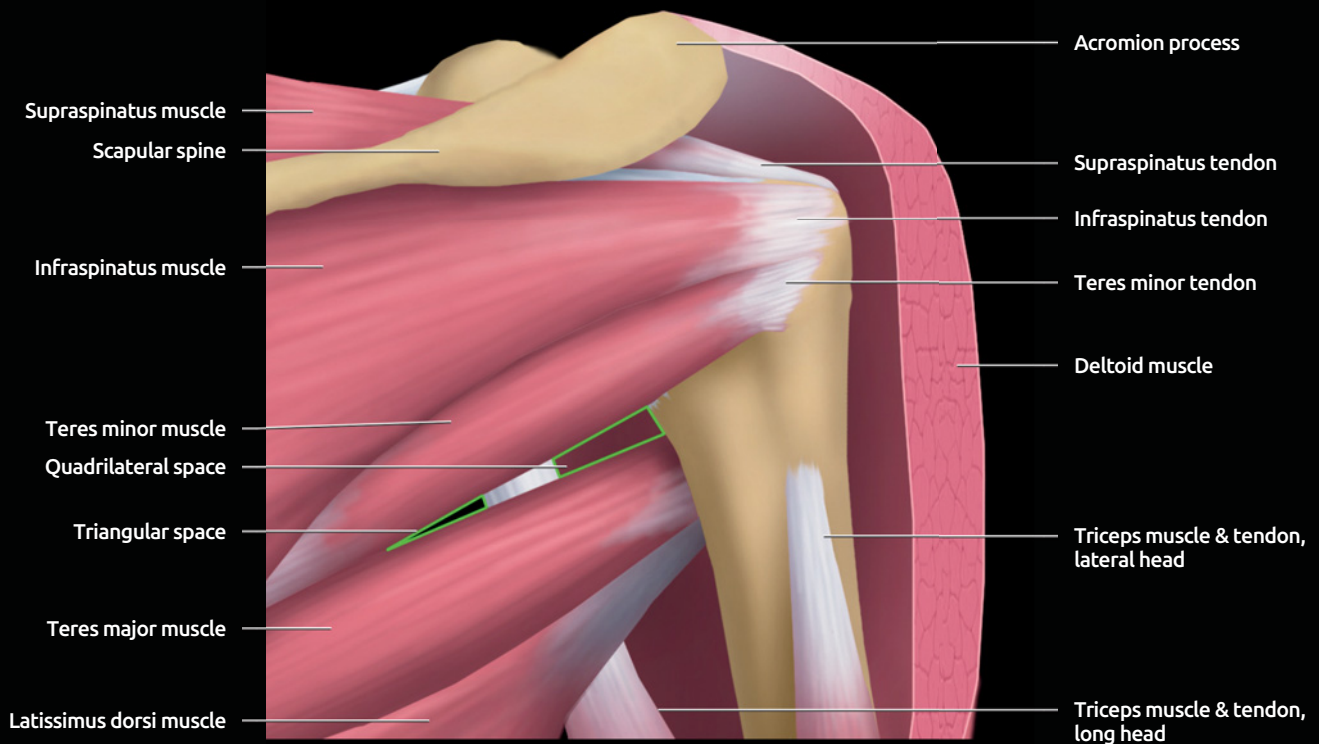
(Top) Anterior graphic of the brachial plexus is shown. **(Bottom)** Posterior graphic of the brachial plexus branches innervating the shoulder is shown.

GRAPHICS: SUPRASCAPULAR & SPINOGLENOID NOTCH



(Top) Deep scapulohumeral dissection shows the course of the suprascapular nerve. **(Bottom)** Axial graphic shows the location of the suprascapular artery, nerve and vein branches, just below the level of the spinoglenoid notch.

GRAPHICS: QUADRILATERAL SPACE



Posterior graphic of the shoulder is shown. Superficial scapulohumeral dissection shows the location of the quadrilateral space and triangular space (each outlined in green).

IMAGING ANATOMY

Overview

- Shoulder joint highly mobile, prone to instability
 - Rotator cuff and glenohumeral ligaments stabilize
 - Small contribution by glenoid labrum
- **Joint capsule**
 - Extends from glenoid margin or scapular neck to anatomic neck of humerus
 - Normal joint recesses are visualized at arthrography
 - Axillary, subscapularis, rotator interval, anterior and posterior recesses, biceps tendon sheath
- **Glenoid**
 - Anteverted, forms shallow cup
 - Central cartilage defect is small, smoothly marginated region that varies slightly in position
- **Glenoid labrum**
 - Fibrocartilaginous structure extending circumferentially around bony glenoid
 - Sits on articular surface, overlies hyaline cartilage
 - Deepens bony glenoid, improves joint congruency and stability
 - In cross section may appear triangular or rounded
 - Anterior labrum larger than posterior
- **Rotator cuff:** 4 muscles arising on scapula and inserting on humerus
 - Supraspinatus: From supraspinatus fossa of scapula to greater tuberosity
 - Abducts humerus, also depresses humeral head
 - Infraspinatus: From posterior surface of scapula to greater tuberosity
 - Externally rotates humerus
 - Teres minor: From lateral border of scapula to greater tuberosity
 - Externally rotates humerus
 - Subscapularis muscle: From anterior surface of scapula to lesser tuberosity
 - Superficial fibers extend across to anterior margin of greater tuberosity as part of transverse ligament
 - Internally rotates, adducts humerus
- **Glenohumeral ligaments:** Thickenings in joint capsule, variable morphology
 - Superior glenohumeral ligament (SGHL)
 - Stabilizes adducted shoulder against inferior subluxation
 - Thin, horizontal band at superior margin of joint
 - Originates glenoid labrum just anterior to biceps tendon
 - Inserts on lesser tuberosity
 - Merges with coracohumeral ligament
 - Middle glenohumeral ligament (MGHL)
 - Stabilizes abducted shoulder
 - Obliquely oriented from superior labrum inferolaterally
 - Originates anterior to SGHL
 - Merges with subscapularis
 - Inserts on lesser tuberosity
 - Enlarged when anterosuperior labrum absent (Buford complex)
 - Inferior glenohumeral ligament (IGHL)
 - Stabilizes abducted shoulder
 - Anterior band: Anteroinferior labrum to surgical neck of humerus
 - Posterior band: Posteroinferior labrum to surgical neck of humerus
- **Coracohumeral ligament (CHL)**
 - Stabilizes long head biceps, forming biceps sling together with SGHL and subscapularis tendon
 - Stabilizes against inferior and posterior subluxation
 - Originates posterior margin coracoid process, inserts greater and lesser tuberosities
 - Broad, thin ligament or capsular fold, with lateral and medial condensations (bands)
 - Lateral band merges with capsule, subscapularis tendon, transverse ligament
 - Attachments can be seen on anterior margin of subscapularis tendon
 - Medial band merges with capsule, SGHL, and distal supraspinatus tendon
- **Rotator interval**
 - Triangular space between supraspinatus, subscapularis tendons
 - Wide medially, narrows laterally, ends at attachments of supraspinatus and subscapularis to humerus
 - Roof formed by CHL
- **Long head of biceps tendon**
 - Originates superior labrum and bony glenoid
 - Extends laterally above humeral head
 - Turns to enter bicipital groove
- **Biceps sling**
 - Stabilizes intraarticular biceps tendon
 - Formed by CHL, SGHL, subscapularis tendon
- **Transverse humeral ligament**
 - Roof of bicipital groove
 - Composed of subscapularis tendon and CHL fibers
- **Posterior rotator interval**
 - Potential space between supraspinatus, infraspinatus tendons

ANATOMY IMAGING ISSUES

Imaging Approaches

- Radiographs
 - Standard views include AP internal rotation, AP external rotation, and axillary views
 - Often a Grashey view (true AP view of glenohumeral joint) is substituted for true AP external rotation view
 - Scapular Y-view to evaluate supraspinatus outlet and assess for dislocation
 - Rockwood view, 30 degrees caudal tilt AP, to evaluate acromion
 - Zanca view, 10-20 degrees cephalic tilt AP, to evaluate acromioclavicular joint
 - Garth apical oblique or West Point axillary view to assess anteroinferior glenoid rim
 - Garth: Patient seated, arm at side, cassette posterior lying parallel to spine of scapula, beam centered at glenohumeral joint angled 45 degrees to plane of thorax and 45 degrees caudal

- West Point axillary: Patient prone, head turned away from involved side, cassette held against superior aspect of shoulder, beam centered at axilla angled 25 degrees downward from horizontal and 25 degrees medial
- Stryker notch view to assess humeral head and base of coracoid process
 - Patient supine, cassette under involved shoulder, palm of hand on top of head with fingers toward back of head
- Arthrography
 - Conventional arthrography
 - Needle placed into glenohumeral joint under fluoroscopic guidance
 - Administer 10 to 12 ml contrast
 - Contrast should remain within joint, without extension into rotator cuff or subacromial-subdeltoid bursa
 - Opacification of subscapular recess & biceps tendon sheath is normal
 - Choice of needle placement for arthrography may depend on site of symptoms &/or patient comfort
 - Rotator interval placement: Most common choice
 - Arm must be rotated externally; patient supine
 - Needle placed high on humeral head, through rotator interval
 - Misplaced injections or partial extravasation least likely with this approach
 - Can result in extravasation into rotator interval mimicking rotator interval tear
 - Inferomedial placement on humeral head
 - Arm rotated externally; patient supine
 - Needle placed inferomedially on humeral head
 - Increased incidence of extravasation into subscapularis tendon, inferior glenohumeral ligament
 - Avoid placing too far medially, on or through labrum
 - Avoid placing in center of humeral head; external rotation compresses capsule at this site, making extravasation more likely
 - Posterior humeral head needle approach (patient in prone position)
 - May be used with anterior complaints, particularly in rotator interval region
 - Procedure: Elevate shoulder with wedge/towels, rotate arm externally
 - High entry point (superomedial humeral head) or low entry point (inferomedial aspect humeral head; has higher risk of extracapsular injection)
 - Potential problem: Posterior rotator interval injection (potential space between supraspinatus and infraspinatus tendons); inadvertent filling occurs when needle is placed superior to humeral head in a posterior approach
 - Expected flow of contrast
 - Easy injection, flowing around cartilage in joint or filling capsule
 - Extraarticular injection may flow freely and mimic filling of capsule; watch anatomy closely during intermittent fluoroscopy
 - Intracartilaginous or intraosseous injection: Puddling of contrast around needle tip
- Injection into substance of capsule or muscle: Usually mixed injection, with contrast entering intraarticular space as well as soft tissue (watch for streaking along muscle/tendon); may mimic tear
- CT arthrography helpful in patients with contraindication to MR
- MR arthrography
 - Best evaluates capsulolabral complex
 - Intraarticular 12 ml dilute gadopentetate dimeglumine (2 mmol/L) mixed with iodinated contrast, Marcaine, & epinephrine according to institutional preference
 - Avoid shoulder exercise prior to imaging to minimize contrast leakage
 - Indirect method utilizes IV gadopentetate dimeglumine followed by exercise prior to imaging
 - T1 FS sequences in axial, coronal oblique, & sagittal oblique planes
 - Optional abduction-external rotation (ABER)
 - Injection of air bubbles can simulate loose bodies
 - High-field MR scanner
 - Dedicated shoulder coil centered on region of interest
 - Patient positioning: Supine, arm neutral to slight external rotation (avoid internal rotation), arm at side & slightly away from side of body

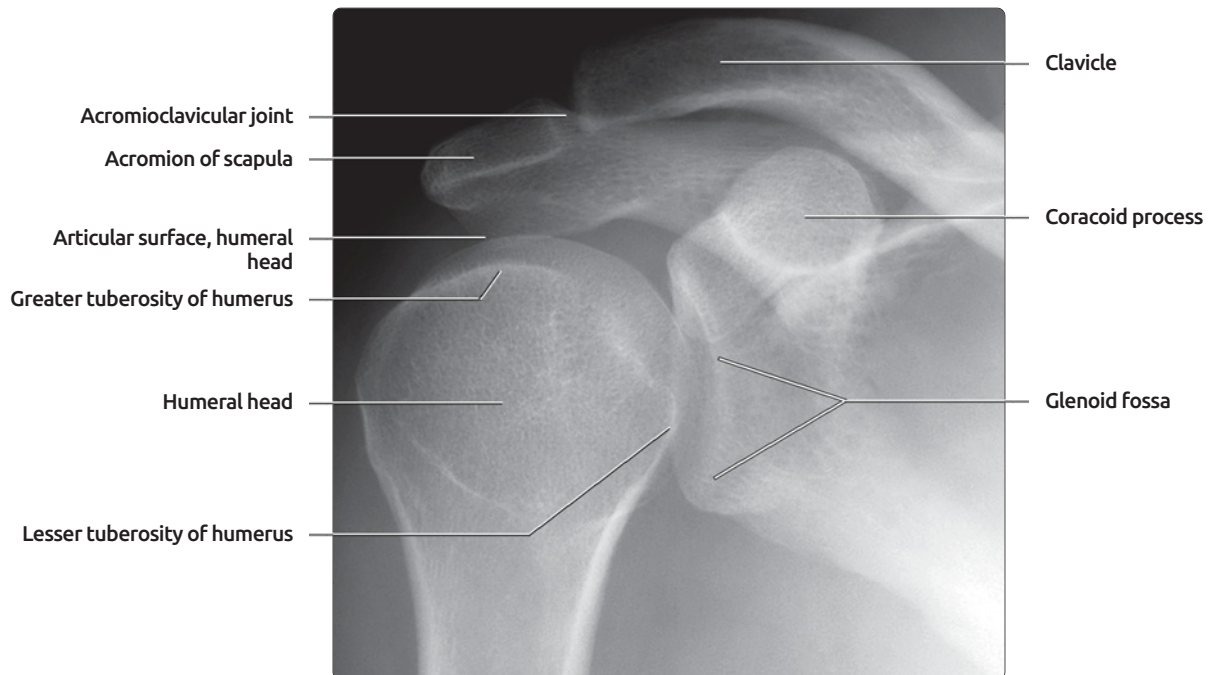
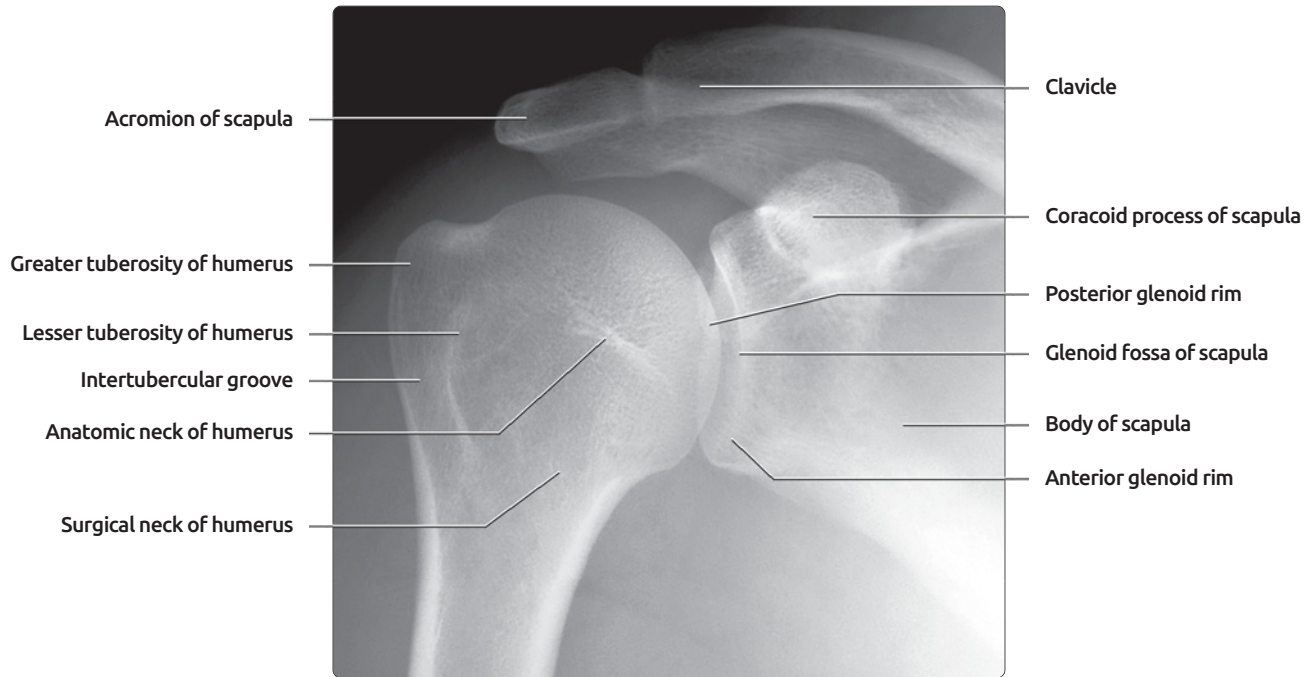
Imaging Pitfalls

- Buford complex: Absent anterosuperior labrum; thick, cord-like MGHL
- Superior labral variations: Superior labrum may have meniscoid configuration at and anterior to biceps anchor
- Injection between fibers of capsule: May mimic capsular tear

SELECTED REFERENCES

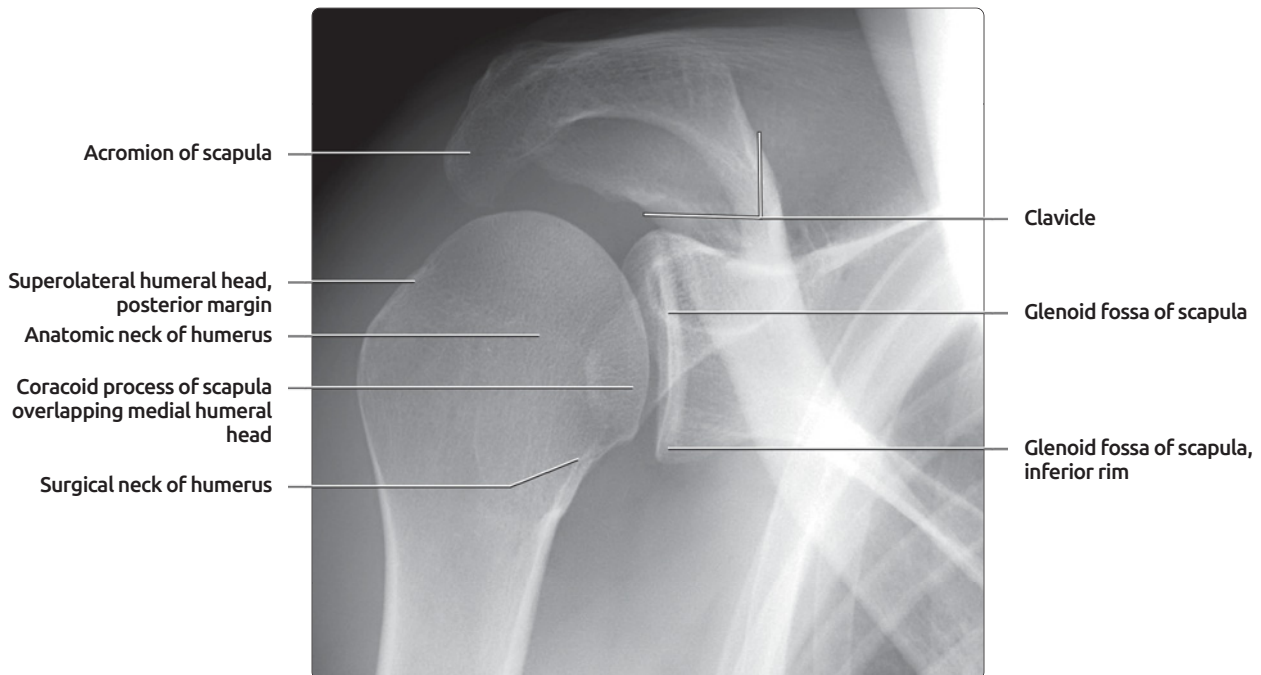
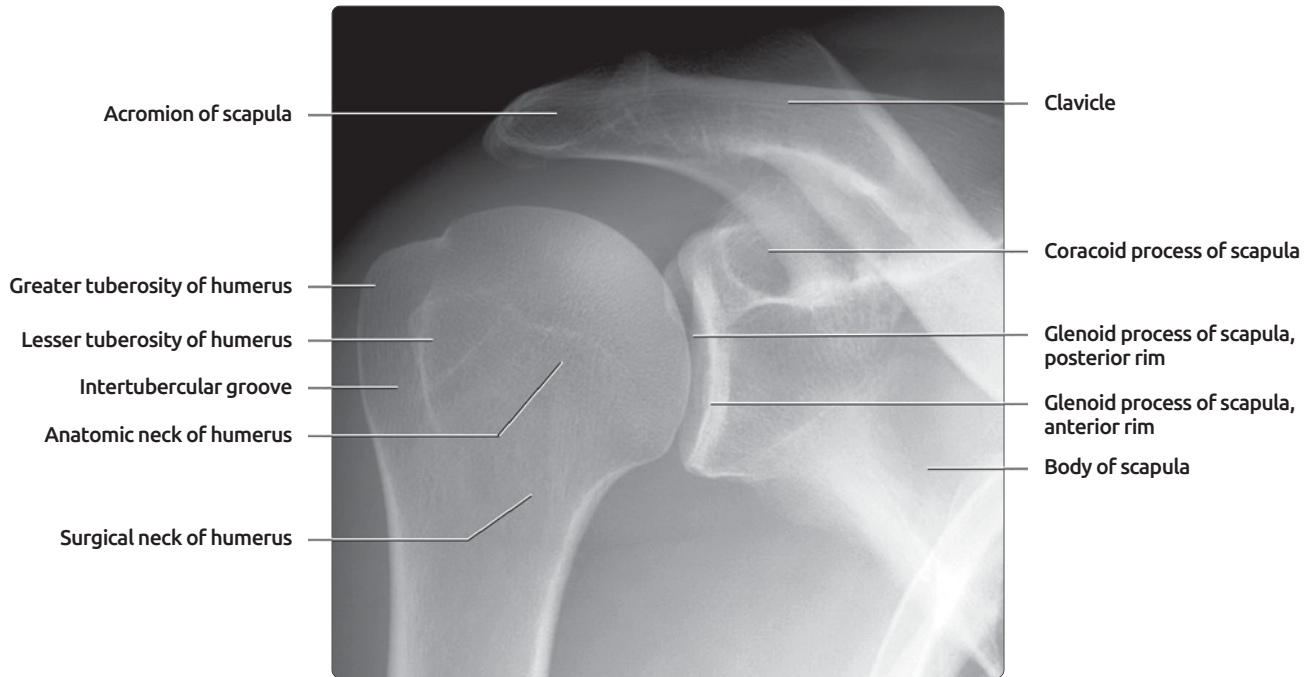
1. Hunt SA et al: The rotator interval: anatomy, pathology, and strategies for treatment. *J Am Acad Orthop Surg.* 15(4):218-27, 2007
2. Krief OP: MRI of the rotator interval capsule. *AJR Am J Roentgenol.* 184(5):1490-4, 2005
3. Morag Y et al: MR arthrography of rotator interval, long head of the biceps brachii, and biceps pulley of the shoulder. *Radiology.* 235(1):21-30, 2005
4. Clark JM et al: Tendons, ligaments, and capsule of the rotator cuff. *Gross and microscopic anatomy. J Bone Joint Surg Am.* 74(5):713-25, 1992

AP EXTERNAL & INTERNAL ROTATION RADIOGRAPHS



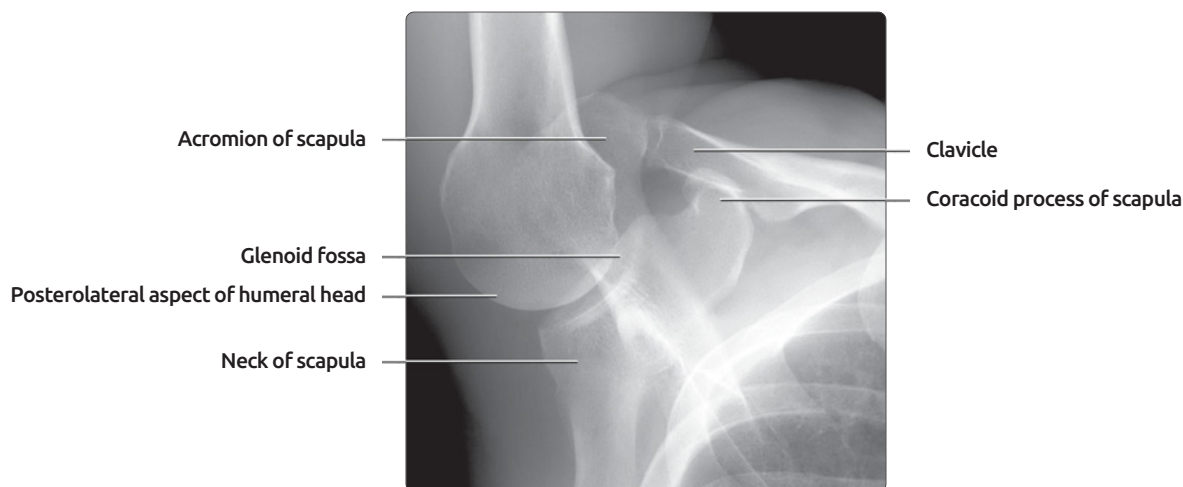
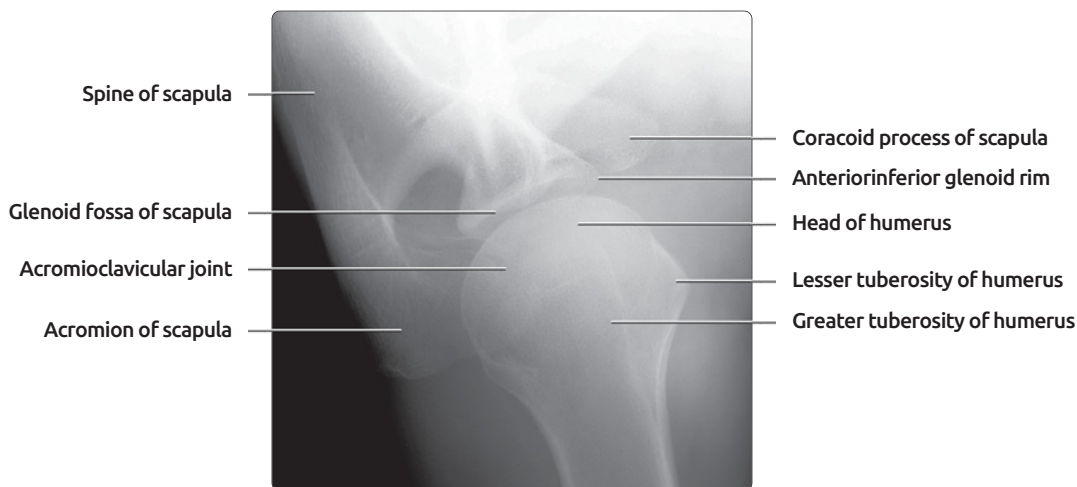
(Top) Standard anteroposterior (AP) external rotation radiograph of shoulder is shown. A standard AP radiograph produces an oblique view of the glenohumeral joint, which has a normal anterior angulation of ~ 40 degrees. The anterior glenoid rim projects medial to the posterior rim on this view. The AP view can be obtained in neutral position, internal rotation, or external rotation. With the arm in external rotation, the greater tuberosity projects at the lateral aspect of the humeral head. **(Bottom)** Standard AP internal rotation radiograph of the shoulder is shown. The lesser tuberosity projects at the medial aspect of the humeral head. The greater tuberosity has rotated anteriorly and its superior margin forms a dense line inferior to the articular surface. The posterolateral aspect of the humeral head projects laterally.

GRASHEY & GARTH RADIOGRAPHS



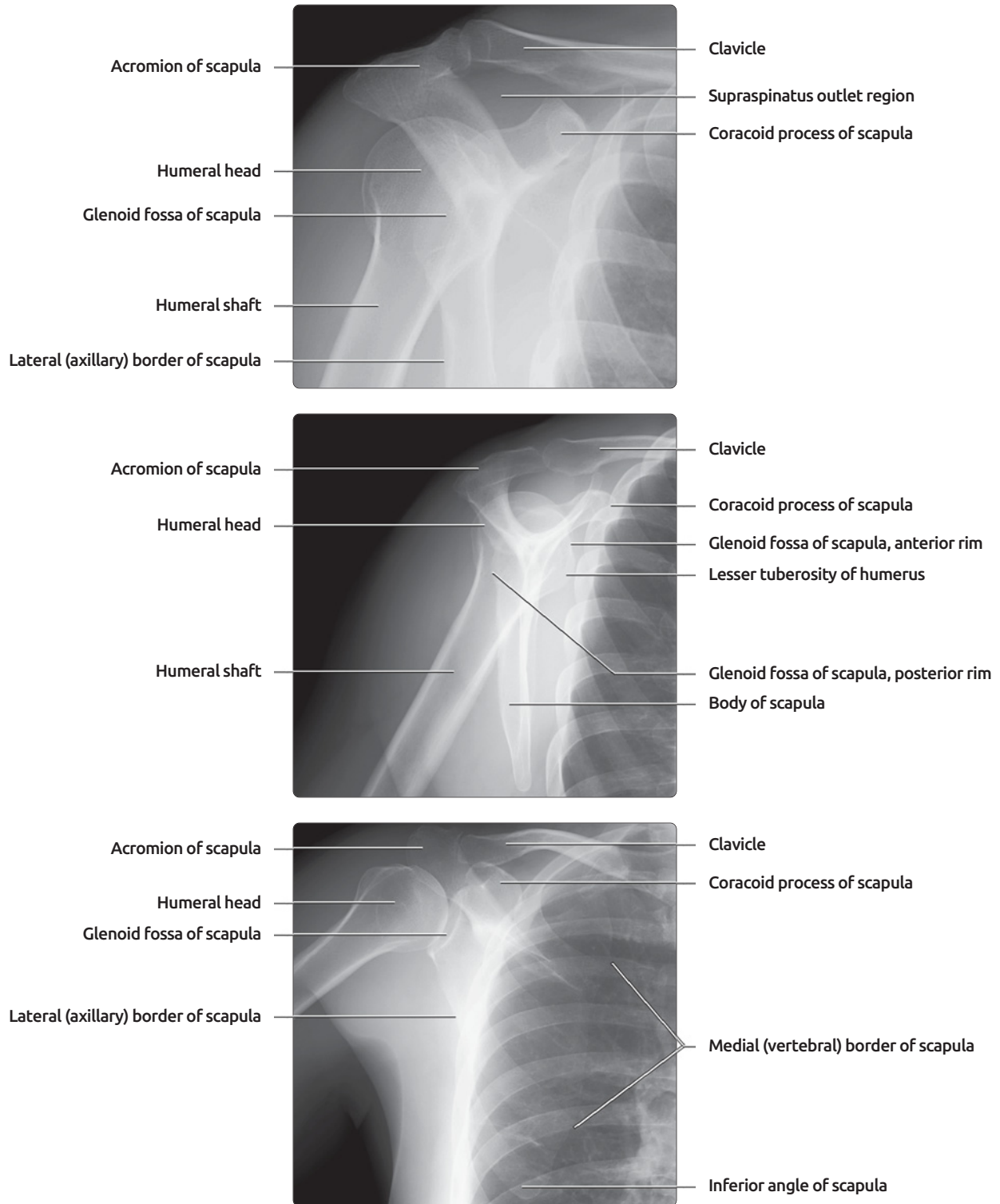
(Top) Grashey or true AP view of the shoulder is shown. A true AP view of the shoulder is obtained by tilting the x-ray beam approximately 45 degrees laterally from the standard AP view. This produces a true AP view of the anteriorly angled glenohumeral joint. The anterior and posterior rims of the glenoid should nearly overlap on this view. The Grashey view is helpful for evaluating joint congruity, joint space narrowing, and humeral head subluxation. **(Bottom)** Garth view of shoulder is shown. The Garth view is obtained by angling the x-ray beam 45 degrees caudally from a standard AP view. The inferior glenohumeral rim and posterior margin of the superolateral humeral head are well demonstrated. In patients with acute or chronic anterior humeral head dislocations, this view may assist in detection of Bankart fractures of the inferior glenoid and Hill-Sachs deformities of the humeral head.

AXILLARY, WEST POINT, & STRYKER NOTCH RADIOGRAPHS



(Top) Axillary view of shoulder was obtained with the patient supine, the arm abducted to 90 degrees, and the x-ray beam angled 15 to 30 degrees medially. The resultant image is tangential to the glenohumeral joint. This view is helpful for identification of humeral head dislocation and anterior or posterior glenoid rim fractures. **(Middle)** West Point axillary view of the shoulder is shown. This variation on the standard axillary view is acquired with the patient prone and the abducted forearm hanging off the edge of the table. The x-ray beam is angled 25 degrees medially and anteriorly. The West Point view better demonstrates the anterior inferior glenoid, making it useful for detection of Bankart fractures. **(Bottom)** Stryker notch view of shoulder is shown. This view is obtained with the patient supine and the arm in an abducted and externally rotated (ABER) position. The x-ray beam is angled 10 degrees cephalic. The posterolateral aspect of the humeral head, where a Hill-Sachs deformity could be located, is well demonstrated.

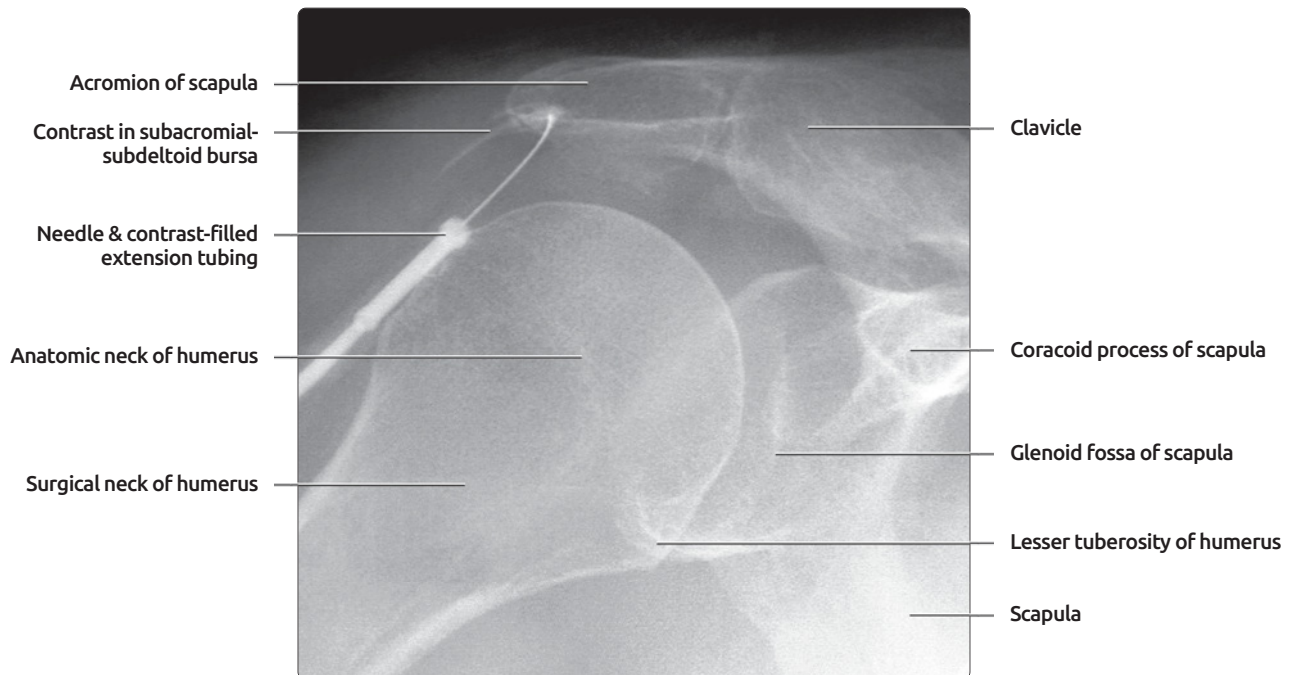
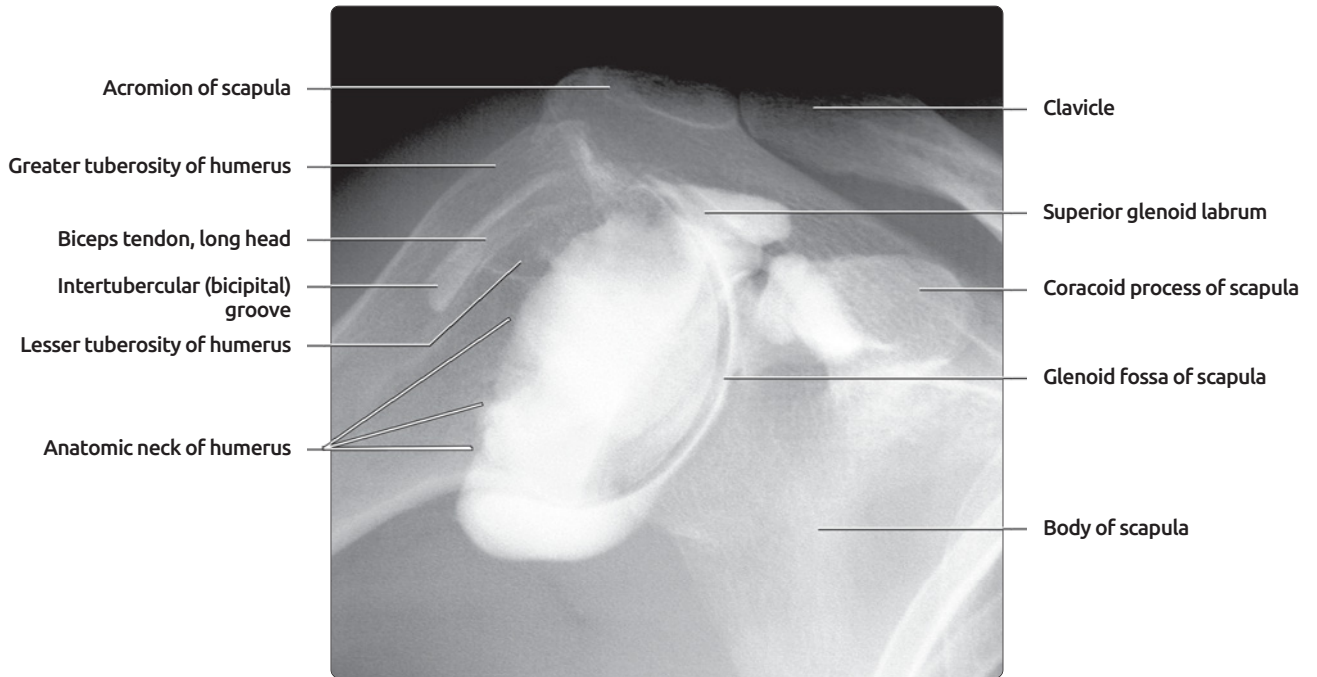
SUPRASPINATUS OUTLET, SCAPULAR Y, & AP SCAPULA RADIOGRAPHS



(Top) Supraspinatus outlet view of the shoulder assesses acromial morphology and humeral head subluxation. This view is obtained by placing the anterior aspect of the affected shoulder against the x-ray plate, rotating the opposite shoulder approximately 40 degrees away from the plate, then tilting the x-ray beam 5-10 degrees caudally. The acromion and subacromial space are imaged in profile.

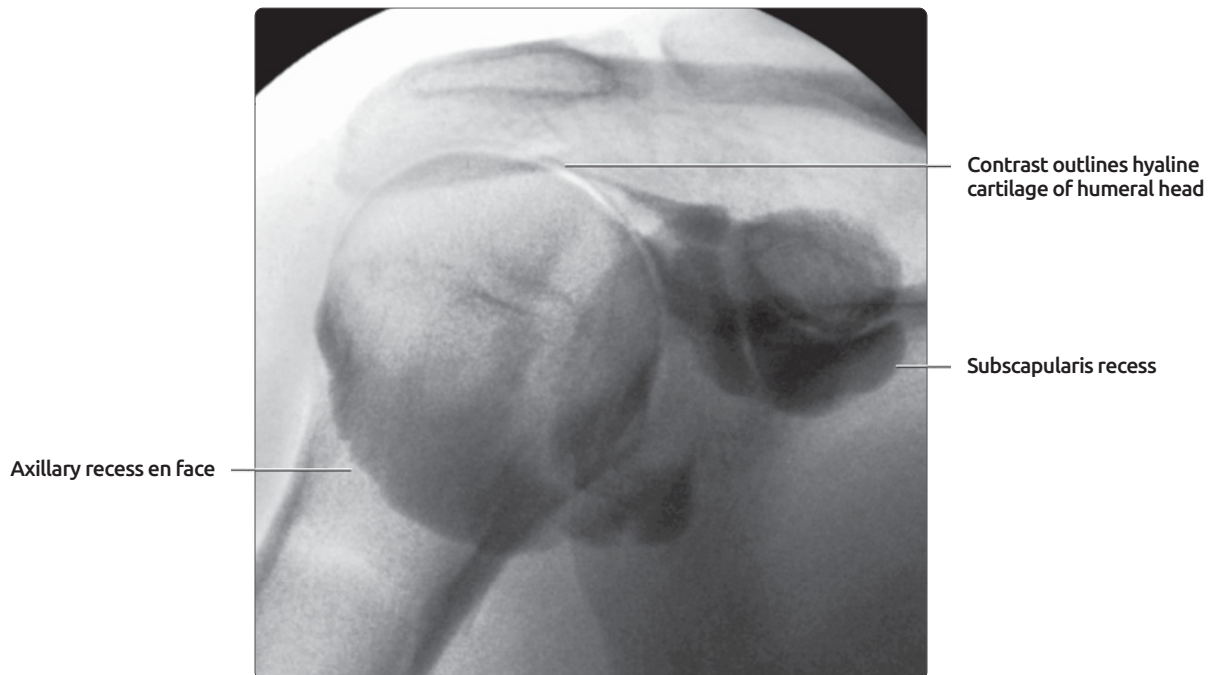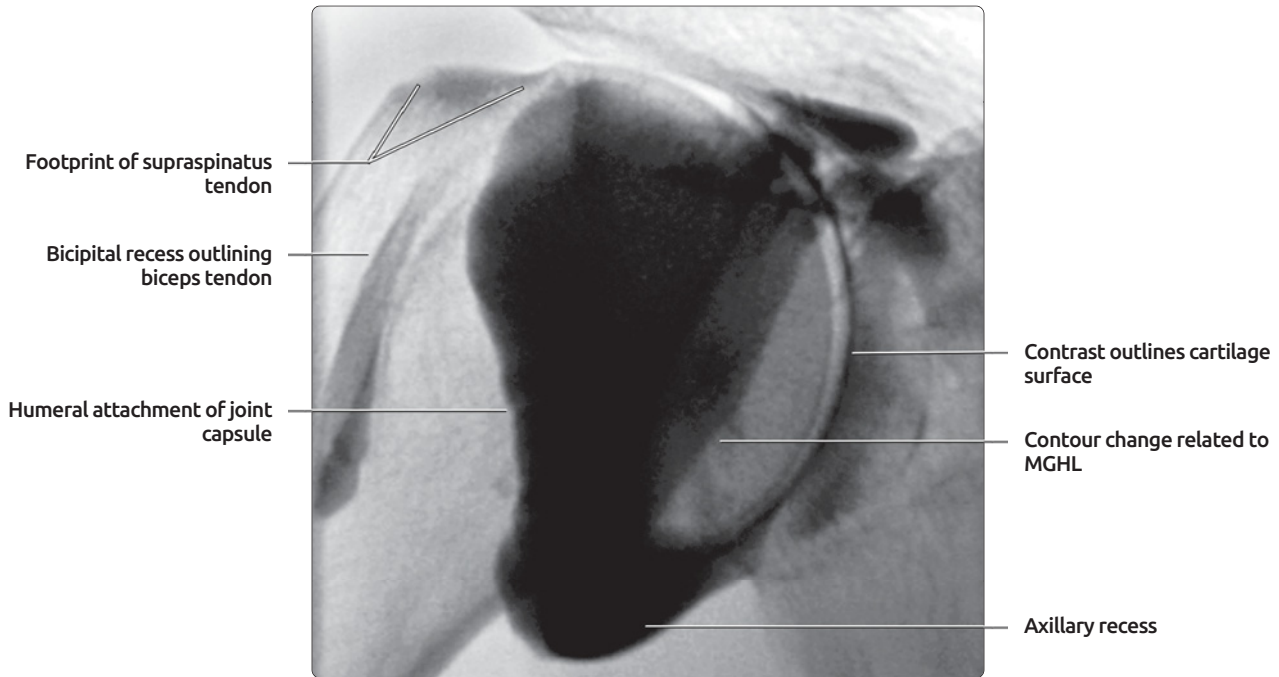
(Middle) Scapular Y view is shown. The anterior aspect of the affected shoulder is placed against the x-ray plate and the opposite shoulder rotated approximately 45-60 degrees away from the plate. The x-ray beam is directed along the scapular spine producing a true lateral view of the shoulder, with the scapula shaped like the letter Y and the humeral head located at the center of the Y. The humeral head will lie below the coracoid process in an anterior dislocation & posterior to the glenoid in posterior dislocation. **(Bottom)** AP view of scapula was obtained standing or supine with the arm abducted and hand supinated.

CONVENTIONAL ARTHROGRAPHY: GLENOHUMERAL JOINT AND SUBDELTOID BURSA



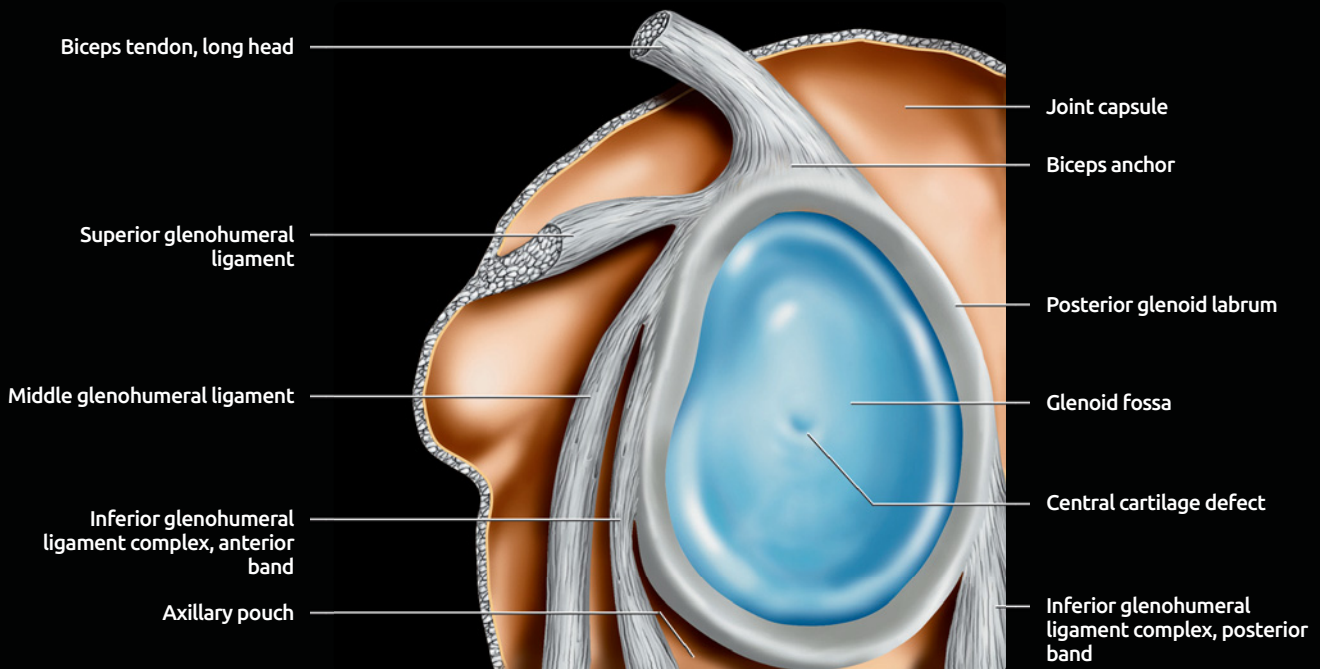
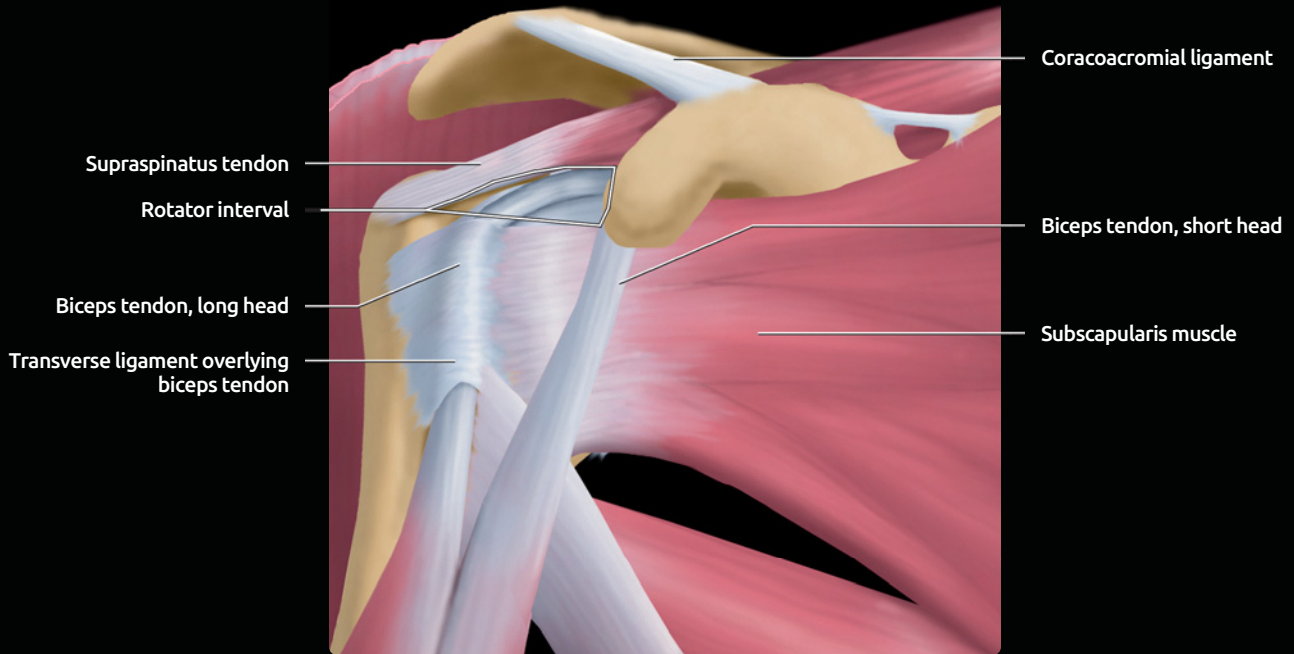
(Top) Conventional shoulder arthrogram is shown. Intraarticular contrast outlines the confines of the joint. Contrast extends to the anatomic neck of the humerus, where the joint capsule inserts. Contrast can normally extend into the biceps tendon sheath and subscapular recess. **(Bottom)** Subacromial-subdeltoid bursa injection is shown. A 25 g needle is placed just below the acromion process. Administered contrast will have a curvilinear configuration as it tracks within the subacromial-subdeltoid bursa. The shoulder is internally rotated on this image.

NORMAL ARTHROGRAM



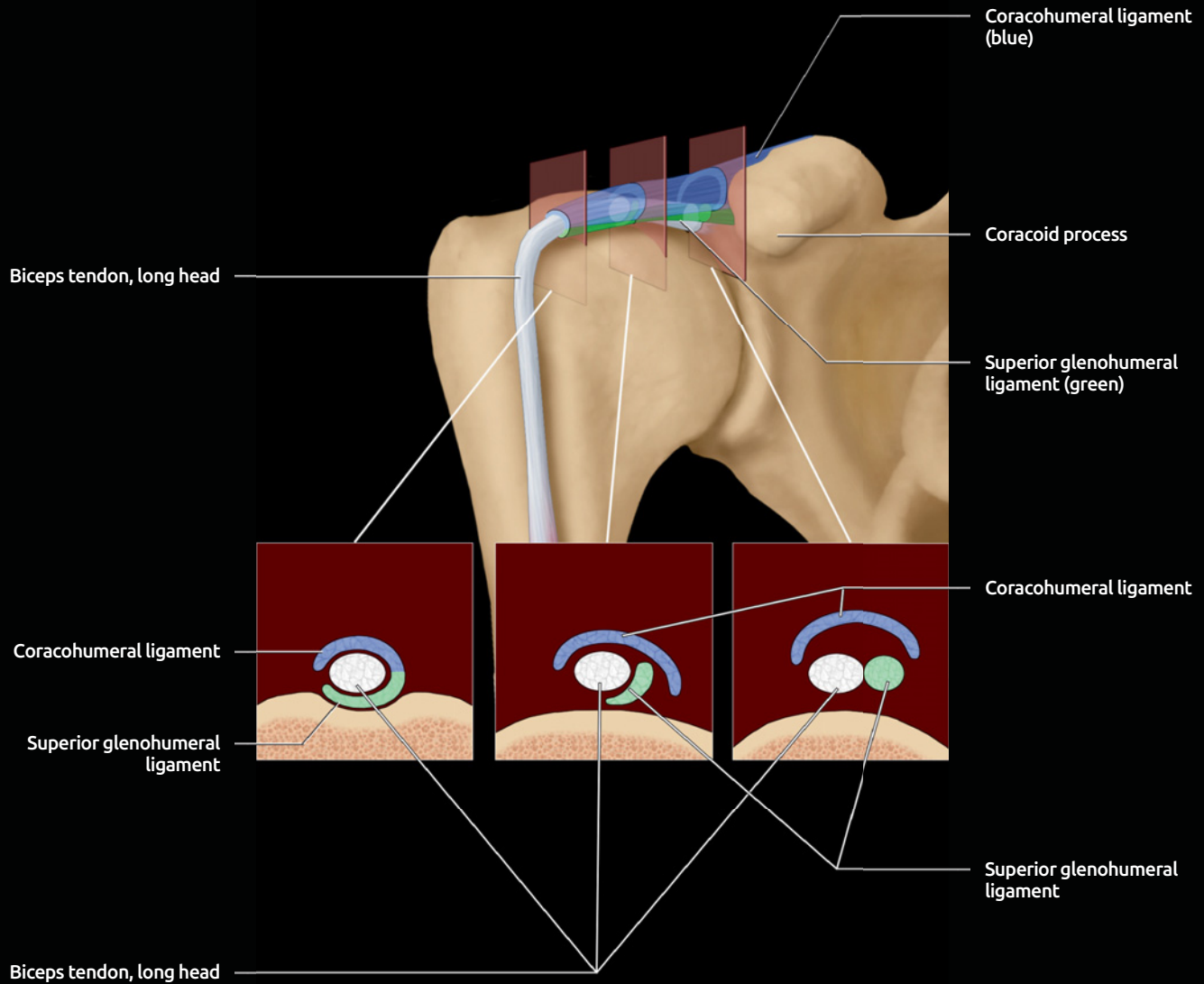
(Top) Anteroposterior arthrogram, fluoroscopic view, with the shoulder externally rotated shows normal oblique contour of the capsular attachment to the anatomic neck of the humerus. Contrast extension lateral to this line, &/or lateral to the greater tuberosity, indicates a rotator cuff tear. Note normal filling of the bicipital and axillary recesses of the joint. **(Bottom)** Anteroposterior arthrogram with the shoulder internally rotated shows contrast now filling the subscapularis recess.

SHOULDER GRAPHICS



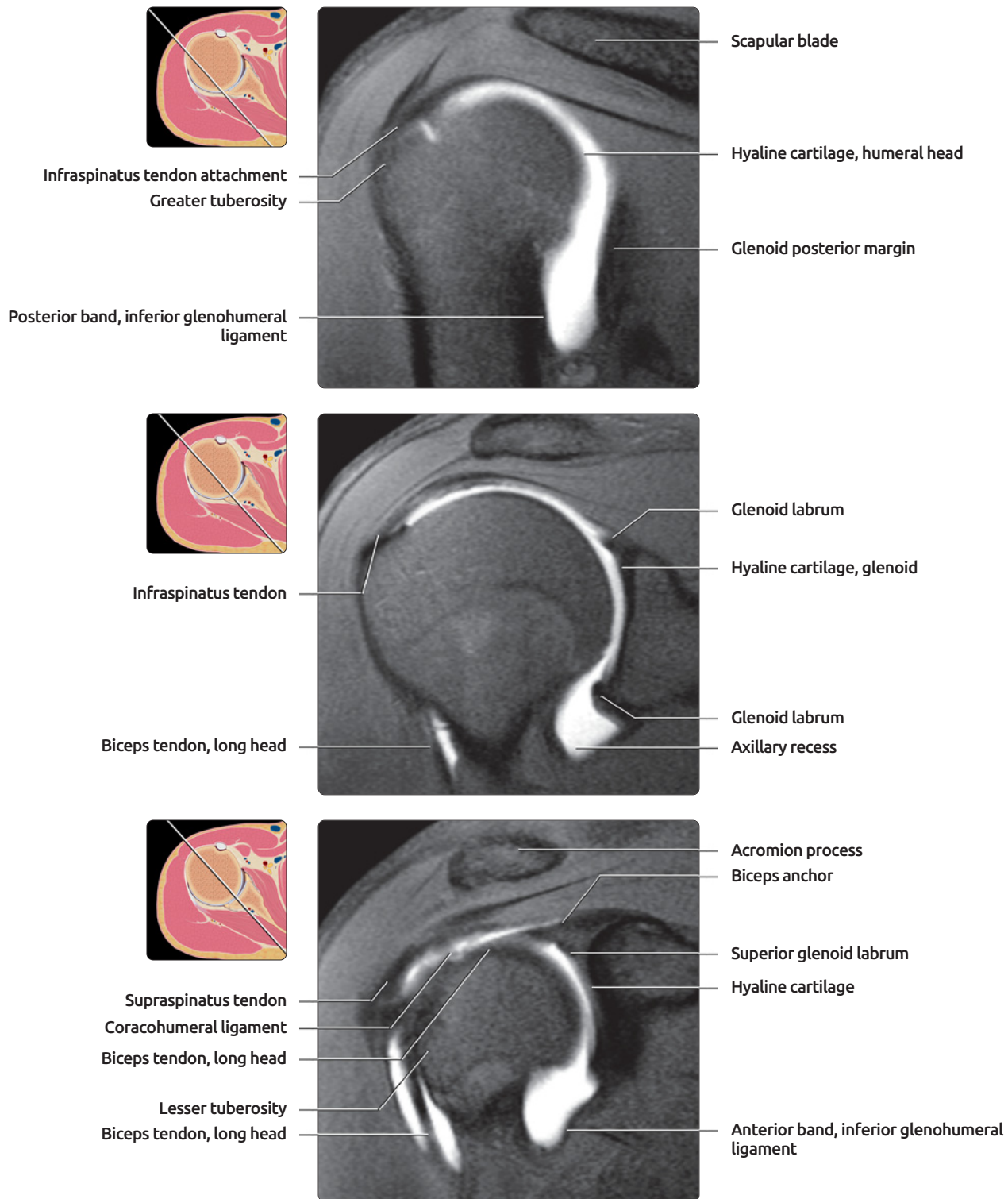
(Top) Anterior graphic shows the relationships of the rotator cuff to the rotator interval, a triangular space wide medially and narrowing laterally, with the apex at the anterior leading edge of the greater tuberosity. **(Bottom)** Sagittal graphic shows the intraarticular portion of the shoulder, humeral head removed. The superior and middle glenohumeral ligaments (SGHL & MGHL) both originate adjacent to the biceps tendon, but SGHL has a horizontal course and forms part of the biceps tendon sling. MGHL has an oblique course inferolaterally and provides anterior stability. The inferior glenohumeral ligament (IGHL) bands originate near the equator of the glenoid anteriorly & posteriorly and form anterior & posterior boundaries of the axillary recess.

ROTATOR INTERVAL GRAPHIC



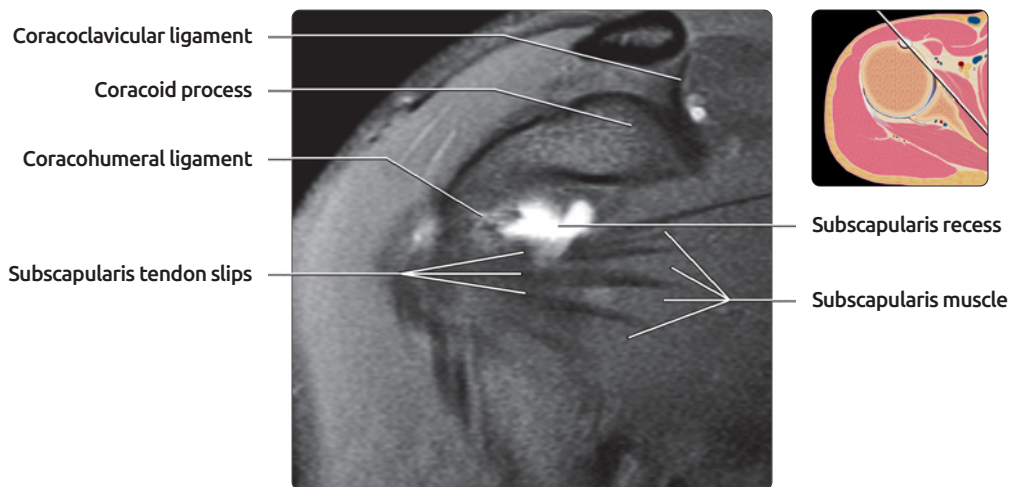
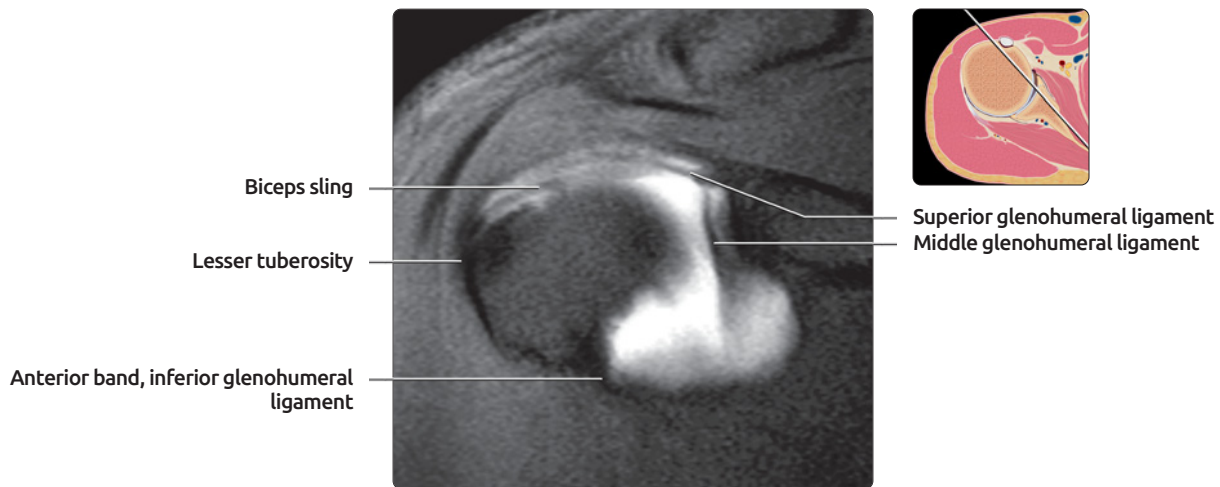
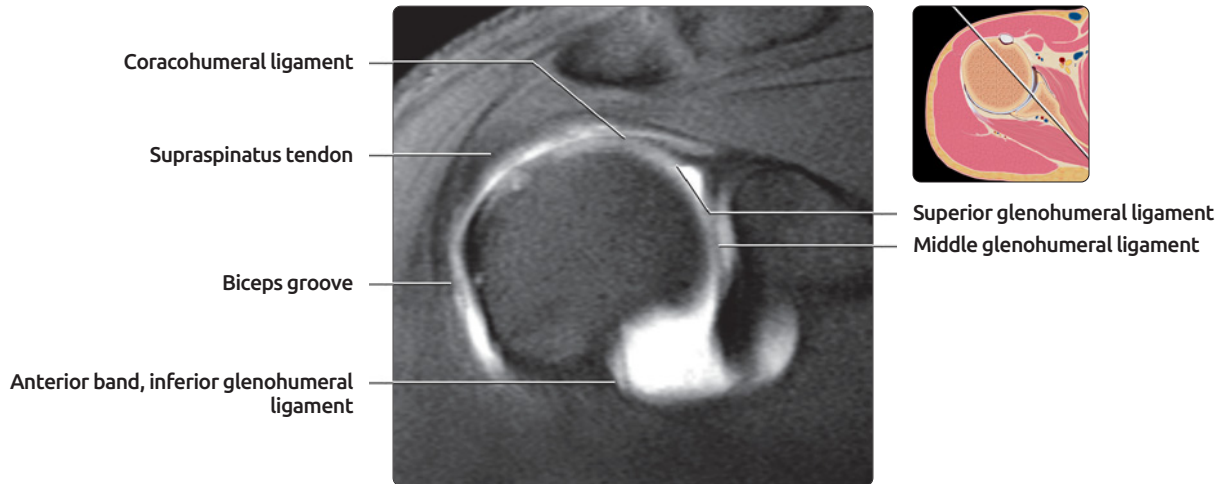
Normal rotator interval anatomy graphic is shown. Cross-section images at lateral, mid, & medial portions of rotator interval are located along bottom of image. At lateral aspect of rotator interval, just proximal to entrance to bicipital groove, medial band of coracohumeral ligament (blue) & superior glenohumeral ligament (green) form a sling around long head of the biceps tendon. At mid portion of rotator interval, coracohumeral ligament covers superior surface of biceps tendon, with superior glenohumeral ligament forming T-shaped junction with coracohumeral ligament. Near medial border of rotator interval, superior glenohumeral ligament is a round structure lying anterior to biceps tendon, & both structures are capped by U-shaped coracohumeral ligament. (Modified from Krief OP, 2005.)

OBLIQUE CORONAL: POSTERIOR TO ANTERIOR



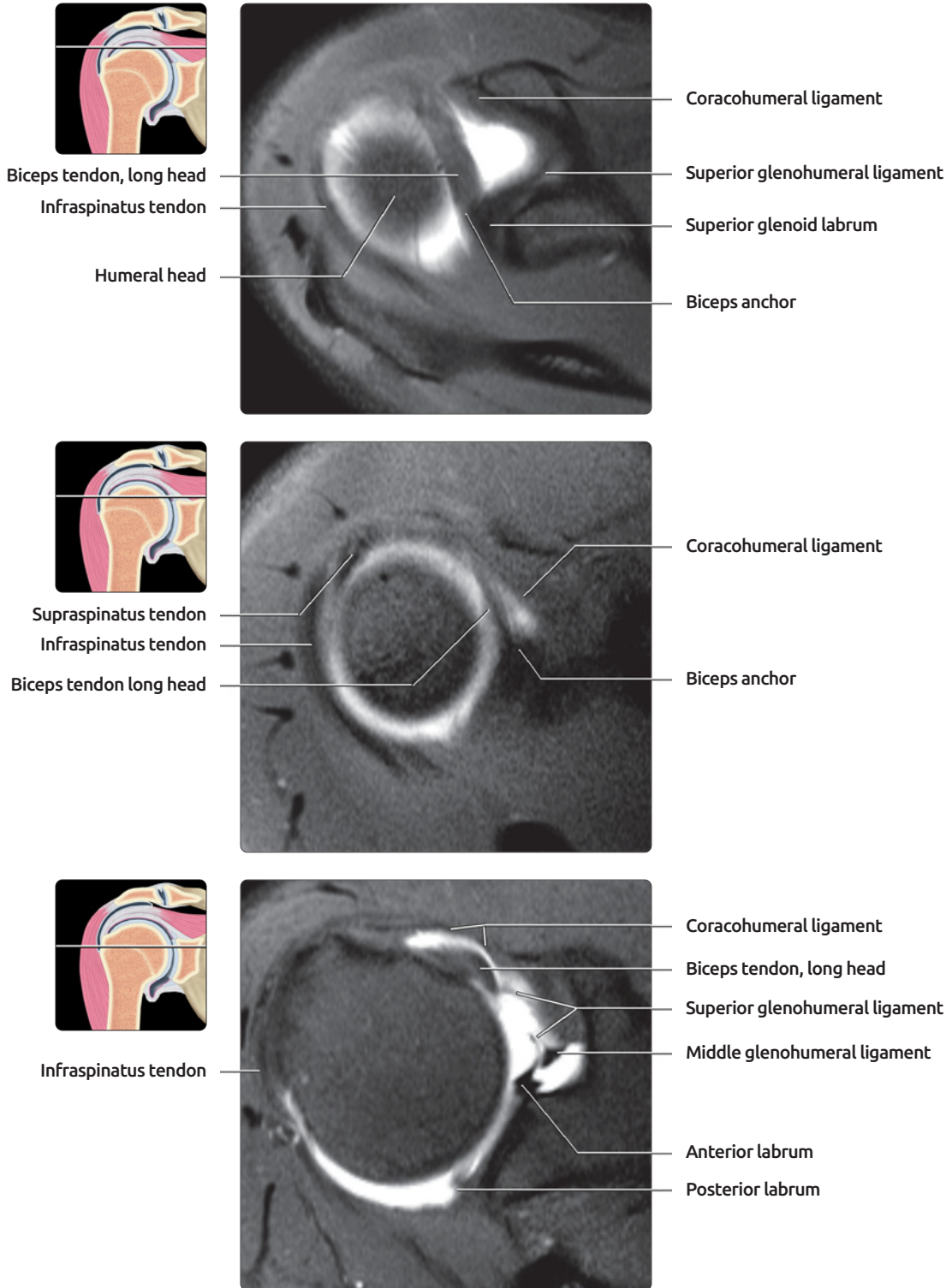
(Top) First of 6 selected coronal oblique T1WI MR arthrogram images, angled along the supraspinatus tendon axis, is shown. The posterior band of the inferior glenohumeral ligament forms a thick, distinct band at the posterior margin of the axillary pouch. **(Middle)** Posterior to the biceps anchor, the glenoid labrum is tightly adherent to the hyaline cartilage, and the sublabral sulci are never present. Because the elbow is posterior to the shoulder in a supine patient, a more anterior portion of the arm is usually seen at the inferior portion of the image than superiorly. **(Bottom)** Biceps originates from the superior bony margin of the glenoid and attaches firmly to the superior labrum. The sublabral sulcus is variably seen in this region but is absent in this patient. Intermediate signal intensity hyaline cartilage extends beneath the superior labrum. Note that the biceps tendon is seen in this mid-shoulder cut rather than more anteriorly because the shoulder is extremely externally rotated.

OBLIQUE CORONAL: POSTERIOR TO ANTERIOR



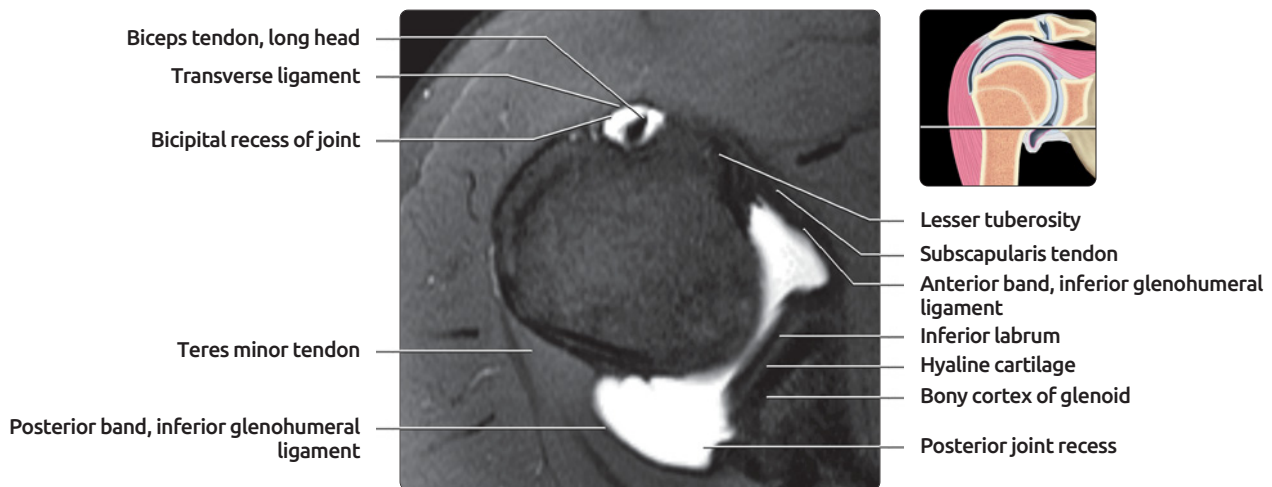
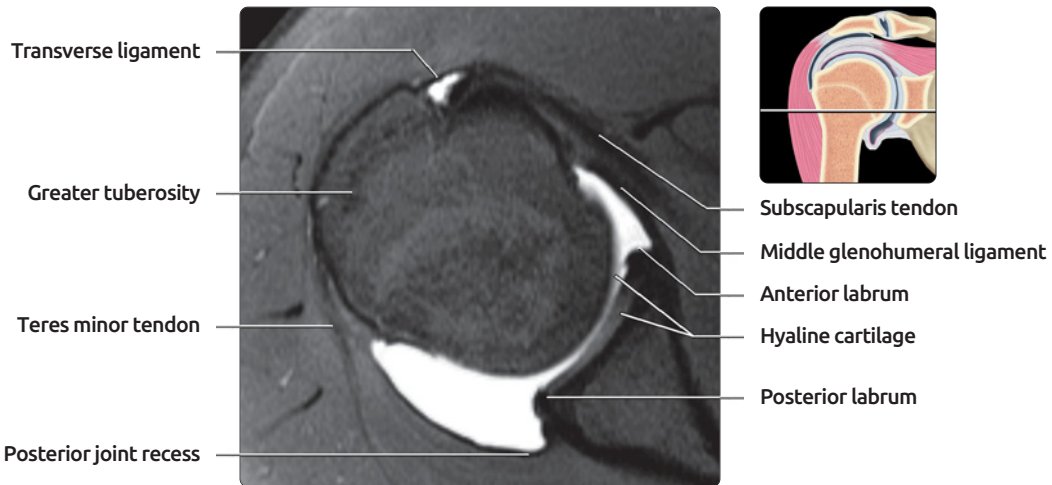
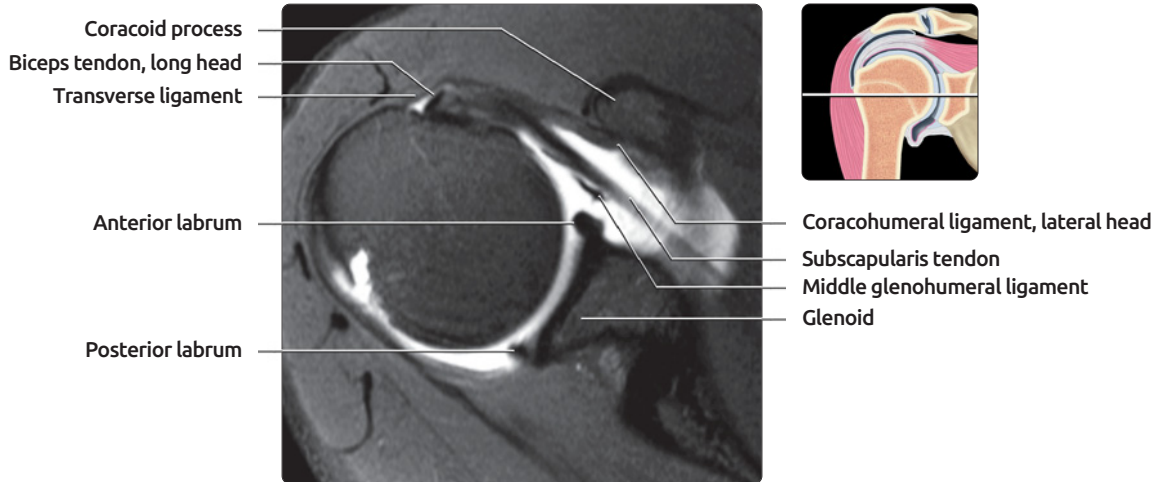
(Top) Immediately anterior to horizontal portion of long head biceps tendon, superior glenohumeral ligament is seen inferior to coracohumeral ligament. Appearance on MR arthrogram varies with rotation of shoulder. Shoulder of this patient is externally rotated, so the ligaments are nearly coronal in orientation. **(Middle)** Additional portions of biceps sling are now visible at the anterior margin of the glenoid, spiraling to form biceps sling. **(Bottom)** Most anterior image through the joint shows the subscapularis recess extending over the superior margin of the subscapularis muscle. Note the normal interdigitation of the subscapularis tendon slips with muscle. Most anterior portion of coracohumeral ligament is also visible merging with the lateral subscapularis fibers.

AXIAL: SUPERIOR TO INFERIOR



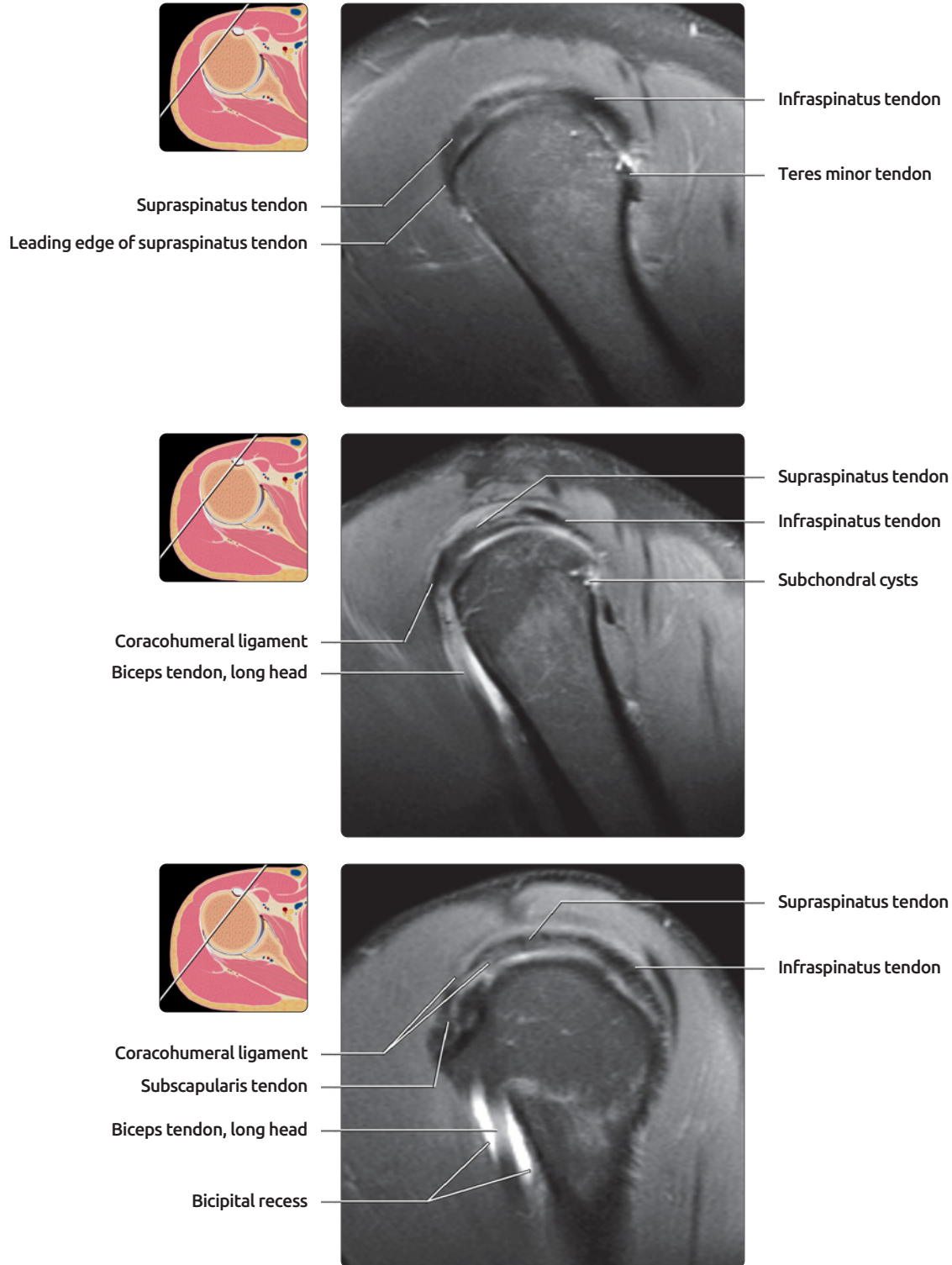
(Top) First of 6 selected T1WI FS MR arthrogram images shows the shoulder joint from superior to inferior. Biceps anchor and horizontal portion of the long head of biceps are well seen, together with portions of the coracohumeral ligament. Superior glenohumeral ligament is deviated medially by joint distention. **(Middle)** Coracohumeral ligament has a medial band, which forms part of biceps sling, and a lateral band, which drapes over anterior margin of subscapularis, attaching to subscapularis and lesser and greater tuberosities. It forms part of transverse ligament. **(Bottom)** Coracohumeral ligament forms roof of rotator interval, as well as part of biceps sling.

AXIAL: SUPERIOR TO INFERIOR



(Top) Lateral band of coracohumeral ligament (CHL) is well seen, extending anterior to subscapularis tendon and forming transverse ligament together with superficial fibers of subscapularis tendon. MGHL is adjacent to the posterior border of subscapularis tendon, with which it merges slightly more inferiorly. **(Middle)** The anterior labrum is larger than the posterior labrum. The intermediate intensity hyaline cartilage extends beneath the labrum both anteriorly and posteriorly. **(Bottom)** At the inferior margin of the joint, the inferior labrum is seen superficial to the hyaline cartilage. A prominent posterior joint recess adjacent to the labrum is a normal finding.

SAGITTAL: LATERAL TO MEDIAL



(Top) First of 9 selected sagittal PD FS MR arthrogram images from lateral to medial shows normal bicycle tire rim appearance of the rotator cuff around the superior and posterior portions of the humeral head. Small tears of the supraspinatus tendon occur at the anterior margin or "leading edge." The leading edge is best seen in the sagittal oblique plane. **(Middle)** Just medial to the footprint of the supraspinatus and infraspinatus tendons, a thin rim of joint fluid is seen beneath the tendons. Small subchondral cysts are noted posteriorly and are an almost universal finding in patients past young adulthood. **(Bottom)** The coracohumeral ligament forms the roof of the rotator interval. It has a variable appearance.