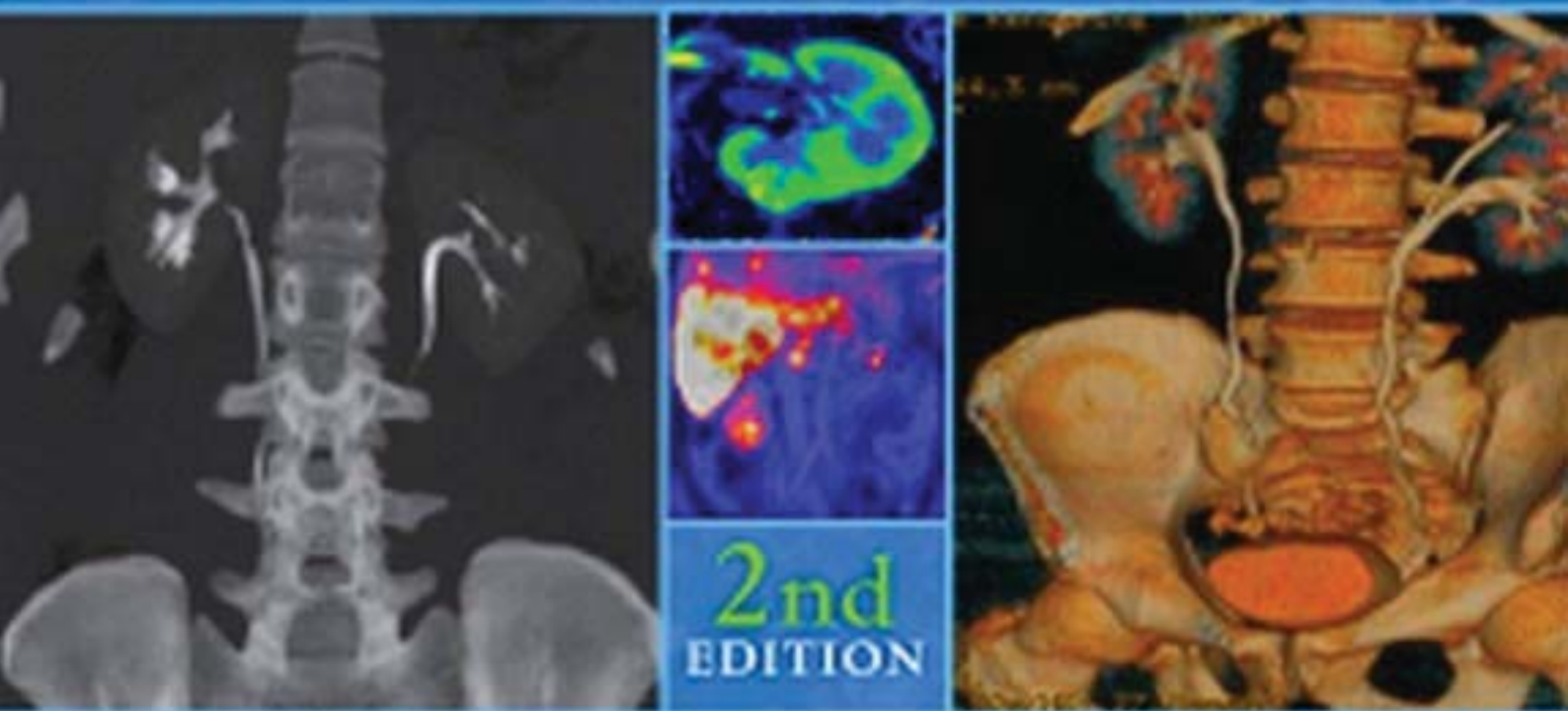


Get Full Access and More at

ExpertConsult.com

ABDOMINAL IMAGING



2nd
EDITION

SAHANI | SAMIR

ELSEVIER

ExpertRadiologySeries

Abdominal Imaging

Abdominal Imaging

Second Edition

Dushyant V. Sahani, MD

Associate Professor of Radiology
Harvard Medical School;
Assistant Radiologist,
Abdominal Imaging & Interventional
Radiology;
Director, CT Imaging Services
Massachusetts General Hospital
Boston, Massachusetts

Anthony E. Samir, MD, MPH

Assistant Professor of Radiology
Harvard Medical School;
Radiologist
Abdominal Imaging & Interventional
Radiology;
Co-Director
MGH/MIT Center for Ultrasound Research
& Translation;
Associate Director
Ultrasound Imaging Services
Massachusetts General Hospital
Boston, Massachusetts

ELSEVIER

ELSEVIER

1600 John F. Kennedy Blvd.
Ste 1800
Philadelphia, PA 19103-2899

ABDOMINAL IMAGING, SECOND EDITION

ISBN: 978-0-323-37798-0

Copyright © 2017 by Elsevier, Inc. All rights reserved.

No part of this publication may be reproduced or transmitted in any form or by any means, electronic or mechanical, including photocopying, recording, or any information storage and retrieval system, without permission in writing from the publisher. Details on how to seek permission, further information about the Publisher's permissions policies and our arrangements with organizations such as the Copyright Clearance Center and the Copyright Licensing Agency, can be found at our website: www.elsevier.com/permissions.

This book and the individual contributions contained in it are protected under copyright by the Publisher (other than as may be noted herein).

Notices

Knowledge and best practice in this field are constantly changing. As new research and experience broaden our understanding, changes in research methods, professional practices, or medical treatment may become necessary.

Practitioners and researchers must always rely on their own experience and knowledge in evaluating and using any information, methods, compounds, or experiments described herein. In using such information or methods they should be mindful of their own safety and the safety of others, including parties for whom they have a professional responsibility.

With respect to any drug or pharmaceutical products identified, readers are advised to check the most current information provided (i) on procedures featured or (ii) by the manufacturer of each product to be administered, to verify the recommended dose or formula, the method and duration of administration, and contraindications. It is the responsibility of practitioners, relying on their own experience and knowledge of their patients, to make diagnoses, to determine dosages and the best treatment for each individual patient, and to take all appropriate safety precautions.

To the fullest extent of the law, neither the Publisher nor the authors, contributors, or editors, assume any liability for any injury and/or damage to persons or property as a matter of products liability, negligence or otherwise, or from any use or operation of any methods, products, instructions, or ideas contained in the material herein.

Previous edition copyrighted 2011.

Library of Congress Cataloging-in-Publication Data

Names: Sahani, Dushyant V., editor. | Samir, Anthony E., editor.
Title: Abdominal imaging / [edited by] Dushyant V. Sahani, Anthony E. Samir.

Other titles: Abdominal imaging (Sahani)

Description: Second edition. | Philadelphia, PA : Elsevier, [2017] | Includes bibliographical references and index.

Identifiers: LCCN 2016018766 | ISBN 9780323377980 (hardcover : alk. paper)

Subjects: | MESH: Digestive System Diseases--diagnosis | Diagnostic

Imaging--methods | Radiography, Abdominal | Abdomen--ultrasonography | Abdomen--radionuclide imaging

Classification: LCC RC804.D52 | NLM WI 141 | DDC 616.3/075--dc23 LC record available at <https://lcn.loc.gov/2016018766>

International Standard Book Number: 978-0-323-37798-0

Content Strategist: Robin Carter

Content Development Specialist: Marybeth Thiel

Publishing Services Manager: Catherine Jackson

Project Manager: Rachel E. McMullen

Design Direction: Brian Salisbury

Printed in China

Last digit is the print number: 9 8 7 6 5 4 3 2 1



With great fondness I dedicate this book to mentors, colleagues, and students for their contributions in my personal and professional life that made me worthy of editing this book, and to my family for their unconditional love, encouragement, and unwavering support.

DUSHYANT V. SAHANI

I dedicate this book to my wife, Susan, whose love and support make everything possible; to my son, Noah, whose curiosity brings me profound happiness; to my daughter, Sophie, whose loving smile makes me deeply grateful for all I have; and to my parents, Charlotte and Moshe, who sacrificed much so that I could achieve something meaningful.

ANTHONY E. SAMIR

EDITORS

Dushyant V. Sahani, MD

Associate Professor of Radiology
Harvard Medical School;
Assistant Radiologist, Abdominal Imaging & Intervention
Director, CT Imaging Services
Massachusetts General Hospital
Boston, Massachusetts

Anthony E. Samir, MD, MPH

Assistant Professor of Radiology
Harvard Medical School;
Radiologist
Abdominal Imaging & Interventional Radiology;
Co-Director
MGH/MIT Center for Ultrasound Research & Translation;
Associate Director
Ultrasound Imaging Services
Massachusetts General Hospital
Boston, Massachusetts

ASSOCIATE EDITORS

Joseph R. Grajo, MD

Assistant Professor of Radiology
Division of Abdominal Imaging
University of Florida College of Medicine
Gainesville, Florida

Nicole D. Horst, MD, MEng

Diagnostic Radiology
North Shore Medical Center
Commonwealth Radiology Associates
Salem, Massachusetts

SECTION EDITORS

Arash Anvari, MD

Postdoctoral Research Fellow
Radiology
Massachusetts General Hospital
Boston, Massachusetts
Ultrasound

Surabhi Bajpai, MBBS, DMRD

Research Fellow
Radiology
Massachusetts General Hospital
Boston, Massachusetts
Gallbladder and Bile Ducts, General Concepts

Luzeng Chen, MD

Associate Professor
Ultrasound Center
Peking University First Hospital
Beijing, China
Ultrasound

Manish Dhyani, MBBS

Instructor in Radiology
Massachusetts General Hospital,
Harvard Medical School
Boston, Massachusetts
Ultrasound

Joseph R. Grajo, MD

Assistant Professor of Radiology
Division of Abdominal Imaging
University of Florida College of Medicine
Gainesville, Florida
Liver, Abdominal and Pelvic Lymph Nodes

Koichi Hayano, MD, PhD

Assistant Professor
Department of Surgery
Chiba University Hospital
Chiba, Japan
*Conventional Imaging of Abdomen, Magnetic Resonance
Imaging, Esophagus and Stomach Imaging*

Nicole D. Horst, MD, MEng

Diagnostic Radiology
North Shore Medical Center
Commonwealth Radiology Associates
Salem, Massachusetts
Colon

**Aoife Kilcoyne, MB BCH BAO, B Med Sc,
MRCP(UK), FFR(RCSI)MB, BCh, MAO**

Clinical Fellow, Diagnostic Radiology
Division of Abdominal Imaging and Intervention
Department of Radiology
Massachusetts General Hospital
Boston, Massachusetts
*Computed Tomography, Positron Emission Tomography and
Co-Registered PET/CT, Nontraumatic Acute Abdomen,
Splenic Lesions*

Naveen M. Kulkarni, MD, DNB

Clinical Fellow
Abdominal Imaging and Intervention
Massachusetts General Hospital
Boston, Massachusetts
*Adrenal Mass, Prostate and Seminal Vesicles, Penis, Prostate and
Scrotum, General Concepts*

**Colin J. McCarthy, MB, BAO, BCh, MRCSI,
FFR(RCSI)**

Division of Abdominal Imaging
Department of Radiology
Massachusetts General Hospital
Boston, Massachusetts
*Kidneys and Urinary Tract, Focal Renal Lesions, Diffuse Renal
Parenchymal Diseases, Ureters and Bladder, Urinary Tract
Anomalies and Variants*

Melissa Price, MD

Thoracic Imaging Fellow
Massachusetts General Hospital
Boston, Massachusetts
Pancreas

Rani S. Sewatkar, MD

Radiology Research Fellow
Radiology
Massachusetts General Hospital
Boston, Massachusetts
Peritoneum and Retroperitoneum, Abdominal Wall Hernias

Abraham C. Thomas, MD

Radiologist
Massachusetts General Hospital
Boston, Massachusetts
*Esophagus and Stomach Imaging, Stomach Lesions, Gastric
Function Imaging, Small Bowel*

CONTRIBUTORS

Francesco Agnello, MD

Radiology Fellow
Dipartimento di Biopatologie Mediche—Sezione di Scienze
Radiologiche
Università di Palermo
Palermo, Italy
Benign Focal Lesions; Malignant Focal Lesions

Diego A. Aguirre, MD

Associate Professor of Radiology
Imaging Department
Fundacion Santa Fe de Bogota, University Hospital
Bogota, Colombia
*Neoplastic and Non-neoplastic Conditions of the Abdominal
Wall, Abdominal Wall Hernias*

Pritish Aher, MBBS, DMRD

Consultant Radiologist
Pune
Maharashtra, India
*Fluoroscopic Study of the Abdomen and Fluoroscopic Contrast
Media*

Stephan W. Anderson, MD

Assistant Professor
Department of Radiology
Director of Body CT
Boston University Medical Center
Boston, Massachusetts
*Acute Appendicitis; Hollow Viscus Perforation; Acute
Gastrointestinal Bleeding*

Arash Anvari, MD

Postdoctoral Research Fellow
Radiology
Massachusetts General Hospital
Boston, Massachusetts
Tissue Harmonic Imaging and Doppler Ultrasound Imaging

Ashwin Asrani, MD, MBBS

Clinical Fellow in Radiology
Harvard Medical School;
Clinical Assistant in Radiology
Massachusetts General Hospital
Boston, Massachusetts
Erectile Dysfunction; Penile Trauma and Miscellaneous Penile Lesions; Imaging of the Scrotum; Benign and Malignant Testicular Lesions

Surabhi Bajpai, MBBS, DMRD

Research Fellow
Radiology
Massachusetts General Hospital
Boston, Massachusetts
Dilated Bile Ducts; Gallbladder and Bile Duct Functional Imaging; Image-Guided Therapy

Arpan K. Banerjee, MBBS (LOND), FRCP, FRCR, FBIR

Hon Senior Clinical Lecturer, Birmingham Medical School;
Consultant Radiologist, Heart of England Foundation NHS Trust
Birmingham, England, United Kingdom;
Past President Radiology Section 2005-2007
Royal Society of Medicine
London, England, United Kingdom
Peritoneal Fluid Collections, Peritonitis, and Peritoneal Abscess

William F. Bennett, MD

Associate Professor
Radiology
The Ohio State University Wexner Medical Center
Columbus, Ohio
Small Bowel Obstruction

Michael Blake, MB, BCh, BSc, MRCPI, FRCR, FFR (RCSI)

Assistant Professor of Radiology
Harvard Medical School;
Assistant Radiologist
Massachusetts General Hospital
Boston, Massachusetts
Positron Emission Tomography and Computed Tomography Technique and Instrumentation; Positron Emission Tomography and Positron Emission Tomography/Computed Tomography Clinical Applications; Enlarged Adrenal Glands; Adrenal Masses

Giuseppe Brancatelli, MD

Associate Professor of Radiology
Dipartimento di Biopatologie Mediche—Sezione di Scienze Radiologiche
Università di Palermo
Palermo, Italy
Benign Focal Lesions; Malignant Focal Lesions

Vito Cantisani, MD, PhD

Professor of Radiology
Instructor in Radiology
Department of Radiological Sciences
University Sapienza of Rome
Rome, Italy
Plain Radiography of the Abdomen

Giovanni Carbognin, MD

Department of Radiology
University Hospital
Verona, Italy
Imaging of the Pancreas

Onofrio Catalano, MD

Clinical Fellow
Harvard Medical School;
Clinical Fellow
Department of Radiology
Massachusetts General Hospital
Boston, Massachusetts
Hepatic Variants; Solid Pancreatic Masses; Cystic Lesions of the Pancreas

Luzeng Chen, MD

Associate Professor
Ultrasound Center
Peking University First Hospital
Beijing, China
Abdominal Ultrasound Imaging: Anatomy, Physics, Instrumentation, Technique

Michael Chew, MBBS, BA

Fellow in Abdominal and Interventional Imaging
Massachusetts General Hospital
Boston, Massachusetts
Dilated Bile Ducts

Aqeel Ahmad Chowdhry, MD

Staff Radiologist
Department of Radiology
Cleveland Clinic—South Pointe Hospital
Cleveland, Ohio
Non-neoplastic Conditions of the Peritoneum and Neoplastic Conditions of the Mesentery and Omentum

Garry Choy, MD, MS, MSc

Clinical Fellow
Department of Radiology
Harvard Medical School;
Clinical Fellow
Massachusetts General Hospital
Boston, Massachusetts
Principles of Magnetic Resonance Imaging Physics; Contrast Media and Contrast-Enhanced Magnetic Resonance Imaging; Advanced Magnetic Resonance Imaging Applications

Rivka R. Colen, MD

Radiology Resident
Massachusetts General Hospital
Boston, Massachusetts
Gastric Function Imaging: Technique and Applications; Imaging of the Scrotum; Benign and Malignant Testicular Lesions

Carmel Cronin, MD, MB, BCh, MRCPI, FFR (RCSI)

Radiology Fellow
 Department of Abdominal Imaging and Interventional
 Radiology
 Massachusetts General Hospital
 Boston, Massachusetts
*Benign Prostatic Hyperplasia; Benign and Malignant Focal
 Prostate Lesions; Seminal Vesicle Lesions*

Ugo D'Ambrosio, MD

Resident
 Department of Radiological Sciences
 University Sapienza of Rome
 Rome, Italy
Plain Radiography of the Abdomen

Mirko D'Onofrio, MD

Assistant Professor of Radiology
 G.B. Rossi University
 Hospital, University of Verona
 Verona, Italy
Imaging of the Pancreas

Abraham H. Dachman, MD, FACR

Professor of Radiology
 Director of Fellowship Programs
 The University of Chicago Medical Center
 Chicago, Illinois
Benign Neoplasms and Wall Thickening of the Small Bowel

Hemali Desai, MD

Research Fellow
 Massachusetts General Hospital
 Boston, Massachusetts;
 Resident
 Beth Israel Medical Center
 Newark, New Jersey
Imaging of Chronic Pancreatitis

Manish Dhyani, MBBS

Instructor in Radiology
 Massachusetts General Hospital,
 Harvard Medical School
 Boston, Massachusetts
*Advanced Ultrasound Techniques: Liver Elastography, Contrast-
 Enhanced Ultrasonography, and Four-Dimensional
 Ultrasound; Benign, Malignant, and Cystic Focal Renal
 Lesions*

Silvana C. Faria, MD, PhD

Assistant Professor
 MD Anderson Cancer Center
 Houston, Texas
*Fatty Liver Disease; Hepatic Storage Disorders; Cirrhosis and
 Hepatitis; Cholestatic Hepatic Disorders*

Todd Fibus, MD

Assistant Professor
 Department of Radiology
 VA Medical Center
 Emory University School of Medicine
 Atlanta, Georgia
Colon Imaging: Conventional Imaging and Computed Tomography

Efrén J. Flores, MD

Harvard Medical School
 Department of Radiology
 Massachusetts General Hospital
 Boston, Massachusetts
Imaging of the Postoperative Bowel

Mark Frank, MD

Associate Professor of Radiology
 Indiana University, School of Medicine
 Indianapolis, Indiana
*Non-neoplastic Conditions of the Peritoneum and Neoplastic
 Conditions of the Mesentery and Omentum*

Karthik Ganesan, DNB

Radiologist, Liver Imaging Group
 Department of Radiology
 University of California San Diego
 San Diego, California
 Consultant Radiologist
 Piramal Diagnostics and Jankharia Imaging
 Mumbai, India
Hepatic Iron Overload

Alpa G. Garg, MD

Clinical Assistant
 Massachusetts General Hospital
 Boston, Massachusetts
Benign and Malignant Bladder Lesions

Arunas E. Gasparaitis, MD

Assistant Professor
 Department of Radiology
 University of Chicago
 Director of Fluoroscopic Services
 University of Chicago Medical Center
 Chicago, Illinois
*Benign Neoplasms and Wall Thickening of the Small Bowel;
 Malignant Neoplasms and Wall Thickening of the Small
 Bowel*

Sukanya Ghosh, MBBS, MRCP, FRCR

St. Bartholomew and the Royal London Hospital
 London, England, United Kingdom
Imaging of the Stomach and Duodenum

Joseph R. Grajo, MD

Assistant Professor of Radiology
Division of Abdominal Imaging
University of Florida College of Medicine
Gainesville, Florida

Advanced Ultrasound Techniques: Liver Elastography, Contrast-Enhanced Ultrasonography, and Four-Dimensional Ultrasound; Imaging of the Liver; Fatty Liver Disease; Hepatic Iron Overload; Hepatic Storage Disorders; Cirrhosis and Hepatitis; Hepatic Venous-occlusive Diseases; Cholestatic Hepatic Disorders; Hepatic Variants; Lymph Node Imaging Techniques and Clinical Role; Benign Prostatic Hyperplasia; Benign and Malignant Focal Prostate Lesions; Seminal Vesicle Lesions

Manuel F. Granja, MD

Research Fellow
Universidad de los Andes Medical School
Imaging Department
Fundacion Santa Fe de Bogota, University Hospital
Bogota, Colombia

Neoplastic and Non-neoplastic Conditions of the Abdominal Wall; Abdominal Wall Hernias

Rossella Graziani, MD

Radiologist
University Hospital
University of Verona
Verona, Italy
Imaging of the Pancreas

Peter F. Hahn, MD, PhD

Associate Professor of Radiology
Harvard Medical School;
Radiologist
Massachusetts General Hospital
Boston, Massachusetts
Dilated Bile Ducts

Robert Hanna, MD

Radiologist (Physician)
Department of Radiology
University of California San Diego
San Diego, California
Hepatic Iron Overload; Cirrhosis and Hepatitis

Donald Hawes, MD

Associate Professor of Radiology
Indiana University
School of Medicine
Indianapolis, Indiana
Non-neoplastic Conditions of the Peritoneum and Neoplastic Conditions of the Mesentery and Omentum

Koichi Hayano, MD, PhD

Assistant Professor
Department of Surgery
Chiba University Hospital
Chiba, Japan

Plain Radiography of the Abdomen; Fluoroscopic Study of the Abdomen and Fluoroscopic Contrast Media; Principles of Magnetic Resonance Imaging Physics; Contrast Media and Contrast-Enhanced Magnetic Resonance Imaging; Advanced Magnetic Resonance Imaging Applications; Esophageal Imaging

Nagaraj-Setty Holalkere, MD, DNB

Instructor, Department of Radiology
Boston Medical Center
Boston, Massachusetts
Enlarged Adrenal Glands, Adrenal Masses

Nicole D. Horst, MD, MEng

Diagnostic Radiology
North Shore Medical Center
Commonwealth Radiology Associates
Salem, Massachusetts
Colon Imaging: Conventional Imaging and Computed Tomography; Computed Tomographic Colonography, Inflammatory and Infectious Colonic Lesions; Colonic Vascular Lesions; Colon Cancer and Screening Strategies; Imaging of the Postoperative Bowel

Kedar Jambhekar, MD, DNB

Assistant Professor
Department of Radiology
University of Arkansas for Medical Sciences
Little Rock, Arkansas
Diffuse Renal Parenchymal Diseases; Renal Vascular Diseases

Bijal Jankharia, MBBS, DMRE, DMRD, DNB

Teacher and Consultant
Piramal Diagnostics
Jankharia Imaging
Mumbai, Maharashtra, India
Tissue Harmonic Imaging and Doppler Ultrasound Imaging

Sanjeeva P. Kalva, MD, MB, BS

Assistant Professor
Department of Radiology
Harvard Medical School;
Associate Director of Clinical Affairs
Division of Vascular Imaging & Intervention
Department of Radiology
Massachusetts General Hospital
Boston, Massachusetts
Acute and Chronic Small Bowel Ischemia

Avinash Kambadakone, MBBS, MD, DNB, FRCR

Assistant Professor
Harvard Medical School;
Radiologist
Abdominal Imaging & Interventional Radiology,
Medical Director
Martha's Vineyard Hospital Imaging
Massachusetts General Hospital
Boston, Massachusetts
Recent Advances; Diffuse Gallbladder Wall Thickening; Focal Gallbladder Wall Thickening; Lymph Node Imaging Techniques and Clinical Role

David P. Katz, MD

Assistant Professor
Department of Radiology
Baylor College of Medicine
Houston, Texas
Imaging of the Kidneys and Urinary Tract; Benign, Malignant, and Cystic Focal Renal Lesions

Keerthana Kesavarapu, BS

Department of Biology
Georgia Institute of Technology
Atlanta, Georgia
Colon Imaging: Conventional Imaging and Computed Tomography

Hansol Kim, MD

Resident
Department of Radiology
Brigham and Women's Hospital
Boston, Massachusetts
Miscellaneous Pancreatitis; Diffuse Pancreatic Disease

Kyoung Won Kim, MD, PhD

Associate Professor
Department of Radiology
University of Ulsan College of Medicine;
Faculty Member
Department of Radiology
Asan Medical Center
Seoul, Republic of Korea
Focal Splenic Lesions; Diffuse Splenic Lesions

Min Ju Kim, MD

Radiology
National Cancer Center
Ilsandong-gu, Goyang-si
Gyeonggi-do, Korea
Focal Splenic Lesions; Diffuse Splenic Lesions

Kirti Kulkarni, MD

Assistant Professor
Department of Radiology
University of Chicago
Chicago, Illinois
Malignant Neoplasms and Wall Thickening of the Small Bowel

Naveen M. Kulkarni, MD, DNB

Clinical Fellow
Abdominal Imaging and Intervention
Massachusetts General Hospital
Boston, Massachusetts
Fluoroscopic Study of the Abdomen and Fluoroscopic Contrast Media; Principles of Computed Tomography Physics, Instrumentation, and Radiation Safety; Colonic Vascular Lesions; Imaging of Chronic Pancreatitis; Enlarged Adrenal Glands; Adrenal Masses, Erectile Dysfunction; Penile Trauma and Miscellaneous Penile Lesions; Imaging of the Scrotum; Benign and Malignant Testicular Lesions; Imaging of Disorders of the Female Urethra; Imaging of Disorders of the Male Urethra; Response Evaluation Criteria in Solid Tumors, World Health Organization, and Other Response Criteria; Principles of CT Physics: Instrumentation and Radiation Safety

A. Nick Kurup, MD

Instructor
Department of Radiology
Mayo Clinic
College of Medicine
Rochester, Minnesota
Imaging of the Kidneys and Urinary Tract; Benign, Malignant, and Cystic Focal Renal Lesions

Somesh Lala, MBBS, DMRD, DNB

Teacher, Consultant Radiologist, and Sonologist
Piramal Diagnostics;
Consultant Radiologist and Sonologist
Midtown Diagnostics,
Jankharia Imaging
Mumbai, Maharashtra, India
Tissue Harmonic Imaging and Doppler Ultrasound Imaging

Chandana G. Lall, MD

Associate Professor of Clinical Radiology
Indiana University School of Medicine
Indianapolis, Indiana
Peritoneal Fluid Collections, Peritonitis and Peritoneal Abscess

Leslie K. Lee, BSc, MD

Clinical Fellow in Radiology
Massachusetts General Hospital
Boston, Massachusetts
Hepatic Storage Disorders; Cholestatic Hepatic Disorders; Hepatic Variants; Benign and Malignant Focal Prostate Lesions

Dipti K. Lenhart, MD

Department of Radiology
Massachusetts General Hospital
Boston, Massachusetts
Colon Cancer and Screening Strategies

Bob Liu, PhD

Physicist
 Massachusetts General Hospital;
 Assistant Professor in Radiology
 Harvard Medical School
 Boston, Massachusetts
*Principles of Computed Tomography Physics, Instrumentation,
 and Radiation Safety*

Xiaozhou Ma, MD

Research Fellow
 Harvard Medical School
 Fellow, 3D Imaging
 Massachusetts General Hospital
 Boston, Massachusetts
*Tissue Harmonic Imaging and Doppler Ultrasound Imaging;
 Advanced Ultrasound Techniques: Liver Elastography,
 Contrast-Enhanced Ultrasonography; and Four-Dimensional
 Ultrasound*

Michael Macari, MD

Vice Chair of Operations
 Section Chief of Abdominal Imaging
 New York University Langone School of Medicine
 New York, New York
Inflammatory and Infectious Colonic Lesions

Riccardo Manfredi, MD

Associate Professor
 Department of Diagnostic Imaging
 University of Verona
 Verona, Italy
Imaging of the Pancreas

Andrea Marcantonio, MD

Resident
 Department of Radiological Sciences
 University Sapienza of Rome
 Rome, Italy
Plain Radiography of the Abdomen

Daniele Marin, MD

Associate Professor
 Department of Radiology
 Duke University
 Durham, North Carolina
Benign Focal Lesions; Malignant Focal Lesions

Deepa Masrani, MD

Clinical Assistant Professor
 Women's Imaging
 Upstate Medical University
 State University of New York
 Syracuse, New York
Erectile Dysfunction

Sameer M. Mazhar, MD

Fellow
 Division of Gastroenterology
 University of California San Diego
 San Diego, California
*Fatty Liver Disease; Hepatic Iron Overload; Hepatic Storage
 Disorders; Cirrhosis and Hepatitis; Hepatic Veno-occlusive
 Diseases; Cholestatic Hepatic Disorders*

Vishakha Mazumdar, MBBS

Fellow
 Radiology
 Piramal Diagnostics
 Jankharia Imaging
 Mumbai, Maharashtra, India
Tissue Harmonic Imaging and Doppler Ultrasound Imaging

Colin J. McCarthy, MB, BAO, BCh, MRCSI, FFR(RCSI)

Division of Abdominal Imaging
 Department of Radiology
 Massachusetts General Hospital
 Boston, Massachusetts
*Imaging of the Kidneys and Urinary Tract; Diffuse Renal
 Parenchymal Diseases; Benign and Malignant Ureteral
 Strictures; Benign and Malignant Bladder Lesions; Urinary
 Tract Anomalies and Variants*

Pardeep Mittal, MD

Assistant Professor
 Department of Radiology
 Emory University School of Medicine
 Atlanta, Georgia
*Colon Imaging: Conventional Imaging and Computed
 Tomography*

Michael Moore, MB, BCh, FFR (RCSI)

Radiologist
 Abdominal Imaging
 Massachusetts General Hospital
 Boston, Massachusetts;
 Consultant Radiologist
 Mercy University Hospital
 Cork, Ireland
*Positron Emission Tomography and Computed Tomography
 Technique and Instrumentation; Positron Emission
 Tomography and Positron Emission Tomography/Computed
 Tomography Clinical Applications*

Giovanni Morana, MD

Director, Radiological Department
 General Hospital
 Treviso, Italy
Gallbladder and Bile Duct Functional Imaging

Ajaykumar Morani, MBBS, MD

Clinical Lecturer I, Body Imaging
 Department of Radiology
 University of Michigan
 Ann Arbor, Michigan
*Erectile Dysfunction; Penile Trauma and Miscellaneous Penile
 Lesions; Imaging of the Scrotum; Benign and Malignant
 Testicular Lesions*

Massimiliano Motton, MD

Department of Radiology
G.B. Rossi Hospital Verona
Verona, Italy
Imaging of the Pancreas

Ozden Narin, MD

Research Fellow
Department of Radiology
Massachusetts General Hospital
Boston, Massachusetts
Colonic Vascular Lesions

Vamsidhar R. Narra, MD, MBA, FRCR, FACR

Professor of Radiology,
Chief, Abdominal Imaging Section,
Vice Chair, Clinical Imaging Informatics & New Business
Development,
Chief of Radiology
Barnes Jewish West County Hospital
Mallinckrodt Institute of Radiology
Washington University—St. Louis
St. Louis, Missouri
*Tumors of the Gallbladder; Intrahepatic Bile Duct Tumors;
Extrahepatic Bile Duct Tumors*

Aytekin Oto, MD

Professor of Radiology and Surgery
Section Chief, Abdominal Imaging
Department of Radiology
University of Chicago Medicine
Chicago, Illinois
*Benign Neoplasms and Wall Thickening of the Small Bowel;
Malignant Neoplasms and Wall Thickening of the
Small Bowel*

Tarun Pandey, MD, DNB, FRCR

Assistant Professor of Radiology
University of Arkansas for Medical Sciences
Little Rock, Arkansas
Diffuse Renal Parenchymal Diseases; Renal Vascular Diseases

Ralph C. Panek, MD

Staff Radiologist
Department of Radiology
St. Elizabeth's Hospital
Brighton, Massachusetts
Benign and Malignant Bladder Lesions

Heather M. Patton, MD

Assistant Clinical Professor of Medicine
Division of Gastroenterology
University of California—San Diego
San Diego, California
Fatty Liver Disease; Hepatic Iron Overload

Rodolfo F. Perini, MD

Fellow
Medical Oncology and Nuclear Medicine
Hospital of the University of Pennsylvania
Philadelphia, Pennsylvania
Imaging of the Kidneys and Urinary Tract

Michael R. Peterson, MD, PhD

Assistant Clinical Professor, Pathology
University of California San Diego
San Diego, California
*Hepatic Iron Overload; Hepatic Storage Disorders; Cirrhosis and
Hepatitis; Hepatic Veno-occlusive Diseases; Cholestatic
Hepatic Disorders*

Giuseppe Petralia, MD

Radiologist
Division of Radiology
European Institute of Oncology
Milan, Italy
Gallbladder and Bile Duct Functional Imaging

Niall Power, MRCPI, FRCR

Consultant Radiologist
Radiology Department
Royal London Hospital
London, England, United Kingdom
Imaging of the Stomach and Duodenum

Anand M. Prabhakar, MD

Clinical Fellow in Abdominal Imaging
Harvard Medical School
Massachusetts General Hospital
Boston, Massachusetts
*Mucosal Diseases of the Stomach: Differentiating Benign from
Malignant; Gastric Stromal Tumors*

Hima B. Prabhakar, MD

Staff Radiologist
South Texas Radiology Group
San Antonio, Texas
*Mucosal Diseases of the Stomach: Differentiating Benign from
Malignant; Gastric Stromal Tumors; Gastric Outlet
Obstruction*

Priya D. Prabhakar, MD, MPH

Clinical Assistant Professor of Radiology
Department of Radiology
Jefferson Medical College;
Staff Radiologist
Department of Radiology
Albert Einstein Medical Center
Philadelphia, Pennsylvania
Gastric Outlet Obstruction

Srinivasa R. Prasad, MD

Professor, Radiology Department
University of Texas
Health Science Center at San Antonio
San Antonio, Texas
*Imaging of Disorders of the Female Urethra; Imaging of
Disorders of the Male Urethra*

Melissa Price, MD

Thoracic Imaging Fellow
Massachusetts General Hospital
Boston, Massachusetts
*Imaging of the Pancreas; Solid Pancreatic Masses; Cystic Lesions
of the Pancreas; Imaging of Acute Pancreatitis; Imaging of
Chronic Pancreatitis*

Daniel A. Pryma, MD

Assistant Professor of Radiology
Modality Chief
Nuclear Medicine/Molecular Imaging
Department of Radiology
University of Pennsylvania
Philadelphia, Pennsylvania
Imaging of the Kidneys and Urinary Tract

Arumugam Rajesh, MBBS, FRCR

Consultant Radiologist
Honorary Senior Lecturer
University Hospitals of Leicester NHS Trust
Leicester, England, United Kingdom
Peritoneal Fluid Collections, Peritonitis and Peritoneal Abscess

Anuradha S. Rebello, MBBS

Instructor, Department of Radiology
Boston University
Boston, Massachusetts
Imaging of Acute Pancreatitis

Oscar M. Rivero, MD

Associate Professor of Radiology
El Bosque University
Imaging Department
Fundacion Santa Fe de Bogota, University Hospital
Bogota, Colombia
Neoplastic and Non-neoplastic Conditions of the Abdominal Wall; Abdominal Wall Hernias

Johannes B. Roedel, MD

Department of Radiology
Harvard Medical School
Massachusetts General Hospital
Boston, Massachusetts
Gastric Function Imaging: Technique and Applications

David A. Rosman, MD, MBA

Assistant Radiologist, Abdominal Imaging and Intervention
Department of Radiology
Massachusetts General Hospital
Boston, Massachusetts
Colon Cancer and Screening Strategies

Dushyant V. Sahani, MD

Associate Professor of Radiology
Harvard Medical School;
Assistant Radiologist, Abdominal Imaging & Intervention
Director, CT Imaging Services
Massachusetts General Hospital
Boston, Massachusetts
Esophageal Imaging; Colon Cancer and Screening Strategies; Imaging of the Postoperative Bowel; Hepatic Variants; Solid Pancreatic Masses; Cystic Lesions of the Pancreas; Imaging of Acute Pancreatitis; Diffuse Gallbladder Wall Thickening; Focal Gallbladder Wall Thickening; Lymph Node Imaging Techniques and Clinical Role

Nisha I. Sainani, MD

Assistant Professor of Radiology, Harvard Medical School
Staff Radiologist, Abdominal Imaging and Intervention
Brigham and Women's Hospital
Boston, Massachusetts
Miscellaneous Pancreatitis, Diffuse Pancreatic Disease

Anthony E. Samir, MD, MPH

Assistant Professor of Radiology
Harvard Medical School;
Radiologist
Abdominal Imaging & Interventional Radiology;
Co-Director
MGH/MIT Center for Ultrasound Research & Translation;
Associate Director
Ultrasound Imaging Services
Massachusetts General Hospital
Boston, Massachusetts
Advanced Ultrasound Techniques: Liver Elastography, Contrast-Enhanced Ultrasonography and Four-Dimensional Ultrasound; Imaging of the Kidneys and Urinary Tract; Benign, Malignant, and Cystic Focal Renal Lesions; Urinary Tract Obstruction; Benign and Malignant Ureteral Strictures; Benign and Malignant Bladder Lesions; Response Evaluation Criteria in Solid Tumors, World Health Organization, and Other Response Criteria

Kumaresan Sandrasegaran, MD

Associate Professor of Radiology
Indiana University
School of Medicine
Indianapolis, Indiana
Principles of Computed Tomography Physics, Instrumentation and Radiation Safety, Recent Advances; Peritoneal Fluid Collections, Peritonitis and Peritoneal Abscess; Non-neoplastic Conditions of the Peritoneum and Neoplastic Conditions of the Mesentery and Omentum

Cynthia S. Santillan, MD

Assistant Clinical Professor of Radiology
University of California San Diego
San Diego, California
Hepatic Veno-occlusive Diseases

Rupan Sanyal, MD

Clinical Associate, Staff Radiologist
Radiology HBG
Cleveland Clinic
Cleveland, Ohio
Computed Tomography Contrast Media and Principles of Contrast Enhancement

Alissa Saunders, MD

Clinical Assistant
Massachusetts General Hospital
Boston, Massachusetts
Benign and Malignant Ureteral Strictures

Richard T. Scuderi, MD, PhD

Fellow, Surgical Pathology
University of California San Diego
San Diego, California
Fatty Liver Disease

Melanie Seale, MBBS, FRANZCR

Radiologist
Medical Imaging Department
St Vincent's Hospital Melbourne
Fitzroy, Victoria, Australia
Urinary Tract Obstruction

Sunit Sebastian, MD

Assistant Professor, Department of Radiology
Chief, Division of Body Imaging
University of Mississippi Medical Center
Jackson, Mississippi
Colon Imaging: Conventional Imaging and Computed Tomography; Computed Tomographic Colonography

Rani S. Sewatkar, MD

Radiology Research Fellow
Radiology
Massachusetts General Hospital
Boston, Massachusetts
Peritoneal Fluid Collections, Peritonitis and Peritoneal Abscess; Non-neoplastic Conditions of the Peritoneum and Neoplastic Conditions of the Mesentery and Omentum

Hemendra Shah, MD, FACR

Professor of Radiology and Urology
University of Arkansas for Medical Sciences
Little Rock, Arkansas
Diffuse Renal Parenchymal Diseases; Renal Vascular Diseases

Shetal N. Shah, MD

Visiting Associate Professor of Radiology
Cleveland Clinic Lerner School of Medicine
Case Western Reserve University;
Co-Director
Center for PET and Molecular Imaging;
Staff, Cleveland Clinic
Imaging Institute
Cleveland, Ohio
Computed Tomography Contrast Media and Principles of Contrast Enhancement; Non-neoplastic Conditions of the Peritoneum and Neoplastic Conditions of the Mesentery and Omentum

Zarine K. Shah, MD, MBBS

Assistant Professor
Department of Radiology
Division of Abdominal Imaging
Ohio State University Medical Center
Columbus, Ohio
Small Bowel Obstruction

Anup Shetty, MD

Instructor of Radiology
Abdominal Imaging Section
Mallinckrodt Institute of Radiology
Washington University School of Medicine
St. Louis, Missouri
Tumors of the Gallbladder; Intrahepatic Bile Duct Tumors; Extrahepatic Bile Duct Tumors

Masoud Shieh-morteza, MD

Liver Imaging Group
Department of Radiology
University of California San Diego
San Diego, California
Cirrhosis and Hepatitis

Claude B. Sirlin, MD

Associate Professor
Liver Imaging Group
Department of Radiology
University of California San Diego
San Diego, California
Fatty Liver Disease; Hepatic Iron Overload; Hepatic Storage Disorders; Cirrhosis and Hepatitis; Hepatic Veno-occlusive Diseases; Cholestatic Hepatic Disorders

William Small, MD, PhD

Associate Professor
Director of Abdominal Imaging
Department of Radiology
Emory University School of Medicine
Emory University Hospital
Atlanta, Georgia
Colon Imaging: Conventional Imaging and Computed Tomography; Computed Tomographic Colonography

Jorge A. Soto, MD

Professor of Radiology
Boston University School of Medicine;
Vice Chairman
Department of Radiology
Boston Medical Center
Boston, Massachusetts
Ureteral and Kidney Stones; Acute Appendicitis; Hollow Viscus Perforation; Acute Gastrointestinal Bleeding

Lance L. Stein, MD

Center for Liver Disease and Transplantation
Columbia University, New York Presbyterian Hospital
New York, New York
Hepatic Storage Disorders

Venkateswar R. Surabhi, MD

Assistant Professor
Department of Radiology
University of Texas Health Science Center at Houston
Houston, Texas
Imaging of Disorders of the Female Urethra; Imaging of Disorders of the Male Urethra

Marco Testoni, MD

Department of Radiology
G.B. Rossi Hospital Verona
Verona, Italy
Imaging of the Pancreas

Ashraf Thabet, MD

Clinical Fellow, Division of Abdominal Imaging and Intervention
Department of Radiology
Harvard Medical School
Massachusetts General Hospital
Boston, Massachusetts
Acute and Chronic Small Bowel Ischemia

Abraham C. Thomas, MD

Radiologist
Massachusetts General Hospital
Boston, Massachusetts
Imaging of the Stomach and Duodenum; Mucosal Diseases of the Stomach: Differentiating Benign from Malignant; Gastric Stromal Tumors; Gastric Outlet Obstruction; Gastric Function Imaging: Technique and Applications; Imaging the Small Bowel; Acute and Chronic Small Bowel Ischemia

Stephen Thomas, MD

Assistant Professor of Radiology
Department of Radiology
The University of Chicago Medical Center
Chicago, Illinois
Benign Neoplasms and Wall Thickening of the Small Bowel; Malignant Neoplasms and Wall Thickening of the Small Bowel

Ernesto Tomei, MD

Associate Professor
Department of Radiology
University Sapienza of Rome
Rome, Italy
Plain Radiography of the Abdomen

Richard Tsai, MD

Resident
Diagnostic Radiology
Mallinckrodt Institute of Radiology
Washington University
St. Louis, Missouri
Tumors of the Gallbladder; Intrahepatic Bile Duct Tumors; Extrahepatic Bile Duct Tumors

Michelle Udeshi, MD

Department of Radiology
Hospital of St. Raphael
New Haven, Connecticut;
Griffin Hospital
Derby, Connecticut
Imaging of the Kidneys and Urinary Tract; Benign, Malignant, and Cystic Focal Renal Lesions

Raul N. Uppot, MD

Assistant Professor
Department of Radiology
Harvard Medical School;
Interventional Radiologist
Division of Interventional Radiology
Massachusetts General Hospital
Boston, Massachusetts
Urinary Tract Anomalies and Variants; Image-Guided Therapy

Sujit Vaidya, MD

Barts and the London NHS Trust
London, England, United Kingdom
Imaging of the Stomach and Duodenum

Sanjaya Viswamitra, MD

Assistant Professor
Department of Radiology
University of Arkansas for Medical Sciences
Little Rock, Arkansas
Diffuse Renal Parenchymal Diseases; Renal Vascular Diseases

T. Gregory Walker, MD

Instructor of Radiology
Harvard Medical School;
Associate Radiologist
Massachusetts General Hospital
Boston, Massachusetts
Acute and Chronic Small Bowel Ischemia

Takeshi Yokoo, MD, PhD

Department of Radiology
University of California San Diego
San Diego, California
Fatty Liver Disease

PREFACE

In 2013, when Elsevier approached us to create an updated, revised, and shortened second edition of *Abdominal Imaging*, we had some concerns. Even though the book had been successful and well-received by many colleagues and friends, we both wondered whether there truly is a need for an abbreviated, but comprehensive text? And would we have the time to work on it, adding the myriad updates to do justice to our fast-moving specialty?

Fortunately, we have had the privilege of working with a fine team of outstanding associate editors, section editors, and new chapter authors. Joe Grajo, MD and Nicole Horst, MD, truly outstanding radiologists and clinical fellows in our department, did superb work editing, collating, and organizing the work of our section editors. Together with the initial authors of the many chapters in this book, Melissa Price, MD, Colin McCarthy, MD, Aiofe Kilcoyne, MD, Rani Sewatkar, MD, Koichi Hayano, MD, Surabhi Bajpayi, MD, Naveen Kulkarni, MD, Arash Anvari, Luzeng Chen, Manish Dhyani, and Abe Thomas, MD all did an outstanding job of editing and revising the many chapters that went into this book. New chapters were contributed by Arash Anvari, MD, Manish Dhyani, MD, Luzeng Chen, MD, Koichi Hayano, MD, Naveen Kulkarni, MD, and Surabhi Bajpayi, MD. We are truly proud to have worked with such an outstanding team.

The new edition has been extensively updated and contains new images and the latest information about new technologies in abdominal imaging. This new edition is available both in a print edition and as part of the online *Clinical Key*. This platform comprises an online tool with high yield content

and numerous annotated images in an easy-to-use format specifically designed for rapid retrieval of clinically useful information.

Our objective in the Second Edition of *Abdominal Imaging* is the same as in the first: to provide you, the reader, with a reference that is both comprehensive and that incorporates features more typically found in handbooks—short, readable sentences, key fact boxes, summary tables, abbreviated reference lists, listings of important review articles, and, above all, a highly integrated knowledge base that allows readers to rapidly access key content from any Internet-connected computer anywhere in the world.

This text is necessarily the work of many people: The numerous chapter authors of the first edition, Associate Editors, Section Editors, and authors of the new chapters. To all of you—we are profoundly grateful for your work. Our efforts would not have been possible without the understanding and strong support of our families and colleagues. We have also been privileged to work with an outstanding team at Elsevier. Marybeth Thiel demonstrated patience and perseverance dealing with busy editors—with you the project would never have been completed. Robin Carter—thank you for inviting us to complete the second edition.

As with the first edition, editing this book has been a tremendous education. We've learned so many new and interesting information about our own subspecialty that we believe there is something exciting in these pages for everyone from the seasoned subspecialist to the busy generalist.

Plain Radiography of the Abdomen

ERNESTO TOMEI | VITO CANTISANI | ANDREA MARCANTONIO |
UGO D'AMBROSIO | KOICHI HAYANO

Technical Aspects

A plain abdominal radiograph must be read with a complete knowledge of the clinical situation. The patient's history and results of the physical examination and laboratory studies are always important to evaluate an acute abdomen, which may be caused by various different diseases. Obtaining plain films with the patient supine and erect and that include the diaphragm is the classic approach. Because chest abnormalities may produce an acute abdomen, a chest posteroanterior radiograph is sometimes ordered.

The standard abdominal radiograph is a supine projection: x-rays are passed from front to back (anteroposterior projection) in a patient lying on his or her back (Figure 1-1). In some circumstances, an abdominal radiograph taken with the patient erect is requested; its advantage over a supine film is the visualization of air/fluid levels. A decubitus film (with the patient lying on his or her side) is also of use in certain situations, especially to visualize fluid levels in the large bowel.

It is important, as with any imaging technique, that the technical details of an abdominal radiograph are assessed. The date the film was taken and the name, age, and sex of the patient are all worth noting. This ensures you are reviewing the correct film with the correct clinical information, and it also may aid your interpretation. Unless the order is specifically labeled, the film is taken with the patient supine. The best way to appreciate normality is to look at as many films as possible, with an awareness of anatomy in mind. Although an abdominal radiograph is a plain radiograph, it has a radiation dose equivalent to 50 posteroanterior chest radiographs or 6 months of standard background radiation.¹

Pros and Cons

Many techniques may be used to acquire images of the abdomen, including ultrasonography, computed tomography (CT), and magnetic resonance imaging (MRI), but the plain abdominal radiograph is the technique that is most readily available in the emergency situation when a patient presents with acute abdominal pain.

Radiographs should never be requested without due consideration. They expend resources and expose the patient to ionizing radiation. They are an adjunct to a careful history and thorough physical examination.

The abdominal radiograph has the advantage of low cost. It is easy to perform and can be done on uncooperative patients, and, if correctly carried out and carefully interpreted,² it can still be used with a dual purpose. It can be used to evaluate catheter placement; identify ingested, inhaled, or introduced foreign bodies or free air in patients with a gastrointestinal perforation (conditions for which the examination is often

diagnostic); or assess a condition of intestinal occlusion or an abdomen in the postoperative phase. It also can be of use in documenting the intestinal morphodynamics, the findings of which at the direct examination of the abdomen depend on both the cause of the acute pathologic process and the time when the examination is performed with respect to the onset of the insult.³ In addition, plain abdominal radiographs are an accessible, relatively inexpensive, convenient, and accurate method of detecting retained surgical needles. They can be used effectively to locate needles over 10 mm in length retained in the abdomen, with a sensitivity of 92% in this size range. In this scenario, plain abdominal radiographs should continue to be used after incorrect needle counts. It is also recommended that the requesting physician provide the radiologist the size of the lost needle. However, for missing needles of 10 mm or less in length, the utility of plain abdominal radiographs is more debatable.⁴

Conversely, criticisms of requests for abdominal films often quote a low number of cases in which the diagnosis or management was changed by the radiographic findings. The diagnostic value is questionable, and very often there is no clear indication. In the majority of cases, the results are negative or nonspecific. In fact, as reported in a recent article by Kellow and colleagues,⁵ the results of abdominal radiography are neither sensitive nor specific. Flak and Rowley⁶ suggested that there are only two clinical entities in which sensitivity of abdominal radiography approaches 100%: free intraperitoneal air and, to a lesser extent, bowel obstruction. For the latter indication, a prospective trial conducted by Frager and associates⁷ determined that clinical and radiographic evaluation was never precise enough to provide the exact location or cause of small bowel obstruction. Furthermore, Taourel and coworkers⁸ demonstrated that not only is CT valuable in making a more accurate diagnosis but also that clinical treatment was correctly modified in 21% of patients because of the additional information provided by using CT. Therefore, abdominal radiography appears of limited value in the initial diagnosis of obstruction. For the indication of free air, the diagnosis is better made by evaluation of a chest radiograph obtained with the patient erect.⁹ In addition, only a few physicians are aware of the relatively high radiation dose of an abdominal film, which is equal to 50 chest radiographs.¹⁰

Controversies

In the 1950s, gastrointestinal radiology consisted of plain abdominal films and single-contrast barium studies to assess gastrointestinal diseases.¹¹ Today, the plain radiograph still may be the first step to evaluate acute abdominal diseases. However, with the advent of CT and ultrasonography, the importance of the plain abdominal film is decreasing. In past years, plain radiography was also used to help diagnose abdominal pathologic

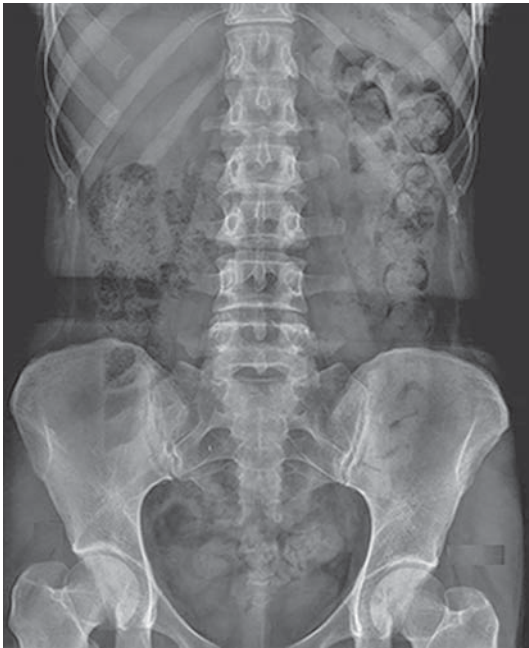


Figure 1-1 Normal anteroposterior abdominal plain film.

processes such as stones in the kidney, gallbladder, or bladder. Plain radiography is now limited to emergency radiology in the acute abdomen. However, despite the undoubted advantages of the speed of examination, the multiplanar capabilities, and the objectivity of interpretation, CT subjects the patient to a higher dose of ionizing radiation.¹² The role of plain radiography of the abdomen in the diagnosis of acute abdomen needs to be reconsidered.¹³ According to some authors, plain radiography should be performed only in patients for whom there are known advantages, such as in the case of suspected gastrointestinal perforation,¹⁴ intestinal occlusion, ingestion of or the search for foreign bodies,¹⁵ and assessment of the postoperative abdomen¹⁶; in these cases, it is still the examination of choice, and only if it does not prove diagnostic should a CT examination be recommended.¹⁷ In addition to these situations, however, there is another indication: the ability of plain radiography to assess the evolution of intestinal morphodynamism, that is, the variations in the motility, shape, and position of the small bowel in acute pathologic conditions.¹⁸ Even though in the first instance assessing the cause or the precise site of the obstruction is advisable, differentiating at least a mechanical ileus from a paralytic ileus,¹⁹ and above all having an understanding of the seriousness and the extension of the cause and the time elapsed since its onset²⁰ can prove clinically more useful. Few comparisons of plain abdominal radiographs and CT scans exist in the literature. Siewert and associates²¹ reported on 91 admitted patients with acute abdominal pain who eventually received CT because of continuing symptoms or failure to respond to therapy. In this series, treatment was changed after CT in 25 patients (27%), but the authors did not state the relative contribution of the plain abdominal radiographs to the pre-CT diagnosis. In particular, the percentage of patients who had abnormal plain abdominal radiographs was not given. A retrospective review of 23 patients with proved mesenteric infarction compared plain abdominal radiographs with CTs and showed that 6 patients (26%) had abnormal plain abdominal radiographs only, 8

patients (35%) had abnormal CTs only, and in only 1 patient (4%) were both tests abnormal.²² Both studies were normal or nonspecific in 8 patients (35%). That 26% of patients had signs of an acute abdominal syndrome shown only on plain abdominal radiographs and not on CT is in sharp contradiction to our findings, in which the plain abdominal radiographs provided minimal additional information in 2 of 74 patients (3%) and at the cost of 33 (57%) potentially misleading false-negative results. There are several possible explanations. Mesenteric infarction may represent one of a series of specific syndromes that have either relatively low CT sensitivity, high plain abdominal radiograph sensitivity, or both. In the review just cited, no patients were diagnosed on plain abdominal radiographs, CT, or clinical course with this syndrome. Other possibilities include individual or institutional variations in radiologic interpretations or improvement in the interpretation of CTs for this and other syndromes over the past decade. The increased imaging capabilities of this newer technology would most likely make the test characteristics of the newer CT scanners even more favorable. Despite these limitations, for emergency department patients with acute abdominal, flank, or back pain, in whom a CT is likely to be obtained, a preliminary plain abdominal radiograph adds almost no additional information and is potentially misleading. Given the utilization of resources required for plain abdominal radiographs as well as the time delay to obtain them, some authors believe that patients in whom the clinical suspicion of significant intra-abdominal pathology is high should go directly to CT.²³

Normal Anatomy

As with any plain radiograph, only five main densities may be distinguished, four of which are natural: black for gas, white for calcified structures, gray representing a host of soft tissue, and a slightly darker gray for fat (because it absorbs slightly fewer x-rays). Metallic objects are seen as an intense bright white. The clarity of outlines of structures depends, therefore, on the differences among these densities. On the chest radiograph, this is easily shown by the contrast between lung and ribs as black air against the white calcium-containing bones. These differences are much less apparent on the abdominal radiograph because most structures are of similar density, mainly soft tissue. A systematic approach to plain abdominal radiographs will help avoid errors in interpretation. Interpretation of the abdominal radiograph depends on the assessment of the bowel gas pattern, solid organ outlines, a search for abnormal calcification, and a review of the skeleton. A search should be made for extraluminal gas. A bowel gas pattern distinguishing the colon from the small bowel may be difficult. The presence of solid feces and the distribution, caliber, and mucosal pattern of the bowel help in deciding whether a particular loop of bowel is stomach, small intestine, or colon. The presence of solid feces indicates the large bowel, which also may be recognized by the incomplete haustral band crossing the colonic gas shadow. Haustra are usually present in the ascending and transverse colon but may be absent from the splenic flexure and descending colon. The valvulae conniventes of the small bowel are closer together and cross the width of the bowel. The distal ileum when dilated can appear smooth, which makes differentiation more difficult. The small bowel when obstructed is generally centrally positioned with numerous loops of tighter curvature than the large bowel. Maximal small bowel caliber is 3.5 cm in the jejunum and

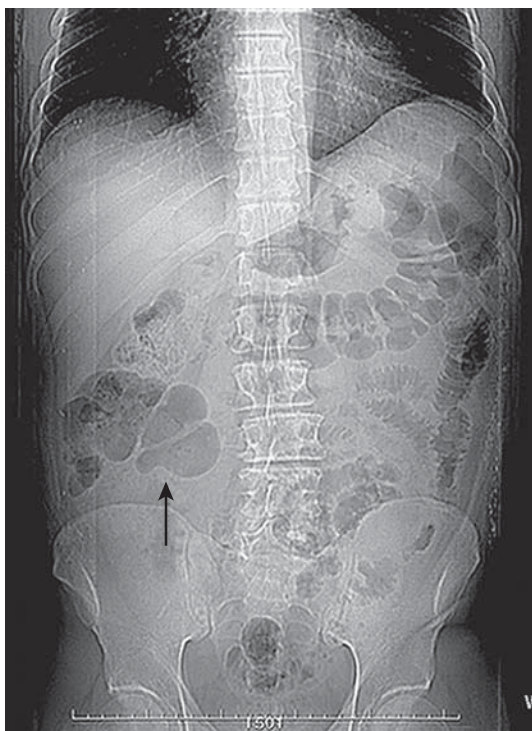


Figure 1-2 Diverticulitis and peridiverticulitis. There is no evidence of bowel distention at the level of either the colon or the small bowel. It is possible to see a mild air dilation of the small bowel. The cecum seems to be medially moved (arrow).

2.5 cm in the ileum. Maximal caliber of the transverse colon on plain films is taken to be 5.5 cm in diameter, and the maximal cecal diameter is 9 cm. Solid organs, the liver edge, renal outlines, and the splenic tip may all be demonstrated.

INTRALUMINAL GAS

One should begin by looking at the amount and distribution of gas in the bowels (intraluminal gas). There is considerable normal variation in the distribution of bowel gas (Figure 1-2). On the abdominal radiograph taken with the patient erect, the gastric gas bubble in the left upper quadrant of the film is a normal finding. Gas is also normally seen within the large bowel, most notably the transverse colon and rectum. Small and large bowel also can be distinguished, most easily when dilated, by their different mucosal markings. Small bowel has valvulae conniventes that traverse the full width of the bowel; large bowel has haustra that cross only part of the bowel wall. These features are important in the next part of this series, which considers abnormal intraluminal gas. Occasionally, fluid levels in the small bowel are a normal finding. Fecal matter in the bowel gives a “mottled” appearance. This is seen as a mixture of gray densities representing a gas/liquid/solid mixture.

EXTRALUMINAL GAS

Gas outside the bowel lumen is invariably abnormal (Figure 1-3). The largest volume of gas one might see is likely to be under the right diaphragm; this occurs after a viscus has been perforated. This gas within the peritoneal cavity is termed

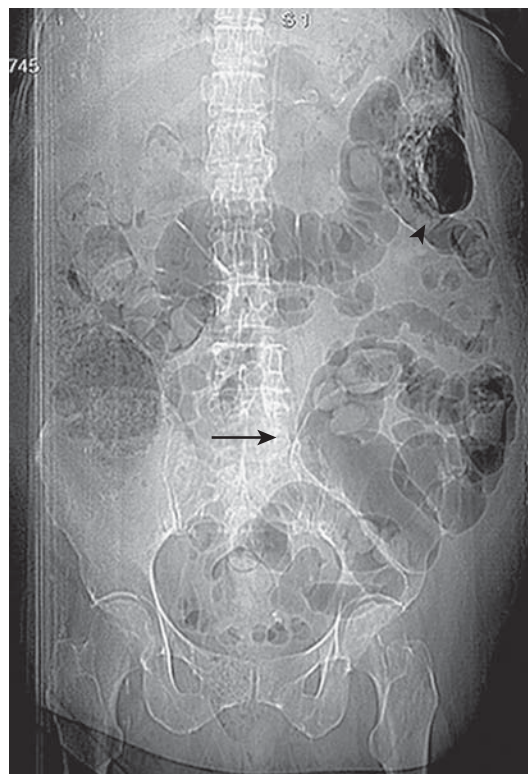

Figure 1-3 Mesenteric ischemia and spleen infarction. Abdominal radiograph shows a colonic dilation (arrow) that is especially marked at distal segments. Furthermore, extracolonic air collections are visible at the spleen level (arrowhead) in the upper left quadrant. Bowel dilation is evident without the finding of bowel obstruction.

BOX 1-1 AREAS TO SEARCH FOR ABNORMAL EXTRALUMINAL GAS

- Under the diaphragm
- In the biliary system
- Within the bowel wall

pneumoperitoneum. Gas in the right upper quadrant within the biliary tree is a “normal” finding after sphincterotomy or biliary surgery, but it can indicate the presence of a fistula between the biliary tree and the gut. One must beware of gas in the portal vein, because this can look very similar to biliary air. Gas in the portal vein is always pathologic and frequently fatal. It occurs in ischemic states, such as toxic megacolon, and it may be accompanied by gas within the bowel wall (intramural gas) (Box 1-1).

CALCIFICATION

Calcium is visible in a variety of structures, both normal and abnormal, and becomes more common with advancing age. Calcification should be identified and anatomically located. In some locations (e.g., vascular calcification), it is common and benign. Vascular calcification may be seen within the aorta, in the splenic artery in the left upper quadrant, or in the pelvis. Abdominal aortic aneurysms are usually below the second lumbar vertebra. Calcification can make them obvious and can

give a rough indication of the internal diameter. Abdominal ultrasonography is required for accurate assessment and to determine the need for surgery or follow-up. Uterine fibroids can become calcified.

Calcified renal tract stones should be looked for around the renal outlines and down the line of the ureters. More rarely, calcified gallstones are seen in the right upper quadrant or a calcified (porcelain) gallbladder is present. The pancreas lies at the level of the T9 to T12 vertebrae. Calcification occurs in chronic pancreatitis and may show the whole outline of the gland.

In the pelvic region, bladder calculi may occasionally be seen. Bladder stones are usually quite large and often multiple. Calcification of a bladder tumor also may occur. Schistosomiasis may produce calcification of the bladder wall.

Other causes of pelvic calcification include phleboliths, calcified fibroids, and, rarely, calcification in ovarian dermoids, which may also contain teeth and hair.

SOFT TISSUES AND BONE

A review of the soft tissues entails evaluating the outlines of the major abdominal organs. Observing these structures is made easier by the fatty rim (properitoneal fat lines) surrounding them. In fact, the loss of these fat planes may indicate an ongoing pathologic process, such as peritonitis.

The liver is seen in the right upper quadrant and extends downward a variable distance. The tip of the right lobe may be seen extending below the right kidney; this is a normal variant called Riedel's lobe. The spleen may be visualized (especially in thin individuals) even when of normal size. It enlarges inferiorly and toward the left lower quadrant. It is often possible to identify both kidneys and the psoas shadows within the retroperitoneum. The kidneys are lateral to the midline in the region of the T12 to L2 vertebrae. (NOTE: A useful way to identify vertebrae is that the lowest one to give off a rib is T12 and thus can serve as a reference point.)

Soft tissue masses or abscess can sometimes be identified on plain films. An abscess generally has a rather heterogeneous density because of the presence of gas and necrotic tissue. Mass lesions are of soft tissue density and will displace bowel gas shadows.

The assessment of bones entails evaluating the spine and pelvis for evidence of a bony pathologic process. Osteoarthritis frequently affects the vertebral bodies, as well as the femoral and the acetabular components of the hip joint. Paget's disease may be identified commonly along the iliopectineal lines of the pelvis. The bone survey should also include a check for fractures, especially subtle femoral neck fractures in elderly persons. The spine and pelvis are also common locations for metastatic deposits. In the spine, this is classically seen as "the absent pedicle."

ARTIFACTS

"Human-made" structures should be correctly identified. These may be iatrogenic (put there by health care professionals), accidental (put there by the patient or another person), or projectional (lying in front of or behind the abdomen but spuriously projected within it on the abdominal radiograph). Examples of iatrogenic structures would be surgical clips, an intrauterine

contraceptive device, a renal or biliary stent, an endoluminal aortic stent, or an inferior vena cava filter. Accidental findings include bullets or an object in the rectum. Projectional findings include pajama buttons, coins in pockets, or body piercings.

Pathologic Findings

Abdominal radiographs obtained with the patient erect are requested to look for fluid levels in obstruction or ileus. Air under the diaphragm may be seen in an erect film if the bowel has been perforated, although a chest radiograph is more commonly obtained to look for that sign (Figure 1-4). An abdominal radiograph is of no value in hematemesis. Avoiding obtaining erect films when unnecessary and avoiding plain films for hematemesis will reduce the level of radiation exposure.

RENAL COLIC

If a patient presents with groin pain, the possibility of renal colic is high; therefore, a kidney/ureter/bladder (KUB) view is requested. Approximately 90% of renal stones are radiopaque. Uric acid stones may be missed. False-positive findings may occur from phleboliths, which are most common in the pelvic veins, and false-negative findings occur from small stones. On the right, calcification may represent gallstones but only a minority of gallstones are radiopaque. The presence of gallstones does not confirm biliary colic as the cause of pain because

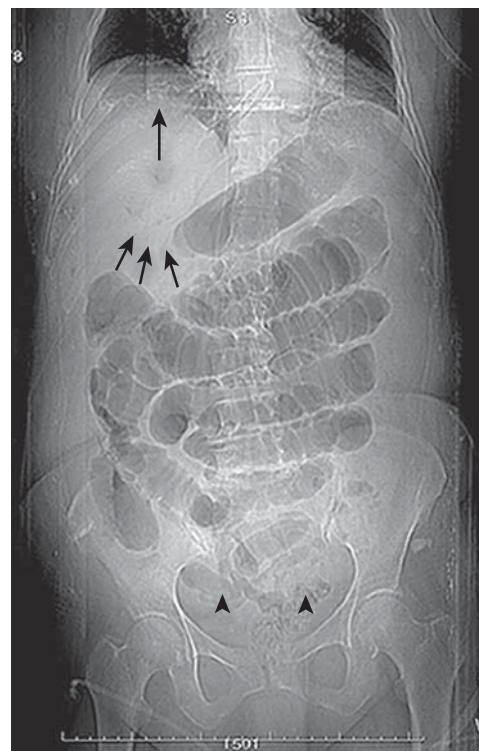


Figure 1-4 Sigmoid carcinoma. Wide sickle-shaped free air is evident under the right hemidiaphragm (large arrow). A small, linear, free air collection is also shown along the lower margin of the liver (small arrows). Marked air distention of jejunum with a transitional area between dilated jejunum and normal ileum is visible (arrowheads).

gallstones become more frequent with age and are often asymptomatic.

INTESTINAL OBSTRUCTION

Erect and supine films are used to confirm the diagnosis. Obstruction of the small bowel shows a ladder-like series of small bowel loops, but this also occurs with an obstruction of the proximal colon. Fluid levels in the bowel can be seen in upright views. Distended loops may be absent if obstruction is at the upper jejunum. Obstruction of the large bowel is more gradual in onset than small bowel obstruction. The colon is in the more peripheral part of the film, and distention may be very marked. Fluid levels also will be seen in paralytic ileus when bowel sounds will be reduced or absent rather than loud and tinkling as in obstruction. In an erect film, a fluid level in the stomach is normal, as may be a level in the cecum. Multiple fluid levels and distention of the bowel are abnormal.

PERFORATION OF THE INTESTINE

If the bowel has been perforated and a significant amount of gas has been released, it will show as a translucency under the diaphragm on an erect film. Gas will also be found under the diaphragm for some time after laparotomy or laparoscopy.

APPENDICITIS

An appendicolith may be apparent in an inflamed appendix in 15% of cases, but as a diagnostic point in the management of appendicitis the plain radiograph is of very limited value, although it may be of value in infants.

INTUSSUSCEPTION

Intussusception occurs in adults and children. A plain abdominal radiograph may show some characteristic gas patterns. A sensitivity and specificity of 90% adds to this rather difficult diagnosis, but ultrasonography is vastly superior.

BODY PACKERS

An increasing problem occurs with people who swallow drugs, usually in condoms, to evade detection. There may be signs that the drugs are leaking, but the carrier is unwilling to disclose the fact for fear of a long prison term, even at risk to life. A plain abdominal radiograph will show 90% of cases, but there will be false-positive findings in 3%. Therefore, a positive result is likely to be true but a negative result does not exclude the clinical suspicion adequately and an ultrasound examination may be considered (Boxes 1-2 and 1-3).

Pathophysiology

SMALL BOWEL

The small bowel contains a small amount to no gas in normal individuals, so it is not visible on a plain film. The presence of more gas than normal should be viewed with suspicion and interpreted in the proper clinical setting. Some clinical situations, such as indigestion or viral enteritis, show an increase of intestinal gas, usually without air/fluid levels; these are self-limiting diseases, and usually they do not need diagnostic efforts.

Intestinal obstruction is a common radiographic finding in an emergency department. Distended intestinal loops with air/fluid levels with scarcely visible colonic gas are among the most commonly seen features of small bowel obstruction; the clinical history of the patient may be the key to the diagnosis in the case of suspected postoperative adhesions, Crohn's disease, or a known tumor. In some cases, however, depending on the gas and fluid distribution it is not impossible to have a near-normal plain film with a true obstruction. On the other hand, diffuse peritoneal metastasis may produce air/fluid levels without obstruction. The level of the intestinal obstruction may be, in some cases, understood; however, in prestenotic loops the fluid may be abundant and gas not visible so that only proximal loops are distended by gas. Again, fluid-filled intestinal loops showing the cause of obstruction either of the bowel wall or extraintestinal are often easily seen at CT. The diagnosis of strangulation requires expertise because the intramural gas and a rigid loop are well-known features but not so commonly seen. It should be remembered that the shape of valvulae conniventes is also generally preserved in severe distention so that they can be used to differentiate small intestinal disease from colonic disease.

The adhesions are not directly seen, but a transition zone (dilatation of the bowel followed by a collapsed loop) without any other visible cause of obstruction may lead to the diagnosis in a patient with a history of surgery.

CT performed after a plain abdominal film can be obtained without oral contrast administration, but intravenous administration of a contrast agent usually cannot be avoided in these often severely ill patients.

A set of CT criteria that may help surgeons decide if a patient needs surgery for small bowel obstruction has been implemented.²⁴ Although plain radiography can be used with good results by experienced surgeons, CT has been reported to have 100% sensitivity in complete obstruction.²⁵ Daneshmand and colleagues compared CT to plain radiography and found a sensitivity and specificity of 75% and 53% for plain film, respectively, and 92% and 71% for CT; they suggest that CT can be used as the primary diagnostic tool for small bowel obstruction.²⁶ The approach to evaluate patients with small bowel

BOX 1-2 KEY TO DENSITIES IN ABDOMINAL RADIOGRAPHS

- Black—gas
- White—calcified structures
- Gray—soft tissues
- Darker gray—fat
- Intense white—metallic objects

BOX 1-3 RADIOGRAPHIC REVIEW POINTS

- Technical specifics of the radiograph
- Amount and distribution of gas
- Extraluminal gas
- Calcification
- Soft tissue outlines and bony structures
- Iatrogenic, accidental, and incidental objects

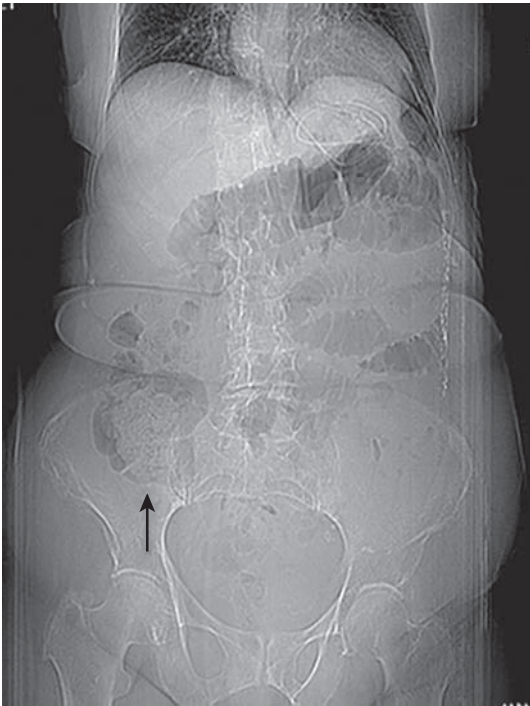

Figure 1-5 Volvulus. Visible fecal material (arrow) is evident in the right colon, whereas the left and sigmoid colon are not represented. Moderate distention of bowel in the upper abdomen can be seen. In the left lower quadrant, a mass is suspected because of the lack of intestinal air.

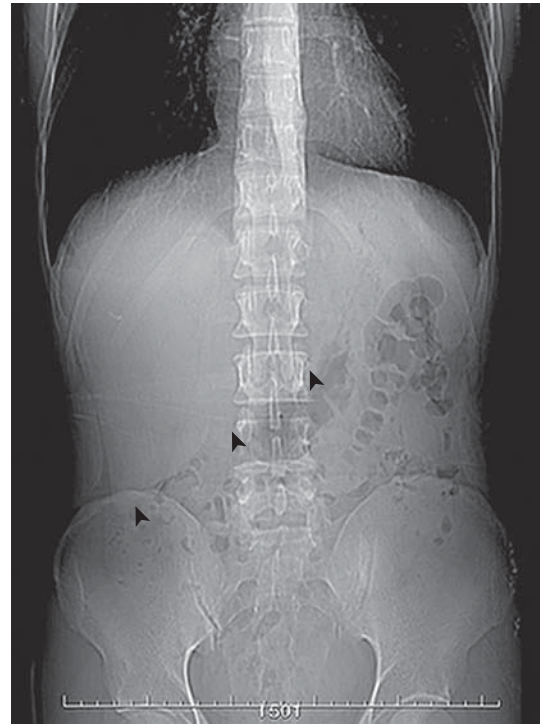


Figure 1-6 Perisigmoid abscess. Note enlargement of the hepatic area (arrowheads). Small bowel and colon are within the normal range for size.

obstruction is not generally accepted; however, CT is considered the preeminent imaging modality to evaluate these patients.²⁷

COLON

Because of the presence of haustra, feces, and gas, understanding diseases of the colon is apparently easier than recognizing diseases of the small bowel on a plain radiograph. An obstruction of the sigmoid colon shows the transition from a dilated to a nondilated colon, and it is not difficult to recognize. On the other hand, an obstruction of the ascending colon may be similar, in some cases, to an obstruction of the last ileal loop. Colonic obstruction producing a severe cecal dilatation greater than 10 to 11 cm is an indication for immediate surgery, to avoid perforation. In elderly constipated patients, a sigmoid volvulus is among the possible causes of obstruction; the dilated sigmoid that is seen as a “kidney bean” also may mimic an abdominal mass. Cecal volvulus, seen in younger patients, produces distention of the cecum (Figure 1-5). In both cases, CT can provide crucial information.

Severe clinical situations such as perirectal or perisigmoidal abscesses or a carcinoma infiltrating bowel wall without obstruction may have a completely normal appearance on a plain film (Figure 1-6); these situations are easily seen on CT.

Distention of the colon, often accompanied with diffuse distention of the small bowel without mechanical obstruction, is the feature of paralytic or adynamic ileus. The intestinal distention may be limited to some part of the intestine so that it may be difficult to distinguish mechanical from paralytic ileus.

The clinical situation of the patient may be enough, in some cases, to make the diagnosis. If the diagnosis is not clear, CT is mandatory.

Ischemic bowel disease produces many different abnormalities on a plain radiograph, ranging from intestinal distention to a gasless abdomen. “Thumbprinting” is a famous, but not so specific, feature of intestinal ischemia. A linear shadow of gas within the bowel wall is difficult to detect on a plain film; when visible, it indicates a poor prognosis.

Toxic megacolon may be a lethal complication of ulcerative colitis. A plain film shows a dilatation of the transverse colon greater than 6 to 8 cm with loss of haustra. The loss of a haustral pattern is important to distinguish a patient with an obstruction of the distal colon from a patient with colitis, in which a haustral pattern is usually lost, even with mild disease. Small bowel distention, often with air/fluid levels, may be seen in a subgroup of patients with severe ulcerative colitis at higher risk for both toxic megacolon and multiple organ dysfunction syndrome. The poor response to therapy and the persistence of gastrointestinal distention are monitored with plain radiography, which is important to evaluate patients who need colectomy.²⁸

MISCELLANEOUS FINDINGS

Free intraperitoneal or subphrenic air is commonly seen in postoperative patients, and the only thing to do is wait for its resorption. A deep intestinal or colonic biopsy also can produce, as a rare complication, free or subphrenic air collection. Perforation of a duodenal ulcer or perforation of a diverticulum

of the colon are not as common causes of extraintestinal air collections.

Cholecystitis, pancreatitis, and other causes of acute abdomen in which a collection of air or fluid may be misleading

should now be assessed by ultrasonography or CT. Fecaloma is easy to detect on a plain film; however, a digital exploration of the rectum is preferred to diagnose this lesion.

Key Points

- The history, physical examination, and laboratory findings are always important to evaluate an acute abdomen, which may be caused by a number of different diseases.
- Plain radiography should be performed as an initial imaging modality in patients for whom there are known advantages, such as those with suspected gastrointestinal perforation, intestinal occlusion, and ingestion of or in a search for foreign bodies, and in the assessment of the postoperative abdomen to detect retained needles. In addition, another indication is the ability of plain radiography to assess the evolution of intestinal morphodynamism, which is the variation in the motility, shape, and position of the small bowel in acute pathologic conditions.
- The lack of positive findings on abdominal radiography is falsely reassuring in nontrauma emergency department patients.
- Further imaging is often required to better characterize abnormalities identified at abdominal radiography.

SUGGESTED READINGS

Anonymous: Best evidence topic reports: role of plain abdominal radiograph in the diagnosis of intussusception. *Emerg Med J* 25:106–107, 2008.

Brazaitis MP, Dachman AH: The radiologic evaluation of acute abdominal pain of intestinal origin: a clinical approach. *Med Clin North Am* 77:939–961, 1993.

Burkill G, Bell J, Healy J: Small bowel obstruction: the role of computed tomography in its diagnosis

and management with reference to other imaging modalities. *Eur Radiol* 11:1405–1422, 2001.

Gupta H, Dupuy DE: Advances in imaging of the acute abdomen. *Surg Clin North Am* 77:1245–1263, 1997.

Hayes R: Abdominal pain: general imaging strategies. *Eur Radiol* 14(Suppl 4):L123–L137, 2004.

Kidmas AT, Ekedigwe JE, Sule AZ, et al: A review of the radiological diagnosis of small bowel obstruction

using various imaging modalities. *Niger Postgrad Med J* 12:33–36, 2005.

Reuchlin-Vroklage LM, Bierma-Zeinstra S, Benninga MA, et al: Diagnostic value of abdominal radiography in constipated children: a systematic review. *Arch Pediatr Adolesc Med* 159:671–678, 2005.

Roszlér MH: Plain film radiologic examination of the abdomen. *Crit Care Clin* 10:277–296, 1994.

REFERENCES

- Levine MS: Plain film diagnosis of the acute abdomen. *Emerg Med North Am* 3:541–562, 1985.
- Baker SR: The abdominal plain film: what will be its role in the future? *Radiol Clin North Am* 31:1335–1344, 1993.
- Grassi R, Di Mizio R, Pinto A, et al: Semeiotica radiografica dell'addome acuto all'esame radiologico diretto: ileo riflesso spastico, ileo riflesso ipotonico, ileo meccanico ed ileo paralitico. *Radiol Med* 108:56–70, 2004.
- Ponrartana S, Coakley FV, Yeh BM: Accuracy of plain abdominal radiographs in the detection of retained surgical needles in the peritoneal cavity. *Ann Surg* 247:8–12, 2008.
- Kellow ZS, MacInnes M, Kurzencwyg D, et al: The role of abdominal radiography in the evaluation of the non-trauma emergency patient. *Radiology* 248:887–893, 2008.
- Flak B, Rowley VA: Acute abdomen: plain film utilisation and analysis. *Can Assoc Radiol J* 44:423–428, 1993.
- Fragar DH, Baer JW, Rothpearl A, et al: Distinction between postoperative ileus and mechanical small-bowel obstruction: value of CT compared with clinical and other radiographic findings. *AJR Am J Roentgenol* 164:891–894, 1995.
- Taourel P, Pradel J, Fabre JM, et al: Role of CT in the acute non-traumatic abdomen. *Semin Ultrasound CT MR* 16:151–164, 1995.
- McCook TA, Ravin CE, Rice RP: Abdominal radiography in the emergency department: a prospective analysis. *Ann Emerg Med* 11:7–8, 1982.
- Campbell JB, Gunn AA: Plain abdominal radiographs and acute abdominal pain. *Br J Surg* 75:554–556, 1988.
- Goldberg HJ, Margulis AR: Gastrointestinal radiology in US: an overview of the past 50 years. *Radiology* 216:1–7, 2000.
- Baker SR: Musings at the beginning of the hyper-CT era. *Abdom Imaging* 28:110–114, 2003.
- Feyler S, Williamson V, King D: Plain abdominal radiographs in acute medical emergencies: an abused investigation? *Postgrad Med J* 78:94–96, 2002.
- Grassi R, Pinto F, Rotondo A, et al: Contributo della radiologia tradizionale alla diagnosi di pneumoperitoneo. In Pinos A, editor: *Pneumoperitoneo*, Napoli, 1996, Guido Gnocchi, pp 7–158.
- Baker SR: Plain films and cross-sectional imaging for acute abdominal pain: unresolved issues. *Semin Ultrasound CT MRI* 20:142–147, 1999.
- Frassinetti A: *La Radiologia dell'Addome Acuto Postoperatorio*. Padua, Piccin, 1982.
- Wiest P, Roth P: *Fundamentals of emergency radiology*, Philadelphia, 1996, WB Saunders, pp 96–112.
- Taourel P, Kessler N, Lesnik A, et al: Non-traumatic abdominal emergencies: imaging of acute intestinal obstruction. *Eur Radiol* 12: 2151–2160, 2002.
- Krestin GP, Choyke PL: *Acute abdomen: diagnostic imaging in the clinical context*, Stuttgart, 1996, Georg Thieme, p 139.
- Silen W: *Cope's early diagnosis of the acute abdomen*, New York, 2005, Oxford University Press, p 159.
- Siewert B, Raptopoulos V, Mueller M, et al: Impact of CT on diagnosis and management of the acute abdomen in patients initially treated without surgery. *AJR Am J Roentgenol* 168:173–178, 1997.
- Smerud MJ, Johnson CD, Stephens DH: Diagnosis of bowel infarction: a comparison of plain films and CT scans in 23 cases. *AJR Am J Roentgenol* 154:99–103, 1990.
- Nagurney JT, Brown DE, Novelline DA, et al: Plain abdominal radiographs and CT scans. *Am J Emerg Med* 17:668–671, 1999.
- Jones K, Mangram AJ, Lebron RA, et al: Can a computed tomography scoring system predict the need for surgery in small-bowel obstruction? *Am J Surg* 194:780–784, 2007.
- Fragar D, Medwid SW, Baer JW, et al: CT of small bowel obstruction: value in establishing the diagnosis and determining the degree and cause. *AJR Am J Roentgenol* 162:37–41, 1994.
- Daneshmand S, Hedley CG, Stain SC: The utility and reliability of CT in the diagnosis of small bowel obstruction. *Am Surg* 65:922–926, 1999.
- Ros PR, Huprich JE: ACR appropriateness criteria on suspected small bowel obstruction. *J Am Coll Radiol* 3:838–841, 2006.
- Latella G, Vernia P, Viscido A, et al: GI distension in severe ulcerative colitis. *Am J Gastroenterol* 5:1169–1175, 2002.

Fluoroscopic Study of the Abdomen and Fluoroscopic Contrast Media

NAVEEN M. KULKARNI | PRITISH AHER | KOICHI HAYANO

Fluoroscopy is a type of imaging technique in which real-time movements of body organs and radiopaque contrast material are visualized. During a fluoroscopic examination, the operator or radiologist controls the functions of radiography equipment and x-ray tubes for real-time imaging of the patient. In abdominal imaging, fluoroscopy has a role in the diagnosis of various clinical conditions with gastrointestinal studies, postoperative studies, genitourinary studies, and more.

Technical Aspects

FLUOROSCOPY

History

Early fluoroscopes had an x-ray tube and fluorescent screen made of barium platinocyanide. Gradually, the screens were replaced by cadmium tungstate and then zinc-cadmium sulfide, which produced a yellow-green emission.¹

Fluoroscopy has evolved from the early days of images on a fluoroscopic screen of poor quality, a dark radiography room, and eye adaptation with red goggles to improved images with image intensifiers, video-recorders, and a variety of C-arm machines. Currently, it is available in many different configurations for use in various clinical applications. With technologic advancements in hardware and image processing, fluoroscopy has gained substantially both qualitatively and quantitatively. The introduction of flat-panel detectors, high-quality image intensifiers with video-recording capabilities, state-of-the-art C-arm design, and digital units has revolutionized the field of fluoroscopic imaging.^{1,2} The superior spatial and contrast resolution combined with faster image reconstruction and reduced radiation along with a variety of safe and effective contrast media has empowered fluoroscopy with advanced capabilities in the diagnostics and interventional realm. A variety of fluoroscopic units are now commercially available, and the components of basic fluoroscopic equipment are shown in [Figure 2-1](#). The main uses of fluoroscopy are listed in [Box 2-1](#).

Patient Preparation

It is important to have the patient empty his or her stomach to increase the sensitivity of the fluoroscopy examination, because food and food residue can mimic disease. Informed consent is required, and any medical history such as heart disease, asthma, allergy, thyrotoxicosis, and hypersensitivity to drugs should be elicited. Also important to consider: What medications (e.g., insulin) is the patient using? Is the patient pregnant or breastfeeding? Has there been a recent diagnosis of small bowel

obstruction or perforation and, if so, what were the surgical details?

Patients scheduled for a double-contrast barium enema must adhere to a clear liquid diet for 24 hours before the procedure. Laxatives may be prescribed to ensure thorough bowel cleansing, and on the morning of the examination a bisacodyl suppository is given per rectum.

However, in the acute/emergency or postoperative setting, patient preparation is usually optional. Moreover, in this setting, iodinated contrast media are preferred over barium sulfate because the latter might interfere with a surgical procedure and any extraluminal collection of barium may create confusion with a diagnosis on subsequent examinations.³⁻⁵ A medical history of severe hypersensitivity to iodinated contrast media or certain medications should be obtained if the procedure requires its use.

FLUOROSCOPIC EXAMINATIONS

Fluoroscopic examinations are of two types: single-contrast studies and double-contrast studies ([Box 2-2](#)). Single-contrast studies are performed either with barium or with iodinated contrast media.^{6,7} For double-contrast media, air or carbon dioxide is used ([Figure 2-2](#)).^{8,9}

Gastrointestinal Fluoroscopic Procedures

- Stomal examinations, enema through ileostomy or colostomy for patency, recurrence of disease, and leak
- Feeding tube studies
- Oral cholecystogram and T-tube cholangiogram
- Hydrostatic reduction of pediatric abdominal emergencies such as intussusceptions and sigmoid volvulus

Genitourinary Fluoroscopic Procedures

- Cystography for evaluation of urinary bladder and vesicoureteric reflux
- Voiding cystourethrography for visualization of urethra
- Retrograde urethrography for anterior urethra
- Hysterosalpingogram for uterus and fallopian tubes

Interventional Procedures

- Placement of vascular catheter and stents
- Percutaneous biliary drainage procedures
- Urologic procedures: Retrograde pyelography, percutaneous nephrostomies, and suprapubic cystostomies

Other Examinations

- Sinogram
- Fistulogram

Fluoroscopic Contrast Agents

Fluoroscopic contrast agents are compounds that enable improved visualization of internal luminal structures, spaces, and tracts and also delineate tubes and catheters on fluoroscopy or radiography (Figure 2-3).

Fluoroscopic contrast agents can be divided into two types: positive contrast and negative contrast. A positive contrast medium absorbs x-rays more strongly than the surrounding tissue or organ being examined and appears radiopaque. A

negative contrast medium absorbs x-rays less strongly and hence appears radiolucent. Positive contrast media are barium and iodine compounds (Figures 2-4 and 2-5). Negative contrast media can be obtained by air or carbon dioxide (Figure 2-6).^{10,11}

BARIUM

The higher the concentration of the barium sulfate suspension, the thinner are the layers that can be identified in the radiograph. The more viscous is the suspension, the better is the

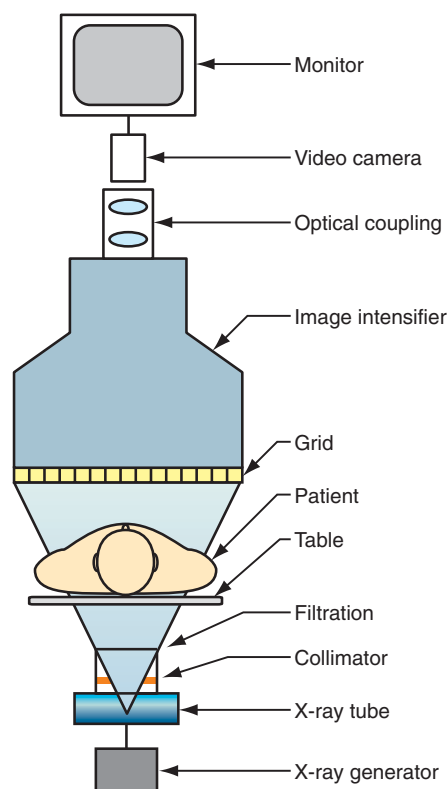


Figure 2-1 Schematic diagram of fluoroscopic imaging system.

BOX 2-1 MAIN USES OF FLUOROSCOPY

- Gastrointestinal imaging
- Genitourinary imaging
- Angiography
- Other:
 - Intraoperative
 - Foreign-body removal
 - Musculoskeletal

BOX 2-2 SINGLE-CONTRAST VERSUS DOUBLE-CONTRAST STUDIES

SINGLE-CONTRAST STUDIES

- Precise control of barium column
- Easier identification of filling defects
- In suspected perforation, single contrast with water-soluble medium preferred
- Can be used to evaluate mechanical problems (e.g., obstruction, fistula)
- Optimal for patients unable to swallow gas-forming tablets

DOUBLE-CONTRAST STUDIES

- Thick barium coats lumen, and effervescent tablets ingested to distend lumen with air
- Produced see-through effect with better assessment of mucosal details
- Better distention and separation of the bowel loops
- Better detection of small mucosal lesions, polyps, ulcers

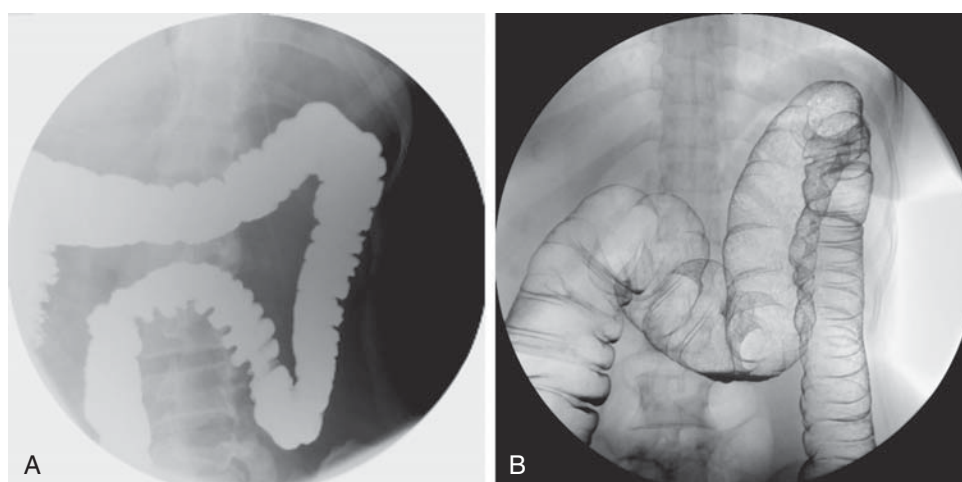


Figure 2-2 Spot radiograph of the mid-transverse colon obtained during single-contrast (A) and double-contrast (B) barium enema. The mucosal details are well seen on the double-contrast study.

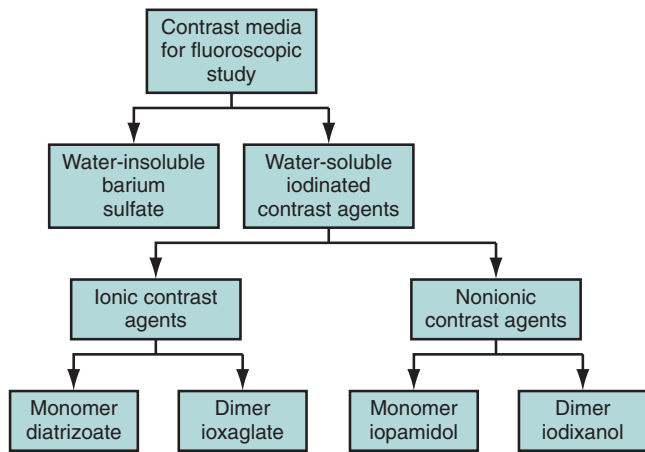


Figure 2-3 Contrast media used in fluoroscopy.

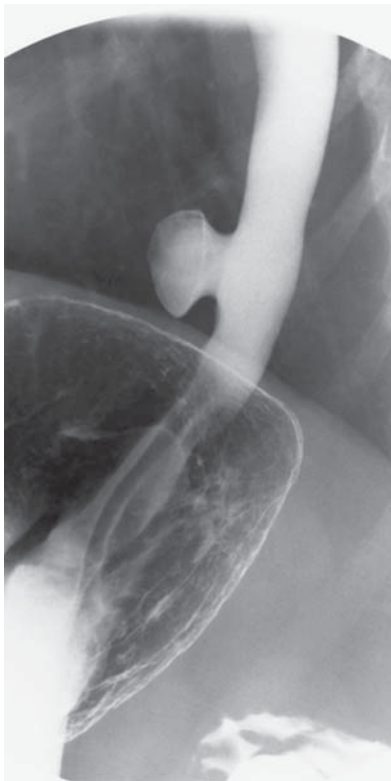


Figure 2-4 Spot film single-contrast barium sulfate study of esophagus shows a pulsion diverticulum from the lower esophagus.

penetration into the finest folds and the more differentiated are the structures that become visible. Different barium preparations available for use are shown in [Figure 2-7](#). Various barium suspensions used for the evaluation of different parts of gastrointestinal tract are depicted in [Table 2-1](#).

Properties desirable for the conventional upper gastrointestinal and per-oral small bowel examinations include suspension stability, good coating ability for double-contrast views, and resistance to flocculation in the small intestine.^{3,4} For dense, uniform coating in the esophagus, stomach, duodenum, and colon, it is also desirable that the barium suspension have the

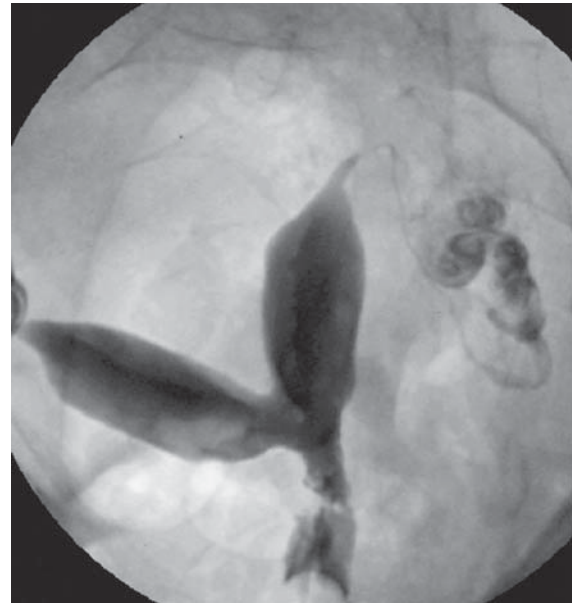


Figure 2-5 Spot film from hysterosalpingography using iodinated contrast media shows a bicornuate uterus with free spill.

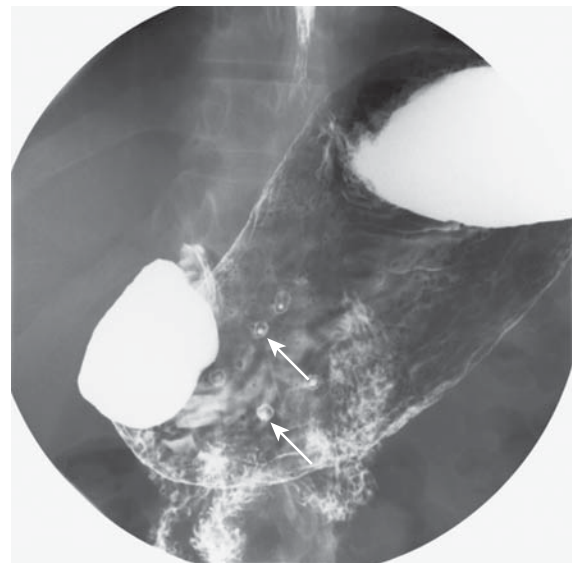


Figure 2-6 Spot film of double-contrast barium study of stomach showing multiple aphthoid ulcers (arrows).

ability to delineate fine mucosal surface details with reasonable flow rate and resistance to flocculation.^{3,4,8}

WATER-SOLUBLE CONTRAST AGENTS

Water-soluble contrast agents can be divided into ionic or non-ionic agents or, depending on the osmolarity, as high- and low-osmolar agents (see [Figures 2-3](#) and [2-8](#)). Ionic contrast media have higher osmolarity and more side effects. Nonionic contrast media have lower osmolarity and tend to have fewer side effects.^{10,11} Water-soluble organic iodine compounds are used in certain circumstances in which barium is contraindicated—for instance, in suspected perforation of gut into the free peritoneal

Figure 2-7 Different barium sulfate preparations for gastrointestinal study.

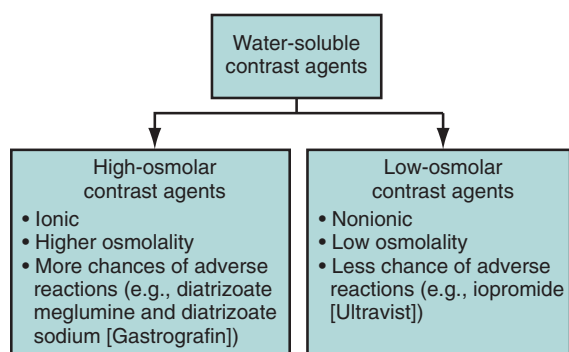
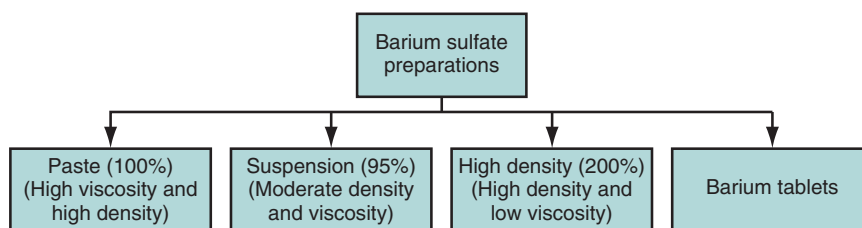


Figure 2-8 Water-soluble contrast agents.

TABLE 2-1 Barium Formulations for Gastrointestinal Tract Radiography

Gastrointestinal Tract Study	Barium Formulations (%)
Barium swallow	Single contrast: 50-100 w/v Double contrast: 250 w/v
Upper gastrointestinal tract (stomach and duodenum)	Single contrast: 35-80 w/v Double contrast: 250 w/v
Small bowel follow-through	40-60 w/v
Enteroclysis	50-95 w/v
Retrograde ileography	20-25 w/v
Barium enema	Single contrast: 12-25 w/v Double contrast: 60-120 w/v (80 commonly used)

w/v, Weight/volume.

cavity, in postoperative cases to look for a leak, or when the risk for aspiration into the lung is high. Barium leakage into the peritoneal cavity can lead to formation of granuloma, and aspiration into the lung can lead to pneumonitis or pulmonary edema.^{5,6}

In general, to achieve good radiographic opacification of the gastrointestinal tract it is recommended that 60% or higher solutions of ionic contrast agents be used. Although ionic contrast agents stimulate intestinal peristalsis and result in more rapid visualization of distal small bowel loops as compared with barium preparations, this effect is quickly nullified by the dilution effect in the bowel secondary to hyperosmolarity of these agents.¹⁰⁻¹² Ideally, one of the nonionic contrast agents should be used when indicated for evaluation of gastrointestinal tract. Iodinated contrast agents such as diatrizoate meglumine preparations (Gastrografin and Hypaque) are commercially available for oral use (Figure 2-9). For genitourinary fluoroscopic procedures, ionic contrast agents such as Renografin and Cystografin

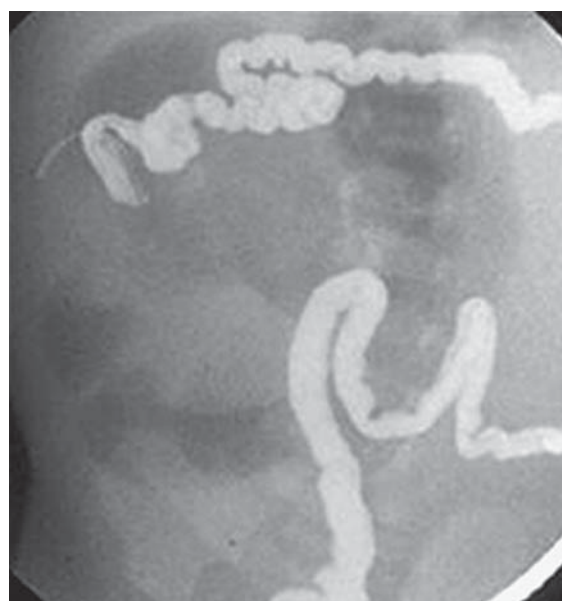

Figure 2-9 Gastrografin enema performed in a neonate with intestinal obstruction shows microcolon.

are preferred over nonionic contrast agents in most institutions owing to the lower cost.

GASTROGRAFIN

Gastrografin (diatrizoate meglumine and diatrizoate sodium) is a commercially available oral contrast medium for opacification of gastrointestinal tract. This preparation is particularly indicated when use of a more viscous agent such as barium sulfate, which is not water soluble, is not feasible, or is potentially dangerous.

Oral Administration

Adult oral dosage usually ranges from 30 to 90 mL (11 to 33 g iodine), depending on the type of the examination and the size of the patient. For infants and children younger than 5 years of age, 30 mL (11 g iodine) is usually adequate; for children 5 to 10 years of age, the suggested dose is 60 mL (22 g iodine). These pediatric doses may be diluted 1:1, if desired, with water, carbonated beverage, milk, or mineral oil. For very young (<10 kg) and debilitated children, the dose should be diluted as 1 part Gastrografin in 3 parts water.

Enemas or Enterostomy Instillations

Gastrografin should be diluted when it is used for enemas and enterostomy instillations. When used as an enema, the suggested dilution for adults is 240 mL (88 g iodine) in 1000 mL

of tap water. For children younger than 5 years of age, a 1:5 dilution in tap water is suggested; for children older than 5 years of age, 90 mL (33 g iodine) in 500 mL of tap water is a suitable dilution.

Oral Gastrografin Indications

Indications for oral use of Gastrografin include the following:

- Cystic fibrosis and subacute intestinal obstruction, because risk for obstruction in the small bowel is greater with barium
- Intestinal perforation
- Suspected tracheoesophageal fistula and pyloric stenosis, to avoid barium aspiration
- Recent rectal biopsy, recent surgery, to visualize postoperative leak, or to visualize ileostomy or colostomy loops
- Infants and neonates with suspected intestinal obstruction, necrotizing enterocolitis, unexplained pneumoperitoneum, gasless abdomen, other bowel perforation, esophageal perforation, or postoperative anastomosis

For genitourinary evaluation, the ionic contrast agents are preferred over the nonionic agents owing to the cost factor. However, in patients with a previous history of allergic reactions, nonionic agents are preferred. The dose and dilution depend on the investigation and body part examined.

EQUIPMENT FACTORS

Equipment factors include the following:

- Source-to-image distance
- Fluoroscopic kilovoltage peak
- Fluoroscopic milliamperere
- Focal spot
- Field of view
- Grid use
- Fluoroscopic acquisition mode
- Dose rate selection
- Video frame rate

PATIENT FACTORS

Patient factors are listed in [Box 2-3](#).

SIDE EFFECTS

Barium

The side effects of barium include the following:

- Bloating
- Constipation (severe or continuing)

SUGGESTED READINGS

Gelfand DW, Ott DJ, Chen YM: Optimizing single- and double-contrast colon examinations. *Crit Rev Diagn Imaging* 27:167–201, 1987.

Maglinte DD, Romano S, Lappas JC: Air (CO₂) double-contrast barium enteroclysis. *Radiology* 252:633–641, 2009.

Nolan DJ: Barium examination of the small intestine. *Br J Hosp Med* 6:136–141, 1994.

Op den Orth JO: Use of barium in evaluation of disorders of upper gastrointestinal tract: current status. *Radiology* 173:601–608, 1989.

Rubesin SE, Maglinte DD: Double-contrast barium enema technique. *Radiol Clin North Am* 41:365–376, 2003.

Schueler BA: The AAPM/RSNA physics tutorial for residents: general overview of fluoroscopic imaging. *Radiographics* 20:1115–1126, 2000.

BOX 2-3 PATIENT FACTORS IN GASTROINTESTINAL FLUOROSCOPY

ABILITY TO INGEST CONTRAST

- To get high-quality images, a relatively large volume of contrast agent needs to be ingested fairly quickly.

MOBILITY

- Multiple positions required for gastrointestinal examinations, particularly double-contrast examinations
- Limited mobility results in fewer diagnostic images.
- Weight
- Tables have weight limits.
- Maximal radiographic technique is required, and exposure is often suboptimal.

- Cramping (severe)
- Nausea or vomiting
- Stomach or lower abdominal pain
- Tightness in chest or troubled breathing
- Wheezing

Some people have reported sensitivity to the flavoring substance and exposure to latex (in gloves and tubes) used in barium contrast studies. Allergic reactions to barium sulfate suspensions are estimated to occur at a rate of less than 2 per million.

Iodinated Oral Contrast Media

The side effects of iodinated oral contrast media may vary from mild reactions such as itching or a rash to rare life-threatening reactions such as shock. These media should be used with caution in patients with known hypersensitivity to iodine, bronchial asthma, eczema, and thyroid disorders such as thyrotoxicosis. Also, patients with inflammatory bowel disease and those with conditions in which there is absorption of contrast media from a mucosal surface may have increased chances of a reaction.¹³ With oral administration patients may experience nausea, vomiting, diarrhea, and stomach cramps.

Pros and Cons

Fluoroscopic examinations may be affordable, but results depend on various factors, including the skill of the radiologist, quality of fluoroscopic equipment, and the patient's weight and compatibility. However, as compared with advanced modalities such as CT or MRI, fluoroscopy has limitations in cross-sectional imaging and radiologic tissue diagnosis.

REFERENCES

1. Cowen AR, Davies AG, Sivananthan MU: The design and imaging characteristics of dynamic, solid-state, flat-panel x-ray image detectors for digital fluoroscopy and fluorography. *Clin Radiol* 63:1073–1085, 2008.
2. Schueler BA: The AAPM/RSNA physics tutorial for residents: general overview of fluoroscopic imaging. *Radiographics* 20:1115–1126, 2000.
3. Op den Orth JO: Use of barium in evaluation of disorders of upper gastrointestinal tract: current status. *Radiology* 173:601–608, 1989.
4. Nolan DJ: Barium examination of the small intestine. *Br J Hosp Med* 6:136–141, 1994.
5. Tanomkiat W, Galassi W: Barium sulfate as contrast medium for evaluation of postoperative anastomotic leaks. *Acta Radiol* 41:482–485, 2000.
6. Gottesman L, Zevon SJ, Brabbee GW, et al: The use of water soluble contrast enemas in the diagnosis of acute lower left quadrant peritonitis. *Dis Colon Rectum* 27:84–88, 1984.
7. Stollman N, Raskin JB: Diverticular disease of the colon. *Lancet* 363:631–639, 2004.
8. Rubesin SE, Maglinte DD: Double-contrast barium enema technique. *Radiol Clin North Am* 41:365–376, 2003.
9. Gelfand DW, Ott DJ, Chen YM: Optimizing single- and double- contrast colon examinations. *Crit Rev Diagn Imaging* 27:167–201, 1987.
10. Jobling JC: Air versus carbon dioxide insufflation in double contrast barium enemas: the role of active gaseous drainage. *Br J Radiol* 69:89–90, 1996.
11. Ott DJ, Gelfand DW: Gastrointestinal contrast agents: indications, uses, and risks. *JAMA* 249:2380–2384, 1983.
12. Rubin JD, Cohan RH: Iodinated radiographic contrast media: comparison of low-osmolar with conventional ionic agents [corrected]. *Curr Opin Radiol* 3:637–645, 1991.
13. Kory LA, Epstein BS: The oral use of iodinated water-soluble contrast agents for visualizing the proximal colon when barium enema examination reveals complete obstruction. *Am J Roentgenol Radium Ther Nucl Med* 115:355–359, 1972.

3

Abdominal Ultrasound Imaging: Anatomy, Physics, Instrumentation, and Technique

LUZENG CHEN

Ultrasonography is low in cost, noninvasive, and highly portable, and it allows real-time imaging in multiple operator-controlled planes. As a result, it is the most widely used cross-sectional imaging modality worldwide. The principal challenge with ultrasonography is greater user-dependence than computed tomography (CT) or magnetic resonance imaging (MRI).

Basic Physics

DEFINITION

Humans can hear sound that vibrates from 20 Hertz (Hz) to 20,000 Hz. *Ultrasound* is the term given to describe sound at frequencies above 20,000 Hz, beyond the range of human hearing. Frequencies of 3 to 7 megahertz (MHz) are commonly used for abdominal ultrasound.

PROPERTIES OF ULTRASOUND

Ultrasound waves propagate as longitudinal waves in soft tissues. Acoustic impedance is an intrinsic physical property of a medium defined as the density of the medium multiplied by the velocity of ultrasound wave propagation in the medium. Acoustic interfaces exist between materials that have different acoustic impedances. Reflection, refraction, and scatter occur when ultrasound waves meet an acoustic interface. The greater the acoustic impedance difference between two sides of the interface, the greater is the ultrasound energy that will be reflected.

The relationship among frequency (f), velocity (c), and wavelength (λ) is $\lambda = c/f$. The higher the frequency, the shorter is the wavelength. In theory, the distance that can be measured by ultrasound is $\frac{1}{2}\lambda$. The shorter the wavelength, the better the resolution will be. With the wavelength shortened, the attenuation will be greater. So a low-frequency probe should generally be selected to examine the deep organs of the abdomen (e.g., liver, kidney, pancreas), and high-frequency probes should be selected to examine superficial tissues (e.g., abdominal wall, appendix) (Figures 3-1 and 3-2).

The velocity of ultrasound is affected by the density and elasticity of the material it traverses; as a result, ultrasound travels at varying velocities through different tissues. Current commercially available ultrasound machines cannot determine which tissues underlie the transducer and instead assume an average tissue velocity of 1540 m/s in their image reconstruction algorithms. The value is obtained from averaging the velocity in normal soft tissue (Figure 3-3).¹

SAFETY

The American Institute of Ultrasound in Medicine has addressed ultrasound safety and bioeffects, as follows: “No independently confirmed adverse effects caused by exposure from present diagnostic ultrasound instruments have been reported in human patients in the absence of contrast agents.” Biological effects (such as localized pulmonary bleeding) have been reported in mammalian systems at diagnostically relevant exposures, but the clinical significance of such effects is not known. Ultrasound should be used by qualified health professionals to provide medical benefit to the patient. Ultrasound exposures during examinations should be as low as reasonably achievable.²

INSTRUMENTATION

A diagnostic ultrasound machine is commonly composed of a transducer (probe) and main body. An electronic transducer is composed of a large number of piezoelectric materials. Ultrasound is produced from piezoelectric material that vibrates in response to the application of electrical energy. Piezoelectric material can be arranged on a plane (linear transducer) or a curved surface (curved transducer). Linear high-frequency transducers are typically used for superficial tissue imaging—for example, appendix, abdominal wall, and scrotum. Low-frequency curved array transducers are typically used for abdominal and obstetric/gynecologic imaging, in which the curvature of the array and penetration depth facilitate large field of view imaging.

When ultrasound travels through tissues, reflection, refraction, and scatter will occur at acoustic interfaces. The reflected and/or scattered ultrasound waves are detected by the transducer and analyzed. Each echo is displayed at a point in the image that corresponds to the relative position of its origin within the body. The brightness of each point in the image is related to the strength of the echo. This form of ultrasound imaging is termed *B-mode* (brightness mode) sonography and is often colloquially termed “gray scale” sonography or “conventional” sonography.

General Abdominal Ultrasonography

Ultrasonography can be used to visualize solid structures in the abdomen, the abdominal wall, and some gastrointestinal lesions. The vasculature within these organs can be evaluated by color Doppler, power Doppler, or spectral modes. Body markers or anatomic labels are used to illustrate the position of the patients

and transducer. A basic glossary of ultrasound terms is listed in Table 3-1.

EQUIPMENT

An ultrasound machine capable of real-time imaging should be used to examine the abdominal organs. The equipment should be adjusted to obtain acceptable resolution. For adults, a curved probe with frequencies between 2 and 5 MHz is most commonly used. A linear probe with frequencies between 5 and 7 MHz is most commonly used when the abdominal wall and

appendix are examined. Image quality should be optimized while keeping total ultrasound energy exposure as low as reasonably achievable.

PREPARATION FOR EXAMINATION

The patient should not eat or drink for 8 hours before the abdominal ultrasound. If fluid is essential to prevent dehydration or take medicine, only water should be given. When the bladder needs to be examined, 400 to 600 mL water should be taken orally 2 hours before examination to ensure there is

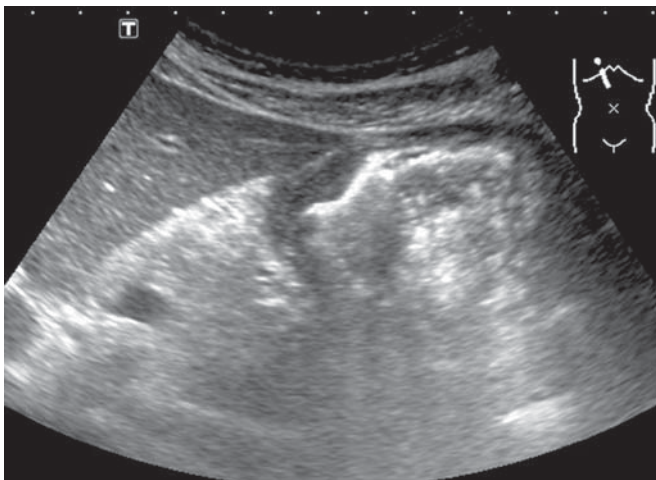


Figure 3-1 Gastric cancer. Gastric mural thickening demonstrated by 3.5-MHz curved probe.

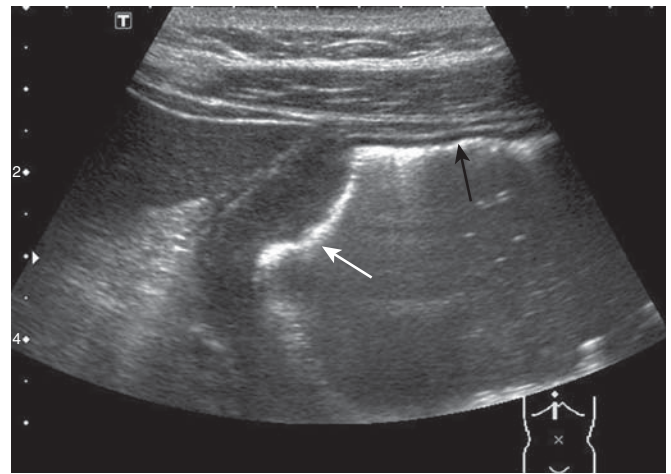


Figure 3-2 In the same patient, gastric mural thickening (*white arrow*) and normal gastric wall (*black arrow*) were demonstrated with greater spatial resolution using a 7.0-MHz linear probe.

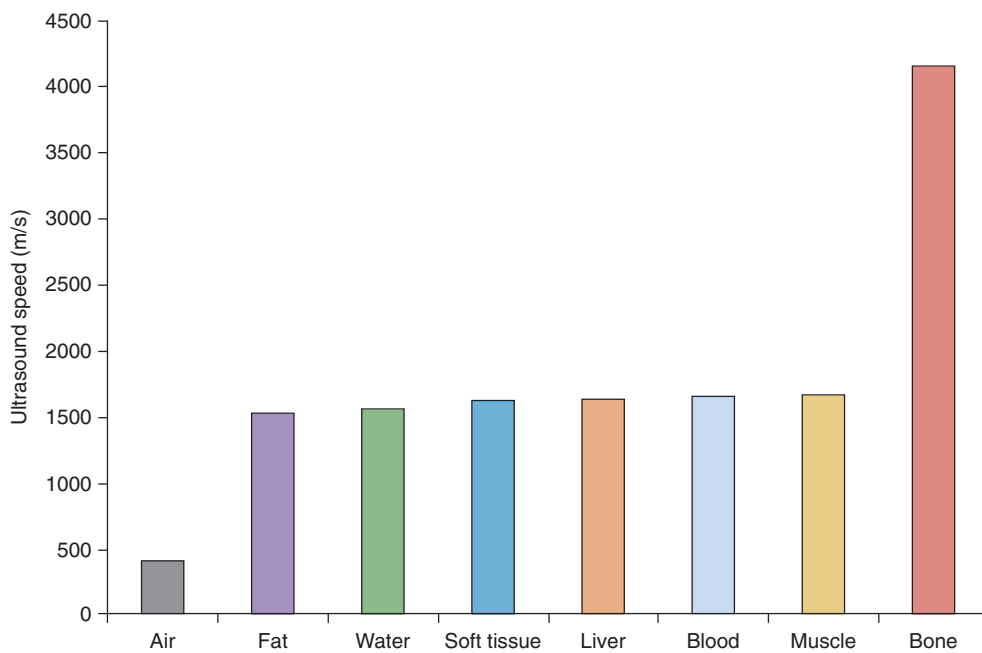


Figure 3-3 Velocity of ultrasound in different tissues.

TABLE 3-1
Basic Ultrasound Glossary

Term	Description	Example
Anechoic	Without echoes; displayed as black in the image	Normal urine and bile
Hypoechoic	Tissues that create dimmer echoes than adjacent tissues	Cortex of lymph nodes, some tumors
Hyperechoic	Tissues that create brighter echoes than adjacent tissues	Air, bone, perinephric fat
Acoustic shadow	The decreased echogenicity of tissues that lie behind a structure that causes marked attenuation or reflection of the ultrasound waves	Typically deep to solid structures (stones, bone) or air
Acoustic window	A tissue or structure that offers little obstruction to the ultrasound waves and can therefore be used as a route to obtain images of a deeper structure	Bladder full of urine, gallbladder full of bile
Cystic	A fluid-filled structure (mass) with thin or thick walls, with or without strong back wall reflections and enhancement of the echoes behind the cyst	Liver, renal cysts common
Solid	Tissue that does not include fluid spaces; will be multiple internal echoes and moderate attenuation of the ultrasound	Solid tumor, liver, muscle

enough urine in the bladder. Emergency ultrasonography can be performed at any time, but the image quality may be affected by air in stomach and bowel.

Normal Ultrasound Image

LIVER

The normal liver parenchyma appears homogeneous, interrupted by the portal vein, hepatic vein, and their branches. The echogenicity of the liver should be compared with that of the right kidney. The liver can be similar or more echogenic than normal kidney. The hepatic veins, the main portal vein, and the right and left branches of the portal vein should be seen clearly (Figure 3-4).

GALLBLADDER AND BILE DUCT

On the longitudinal scan, the gallbladder will appear as an anechoic, pear-shaped structure. It is variable in position, size, and shape, but the normal gallbladder is seldom more than 40 mm wide. The thickness of normal gallbladder wall is no more than 3 mm (Figure 3-5). The intrahepatic bile ducts usually are located above the corresponding portal branches. The common bile duct (CBD) is located anterior the portal vein. The normal diameter of the CBD is less than 6 mm. Ultrasonography has limited capacity to detect small lesions within the distal CBD. Sometimes, tiny stones in the CBD can be detected (Figure 3-6).

PANCREAS

The pancreas has approximately the same echogenicity as the adjacent liver and should appear homogeneous. However, pancreatic echogenicity increases with age. The contour of the normal pancreas is smooth. The shape and the size of the pancreas are variable. The diameter of the pancreatic duct should not exceed 2 mm. The tail of pancreas is often difficult to demonstrate, because of gas in the stomach and bowel. If there is no clinical contraindication, it may be helpful to give the patient 300 to 500 mL water to drink when scanning the pancreas (Figure 3-7). The pancreatic tail also occasionally can be demonstrated through the spleen (Figure 3-8).

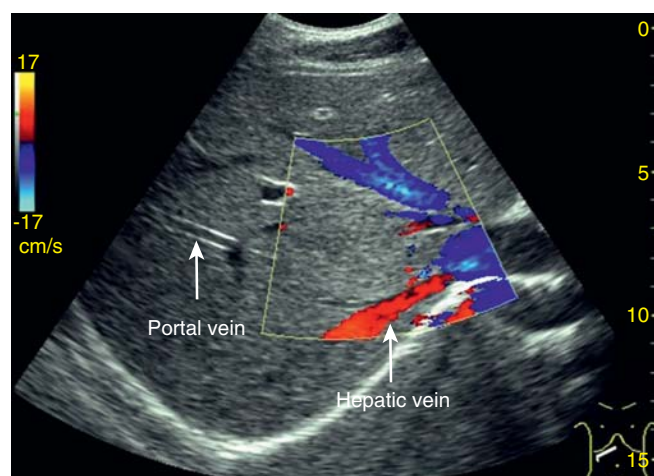


Figure 3-4 Normal liver parenchyma, portal vein, and hepatic vein.

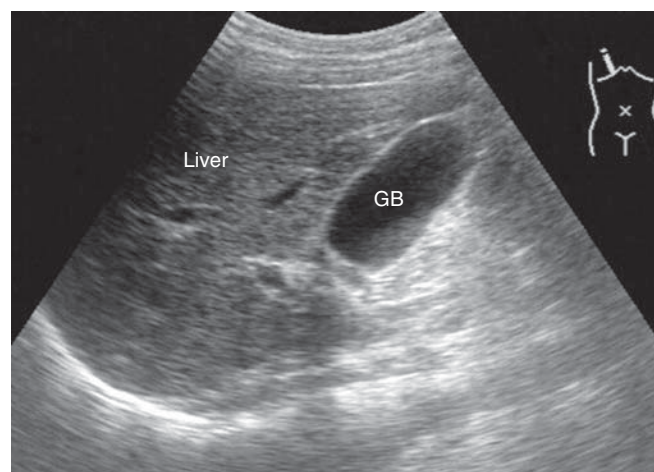


Figure 3-5 Normal gallbladder (GB).

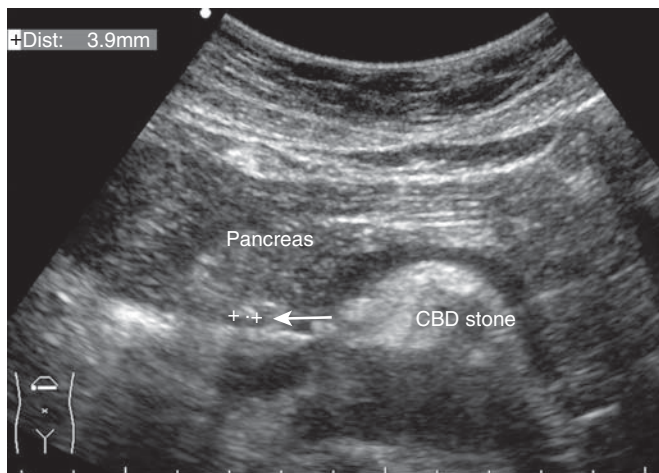


Figure 3-6 Tiny stone with acoustic shadowing within the intrapancreatic common bile duct (CBD).

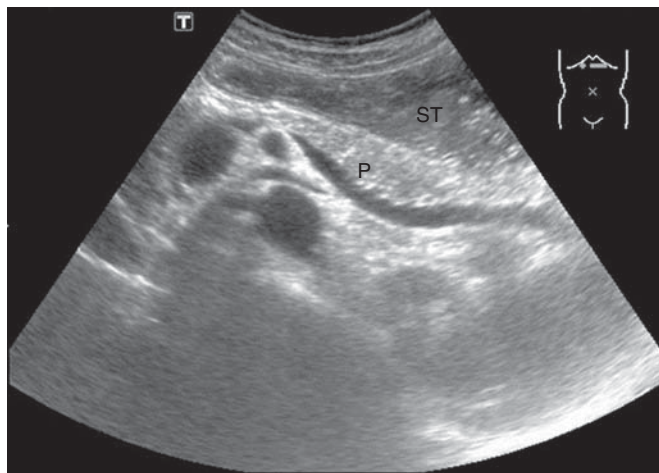


Figure 3-7 Normal body and tail of pancreas were demonstrated after drinking 300 mL water. P, Pancreas; ST, stomach.

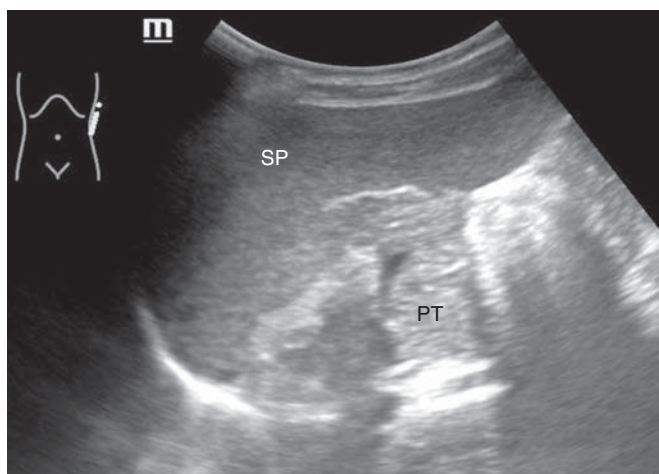


Figure 3-8 The spleen was used as an acoustic window, and the pancreatic tail can be demonstrated clearly. PT, pancreatic tail; SP, spleen.

SPLEEN

The spleen should show a uniform homogeneous echo pattern. It is slightly less echogenic than the liver. The length of the normal spleen is no more than 12 cm, and the thickness is no more than 4 cm (Figure 3-9).

KIDNEY AND ADRENAL GLAND

The renal capsule appears as a bright, smooth, echogenic line around the kidney. The cortex is less echogenic than the liver but more echogenic than the adjacent renal pyramids. The renal pyramids are poorly defined hypoechoic areas in the medulla of the kidney. The central echo complex (the renal sinus) is hyperechoic relative to renal parenchyma. The renal arteries and veins are readily seen at the renal hilus and around the aorta. Like other visceral arteries, the renal artery has high diastolic blood flow (Figures 3-10 and 3-11).

The adrenals are located above and medial to the kidneys. Except in infants, the adrenal glands are not easily visible with ultrasound (Figure 3-12).

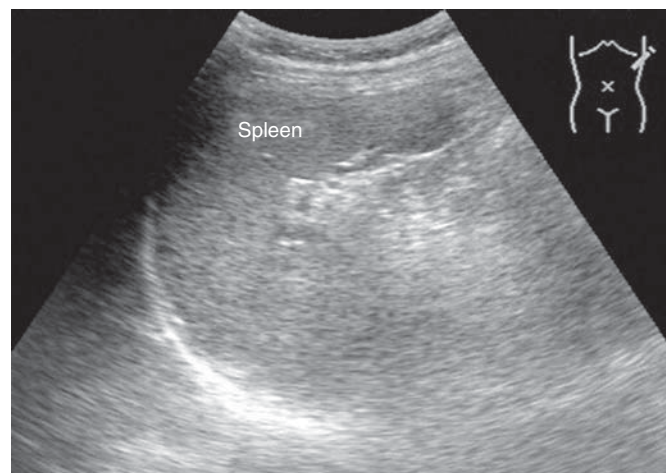


Figure 3-9 Normal spleen.

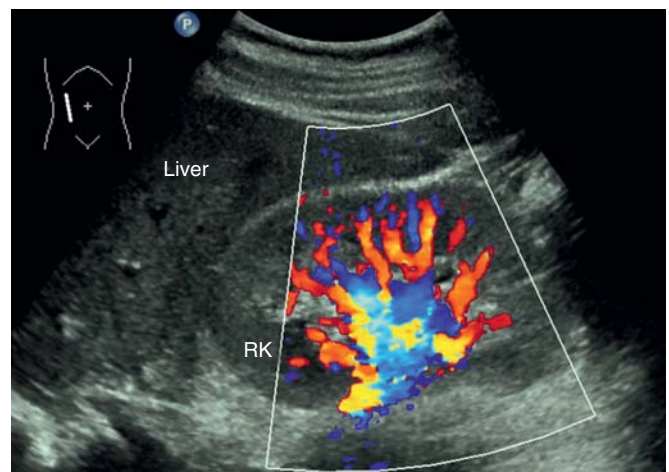


Figure 3-10 Normal right kidney (RK).

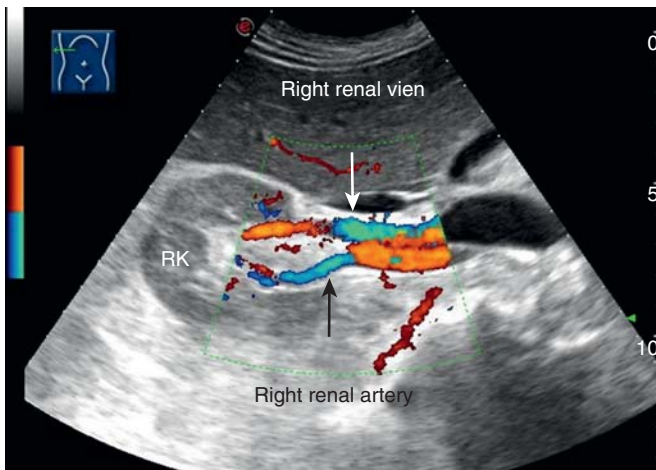


Figure 3-11 Normal right kidney (RK), right renal artery and vein.

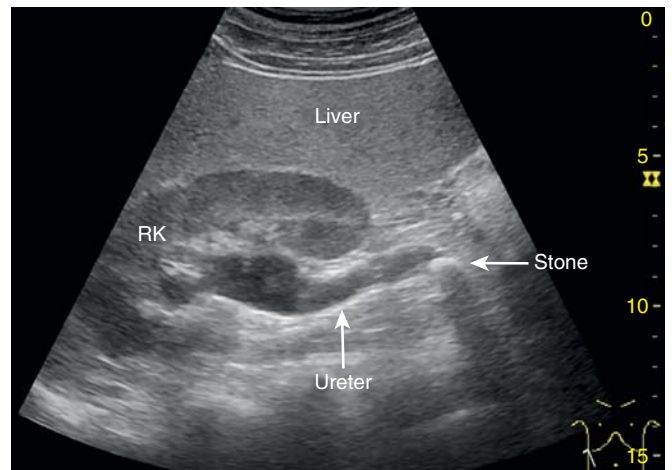


Figure 3-13 Right renal pelvis and upper right ureter were distended, a stone with acoustic shadow was demonstrated in the lumen of the right ureter. RK, Right kidney.

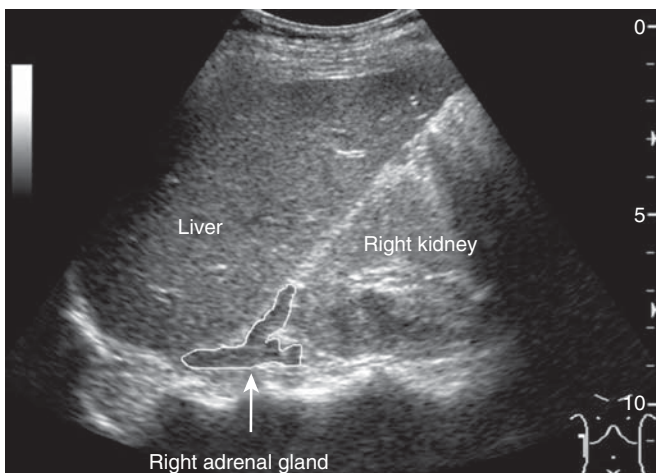


Figure 3-12 Enlarged right adrenal gland in a patient with Cushing's syndrome.

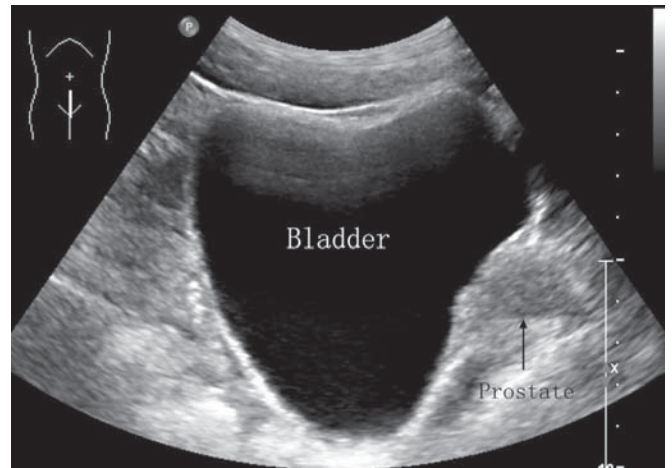


Figure 3-14 Normal full urinary bladder. SAG, Sagittal plane.

URETERS, BLADDER AND PROSTATE

The normal ureters are usually not readily visible, but can be demonstrated when distended (Figure 3-13). The bladder should be evaluated while distended with urine, because bladder tumors may not be detected in an empty bladder. The full urinary bladder appears as a large, rounded, anechoic area arising from the pelvis. The thickness of the bladder wall will vary with the degree of distention. When distended, the normal bladder wall is less than 4 mm thick (Figure 3-14).

The prostate can be divided into four glandular zones: the peripheral zone, transitional zone, central zone, and periurethral glandular area. It is difficult to identify these zones with transabdominal sonography. Transrectal ultrasound can delineate the prostate zonal anatomy and is useful for guiding prostate biopsy (Figure 3-15).

SCROTUM

The normal testes are oval, homogeneous, and hyperechoic. Often a small amount of physiologic fluid is present within the scrotum around the testes. The epididymis lies on the inferior

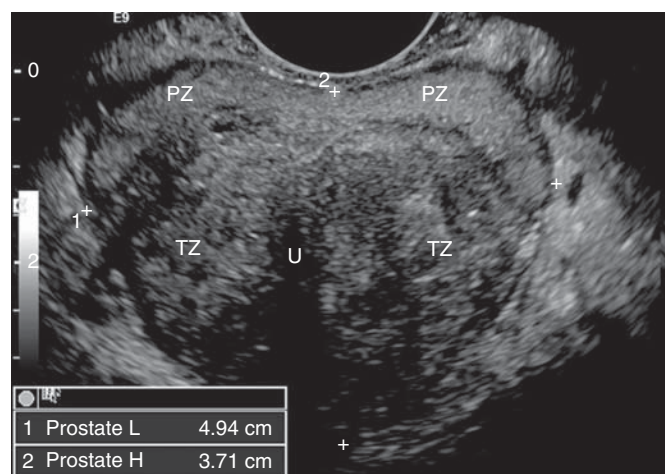


Figure 3-15 Transrectal axial view of benign prostatic hyperplasia. PZ, Peripheral zone; TZ, transitional zone; U, urethra.