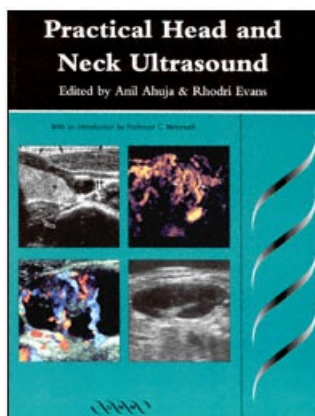

title: Practical Head and Neck Ultrasound
author: Ahuja, Anil.; Evans, Rhodri.
publisher: Greenwich Medical Media Limited
isbn10 | asin: 1900151995
print isbn13: 9781900151993
ebook isbn13: 9780511043505
language: English
subject Head--Ultrasonic imaging, Neck--Ultrasonic imaging.
publication date: 2000
lcc: RV291P73 2000eb
ddc:
subject: Head--Ultrasonic imaging, Neck--Ultrasonic imaging.

Practical Head & Neck Ultrasound

Edited by
Anil T Ahuja

MBBS (Bombay) MD (Bombay) FRCR
FHKCR FHKAM

Associate Professor
Department of Diagnostic
Radiology and Organ Imaging
Chinese University of Hong Kong
Prince of Wales Hospital
Shatin
Hong Kong
China

Rhodri M Evans

MB BCh FRCR
Consultant Radiologist
Radiology Department
Morrison Hospital
Morrison
Swansea
Wales
UK



© 2000

Greenwich Medical Media Limited
137 Euston Road
London
NW1 2AA

ISBN 1 900 151 995

First published 2000

Apart from any fair dealing for the purposes of research or private study, or criticism or review, as permitted under the UK Copyright Designs and Patents Act 1988, this publication may not be reproduced, stored, or transmitted, in any form or by any means, without the prior permission in writing of the publishers, or in the case of reprographic reproduction only in accordance with the terms of the licences issued by the appropriate Reproduction Rights Organisations outside the UK. Enquiries concerning reproduction outside the terms stated here should be sent to the publishers at the London address printed above.

The publisher makes no representation, express or implied, with regard to the accuracy of the information contained in this book and cannot accept any legal responsibility or liability for any errors or omissions that may be made.

The right of Anil Ahuja and Rhodri Evans to be identified as editors of this work has been asserted by them in accordance with the Copyright Designs and Patents Act 1988.

A catalogue record for this book is available from the British Library.

Typeset by Phoenix Photosetting, Chatham, Kent

Colour separation by Tenon & Polert Colour Scanning Ltd

Printed in China

Contents

Contributors	ix
Introduction	xi
Acknowledgement	xiii
Chapter 1	
Anatomy and Technique	
<i>R M Evans</i>	
Equipment and Technique	3
Anatomy: Introduction	4
Ultrasound Anatomy	6
Chapter 2	
Salivary Glands	
<i>M J Bradley</i>	
Normal Anatomy	19
Salivary Gland Technique	21
Calculi and Acute Inflammatory Disease	22
Chronic Inflammatory Conditions	25
Trauma	26
Salivary Gland Tumours	26
Miscellaneous 'Parotid' Lesions	31
Chapter 3	
The Thyroid and Parathyroids	
<i>A T Ahuja</i>	
Ultrasound of the Thyroid	37
Anatomy of the Thyroid	37
Examination	39
Papillary Carcinoma	43
Anaplastic Carcinoma	46
Medullary Carcinoma	48
Follicular Lesion	49
Lymphoma	50

Thyroid Metastases	51
Hurthle Cell Tumours	52
Multinodular Thyroid	53
Thyroid Cysts	55
Thyroiditis	55
Postoperative Hypertrophy	58
Ultrasound of the Parathyroids	59
Chapter 4	
Lymph Nodes	
<i>R M Evans</i>	
Anatomy	67
Ultrasound Anatomy	68
Classification Systems	74
Criteria of Malignancy	75
Chapter 5	
Lumps and Bumps in the Head and Neck	
<i>A T Ahuja</i>	
Masses in the Submental Region	87
Masses in the Submandibular Region	89
Masses in the Parotid Region	94
Masses along the Carotid Artery and Internal Jugular Vein	97
Masses in the Posterior Triangle	100
Miscellaneous Neck Masses	101
Chapter 6	
The Larynx	
<i>E Loveday</i>	
Anatomy and Sonographic Anatomy	107
Examination Technique	108
Vocal Folds	109
Clinical Applications	110
Chapter 7	
What the Surgeon Needs to Know, and Why	
<i>D W Patton, K C Silvester</i>	
The Clinical Characteristics of a Lump	121
Establishing a Tissue Diagnosis	122
Malignant Lumps in the Neck	122
Does Improved Imaging Result in a Better Outcome for the Patient?	127

Chapter 8	
Fine-Needle Aspiration or Core Biopsy?	
<i>N J A Cozens, L Berman</i>	
Fine-needle Aspiration	131
Core Biopsy	138
Chapter 9	
Carotid and Vertebral Ultrasonography	
<i>S Ho, C Metreweli</i>	
Anatomy	147
Examination	148
Normal Ultrasound Appearances	153
Ultrasound Appearances of Carotid and Vertebral Artery Pathology	153
Index	167

Contributors

Anil T Ahuja MBBS (Born) MD (Bom)
FRCR FHKCR FHKAM
Associate Professor
Department of Diagnostic Radiology and
Organ Imaging
Chinese University of Hong Kong
Prince of Wales Hospital
Shatin, Hong Kong
China

Laurence Berman FRCP FRCR
Consultant Radiologist Lecturer/Honorary Consultant
University Department of Radiology
Addenbrooke's Hospital NHS Trust
Hills Road
Cambridge

Michael Jameson Bradley MB BCH FRCR
Consultant Radiologist and Honorary Senior
Clinical Lecturer
X Ray Department
North Bristol Trust
Southmead Hospital
Westbury-on-Trym
Bristol, UK

Neil Cozens DMRD FRCR
Consultant Radiologist
Derbyshire Royal Infirmary NHS Trust
Derby, UK

Rhodri M Evans MB BCh FRCR
Consultant Radiologist
Radiology Department
Morrison Hospital
Morrison, Swansea
Wales, UK

Stella S Y Ho MPhil RDMS RVT
Senior Radiographer
Department of Diagnostic Radiology and Organ Imaging
Chinese University of Hong Kong
Prince of Wales Hospital
Shatin, Hong Kong
China

Eric Loveday
Consultant Radiologist
X Ray Department
Southmead Hospital
Westbury-on-Trym
Bristol, UK

C Metreweli FRCR FRCP
Professor and Chairman
Department of Diagnostic Radiology and Organ Imaging
Chinese University of Hong Kong
Prince of Wales Hospital
Shatin, Hong Kong
China

David William Patton TD FDS FRCS
Consultant Oral and Maxillofacial Surgeon
Department of Oral and Maxillofacial Surgery

Morrison Hospital
Morrison, Swansea
Wales, UK

Keith Charles Silvester MBBS (Lond) BDS (Lond)
FDS RCS (Eng) FRCS (Ed)
Consultant Oral and Facial Surgeon
Department of Oral and Maxillofacial Surgery
Morrison Hospital
Morrison, Swansea
Wales, UK

Introduction

We have the privilege of working and living during a time of unprecedented technological advances in diagnostic medicine. This now means that for any one diagnostic problem we have not only have one method of imaging but many methods available to us. Wise use of the various technologies dictates that the most informative, least harmful, most easily available and least expensive techniques should be employed first.

With the arrival of CT, MRI, ultrasound and nuclear medicine in medical imaging, a new era of diagnostic understanding of the head and neck has flowered.

In the soft tissues of the neck, many of the diagnostic problems that present to the clinician can be managed with maximal efficiency using ultrasound. Surprisingly, despite the pioneering of neck ultrasound by Bruneton and Solbiati, a large number of neck examinations are still being performed using nuclear medicine, CT and MRI. One might have thought that neck ultrasound would thrive in hospitals in which CT and, particularly, MRI are not readily available. Alas, it seems that most clinicians would prefer to let their patients wait several weeks for MRI and then not get a satisfactory answer, rather than obtain an ultrasound scan quickly from a knowledgeable professional and have an accurate answer sooner.

There are several texts on imaging of the head and neck^{1,2} but these are predominantly CT and MRI orientated. Apart from chapters in Solbiati and Rizzato's book,³ there is very little helpful information to enable the radiologist in a busy general hospital to come to grips with ultrasound of the head and neck. This is unfortunate quite apart from the usual well-known advantages of ultrasound in the head and neck, it is remarkably accurate and easier to apply than CT and MRI.

This book therefore aims to fill that gap. The text is intended as a practical guide and bench book. It is to be hoped that it will encourage anyone with a reasonable knowledge of ultrasound to pick up the (appropriate!) transducer and start scanning the neck effectively rather than simply 'gel spreading'. It is intended to help the reader to be able to reach a useful opinion in 90% of the problems that arise in daily practice. The remaining 10% will have to be learnt from personal experience and greater in-depth reading. By the Pareto principle, trying to cover that 10% would probably quadruple the size of this book, so do not expect this book to have the answer to everything.

Besides omitting rarities we have also avoided myths those anecdotal 'facts' that keep reappearing in textbooks and examinations but which one never sees in daily practice.

The book contains the sort of information that we wish we could have had when we started neck scanning ten years ago. Much of the information is available in the literature but is scattered. Here the most useful information is gathered together by people who actually scan; the 'litter-ature' has therefore been weeded out.

Please note that this book is intended for those who will actually scan. It depends on an interactive approach. It is not meant for the CPR (couch potato radiologist) who sits back and lets others perform the scan and then 'reports the films!'. We strongly believe that this is not the way to practice ultrasound. We are also strong believers in the opinion that (good) ultrasound is not 'operator dependent', at least no more so than MRI, CT or, for that matter, surgery or pathology. The claim that ultrasound is operator dependent is merely a feeble line of defence for CPRs who are unwilling to roll up their sleeves and learn how to do the job properly!

For thyroid nodules, we can now make a diagnosis with ultrasound that can be more reliable than fine-needle aspiration cytology (FNAC) and far more useful than scintigraphy, which surprisingly is still mentioned in the texts as

being a method of choice. It is high time that thyroid scintigraphy took its proper place in the history books, alongside air encephalography.

With neck lymph nodes we can now examine their vascularity, not only with colour flow and power Doppler but also with 3D volumetric analysis. The detail that can be seen in lymph nodes is superior to and more clinically useful than that obtained by either CT or MRI.

The characterisation and localisation of salivary gland tumours is simple and easy without the need to inject contrast or cannulate the ducts. Even those mysterious lumps and bumps that do not seem to belong to the expected organs reveal their secrets to ultrasound.

In many cases one is able to make a confident diagnosis before FNAC or histology, but in those cases where this is still indicated ultrasound is the imaging technique of choice in guiding the needle to its best target. Palpationguided FNA is not only barbaric but inaccurate. Those who know how difficult it is to guide a needle into a target under direct visual control will know why the blind approach is inaccurate. In these days 'blind' biopsy 'technique' must surely mean 'blind to the benefits of guided biopsy'.

Lest the reader consider this book too dogmatic, we appreciate that there are still major controversies to sort out, and different centres have varying strengths and therefore different approaches to diagnostic management. This is best exemplified by the chapter dealing with biopsy techniques which voices the different approaches that can be used in the head and neck.

Despite its multiple authorship this book has a feeling of common purpose and I would like to think, with considerable pride, that this is the result of a common origin for several of the authors. Rhodri Evans, Mike Bradley and Eric Loveday have all passed through my department in the Chinese University of Hong Kong at the Prince of Wales Hospital. It was here that they learnt the initial skills and have been able to take these back to Europe (I believe that Britain is considered, by some, to be part of Europe in a peripheral sort of way!) and to develop them further.

Most of the authors have taught at the Morriston Head and Neck Ultrasound Workshops. As the Morriston course evolved, it became clear that there is a real need for a co-ordinated approach to the head and neck. This text should fill that need. The spectrum of topics discussed should provide the necessary background for anyone starting out in head and neck ultrasound.

The Morriston course has not so far not included a section on carotid and vertebral ultrasound/Doppler; however, it was felt that this is an essential component of neck ultrasound and has therefore been added. The sonologist or sonographer who deals with the head and neck must be competent not only in grey-scale ultrasound but colour flow and pulsed Doppler as well. In the neck we have the opportunity of using every new technique that the ultrasound designers can give us!

It is gratifying to learn that the European Association of Radiology has now recognised head and neck imaging as a subspecialty in its own right, alongside such older worthies as neuroradiology and paediatric radiology.

This handbook is therefore timely and we hope that it will add a small, but useful, gust to the necessary winds of change.

CON METREWELI

References

1. Som PM, Curtin HD. *Head and Neck Imaging*, 3rd edn. St Louis: MosbyYear Book, 1996.
2. Harnsberger HR. *Handbook of Head and Neck Imaging*, 2nd edn. St Louis: MosbyYear Book, 1995.
3. Solbiati L, Rizzatto G. *Ultrasound of Superficial Structures*. Edinburgh: Churchill Livingstone, 1995.

Acknowledgement

This text is the result of a team effort. We therefore say 'thank you' to the team. We would particularly like to thank 'Prof M' for giving us both the opportunity to develop our interest in head and neck ultrasound. We also owe a large debt of gratitude to our colleagues and staff of our respective hospitals, namely: The Prince of Wales Hospital, Shatin, Hong Kong; Morrision Hospital, Swansea and Neath General Hospital for their generous support, not just in the writing and editing of this text but also in the organising and running of the Morrision Workshops.

On a more personal level we must acknowledge the close support and help provided by our families. For Anil this is, in particular, his wife Chu Wai Po, his mother and his late father. On Rhodri's part 'Diolch yn fawr i Lynne, Catrin, Bethan a Gwyn'.

ANIL AND RHODRI

1
Anatomy and Technique

RM Evans

Equipment and Technique
Anatomy: Introduction
Ultrasound Anatomy

Introduction

Over the past two decades, rapid strides in ultrasound (US) technology and in particular the development of high resolution US have led to a greater role for ultrasound in the assessment of the extracranial head and neck. The increased spatial resolution achieved by the latest generation of machines and transducers allows excellent near field resolution. When one considers that the majority of structures and associated pathology in the neck lie only between one and five centimetres below the skin surface, and given the superior resolution that high resolution US can attain, it is not surprising that US is gaining in popularity in the field of head and neck imaging. As it is relatively inexpensive (in Radiology terms) and is readily available, the use of US will continue to increase.

One criticism of US is that it is 'operator dependent'. While there can be no argument with that statement, it is not a criticism that is made of other imaging techniques, which are equally operator dependent. We accept that cytology is operator dependent, we know that surgery is operator dependent, so why is 'operator dependent' a criticism that is continually heard when US is discussed? Most medicine is operator dependent in one form or other; the myth that US is more 'operator dependent' than other techniques should be laid to rest. If one is enthusiastic and willing to learn, the learning curve in US is no steeper than that in magnetic resonance imaging (MRI), computed tomography (CT), or any other branch of radiology.

The key to an understanding of the neck, as in all other areas of radiology, is a sound knowledge of anatomy. The aim of this chapter is to provide that knowledge as a basis for understanding ultrasound of the neck.

Equipment and Technique.

A state-of-the-art high resolution US machine is desirable but not essential. A dedicated high resolution US machine is a luxury for most of those who work in busy US departments; however, most reputable multifunction machines now have sufficient high resolution hardware, software and probes to allow adequate examination of the head and neck. A linear 7.5-10 MHz probe with a relatively small 'footprint', i.e. a small contact surface area, is optimal. Higher frequency probes, i.e. 10 MHz and above, allow superior resolution for superficial structures but there is a trade-off in lack of depth penetration. Be aware that a probe of too high a frequency, i.e. 10-13 MHz, can definitely be counterproductive when learning; for the beginner, an appreciation of the overall anatomy is much more easily obtained using lower frequency probes. There is a role for 5 MHz probes in assessing deep lesions such as those in the deep lobe of the parotid. Colour flow facilities are now standard on most machines; and while preferable they are not necessarily essential. The beginner will find it easier to pick out the vascular anatomy of the neck using colour flow, but there will be less dependence once familiarity with the anatomy has been attained. Power flow applications are desirable for assessing flow patterns, for example in lymph nodes and thyroid nodules. The beginner may be deterred from carrying out a biopsy in the head and neck if colour imaging is regularly used. Many head and neck tumours and lymph nodes have spectacular colour flow features but core biopsy and fine-needle aspiration biopsy (FNAB) can still be safely carried out!

One essential piece of equipment is a high quality, adjustable and mobile table. It is important that for US and US guided procedures in the neck, the examiner is comfortable. A mobile table that can be easily positioned so that the patient's neck is level with the US monitor and within the operators scanning range is essential. Most operators find the most comfortable position to be, one in which the patient's neck is level with the examiner's thigh or knees. When carrying out biopsy techniques the operator must be positioned so that the monitor can be viewed comfortably without undue stretching or twisting. A monitor on a manoeuvrable arm is ideal. The patient's neck should be sufficiently close so that both the hand holding the probe and the hand holding the needle or biopsy gun are in a relaxed position, again without undue stretching or twisting. The probe, needle, monitor and patient should be in a tight or acute field of view for optimal positioning. Comfort of operator and patient will reduce problems when free-hand biopsies are performed under real-time US control. While this appears to be no more common sense, most of the problems encountered by the author when teaching free-hand biopsy techniques are due to poor positioning of both radiologist and patient.

The patient should be positioned with the neck extended, a pillow behind the shoulders and lower neck allowing the patient to adopt a comfortable position that can be maintained throughout the study. There may be difficulties in elderly patients with arthritic necks or respiratory problems; in these patients the table should be adjusted to 45 degrees and a pillow

placed behind the shoulders, if possible, to enable some extension of the neck. The patient may be scanned in a sitting position if necessary, although assessment of the lower neck may be compromised.

The use of a gel block is sometimes required, particularly if one is not blessed with a probe with a small footprint. Integrated stand-off blocks are not necessary. In certain 'angular' positions, such as the angle of the mandible and supraclavicular fossa in thin individuals, a better image will be obtained using a stand off block. The author finds a small (9 cm), round gel disc (Aqua flex gel pad, Parker laboratories, USA) to be the most satisfactory. It is washable and usually lasts for 46 weeks in a busy department. If one has a high frequency probe with a small footprint, the application of a good covering of gel is usually sufficient for the assessment of the most superficial structures.

EQUIPMENT AND TECHNIQUE

High frequency (7.510 MHz), small footprint probe
 Colour flow imaging
 Manoeuvrable monitor
 Mobile adjustable table
 Pillow under patient's shoulders
 Comfort is vital, for operator and patient alike

Anatomy:
 Introduction

As in any field of radiology, an understanding of the anatomy of the region is the key to the radiological approach. Unfortunately the complex anatomy of the

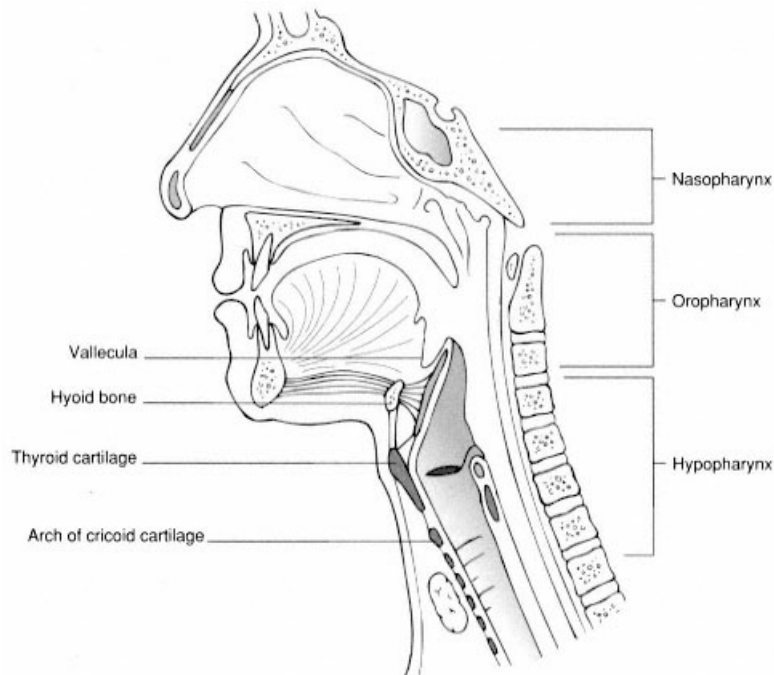


Figure 1.1
 Sagittal section showing the divisions of the upper aerodigestive tract.

head and neck can prove a daunting prospect for the radiologist who only infrequently carries out scanning in this area. The situation is not helped by the many and varied methods and concepts employed in describing the anatomy of the extracranial head and neck.

Traditionally, the upper aerodigestive tract is divided into four areas: nasopharynx, oropharynx, hypopharynx and oral cavity. These subdivisions are important in CT and MRI but of less significance in ultrasound. All radiologists should be aware of these traditional divisions (Figure 1.1). They are relevant in the diagnosis and staging of squamous cell carcinoma (SCC), the most prevalent tumour of the upper aerodigestive tract.¹

Surgeons and anatomists² have traditionally divided the neck into triangles based on muscular landmarks and boundaries. This division of the neck into triangles does not sit easily with the cross-sectional anatomy techniques practised by radiologists, however radiologists must be aware of the surgical system in order to comprehend referrals for imaging (Figure 1.2).

Knowledge of the anatomy of just three muscles the sternocleidomastoid, digastric and omohyoid is the key to understanding the triangles of the neck. The sternocleidomastoid, which runs from the mastoid process to the clavicle and sternum, divides the neck into two large triangles: anterior and posterior.

The anterior triangle is subdivided into supra- and infra-hyoid portions. The suprahyoid portion is further divided by the anterior belly of digastric muscle into the submental and submandibular triangles. The infrahyoid portion is divided by the superior belly of the omohyoid muscle into muscular and carotid triangles. The posterior belly of digastric marks the superior border of the carotid triangle.

The posterior triangle is demarcated by the posterior border of sternomastoid anteriorly and the anterior border of trapezius posteriorly. The apex is formed by the occiput while the base of the triangle is formed by the clavicle. The triangle is further subdivided by the posterior belly of the omohyoid muscle, forming an occipital triangle superiorly and a supraclavicular triangle inferiorly. The division of the neck by the sternomastoid often poses a dilemma in that a mass deep to the sternomastoid is not strictly in the anterior or the posterior triangle, the posterior border of sternomas-

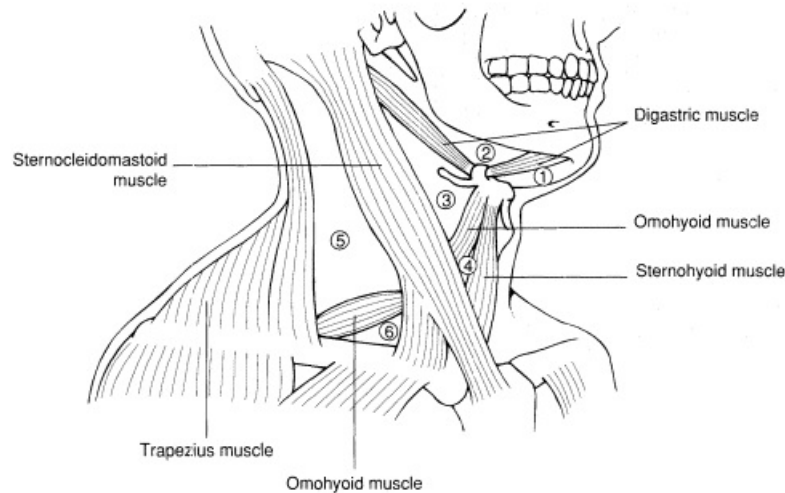


Figure 1.2

Division of the neck into 'triangles'. The anterior triangle is divided into ① submental ② submandibular, ③ carotid and ④ muscular triangles. The posterior triangle is divided into a ⑤ occipital triangle and an ⑥ supraclavicular.

toid demarcating the anterior boundary of the posterior triangle.

The advent of CT and MRI has brought about a reappraisal by radiologists of the anatomy of the extracranial head and neck. The multiplanar capabilities of MRI in particular have enabled a far better appreciation of the complex anatomy of this region. The 'spaces' concept has been heralded as the key to a better understanding of the anatomy and pathology of the head and neck. Radiologists, in particular Harnsberger,³⁶ have developed a clear and practical method of using the spaces concept to analyse head and neck pathology (Figures 1.3, 1.4). Above the hyoid bone the spaces concept works well and knowledge of the suprahyoid spaces aids assessment with ultrasound, however the same is not true when assessing the infrahyoid neck.

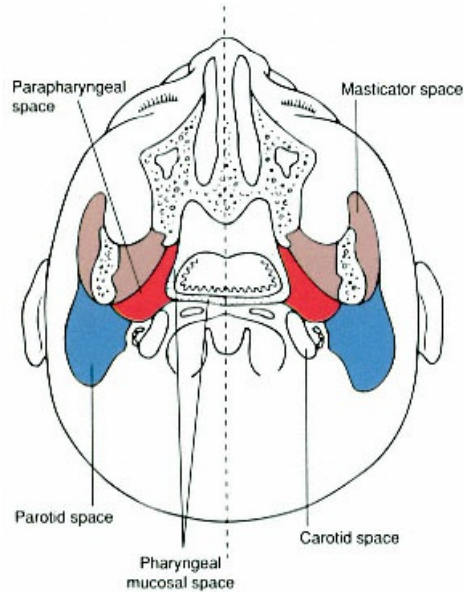


Figure 1.3

Axial section depicting the 'big five' spaces of the neck, i.e. parapharyngeal space (red), parotid space (blue), carotid space, masticator space (brown), and pharyngeal mucosal space.

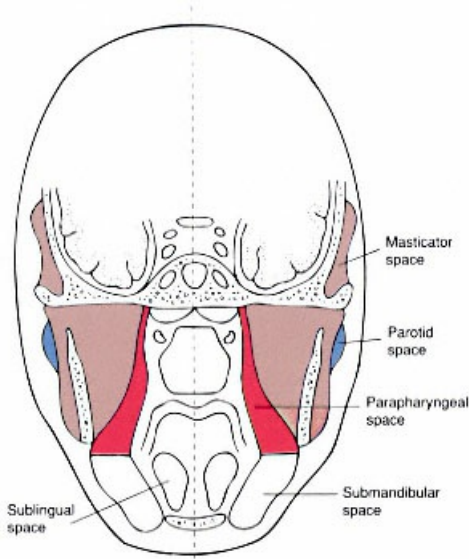


Figure 1.4

Coronal section showing the major spaces. Note the cranial/caudal extension of the parapharyngeal and masticator spaces. Note also the communication between the parapharyngeal and submandibular spaces.

Ultrasound Anatomy

'Where do I start?' is a familiar plea when attempting ultrasound of the head and neck. It is essential to have an easily replicated systematic strategy for the examination of the extracranial head and neck. This allows key structures to be identified and enables assessment of the whole neck. The aim of this chapter is to present a strategy that allows the sonographer or radiologist to quickly and systematically examine the neck.

The ensuing method follows a logical progression from mandible to clavicle in direction. For each region the key structures that can be, and need

to be, identified will be highlighted.

Submental Region (Figure 1.5)

The borders of the submental triangle are easily defined on ultrasound. The floor is formed by the mylohyoid muscle, and the apex of the triangle by the symphysis mentis, the base of the triangle being formed by the hyoid bone. The anterior belly of the digastric muscles represent the sides of the triangle. These can be followed down in transverse section to the hyoid. The only contents of note are the submental lymph node group.

The genioglossus and geniohyoid muscles form the root of the tongue. Together with the hyoglossus muscle they make up the major extrinsic muscles of the tongue. The mylohyoid muscle is synonymous with the floor of mouth, forming a muscular sling between the medial aspect of the mandibular bodies. Posteriorly the mylohyoid has a free thick border and is thinner anteriorly where it is attached to the anterior mandible inferior to the origins of the genial muscles (genioglossus and geniohyoid). The anterior portion of the mylohyoid can be difficult to demonstrate, and in some instances it is deficient anteriorly.

The lingual artery can be easily picked up using colour flow imaging, and is a readily recognised landmark. It is just medial to the hyoglossus muscle. Differentiation between the mylohyoid and hyoglossus muscles can be aided by scanning in the coronal plane, while asking the patient to move the tongue from side to side. The mylohyoid is relatively immobile while the hyoglossus is identified actively contracting (see Figure 1.6b, c). Contraction of the hyoglossus muscle depresses the tongue. Lateral to the hyoglossus, the submandibular duct can be identified⁷, particularly if it is dilated (see Figure 1.6d). Take care not to confuse the duct with the lingual vein which sits alongside the proximal submandibular duct; colour flow imaging usually identifies the vein. The submandibular duct is sandwiched with the sublingual gland between the hyoglossus and mylohyoid muscles. It lies just superior and lateral to the lingual artery, which can be identified medial to the hyoglossus muscle (Fig 1.6b).

The sublingual gland is identified on transverse or axial sections as an elongated hyperechoic structure, lateral to hyoglossus. It is much larger than is generally appreciated: anteriorly it almost touches the symphysis mentis and posteriorly it abuts the deep surface of the submandibular gland. The submandibular duct often receives a large accessory duct from the anterior part of the sublingual gland (Bartholin's duct). The sublingual gland may be joined to the submandibular gland to form a large, single sublingualsubmandibular complex.

The mylohyoid muscle is the key to differentiating whether or not a lesion is in the sublingual or submandibular space. Lesions deep to mylohyoid are within the sublingual space; if a lesion is superficial to mylohyoid it lies within the submandibular space (see Figure 1.4). Around the posterior border of the mylo-

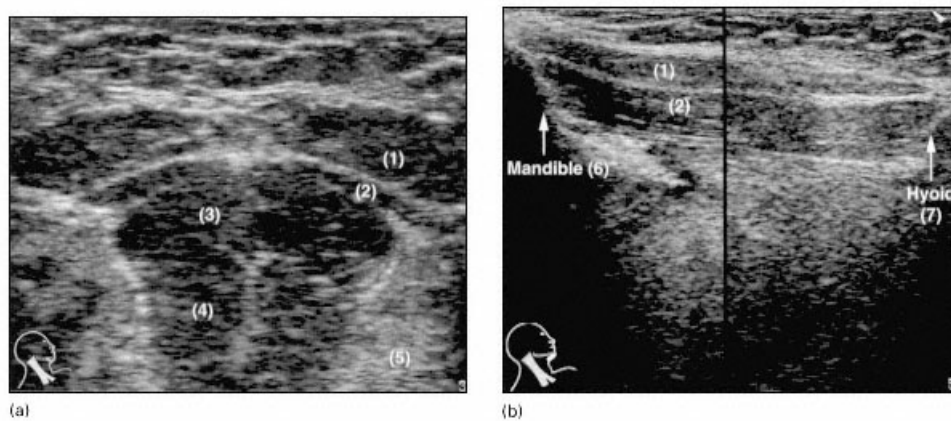


Figure 1.5

- (a) Coronal and (b) sagittal images of the submental region. (1) Anterior belly of digastric muscle. (2) Mylohyoid. (3) Geniohyoid. (4) Genioglossus. (5) Sublingual gland. (6) Mandible. (7) Hyoid.

hyoid muscle free communication is possible between the posterior sublingual space and the adjacent submandibular and inferior parapharyngeal space (as in a diving ranula a retention cyst of the sublingual gland that extends posteriorly into the submandibular space and inferiorly into the parapharyngeal space).

The submandibular duct extends anteriorly from the gland within the submandibular space into the sublingual space, swerving around the free posterior border of mylohyoid.

Submandibular Region (Figure 1.6)

The submandibular gland sits like a saddle astride the digastric and mylohyoid muscles when viewed in a transverse plane. The anterior belly of the digastric may be seen emerging anteriorly. The anterior belly of the digastric is more muscular and easier to define than the tendinous portion of the posterior belly which is identified immediately posterior to the body of the submandibular gland. The tendon of the posterior belly can be followed down towards the hyoid. Immediately

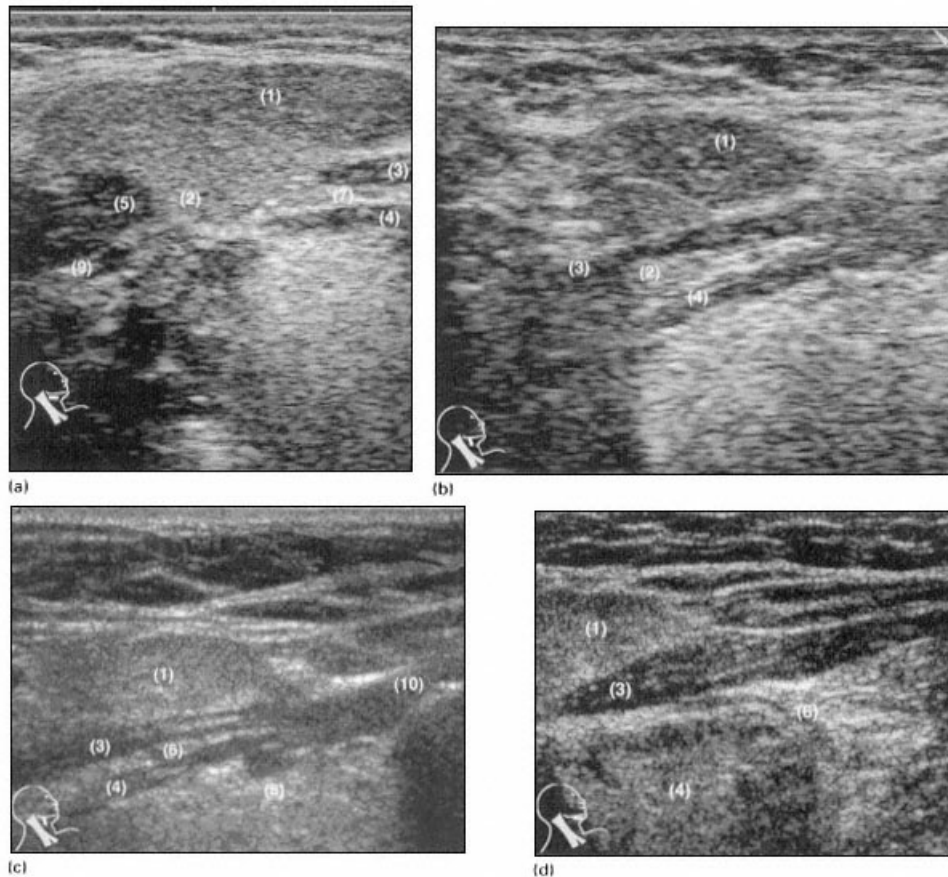


Figure 1.6

- (a) Transverse, (b) coronal, (c) coronal oblique, (d) transverse views of the submandibular region.
 (1) Superficial submandibular gland. (2) Deep submandibular gland. (3) Mylohyoid. (4) Hyoglossus.
 (5) Posterior belly of digastric. (6) Submandibular duct. (7) Lingual vein. (8) Lingual artery.
 (9) Facial artery. (10) Hyoid.

inferior to the submandibular gland it cannot usually be seen as it splits the stylohyoid muscle and then enters its fascial tunnel. The submandibular gland lies in the plane of the anterior belly of digastric, hence more of the anterior belly is identified in parasagittal sections of the submandibular gland than the posterior belly which runs in a more cranialcaudal orientation, i.e. more vertically. More posteriorly the mylohyoid is visible, its posterior free border indenting the submandibular gland.

Anterior to the submandibular gland is a small, fatfilled triangular space. Lymph nodes can be identified in this region. Two constant venous landmarks outline the submandibular gland; anteriorly and superiorly the facial vein can be seen coursing superficially, and posteriorly the anterior division of the retromandibular vein can be identified. This joins with the facial vein to drain into the internal jugular vein. Displacement of this venous structure is the key to differentiating whether a mass is arising from the submandibular gland anteriorly or the parotid gland posteriorly. The superficial venous anatomy of the neck, while variable, provides many recognisable landmarks (Figure 1.7). The serpiginous course of the facial artery can be identified with colour flow imaging as it passes deep to the anterior portion of the submandibular gland. It emerges from behind the mid/anterior portion of the gland to pass up and over the body of mandible.

Parotid Region (Figure 1.8)

The parotid space extends from the external auditory meatus superiorly to the angle of the mandible inferiorly. Within the gland lies the retromandibular vein (RMV) and, just medial to it, the external carotid artery (ECA). The RMV is a landmark for the facial nerve which courses just laterally. The RMV can be taken as a marker for the division of the parotid into superficial and deep lobes. Alternatively, an imaginary line drawn along the axis of the ramus of the mandible through the parotid acts to divide the superficial and deep lobes. The main parotid duct is identified as an echogenic line within the superficial lobe. The masseter muscle lies just deep to the anterior aspect of the superficial lobe, and accessory lobes of the parotid are identified in this region. The parotid duct runs approximately one finger breadth below the zygomatic arch, coursing anteriorly through the buccal space before

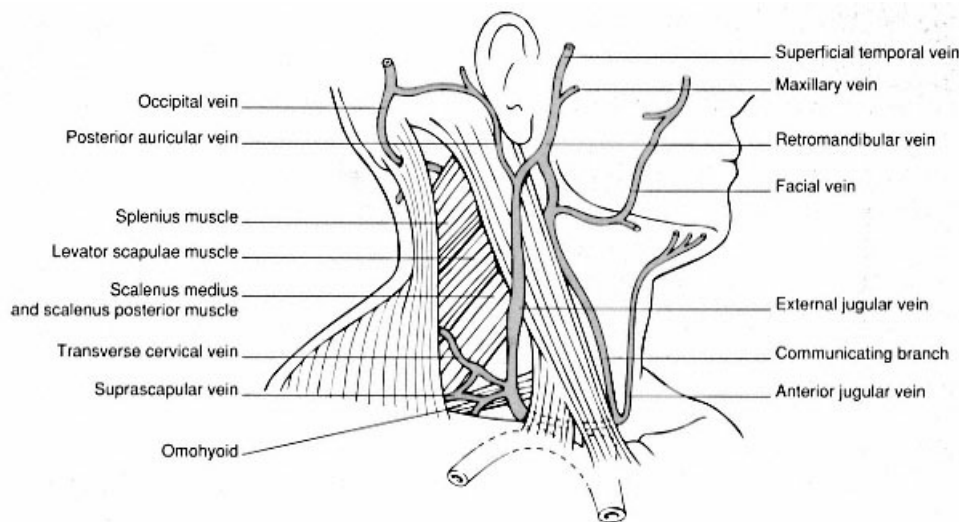


Figure 1.7
Superficial venous anatomy of the neck.

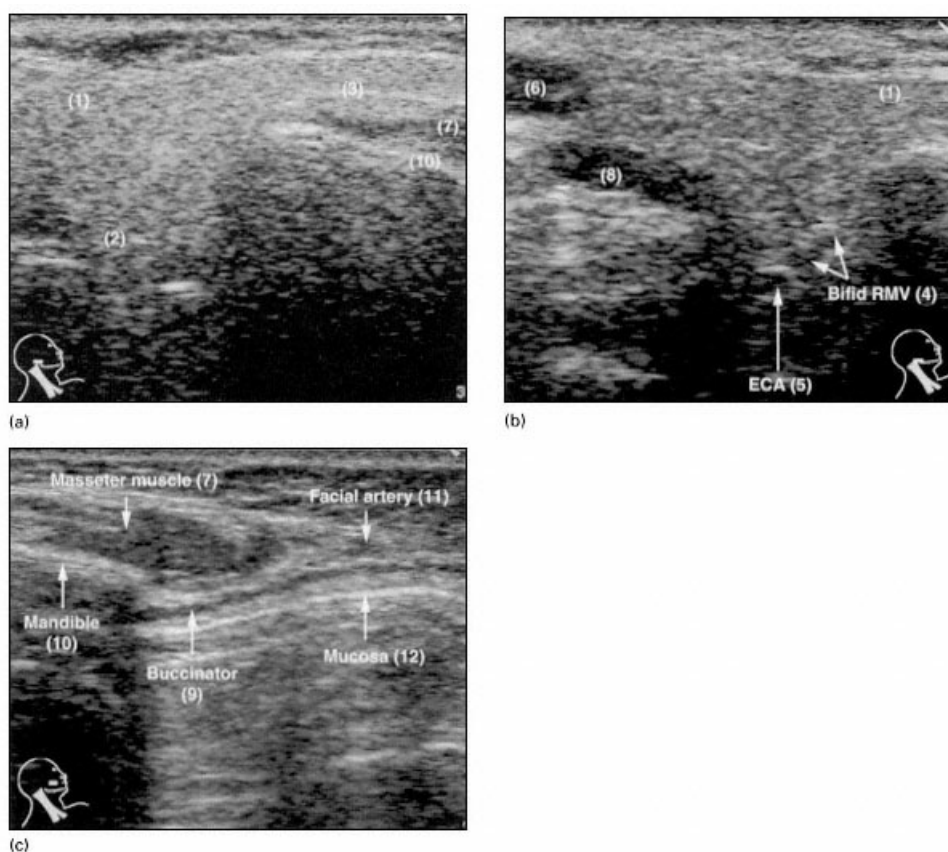


Figure 1.8

- (a) Axial image of body of parotid, (b) axial image of parotid tail, (c) axial image of buccal region.
 (1) Superficial lobe parotid. (2) Deep lobe parotid. (3) Parotid duct. (4) Retromandibular vein.
 (5) External carotid artery. (6) Sternomastoid. (7) Masseter. (8) Posterior belly digastric.
 (9) Buccinator. (10) Mandible. (11) Facial artery. (12) Mucosa.

piercing the buccinator muscle. The thin buccinator muscle extends anteriorly and just medially to the anterior margin of the masseter (Figure 1.8c). Asking the patient to blow out the cheek or clench the teeth aids its identification. The buccal space, which lies lateral to the buccinator muscle, contains fat, the facial nerve, vein, artery and parotid duct.

Upper Cervical Region (Figure 1.9)

As the probe passes down from the tail of the parotid gland the operator is confronted by a minefield of vascular structures. Colour flow imaging is of great assistance in this area.

The two structures to pick out are the internal jugular vein (IJV), which acts as the landmark for the deep cervical lymph node chain, and the posterior belly of digastric muscle. The posterior belly of the digastric muscle is a key structure in separating the parotid region from the upper cervical region inferiorly. Clinically, the posterior belly of the digastric muscle marks the division between the submandibular triangle anteriorly and the carotid triangle more posteriorly. To identify it, align the probe just anterior to the mastoid process, directing down towards the hyoid. The posterior belly of digastric will be identified emerging deep to sternomastoid muscle to abut the tail of the parotid. It is a superficial structure and courses at approximately

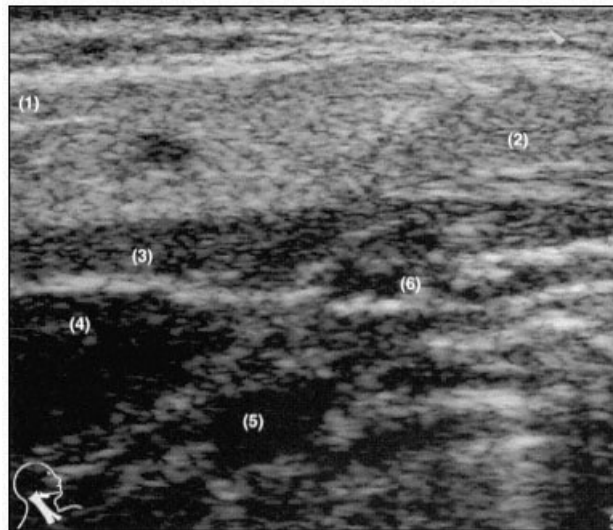


Figure 1.9
 Axial image of the upper cervical region. (1) Parotid gland.
 (2) Submandibular gland. (3) Posterior belly digastric.
 (4) Internal jugular vein. (5) Internal carotid artery.
 (6) External carotid artery. Note the union of the
 parotid and submandibular glands (normal variant).

45 degrees to the plane of the north-south axis of the parotid gland; the retromandibular vein and its connection to the external jugular vein can be seen passing superficial to it. This is the only major vascular structure that is superficial to the posterior belly of digastric.

By turning the probe slightly inferiorly along the line of the posterior belly of digastric the vessels deep to it are seen. From posterior to anterior, they are the internal jugular vein, internal carotid artery and external carotid artery (Figure 1.10).

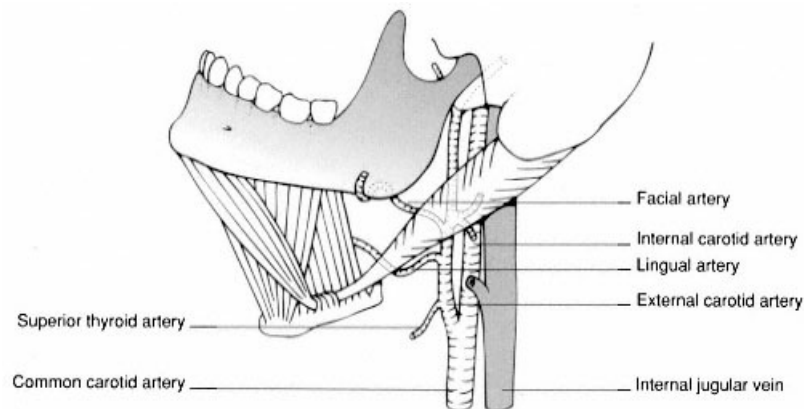


Figure 1.10
 The key relationships of the posterior belly of digastric muscle.

In thin necks the transverse process of the atlas may be identified, situated halfway between the mastoid process and the angle of the mandible.

Mid Cervical Region (Figure 1.11)

Where does the upper cervical region end and the mid cervical region begin? The cervical region is divided into upper and mid portions by the hyoid bone. The cricoid cartilage divides mid from lower portions.

The omohyoid muscle is an important surgical landmark. The superior belly of omohyoid divides the infrahyoid portion of the anterior triangle into carotid and muscular triangles whilst the posterior or inferior belly divides the posterior triangle into occipital and subclavian triangles. Many tumours are treated by tumour resection with a supra-omohyoid lymph node dissection. The omohyoid also represents an important landmark in the radical neck dissection.

The omohyoid arises from the anterior portion of the body of the hyoid bone before running obliquely to cross anterior to the common carotid artery and then deep to sternomastoid. It has an intermediate tendon which passes through a fascial sling attached to the clavicle. At this point it occasionally overlies the IJV but is usually found immediately lateral to it, where it may be mistaken for a lymph node. It then runs obliquely again across the fascial carpet of the inferior posterior triangle to attach to the posterior aspect of the lateral clavicle.

The key structures of the mid cervical region are the common carotid artery (CCA) and IJV. Scanning inferiorly in a transverse plane detects any adjacent lymph nodes and allows the omohyoid to be identified crossing from medial to lateral over the CCA. This point is usually at the level of the cricoid cartilage, demarcating the division between the mid and lower portions of the deep cervical chain. When scanning transversely, just

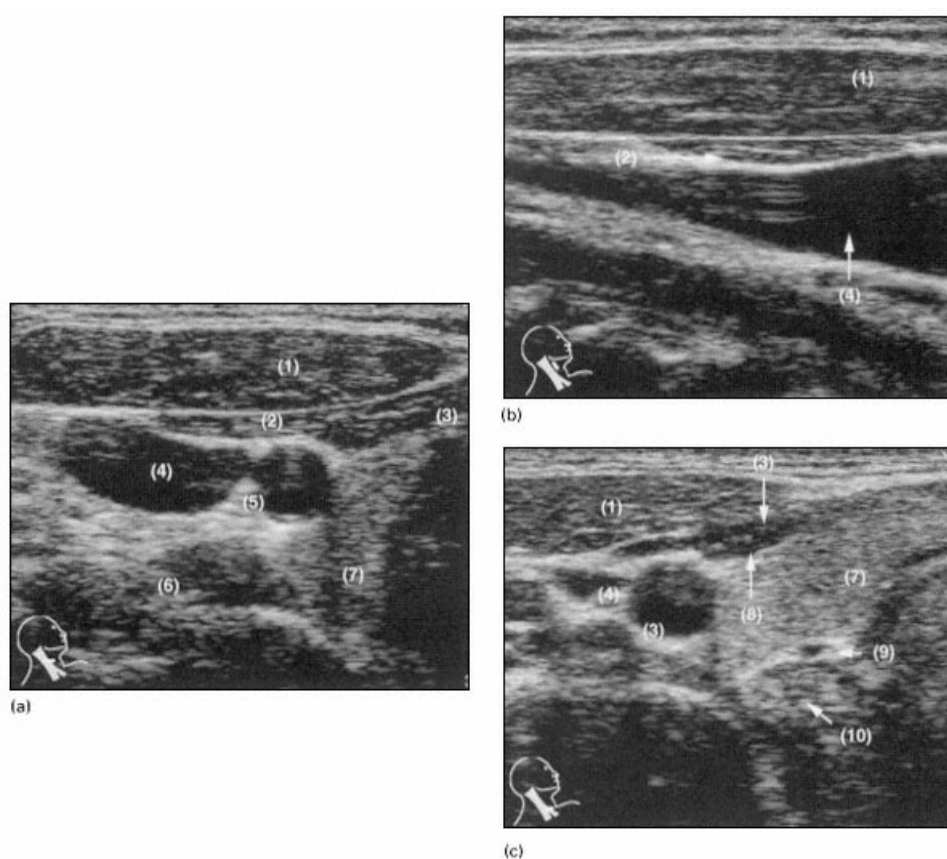


Figure 1.11

- (a) Axial and (b) sagittal views of the mid cervical region; (c) axial view of the lower cervical region.
 (1) Sternomastoid. (2) Omohyoid. (3) Sternohyoid. (4) Internal jugular vein. (5) Common carotid artery.
 (6) Scalenus anterior. (7) Thyroid. (8) Sternothyroid. (9) Inferior thyroid artery. (10) Oesophagus.

as when examining the deep venous system of the leg, repeatedly compress the IJV (i.e. bounce the probe). This does two things: it easily identifies the compressible IJV and 'fixes' the IJV in the centre of the probe and subsequent field of view. When the mid and lower cervical regions are scanned, the oesophagus may be identified medial to the CCA and at times it is situated quite lateral to the trachea. It is more commonly seen on the left. Ask the patient to swallow to permit easy clarification.

Lower Cervical Region (see Figure 1.11c)

The point at which the omohyoid crosses the carotid artery marks the boundary of the lower cervical region.

Continue to scan inferiorly in the transverse plane, using the great vessels as key localising structures, to reach the junction of the subclavian and CCA. This marks the root of the neck; the origin of the subclavian artery can be seen by angling the probe inferiorly behind the medial head of the clavicle.

The key structure in the root of the neck is the scalenus anterior muscle. This muscle runs inferiorly from the transverse processes of the cervical spine, passing posterior to the IJV to dip behind the medial clavicle to attach to the first rib. Scanning the IJV transversely and then in the sagittal plane more inferiorly, it is possible to identify the scalenus anterior muscle posterior to the IJV running from 12 o'clock to 7 o'clock (on the patient's right). This muscle lies between the second part of the subclavian artery posteriorly and the subclavian vein anteriorly.

The root of the neck is a difficult area to assess with ultrasound. The anatomy is more easily appreciated once the scalenus anterior and the subclavian artery are identified (Figure 1.12). By angling inferiorly one can identify reverberation artefact from the apex of the lung inferior to the subclavian artery (Figure 1.13d). The ideal combination is a patient with a relatively thin neck and a small footprint probe a situation that is not always encountered.

Posterior Triangle Region (Figure 1.13).

Having reached the clavicle, one now heads northwards again to assess the posterior triangle region. Beginners in head and neck ultrasound are often daunted in their attempts at assessing the posterior triangle by the large number of muscles that instantly fill the screen. Where does one start?

Remember that the posterior triangle is a very superficial region of the neck, bordered anteriorly by the sternomastoid and posteriorly by the trapezius muscle. The floor is formed by muscles running obliquely: these are (from anterior to posterior) the scalene, levator scapulae and splenius capitis muscles. Covering the muscular floor is a carpet of cervical fascia. The contents of the posterior triangle which lie superficial to the fascial carpet are few: spinal accessory nerve (XI), spinal accessory lymph node chain, pre-axillary

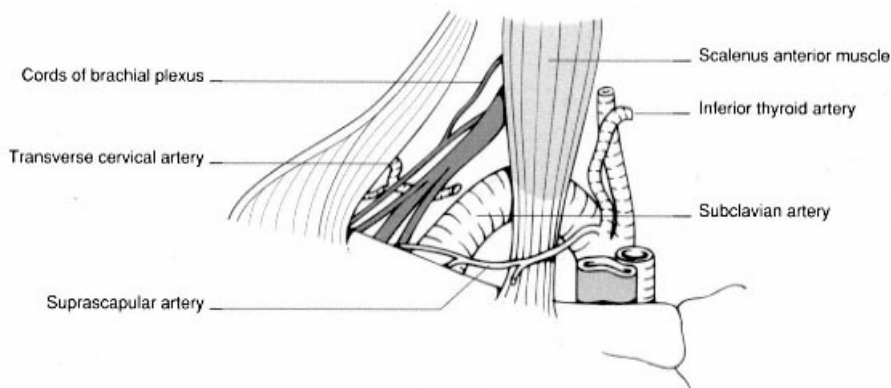


Figure 1.12

The key relationships of the scalenus anterior muscle.

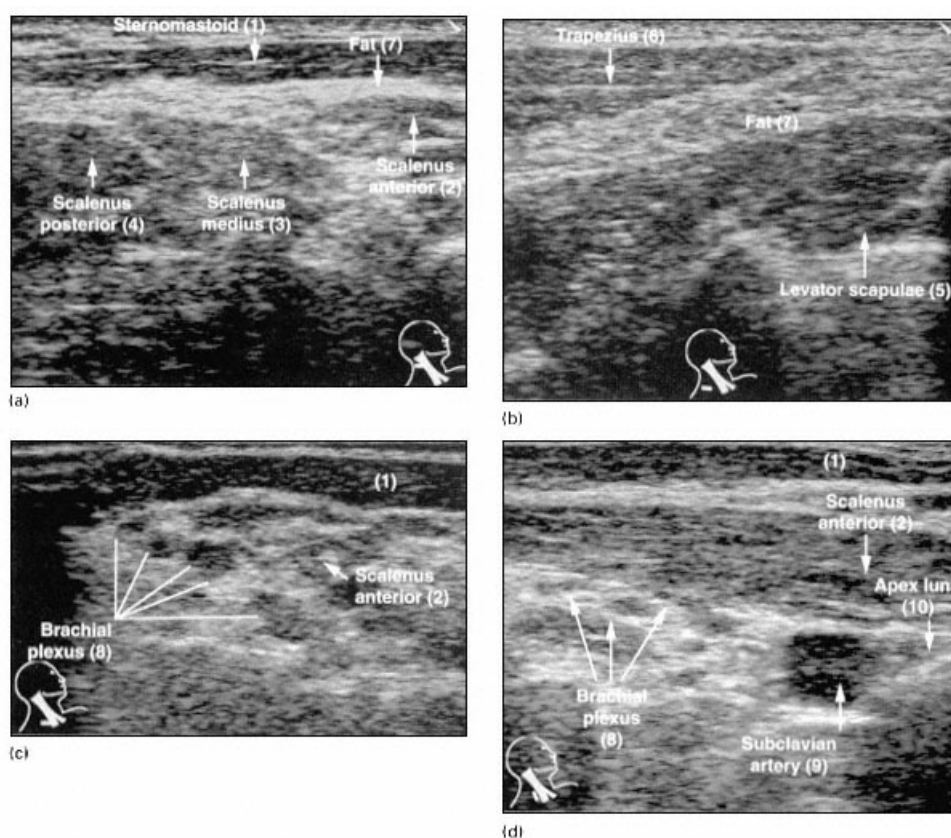


Figure 1.13

- (a, b) Axial views of the posterior triangle region; (c) axial view of the supraclavicular region; (d) sagittal view of the supraclavicular region. (1) Sternomastoid. (2) Scalenus anterior. (3) Scalenus medius. (4) Scalenus posterior. (5) Levator scapulae. (6) Trapezius. (7) Fat. (8) Brachial plexus. (9) Subclavian artery. (10) Apex lung.

brachial plexus, dorsal scapular nerve and fat. More inferiorly the transverse cervical artery and vein, arising from the thyrocervical trunk and IJV respectively, can be found coursing parallel to the clavicle.

Assessment is easy if it is remembered that the posterior triangle is a fat-filled superficial structure. The plane between the superficial sternomastoid and trapezius muscles and the deeper muscles of the posterior triangle floor is identified, and scanning is undertaken in a transverse plane from mastoid tip, i.e. sternomastoid origin, to mid/lateral clavicle. Remember that the spinal accessory nerve (and the accompanying lymph node chain) runs from a point halfway between the mastoid process and angle of mandible to the outer third of the clavicle; maintaining the probe in that line will ensure that the territory of the spinal accessory chain is covered. On transverse scans, the tips of the transverse processes of the vertebrae may be seen as echogenic structures with posterior acoustic shadowing. Do not mistake these for calcified lymph nodes.

Supraclavicular Region (see Figure 1.13c, d)

Once the probe has passed down along the line of the posterior triangle and come to rest at the lateral clavi-