

KEEP THIS CARD.

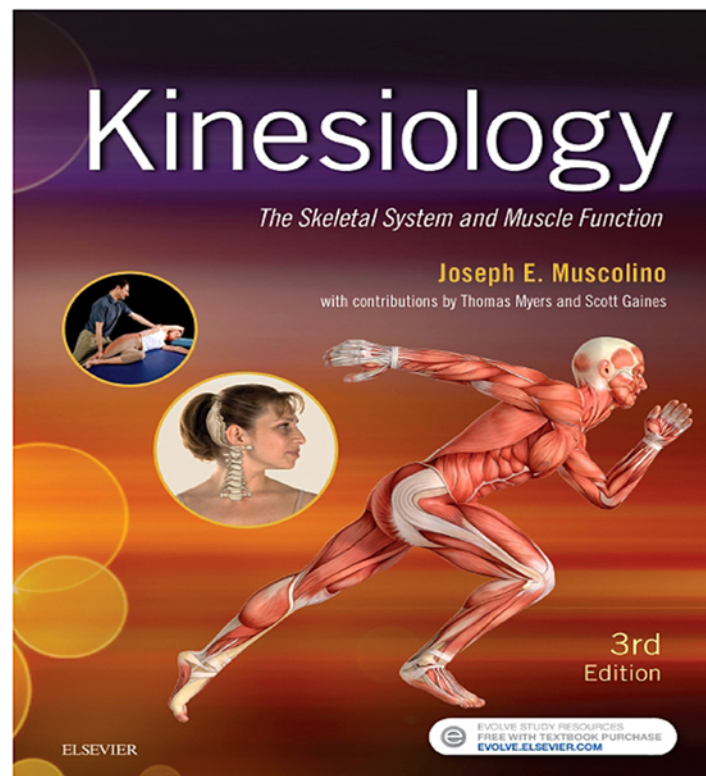
ACCESS CODE INSIDE

ELSEVIER

eBook on Intel® Education Study

MUSCOLINO: KINESIOLOGY

EDITION 3



THIS PACKAGE CANNOT BE RETURNED FOR REFUND OR CREDIT IF OPENED.

PART I
Fundamentals of Structure and
Motion of the Human Body

Chapter 1 Parts of the Human Body

Chapter 2 Mapping the Human Body

PART II
Skeletal Osteology:
Study of the Bones

Chapter 3 Skeletal Tissues

Chapter 4 Fascia

Chapter 5 Bones of the Human Body

PART III
Skeletal Arthrology:
Study of the Joints

Chapter 6 Joint Action Terminology

Chapter 7 Classification of Joints

Chapter 8 Joints of the Axial Body

Chapter 9 Joints of the Lower Extremity

Chapter 10 Joints of the Upper Extremity

PART IV
Myology:
Study of the Muscular System

Chapter 11 Attachments and Actions of Muscles

Chapter 12 Anatomy and Physiology of Muscle Tissue

Chapter 13 How Muscles Function: the Big Picture

Chapter 14 Types of Muscle Contractions

Chapter 15 Roles of Muscles

Chapter 16 Types of Joint Motion and Musculoskeletal Assessment

Chapter 17 Determining the Force of a Muscle Contraction

Chapter 18 Biomechanics

Chapter 19 The Neuromuscular System

Chapter 20 Posture and the Gait Cycle

Chapter 21 Common Postural Distortion Patterns

Chapter 22 Stretching

Chapter 23 Principles of Strengthening Exercise

This page intentionally left blank

Kinesiology

The Skeletal System and Muscle Function

Joseph E. Muscolino, DC

Instructor, Purchase College, State University of New York

Purchase, New York

Owner, The Art and Science of Kinesiology

Stamford, Connecticut

www.learnmuscles.com

**3rd
Edition**

ELSEVIER

ELSEVIER

3251 Riverport Lane
St. Louis, Missouri 63043

KINESIOLOGY: THE SKELETAL SYSTEM
AND MUSCLE FUNCTION, THIRD EDITION

ISBN: 978-0-323-39620-2

Copyright © 2017 by Elsevier, Inc. All rights reserved.

No part of this publication may be reproduced or transmitted in any form or by any means, electronic or mechanical, including photocopying, recording, or any information storage and retrieval system, without permission in writing from the publisher. Details on how to seek permission, further information about the Publisher's permissions policies and our arrangements with organizations such as the Copyright Clearance Center and the Copyright Licensing Agency, can be found at our website: www.elsevier.com/permissions.

This book and the individual contributions contained in it are protected under copyright by the Publisher (other than as may be noted herein).

Notices

Knowledge and best practice in this field are constantly changing. As new research and experience broaden our understanding, changes in research methods, professional practices, or medical treatment may become necessary.

Practitioners and researchers must always rely on their own experience and knowledge in evaluating and using any information, methods, compounds, or experiments described herein. In using such information or methods they should be mindful of their own safety and the safety of others, including parties for whom they have a professional responsibility.

With respect to any drug or pharmaceutical products identified, readers are advised to check the most current information provided (i) on procedures featured or (ii) by the manufacturer of each product to be administered, to verify the recommended dose or formula, the method and duration of administration, and contraindications. It is the responsibility of practitioners, relying on their own experience and knowledge of their patients, to make diagnoses, to determine dosages and the best treatment for each individual patient, and to take all appropriate safety precautions.

To the fullest extent of the law, neither the Publisher nor the authors, contributors, or editors, assume any liability for any injury and/or damage to persons or property as a matter of products liability, negligence or otherwise, or from any use or operation of any methods, products, instructions, or ideas contained in the material herein.

Previous editions copyrighted 2011 and 2006.

Library of Congress Cataloging-in-Publication Data

Names: Muscolino, Joseph E., author
Title: Kinesiology : the skeletal system and muscle function / Joseph E. Muscolino.
Description: 3rd edition. | St. Louis : Elsevier Inc., [2017] | Includes bibliographical references and index.
Identifiers: LCCN 2016022344 | ISBN 9780323396202 (pbk. : alk. paper)
Subjects: | MESH: Kinesiology, Applied | Musculoskeletal System | Biochemical Phenomena
Classification: LCC QP303 | NLM WE 103 | DDC 612.7/6—dc23
LC record available at <https://lcn.loc.gov/2016022344>

Content Strategist: Brandi Graham
Content Development Manager: Ellen Wurm-Cutter
Associate Content Development Specialist: Erin Garner
Publishing Services Manager: Julie Eddy
Book Production Specialist: Celeste Clingan
Design Direction: Julia Dummitt

Printed in China

Last digit is the print number: 9 8 7 6 5 4 3 2 1



Dedication

*This book is dedicated to my entire family,
who has given me everything of value,
most importantly love and support.*


Contributors



Alex Charmoz has been teaching anatomy with Dr. Muscolino since 2009 at the University of Bridgeport cadaver lab. He has several years of work experience in training athletes in studio gyms and privately. He is NASM certified and has attended numerous conferences and workshops over the years. He has a Bachelor's degree in Biology from the University of Bridgeport and has just completed his MD at the University of Connecticut School of Medicine. He plans to practice Emergency Medicine in the future.



Scott E. Gaines, MS, Professor of Biology, Anatomy & Physiology, and Biomechanics, Concordia University, Irvine, California, and Adjunct Professor of Biomechanics, A.T. Still University, Mesa, Arizona. Professor Gaines received his Bachelor of Science degree in Biology from the University of California, Irvine in 1994 and his Master of Science degree in Human Movement from A.T. Still University in 2008. In addition to his work as a professor, he has been the Senior Vice President of the National Exercise and Sports Trainers Association (NESTA) since 2004, overseeing the development of exercise science educational programs for fitness professionals around the globe. He is a national speaker on fitness and performance in areas such as biomechanics and cardiovascular program design.



Thomas Myers, LMT, is the author of *Anatomy Trains: Myofascial Meridians for Manual and Movement Therapists* (Elsevier 2014), the co-author of *Fascial Release for Structural Balance* (North Atlantic 2010), and numerous journal articles. He has also authored instructional DVDs and webinars on visual assessment, Fascial Release Technique, fascial dissection, and the applications of fascial research. Tom and his faculty provide professional development courses worldwide. Tom lives, writes, and sails on the coast of Maine with his partner, Quan.

Tom has practiced integrative manual therapy for 40 years in a variety of clinical and cultural settings, after study with Buckminster Fuller, and with Drs. Ida Rolf and Moshe Feldenkrais. He has also studied movement and martial arts. His work is influenced by cranial, visceral, and biodynamic schools of osteopathy.

Reviewers

Sandra K. Anderson, BA, LMT, ABT, NCTMB

Co-Owner and Practitioner, Tucson Touch Therapies
Treatment Center and Education Center
Tucson, Arizona

Eva Beaulieu, MEd, ATC, LAT

Assistant Athletic Trainer
Georgia College & State University
Milledgeville, Georgia

Vincent Carvelli, BS, RTS2

President, Co-Founder, and Senior Biomechanics
Instructor, Academy of Applied Personal Training
Education (AAPTE)
East Meadow, New York
Continuing Education Specialist, American Council on
Exercise (ACE)
Career and Technical Education Teacher, Joseph M.
Barry Career and Technical Education Center
Westbury, New York
Fellow, National Board of Fitness Examiners (NBFE)

Michael Choothesa, BA, CPT-AFAA

Fairfield, Connecticut

Jonathan Passmore

Investment Professional
Fairfield, Connecticut

Michael P. Reiman, PT, DPT, OCS, SCS, ATC, FAAOMPT, CSCS

Assistant Professor
Wichita State University, Physical Therapy Department
Wichita, Kansas

Pamela Shelline, LMT

Director
Massage Therapy Academy
Saint George, Utah

Third Edition Forewords

RALPH STEPHENS

It has always amazed me how education can take the most fascinating subject on the planet, the study of our own human bodies, and make it arguably the most boring, dreaded subject taught in the training of healthcare providers. That is why I am so excited about the third edition of *Kinesiology*, by my friend and colleague Joseph E. Muscolino, DC. Joe has been teaching anatomy, physiology, kinesiology, as well as hands-on manual and movement therapy techniques for over 30 years and obviously realizes the shortcomings of most anatomy textbooks and programs. Most anatomical education is taught in static, two-dimensional formats. Students memorize text and pictures, then regurgitate them back on tests and forget most of it within a few weeks. This is so sad, primarily because it negatively impacts the quality of care and treatment the public receives.

People are seeking ever-faster resolution of their pain and stress. As we learn more about how the nervous system interacts with the contractile connective tissues and how precise movements, applied as stimuli, can reset the tonus of muscles almost instantly, it has become as important to know what movements a particular muscle performs in the body as where it is. It takes both to be an effective therapist and especially to accurately stimulate the nervous system to bring about the most rapid and complete resets of dysfunctional tissues.

The patients we see are living, moving, and very dynamic organisms. Life is movement; one could define death as a “lack of movement.” In *Kinesiology*, Joe has put the “life” back into the teaching and study of anatomy and physiology by combining it with the study of movement. In real life, anatomy is not separate from movement. For an exciting, memorable learning experience that can be translated into therapeutic effectiveness, they should be taught and learned together. It is the association of the movement each muscle causes and each joint allows (kinesiology) that brings anatomy alive, making it memorable and applicable to a student of any healing art. Life is 3-dimensional. Learning anatomy in a way that makes it real, meaningful, and applicable to therapeutic situations requires it to be taught in 3D.

Joe has done an impressive job of bringing anatomy off the 2-dimensional page and into 3-dimensional reality. Richly illustrated with a combination of colorful illustrations and photographs that bring the text alive, this new edition is easy to read, efficient to reference, and pleasing to the eye. More than 150 videos are included on the accompanying Evolve website, providing more than 2 hours of enhanced visual-spatial learning. Further resources are provided online including—An Interactive Muscle Program, A Stretching Program for patients, a Body Systems Quick Guide, Bony Landmark Palpation Identification Exercises, and more!—making this text a dynamic, ongoing educational resource that will serve readers not only in school but also well into their career.

As valuable as soft-tissue manual therapies can be, they are a fairly static and passive way of addressing the body, and are not very effective at elongating tissue and creating strength balance across joints. *Kinesiology* has brilliant chapters on both stretching and strengthening. This is an exciting addition to both anatomical and clinical education, as it gives practical application to the study of both musculoskeletal anatomy and movement. The answer to most patients’ soft-tissue pain complaints is found in anatomy and kinesiology. This book will be an invaluable tool for the manual and movement soft-tissue therapist/physician/trainer looking for the anatomical answers.

Furthermore, in this third edition, three chapters have been added, all of which are exciting additions to this study of the body.

Chapter 4, *Fascia*, brings to the study of kinesiology the latest information on this all-pervading tissue. Co-written by Thomas Myers, Rolfer, and the author of *Anatomy Trains*, this fascinating chapter provides a wealth of easily understood information and insight into this mysterious tissue that is the focus of so much research and attention lately.

The new Chapter 18, *Biomechanics*, offers the reader an introduction to the topic of biomechanics, which is the study of how forces affect the human body. Both kinematics and kinetics are covered. This topic is of special importance for movement trainers/instructors/therapists who are studying kinesiology in university settings, and is presented to empower them to be able to understand biomechanical principles to optimize the client’s needs in order to maximize performance and minimize injury.

The new Chapter 21, *Common Postural Distortion Patterns*, has now made that study much easier and quicker, giving students the awareness to help people that few therapists ever achieve. Having these patterns for reference will make the sometimes-difficult assessment of postural distortion and its role in a patient’s pain complaints relatively simple. When you can get people out of pain, you will always be busy, as you will never run out of people in pain. This text gives you a solid anatomical foundation for developing a successful clinical practice.

The better you know anatomy, physiology and kinesiology the better therapist you are. It is a life-long study, pursued by serious therapists who care about helping people get out of pain and dysfunction. This book is the best starting point I have seen to date for the most important educational journey a therapist undertakes. It is written with precision, scientific accuracy, and a lot of heart. May this book guide you to better serve humanity through the power of knowledge, compassion, and manual and movement therapy.

Ralph Stephens, LMT, NCBTMB
Ralph Stephens Seminars
Coralville, Iowa

SEAN GALLAGHER

Dr. Muscolino has provided an up-to-date, comprehensive, and integrative review of osteology, arthrology, myology, movement, and special tests that allow any student to gain a unique understanding of the body in front of you when teaching, treating, or evaluating. By being able to organize and search for the tests as well as the anatomy and other body systems related to these tests in a way that allows students as well as practitioners to review for the clinical setting is a great resource. Having a book that allows you to systematically learn the anatomy, myology and body systems, and clinically relevant tests is what is demanded in today's learning environment for physical therapists who are required to have a broad-based systems understanding of the body. Dr. Muscolino's approach in this book makes learning the material not only comprehensive but also interesting at the same time. Allowing the student to make the connections through the boxes and the online materials while studying will help reinforce the learning process.

The use of boxes to highlight special considerations as well as spotlight specific areas of study or interest is a great learning tool for anyone new to this information as well as those who have a clinical need to review. To be able to gain a better understanding of the material presented, the boxes reinforce the dynamic relationships that every therapist needs to gain to truly understand how to put all the different parts together. This book and how it is organized helps students better grasp underlying complexities of the body that are

often not clearly understood when learning only the anatomy or the biomechanics or the neuromuscular system as separate entities. The integrative learning style that Dr. Muscolino has presented in this book will provide anyone who uses all that it has to offer a pathway to becoming a practitioner that understands the complexities of the human body and how to scientifically as well as clinically develop a plan of action to address their particular needs.

The companion Evolve site contains over 150 videos that provide the student with an excellent review of common terms of movement and joint function providing an extra benefit in visual learning that is so integral in understanding the dynamic body. Having this material available online as a supplement to the book is especially beneficial for students as well as new or even seasoned physical therapists who need to review a muscle, special test, or concept with which a patient presents that they have not seen in a while and thus can benefit from a review that is easily accessible.

Kinesiology: The Skeletal System and Muscle Function should be in every student of movement, bodywork, and manual therapy's special category of books to keep a lifetime as it will be the go-to reference when they have anatomical or kinesiological questions they need to answer when working with their clients and patients.

Sean P. Gallagher, BFA, PT, CPI, CFP, EMT, MS
Performing Arts Physical Therapy
New York, New York

Second Edition Foreword

The many different styles of massage therapy and bodywork have become an integral component of addressing musculoskeletal pain and injury conditions. The public's expectations place a high demand on the knowledge base of these practitioners. Consequently, the professional development of massage and bodywork therapists must accommodate the changing requirements of the profession. In the first edition of this text, author Joe Muscolino made an excellent contribution to the professional literature to aid today's soft-tissue therapist. In this new edition of *Kinesiology: The Skeletal System and Muscle Function*, updates and improvements have taken this text to the next level and significantly improved an already excellent resource.

Kinesiology is a critical component of the knowledge and skills necessary for today's soft-tissue therapist. By definition kinesiology is the study of anatomy (structure), neuromuscular physiology (function), and biomechanics (the mechanics of movement related to living systems). Competence in these principles is required even for those practitioners who work in an environment where massage or movement therapy is used only for relaxation or stress reduction. The need to understand proper movement can arise in the most basic soft-tissue treatment.

The requirements for knowing the principles of kinesiology are even greater for those practitioners who actively choose to address soft-tissue pain and injury conditions. Treatment of any soft-tissue disorder begins with a comprehensive assessment of the problem. Accurate assessment is not possible without an understanding of how the body moves under normal circumstances and what may impair its movement in pathology. Joe Muscolino has continually set high standards for helping prepare practitioners of soft-tissue therapy. The improvements in this new edition build on the established foundation that is crucial for today's clinician.

Over the years of teaching orthopedic assessment and treatment to soft-tissue therapists, I have found many students deficient in their understanding of kinesiology. Similarly, students express frustration about understanding how to apply basic kinesiology principles in their practice. Although they receive some training in their initial coursework, traditional approaches to teaching kinesiology often provide little benefit to students. Overwhelmingly, basic courses in kinesiology prove to be insufficient and fail to connect the student with the skills necessary for professional success.

Learning muscle attachments and concentric actions tends to be the focus of most kinesiology curricula and is often turned into an exercise of rote memorization. Yet, there is significantly more to this important subject than these topics. Eccentric actions, force loads, angle of pull, axis of rotation, synergistic muscles, and other concepts are necessary for understanding human movement.

These principles, in turn, are prerequisites for effective therapeutic treatment. An adequate understanding of kinesiology requires more than a curriculum plan that emphasizes memorization. A competent education in kinesiology requires a foundation in the functional application of its principles.

Joe Muscolino's scientific background and years of experience as an educator teaching anatomy, pathology, and kinesiology make him uniquely qualified to tackle a project of this scope. His skill, talent, and demonstrated expertise are evidenced in this work and are of great benefit to the soft-tissue professions. During the years I've known Joe as a professional colleague, we have repeatedly engaged in animated discussions about how to raise the quality of training and improve educational resources available in the profession.

I was thoroughly impressed with the content and presentation of the first edition of this text. In this new edition, the author has responded to the needs of students and educators by including new sections on strength training and stretching. These topics are of great importance to manual therapy practitioners and are often not present in this detail in many other resources. Also included is new and updated information on the role of fascia in movement, stability and posture. Many clinicians are increasingly aware of the importance of fascia, and these new findings help us understand this ubiquitous tissue even better. Finally, a new section on understanding how to read a research paper has been added to this edition. This section introduces the student/practitioner to the importance of research in the manual therapy professions, and then explains how to read and understand a research article. Research literacy is an increasingly important skill in the manual therapy profession, and this section facilitates that process.

The educational landscape is changing at a dramatic pace and one of the most powerful changes driving this transformation is the development and use of enhanced multimedia resources. The Elsevier Evolve site is a wealth of teaching and learning materials for students and users of this text. Numerous activities have been designed to aid the student in both comprehension of basic concepts as well as developing high order thinking skills that are essential in clinical practice.

When this book first came out it was clear that it excelled as both a comprehensive resource for the practicing professional and an excellent guide for students new to the field. This updated edition has broken new ground and set the bar high as a comprehensive resource and learning tool for professionals in multiple disciplines.

Whitney Lowe, LMT
Orthopedic Massage Education & Research Institute
Sisters, Oregon

Preface

The term *kinesiology* literally means *the study of motion*. Because motion of the body is created by the forces of muscle contractions pulling on bones and moving body parts at joints, kinesiology involves the study of the musculoskeletal system. Because muscle functioning is controlled by the nervous system, kinesiology might be better described as study of the neuromusculoskeletal system. And because the importance of fascia is better understood and accepted, perhaps the best description might be study of the neuro-myo-fascio-skeletal system!

There are three keys to healthy motion: (1) flexibility of soft tissues to allow motion, (2) strength of musculature to create motion and stability, and (3) neural control from the nervous system. This book provides the readers/students with necessary information to apply this knowledge and to help their patients/clients in the health and fitness fields.

Kinesiology: The Skeletal System and Muscle Function, third edition, is unique in that it is written for the allied health fields of manual and movement therapies, and rehabilitation and fitness training. These fields include massage therapy, physical therapy, occupational therapy, yoga, Pilates, fitness and athletic training, Feldenkrais technique, Alexander technique, chiropractic, osteopathy, naturopathy, and exercise physiology. Information is presented in a manner that explains the fundamental basis for movement of the human body as it pertains to working with clients in these fields. Clinical applications are located throughout the text's narrative and in special lightbulb and spotlight boxes to explain relevant concepts.





CONCEPTUAL APPROACH

The purpose of this book is to explain the concepts of kinesiology in a clear, simple, and straightforward manner, without dumbing down the material. The presentation of the subject matter of this book encourages the reader or student to think critically instead of memorize. This is achieved through a clear and orderly layout of the information. My belief is that no subject matter is difficult to learn if the big picture is first presented, and then the smaller pieces are presented in context to the big picture. An analogy is a jigsaw puzzle, wherein each piece of the puzzle represents a piece of information that must be learned. When all the pieces of the puzzle first come cascading out of the box, the idea of learning them and fitting them together can seem overwhelming; and indeed it is a daunting task if we do not first look at the big picture on the front of the box. However, if the big picture is first explained and understood, then our ability to learn and place into context all the small pieces is facilitated. This approach makes the job of being a student of kinesiology much easier!

ORGANIZATION

Generally, the information within this book is laid out in the order that the musculoskeletal system is usually covered. Terminology is usually needed before bones can be discussed. Bones then need to be

studied before the joints can be learned. Finally, once the terminology, bones, and joints have been learned, the muscular system can be explored. However, depending on the curriculum of your particular school, you might need to access the information in a different order and jump around within this book. The compartmentalized layout of the sections of this book easily allows for this freedom.

- Scattered throughout the text of this book are lightbulb  and spotlight  icons. These icons alert the reader to additional information on the subject matter being presented. A  contains an interesting fact or short amount of additional information; a  contains a greater amount of information. In most cases, these illuminating boxes immediately follow the text statements that explain the concept.
- At the beginning of each chapter is a list of learning objectives. Refer to these objectives as you read each chapter of the book.
- After the learning objectives is an overview of the information of the chapter. I strongly suggest that you read this overview so that you have a big picture idea of what the chapter covers before delving into the details.
- Immediately after the overview is a list of key terms for the chapter, with the proper pronunciation included where necessary. These key terms are also in bold blue type when they first appear in the text. A complete glossary of all key terms from the book is located on the Evolve website that accompanies this book.
- After the key terms is a list of word origins. These origins explore word roots (prefixes, suffixes, and so forth) that are commonly used in the field of kinesiology. Learning a word root once can enable you to make sense of tens or hundreds of other terms without having to look them up!

Kinesiology, The Skeletal System and Muscle Function is divided into four parts:

- **Part I** covers essential terminology that is used in kinesiology. Terminology that is unambiguous is necessary to allow for clear communication, which is especially important when dealing with clients in the health, athletic training, and rehabilitation fields.
- **Part II** covers the fascial and skeletal systems. This part explores the makeup of skeletal and fascial tissues and also contains a photographic atlas of all bones and bony landmarks, as well as joints, of the human body.
- **Part III** contains a detailed study of the joints of the body. The first two chapters explain the structure and function of joints in general. The next three chapters provide a thorough regional examination of all joints of the body.
- **Part IV** examines how muscles function. After covering the anatomy and physiology of muscle tissue, the larger kinesiological concepts of muscle function are addressed. A big picture idea of what defines muscle contraction is first explained. From this point, various topics such as types of muscle contractions, roles of muscles, types of joint motions, musculoskeletal assessment, control by the nervous system, posture, the gait cycle, postural distortion patterns, stretching, and strength fitness training are covered. A thor-

ough illustrated atlas of all the skeletal muscles of the body, along with their attachments and major actions, is also given.

DISTINCTIVE FEATURES

There are many features that distinguish this book:

- Clear and ordered presentation of the content
- Simple and clear verbiage that makes learning concepts easy
- Full-color illustrations that visually display the concepts that are being explained so that the student can see what is happening
- Light-bulb and spotlight boxes that discuss interesting applications of the content, including pathologic conditions and clinical scenarios
- Open bullets next to each piece of information allow the student to check off what has been or needs to be learned and allows the instructor to assign clearly the material that the students are responsible to learn
- The Evolve companion site includes video clips that show and explain all joint movements of the body and the major concepts of kinesiology

NEW TO THIS EDITION

Every feature of the second edition has been preserved. In addition, the third edition has many new features:

- A greatly expanded chapter containing a thorough illustrated atlas of all the skeletal muscles of the body along with their attachments and major standard and reverse actions
- A comprehensive chapter on fascial tissue, co-authored by Tom Myers.
- An entire chapter on biomechanics.
- An entire chapter on postural distortion patterns in the body
- Evidence-based references for the entire book.

EVOLVE RESOURCES

- Video clips demonstrating all joint actions of the body are located on the Evolve site. This includes:
 - Kinesiology videos that explain key concepts of kinesiology such as anatomic position, planes, axes, how to name joint actions, and the concept of reverse actions. The videos also demonstrate and describe all the major joint actions of the human body, beginning with actions of the axial body, followed by actions of the lower extremity and upper extremity
 - Palpation demonstration videos
 - Bonus clip on teaching muscle palpation
- Bony landmark identification exercises reinforce your knowledge.
- Answers to review questions in the textbook
- Drag-and-drop labeling exercises aid in your review of the material as you drag the name of the structure and drop it into the correct position on illustrations.
- Crossword puzzles help reinforce muscle names and terminology through fun, interactive activities!
- Glossary of terms and word origins. All terms from the book are defined and explained, along with word origins, on the Evolve site.
- Additional strengthening exercise photographs demonstrate key strengthening exercises on Evolve.

- Stretching Customization allows you to create customized stretching instructions with images for clients to use at home.
- *Musculoskeletal Anatomy Flashcards* provide students with 257 full-color cards that will test their knowledge of muscles, muscle location, pronunciations, attachments, actions, and innervation information.
- Interactive muscle program
- Body systems quick guide
- Audio files for self study
- Radiographs
 - Study these radiographs for real-world application of material in the book.

INSTRUCTOR RESOURCES

For instructors, TEACH lesson plans and PowerPoints cover the book in 50-minute lectures, with learning outcomes, discussion topics, and critical thinking questions. There is also an instructor's manual that provides step-by-step approaches to leading the class through learning the content, as well as kinesthetic in-class activities. Further, a complete image collection that contains every figure in the book, and a test bank in ExamView containing 1,000 questions, are provided.

RELATED PUBLICATIONS

This book has been written to stand on its own. However, it can also complement and be used in conjunction with *The Muscular System Manual*, *The Skeletal Muscles of the Human Body*, fourth edition (Elsevier 2017). *The Muscular System Manual* is a thorough and clearly presented atlas of the skeletal muscles of the human body that covers all aspects of muscle function. These two textbooks, along with *Musculoskeletal Anatomy Coloring Book*, third edition (Elsevier 2018), and *Flashcards for Bones, Joints, and Actions of the Human Body*, second edition (Elsevier 2011), give the student a complete set of resources to study and thoroughly learn all aspects of kinesiology.

For more direct clinical assessment and treatment techniques, look also for *The Muscle and Bone Palpation Manual, With Trigger Points, Referral Patterns, and Stretching*, second edition (Elsevier 2016), *Flashcards for Palpation, Trigger Points, and Referral Patterns* (Elsevier 2009), and *Mosby's Trigger Point Flip Chart, with Referral Patterns and Stretching* (Elsevier 2009). For additional information about these products, visit <http://joeknows.elsevier.com>.

Even though kinesiology can be viewed as the science of studying the biomechanics of body movement (and the human body certainly is a marvel of biomechanical engineering), kinesiology can also be seen as the study of an art form. Movement is more than simply lifting a glass or walking across a room; movement is the means by which we live our lives and express ourselves. Therefore science and art are part of the study of kinesiology. Whether you are just beginning your exploration of kinesiology, or you are an experienced student looking to expand your knowledge, I hope that *Kinesiology: The Skeletal System and Muscle Function*, third edition, proves to be a helpful and friendly guide. Even more importantly, I hope that it also facilitates an enjoyment and excitement as you come to better understand and appreciate the wonder and beauty of human movement!

Joseph E. Muscolino, DC
February 2016

Acknowledgments

Usually only one name is listed on the front of a book, and that is the author's. This practice can give the reader the misconception that the author is the only person responsible for what lies in his or her hands. However, many people who work behind the scenes and are invisible to the reader have contributed to the effort. The Acknowledgments section of a book is the author's opportunity to both directly thank these people and acknowledge them to the readers.

First, I would like to thank William Courtland. William, now an instructor and author himself, was the student who 15 years ago first recommended that I should write a kinesiology textbook. William, thanks for giving me the initial spark of inspiration to write.

Because kinesiology is the study of movement, the illustrations in this book are just as important, if not more important, than the written text. I am lucky to have had a brilliant team of illustrators and photographers. Jeannie Robertson illustrated the bulk of the figures in this book. Jeannie is able to portray three-dimensional movements of the body with sharp, accurate, simple, and clear full-color illustrations. Tiziana Cipriani contributed a tremendous number of beautiful drawings to this book, including perhaps my two favorites, Figures 13-13A and 13-13B. Jean Luciano, my principle illustrator for the first edition of *The Muscular System Manual*, also stepped in to help with a few beautiful illustrations. And in this third edition, many beautiful illustrations have been added by Giovanni Rimasti and Jodie Bernard of Lightbox Visuals in Canada. Yanik Chauvin is the photographer who took the photos that appear in Chapters 8, 9, 10, 11, and 22, as well as a few others. Yanik is extremely talented, as well as being one of the easiest people with whom to work. Frank Forney is an illustrator who came to this project via Electronic Publishing Services (EPS). Frank drew the computer drawings of the bones that were overlaid on Yanik's photos in Chapters 8, 9, and 10. Frank proved to be an extremely able and invaluable asset to the artwork team. For Chapter 11, the newly expanded illustrated atlas of muscles chapter, Giovanni Rimasti, Frank

Forney, and Dave Carlson, provided computer-drawn images of the bones and muscles overlaid on Yanik's photos. These illustrations are astoundingly beautiful! Last but not least is Dr. David Eliot of Touro University College of Osteopathic Medicine, who provided the bone photographs that are found in Chapter 5. Dr. Eliot is a PhD anatomist whose knowledge of the musculoskeletal system is as vast as his photographs are beautiful. I was lucky to have him as a contributor to this book.

I would also like to thank the models for Yanik's photographs: Audrey Van Herck, Kiyoko Gotanda, Gamaliel Martinez Fonseca, Patrick Tremblay, and Simona Cipriani. The beauty and poise of their bodies was invaluable toward expressing the kinesiological concepts of movement in the photographs for this book.

I must thank the authors of the other kinesiology textbooks that are presently in print. I like to think that we all stand on the shoulders of those who have come before us. Each kinesiology textbook is unique and has contributed to the field of kinesiology, as well as my knowledge base. I would particularly like to thank Donald Neumann, PT, PhD of Marquette University. His book, *Kinesiology of the Musculoskeletal System*, in my opinion, is the best book ever written on joint mechanics. I once told Don Neumann that if I could have written just one book, I wish it would have been his.

Writing a book is not only the exercise of stating facts but also the art of how to present these facts. In other words, a good writer should be a good teacher. Toward that end, I would like to thank all my present and past students for helping me become a better teacher.

For the act of actually turning this project into a book, I must thank the entire Elsevier team in St. Louis who spent tremendous hours on this project, particularly Shelly Stringer, Brandi Graham, Celeste Clingan, Erin Garner, and Teresa Exley. Thank you for making the birth of this book as painless as possible.

Finally, to echo my dedication, I would like to thank my entire family, who makes it all worthwhile!

About the Author

Dr. Joseph E. Muscolino has been teaching musculoskeletal and visceral anatomy and physiology, kinesiology, neurology, and pathology courses for more than 30 years. He has also been instrumental in course manual development and has assisted with curriculum development. He has published:

- *The Muscular System Manual*, fourth edition
- *The Muscle and Bone Palpation Manual*, second edition
- *Musculoskeletal Anatomy Coloring Book*, second edition
- *Know the Body – Muscle, Bone, and Palpation Essentials*
- *Know the Body Workbook – Muscle, Bone, and Palpation Essentials*
- *Musculoskeletal Anatomy Flashcards*, second edition
- *Flashcards for Bones, Joints, and Actions of the Human Body*, second edition
- *Flashcards for Palpation, Trigger Points, and Referral Patterns*
- *Mosby's Trigger Point Flip Chart, with Referral Patterns and Stretching*
- *Advanced Treatment Techniques for the Manual Therapist: Neck*
- *Manual Therapy for the Low Back and Pelvis – A Clinical Orthopedic Approach*

He has also published more than 70 articles in the *Massage Therapy Journal*, *Journal of Bodywork and Movement Therapies*, *Massage and Bodywork Magazine*, *Massage Magazine*, *Massage Today*, *Pilates Style*, and numerous other overseas journals in the world of manual therapy. And he has developed and created 15 DVDs on manual and movement therapy assessment and treatment techniques for therapists, instructors, and trainers.



Dr. Muscolino runs continuing education workshops on topics such as body mechanics for deep tissue massage, intermediate and advanced stretching techniques, joint mobilization, kinesiology, and cadaver lab workshops. He offers a Certification in Clinical Orthopedic Manual Therapy (COMT) both within the United States and around the world. He is approved by the National Certification Board for Therapeutic Massage and Bodywork (NCBTMB) as a provider of continuing education, and grants continuing education credit (CEUs) for massage therapists toward certification renewal. Dr. Muscolino also served as a subject matter expert and member of the NCBTMB's Continuing Education and Exam Committees.

Dr. Muscolino holds a Bachelor of Arts degree in biology from the State University of New York at Binghamton, Harpur College.

He attained his Doctor of Chiropractic degree from Western States Chiropractic College in Portland, Oregon, and is licensed in Connecticut, New York, and California. He has been in private practice in Connecticut for more than 30 years, currently practicing in Stamford, CT at *Synergy Health and Fitness*, and incorporates soft-tissue work into his chiropractic practice for all his patients.

If you would like further information regarding *Kinesiology: The Skeletal System and Muscle Function*, third edition, or any of Dr. Muscolino's other Elsevier publications, or if you are an instructor and would like information regarding the many supportive materials such as PowerPoint slides, test banks of questions, or instructor's manuals, please visit <http://www.us.elsevierhealth.com>. For questions regarding his other publications, DVDs, or his COMT Certification program, you can contact Dr. Muscolino directly at his web site: <http://www.learnmuscles.com>.

PART I

Fundamentals of Structure and Motion of the Human Body, 1

Chapter 1 Parts of the Human Body, 1

- 1.1 Major Divisions of the Human Body, 2
- 1.2 Major Body Parts, 3
- 1.3 Joints Between Body Parts, 5
- 1.4 Movement of a Body Part Relative to an Adjacent Body Part, 6
- 1.5 Movement within a Body Part, 7
- 1.6 True Movement of a Body Part Versus “Going Along for the Ride”, 8
- 1.7 Regions of the Body, 9

Chapter 2 Mapping the Human Body, 11

- 2.1 Anatomic Position, 13
- 2.2 Location Terminology, 13
- 2.3 Anterior/Posterior, 14
- 2.4 Medial/Lateral, 15
- 2.5 Superior/Inferior and Proximal/Distal, 16
- 2.6 Superficial/Deep, 17
- 2.7 Location Terminology Illustration, 18
- 2.8 Planes, 19
- 2.9 Motion of the Human Body within Planes, 20
- 2.10 Axes, 22
- 2.11 Planes and Their Corresponding Axes, 23
- 2.12 Visualizing the Axes—Door Hinge Pin Analogy, 24
- 2.13 Visualizing the Axes—Pinwheel Analogy, 26

PART II

Skeletal Osteology: Study of the Bones, 29

Chapter 3 Skeletal Tissues, 29

- 3.1 Classification of Bones by Shape, 31
- 3.2 Parts of a Long Bone, 32
- 3.3 Functions of Bones, 33
- 3.4 Bone as a Connective Tissue, 35
- 3.5 Compact and Spongy Bone, 36
- 3.6 Bone Development and Growth, 37
- 3.7 Fontanel, 39
- 3.8 Fracture Healing, 40
- 3.9 Effects of Physical Stress on Bone, 41
- 3.10 Cartilage Tissue, 43

Chapter 4 Fascia, 47

- 4.1 Fascia, 48
- 4.2 The Fascial Web, 52
- 4.3 Fascial Response to Physical Stress, 55
- 4.4 Tendons and Ligaments, 57
- 4.5 Bursae and Tendon Sheaths, 58
- 4.6 Properties of Fascial Connective Tissues, 60

Chapter 5 Bones of the Human Body, 63

- 5.1 Bones of the Head, 71
- 5.2 Bones of the Spine (and Hyoid), 85
- 5.3 Bones of the Ribcage and Sternum, 103
- 5.4 Entire Lower Extremity, 107
- 5.5 Bones of the Pelvis and Hip Joint, 108
- 5.6 Bones of the Thigh and Knee Joint, 113
- 5.7 Bones of the Leg and Ankle Joint, 117
- 5.8 Bones of the Foot, 122
- 5.9 Entire Upper Extremity, 127
- 5.10 Bones of the Shoulder Girdle and Shoulder Joint, 128
- 5.11 Bones of the Arm and Elbow Joint, 133
- 5.12 Bones of the Forearm, Wrist Joint, and Hand, 137

PART III

Skeletal Arthrology: Study of the Joints, 150

Chapter 6 Joint Action Terminology, 150

- 6.1 Overview of Joint Function, 152
- 6.2 Axial and Nonaxial Motion, 152
- 6.3 Nonaxial/Gliding Motion, 153
- 6.4 Rectilinear and Curvilinear Nonaxial Motion, 154
- 6.5 Axial/Circular Motion, 154
- 6.6 Axial Motion and the Axis of Movement, 155
- 6.7 Roll and Spin Axial Movements, 156
- 6.8 Roll, Glide, and Spin Movements Compared, 156
- 6.9 Naming Joint Actions—Completely, 157
- 6.10 Joint Action Terminology Pairs, 158
- 6.11 Flexion/Extension, 159
- 6.12 Abduction/Adduction, 160
- 6.13 Right Lateral Flexion/Left Lateral Flexion, 161
- 6.14 Lateral Rotation/Medial Rotation, 162
- 6.15 Right Rotation/Left Rotation, 162
- 6.16 Plantarflexion/Dorsiflexion, 163
- 6.17 Eversion/Inversion, 164
- 6.18 Pronation/Supination, 164
- 6.19 Protraction/Retraction, 165
- 6.20 Elevation/Depression, 166
- 6.21 Upward Rotation/Downward Rotation, 167
- 6.22 Anterior Tilt/Posterior Tilt, 168
- 6.23 Opposition/Reposition, 169
- 6.24 Right Lateral Deviation/Left Lateral Deviation, 169
- 6.25 Horizontal Flexion/Horizontal Extension, 170
- 6.26 Hyperextension, 171
- 6.27 Circumduction, 172
- 6.28 Naming Oblique Plane Movements, 172
- 6.29 Reverse Actions, 174
- 6.30 Vectors, 175

Chapter 7 Classification of Joints, 179

- 7.1 Anatomy of a Joint, 181
- 7.2 Physiology of a Joint, 181
- 7.3 Joint Mobility Versus Joint Stability, 182
- 7.4 Joints and Shock Absorption, 183
- 7.5 Weight-Bearing Joints, 184
- 7.6 Joint Classification, 185
- 7.7 Fibrous Joints, 186
- 7.8 Cartilaginous Joints, 187
- 7.9 Synovial Joints, 188
- 7.10 Uniaxial Synovial Joints, 191
- 7.11 Biaxial Synovial Joints, 192
- 7.12 Triaxial Synovial Joints, 195
- 7.13 Nonaxial Synovial Joints, 197
- 7.14 Menisci and Articular Discs, 198

Chapter 8 Joints of the Axial Body, 202

- 8.1 Suture Joints of the Skull, 204
- 8.2 Temporomandibular Joint (TMJ), 205
- 8.3 Spine, 210
- 8.4 Spinal Joints, 213
- 8.5 Atlanto-Occipital and Atlantoaxial Joints, 221
- 8.6 Cervical Spine (The Neck), 226
- 8.7 Thoracic Spine (The Thorax), 230
- 8.8 Rib Joints of the Thorax, 231
- 8.9 Lumbar Spine (The Abdomen), 235
- 8.10 Thoracolumbar Spine (The Trunk), 237
- 8.11 Thoracolumbar Fascia and Abdominal Aponeurosis, 239

Chapter 9 Joints of the Lower Extremity, 244

- 9.1 Introduction to the Pelvis and Pelvic Movement, 247
- 9.2 Intrapelvic Motion (Symphysis Pubis and Sacroiliac Joints), 248
- 9.3 Movement of the Pelvis at the Lumbosacral Joint, 251
- 9.4 Movement of the Pelvis at the Hip Joints, 253
- 9.5 Movement of the Pelvis at the Lumbosacral and Hip Joints, 255
- 9.6 Relationship of Pelvic/Spinal Movements at the Lumbosacral Joint, 257
- 9.7 Relationship of Pelvic/Thigh Movements at the Hip Joint, 259
- 9.8 Effect of Pelvic Posture on Spinal Posture, 263
- 9.9 Hip Joint, 264
- 9.10 Angulations of the Femur, 269
- 9.11 Femoropelvic Rhythm, 271
- 9.12 Overview of the Knee Joint Complex, 272
- 9.13 Tibiofemoral (Knee) Joint, 273
- 9.14 Patellofemoral Joint, 279
- 9.15 Angulations of the Knee Joint, 280
- 9.16 Tibiofibular Joints, 283
- 9.17 Overview of the Ankle/Foot Region, 284
- 9.18 Talocrural (Ankle) Joint, 287
- 9.19 Subtalar Tarsal Joint, 293
- 9.20 Transverse Tarsal Joint, 296
- 9.21 Tarsometatarsal (TMT) Joints, 297
- 9.22 Intermetatarsal (IMT) Joints, 298
- 9.23 Metatarsophalangeal (MTP) Joints, 299
- 9.24 Interphalangeal (IP) Joints of the Foot, 301

Chapter 10 Joints of the Upper Extremity, 305

- 10.1 Shoulder Joint Complex, 308
- 10.2 Glenohumeral Joint, 309

- 10.3 Scapulocostal (ScC) Joint, 314
- 10.4 Sternoclavicular (SC) Joint, 316
- 10.5 Acromioclavicular (AC) Joint, 319
- 10.6 Scapulohumeral Rhythm, 321
- 10.7 Elbow Joint Complex, 324
- 10.8 Elbow Joint, 324
- 10.9 Radioulnar Joints, 327
- 10.10 Overview of the Wrist/Hand Region, 330
- 10.11 Wrist Joint Complex, 334
- 10.12 Carpometacarpal Joints, 339
- 10.13 Saddle (Carpometacarpal) Joint of the Thumb, 342
- 10.14 Intermetacarpal Joints, 346
- 10.15 Metacarpophalangeal (MCP) Joints, 348
- 10.16 Interphalangeal (IP) Joints of the Hand, 351

PART IV

Myology: Study of the Muscular System, 357

Chapter 11 Attachments and Actions of Muscles, 357

- 11.1 Overview of the Skeletal Muscles of the Body, 362
- 11.2 Muscles of the Shoulder Girdle, 364
- 11.3 Muscles of the Glenohumeral Joint, 367
- 11.4 Muscles of the Elbow and Radioulnar Joints, 372
- 11.5 Muscles of the Wrist Joint, 377
- 11.6 Extrinsic Muscles of the Finger Joints, 380
- 11.7 Intrinsic Muscles of the Finger Joints, 385
- 11.8 Muscles of the Spinal Joints, 391
- 11.9 Muscles of the Ribcage Joints, 410
- 11.10 Muscles of the Temporomandibular Joints, 414
- 11.11 Muscles of Facial Expression, 420
- 11.12 Muscles of the Hip Joint, 430
- 11.13 Muscles of the Knee Joint, 439
- 11.14 Muscles of the Ankle and Subtalar Joints, 444
- 11.15 Extrinsic Muscles of the Toe Joints, 448
- 11.16 Intrinsic Muscles of the Toe Joints, 450

Chapter 12 Anatomy and Physiology of Muscle Tissue, 457

- 12.1 Skeletal Muscle, 459
- 12.2 Tissue Components of a Skeletal Muscle, 460
- 12.3 Skeletal Muscle Cells, 461
- 12.4 Muscular Fascia, 462
- 12.5 Microanatomy of Muscle Fiber/Sarcomere Structure, 463
- 12.6 Sliding Filament Mechanism, 464
- 12.7 Energy Source for the Sliding Filament Mechanism, 466
- 12.8 Nervous System Control of Muscle Contraction, 467
- 12.9 Motor Unit, 469
- 12.10 All-or-None—Response Law, 470
- 12.11 Sarcomere Structure in More Detail, 471
- 12.12 Sliding Filament Mechanism in More Detail, 474
- 12.13 Red and White Muscle Fibers, 476
- 12.14 Myofascial Meridians and Tensegrity, 477

Chapter 13 How Muscles Function: the Big Picture, 488

- 13.1 “Big Picture” of Muscle Structure and Function, 489
- 13.2 What Happens When a Muscle Contracts and Shortens?, 490
- 13.3 Five-Step Approach to Learning Muscles, 492
- 13.4 Rubber Band Exercise, 493
- 13.5 Lines of Pull of a Muscle, 494

- 13.6 Functional Group Approach to Learning Muscle Actions, 496
- 13.7 Determining Functional Groups, 498
- 13.8 Off-Axis Attachment Method for Determining Rotation Actions, 500
- 13.9 Transferring the Force of a Muscle's Contraction to Another Joint, 501
- 13.10 Muscle Actions That Change, 503

Chapter 14 Types of Muscle Contractions, 507

- 14.1 Overview of the Types of Muscle Contractions, 508
- 14.2 Concentric, Eccentric, and Isometric Contraction Examples, 510
- 14.3 Relating Muscle Contraction and the Sliding Filament Mechanism, 511
- 14.4 Concentric Contractions in More Detail, 513
- 14.5 Eccentric Contractions in More Detail, 516
- 14.6 Isometric Contractions in More Detail, 519
- 14.7 Movement Versus Stabilization, 520

Chapter 15 Roles of Muscles, 523

- 15.1 Mover Muscles, 525
- 15.2 Antagonist Muscles, 527
- 15.3 Determining the "Muscle that is Working", 529
- 15.4 Stopping Unwanted Actions of the "Muscle that is Working", 531
- 15.5 Fixator/Stabilizer Muscles, 532
- 15.6 Concept of Fixation and Core Stabilization, 535
- 15.7 Neutralizer Muscles, 537
- 15.8 Step-by-Step Method for Determining Fixators and Neutralizers, 539
- 15.9 Support Muscles, 541
- 15.10 Synergists, 543
- 15.11 Coordinating Muscle Roles, 544
- 15.12 Coupled Actions, 547

Chapter 16 Types of Joint Motion and Musculoskeletal Assessment, 551

- 16.1 Active Versus Passive Range of Motion, 552
- 16.2 Resisted Motion/Manual Resistance, 555
- 16.3 Musculoskeletal Assessment: Muscle or Joint?, 556
- 16.4 Muscle Palpation, 558
- 16.5 Do We Treat Movers or Antagonists?, 560
- 16.6 Do We Treat Signs or Symptoms?, 561
- 16.7 Understanding Research, 563

Chapter 17 Determining the Force of a Muscle Contraction, 568

- 17.1 Partial Contraction of a Muscle, 570
- 17.2 Muscle Fiber Architecture, 571
- 17.3 Active Tension Versus Passive Tension, 574
- 17.4 Active Insufficiency, 574
- 17.5 Length-Tension and Force-Velocity Relationship Curves, 576
- 17.6 Leverage of a Muscle, 578
- 17.7 Leverage of a Muscle—More Detail, 580
- 17.8 Classes of Levers, 581
- 17.9 Leverage of Resistance Forces, 583

Chapter 18 Biomechanics, 588

- 18.1 Introduction to Biomechanics, 590
- 18.2 A Brief Introduction to Forces, 592
- 18.3 Basic Principles in Mechanics, 595
- 18.4 Describing Human Movement—Analyzing Kinematics, 597
- 18.5 Describing the Forces of Human Movement—Analyzing Kinetics, 602

Chapter 19 The Neuromuscular System, 609

- 19.1 Overview of the Nervous System, 611
- 19.2 Voluntary Movement Versus Reflex Movement, 615
- 19.3 Reciprocal Inhibition, 618
- 19.4 Overview of Proprioception, 619
- 19.5 Fascial/Joint Proprioceptors, 621
- 19.6 Muscle Spindles, 622
- 19.7 Golgi Tendon Organs, 625
- 19.8 Inner Ear Proprioceptors, 627
- 19.9 Other Musculoskeletal Reflexes, 630
- 19.10 Pain-Spasm-Pain Cycle, 633
- 19.11 Gate Theory, 635

Chapter 20 Posture and the Gait Cycle, 639

- 20.1 Importance of "Good Posture", 640
- 20.2 Ideal Standing Plumb Line Posture, 641
- 20.3 Analyzing Plumb Line Postural Distortions, 642
- 20.4 Secondary Postural Distortions and Postural Distortion Patterns, 644
- 20.5 General Principles of Compensation Within the Body, 646
- 20.6 Limitations of Standing Ideal Plumb Line Posture, 647
- 20.7 Gait Cycle, 648
- 20.8 Muscular Activity During the Gait Cycle, 650

Chapter 21 Common Postural Distortion Patterns, 657

- 21.1 Lower Crossed Syndrome, 659
- 21.2 Rounded Low Back/Pelvis, 662
- 21.3 Upper Crossed Syndrome, 663
- 21.4 Flat Back, 665
- 21.5 Elevated/Depressed Pelvis, 667
- 21.6 Scoliosis, 668
- 21.7 Elevated Shoulder Girdle, 669
- 21.8 Pelvic/Spinal Rotational Distortion, 670
- 21.9 Overpronation, 671
- 21.10 Rigid High Arch, 673
- 21.11 Hallux Valgus, 674
- 21.12 Hammertoes, 675
- 21.13 Morton's Foot, 676
- 21.14 Genu Valgum/Genu Varum, 676
- 21.15 Genu Recurvatum, 677
- 21.16 Pigeon-Toe/Toe-in, 678
- 21.17 Cubitus Valgus, 680

Chapter 22 Stretching, 683

- 22.1 Introduction, 684
- 22.2 Basic Stretching Techniques: Static Stretching Versus Dynamic Stretching, 688
- 22.3 Advanced Stretching Techniques: Pin and Stretch Technique, 690
- 22.4 Advanced Stretching Techniques: Contract Relax and Agonist Contract Stretching Techniques, 691

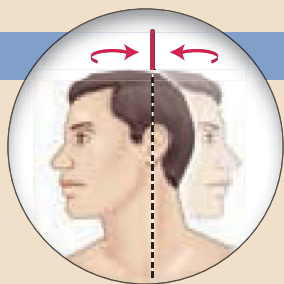
Chapter 23 Principles of Strengthening Exercise, 697

- 23.1 Reasons for Exercise, 699
- 23.2 Types of Exercise, 701
- 23.3 Types of Resistance, 703
- 23.4 Execution of Exercise, 713
- 23.5 Exercise Technique, 718
- 23.6 Program Design, 722

Index, 731

This page intentionally left blank

Fundamentals of Structure and Motion of the Human Body



CHAPTER 1

Parts of the Human Body

CHAPTER OUTLINE

Section 1.1	Major Divisions of the Human Body	Section 1.5	Movement within a Body Part
Section 1.2	Major Body Parts	Section 1.6	True Movement of a Body Part versus "Going along for the Ride"
Section 1.3	Joints between Body Parts	Section 1.7	Regions of the Body
Section 1.4	Movement of a Body Part Relative to an Adjacent Body Part		

CHAPTER OBJECTIVES

After completing this chapter, the student should be able to perform the following:

1. Define the key terms of this chapter and state the meanings of the word origins of this chapter.
2. List the major divisions of the body.
3. List and locate the 11 major parts of the body.
4. Describe the concept of and give an example of movement of a body part.
5. List the aspects of and give an example of fully naming a movement of the body.
6. Describe the concept of and give an example of movement of smaller body parts located within larger (major) body parts.
7. Explain the difference between and give an example of true movement of a body part compared with "going along for the ride."
8. List and locate the major regions of the body.

OVERVIEW

The human body is composed of 11 major parts that are located within the axial and appendicular portions of the body. Some of these major body parts have smaller body parts within them. Separating two adjacent body parts from each other

is a joint. True movement of a body part involves movement of that body part relative to another body part at the joint that is located between them.

KEY TERMS

Abdominal (ab-DOM-i-nal)	Brachial (BRAKE-ee-al)
Antebrachial (AN-tee-BRAKE-ee-al)	Carpal (KAR-pal)
Antecubital (an-tee-KYU-bi-tal)	Cervical (SER-vi-kal)
Anterior view (an-TEER-ee-or)	Cranial (KRAY-nee-al)
Appendicular (ap-en-DIK-u-lar)	Crural (KROO-ral)
Arm	Cubital (KYU-bi-tal)
Axial (AK-see-al)	Digital (DIJ-i-tal)
Axillary (AK-sil-err-ee)	Facial
Body part	Femoral (FEM-o-ral)

Foot
Forearm
Gluteal (GLOO-tee-al)
“Going along for the ride”
Hand
Head
Inguinal (ING-gwi-nal)
Interscapular (IN-ter-skap-u-lar)
Joint
Lateral view (LAT-er-al)
Leg
Lower extremity (eks-TREM-i-tee)
Lumbar (LUM-bar)
Mandibular (man-DIB-u-lar)
Neck
Palmar (PAL-mar)

Patellar (pa-TEL-ar)
Pectoral (PEK-to-ral)
Pelvis
Plantar (PLAN-tar)
Popliteal (pop-LIT-ee-al)
Posterior view (pos-TEER-ee-or)
Pubic (PYU-bik)
Sacral (SAY-kral)
Scapular (SKAP-u-lar)
Shoulder girdle
Supraclavicular (SUE-pra-kla-VIK-u-lar)
Sural (SOO-ral)
Thigh
Thoracic (tho-RAS-ik)
Trunk
Upper extremity (eks-TREM-i-tee)

WORD ORIGINS

- Ante—From Latin *ante*, meaning *before, in front of*
- Append—From Latin *appendo*, meaning *to hang something onto something*
- Ax—From Latin *axis*, meaning *a straight line*
- Fore—From Old English *fore*, meaning *before, in front of*
- Inter—From Latin *inter*, meaning *between*
- Lat—From Latin *latus*, meaning *side*
- Post—From Latin *post*, meaning *behind, in the rear, after*
- Supra—From Latin *supra*, meaning *on the upper side, above*

SECTION 1.1 MAJOR DIVISIONS OF THE HUMAN BODY

- The human body can be divided into two major sections (Figure 1-1):
 - The **axial** body
 - The **appendicular** body¹
- When we learn how to name the location of a structure of the body or a point on the body (see Chapter 2), it will be crucial that we understand the difference between the axial body and the appendicular body.

AXIAL BODY

- The axial body is the central core axis of the body and contains the following body parts:
 - Head
 - Neck
 - Trunk

APPENDICULAR BODY

- The appendicular body is made up of appendages that are “added onto” the axial body.
- The appendicular body can be divided into the right and left upper extremities and the right and left lower extremities.

- An **upper extremity** contains the following body parts:
 - **Shoulder girdle** (scapula and clavicle)
 - Arm
 - Forearm
 - Hand²
- A **lower extremity** contains the following body parts:
 - **Pelvis** (pelvic girdle)
 - Thigh
 - Leg
 - Foot²
- The pelvis is often considered to be part of the axial body. In actuality, it is a transitional body part of both the axial body and the appendicular body³; the sacrum and coccyx are axial body bones and the pelvic bones are appendicular body bones. For symmetry, we will consider the pelvis to be part of the lower extremity (therefore the appendicular body), because the shoulder girdle is part of the upper extremity. Note: The word *girdle* is used because the pelvic and shoulder girdles resemble a girdle in that they encircle the body as a girdle does (actually, the shoulder girdle does not completely encircle the body because the two scapulae do not meet in back).

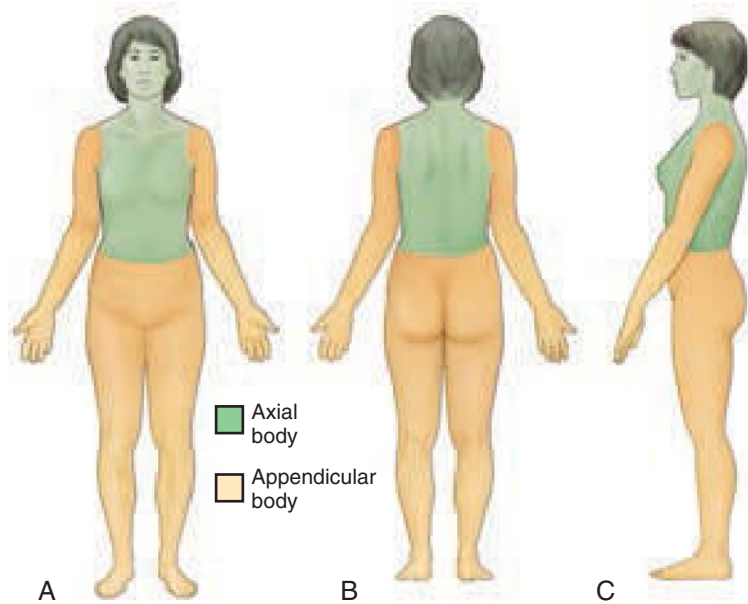


FIGURE 1-1 The major divisions of the human body: the axial body and the appendicular body. **A**, Anterior view. **B**, Posterior view. **C**, Lateral view.

SECTION 1.2 MAJOR BODY PARTS

- A **body part** is a part of the body that can move independently of another body part that is next to it.
- Generally it is the presence of a bone (sometimes more than one bone) within a body part that defines the body part.
- For example, the humerus defines the arm; the radius and ulna define the forearm.
- The human body has 11 major body parts (Figure 1-2):

○ Head	}	Axial body	}	Appendicular body
○ Neck				
○ Trunk				
○ Pelvis	}	Lower extremity		
○ Thigh				
○ Leg				
○ Foot	}	Upper extremity		
○ Shoulder girdle				
○ Arm				
○ Forearm				
○ Hand				
- It is important to distinguish the thigh from the leg. The thigh is between the hip joint and the knee joint, whereas the leg is between the knee joint and the ankle joint.⁴ In our terminology, the thigh is not part of the leg.
- It is important to distinguish the arm from the forearm. The arm is between the shoulder joint and the elbow joint, whereas the forearm is between the elbow joint and the wrist joint. In our terminology, the forearm is not part of the arm.
- The shoulder girdle contains the scapulae and the clavicles.⁴
 - Most sources include the sternum as part of the shoulder girdle.
 - The shoulder girdle is also known as the *pectoral girdle*.
- The pelvis as a body part includes the pelvic girdle of bones.
 - The pelvic girdle contains the two pelvic bones, the sacrum, and the coccyx.⁴

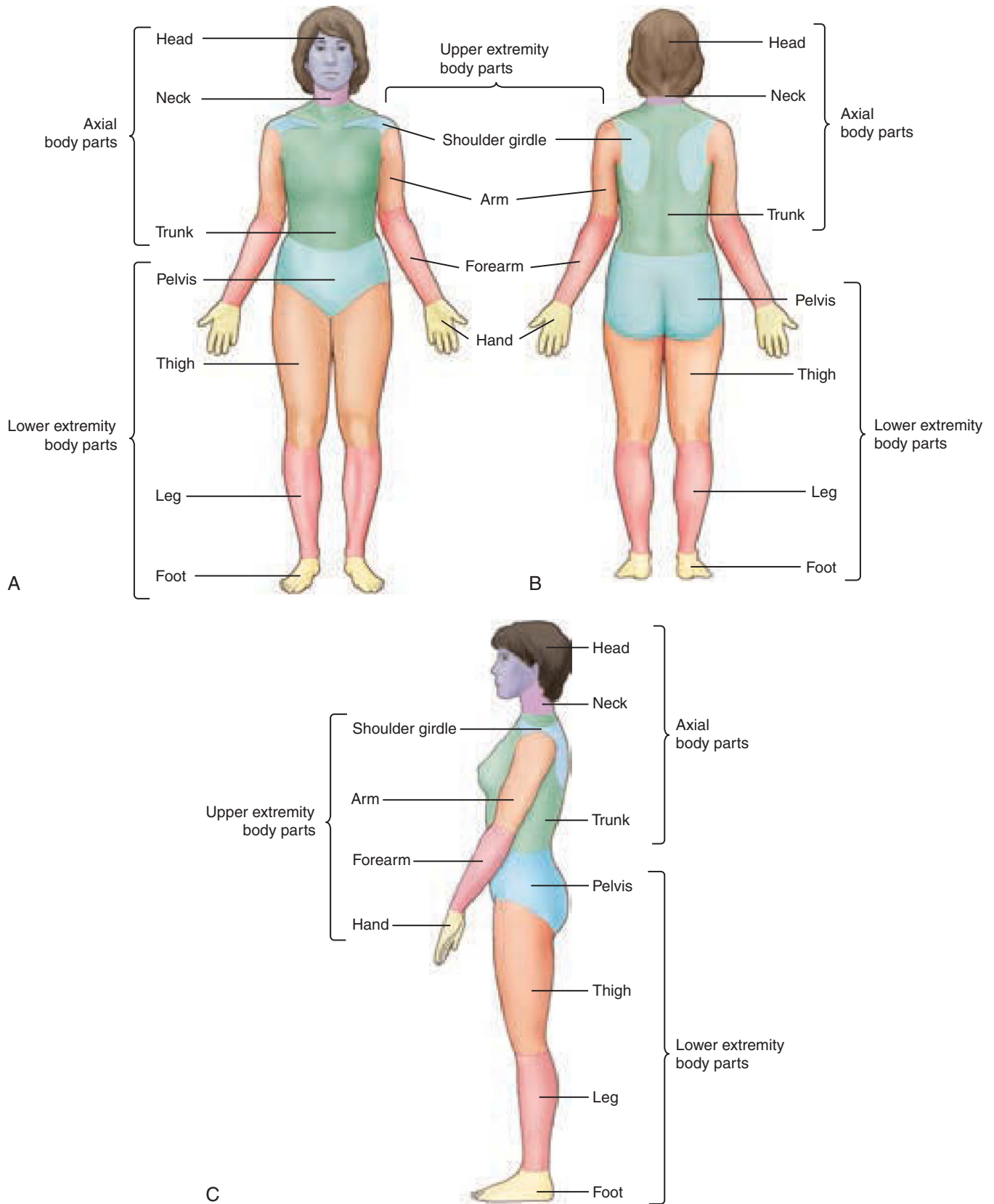


FIGURE 1-2 The 11 major parts of the human body. **A**, Anterior view. **B**, Posterior view. **C**, Lateral view. Note: The body parts indicated in this figure are key terms of this chapter.

SECTION 1.3 JOINTS BETWEEN BODY PARTS

- What separates one body part from the body part next to it is the presence of a **joint** between the bones of the body parts. A joint is located between two adjacent body parts (Figure 1-3).³
- When we say that a body part moves, our general rule will be that the body part moves relative to an adjacent body part.
- This movement occurs at the joint that is located between these two body parts (Figure 1-4).

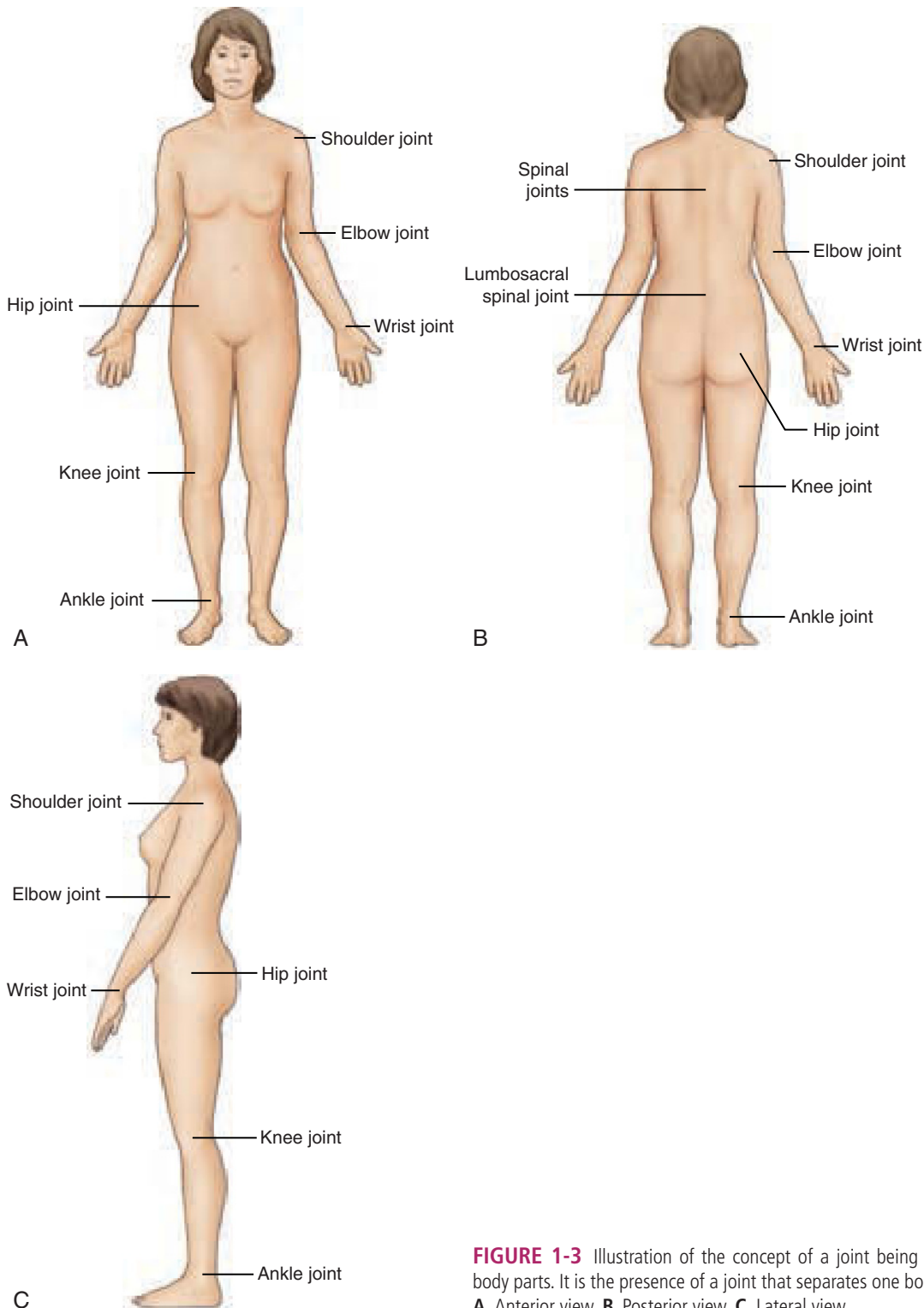
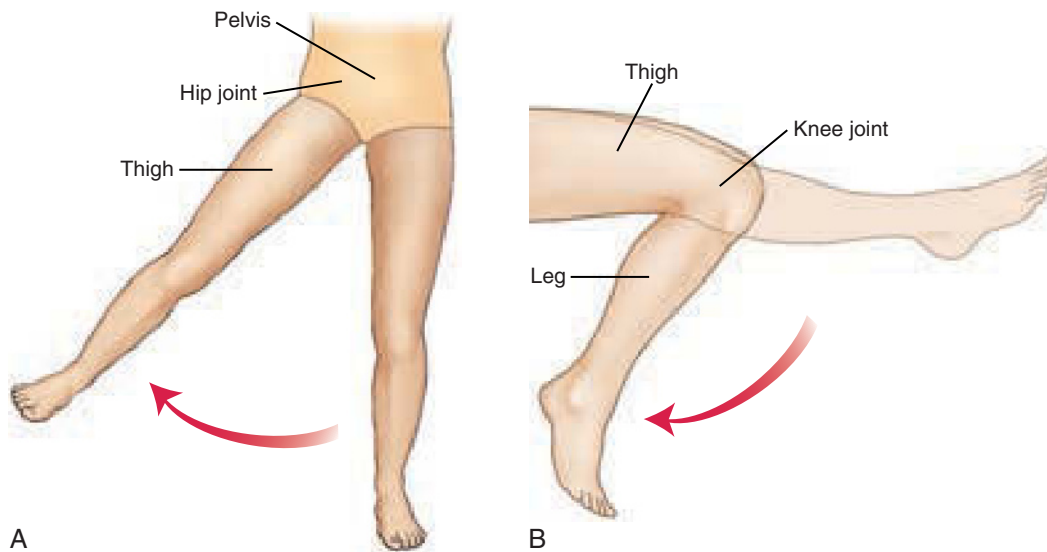


FIGURE 1-3 Illustration of the concept of a joint being located between two adjacent body parts. It is the presence of a joint that separates one body part from another body part. **A**, Anterior view. **B**, Posterior view. **C**, Lateral view.



A

B

FIGURE 1-4 **A**, The thigh moving (abducting) relative to the pelvis. This motion is occurring at the hip joint, which is located between them. **B**, Leg moving (flexing) relative to the thigh. This motion is occurring at the knee joint, which is located between them.

SECTION 1.4 MOVEMENT OF A BODY PART RELATIVE TO AN ADJACENT BODY PART

- When movement of our body occurs, we see the following:
 - It is a body part that is moving.
 - That movement is occurring at a joint that is located between that body part and an adjacent body part.⁵
- To name this movement properly and fully, two things must be stated:
 1. The name of the body part that is moving
 2. The joint where the movement is occurring⁵
- Most texts describe a movement of the body by stating only the body part that is moving or by stating only the joint where the motion is occurring. However, to be complete and to fully describe and understand what is happening, both aspects should be stated. By doing this every time you describe a movement of the body, you will gain a better visual picture and understanding of the movement that is occurring.
- Figures 1-5, 1-6, and 1-7 show examples of movements of body parts relative to adjacent body parts.

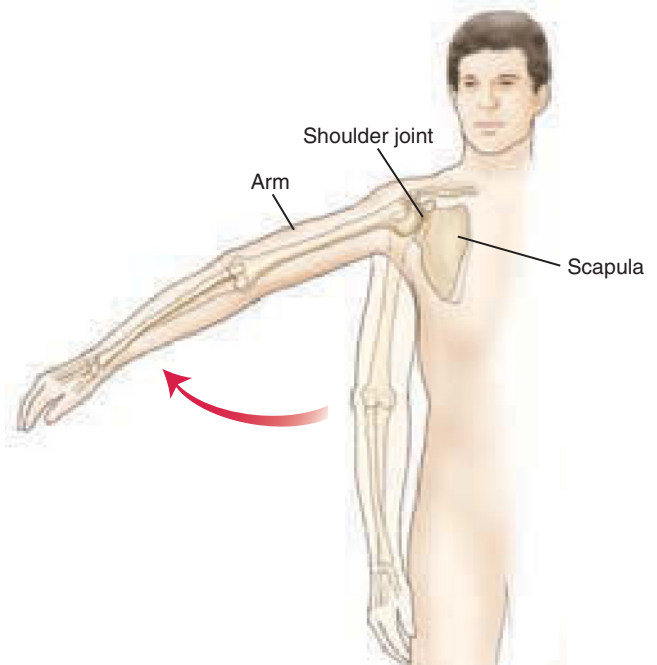


FIGURE 1-5 Illustration of a body movement. The body part that is moving is the arm, and the joint where this movement is occurring is the shoulder joint. We say that the arm is moving (abducting) at the shoulder joint. This motion of the arm occurs relative to the body part that is next to it (i.e., the shoulder girdle; more specifically, the scapula of the shoulder girdle).

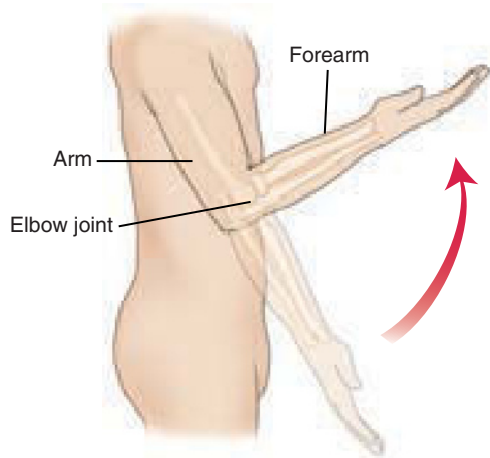


FIGURE 1-6 Illustration of a body movement. The body part that is moving is the forearm, and the joint where this movement is occurring is the elbow joint. We say that the forearm is moving (flexing) at the elbow joint. This motion of the forearm occurs relative to the body part that is next to it (i.e., the arm).

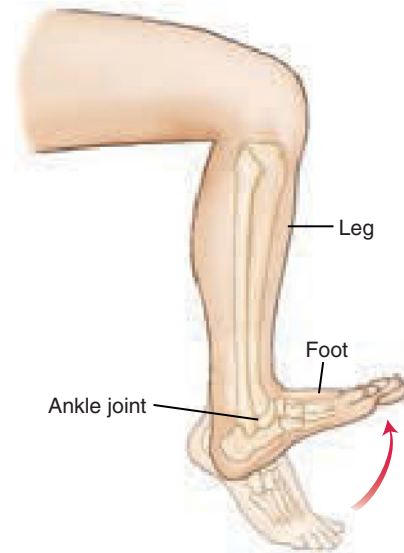

FIGURE 1-7 Illustration of a body movement. The body part that is moving is the foot, and the joint where this movement is occurring is the ankle joint. We say that the foot is moving (dorsiflexing) at the ankle joint. This motion of the foot occurs relative to the body part that is next to it (i.e., the leg).

SECTION 1.5 MOVEMENT WITHIN A BODY PART

- We have seen that when a major body part moves, the movement occurs at the joint that is located between that body part and an adjacent body part.
- Because that joint is located between two different major body parts, when one body part moves relative to another body part, it can be said that the movement occurs *between* body parts.
- However, sometimes movement can occur *within* a major body part.
- This can occur whenever the major body part has two or more smaller body parts (i.e., bones) located within it. When this sit-

uation exists, movement can occur at the joint that is located between these smaller body parts (i.e., bones) within the major body part.⁵

- The simplest example of this is the hand. The hand is considered to be a major body part, and motion of the hand is described as occurring between it and the forearm at the wrist joint (Figure 1-8, A). However, the hand has other body parts, the fingers, within it. Each finger is a body part in its own right, because a finger can move relative to the palm of the hand (Figure 1-8, B). Furthermore, each finger has three

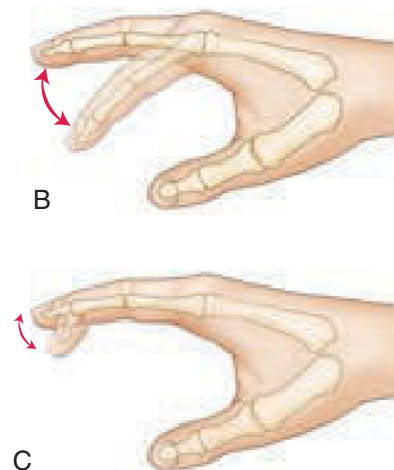
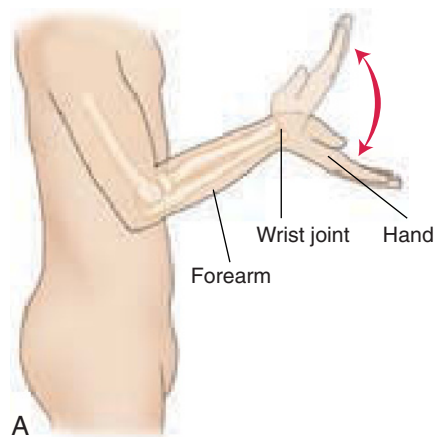


FIGURE 1-8 **A**, Lateral view showing the hand moving relative to the forearm at the wrist joint. **B**, Depiction of motion within the hand. This is a lateral view in which we see a finger moving relative to the palm of the hand at the joint that is located between them. **C**, Illustration of movement of one part of a finger relative to another part of the finger at the joint that is located between them. Note: **B** and **C** both illustrate the concept of movement occurring within a major body part because smaller body parts are within it.

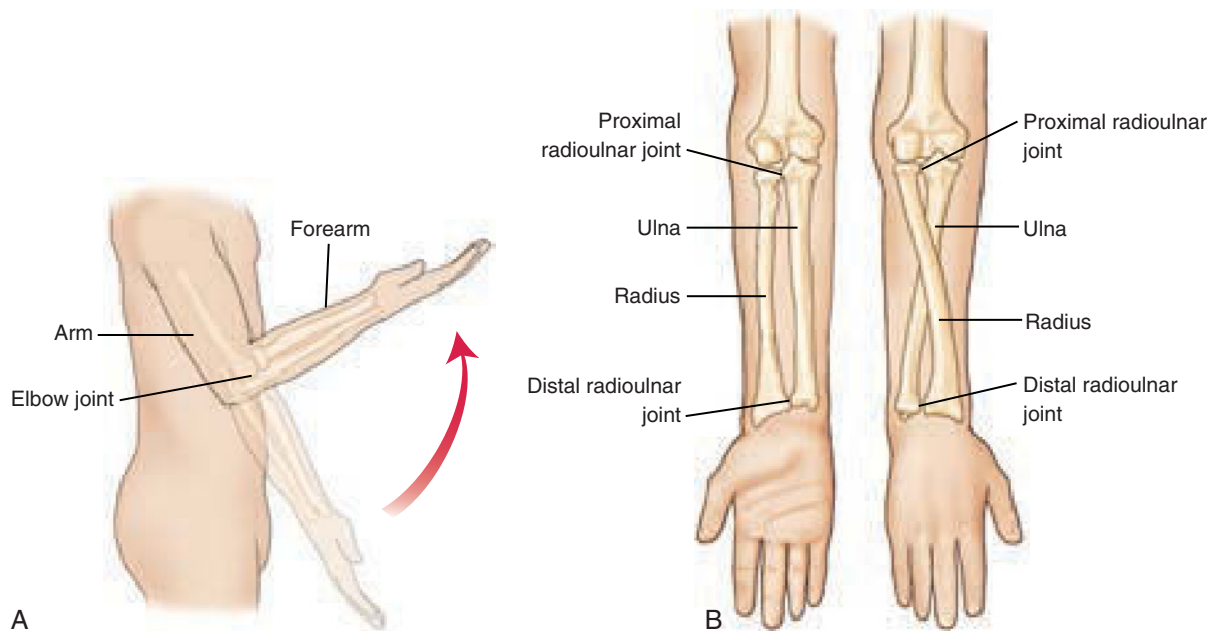


FIGURE 1-9 **A**, Lateral view showing the forearm moving (flexing) relative to the arm at the elbow joint. **B**, Movement of one of the bones (i.e., the radius) within the forearm, relative to the other bone (i.e., the ulna) of the forearm; this motion occurs at the radioulnar joints located between the two bones.

separate parts (i.e., bones) within it, and each of these parts can move independently as well (Figure 1-8, C).

- A second example is the forearm. The forearm is usually described as moving relative to the arm at the elbow joint (Figure 1-9, A). However, the forearm has two bones within it, and joints are located between these two bones. Motion of one of these bones can occur relative to the other (Figure 1-9, B). In this case each one of the two bones would be considered to be a separate, smaller body part.
- A third, more complicated example is the cervical spine. The cervical spine has seven vertebrae within it. The neck may be described as moving relative to the trunk that is beneath it (Figure 1-10, A). However, each one of the seven vertebrae can move independently. Therefore motion can occur between vertebrae within the neck at the joints located between the vertebrae (Figure 1-10, B).

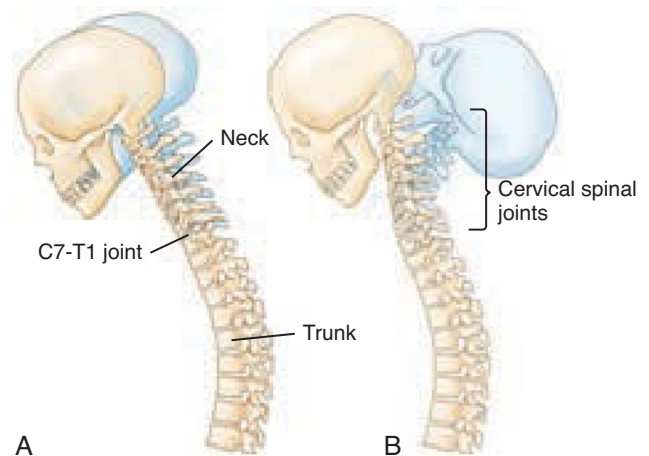


FIGURE 1-10 **A**, Lateral view of the neck showing the neck moving relative to the trunk at the spinal joint between them (C7-T1). **B**, Motion within the neck that is occurring between several individual vertebrae of the neck. This motion occurs at the spinal joints located between these bones.

SECTION 1.6 TRUE MOVEMENT OF A BODY PART VERSUS “GOING ALONG FOR THE RIDE”

- In lay terms, when we say that a body part has moved, it does not always mean that true movement of that body part has occurred (according to the terminology that is used in the musculoskeletal field for describing joint movements).
- A distinction must be made between *true movement of a body part* and what we will call “going along for the ride.”
- For true movement of a body part to occur, the body part must move relative to an adjacent body part (or the body part must have movement occur within it).
- For example, in Figure 1-11 we see that a person is moving the right upper extremity.

- In lay terms, we might say that the person's right hand is moving because it is changing its position in space.
- However, in our terminology the right hand is not moving, because the position of the hand relative to the forearm is not changing (i.e., the right hand is not moving relative to the forearm [and motion is not occurring within the hand]).

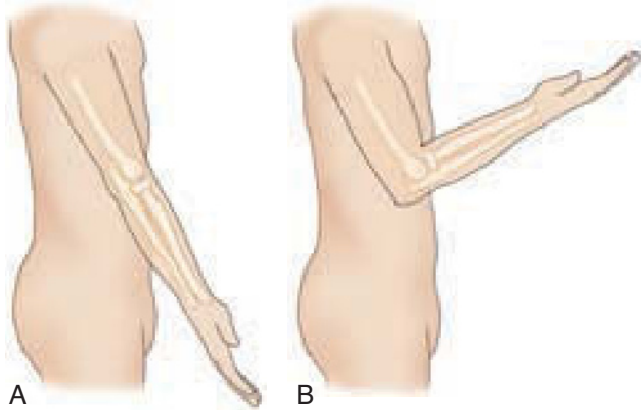


FIGURE 1-11 **A** and **B**, Illustration of the concept that the forearm is moving (because its position relative to the arm is changing). The motion that is occurring here is flexion of the forearm at the elbow joint. The hand is not moving, because its position relative to the forearm is not changing; the hand is merely “going along for the ride.”

- The movement that is occurring in Figure 1-11 is flexion of the forearm at the elbow joint. It is the forearm that is moving relative to the arm at the elbow joint.
- The hand is not moving in this scenario. We could say that the hand is merely “going along for the ride.”
- Figure 1-12 depicts true movement of the hand relative to the forearm.

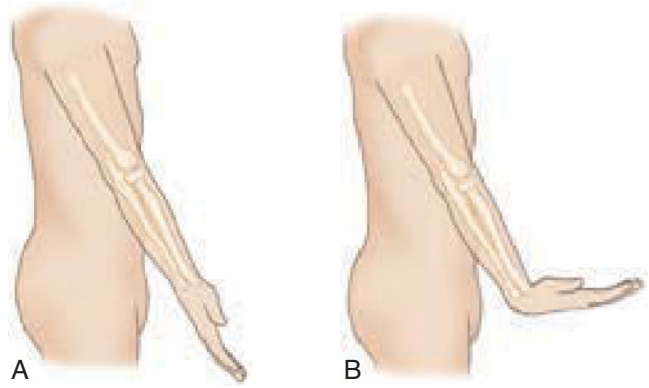


FIGURE 1-12 Illustration of true movement of the hand, because the position of the hand is changing relative to the forearm. This movement is called flexion of the hand at the wrist joint. **A**, Neutral (anatomic) position. **B**, Flexed position.

SECTION 1.7 REGIONS OF THE BODY

- Within the human body, areas or regions exist that are given names. Sometimes these regions are located within a body part; sometimes they are located across two or more body parts.

Following are illustrations that show the various regions of the body (Figure 1-13).⁶

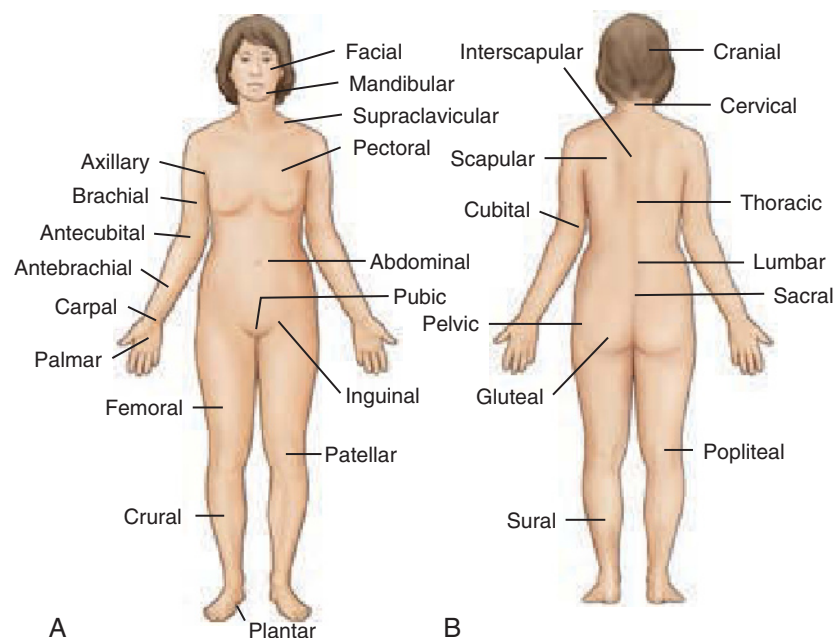


FIGURE 1-13 **A**, Anterior view of the body illustrating its major regions. **B**, Posterior view of the body illustrating its major regions. Note: The body regions indicated in this figure are key terms of this chapter.

REVIEW QUESTIONS

evolve Answers to the following review questions appear on the Evolve website accompanying this book at: <http://evolve.elsevier.com/Muscolino/kinesiology/>.

1. What are the two major divisions of the human body?

2. What are the 11 major body parts of the human body?

3. What defines a body part?

4. What is the difference between the thigh and the leg?

5. What is the difference between the arm and the forearm?

6. What is the difference between the trunk and the pelvis?

7. What two things are stated to describe properly and fully a movement of the body?

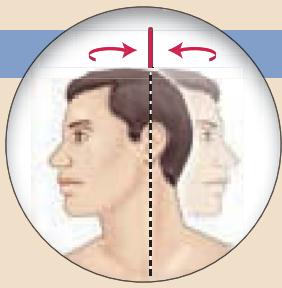
8. How can movement occur within a body part?

9. What is the difference between *true movement* and "going along for the ride"?

10. Name five regions of the human body.

REFERENCES

1. Thibodeau GA, Paton KT: Anatomy & physiology, ed 5, St Louis, 2003, Mosby.
2. Watkins J: Structure and function of the musculoskeletal system, Champaign, Ill, 1999, Human Kinetics.
3. Neumann DA: Kinesiology of the musculoskeletal system: Foundations for physical rehabilitation, ed 3, St Louis, 2017, Elsevier.
4. Drake RL, Vogl W, Mitchell AWM: Gray's anatomy for students, Philadelphia, 2005, Churchill Livingstone.
5. Hamilton N, Weimar W, Luttgens K: Kinesiology: Scientific basis of human motion, ed 12, New York, 2012, McGraw Hill.
6. Dail NW, Agnew TA, Floyd RT: Kinesiology for manual therapies, New York, 2011, McGraw Hill.



CHAPTER 2

Mapping the Human Body

CHAPTER OUTLINE

Section 2.1	Anatomic Position	Section 2.8	Planes
Section 2.2	Location Terminology	Section 2.9	Motion of the Human Body within Planes
Section 2.3	Anterior/Posterior	Section 2.10	Axes
Section 2.4	Medial/Lateral	Section 2.11	Planes and Their Corresponding Axes
Section 2.5	Superior/Inferior and Proximal/Distal	Section 2.12	Visualizing the Axes—Door Hinge Pin Analogy
Section 2.6	Superficial/Deep	Section 2.13	Visualizing the Axes—Pinwheel Analogy
Section 2.7	Location Terminology Illustration		

CHAPTER OBJECTIVES

After completing this chapter, the student should be able to perform the following:

1. Define the key terms of this chapter and state the meanings of the word origins of this chapter.
2. Describe and explain the importance of anatomic position.
3. Explain how location terminology can be used to map the body.
4. List and apply the following pairs of terms that describe relative location on the human body: anterior/posterior, medial/lateral, superior/inferior, proximal/distal, and superficial/deep.
5. List and apply the following additional pairs of terms that describe relative location on the human body: ventral/dorsal, volar/dorsal, radial/ulnar, tibial/fibular, plantar/dorsal, and palmar/dorsal.
6. List and describe the three cardinal planes and explain the concept of an oblique plane.
7. Explain how motion occurs within a plane, and give an example of motion occurring in each of the three cardinal planes and in an oblique plane.
8. Define what an axis is, and explain how motion can occur relative to an axis.
9. Do the following related to planes and their corresponding axes:
 - List the axes that correspond to each of the three cardinal planes.
 - Determine the axis for an oblique plane.
 - Give an example of motion occurring within each of the three cardinal planes and around each of the three cardinal axes.
10. Draw an analogy between the hinge pin of a door and the pin of a pinwheel to the axis of movement for each of the three cardinal planes.



2-1

OVERVIEW

The field of kinesiology uses directional terms of relative location to describe and communicate the location of a structure of the body or a point on the body. These terms are similar to geographic directional terms such as *north* and *south*, and *east* and *west*. However, instead of mapping the Earth, we use our terms to map the human body. We also need to map the space around the human body by describing the three dimensions or *planes* of space. Understanding the orientation of the planes is extremely important in the field of kinesiology because when the body moves, motion of body parts occurs within these planes. The concept of an axis is then explored, because most body movements are axial movements that occur within a plane and around an axis.

Putting the information that was learned in Chapter 1 together with the information that is presented in Chapter 2, the student will have a clear and fundamental understanding of body movement. That is, when motion of the human body occurs, a body part moves relative to an adjacent body part at the joint that is located between them, and this motion occurs within a plane; and if this motion is an axial movement, then it occurs around an axis. After the bones are studied in more detail in Chapters 3 and 5, the exact terms that are used to describe these movements of body parts are covered in Chapter 6.

KEY TERMS

Anatomic position (an-a-TOM-ik)

Angular movement

Anterior (an-TEER-ee-or)

Anteroposterior axis (an-TEER-o-pos-TEER-ee-or)

Axial movement (AK-see-al)

Axis, pl. axes (AK-sis, AK-seez)

Axis of rotation

Cardinal axis (KAR-di-nal)

Cardinal plane

Circular movement

Coronal plane (ko-RO-nal)

Deep

Distal

Dorsal (DOOR-sal)

Fibular (FIB-u-lar)

Frontal-horizontal axis

Frontal plane

Horizontal plane

Inferior (in-FEER-ee-or)

Lateral

Mechanical axis

Medial (MEE-dee-al)

Mediolateral axis (MEE-dee-o-LAT-er-al)

Midsagittal plane (MID-SAJ-i-tal)

Oblique axis (o-BLEEK)

Oblique plane

Plane

Posterior (pos-TEER-ee-or)

Proximal (PROK-si-mal)

Radial (RAY-dee-al)

Rotary movement

Sagittal-horizontal axis (SAJ-i-tal)

Sagittal plane

Superficial

Superior (sue-PEER-ee-or)

Superoinferior axis (sue-PEER-o-in-FEER-ee-or)

Tibial (TI-bee-al)

Transverse plane

Ulnar (UL-nar)

Ventral (VEN-tral)

Vertical axis

Volar (VO-lar)

WORD ORIGINS

○ Ana—From Latin *ana*, meaning *up*

○ Dors—From Latin *dorsum*, meaning *the back*

○ Infer—From Latin *inferus*, meaning *below, lower*

○ Medial—From Latin *medialis*, meaning *middle*

○ Oblique—From Latin *obliquus*, meaning *slanting*

○ Rota—From Latin *rota*, meaning *wheel*

○ Super—From Latin *superus*, meaning *higher, situated above*

○ Tome—From Latin *tomus*, meaning *a cutting*

○ Trans—From Latin *trans*, meaning *across, to the other side of*

○ Ventr—From Latin *venter*, meaning *belly, stomach*



2-2

SECTION 2.1 ANATOMIC POSITION

- Although the human body can assume an infinite number of positions, one position is used as the reference position for mapping the body. This position is used to name the location of body parts, structures, and points on the body and is called **anatomic position**.¹ In anatomic position the person is standing erect, facing forward, with the arms at the sides, the palms facing forward, and the fingers and thumbs extended (Figure 2-1).²

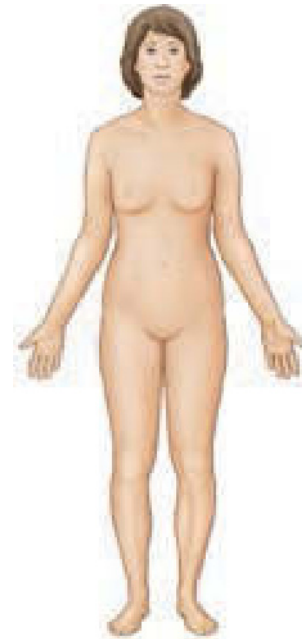


FIGURE 2-1 Anterior view of anatomic position. Anatomic position is the position assumed when a person stands erect, facing forward, with the arms at the sides, the palms facing forward, and the fingers and thumbs extended. Anatomic position is important because it is used as a reference position for naming locations on the human body.

2

SECTION 2.2 LOCATION TERMINOLOGY

NAMING LOCATIONS ON THE HUMAN BODY

- Whenever we want to describe the location of a structure of the human body or the location of a specific point on the human body, we always do so in reference to anatomic position.
- Describing a location on the human body involves the use of specific directional terms that describe the location of one structure or point on the body relative to another structure or point on the body (Box 2-1).
- The reason for specific terminologies like this to exist is that they help us to avoid the ambiguities of lay language. An example of a lay term that is ambiguous and can create confusion and poor communication when describing a location on the human body

is the word *under*. *Under* can mean *inferior*, or it can mean *deep*. Similarly, the word *above* can mean both *superior* and *superficial*. Therefore embracing and using these terms is extremely important in the health field, where someone's health is dependent on clear communication.

- These terms always come in pairs; the terms of each pair are opposite to each other.
- These pairs of terms are similar to the terms *north/south*, *east/west*, and *up/down*. However, our terms specifically relate to directions on the human body.



BOX 2-1 Spotlight on Describing Specific Locations

It is important to emphasize that location terminology is relative. A structure of the human body that is said to be anterior is so named because it is anterior relative to another structure that is more posterior. However, that same anterior structure may be posterior to a third structure that is more anterior than it is. For example, the sternum is anterior to the spine. However, the sternum is posterior to the skin that lies over it. Therefore, depending on which structure we are comparing it with, the sternum may be described as anterior or posterior.



- In essence, we are mapping the human body and using specific terminology to describe points on this map. In the following sections are the pairs of directional terms for naming the relative location of structures or points on the human body.
- Once these pairs of terms for relative location have been learned, they may be combined to describe a structure or point's

location. For example, a point on the body may be both anterior and medial to another point. When these terms are combined, it is customary to drop the end of the first term and combine the two terms together with the letter *o* (e.g., *anterior* and *medial* become *anteromedial*). It is also common practice for the terms *anterior* and *posterior* to come first.

SECTION 2.3 ANTERIOR/POSTERIOR

- **Anterior**—Means *farther to the front*
- **Posterior**—Means *farther to the back*
 - The terms *anterior/posterior* can be used for the entire body (i.e., for the axial and the appendicular body parts).

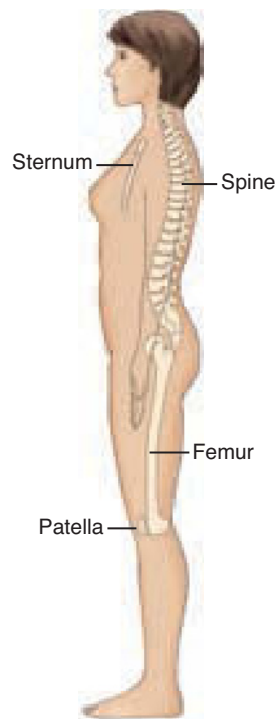


FIGURE 2-2 Lateral view of a person in anatomic position. The sternum is anterior to the spine; conversely, the spine is posterior to the sternum. The patella is anterior to the femur; conversely, the femur is posterior to the patella.

Examples: The sternum is anterior to the spine.
The spine is posterior to the sternum (Figure 2-2).

Examples: The patella is anterior to the femur.
The femur is posterior to the patella (see Figure 2-2).

Notes:

- The terms *ventral/dorsal* are often used synonymously with *anterior/posterior*.
 - **Ventral** essentially means *anterior*.
 - **Dorsal** essentially means *posterior* (Box 2-2).
- The term **volar** is occasionally used in place of anterior for the hand region (*dorsal* is usually used as the opposite term in the pair).³



**BOX
2-2**

Spotlight on Ventral/Dorsal

Each body part has a soft, fleshy surface and a harder, firmer surface. The term *ventral* actually refers to the belly or the softer surface of a body part; the term *dorsal* refers to the back or the harder, firmer surface of a body part. These terms derive evolutionarily from the ventral and dorsal surfaces of a fish. The ventral surfaces of the entire upper extremity and axial body are located anteriorly; the ventral surface of the thigh is medial/posteromedial; the ventral surface of the leg is posterior; and the ventral surface of the foot is the inferior, plantar surface. The dorsal surfaces are on the opposite side of the ventral surfaces.

SECTION 2.4 MEDIAL/LATERAL

- **Medial**—Means *closer to an imaginary line that divides the body into left and right halves* (Figure 2-3). (Note: This imaginary line that divides the body into left and right halves is the *midsagittal plane*; see Section 2.8.)
- **Lateral**—Means *farther from an imaginary line that divides the body into left and right halves* (i.e., more to the left side or the right side).
 - The terms *medial/lateral* can be used for the entire body (i.e., for the axial and the appendicular body parts).

Examples: The sternum is medial to the humerus.
The humerus is lateral to the sternum (see Figure 2-3).

Examples: The little finger is medial to the thumb.
The thumb is lateral to the little finger (see Figure 2-3).

Notes:

- In the forearm and hand, the terms *ulnar/radial* can be used instead of *medial/lateral*. **Ulnar** means *closer to the ulna*, which is more medial. **Radial** means *closer to the radius*, which is more lateral.
- In the leg, the terms *tibial/fibular* can be used instead of *medial/lateral*. **Tibial** means *closer to the tibia*, which is more medial. **Fibular** means *closer to the fibula*, which is more lateral.³

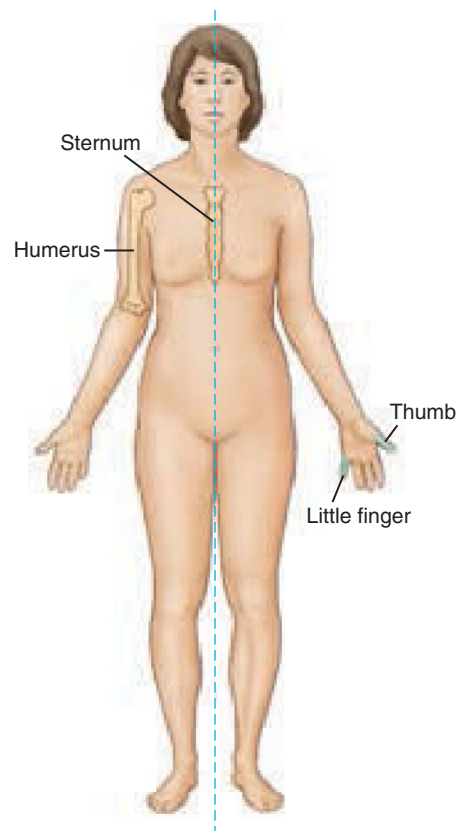


FIGURE 2-3 Anterior view of a person in anatomic position. The midline of the body, which is most medial in location, is represented by the vertical dashed line that divides the body into left and right halves. The sternum is medial to the humerus; conversely, the humerus is lateral to the sternum. The little finger is medial to the thumb; conversely, the thumb is lateral to the little finger.

SECTION 2.5 SUPERIOR/INFERIOR AND PROXIMAL/DISTAL

2

- **Superior**—Means *above*
- **Inferior**—Means *below*
- The terms *superior/inferior* are used for the axial body parts only.

Examples: The head is superior to the trunk.
The trunk is inferior to the head (Figure 2-4, A).

Examples: The sternum is superior to the umbilicus.
The umbilicus is inferior to the sternum (see Figure 2-4, A).

Note:

- Although most sources apply these terms only to the axial body, some sources use these terms for the appendicular body as well.
- **Proximal**—Means *closer* (i.e., greater proximity) *to the axial body*
- **Distal**—Means *farther* (i.e., more distant) *from the axial body*
- The terms *proximal/distal* are used for the appendicular body parts only.³

Examples: The arm is proximal to the forearm.
The forearm is distal to the arm (Figure 2-4, B).

Examples: The thigh is proximal to the leg.
The leg is distal to the thigh (see Figure 2-4, B).

Note regarding the use of superior/inferior versus proximal/distal:

- Given that the terms *superior/inferior* are used on the axial body and are not used on the appendicular body, and the terms *proximal/distal* are used on the appendicular body and are not used on the axial body, a dilemma arises when we look to compare the relative location of a point that is on an extremity with a point that is on the axial body. For example, the psoas major muscle attaches from the trunk to the thigh. How would one describe its attachments? It is convention to use either one pair of terms or the other but not to mix the two pairs of terms. In other words, you could describe the attachments of this muscle as being *superior and inferior*, or you could describe them as being *proximal and distal*. Do not mix these terms and describe the attachments as superior and distal, or proximal and inferior. The terms *proximal/distal* are more commonly used.

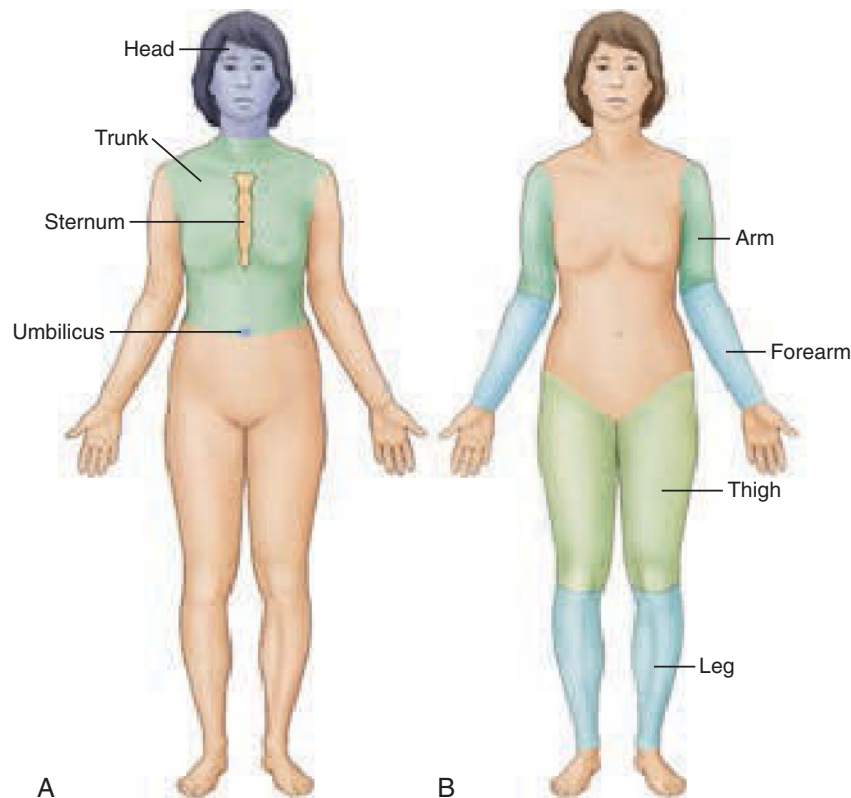


FIGURE 2-4 Anterior views of a person in anatomic position. **A**, The head is superior to the trunk; conversely, the trunk is inferior to the head. In addition, the sternum is superior to the umbilicus; conversely, the umbilicus is inferior to the sternum. **B**, The arm is proximal to the forearm; conversely, the forearm is distal to the arm. In addition, the thigh is proximal to the leg; conversely, the leg is distal to the thigh.

SECTION 2.6 SUPERFICIAL/DEEP

- **Superficial**—Means *closer to the surface of the body*
- **Deep**—Means *farther from the surface of the body* (i.e., more internal or deep)
 - The terms *superficial/deep* can be used for the entire body (i.e., for the axial and the appendicular body parts).³

Examples: The anterior abdominal wall muscles are superficial to the intestines.

The intestines are deep to the anterior abdominal wall muscles (Figure 2-5).

Examples: The biceps brachii muscle is superficial to the humerus (arm bone).

The humerus is deep to the biceps brachii muscle (see Figure 2-5).

Note:

- Whenever designating a structure of the human body as superficial or deep, it is important to state the perspective from which one is looking at the body. This is important because one structure

may be deep to another structure from one perspective but not deep to it from another perspective. An example is the brachialis muscle of the arm. The brachialis is usually thought of as deep to the biceps brachii muscle because from the anterior perspective the brachialis is deep to it. As a result, many bodyworkers do not realize that the brachialis is superficial (deep only to the skin) and easily accessible and palpable laterally and medially. Furthermore, the deeper a structure is from one perspective of the body, the more superficial it is from the other perspective. An example is the dorsal interossei pedis muscles of the feet. These muscles are considered to be in the deepest plantar layer of musculature of the feet, and viewed from the plantar perspective they are located deep to the plantar interossei muscles. However, from the dorsal perspective, they are superficial to the plantar interossei muscles; and indeed, the dorsal interossei pedis muscles are more accessible and palpable from the dorsal side.

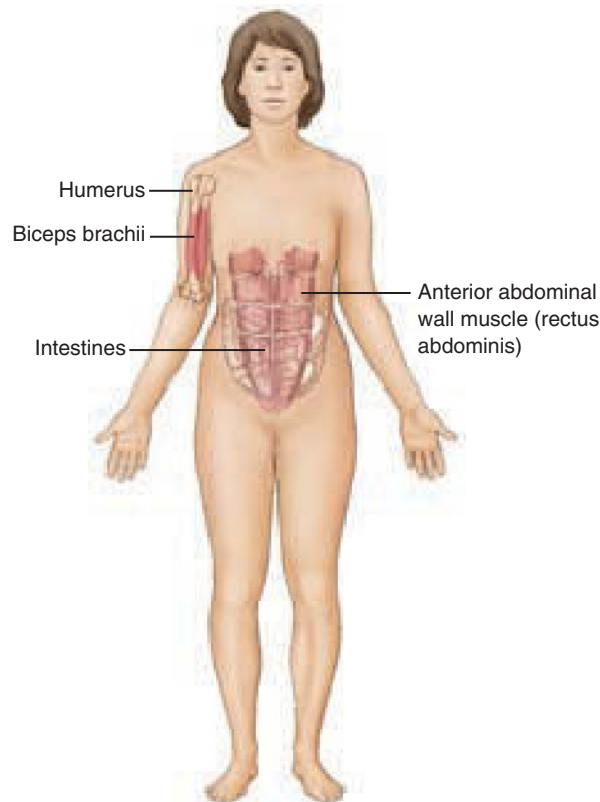


FIGURE 2-5 Anterior view of a person in anatomic position. The anterior perspective shows that the rectus abdominis muscle of the anterior abdominal wall is superficial to the intestines (located within the abdominopelvic cavity); conversely, the intestines are deep to the rectus abdominis muscle. From the anterior perspective, the biceps brachii muscle is superficial to the humerus; conversely, the humerus is deep to the biceps brachii muscle.

SECTION 2.7 LOCATION TERMINOLOGY ILLUSTRATION

2

Figure 2-6 is an anterior view of a person, illustrating the terms of relative location as they pertain to the body.

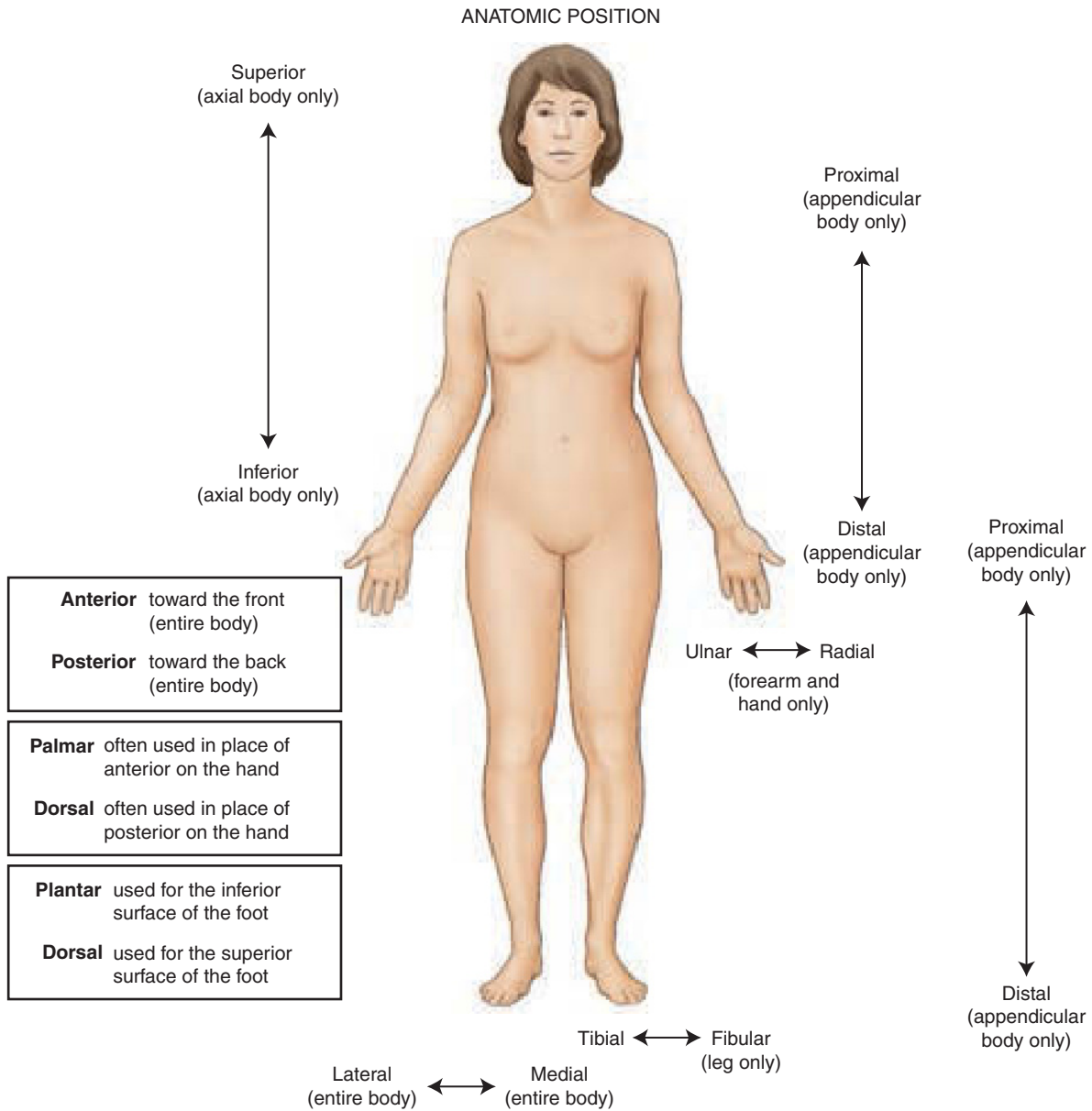


FIGURE 2-6 Various directional terms of location relative to anatomic position.



2-3

SECTION 2.8 PLANES

2

All too often, planes are presented in textbooks with an illustration and a one-line definition for each one. Consequently, students often memorize them with a weak understanding of what they really are and their importance. Because a clear and thorough understanding of planes greatly facilitates learning and understanding the motions caused by muscular contractions, the following is presented.

- We have already mapped the human body to describe the location of structures and/or points of the body.
- However, when we want to describe motion of the human body, we need to describe or map the space through which motion occurs.
- As we all know, space is three-dimensional (3-D); therefore to map space we need to describe its three dimensions.
- We describe each one of these dimensions with a **plane**. Because three dimensions exist, three types of planes exist.
- The word *plane* actually means a *flat surface*. Each of the planes is a flat surface that cuts through space, describing a dimension of space.
- The three major types of planes are called *sagittal*, *frontal*, and *transverse* (Figure 2-7).⁴
- The human body or a part of the body can move in each of these three dimensions or planes:
 - A body part can move in an anterior to posterior (or posterior to anterior) direction. This direction describes the **sagittal plane**.⁴
 - A body part can move in a left to right (or right to left) direction; this could also be described as a medial to lateral (or lateral to medial) direction of movement. This direction describes the **frontal plane**.⁴
 - A body part can stay in place and spin (i.e., rotate). This direction describes the **transverse plane**.⁴

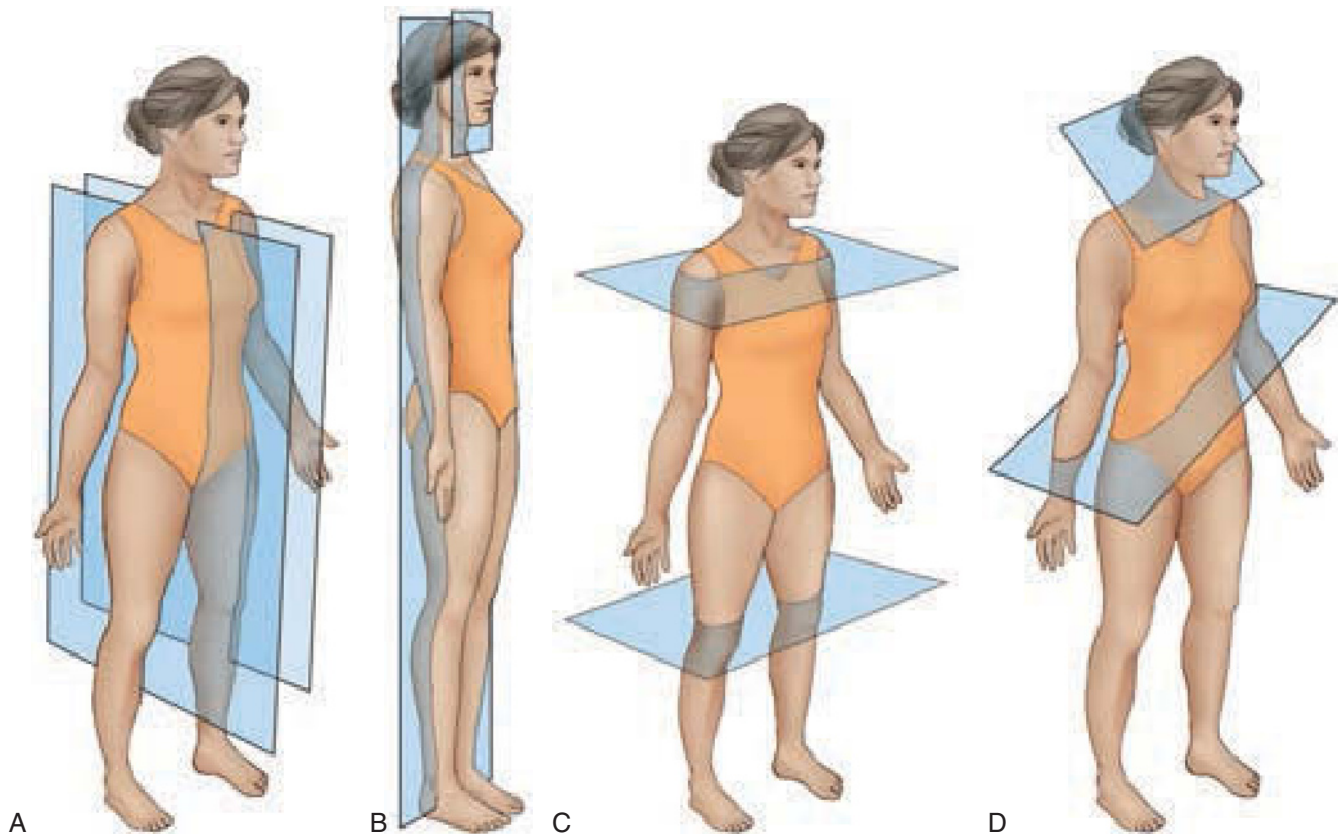


FIGURE 2-7 Anterolateral views of the body, illustrating the four types of planes: sagittal, frontal, transverse, and oblique. **A**, Two examples of sagittal planes; a sagittal plane divides the body into left and right portions. **B**, Two examples of frontal planes; a frontal plane divides the body into anterior and posterior portions. **C**, Two examples of transverse planes; a transverse plane divides the body into upper (superior and/or proximal) and lower (inferior and/or distal) portions. **D**, Two examples of oblique planes; an oblique plane is a plane that is not exactly sagittal, frontal, or transverse (i.e., it has components of two or three cardinal planes). The upper oblique plane has frontal and transverse components; the lower oblique plane has sagittal and transverse components.

- These three major planes are called **cardinal planes** and are defined as follows:
 - A sagittal plane divides the body into left and right portions.
 - The sagittal plane that is located down the center of the body and divides the body wall into equal left and right halves is called the **midsagittal plane**.
 - A frontal plane divides the body into anterior and posterior portions.
 - A transverse plane divides the body into (upper) superior/proximal and (lower) inferior/distal portions.
- Please note the following:
 - These three cardinal planes are defined relative to anatomic position. (This is not to say that motion of the human body

can be initiated only from anatomic position. It only means that these three cardinal planes were originally defined with the body parts in anatomic position.)

- Any plane that is not purely sagittal, frontal, or transverse (i.e., has components of two or three of the cardinal planes) is called an **oblique plane**.⁴
- The sagittal and frontal planes are oriented vertically; the transverse plane is oriented horizontally.
- An infinite number of sagittal, frontal, transverse, and oblique planes are possible.
- The frontal plane is also commonly called the **coronal plane**.
- The transverse plane is also commonly called the **horizontal plane**.

2



2-4

SECTION 2.9 MOTION OF THE HUMAN BODY WITHIN PLANES

- Because an understanding of the planes is an important part of understanding movements of the body, motion of the human body in each of the three planes should be examined. Figure 2-8, A to D, illustrates motion of the body in the sagittal, frontal, and

transverse planes, as well as in an oblique plane, respectively. Figure 2-8, E to H, illustrates additional examples of motions within planes. (For a detailed discussion of the names of these motions, please see Chapter 6, Sections 6.11 through 6.25.)

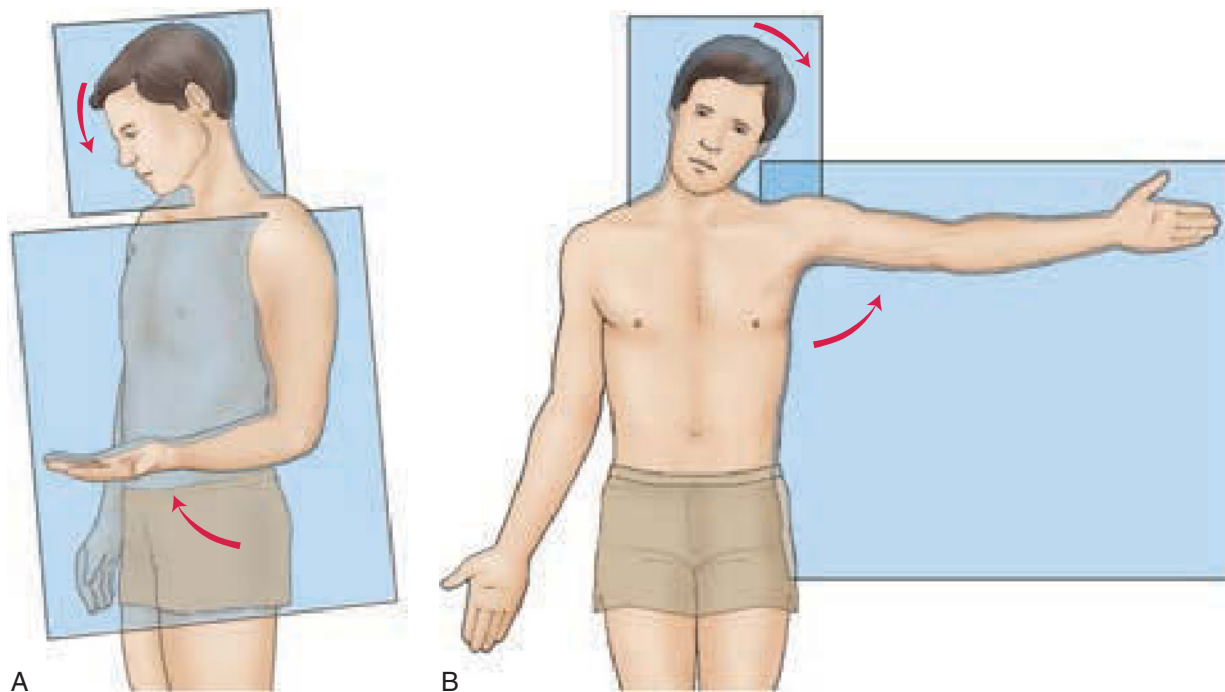


FIGURE 2-8 **A**, Anterolateral view illustrates two examples of the concept of motion of a body part within a sagittal plane. The head and neck are flexing (moving anteriorly) at the spinal joints, and the left forearm is flexing (moving anteriorly) at the elbow joint. **B**, Anterior view illustrates two examples of the concept of motion of a body part within a frontal plane. The head and neck are left laterally flexing (bending to the left side) at the spinal joints, and the left arm is abducting (moving laterally away from the midline) at the shoulder joint.

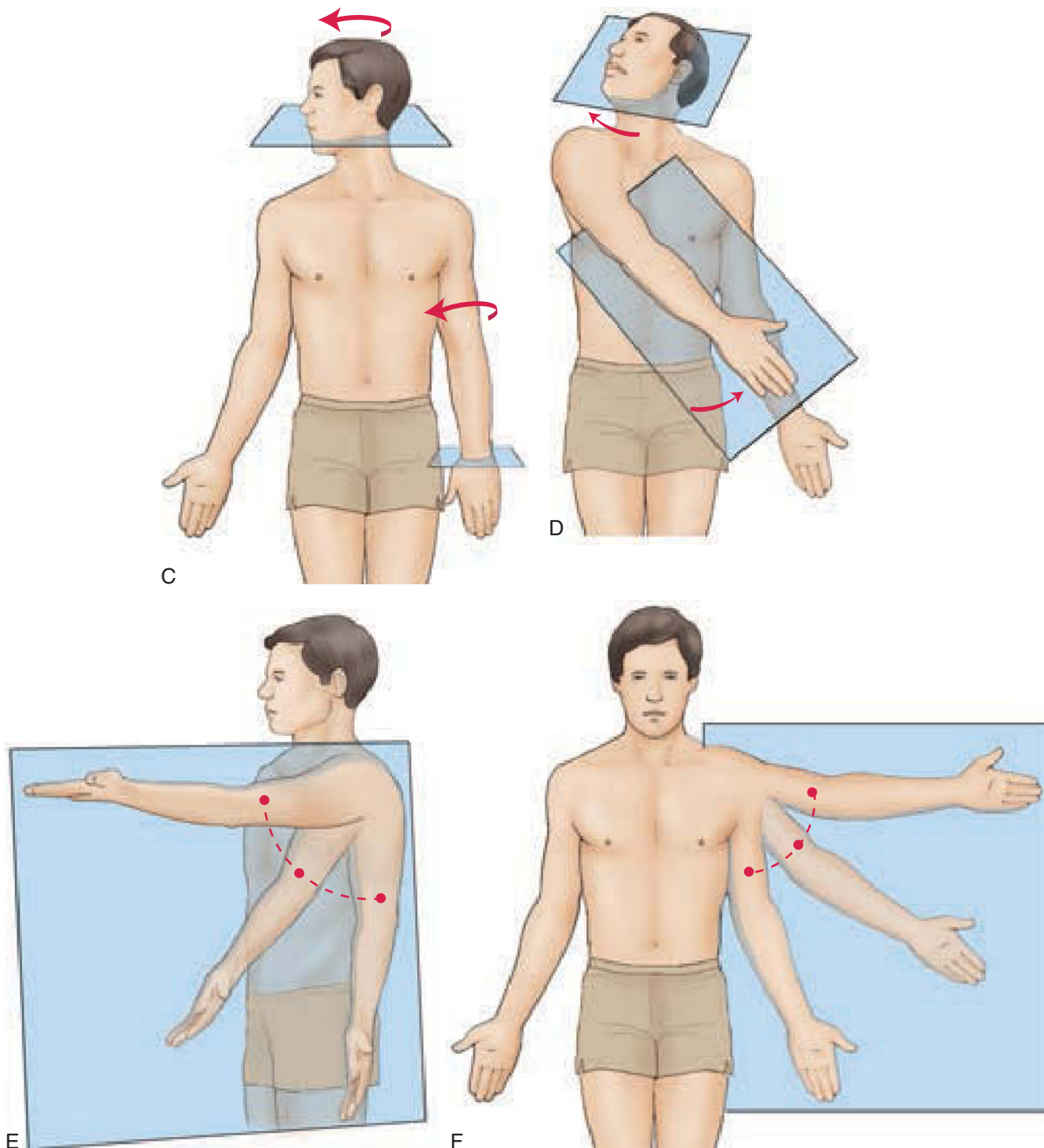


FIGURE 2-8, cont'd **C**, Anterior view illustrates two examples of the concept of motion of a body part within a transverse plane. The head and neck are rotating to the right (twisting/turning to the right) at the spinal joints; and the left arm is medially rotating (rotating toward the midline) at the shoulder joint. **D**, Anterior view illustrates two examples of the concept of motion of a body part within an oblique plane (i.e., a plane that has components of two or three of the cardinal planes). The head and neck are doing a combination of sagittal, frontal, and transverse plane movements (at the spinal joints). These movements are extension (moving posteriorly) in the sagittal plane, left lateral flexion (bending to the left side) in the frontal plane, and right rotation (twisting/turning to the right) in the transverse plane. The right arm is also doing a combination of sagittal, frontal, and transverse plane movements (at the shoulder joint). These movements are flexion (moving anteriorly) in the sagittal plane, adduction (moving medially toward the midline) in the frontal plane, and medial rotation (rotating toward the midline) in the transverse plane. **E to H**, Motion of the arm at the shoulder joint within each of the three cardinal planes and an oblique plane. A point has been drawn on the arm; the arc that is created by the movement of this point has also been drawn (in each case, the arc of motion of this point is within the plane of motion that the body part is moving within, illustrating that motion of a body part occurs within a plane). **E**, An anterolateral view illustrates the left arm flexing (moving anteriorly) at the shoulder joint within a sagittal plane. **F**, Anterior view illustrates the left arm abducting (moving laterally away from the midline) at the shoulder joint within a frontal plane.

Continued

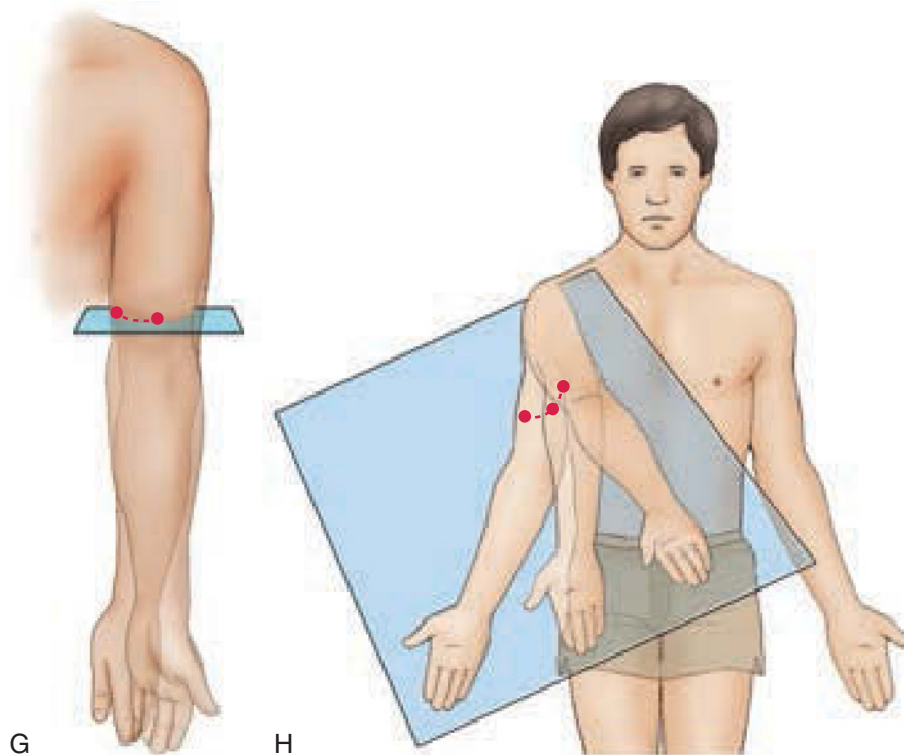


FIGURE 2-8, cont'd **G**, Anterior view illustrates the left arm laterally rotating (rotating away from the midline) at the shoulder joint within a transverse plane. **H**, Anterior view illustrates the right arm making a motion that is a combination of flexion (moving anteriorly) and adduction (moving toward the midline) at the shoulder joint within an oblique plane.



2-5

SECTION 2.10 AXES

- An **axis** (plural: axes) is an imaginary line around which a body part moves.
- An axis is often called a **mechanical axis**.⁵
- Movement around an axis is called **axial movement** (Figure 2-9).
- When a body part moves around an axis, it does so in a circular fashion. For this reason, axial movement is also known as **circular movement**.
- An axial movement can also be called an **angular movement** or a **rotary movement** (Box 2-3).⁵
- The terms *axial movement*, *circular movement*, *angular movement*, and *rotary movement* are all synonyms. The concept of axial movement is visited again and covered in more detail in Chapter 6, Sections 6.5 through 6.7.

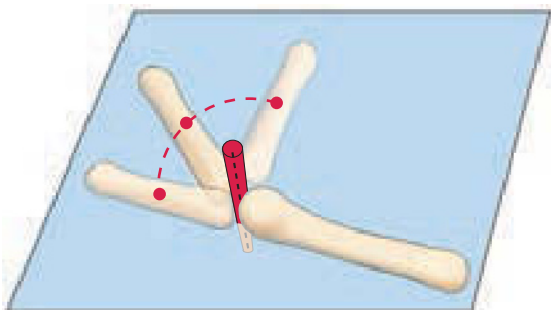


FIGURE 2-9 An axis is an imaginary line around which motion occurs. This figure illustrates the motion of a bone within a plane and around an axis; the axis is drawn in as a red tube. This type of movement is known as an axial movement. A point has been drawn on the bone, and the arc that is transcribed by the motion of this point can be seen to move in a circular path.



BOX 2-3 Spotlight on Axes

Because a body part is often described as rotating around the axis, an axial movement can also be called a rotary movement, or even rotation. Indeed, an axis is often referred to as an axis of rotation. However, referring to axial movements as rotary or rotation movements can be confusing because certain axial movements actually have the word rotation within their name (spin axial movements such as right rotation, left rotation, lateral rotation, medial rotation), whereas other types of axial movement (roll axial movements such as flexion, extension, abduction, adduction) do not. Therefore it is easy to confuse these different types of axial movements with each other. Axial movements (and in particular spin and roll axial movements) are discussed in Chapter 6, Sections 6.7 and 6.8.



2-6

SECTION 2.11 PLANES AND THEIR CORRESPONDING AXES

- When motion of a body part occurs, it can be described as occurring within a plane.
- If the motion is axial, it can be further described as moving around an axis.
- Therefore for each one of the three cardinal planes of the body, a corresponding **cardinal axis** exists; hence three cardinal axes exist (Figure 2-10, A to C).⁶
- For every motion that occurs within an oblique plane, a corresponding **oblique axis** exists (Figure 2-10, D). Therefore an infinite number of oblique axes exist, one for each possible oblique plane.
- Naming an axis is straightforward; simply describe its orientation.
- The three cardinal axes are the mediolateral, anteroposterior, and superoinferior (vertical) axes (see Figure 2-10, A to C).
- Please note that an axis around which motion occurs is always perpendicular to the plane in which the motion is occurring.
- An axial movement of a body part is one in which the body part moves within a plane and around an axis.

MEDIOLATERAL AXIS

- A **mediolateral axis** is a line that runs from medial to lateral (or lateral to medial [i.e., left to right or right to left]) in direction (see Figure 2-10, A).
- Movements that occur in the sagittal plane move around a mediolateral axis.
- The mediolateral axis is also known as the **frontal-horizontal axis** because it runs horizontally and is located within the frontal plane.⁶

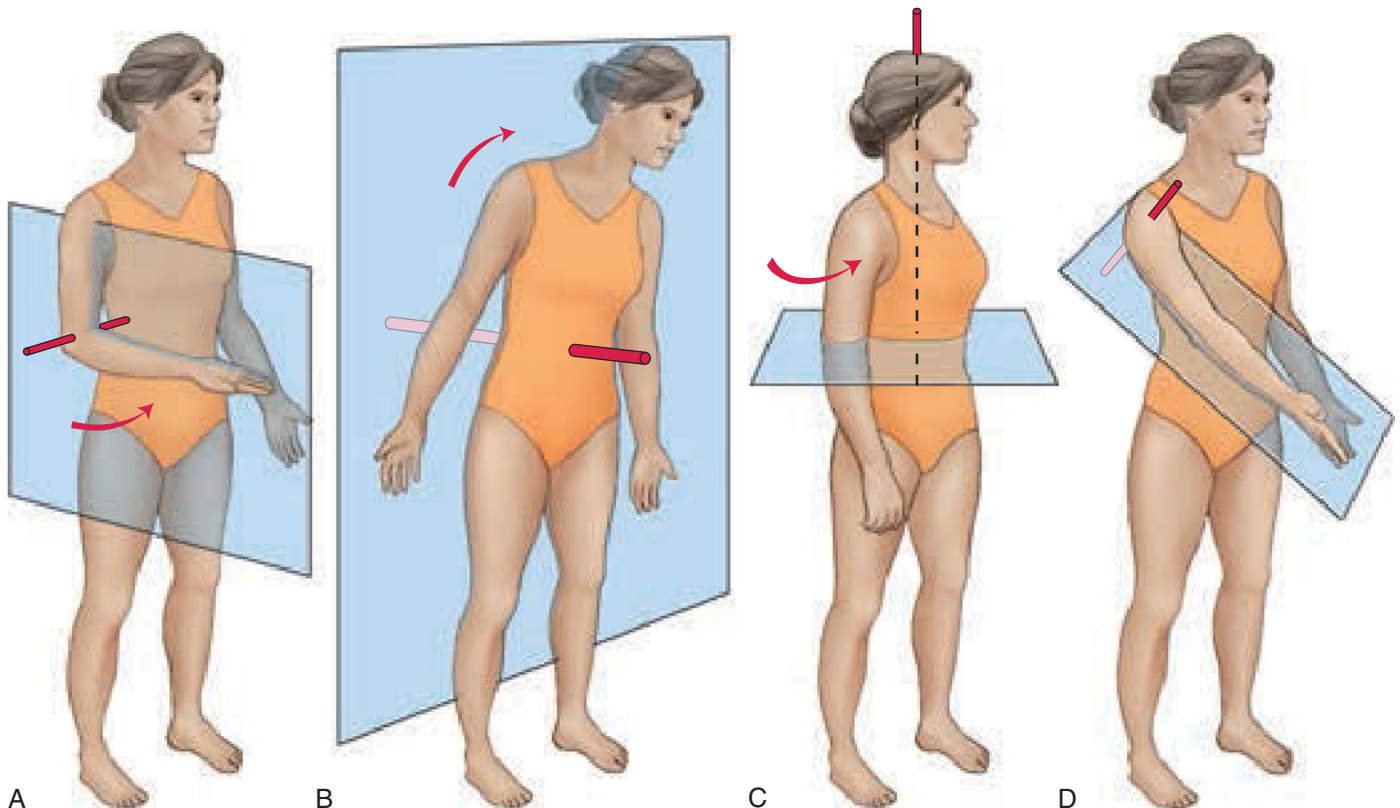


FIGURE 2-10 Anterolateral views that illustrate the corresponding axes for the three cardinal planes and an oblique plane; the axes are shown as red tubes. Note that an axis always runs perpendicular to the plane in which the motion is occurring. **A**, Motion occurring in the sagittal plane; because this motion is occurring around an axis that is running horizontally in a medial to lateral orientation, it is called the mediolateral axis. **B**, Motion occurring in the frontal plane; because this motion is occurring around an axis that is running horizontally in an anterior to posterior orientation, it is called the anteroposterior axis. **C**, Motion occurring in the transverse plane; because this motion is occurring around an axis that is running vertically in a superior to inferior orientation, it is called the superoinferior axis, or, more simply, the vertical axis. **D**, Motion occurring in an oblique plane; this motion is occurring around an axis that is running perpendicular to that plane (i.e., it is the oblique axis for this oblique plane).

ANTEROPOSTERIOR AXIS

- An **anteroposterior axis** is a line that runs anterior to posterior (or posterior to anterior) in direction (see Figure 2-10, B).
- Movements that occur in the frontal plane move around an anteroposterior axis.
- The anteroposterior axis is also known as the **sagittal-horizontal axis** because it runs horizontally and is located within the sagittal plane.⁶

SUPEROINFERIOR AXIS

- A **superoinferior axis** is a line that runs from superior to inferior (or inferior to superior) in direction (see Figure 2-10, C).
- Movements that occur in a transverse plane move around a superoinferior axis.
- The superoinferior axis is more commonly referred to as the **vertical axis** because it runs vertically. (This text will use the term *vertical axis* because it is an easier term for the reader/student to visualize.)⁶

SECTION 2.12 VISUALIZING THE AXES—DOOR HINGE PIN ANALOGY

- To help visualize an axis for motion, the following visual analogy may be helpful. An axis may be thought of as the hinge pin of a door. Just as a body part's motion occurs around its

axis, a door's motion occurs around its hinge pin, which is its axis for motion (Figure 2-11).

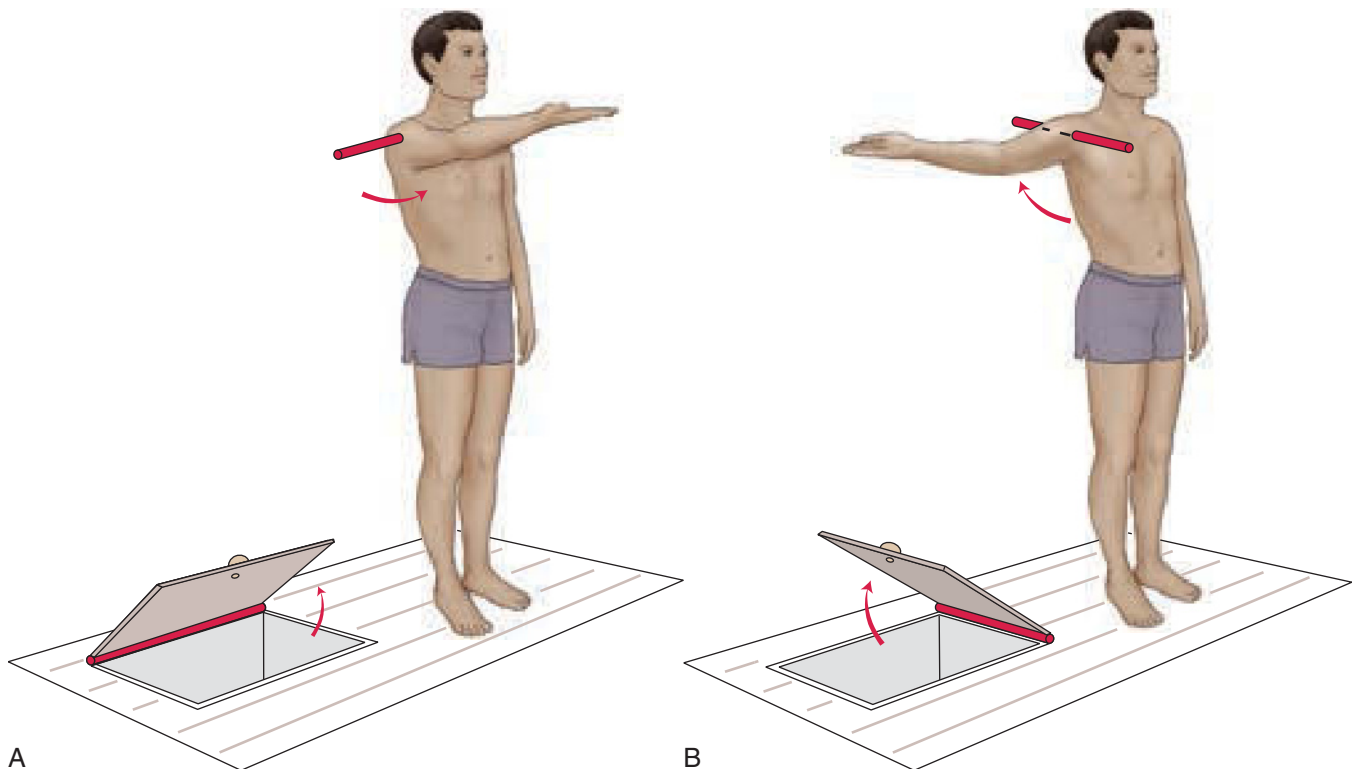


FIGURE 2-11 Anterolateral views that compare the axes of motion for movement of the arm with the axes of motion for a door that is moving (i.e., opening); the axes are drawn in as red tubes. **A**, A trap door in a floor that is moving. The person standing next to the door is moving the arm in the same manner in which the trap door is opening. These movements are occurring in the sagittal plane. If we look at the orientation of the hinge pin of the door, which is its axis of motion, we will see that it is medial to lateral in orientation. Note that the axis for the motion of the person's arm is also medial to lateral in orientation. Hence the axis for sagittal plane motion is mediolateral. **B**, A trap door in a floor that is moving (i.e., opening). The person standing next to the door is moving the arm in the same manner in which the trap door is opening. These movements are occurring in the frontal plane. If we look at the orientation of the hinge pin of the door, which is its axis of motion, we will see that it is anterior to posterior in orientation. Note that the axis for the motion of the person's arm is also anterior to posterior in orientation. Hence the axis for frontal plane motion is anteroposterior.

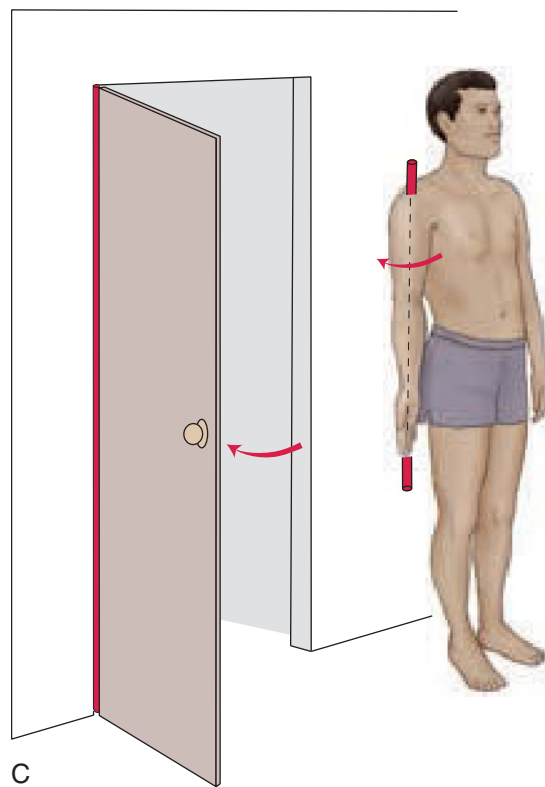


FIGURE 2-11, cont'd C, A door that is moving (i.e., opening). The person standing next to the door is moving the arm in the same manner in which the door is opening. These movements are occurring in the transverse plane. If we look at the orientation of the hinge pin of the door, which is its axis of motion, we will see that it is superior to inferior in orientation (i.e., it is vertical). Note that the axis for the motion of the person's arm is also superior to inferior in orientation. Hence the axis for transverse plane motion is vertical.

SECTION 2.13 VISUALIZING THE AXES—PINWHEEL ANALOGY

2

- Another visual analogy that may be helpful for determining the axis of motion is a pinwheel. When a child blows on a pinwheel, its wheel spins in a plane, and the pin is the axis around which the wheel spins. If you orient the motion of the wheel in any one of the three cardinal planes, then naming the orientation of the pin of the pinwheel will name the axis for that plane's motion (Figure 2-12, A to C).
- The face of a clock is another good example of motion within a plane and around an axis. The hands of the clock move within the plane of the face of the clock. The pin that fastens the arms to the clock face is the axis around which the hands move. If the clock is oriented to be in the sagittal, frontal, or transverse plane relative to your body, then describing the orientation of the pin in each case illustrates the axis.

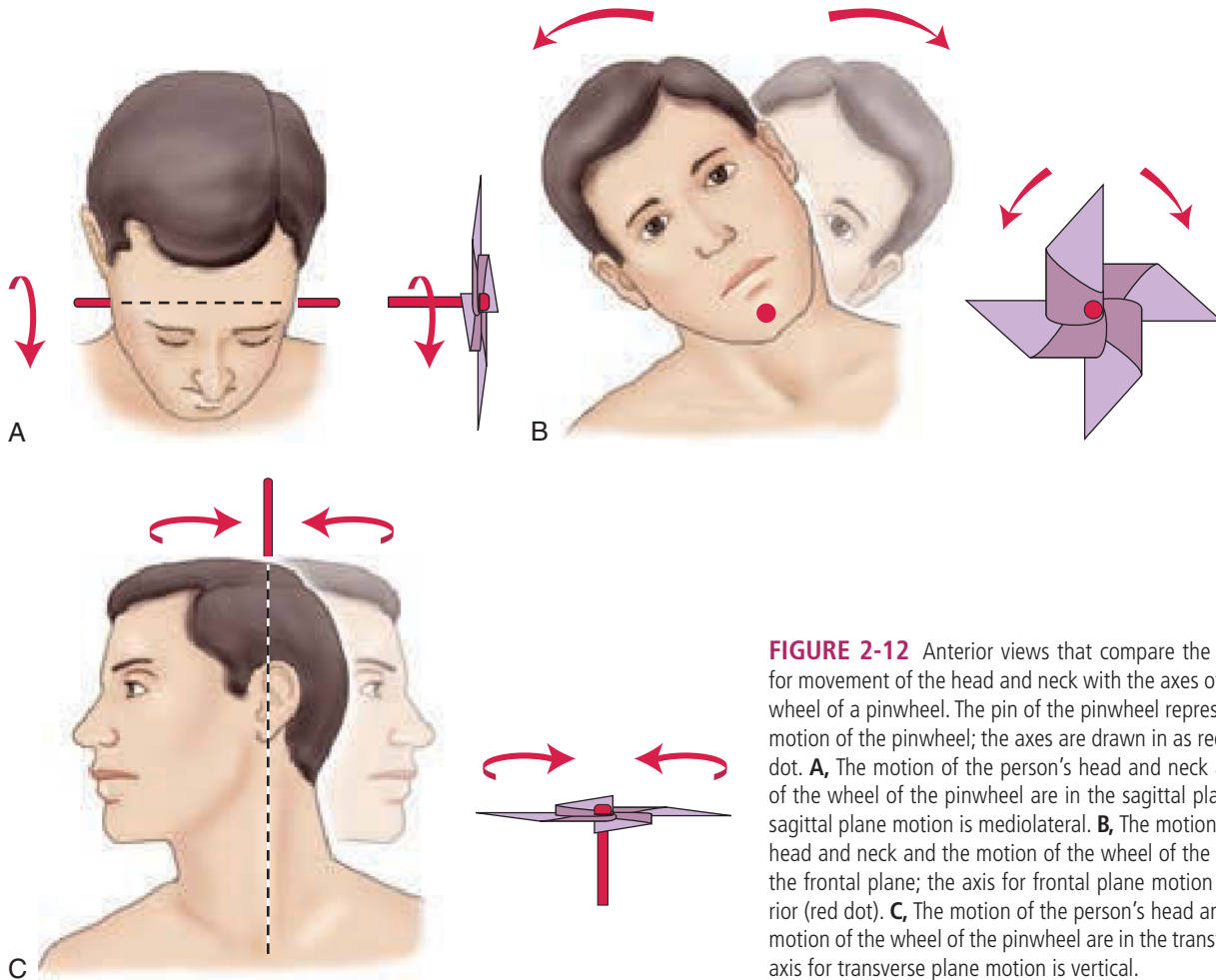


FIGURE 2-12 Anterior views that compare the axes of motion for movement of the head and neck with the axes of motion for the wheel of a pinwheel. The pin of the pinwheel represents the axis of motion of the pinwheel; the axes are drawn in as red tubes or a red dot. **A**, The motion of the person's head and neck and the motion of the wheel of the pinwheel are in the sagittal plane; the axis for sagittal plane motion is mediolateral. **B**, The motion of the person's head and neck and the motion of the wheel of the pinwheel are in the frontal plane; the axis for frontal plane motion is anteroposterior (red dot). **C**, The motion of the person's head and neck and the motion of the wheel of the pinwheel are in the transverse plane; the axis for transverse plane motion is vertical.