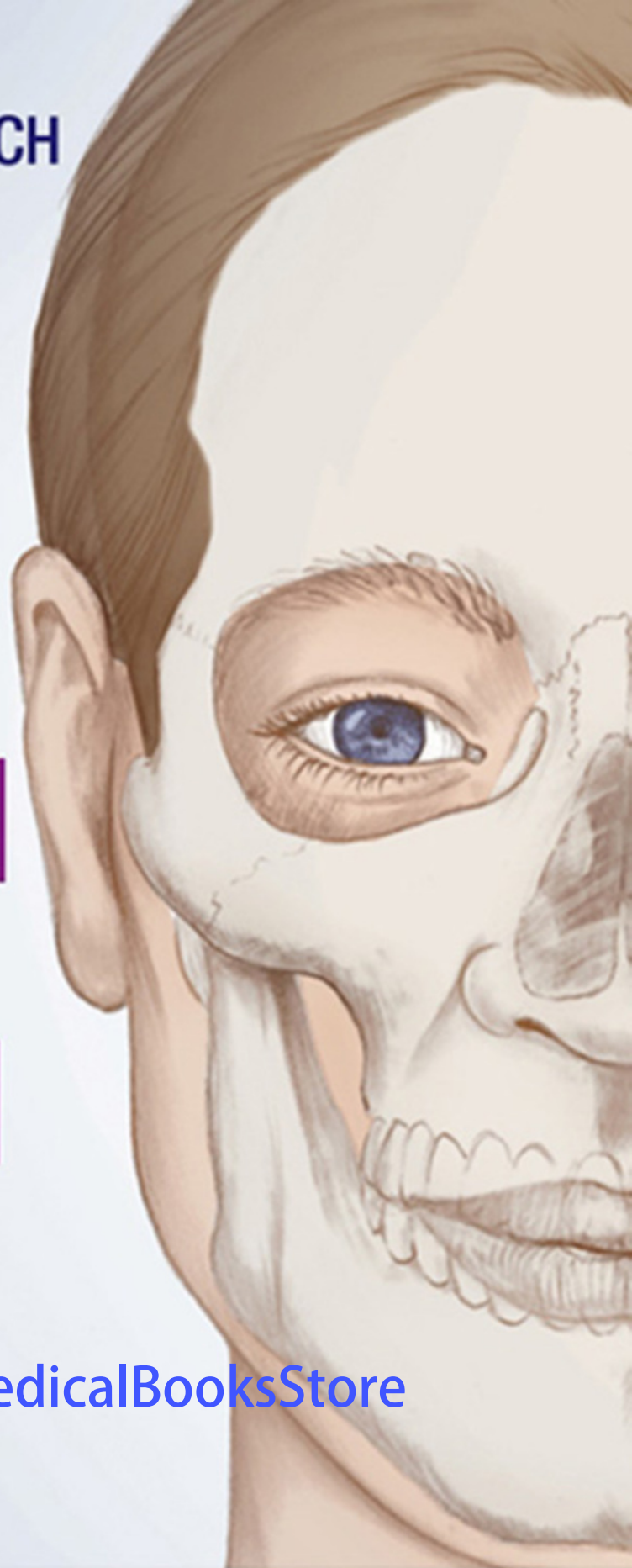
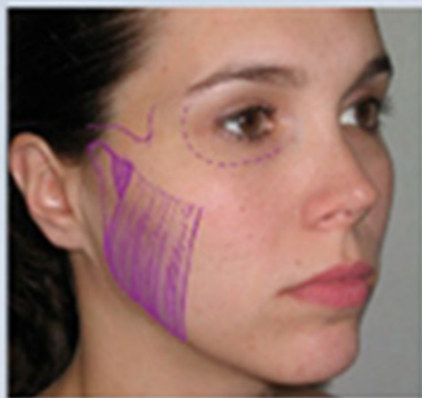
MARGARET J. FEHRENBACH  
SUSAN W. HERRING



# Illustrated Anatomy OF THE **Head** AND **Neck**

[https://t.me/MBS\\_MedicalBooksStore](https://t.me/MBS_MedicalBooksStore)

5<sup>th</sup>  
EDITION

ELSEVIER



EVOLVE STUDY RESOURCES FREE WITH TEXTBOOK PURCHASE  
[EVOLVE.ELSEVIER.COM](https://www.elsevier.com/evolve)

# YOU'VE JUST PURCHASED MORE THAN A TEXTBOOK!

Evolve Student Resources for *Fehrenbach: Illustrated Anatomy of the Head and Neck, 5th edition*, include the following:

- **Discussion Questions**  
Review/Assessment short answer questions for each chapter.
- **Practice Quizzes**  
Questions about key information in each chapter, with instant feedback and scoring at the click of a button.



Activate the complete learning experience that comes with each textbook purchase by registering at

<http://evolve.elsevier.com/Fehrenbach/headneck/>

**REGISTER TODAY!**

You can now purchase Elsevier products on Evolve!  
Go to [evolve.elsevier.com/html/shop-promo.html](http://evolve.elsevier.com/html/shop-promo.html) to search and browse for products.

**Illustrated  
Anatomy  
OF THE Head  
AND Neck**

This page intentionally left blank

5<sup>th</sup>  
EDITION

# Illustrated Anatomy OF THE Head AND Neck

**MARGARET J. FEHRENBACH, RDH, MS**

Oral Biologist and Dental Hygienist  
Adjunct Instructor, Bachelor of Applied Science Degree  
Dental Hygiene Program  
Seattle Central College  
Educational Consultant and Dental Science Writer  
Seattle, Washington

**SUSAN W. HERRING, PhD**

Professor of Orthodontics and Oral Health Sciences  
School of Dentistry  
Adjunct Professor of Biological Structure  
School of Medicine  
Adjunct Professor of Biology  
College of Arts and Sciences  
University of Washington  
Seattle, Washington

ELSEVIER

# ELSEVIER

3251 Riverport Lane  
St. Louis, Missouri 63043

ILLUSTRATED ANATOMY OF THE HEAD AND NECK,  
FIFTH EDITION

ISBN: 978-0-323-39634-9

Copyright © 2017 by Elsevier Inc. All rights reserved.

No part of this publication may be reproduced or transmitted in any form or by any means, electronic or mechanical, including photocopying, recording, or any information storage and retrieval system, without permission in writing from the publisher. Details on how to seek permission, further information about the Publisher's permissions policies and our arrangements with organizations such as the Copyright Clearance Center and the Copyright Licensing Agency, can be found at our website: [www.elsevier.com/permissions](http://www.elsevier.com/permissions).

This book and the individual contributions contained in it are protected under copyright by the Publisher (other than as may be noted herein).

Although for mechanical reasons some pages of this publication are perforated, only those pages imprinted with an Elsevier Inc. copyright notice are intended for removal.

## Notices

Knowledge and best practice in this field are constantly changing. As new research and experience broaden our understanding, changes in research methods, professional practices, or medical treatment may become necessary.

Practitioners and researchers must always rely on their own experience and knowledge in evaluating and using any information, methods, compounds, or experiments described herein. In using such information or methods they should be mindful of their own safety and the safety of others, including parties for whom they have a professional responsibility.

With respect to any drug or pharmaceutical products identified, readers are advised to check the most current information provided (i) on procedures featured or (ii) by the manufacturer of each product to be administered, to verify the recommended dose or formula, the method and duration of administration, and contraindications. It is the responsibility of practitioners, relying on their own experience and knowledge of their patients, to make diagnoses, to determine dosages and the best treatment for each individual patient, and to take all appropriate safety precautions.

To the fullest extent of the law, neither the Publisher nor the authors, contributors, or editors, assume any liability for any injury and/or damage to persons or property as a matter of products liability, negligence or otherwise, or from any use or operation of any methods, products, instructions, or ideas contained in the material herein.

Previous editions copyrighted 2012, 2007, 2002, 1996 by Saunders, an imprint of Elsevier Inc.

## Library of Congress Cataloging-in-Publication Data

Names: Fehrenbach, Margaret J., author. | Herring, Susan W., author.  
Title: Illustrated anatomy of the head and neck / Margaret J. Fehrenbach, Susan W. Herring.  
Description: 5th edition. | St. Louis, Missouri : Elsevier [2017] | Includes bibliographical references and index.  
Identifiers: LCCN 2015038498 | ISBN 9780323396349 (pbk. : alk. paper)  
Subjects: MESH: Head—anatomy & histology. | Head—anatomy & histology—Programmed Instruction. | Neck—anatomy & histology—Programmed Instruction. | Neck—anatomy & histology.  
Classification: LCC QM535 | NLM WE 705 | DDC 611/.91—dc23  
LC record available at <http://lccn.loc.gov/2015038498>

*Content Strategist:* Kristin Wilhelm  
*Senior Content Development Specialist:* Rebecca Leenhouts  
*Publishing Services Manager:* Patricia Tannian  
*Senior Project Manager:* Carrie Stetz  
*Design Direction:* Ashley Miner

Printed in China

Last digit is the print number: 9 8 7 6 5 4 3 2 1



Working together  
to grow libraries in  
developing countries

[www.elsevier.com](http://www.elsevier.com) • [www.bookaid.org](http://www.bookaid.org)

# PREFACE

## OVERVIEW OF NEW EDITION

To meet the needs of today's dental professional, the fifth edition of *Illustrated Anatomy of the Head and Neck* offers more than basic information on head and neck anatomy. Clinical considerations are noted throughout the textbook. Special emphasis is given in the chapter on the temporomandibular joint on the joint's complex anatomy and its associated disorders. Also included are chapters on the anatomic basis of local anesthesia for pain control and the spread of infection related to the head and neck.

## FEATURES IN THIS EDITION

To facilitate the learning process, chapters are divided into the various anatomic systems, ending in the considerations for the anatomic basis for local anesthesia and the regional study of fasciae and spaces as well as the spread of infection.

Each chapter begins with learning objectives and a list of key terms with pronunciation guides from the 32<sup>nd</sup> edition of *Dorland's Medical Dictionary*. The pronunciation of each anatomic structure is also included within each chapter when introduced. The anatomic terms follow those outlined in the internationally approved official body of anatomic nomenclature; older terms are included in many cases for completeness.

Each chapter features two different types of highlighted terms. The terms appearing in bold and red are **key terms** and appear in the key terms list at the beginning of the chapter. The terms that appear in bold and black are **anatomic terms** that are important to the material being discussed in the chapter and are therefore emphasized. Both types of highlighted terms can be found in the Glossary.

All chapter topics discussed in depth have been chosen for their relevance to the needs of the dental professional and to build on former topics. Within each chapter are cross-references to other figures or chapters so the reader can review or investigate interrelated subjects. The content of this edition incorporates additional input from students and educators as well as the latest information from scientific studies and experts.

High-quality, full-color original illustrations and photographs are included throughout the text to reinforce a three-dimensional understanding of anatomy. We are excited to have added new osteology figures as provided for by Neil S. Norton, PhD, Professor of Oral Biology, School of Dentistry, Creighton University. He is the editor of the outstanding atlas, *Netter's Dental Anatomy*. Other in-depth figures have also been added or expanded within this new edition to improve overall anatomic understanding.

Tables and boxes summarizing important information appear throughout the text. Flow charts have been included to help with

coordination of structures. Identification exercises and updated review questions are included for each chapter; both are great tools for self-study as well as study group discussion.

At the end of the book are two appendices. **Appendix A** is an updated bibliography that references published works relevant to head and neck anatomy. **Appendix B** provides a review of the procedures for performing extraoral and intraoral examinations. Following Appendix B are a Glossary containing both key terms and anatomic terms that uses short, easy-to-remember definitions and a detailed index to quickly look up topics.

This textbook is coordinated with *Illustrated Dental Embryology, Histology, and Anatomy* by Margaret J. Fehrenbach and Tracy Popowics and can be considered a companion textbook to complete the curriculum in oral biology. Many of the figures in this text also appear as hand-drawn outlines in the *Dental Anatomy Coloring Book*, edited by Margaret J. Fehrenbach.

## NOTABLE IN THIS EDITION

The important anatomy-related key chapters on the temporomandibular joint, local anesthesia anatomy, and spread of infection have been significantly revised to allow for the latest updated evidence-based information. **Thirty-six full-color flashcards** are located in the back of the text. The cards are perforated for easy removal from the text and are an excellent study tool for students who want to test their knowledge of head and neck anatomy.

The **Evolve website** continues to be an important component, as it was in the last edition, and has been expanded. This site provides a variety of resources for both instructors and students. Included for instructors are an image collection, answer keys, and a test bank. For students, we have included discussion questions for each chapter and practice quizzes.

In addition, we have continued to have the resource of **TEACH** online, an exciting coordinated effort for instructors, which includes a Lesson Plan Manual for all topics covered in the textbook. It features updated online PowerPoint slides with notes that can be individualized for custom presentations. There are also other related materials for both students and instructors. Elsevier sales representatives will be able to help demonstrate the latest in this exciting digital format; student dental professionals can check with their instructors.

As authors, we have tried to make the text easy to understand and interesting to read. We hope that it challenges the reader to incorporate the information presented into clinical situations.

**Margaret J. Fehrenbach, RDH, MS**  
**Susan W. Herring, PhD**

This page intentionally left blank



# ACKNOWLEDGMENTS

Our families and friends need to be thanked for their understanding of our devotion to the Work. Finally, we would like to thank Editors Kristin Wilhelm, Rebecca Leenhouts, and Carrie Stetz as well as the staff of Elsevier for making this latest edition possible.

**Margaret J. Fehrenbach, RDH, MS**  
**Susan W. Herring, PhD**

This page intentionally left blank

# CONTENTS

## CHAPTER 1

### INTRODUCTION TO HEAD AND NECK ANATOMY, 1

- Clinical Applications, 1
- Anatomic Nomenclature, 2
- Anatomic Variation, 3

## CHAPTER 2

### SURFACE ANATOMY, 11

- Surface Anatomy Overview, 11
- Regions of Head, 11
- Regions of Neck, 21

## CHAPTER 3

### SKELETAL SYSTEM, 32

- Skeletal System Overview, 32
- Head and Neck Bones, 33

## CHAPTER 4

### MUSCULAR SYSTEM, 92

- Muscular System Overview, 92
- Head and Neck Muscles, 92

## CHAPTER 5

### TEMPOROMANDIBULAR JOINT, 123

- Temporomandibular Joint Overview, 123
- Jaw Movements With Muscle Relationships, 127

## CHAPTER 6

### VASCULAR SYSTEM, 133

- Vascular System Overview, 133
- Arterial Blood Supply to Head and Neck, 134
- Venous Drainage of Head and Neck, 145

## CHAPTER 7

### GLANDULAR TISSUE, 158

- Glandular Tissue Overview, 158

## CHAPTER 8

### NERVOUS SYSTEM, 171

- Nervous System Overview, 171

## CHAPTER 9

### ANATOMY OF LOCAL ANESTHESIA, 204

- Anatomic Considerations for Local Anesthesia, 204

## CHAPTER 10

### LYMPHATIC SYSTEM, 243

- Lymphatic System Overview, 243
- Lymph Nodes of Head, 246
- Occipital Lymph Nodes, 247
- Posterior Auricular, Anterior Auricular, and Superficial Parotid Lymph Nodes, 247
- Facial Lymph Nodes, 247
- Cervical Lymph Nodes, 248

## CHAPTER 11

### FASCIAE AND SPACES, 264

- Fasciae and Spaces Overview, 264

## CHAPTER 12

### SPREAD OF INFECTION, 289

- Infection Process Overview, 289
- Odontogenic Infection, 289
- Spread of Odontogenic Infection, 294
- Prevention of Spread of Infection, 297

## APPENDIX A

### BIBLIOGRAPHY, 300

## APPENDIX B

### EXTRAORAL AND INTRAORAL EXAMINATIONS PROCEDURE, 302

## GLOSSARY OF KEY TERMS AND ANATOMIC STRUCTURES, 313

## INDEX, 327

## FLASHCARDS

This page intentionally left blank

# Introduction to Head and Neck Anatomy

## LEARNING OBJECTIVES

1. Define and pronounce the **key terms** and **anatomic terms** in this chapter.
2. Discuss the clinical applications of head and neck anatomy by dental professionals.
3. Discuss anatomic variation and how it applies to head and neck structures.
4. Correctly complete the review questions and activities for this chapter.
5. Apply the correct anatomic nomenclature during dental clinical procedures.

## KEY TERMS

<b>Anatomic nomenclature</b> (an-uh-tom-ik no-muhn-klay-chuhr) System of names for anatomic structures.	at any level into anterior and posterior parts.	<b>Median plane</b> Plane related to imaginary line dividing body into right and left halves.
<b>Anatomic position</b> Erect position, arms at sides, palms and toes directed forward, with eyes looking forward.	<b>Frontal section</b> Section through any frontal plane.	<b>Midsagittal section</b> (mid-saj-i-tuhl) Section through median plane.
<b>Anterior</b> Front of area.	<b>Horizontal plane</b> Plane related to imaginary line dividing body at any level into superior and inferior parts.	<b>Posterior</b> Back of area.
<b>Apex/Apices</b> (ay-peks, ay-pih-sees) Pointed end(s) of conical structure.	<b>Inferior</b> Area facing away from head and toward feet.	<b>Proximal</b> (prok-si-muhl) Area closer to median plane.
<b>Contralateral</b> (kon-truh-lat-uhr-uhl) Structure on opposite side.	<b>Internal</b> Inner side of wall of hollow structure.	<b>Sagittal plane</b> (saj-i-tuhl) Planes of body related to any imaginary plane parallel to median plane.
<b>Deep</b> Structure located inwards and away from surface.	<b>Ipsilateral</b> (ip-see-lat-uhr-uhl) Structure on same side.	<b>Superficial</b> Structure located toward surface.
<b>Distal</b> (dis-tuhl) Area farther away from median plane.	<b>Lateral</b> Area farther away from median plane.	<b>Superior</b> Area facing toward head and away from feet.
<b>Dorsal</b> (dor-suhl) Back of area.	<b>Medial</b> (me-dee-uhl) Area closer to median plane; considered mesial within dentition.	<b>Transverse section</b> (tranz-vurs) Section through any horizontal plane.
<b>External</b> Outer side of wall of hollow structure.	<b>Median</b> (me-dee-uhn) Structure at median plane.	<b>Ventral</b> (ven-truhl) Front of area.
<b>Frontal plane</b> (frun-tuhl) Plane related to imaginary line dividing body		

## CLINICAL APPLICATIONS

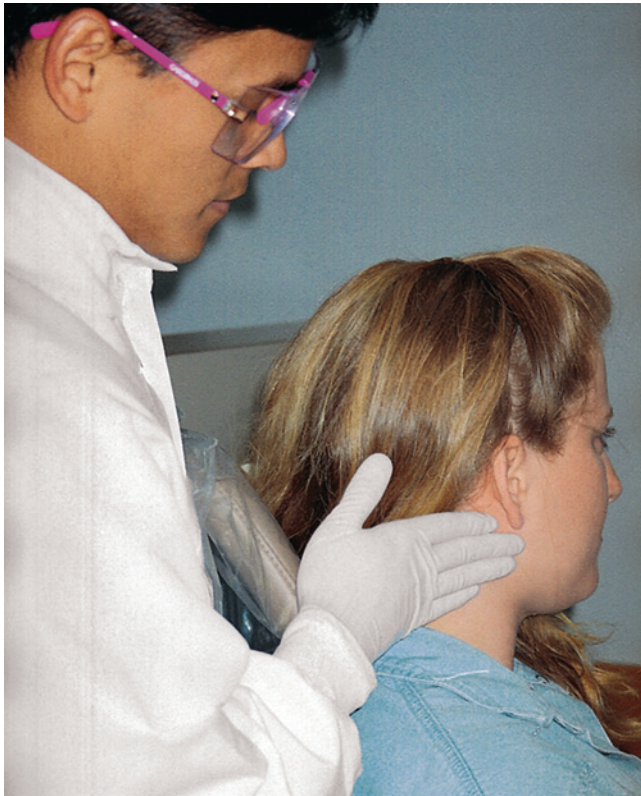The dental professional must have a thorough understanding of head and neck anatomy when performing patient examination procedures, both extraoral and intraoral procedures (Figure 1-1). This will help determine whether any abnormalities or pathologic lesions exist and possibly indicate their cause and degree of involvement. This will also provide a basis for the description of the lesion and its location for record-keeping purposes.

During examination of the patient, the dental professional may specifically note the presence of dental (or odontogenic) infection. It is

important to know the source of the infection as well as the areas to which it could spread by way of certain anatomic features of the head and neck. This background in anatomy will help the dental professional understand the spread of dental infection to reduce its risk.

A patient may also present with features of a temporomandibular joint disorder. A dental professional must understand the anatomy of the joint to understand the various disorders associated with it.

When taking radiographs, the dental professional uses surface landmarks for film placement and consistency. In addition to these landmarks, an understanding of anatomy is important in the mounting and analysis of the films.



**FIGURE 1-1** Examination of the patient is based on an understanding of head and neck anatomy. (Courtesy of Margaret J. Fehrenbach, RDH, MS.)

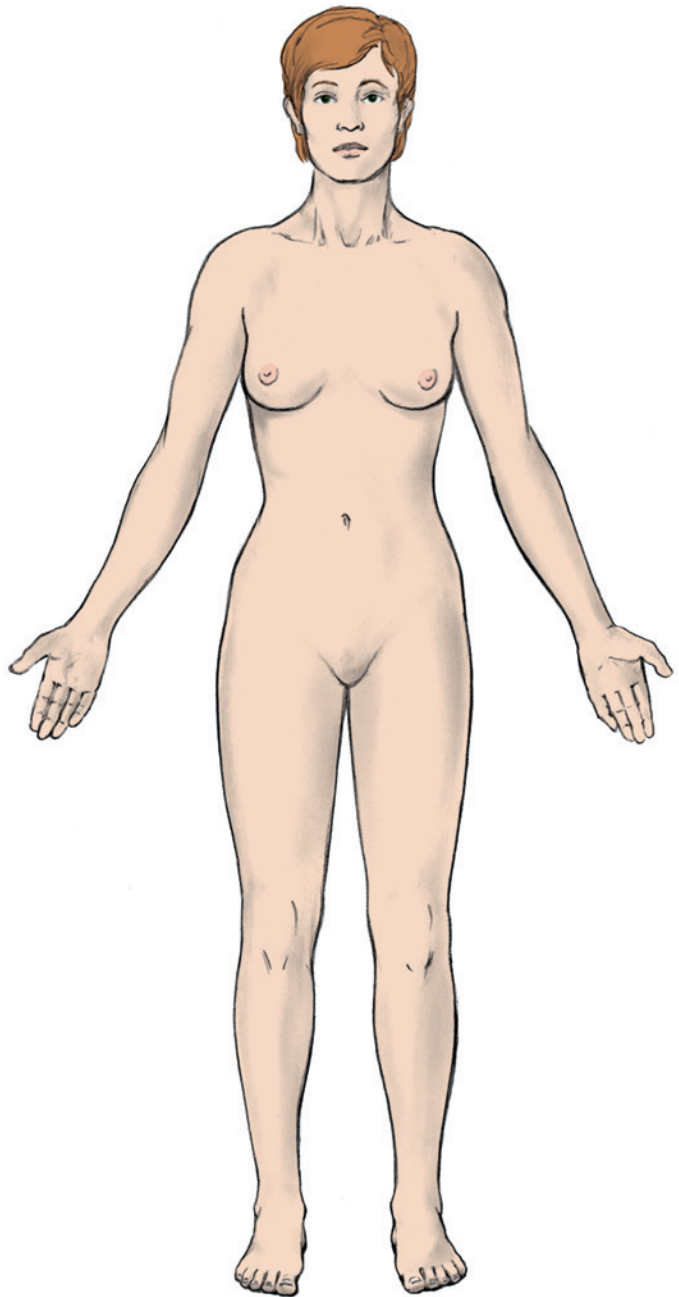
The administration of local anesthesia is also based on landmarks of the head and neck. Knowledge of anatomy helps the dental professional plan for use of a local anesthetic to reduce pain levels during various dental procedures. This knowledge also allows for correct placement of the syringe and its anesthetic agent, potentially avoiding complications.

To initially consider patient care through anatomic study, this text takes mainly a systemic approach to the study of head and neck anatomy after its two initial background chapters, **Chapters 1 and 2**. Through most of its chapters, **Chapters 3 to 10**, this approach takes a look at each system separately (e.g., skeletal, muscular). Another way to study anatomy for patient care integration is the regional approach, which is taken up later within **Chapter 11**, since it focuses on the fasciae and fascial spaces of the head and neck. Both approaches, when used in the order presented in this text, are complementary and effective ways to study head and neck anatomy and prepare for patient care considerations.

To reinforce the material already presented and make it readily useful for clinicians, **Chapter 9** also has an expanded clinical emphasis covering the anatomy of local anesthesia. The final chapter, **Chapter 12**, also emphasizes this important clinical approach to head and neck anatomy during the consideration of the spread of infection. In addition, all the other chapters include important clinical considerations when appropriate, such as related pathology.

## ANATOMIC NOMENCLATURE

Before beginning the study of head and neck anatomy, the dental professional may need to review **anatomic nomenclature**, which is

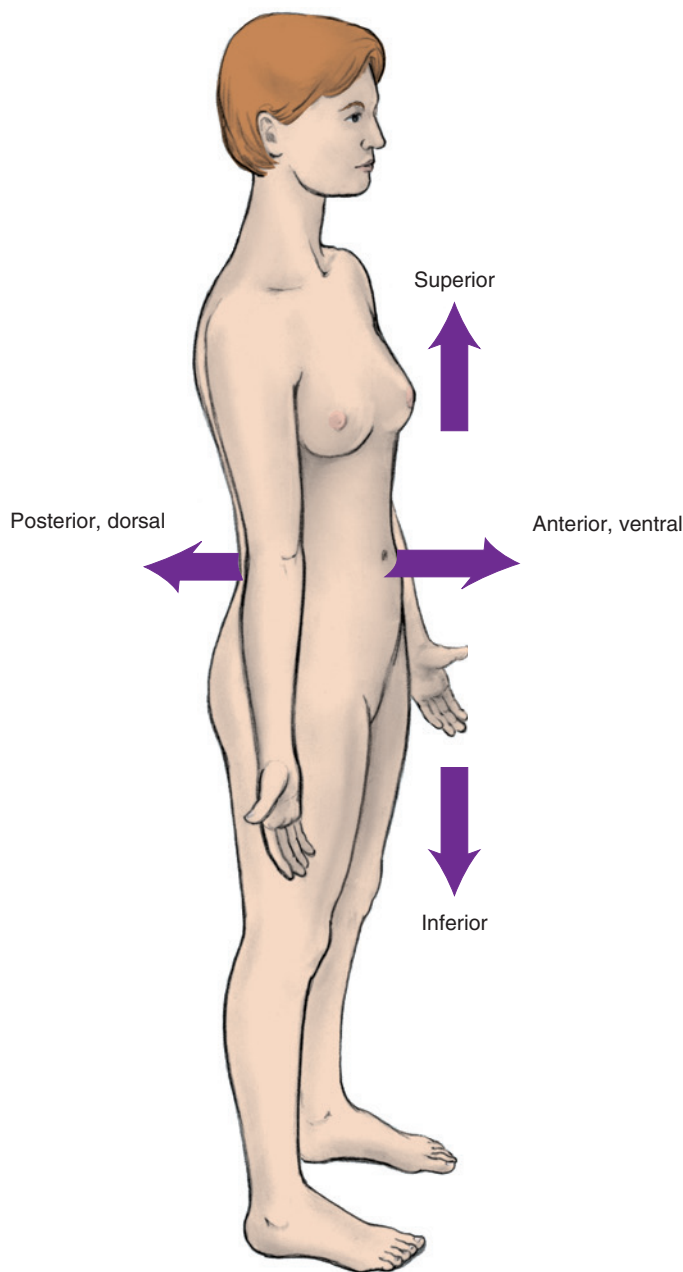


**FIGURE 1-2** Body in anatomic position.

the system of names for anatomic structures. This review will allow for easy application of these terms to the head and neck area when examining a patient, for use in the patient's record, or during related clinical procedures.

The nomenclature of anatomy is based on the body being in **anatomic position** (Figure 1-2). In anatomic position, the body can be standing erect. The arms are at the sides with the palms and toes directed forward and the eyes looking forward. This position is assumed even when the body may be supine (on the back) or prone (on the front) or even with respect to the position of the patient's head and neck when sitting upright in a dental chair.

When studying the body in anatomic position, certain terms are used to refer to areas in relationship to other areas (Figure 1-3). The front of an area in relationship to the entire body is its **anterior** part.



**FIGURE 1-3** Body in anatomic position with the anterior (or ventral), posterior (or dorsal), superior, and inferior areas noted.

The back of an area is its **posterior** part. The **ventral** part is directed toward the anterior and is the opposite of the **dorsal** part or part directed toward the posterior when considering the entire body.

Other terms can be used to refer to areas in relationship to other areas of the body. An area that faces toward the head and away from the feet is its **superior** part. An area that faces away from the head and toward the feet is its **inferior** part. As an example, the face is on the anterior side of the head, and the hair is superior and posterior to the face. The **apex** or tip is the pointed end of a conical structure such as the apex or tip of the tongue.

The body in anatomic position can be divided into areas by planes or flat surfaces (Figure 1-4). The **median plane** or *midsagittal plane* (mid-saj-i-tuhl) is related by an imaginary line dividing the body into equal right and left halves. On the surface of the body, these halves

are generally symmetric, yet the same symmetry does not apply to all internal structures.

Differing imaginary lines related to other planes can divide the body into areas too. A **sagittal plane** is a plane related to any imaginary line dividing the body that is parallel to the median plane just discussed. A **frontal plane** or *coronal plane* (kor-o-nuhl) is related to an imaginary line dividing the body at any level into anterior and posterior parts. A **horizontal plane** is related to an imaginary line dividing the body at any level into superior and inferior parts and is always perpendicular to the median plane.

Parts of the body in anatomic position can also be described in relationship to these planes (Figure 1-5). A structure located at the median plane (e.g., the nose) is considered **median**. An area closer to the median plane of the body or structure is considered **medial** or *mesial* within the dentition. An area farther from the median plane of the body or structure is considered **lateral**. For example, the eyes are medial to the ears and the ears are lateral to the eyes.

Terms can be used to describe the relationship of parts of the body in anatomic position. An area closer to the median plane is considered to be **proximal**, and an area farther from the median plane is **distal** even within the dentition. For example, in the upper limb the shoulder is proximal and the same side fingers are distal.

Additional terms can be used to describe relationships between structures. A structure on the same side of the body is considered **ipsilateral**. A structure on the opposite side of the body is considered **contralateral**. For example, the right leg is ipsilateral to the right arm but contralateral to the left arm.

Certain terms can be used to give information about the depth of a structure in relationship to the surface of the body. A structure located toward the surface of the body is **superficial**. A structure located inward, away from the body surface, is **deep**. For example, the skin is superficial and the bones are deep.

Terms also can be used to give information about location in hollow structures such as the braincase of the skull. The inner side of the wall of a hollow structure is referred to as **internal**. The outer side of the wall of a hollow structure is **external**.

The body or parts of it in anatomic position can also be divided into sections along various planes in order to study the specific anatomy of a region (Figure 1-6). The **midsagittal section** or *median section* is a division through the median plane. The **frontal section** or *coronal section* is a division through any frontal plane. The **transverse section** or *horizontal section* is a division through a horizontal plane.

It is important to keep in mind when studying diagrams or associated photographs especially those of dissections, to first note any overall descriptions (e.g., view, section) as well as any nearby directional pointers. Then note any familiar structures (e.g., apex of tongue or nose, maxilla, or mandible) to allow for basic orientation. Next look to the areas highlighted, if noted, and of course those structures that are labeled. This process will help overall in the study of the head and neck.

## ANATOMIC VARIATION

When studying anatomy, the dental professional must understand that there can be anatomic variations of head and neck structures. The number of bones and muscles in the head and neck is usually constant, but specific details of these structures can vary from patient to patient. Bones may have different sizes of processes. Muscles may differ in size and details of their attachments. Joints, vessels, nerves, glands, lymph nodes, fasciae, and spaces of an individual can vary in size, location, and even presence. The most common variations of the head and neck that affect dental treatment are discussed in this text.