



SALADIN

# ANATOMY & PHYSIOLOGY

The Unity of Form and Function

Eighth Edition

Mc  
Graw  
Hill  
Education

# ANATOMY & PHYSIOLOGY

The Unity of Form and Function

Eighth Edition

KENNETH S. SALADIN

*Georgia College*

**Digital Authors**

CHRISTINA A. GAN

*Highline Community College*

HEATHER N. CUSHMAN

*Tacoma Community College*





## ANATOMY & PHYSIOLOGY: THE UNITY OF FORM AND FUNCTION, EIGHTH EDITION

Published by McGraw-Hill Education, 2 Penn Plaza, New York, NY 10121. Copyright © 2018 by McGraw-Hill Education. All rights reserved. Printed in the United States of America. Previous editions © 2015, 2012, and 2010. No part of this publication may be reproduced or distributed in any form or by any means, or stored in a database or retrieval system, without the prior written consent of McGraw-Hill Education, including, but not limited to, in any network or other electronic storage or transmission, or broadcast for distance learning.

Some ancillaries, including electronic and print components, may not be available to customers outside the United States.

This book is printed on acid-free paper.

1 2 3 4 5 6 7 8 9 LWI 21 20 19 18 17 16

ISBN 978-1-259-27772-6

MHID 1-259-27772-0

Chief Product Officer, SVP Products & Markets: *G. Scott Virkler*

Vice President, General Manager, Products & Markets: *Marty Lange*

Vice President, Content Design & Delivery: *Betsy Whalen*

Managing Director: *Lynn Breithaupt*

Executive Brand Manager: *Amy Reed*

Director, Product Development: *Rose Koos*

Senior Product Developer: *Fran Simon*

Marketing Manager: *Kelly Brown/James Connely*

Market Development Manager: *Kristine Rellihan*

Director of Digital Content: *Michael G. Koot, PhD*

Digital Product Analyst: *John J. Theobald*

Director, Content Design & Delivery: *Linda Avenarius*

Program Manager: *Angela R. FitzPatrick*

Content Project Managers: *Vicki Krug/Christina Nelson*

Buyer: *Sandy Ludovissy*

Design: *David Hash*

Content Licensing Specialists: *Lori Hancock/Lorraine Buczek*

Cover Image: ©PeoplesImages.com/DigitalVision/Getty Images; anatomy art overlay: *MPS North America LLC*

Compositor: *MPS Limited*

Printer: *LSC Communications*

All credits appearing on page or at the end of the book are considered to be an extension of the copyright page.

### Library of Congress Cataloging-in-Publication Data

Names: Saladin, Kenneth S., author. | Gan, Christina A., author. | Cushman, Heather N., author.

Title: Anatomy & physiology : the unity of form and function / Kenneth S. Saladin, Georgia College & State University ; digital authors, Christian A. Gan, Highline Community College, Heather N. Cushman, Tacoma Community College.

Other titles: Anatomy and physiology

Description: Eighth edition. | New York, NY : McGraw-Hill Education, [2018]

Includes index.

Identifiers: LCCN 2016033675 | ISBN 9781259277726 (alk. paper)

Subjects: LCSH: Human physiology—Textbooks. | Human anatomy—Textbooks.

Classification: LCC QP34.5 .S23 2018 | DDC 612—dc23 LC record available at <https://lccn.loc.gov/2016033675>

The Internet addresses listed in the text were accurate at the time of publication. The inclusion of a website does not indicate an endorsement by the authors or McGraw-Hill Education, and McGraw-Hill Education does not guarantee the accuracy of the information presented at these sites.

[mheducation.com/highered](http://mheducation.com/highered)

# BRIEF CONTENTS

About the Authors iv

## PART ONE

### ORGANIZATION OF THE BODY 1

- 1 Major Themes of Anatomy and Physiology 1  
ATLAS A General Orientation to Human Anatomy 27
- 2 The Chemistry of Life 41
- 3 Cellular Form and Function 75
- 4 Genetics and Cellular Function 111
- 5 Histology 139

## PART TWO

### SUPPORT AND MOVEMENT 175

- 6 The Integumentary System 175
- 7 Bone Tissue 201
- 8 The Skeletal System 228
- 9 Joints 273
- 10 The Muscular System 307  
ATLAS B Regional and Surface Anatomy 373
- 11 Muscular Tissue 395

## PART THREE

### INTERNAL COORDINATION AND CONTROL 431

- 12 Nervous Tissue 431
- 13 The Spinal Cord, Spinal Nerves, and Somatic Reflexes 471
- 14 The Brain and Cranial Nerves 504
- 15 The Autonomic Nervous System and Visceral Reflexes 554
- 16 Sense Organs 575
- 17 The Endocrine System 626

## PART FOUR

### CIRCULATION AND DEFENSE 669

- 18 The Circulatory System: Blood 669
- 19 The Circulatory System: Heart 705
- 20 The Circulatory System: Blood Vessels and Circulation 741
- 21 The Lymphatic and Immune Systems 800

## PART FIVE

### INTAKE AND OUTPUT 845

- 22 The Respiratory System 845
- 23 The Urinary System 886
- 24 Fluid, Electrolyte, and Acid–Base Balance 921
- 25 The Digestive System 944
- 26 Nutrition and Metabolism 991

## PART SIX

### REPRODUCTION AND THE LIFE CYCLE 1025

- 27 The Male Reproductive System 1025
- 28 The Female Reproductive System 1055
- 29 Human Development and Aging 1093

APPENDIX A: Periodic Table of the Elements A-1

APPENDIX B: Answer Keys A-2

APPENDIX C: Symbols, Weights, and Measures A-15

APPENDIX D: Biomedical Abbreviations A-18

APPENDIX E: The Genetic Code A-19


APPENDIX F: Lexicon of Biomedical Word Elements A-20

APPENDIX G: Eighth Edition Changes in Terminology A-24

Glossary G-1

Index I-1

# ABOUT THE AUTHORS



© Tim Vacula

**KENNETH S. SALADIN** has taught since 1977 at Georgia College in Milledgeville, Georgia. He earned a B.S. in zoology at Michigan State University and a Ph.D. in parasitology at Florida State University, with interests especially in the sensory ecology of freshwater invertebrates. In addition to human anatomy and physiology, his teaching experience includes histology, parasitology, animal behavior, sociobiology, introductory biology, general zoology, biological etymology, and study abroad in the Galápagos Islands. Ken has been recognized as “most significant undergraduate mentor” nine times over the years by outstanding students inducted into Phi Kappa Phi. He received the university’s Excellence in Research and Publication Award for the first edition of this book, and was named Distinguished Professor in 2001.

Ken is a member of the Human Anatomy and Physiology Society, the Society for Integrative and Comparative Biology, American Physiological Society, and the American Association for the Advancement of Science. He served as a developmental reviewer and wrote supplements for several other McGraw-Hill anatomy and physiology textbooks for a number of years before becoming a textbook writer.

Ken’s outside interests include the Galápagos Conservancy, and he has endowed student scholarships, the natural history museum, and a faculty chair at his university. Ken is married to Diane Saladin, a registered nurse. They have two adult children.



© Chris Gan/Yuen Lui Studios

**CHRISTINA A. GAN**, digital coauthor for Connect®, has been teaching anatomy and physiology, microbiology, and general biology at Highline Community College in Des Moines, Washington, since 2004. Before that, she taught at Rogue Community College in Medford, Oregon, for 6 years. She earned her M.A. in biology from Humboldt State University, researching the genetic variation of mitochondrial DNA in various salmonid species, and is a member of the Human Anatomy and Physiology Society. When she is not in the classroom or developing digital media, she is climbing, mountaineering, skiing, kayaking, sailing, cycling, and mountain biking throughout the Pacific Northwest.



© JC Penney Portraits/Lifetouch Portrait Studios, Inc.

**HEATHER N. CUSHMAN**, digital coauthor for Connect®, teaches anatomy and physiology at Tacoma Community College in Tacoma, Washington, and is a member of the Human Anatomy and Physiology Society. She received her Ph.D. in neuroscience from the University of Minnesota in 2002, and completed a postdoctoral fellowship at the Vollum Institute at Oregon Health & Science University in Portland, Oregon, where she studied sensory transduction and the cellular and molecular mechanisms of muscle pain. She currently resides in Tacoma, Washington, and enjoys climbing, camping, and hiking with her husband Ken and their daughter Annika.



# THE EVOLUTION OF A STORYTELLER




Ken in 1964

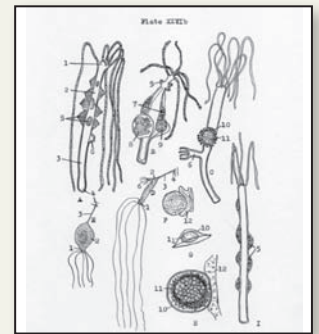
Ken Saladin's first step into authoring was a 318-page paper on the ecology of hydras written for his tenth-grade biology class. With his "first book," featuring 53 original India ink drawings and photomicrographs, a true storyteller was born.

*When I first became a textbook writer, I found myself bringing the same enjoyment of writing and illustrating to this book that I first discovered when I was 15.*

—Ken Saladin




Ken's "first book," *Hydra Ecology*, 1965  
Courtesy of Ken Saladin




One of Ken's drawings from *Hydra Ecology*  
Courtesy of Ken Saladin

**Ken began working** on his first book for McGraw-Hill in 1993, and in 1997 the first edition of *The Unity of Form and Function* was published. In 2017, the story continues with the eighth edition of Ken's best-selling A&P textbook.



The first edition (1997)



The story continues (2017)

## ACKNOWLEDGMENTS

Peer review is a critical part of the scientific process, and very important to ensure the content in this book continues to meet the needs of the instructors and students who use it. We are grateful for the people who agree to participate in this process and thank them for their time, talents, and feedback. The reviewers of this text have contributed significant comments that help us refine and update the print and digital components of this program.

Mervan Agovic  
*City University of New York*

Rita Bagwe  
*GBC, Pahrump*

Neda Baniyadi  
*North Shore Community College*

Joan Barber  
*Delaware Technical Community College*

Jennifer Biederman  
*Winona State University*

Carol Britson  
*University of Mississippi*

Susan Capasso  
*St. Vincent's College*

Kwan Christenson  
*Georgia College*

Joseph Comber  
*Villanova University*

Suzanne Cooke  
*UNH Manchester*

Andrew Corless  
*Vincennes University*

Rupa De  
*Purdue University*

Elizabeth Dunphy  
*Gateway Community College*

Chelsea Edward  
*Cleveland Community College*

Lori Garrett  
*Parkland College*

Melissa Glenn  
*SUNY Broome*

Donna Harman  
*Lubbock Christian University*

Clare Hays  
*Metropolitan State University of Denver*

Jana Herron  
*Chattanooga State Community College*

Austin Hicks  
*University of Alabama*

Roxann Isch-Clifton  
*SWOSU at Sayre*

Pamela Jackson  
*Piedmont Technical College*

Paula Johnson  
*New River Community and Technical College*

Jacqueline Jordan  
*Clayton State University*

Karen Kelly  
*Milligan College*

Shadi Kilani  
*Houston Community College*

Nathaniel M. King  
*Palm Beach State College*

Jeff Kingsbury  
*Arizona State University*

Brian H. Kipp  
*Grand Valley State University*

Shelley Kirkpatrick  
*Saint Francis University*

Theresa Kong  
*William Rainey Harper College*

Mary Katherine Lockwood  
*University of New Hampshire*

Kerrie McDaniel  
*Western Kentucky University*

Melinda Melton  
*McNeese State University*

Melanie Meyer  
*Community College of Vermont*

Kathy Monroe  
*Blue Ridge Community and Technical College*

David Moore  
*Harrisburg Area Community College*

Mina Moussavi  
*University of Central Missouri*

Ellen Ott-Reeves  
*Blinn College Bryan*

Andrew Petto  
*UW Milwaukee*

James Roush  
*WKCTC*

Stephen R. Peterson  
*Delgado Community College*

Richard Pirkle  
*Tennessee Tech University*

Jackie Reynolds  
*Richland College*

Crista Royal  
*Toccoa Falls College*

Frantz Sainvil  
*Broward College*

Colin Scanes  
*UWM*

Carl Shuster  
*Madison College*

Scott Simerlein  
*Purdue University North Central*

Gehan Soliman  
*FTCC*

Sherry Stewart  
*Navarro College*

Leticia Vega  
*Barry University*

Cuc Vu  
*St. Catherine University*

Stephanie Wallace  
*Texas Christian University*

Katy Wallis  
*State College of Florida*

Janice Webster  
*Ivy Tech Community College*

John Whitlock  
*Mount Aloysius College*

Harvey Wiener  
*Manchester Community College*

Sonya J. Williams  
*Oklahoma City Community College*

Cindy Wingert  
*Cedarville University*

Theophilieus Worrell  
*Delgado Community College*

Robin Wright  
*Houston Community College*

Xiaobo Yu  
*Kean University (Union, NJ)*

David Zimmer  
*Trocaire College*

Jeff Zuiderveen  
*Columbus State University*

## Board of Advisors

Cheryl Christensen  
*Palm Beach State College*

Lisa Conley  
*Milwaukee Area Tech*

Thomas Kalluvila  
*Bryant and Stratton College*

AJ Petto  
*University of Wisconsin - Milwaukee*

Jason Pienaar  
*University of Alabama Tuscaloosa*

Frantz Sainvil  
*Broward College Central*

Colin Scanes  
*University of Wisconsin - Milwaukee*

Carl Shuster  
*Madison College*

# THE STORY OF FORM AND FUNCTION

Saladin's text is written using plain language for A&P students who may be taking this course early in their curricula. Students say the enlightening analogies, clinical applications, historical notes, biographical vignettes, and evolutionary insights make the book not merely informative, but a pleasure to read.

## INNOVATIVE CHAPTER SEQUENCING

Some chapters and topics are presented in a sequence that is more instructive than the conventional order.

### Early Presentation of Heredity

Fundamental principles of heredity are presented in the last few pages of chapter 4 rather than at the back of the book to better integrate molecular and Mendelian genetics. This organization also prepares students to learn about such genetic traits and conditions as cystic fibrosis, color blindness, blood types, hemophilia, cancer genes, and sickle-cell disease by first teaching them about dominant and recessive alleles, genotype and phenotype, and sex linkage.

### Urinary System Presented Close to Circulatory and Respiratory Systems

Most textbooks place this system near the end of the book because of its anatomical and developmental relationships with the reproductive system. However, its physiological ties to the circulatory and respiratory systems are much more important. Except for a necessary digression on lymphatics and immunity, the circulatory system is followed almost immediately with the respiratory and urinary systems, which regulate blood composition and whose functional mechanisms rely on recently covered principles of blood flow and capillary exchange.

### Muscle Anatomy and Physiology Follow Skeleton and Joints

The functional morphology of the skeleton, joints, and muscles is treated in three consecutive chapters, 8 through 10, so when students learn muscle attachments, these come only two chapters after the names of the relevant bone features. When they learn muscle actions, it is in the first chapter after learning the terms for the joint movements. This order brings another advantage: the physiology of muscle and nerve cells is treated in two consecutive chapters (11 and 12), which are thus closely integrated in their treatment of synapses, neurotransmitters, and membrane electrophysiology.

## BRIEF CONTENTS

About the Author iv

### PART ONE

#### ORGANIZATION OF THE BODY 1

- 1 Major Themes of Anatomy and Physiology 1  
ATLAS A General Orientation to Human Anatomy 27
- 2 The Chemistry of Life 41
- 3 Cellular Form and Function 75
- 4 Genetics and Cellular Function 111
- 5 Histology 139

### PART TWO

#### SUPPORT AND MOVEMENT 175

- 6 The Integumentary System 175
- 7 Bone Tissue 201
- 8 The Skeletal System 228
- 9 Joints 273
- 10 The Muscular System 307  
ATLAS B Regional and Surface Anatomy 373
- 11 Muscular Tissue 395

### PART THREE

#### INTERNAL COORDINATION AND CONTROL 431

- 12 Nervous Tissue 431
- 13 The Spinal Cord, Spinal Nerves, and Somatic Reflexes 471
- 14 The Brain and Cranial Nerves 504
- 15 The Autonomic Nervous System and Visceral Reflexes 554
- 16 Sense Organs 575
- 17 The Endocrine System 626

### PART FOUR

#### CIRCULATION AND DEFENSE 669

- 18 The Circulatory System: Blood 669
- 19 The Circulatory System: Heart 705
- 20 The Circulatory System: Blood Vessels and Circulation 741
- 21 The Lymphatic and Immune Systems 800

### PART FIVE

#### INTAKE AND OUTPUT 845

- 22 The Respiratory System 845
- 23 The Urinary System 886
- 24 Fluid, Electrolyte, and Acid-Base Balance 921
- 25 The Digestive System 944
- 26 Nutrition and Metabolism 991

### PART SIX

#### REPRODUCTION AND THE LIFE CYCLE 1025

- 27 The Male Reproductive System 1025
- 28 The Female Reproductive System 1055
- 29 Human Development and Aging 1093

APPENDIX A: Periodic Table of the Elements A1

APPENDIX B: Answer Keys A2

APPENDIX C: Symbols, Weights, and Measures A15

APPENDIX D: Biomedical Abbreviations A18

APPENDIX E: The Genetic Code A20

APPENDIX F: Lexicon of Biomedical Word Elements A21

APPENDIX G: Eighth Edition Changes in Terminology A25

Glossary G-1

Index I-1

iii



# THE STORY OF FORM AND FUNCTION

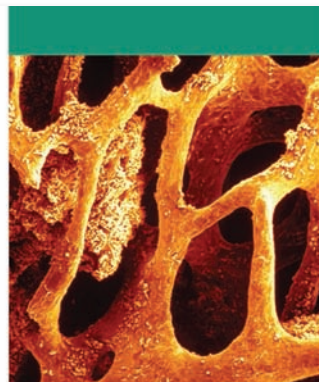
## LEARNING TOOLS

### Engaging Chapter Layouts

- Chapters are structured around the way students learn.
- Frequent subheadings and expected learning outcomes help students plan their study time and review strategies.

**Chapter Outlines** provide quick previews of the content.

**Deeper Insights** highlight areas of interest and career relevance for students.



Spongy bone of the human femur  
© Univ. of Zurich/Science Source

## CHAPTER 7

### BONE TISSUE

202 PART TWO Support and Movement

#### BRUSHING UP

- Bones develop from an embryonic connective tissue called mesenchyme, described in “Embryonic Tissues” in section 5.1.
- Hyaline cartilage histology (see table 5.7) is important for understanding bone development and certain features of the mature skeleton.
- Review “Stem Cells” in section 5.6 to best understand bone cells and their origins.

In art and history, nothing has so often symbolized death as a skull or skeleton! Bones and teeth are the most durable remains of a once-living body and the most vivid reminder of the impermanence of life.

The dry bones presented for laboratory study may wrongly suggest that the skeleton is a nonliving scaffold for the body, like the steel girders of a building. Seeing it in such a sanitized form makes it easy to forget that the living skeleton is made of dynamic tissues, full of cells—that it continually remodels itself and interacts physiologically with all of the other organ systems of the body. The skeleton is permeated with nerves and blood vessels, which attests to its sensitivity and metabolic activity.

**Osteology**, the study of bone, is the subject of these next three chapters. In this chapter, we study bone as a tissue—its composition, its functions, how it develops and grows, how its metabolism is regulated, and some of its disorders. This will provide a basis for understanding the skeleton, joints, and muscles in the chapters that follow.

#### 7.1 Tissues and Organs of the Skeletal System

##### Expected Learning Outcomes

When you have completed this section, you should be able to

- name the tissues and organs that compose the skeletal system;
- state several functions of the skeletal system;
- distinguish between bone as a tissue and as an organ; and
- describe the general features of a long bone and a flat bone.

The **skeletal system** is composed of bones, cartilages, and ligaments joined tightly to form a strong, flexible framework for the body. Cartilage, the forerunner of most bones in embryonic and childhood development, covers many joint surfaces in the mature skeleton. Ligaments hold bones together at the joints and are

<sup>1</sup>skull = dried up  
<sup>2</sup>teeth = bones; legs = study of

discussed in chapter 9. Tendons are structurally similar to ligaments but attach muscle to bone; they are discussed with the muscular system in chapter 10. Here, we focus on the bones.

#### Functions of the Skeleton

The skeleton plays at least six roles:

1. **Support.** Bones of the limbs and vertebral column support the body; the mandible and maxilla support the teeth; and some viscera are supported by nearby bones.
2. **Protection.** Bones enclose and protect the brain, spinal cord, heart, lungs, pelvic viscera, and bone marrow.
3. **Movement.** Limb movements, breathing, and other movements are produced by the action of muscles on the bones.
4. **Electrolyte balance.** The skeleton stores calcium and phosphorus and releases them into the tissue fluid and blood according to the body's physiological needs.
5. **Acid-base balance.** Bone tissue buffers the blood against excessive pH changes by absorbing or releasing alkaline phosphate and carbonate salts.
6. **Blood formation.** Red bone marrow is the major producer of blood cells, including cells of the immune system.

#### Bones and Osseous Tissue

Bone, or **osseous** tissue, is a connective tissue in which the matrix is hardened by the deposition of calcium phosphate and other minerals. The hardening process is called **mineralization** or **calcification**. (Bone is not the hardest substance in the body; that distinction goes to tooth enamel.) Osseous tissue is only one of the tissues that make up a bone. Also present are blood, bone marrow, cartilage, adipose tissue, nervous tissue, and fibrous connective tissue. The word *bone* can denote an organ composed of all these tissues, or it can denote just the osseous tissue.

#### General Features of Bones

Bones have a wide variety of shapes correlated with their varied protective and locomotor functions. Most of the cranial bones are in the form of thin curved plates called **flat bones**, such as the paired parietal bones that form the dome of the top of the head. The sternum (breastbone), scapula (shoulder blade), ribs, and hip bones are also flat bones. The most important bones in body movement are the **long bones** of the limbs—the humerus, radius, and ulna of the arm and forearm; the femur, tibia, and fibula of the thigh and leg; and the metacarpals, metatarsals, and phalanges of the hands and feet. Like crowbars, long bones serve as rigid levers that are acted upon by skeletal muscles to produce the major body movements. Various bones that do not fit the flat or long bone groups are sometimes called **short bones** (such as

<sup>1</sup>for, enter, enter = bone

#### CHAPTER OUTLINE

##### 7.1 Tissues and Organs of the Skeletal System

- Functions of the Skeleton
- Bones and Osseous Tissue
- General Features of Bones

##### 7.2 Physiology of Osseous Tissue

- Cells
- Matrix
- Joint Bone
- Flat Bone
- Marrow

##### 7.3 Development, Remodeling, Ossification, Growth and Remodeling

##### 7.4 Physiology of Osseous Tissue

- Mineral Deposition and Resorption
- Calcium Homeostasis
- Phosphate Homeostasis
- Other Factors Affecting Bone

##### 7.5 Bone Disorders

- Fractures and Their Repair
- Other Bone Disorders

##### Connective Tissues

##### Study Guide

#### DEEPER INSIGHTS

- 7.1 Medical History: Bone Contamination
- 7.2 Clinical Application: Achondroplastic Dwarfism
- 7.3 Clinical Application: Osseous Tissue and pH Balance
- 7.4 Clinical Application: Osteoporosis

Anatomy & Physiology  
**REVEALED**  
aprevealed.com

Module 5: Skeletal System

201

### Tiered Assessments Based on Key Learning Outcomes

- Chapters are divided into easily manageable chunks, which help students budget study time effectively.
- Section-ending questions allow students to check their understanding before moving on.

Each chapter begins with **Brushing Up** to emphasize the interrelatedness of concepts, and serves as an aid for instructors when teaching chapters out of order.

Each numbered section begins with **Expected Learning Outcomes** to help focus the reader's attention on the larger concepts and make the course outcome-driven. This also assists instructors in structuring their courses around expected learning outcomes.

## ▶▶▶ APPLY WHAT YOU KNOW

Some people have abnormal cords or bridges of myocardium that extend from atrium to ventricle, bypassing the AV node and other parts of the conduction system. How would you expect this to affect the cardiac rhythm?

**Questions** in figure legends and **Apply What You Know** items prompt students to think more deeply about the implications and applications of what they have learned. This helps students practice higher order thinking skills throughout the chapter.

The end-of-chapter **Study Guide** offers several methods for assessment that are useful to both students and instructors.

**Assess Your Learning Outcomes** provides students a study outline for review, and addresses the needs of instructors whose colleges require outcome-oriented syllabi and assessment of student achievement of the expected learning outcomes.

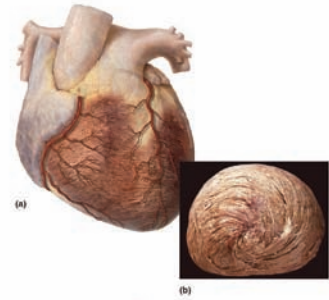
**End-of-chapter questions** build on all levels of Bloom's taxonomy in sections to

1. assess learning outcomes
2. test simple recall and analytical thought
3. build medical vocabulary
4. apply the basic knowledge to new clinical problems and other situations

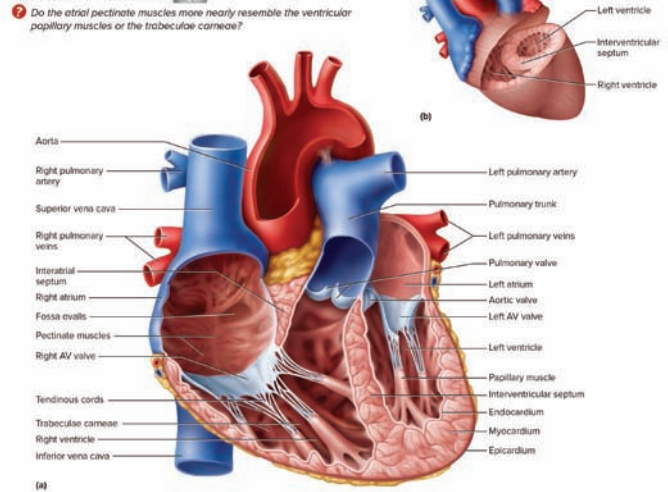
**What's Wrong with These Statements** questions further address Bloom's taxonomy by asking the student to explain *why* the false statements are untrue.

**Testing Your Comprehension** questions address Bloom's Taxonomy in going beyond recall to application of ideas.

**FIGURE 19.6 The Myocardial Vortex.** (a) Anterior view of the heart with the epicardium rendered transparent to expose the bundles of myocardial muscle. (b) View from the apex to show the way the muscle coils around the heart. This results in a twisting motion when the ventricles contract.



**FIGURE 19.7 Internal Anatomy of the Heart.** (a) Frontal section of heart, anterior view. (b) Cross section, showing shapes and spatial relationship of ventricles. The right ventricle wraps around the left in a C-shape, but both ventricles have the same volume. **APR**



CHAPTER 7 Bone Tissue 225

### STUDY GUIDE

**Assess Your Learning Outcomes**

In your own words, discuss the following topics with a study partner or in writing, ideally from memory.

7.1 Tissues and Organs of the Skeletal System

1. The route by which nerves and blood vessels penetrate through a bone.
2. Comparisons of the histology of spongy bone with that of compact bone; where spongy bone is found, and why bones are not composed solely of compact bone.
3. The origin and consequences of hypercalcemia and hypocalcemia.
4. The role of the skeleton as a calcium reservoir in regulating blood calcium levels.
5. How calcitriol is synthesized and the mechanism by which it supports or raises blood calcium levels.

226 PART TWO Support and Movement

### STUDY GUIDE

1. Osteoclasts are most closely related, by common descent, to
  - a. osteoprogenitor cells.
  - b. osteogenic cells.
  - c. blood cells.
  - d. fibroblasts.
  - e. osteoblasts.
2. The walls between cartilage lacunae break
  - a. collagen fibers.
  - b. hyaline cartilage crystals.
  - c. One long fiber meets another at its
    - a. diaphysis.
    - b. epiphyseal plate.
    - c. periosteum.
    - d. metaphysis.
    - e. osteoblasts.
3. A bone increases in diameter only by \_\_\_\_\_ growth, the addition of new outer lamellae.
4. Small crystals of hydroxyapatite form only when the levels of calcium and phosphate in the tissue fluid exceed the \_\_\_\_\_.
5. A calcium deficiency called \_\_\_\_\_ can

CHAPTER 7 Bone Tissue 227

### STUDY GUIDE

**Testing Your Comprehension**

1. Most osteocytes of an osseous are far removed from blood vessels, but still receive blood-borne nutrients. Explain how this is possible.
2. A 30-year-old business executive decides he has not been getting enough exercise for the last several years. He takes up hiking and finds that he really loves it. Within 2 years, he is spending many of his weekends hiking with a heavy backpack and camping in the mountains. Explain what changes in his anatomy could be predicted from Wolff's law of bone.
3. How does the regulation of blood calcium concentration exemplify negative feedback and homeostasis?
4. Describe how the arrangement of trabeculae in spongy bone demonstrates the unity of form and function.
5. Identify two bone diseases you would expect to see if the epidermis were a completely effective barrier to UV radiation and a person took no dietary supplements to compensate for this. Explain your answer.

**Improve Your Grade**

**connect** **SMARTBOOK®** **REVEALED!**

Connect Interactive Questions Refine your knowledge using multiple types of questions: interactive, estimation, classification, labeling, sequencing, composition, and traditional multiple choice and true/false.

SmartBook Proven to help students improve grades and study more efficiently, SmartBook contains the same content within the print book but actively tailors that content to the needs of the individual.

Anatomy & Physiology REVEALED! Dive into the human body by peeling back layers of cadaver imaging. Utilize this world-class cadaver dissection tool for a closer look at the body anytime, from anywhere.



# THE STORY OF FORM AND FUNCTION

## ARTWORK THAT INSPIRES LEARNING

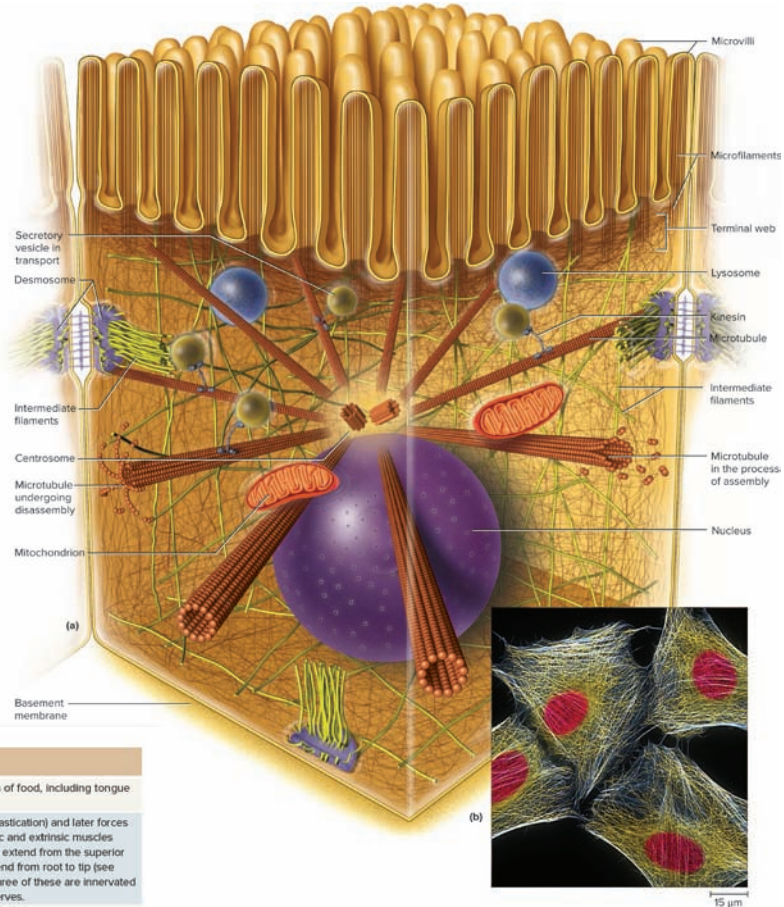
The incredible art program in this textbook sets the standard in A&P. The stunning portfolio of art and photos was created with the aid of art focus groups, and with feedback from hundreds of accuracy reviews.

### Conductive to Learning

- Easy-to-understand process figures
- Tools for students to easily orient themselves

### Vivid Illustrations

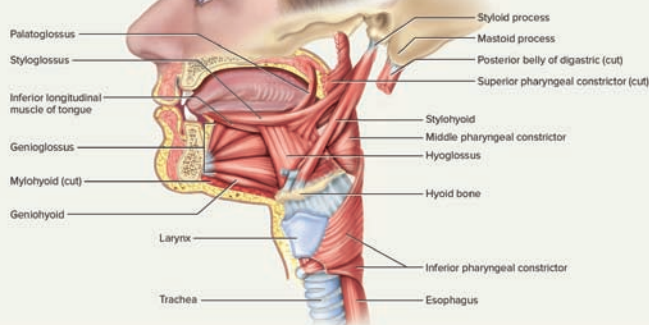
Rich textures and shading and bold, bright colors bring structures to life.



**TABLE 10.2** Muscles of Chewing and Swallowing

The following muscles contribute to facial expression and speech but are primarily concerned with the manipulation of food, including tongue movements, chewing, and swallowing.

**Extrinsic Muscles of the Tongue.** The tongue is a very agile organ. It pushes food between the molars for chewing (mastication) and later forces the food into the pharynx for swallowing (deglutition); it is also, of course, of crucial importance to speech. Both intrinsic and extrinsic muscles are responsible for its complex movements. The intrinsic muscles consist of a variable number of vertical fascicles that extend from the superior to the inferior sides of the tongue, transverse fascicles that extend from right to left, and longitudinal fascicles that extend from root to tip (see figs. 10.1c and 25.5b). The extrinsic muscles listed here connect the tongue to other structures in the head (fig. 10.9). Three of these are innervated by the hypoglossal nerve (CN XII), whereas the fourth is innervated by both the vagus (CN X) and accessory (CN XI) nerves.



**FIGURE 10.9** Muscles of the Tongue and Pharynx.

| Name  | Action   | Skeletal Attachments  | Innervation                |
|---|--|---|----------------------------|
| Genioglossus <sup>29</sup><br>(JEE-nee-oh-GLOSS-us) | Unilateral action draws tongue to one side; bilateral action depresses midline of tongue or protrudes tongue     | <ul style="list-style-type: none"> <li>• Superior mental spine on posterior surface of mental protuberance</li> <li>• Inferior surface of tongue from root to apex</li> </ul> | Hypoglossal nerve          |
| Hyoglossus <sup>30</sup><br>(HI-oh-GLOSS-us)        | Depresses tongue   | <ul style="list-style-type: none"> <li>• Body and greater horn of hyoid bone</li> <li>• Lateral and inferior surfaces of tongue</li> </ul>                                    | Hypoglossal nerve          |
| Styloglossus <sup>31</sup><br>(STY-lo-GLOSS-us)     | Draws tongue upward and posteriorly  | <ul style="list-style-type: none"> <li>• Styloid process of temporal bone and ligament from styloid process to mandible</li> <li>• Superolateral surface of tongue</li> </ul> | Hypoglossal nerve          |
| Palatoglossus <sup>32</sup><br>(PAL-a-toe-GLOSS-us) | Elevates root of tongue and closes oral cavity off from pharynx; forms palatoglossal arch at rear of oral cavity | <ul style="list-style-type: none"> <li>• Soft palate</li> <li>• Lateral surface of tongue</li> </ul>  | Accessory and vagus nerves |

<sup>29</sup>geni = chin; gloss = tongue  
<sup>30</sup>hyo = hyoid bone; gloss = tongue

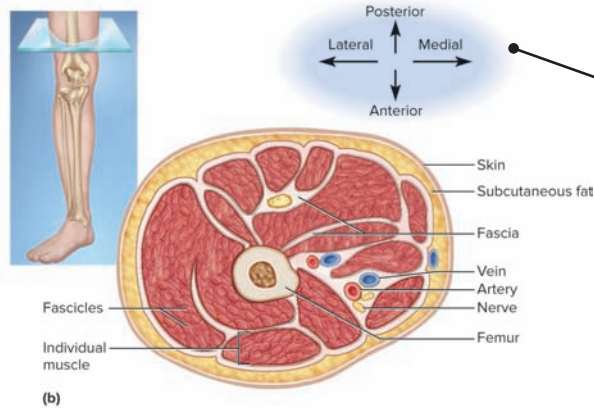
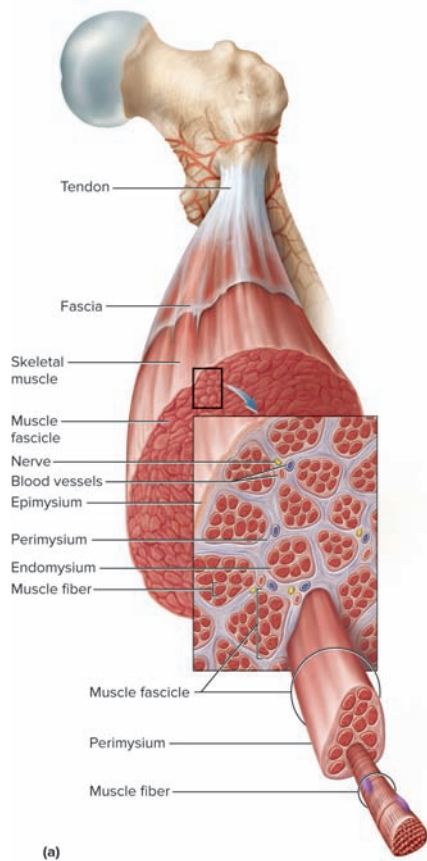
<sup>31</sup>styla = styloid process; gloss = tongue  
<sup>32</sup>palato = palate; gloss = tongue

### Muscle Tables

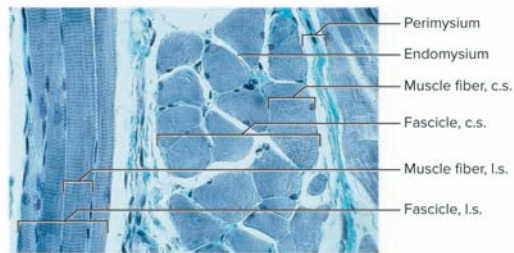
Muscle tables organize information and integrate stunning visuals to help students learn. They also serve as a great student reference for study.

*The visual appeal of nature is immensely important in motivating one to study it. We certainly see this at work in human anatomy—in the countless students who describe themselves as visual learners, in the many laypeople who find anatomy atlases so intriguing, and in the enormous popularity of Body Worlds and similar exhibitions of human anatomy.*

—Ken Saladin



(b)



(c)

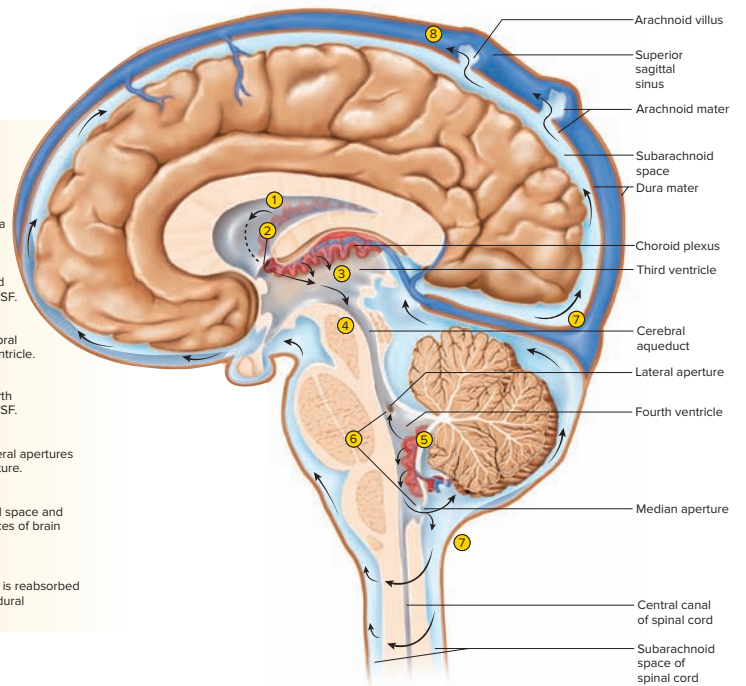
### Orientation Tools

Saladin art integrates tools to help students quickly orient themselves within a figure and make connections between ideas.

### Process Figures

Saladin breaks complicated physiological processes into numbered steps for a manageable introduction to difficult concepts.

- 1 CSF is secreted by choroid plexus in each lateral ventricle.
- 2 CSF flows through interventricular foramina into third ventricle.
- 3 Choroid plexus in third ventricle adds more CSF.
- 4 CSF flows down cerebral aqueduct to fourth ventricle.
- 5 Choroid plexus in fourth ventricle adds more CSF.
- 6 CSF flows out two lateral apertures and one median aperture.
- 7 CSF fills subarachnoid space and bathes external surfaces of brain and spinal cord.
- 8 At arachnoid villi, CSF is reabsorbed into venous blood of dural venous sinuses.



# WHAT'S NEW IN THE EIGHTH EDITION?

## New Scientific Content

Saladin's *Anatomy & Physiology*, eighth edition, has about 85 updates in scientific content, keeping abreast of new literature and new interpretations of old assumptions, including:

- New guidelines on cholesterol and *trans* fats (chapter 2)
- New skin-grafting method (chapter 6)
- New coverage of the genetics and evolution of lactose intolerance (chapter 25)
- New federal guidelines for recommended dietary intakes (chapter 26)
- Updates on papillomavirus, genital warts, and cervical cancer (chapter 27)

For a complete list, please visit [www.mcgrawhillconnect.com](http://www.mcgrawhillconnect.com).

## New Photographs

This edition contains many new photographs, including:

- Figure 1.10: new brain scans
- Figure 7.20: osteoporosis with kyphosis
- Figure 19.22: coronary artery disease
- Figure 20.1: vascular cast of thyroid gland capillary beds
- Figure 29.7: embryonic and fetal developmental stages

For a complete list, please visit [www.mcgrawhillconnect.com](http://www.mcgrawhillconnect.com).

## New Pedagogy

- In each chapter Study Guide, where students were previously prompted to distinguish between five true and five false statements, they are now prompted to analyze the fallacies of 10 false statements.
- This edition deletes 21 increasingly obsolete eponymous terms that are no longer recommended by the *Terminologia Anatomica* or *Gray's Anatomy* (such as *Skene glands*, *Howship lacunae*, *Auerbach plexus*, *Hassall corpuscles*, and *organ of Corti*) and replaces them with the standard English terms for easier student comprehension and retention.
- The explanation of units of chemical concentration is moved from chapter 2 to appendix C.

## Enhanced Concepts

Saladin's *Anatomy & Physiology*, eighth edition, also updates and enhances about 25 more major physiological concepts in response to user feedback, including:

- Chapter 3: leak and gated channels
- Chapter 4: functions of intron DNA, small regulatory RNAs, and cell-cycle regulators
- Chapter 11: the lactate threshold
- Chapter 12: the vasomotor role of astrocytes, serial and parallel processing in neural circuits, long-term depression and forgetting
- Chapter 14: the role of orexins in the sleep–wake cycle, Bell palsy
- Chapter 16: tactile functions of lingual papillae, function of oblique muscles of the eye
- Chapter 17: stimuli inducing secretion of individual hormones, photoperiod and pineal gland function
- Chapter 18: ABO blood types in hemolytic disease of the newborn, lymphocyte selection in the thymus
- Chapter 20: sympathetic effects on coronary arteries
- Chapter 21: precipitation versus agglutination in antibody action
- Chapter 25: membrane transport of dietary triglycerides, blood circulation of the colon
- Chapter 26: fuller coverage of hepatitis, fuller coverage of core versus shell body temperature
- Chapter 27: structure and function of the male prepuce



- Chapter 28: history of mastectomy approaches, leptin and adiposity in relation to menarche, endometriosis
- Chapter 29: telomere repair and cancer

## Enhanced Artwork

This edition contains many pieces of enhanced artwork, including:

- Figure 3.15: mechanism of osmosis
- Figure 3.28: structure of the cell nucleus
- Figure 11.6: organization and size principle of motor units
- Figure 14.13: functions of the five cerebral lobes
- Figure 15.2: somatic versus autonomic outflow pathways
- Figure 19.7: cross-sectional shapes and relationships of heart ventricles
- Figure 20.4: schematic of blood distribution in rest and exercise
- Figure 25.18: positive feedback control of gastric secretion
- Figure 25.31: pathways of nutrient digestion and assimilation
- Figure 26.12: environmental temperatures versus core and shell body temperatures

For a complete list, please visit [www.mcgrawhillconnect.com](http://www.mcgrawhillconnect.com).

## Enhanced Data-Driven Revision

Thousands of students have interacted with this textbook via McGraw-Hill Education's adaptive reading experience, SmartBook®. Data about these interactions are collected over time and visually displayed in a heat map. Heat maps direct the author's attention to areas where students are struggling. The author then evaluates the questions and associated text content to determine if revisions are needed to more clearly ask the question or clarify explanations. Heat maps can also confirm areas that the text is successful in aiding students' comprehension. This edition was revised using heat map data to clarify explanations, and to enhance the SmartBook® experience for all students.

## New Digital Enhancements

**Faculty now have the ability to assign select LearnSmart® questions in Connect®.** The question bank in Connect® has select probes from SmartBook® available for you to assign on assignments or quizzes as you see fit.

**The 8<sup>th</sup> edition provides SmartBook® sub-section assignability.** SmartBook® assignments now go beyond section level to give instructors a more granular level of content.

**Four new Concept Overview Interactive animations give exploration and engagement on key concepts:** Innate Immunity; Adaptive Immunity; Blood Pressure; Endocrine System, in addition to the existing Glomerular Filtration and Its Regulation; Tubular Reabsorption and Tubular Secretion; Neuron Physiology; Passive and Active Processes of Membrane Transport; Skeletal Muscle Contraction; Changes Associated with a Cardiac Cycle; and The Movement of Oxygen and Carbon Dioxide. This brings the total Concept Overview Interactive animations to 11. They can be used in class, as a study tool, and are assignable in modules with associated questions. The animations were recently converted to html for mobile compatibility.

**Anatomy and Physiology REVEALED® 3.2** cadaver dissection simulator is available with Connect® Anatomy & Physiology. Now in html for mobile compatibility, with customizable anatomical structure list, version 3.2 offers 50 new animations, and 7 added physiology interactives.

**Enhanced focus on encouraging critical thinking.** Connect® question banks now have 30% or more questions at Bloom's level 3 (apply) or higher.

**SmartBook® includes additional Learning Resources** – McGraw-Hill Education, using student usage data, determined the most difficult concepts for students. Additional study tools (tutorial videos, narrated slides, interactive activities) are now available for those difficult concepts in SmartBook®, just when the student needs it!

**Assignable Connect® orientation videos** available in the question bank can be assigned to help students get acquainted with Connect® and best practices for use.

**Assignable APR, Ph.I.L.S, diagnostic prep exams, model questions and more!** Course-wide A&P content gives a much larger pool of assignable content so instructors can easily tailor the course to their needs.



©Getty Images/iStockphoto

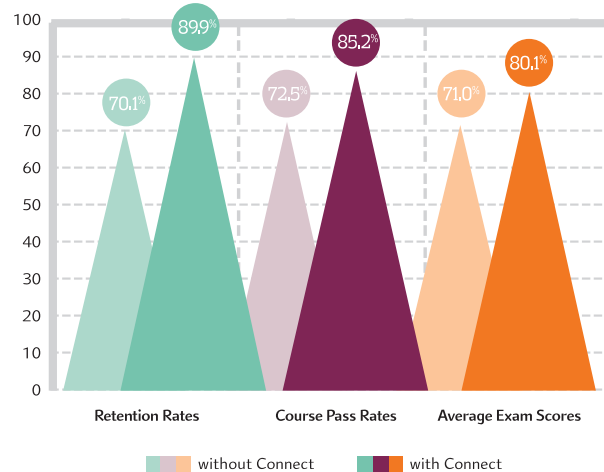
## McGraw-Hill Connect® Learn Without Limits

Connect is a teaching and learning platform that is proven to deliver better results for students and instructors.

Connect empowers students by continually adapting to deliver precisely what they need, when they need it, and how they need it, so your class time is more engaging and effective.

73% of instructors who use **Connect** require it; instructor satisfaction **increases by 28%** when **Connect** is required.

### Connect's Impact on Retention Rates, Pass Rates, and Average Exam Scores



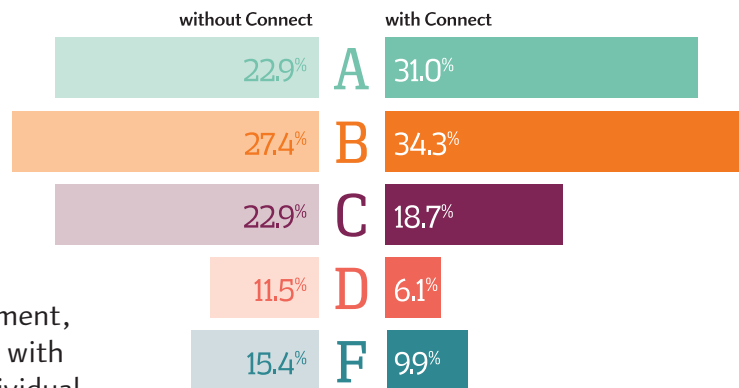
Using **Connect** improves retention rates by **19.8%**, passing rates by **12.7%**, and exam scores by **9.1%**.

## Analytics

### Connect Insight®

Connect Insight is Connect's new one-of-a-kind visual analytics dashboard—now available for both instructors and students—that provides at-a-glance information regarding student performance, which is immediately actionable. By presenting assignment, assessment, and topical performance results together with a time metric that is easily visible for aggregate or individual results, Connect Insight gives the user the ability to take a just-in-time approach to teaching and learning, which was never before available. Connect Insight presents data that empowers students and helps instructors improve class performance in a way that is efficient and effective.

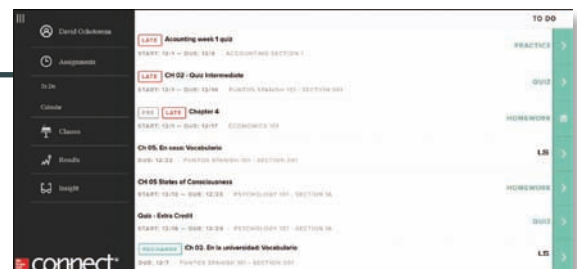
### Impact on Final Course Grade Distribution



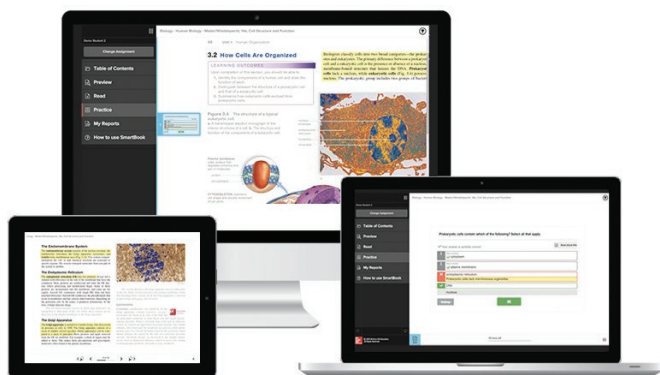Students can view their results for any **Connect** course.

## Mobile

Connect's new, intuitive mobile interface gives students and instructors flexible and convenient, anytime-anywhere access to all components of the Connect platform.



# Adaptive



## THE ADAPTIVE READING EXPERIENCE DESIGNED TO TRANSFORM THE WAY STUDENTS READ

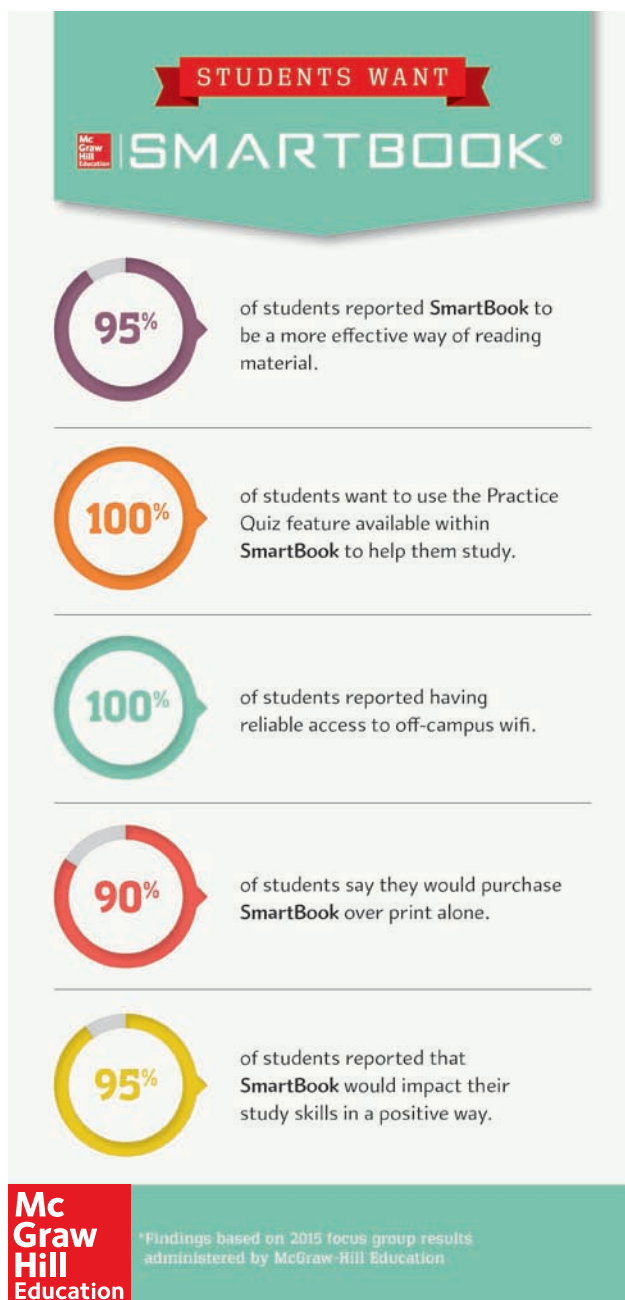More students earn **A's** and **B's** when they use McGraw-Hill Education **Adaptive** products.

### SmartBook®

Proven to help students improve grades and study more efficiently, SmartBook contains the same content within the print book, but actively tailors that content to the needs of the individual. SmartBook's adaptive technology provides precise, personalized instruction on what the student should do next, guiding the student to master and remember key concepts, targeting gaps in knowledge and offering customized feedback, and driving the student toward comprehension and retention of the subject matter. Available on tablets, SmartBook puts learning at the student's fingertips—anywhere, anytime.

Over **8 billion** questions have been answered, making McGraw-Hill Education products more intelligent, reliable, and precise.

[www.mheducation.com](http://www.mheducation.com)



# 50% of the country's students are not ready for A&P

## LearnSmart® Prep can help!

Improve preparation for the course and increase student success with the only adaptive Prep tool available for students today. Areas of individual weaknesses are identified in order to help students improve their understanding of core course areas needed to succeed.

**LEARNSMART®**

*Prep for A&P*

Anatomy & Physiology | **REVEALED®**  
3.2

*Virtual dissection*

Students seek lab time that fits their busy schedules. Anatomy & Physiology REVEALED 3.2, our Virtual Dissection tool, allows them practice anytime, anywhere. Now featuring enhanced physiology with Concept Overview Interactives and 3D animations!

Bringing to life complex processes is a challenge. Ph.I.L.S. 4.0 is the perfect way to reinforce key physiology concepts with powerful lab experiments. Tools like Concept Overview Interactives, Ph.I.L.S., and world-class animations make it easier than ever.

**Ph.I.L.S.**

*Physiology supplements*

Since 2009, our adaptive programs in A&P have hosted 900,000 unique users who have answered more than 800 million probes, giving us the only data-driven solutions to help your students get from their first college-level course to program readiness.

# CONTENTS

About the Authors iv

## **PART ONE**

### **ORGANIZATION OF THE BODY**

#### **CHAPTER 1**

##### **MAJOR THEMES OF ANATOMY AND PHYSIOLOGY 1**

- 1.1 The Scope of Anatomy and Physiology 2
- 1.2 The Origins of Biomedical Science 3
- 1.3 Scientific Method 6
- 1.4 Human Origins and Adaptations 9
- 1.5 Human Structure 11
- 1.6 Human Function 13
- 1.7 The Language of Medicine 19
- 1.8 Review of Major Themes 21

##### **STUDY GUIDE 24**

#### **ATLAS A**

##### **GENERAL ORIENTATION TO HUMAN ANATOMY 27**

- A.1 General Anatomical Terminology 28
- A.2 Major Body Regions 29
- A.3 Body Cavities and Membranes 32
- A.4 Organ Systems 35

##### **STUDY GUIDE 38**

#### **CHAPTER 2**

##### **THE CHEMISTRY OF LIFE 41**

- 2.1 Atoms, Ions, and Molecules 42
- 2.2 Water and Mixtures 49
- 2.3 Energy and Chemical Reactions 53
- 2.4 Organic Compounds 56

##### **STUDY GUIDE 72**

#### **CHAPTER 3**

##### **CELLULAR FORM AND FUNCTION 75**

- 3.1 Concepts of Cellular Structure 76
- 3.2 The Cell Surface 80
- 3.3 Membrane Transport 88
- 3.4 The Cell Interior 98

##### **STUDY GUIDE 108**

#### **CHAPTER 4**

##### **GENETICS AND CELLULAR FUNCTION 111**

- 4.1 DNA and RNA—The Nucleic Acids 112
- 4.2 Genes and Their Action 117
- 4.3 DNA Replication and the Cell Cycle 126
- 4.4 Chromosomes and Heredity 130

##### **STUDY GUIDE 136**

#### **CHAPTER 5**

##### **HISTOLOGY 139**

- 5.1 The Study of Tissues 140
- 5.2 Epithelial Tissue 143
- 5.3 Connective Tissue 149
- 5.4 Nervous and Muscular Tissues—Excitable Tissues 158
- 5.5 Cell Junctions, Glands, and Membranes 160
- 5.6 Tissue Growth, Development, Repair, and Degeneration 167

##### **STUDY GUIDE 172**

## **PART TWO**

### **SUPPORT AND MOVEMENT**

#### **CHAPTER 6**

##### **THE INTEGUMENTARY SYSTEM 175**

- 6.1 The Skin and Subcutaneous Tissue 176
- 6.2 Hair and Nails 184
- 6.3 Cutaneous Glands 189

- 6.4 Skin Disorders 192

##### **CONNECTIVE ISSUES 197**

##### **STUDY GUIDE 198**

#### **CHAPTER 7**

##### **BONE TISSUE 201**

- 7.1 Tissues and Organs of the Skeletal System 202
- 7.2 Histology of Osseous Tissue 204
- 7.3 Bone Development 208
- 7.4 Physiology of Osseous Tissue 215
- 7.5 Bone Disorders 220

##### **CONNECTIVE ISSUES 224**

##### **STUDY GUIDE 225**

#### **CHAPTER 8**

##### **THE SKELETAL SYSTEM 228**

- 8.1 Overview of the Skeleton 229
- 8.2 The Skull 231
- 8.3 The Vertebral Column and Thoracic Cage 245
- 8.4 The Pectoral Girdle and Upper Limb 254
- 8.5 The Pelvic Girdle and Lower Limb 258

##### **STUDY GUIDE 270**

#### **CHAPTER 9**

##### **JOINTS 273**

- 9.1 Joints and Their Classification 274
- 9.2 Synovial Joints 278
- 9.3 Anatomy of Selected Diarthroses 292

##### **STUDY GUIDE 304**

#### **CHAPTER 10**

##### **THE MUSCULAR SYSTEM 307**

- 10.1 Structural and Functional Organization of Muscles 308
- 10.2 Muscles of the Head and Neck 317
- 10.3 Muscles of the Trunk 328
- 10.4 Muscles Acting on the Shoulder and Upper Limb 338



10.5 Muscles Acting on the Hip and Lower Limb 354

**STUDY GUIDE 370**

## **ATLAS B**

**REGIONAL AND SURFACE ANATOMY 373**

- B.1 Regional Anatomy 374
- B.2 The Importance of Surface Anatomy 374
- B.3 Learning Strategy 374

## **CHAPTER 11**

**MUSCULAR TISSUE 395**

- 11.1 Types and Characteristics of Muscular Tissue 396
- 11.2 Microscopic Anatomy of Skeletal Muscle 397
- 11.3 The Nerve–Muscle Relationship 402
- 11.4 Behavior of Skeletal Muscle Fibers 405
- 11.5 Behavior of Whole Muscles 412
- 11.6 Muscle Metabolism 415
- 11.7 Cardiac and Smooth Muscle 420

**CONNECTIVE ISSUES 427**

**STUDY GUIDE 428**

## **PART THREE**

### **INTERNAL COORDINATION AND CONTROL**

#### **CHAPTER 12**

**NERVOUS TISSUE 431**

- 12.1 Overview of the Nervous System 432
- 12.2 Properties of Neurons 433
- 12.3 Supportive Cells (Neuroglia) 438
- 12.4 Electrophysiology of Neurons 443
- 12.5 Synapses 451
- 12.6 Neural Integration 457

**CONNECTIVE ISSUES 467**

**STUDY GUIDE 468**

#### **CHAPTER 13**

**THE SPINAL CORD, SPINAL NERVES, AND SOMATIC REFLEXES 471**

- 13.1 The Spinal Cord 472

13.2 The Spinal Nerves 480

13.3 Somatic Reflexes 493

**STUDY GUIDE 501**

#### **CHAPTER 14**

**THE BRAIN AND CRANIAL NERVES 504**

- 14.1 Overview of the Brain 505
- 14.2 Meninges, Ventricles, Cerebrospinal Fluid, and Blood Supply 509
- 14.3 The Hindbrain and Midbrain 514
- 14.4 The Forebrain 521
- 14.5 Integrative Functions of the Brain 527
- 14.6 The Cranial Nerves 538

**STUDY GUIDE 551**

#### **CHAPTER 15**

**THE AUTONOMIC NERVOUS SYSTEM AND VISCERAL REFLEXES 554**

- 15.1 General Properties of the Autonomic Nervous System 555
- 15.2 Anatomy of the Autonomic Nervous System 558
- 15.3 Autonomic Effects on Target Organs 565
- 15.4 Central Control of Autonomic Function 569

**STUDY GUIDE 572**

#### **CHAPTER 16**

**SENSE ORGANS 575**

- 16.1 Properties and Types of Sensory Receptors 576
- 16.2 The General Senses 578
- 16.3 The Chemical Senses 584
- 16.4 Hearing and Equilibrium 589
- 16.5 Vision 603

**STUDY GUIDE 622**

#### **CHAPTER 17**

**THE ENDOCRINE SYSTEM 626**

- 17.1 Overview of the Endocrine System 627
- 17.2 The Hypothalamus and Pituitary Gland 630
- 17.3 Other Endocrine Glands 637

17.4 Hormones and Their Actions 647

17.5 Stress and Adaptation 656

17.6 Eicosanoids and Other Signaling Molecules 657

17.7 Endocrine Disorders 659

**CONNECTIVE ISSUES 665**

**STUDY GUIDE 666**

## **PART FOUR**

### **CIRCULATION AND DEFENSE**

#### **CHAPTER 18**

**THE CIRCULATORY SYSTEM: BLOOD 669**

- 18.1 Introduction 670
- 18.2 Erythrocytes 675
- 18.3 Blood Types 682
- 18.4 Leukocytes 687
- 18.5 Platelets and Hemostasis—The Control of Bleeding 693

**STUDY GUIDE 702**

#### **CHAPTER 19**

**THE CIRCULATORY SYSTEM: HEART 705**

- 19.1 Overview of the Cardiovascular System 706
- 19.2 Gross Anatomy of the Heart 708
- 19.3 Cardiac Muscle and the Cardiac Conduction System 717
- 19.4 Electrical and Contractile Activity of the Heart 719
- 19.5 Blood Flow, Heart Sounds, and the Cardiac Cycle 725
- 19.6 Cardiac Output 731

**STUDY GUIDE 738**

#### **CHAPTER 20**

**THE CIRCULATORY SYSTEM: BLOOD VESSELS AND CIRCULATION 741**

- 20.1 General Anatomy of the Blood Vessels 742
- 20.2 Blood Pressure, Resistance, and Flow 750
- 20.3 Capillary Exchange 756
- 20.4 Venous Return and Circulatory Shock 760

20.5 Special Circulatory Routes 763  
20.6 Anatomy of the Pulmonary Circuit 764  
20.7 Systemic Vessels of the Axial Region 765  
20.8 Systemic Vessels of the Appendicular Region 784  
**CONNECTIVE ISSUES 795**  
**STUDY GUIDE 796**

## **CHAPTER 21**

**THE LYMPHATIC AND IMMUNE SYSTEMS 800**

21.1 The Lymphatic System 801  
21.2 Innate Immunity 814  
21.3 Adaptive Immunity—General Aspects 822  
21.4 Cellular Immunity 827  
21.5 Humoral Immunity 830  
21.6 Immune System Disorders 835  
**CONNECTIVE ISSUES 841**  
**STUDY GUIDE 842**

## **PART FIVE**

### **INTAKE AND OUTPUT**

#### **CHAPTER 22**

**THE RESPIRATORY SYSTEM 845**  
22.1 Anatomy of the Respiratory System 846  
22.2 Pulmonary Ventilation 857  
22.3 Gas Exchange and Transport 868  
22.4 Respiratory Disorders 878  
**CONNECTIVE ISSUES 882**  
**STUDY GUIDE 883**

#### **CHAPTER 23**

**THE URINARY SYSTEM 886**  
23.1 Functions of the Urinary System 887  
23.2 Anatomy of the Kidney 889  
23.3 Urine Formation I: Glomerular Filtration 895  
23.4 Urine Formation II: Tubular Reabsorption and Secretion 901  
23.5 Urine Formation III: Water Conservation 905  
23.6 Urine and Renal Function Tests 908

23.7 Urine Storage and Elimination 911  
**CONNECTIVE ISSUES 917**  
**STUDY GUIDE 918**

#### **CHAPTER 24**

**FLUID, ELECTROLYTE, AND ACID–BASE BALANCE 921**  
24.1 Fluid Balance 922  
24.2 Electrolyte Balance 928  
24.3 Acid–Base Balance 933  
**STUDY GUIDE 941**

#### **CHAPTER 25**

**THE DIGESTIVE SYSTEM 944**  
25.1 General Anatomy and Digestive Processes 945  
25.2 The Mouth Through Esophagus 949  
25.3 The Stomach 956  
25.4 The Liver, Gallbladder, and Pancreas 965  
25.5 The Small Intestine 971  
25.6 Chemical Digestion and Absorption 974  
25.7 The Large Intestine 981  
**CONNECTIVE ISSUES 987**  
**STUDY GUIDE 988**

#### **CHAPTER 26**

**NUTRITION AND METABOLISM 991**  
26.1 Nutrition 992  
26.2 Carbohydrate Metabolism 1003  
26.3 Lipid and Protein Metabolism 1010  
26.4 Metabolic States and Metabolic Rate 1012  
26.5 Body Heat and Thermoregulation 1016  
**STUDY GUIDE 1021**

## **PART SIX**

### **REPRODUCTION AND THE LIFE CYCLE**

#### **CHAPTER 27**

**THE MALE REPRODUCTIVE SYSTEM 1025**  
27.1 Sexual Reproduction and Development 1026

27.2 Male Reproductive Anatomy 1031  
27.3 Puberty, Hormonal Control, and Climacteric 1039  
27.4 Sperm and Semen 1041  
27.5 Male Sexual Response 1046  
**STUDY GUIDE 1052**

#### **CHAPTER 28**

**THE FEMALE REPRODUCTIVE SYSTEM 1055**  
28.1 Reproductive Anatomy 1056  
28.2 Puberty and Menopause 1066  
28.3 Oogenesis and the Sexual Cycle 1068  
28.4 Female Sexual Response 1076  
28.5 Pregnancy and Childbirth 1077  
28.6 Lactation 1084  
**CONNECTIVE ISSUES 1089**  
**STUDY GUIDE 1090**

#### **CHAPTER 29**

**HUMAN DEVELOPMENT AND AGING 1093**  
29.1 Fertilization and the Preembryonic Stage 1094  
29.2 The Embryonic and Fetal Stages 1100  
29.3 The Neonate 1109  
29.4 Aging and Senescence 1114  
**STUDY GUIDE 1123**

**APPENDIX A: PERIODIC TABLE OF THE ELEMENTS A-1**

**APPENDIX B: ANSWER KEYS A-2**

**APPENDIX C: SYMBOLS, WEIGHTS, AND MEASURES A-15**

**APPENDIX D: BIOMEDICAL ABBREVIATIONS A-18**

**APPENDIX E: THE GENETIC CODE A-19**

**APPENDIX F: LEXICON OF BIOMEDICAL WORD ELEMENTS A-20**

**APPENDIX G: EIGHTH EDITION CHANGES IN TERMINOLOGY A-24**

**GLOSSARY G-1**

**INDEX I-1**

# LETTER TO STUDENTS

**W**hen I was a young boy, I became interested in what I then called “nature study” for two reasons. One was the sheer beauty of nature. I reveled in children’s books with abundant, colorful drawings and photographs of animals, plants, minerals, and gems. It was this esthetic appreciation of nature that made me want to learn more about it and made me happily surprised to discover I could make a career of it. At a slightly later age, another thing that drew me still deeper into biology was to discover writers who had a way with words—who could captivate my imagination and curiosity with their elegant prose. Once I was old enough to hold part-time jobs, I began buying zoology and anatomy books that mesmerized me with their gracefulness of writing and fascinating art and photography. I wanted to write and draw like that myself, and I began teaching myself by learning from “the masters.” I spent many late nights in my room peering into my microscope and jars of pond water, typing page after page of manuscript, and trying pen and ink as an art medium. My “first book” was a 318-page paper on some little pond animals called hydras, with 53 India ink illustrations that I wrote for my tenth-grade biology class when I was 16 (see page v).

Fast-forward about 30 years, to when I became a textbook writer, and I found myself bringing that same enjoyment of writing and illustrating to the first edition of this book you are now holding. Why? Not only for its intrinsic creative satisfaction, but because I’m guessing that you’re like I was—you can appreciate a book that does more than simply give you the information you need. You appreciate, I trust, a writer who makes it enjoyable for you through his scientific, storytelling prose and his concept of the way things should be illustrated to spark interest and facilitate understanding.

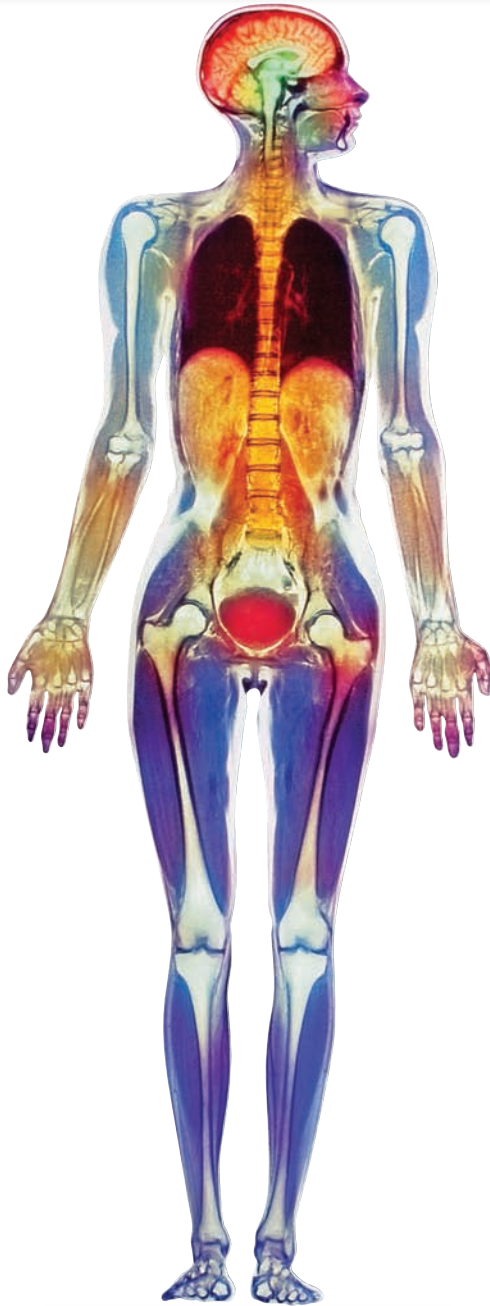
I know from my own students, however, that you need more than captivating illustrations and enjoyable reading. Let’s face it—A&P is a complex subject and it may seem a formidable task to acquire even a basic knowledge of the human body. It was difficult even for me to learn (and the learning never ends). So in addition to simply writing this book, I’ve given a lot of thought to its

pedagogy—the art of teaching. I’ve designed my chapters to make them easier for you to study and to give you abundant opportunity to check whether you’ve understood what you read—to test yourself (as I advise my own students) before the instructor tests you.

Each chapter is broken down into short, digestible bits with a set of Expected Learning Outcomes at the beginning of each section, and self-testing questions (Before You Go On) just a few pages later. Even if you have just 30 minutes to read during a lunch break or a bus ride, you can easily read or review one of these brief sections. There are also numerous self-testing questions in a Study Guide at the end of each chapter, in some of the figure legends, and the occasional Apply What You Know questions dispersed throughout each chapter. The questions cover a broad range of cognitive skills, from simple recall of a term to your ability to evaluate, analyze, and apply what you’ve learned to new clinical situations or other problems. In this era of digital publishing, however, learning aids go far beyond what I write into the book itself. SmartBook®, available on smartphones and tablets, includes all of the book’s contents plus adaptive technology that can give you personalized instruction, target the unique gaps in your knowledge, and guide you in comprehension and retention of the subject matter.

I hope you enjoy your study of this book, but I know there are always ways to make it even better. Indeed, what quality you may find in this edition owes a great deal to feedback I’ve received from students all over the world. If you find any typos or other errors, if you have any suggestions for improvement, if I can clarify a concept for you, or even if you just want to comment on something you really like about the book, I hope you’ll feel free to write to me. I correspond quite a lot with students and would enjoy hearing from you.

Ken Saladin  
Georgia College  
Milledgeville, GA 31061 (USA)  
ksaladin2@windstream.net



A colorized MRI scan of the human body  
© Simon Fraser/Getty Images

CHAPTER 1

# MAJOR THEMES OF ANATOMY AND PHYSIOLOGY

## CHAPTER OUTLINE

- 1.1** The Scope of Anatomy and Physiology
  - Anatomy—The Study of Form
  - Physiology—The Study of Function
- 1.2** The Origins of Biomedical Science
  - The Greek and Roman Legacy
  - The Birth of Modern Medicine
  - Living in a Revolution
- 1.3** Scientific Method
  - The Inductive Method
  - The Hypothetico–Deductive Method
  - Experimental Design
  - Peer Review
  - Facts, Laws, and Theories
- 1.4** Human Origins and Adaptations
  - Evolution, Selection, and Adaptation
  - Our Basic Primate Adaptations
  - Walking Upright
- 1.5** Human Structure
  - The Hierarchy of Complexity
  - Anatomical Variation
- 1.6** Human Function
  - Characteristics of Life
  - Physiological Variation
  - Homeostasis and Negative Feedback
  - Positive Feedback and Rapid Change
  - Gradients and Flow

- 1.7** The Language of Medicine
  - The History of Anatomical Terminology
  - Analyzing Medical Terms
  - Plural, Adjectival, and Possessive Forms
  - Pronunciation
  - The Importance of Precision
- 1.8** Review of Major Themes

Study Guide

## DEEPER INSIGHTS

- 1.1** Evolutionary Medicine: Vestiges of Human Evolution
- 1.2** Clinical Application: Situs Inversus and Other Unusual Anatomy
- 1.3** Medical History: Men in the Oven
- 1.4** Medical History: Obscure Word Origins
- 1.5** Clinical Application: Medical Imaging

Anatomy & Physiology | REVEALED®  
aprevealed.com

Module 1: Body Orientation



No branch of science hits as close to home as the science of our own bodies. We're grateful for the dependability of our hearts; we're awed by the capabilities of muscles and joints displayed by Olympic athletes; and we ponder with philosophers the ancient mysteries of mind and emotion. We want to know how our body works, and when it malfunctions, we want to know what's happening and what we can do about it. Even the most ancient writings of civilization include medical documents that attest to humanity's timeless drive to know itself. You are embarking on a subject that is as old as civilization, yet one that grows by thousands of scientific publications every week.

This book is an introduction to human structure and function, the biology of the human body. It is meant primarily to give you a foundation for advanced study in health care, exercise physiology, pathology, and other fields related to health and fitness. Beyond that purpose, however, it can also provide you with a deeply satisfying sense of self-understanding.

As rewarding and engrossing as this subject is, the human body is highly complex, and understanding it requires us to comprehend a great deal of detail. The details will be more manageable if we relate them to a few broad, unifying concepts. The aim of this chapter, therefore, is to introduce such concepts and put the rest of the book into perspective. We consider the historical development of anatomy and physiology, the thought processes that led to the knowledge in this book, the meaning of human life, some central concepts of physiology, and how to better understand medical terminology.

## 1.1 The Scope of Anatomy and Physiology

### Expected Learning Outcomes

When you have completed this section, you should be able to

- define *anatomy* and *physiology* and relate them to each other;
- describe several ways of studying human anatomy; and
- define a few subdisciplines of human physiology.

**Anatomy** is the study of structure, and **physiology** is the study of function. These approaches are complementary and never entirely separable. Together, they form the bedrock of the health sciences. When we study a structure, we want to know, What does it do? Physiology thus lends meaning to anatomy; conversely, anatomy is what makes physiology possible. This *unity of form and function* is an important point to bear in mind as you study the body. Many examples of it will be apparent throughout the book—some of them pointed out for you, and others you will notice for yourself.

### Anatomy—The Study of Form

There are several ways to examine the structure of the human body. The simplest is **inspection**—simply looking at the body's appearance, as in performing a physical examination or making

a clinical diagnosis from surface appearance. Physical examinations also involve touching and listening to the body. **Palpation**<sup>1</sup> means feeling a structure with the hands, such as palpating a swollen lymph node or taking a pulse. **Auscultation**<sup>2</sup> (AWS-cul-TAY-shun) is listening to the natural sounds made by the body, such as heart and lung sounds. In **percussion**, the examiner taps on the body, feels for abnormal resistance, and listens to the emitted sound for signs of abnormalities such as pockets of fluid, air, or scar tissue.

But a deeper understanding of the body depends on **dissection** (dis-SEC-shun)—carefully cutting and separating tissues to reveal their relationships. The very words *anatomy*<sup>3</sup> and *dissection*<sup>4</sup> both mean “cutting apart”; until the nineteenth century, dissection was called “anatomizing.” In many schools of health science, one of the first steps in training students is dissection of the **cadaver**,<sup>5</sup> a dead human body. Many insights into human structure are obtained from **comparative anatomy**—the study of multiple species in order to examine similarities and differences and analyze evolutionary trends. Anatomy students often begin by dissecting other animals with which we share a common ancestry and many structural similarities. Many of the reasons for human structure become apparent only when we look at the structure of other animals.

Dissection, of course, is not the method of choice when studying a living person! It was once common to diagnose disorders through **exploratory surgery**—opening the body and taking a look inside to see what was wrong and what could be done about it. Any breach of the body cavities is risky, however, and most exploratory surgery has now been replaced by **medical imaging** techniques—methods of viewing the inside of the body without surgery, discussed at the end of this chapter (see Deeper Insight 1.5). The branch of medicine concerned with imaging is called **radiology**. Structure that can be seen with the naked eye—whether by surface observation, radiology, or dissection—is called **gross anatomy**.

Ultimately, the functions of the body result from its individual cells. To see those, we usually take tissue specimens, thinly slice and stain them, and observe them under the microscope. This approach is called **histology**<sup>6</sup> (**microscopic anatomy**). **Histopathology** is the microscopic examination of tissues for signs of disease. **Cytology**<sup>7</sup> is the study of the structure and function of individual cells. **Ultrastructure** refers to fine detail, down to the molecular level, revealed by the electron microscope.

### Physiology—The Study of Function

Physiology<sup>8</sup> uses the methods of experimental science discussed later. It has many subdisciplines such as *neurophysiology* (physiology of the nervous system), *endocrinology* (physiology of

<sup>1</sup>palp = touch, feel; ation = process

<sup>2</sup>auscult = listen; ation = process

<sup>3</sup>ana = apart; tom = cut

<sup>4</sup>dis = apart; sect = cut

<sup>5</sup>from cadere = to fall down or die

<sup>6</sup>histo = tissue; logy = study of

<sup>7</sup>cyto = cell; logy = study of

<sup>8</sup>physio = nature; logy = study of



hormones), and *pathophysiology* (mechanisms of disease). Partly because of limitations on experimentation with humans, much of what we know about bodily function has been gained through **comparative physiology**, the study of how different species have solved problems of life such as water balance, respiration, and reproduction. Comparative physiology is also the basis for the development of new drugs and medical procedures. For example, a cardiac surgeon may learn animal surgery before practicing on humans, and a vaccine cannot be used on human subjects until it has been demonstrated through animal research that it confers significant benefits without unacceptable risks.

### BEFORE YOU GO ON

Answer the following questions to test your understanding of the preceding section:

1. What is the difference between anatomy and physiology? How do these two sciences support each other?
2. Name the method that would be used for each of the following: listening to a patient for a heart murmur; studying the microscopic structure of the liver; microscopically examining liver tissue for signs of hepatitis; learning the blood vessels of a cadaver; and performing a breast self-examination.

## 1.2 The Origins of Biomedical Science

### Expected Learning Outcomes

When you have completed this section, you should be able to

- a. give examples of how modern biomedical science emerged from an era of superstition and authoritarianism; and
- b. describe the contributions of some key people who helped to bring about this transformation.

Any science is more enjoyable if we consider not just the current state of knowledge, but how it compares to past understandings of the subject and how our knowledge was gained. Of all sciences, medicine has one of the most fascinating histories. Medical science has progressed far more in the last 50 years than in the 2,500 years before that, but the field did not spring up overnight. It is built upon centuries of thought and controversy, triumph and defeat. We cannot fully appreciate its present state without understanding its past—people who had the curiosity to try new things, the vision to look at human form and function in new ways, and the courage to question authority.

### The Greek and Roman Legacy

As early as 3,000 years ago, physicians in Mesopotamia and Egypt treated patients with herbal drugs, salts, physical therapy, and faith healing. The “father of medicine,” however, is

usually considered to be the Greek physician **Hippocrates** (c. 460–c. 375 BCE). He and his followers established a code of ethics for physicians, the Hippocratic Oath, which is still recited in modern form by graduating physicians at some medical schools. Hippocrates urged physicians to stop attributing disease to the activities of gods and demons and to seek their natural causes, which could afford the only rational basis for therapy.

**Aristotle** (384–322 BCE) was one of the first philosophers to write about anatomy and physiology. He believed that diseases and other natural events could have either supernatural causes, which he called *theologi*, or natural ones, which he called *physici* or *physiologi*. We derive such terms as *physician* and *physiology* from the latter. Until the nineteenth century, physicians were called “doctors of physic.” In his anatomy book, *On the Parts of Animals*, Aristotle tried to identify unifying themes in nature. Among other points, he argued that complex structures are built from a smaller variety of simple components—a perspective that we will find useful later in this chapter.

### ▶▶▶ APPLY WHAT YOU KNOW

*When you have completed this chapter, discuss the relevance of Aristotle’s philosophy to our current thinking about human structure.*

**Claudius Galen** (c. 130–c. 200), physician to the Roman gladiators, wrote the most influential medical textbook of the ancient era—a book worshipped to excess by medical professors for centuries to follow. Cadaver dissection was banned in Galen’s time because of some horrid excesses that preceded him, including public dissection of living slaves and prisoners. Aside from what he could learn by treating gladiators’ wounds, Galen was therefore limited to dissecting pigs, monkeys, and other animals. Because he was not permitted to dissect cadavers, he had to guess at much of human anatomy and made some incorrect deductions from animal dissections. He described the human liver, for example, as having five fingerlike lobes, somewhat like a baseball glove, because that is what he had seen in baboons. But Galen saw science as a method of discovery, not as a body of fact to be taken on faith. He warned that even his own books could be wrong and advised his followers to trust their own observations more than any book. Unfortunately, his advice was not heeded. For nearly 1,500 years, medical professors dogmatically taught what they read in Aristotle and Galen, seldom daring to question the authority of these “ancient masters.”

### The Birth of Modern Medicine

In the Middle Ages, the state of medical science varied greatly from one religious culture to another. Science was severely repressed in the Christian culture of Europe until about the sixteenth century, although some of the most famous medical schools of Europe were founded during this era. Their professors, however, taught medicine primarily as a dogmatic commentary on Galen and Aristotle, not as a field of original research.

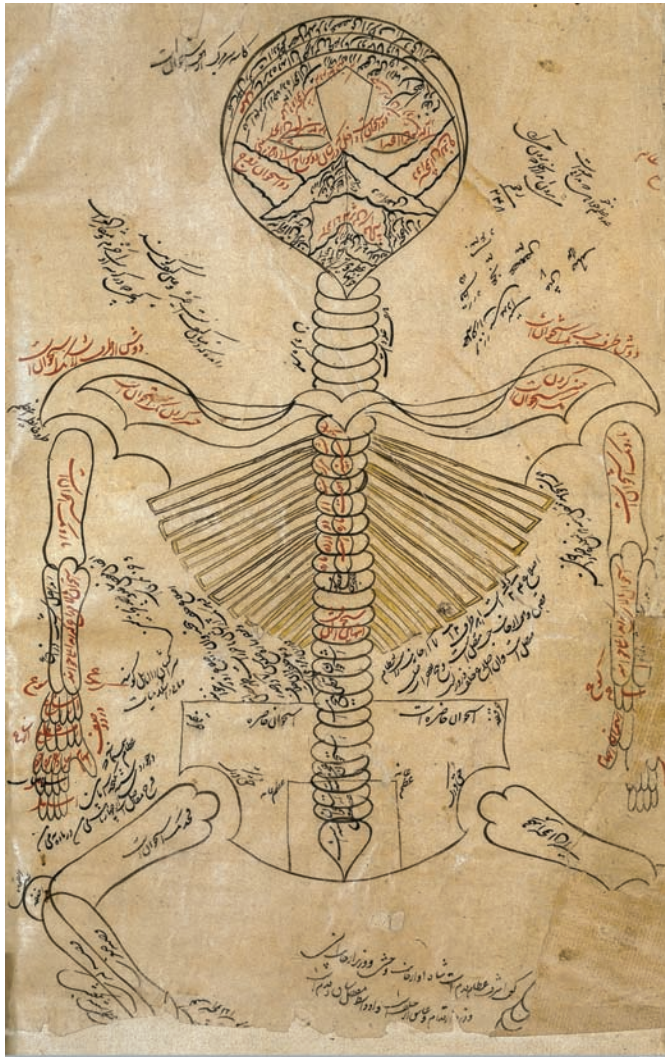
Medieval medical illustrations were crude representations of the body intended more to decorate a page than to depict the body realistically (fig. 1.1a). Some were astrological charts that showed which sign of the zodiac was thought to influence each organ of the body. From such pseudoscience came the word *influenza*, Italian for “influence.”

Free inquiry was less inhibited in Jewish and Muslim culture during this time. Jewish physicians were the most esteemed practitioners of their art—and none more famous than *Moses ben Maimon* (1135–1204), known in Christendom as **Maimonides**. Born in Spain, he fled to Egypt at age 24 to escape antisemitic persecution. There he served the rest of his life as physician to the court of the sultan, Saladin. A highly admired rabbi, Maimonides wrote voluminously on Jewish law and theology, but also wrote 10 influential medical books and numerous treatises on specific diseases.

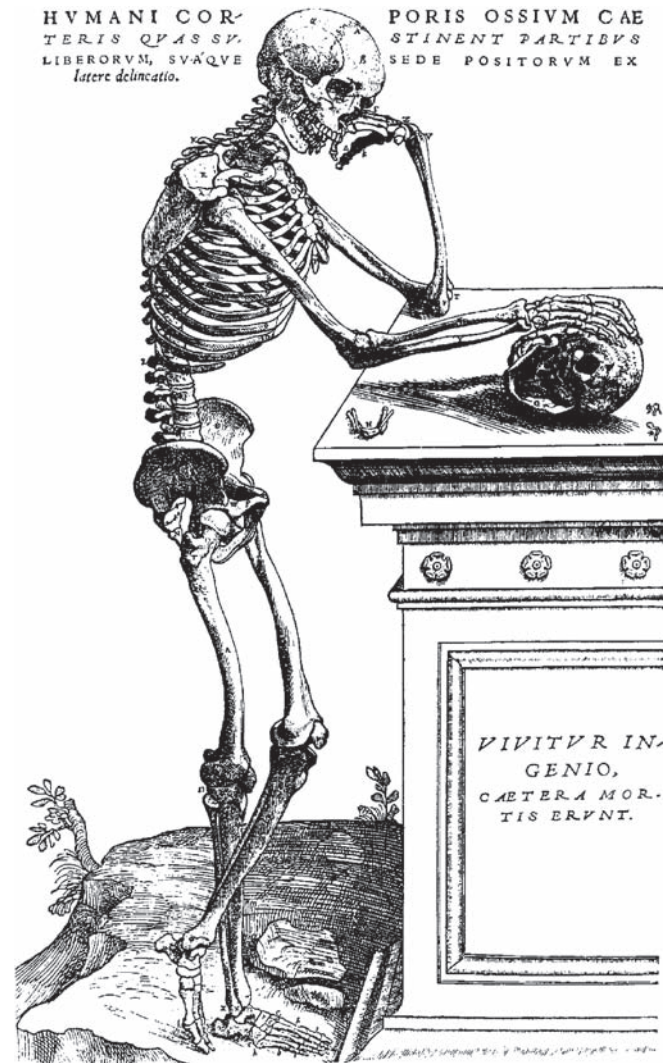
Among Muslims, probably the most highly regarded medical scholar was *Ibn Sina* (980–1037), known in the West as **Avicenna** or “the Galen of Islam.” He studied Galen and Aristotle, combined their findings with original discoveries, and questioned authority when the evidence demanded it. Medicine in the Mideast soon became superior to European medicine. Avicenna’s textbook, *The Canon of Medicine*, was the leading authority in European medical schools for over 500 years.

Chinese medicine had little influence on Western thought and practice until relatively recently; the medical arts evolved in China quite independently of European medicine. Later chapters of this book describe some of the insights of ancient China and India.

Modern Western medicine began around the sixteenth century in the innovative minds of such people as the anatomist Andreas Vesalius and the physiologist William Harvey.



(a)



(b)

**FIGURE 1.1 The Evolution of Medical Art.** Two illustrations of the skeletal system made about 500 years apart. (a) From an eleventh-century work attributed to Persian physician Avicenna. (b) From *De Humani Corporis Fabrica* by Andreas Vesalius, 1543.

a: Source: Wellcome Library, London/CC BY 4.0; b: © SPL/Science Source



**Andreas Vesalius** (1514–64) taught anatomy in Italy. In his time, the Catholic Church relaxed its prohibition against cadaver dissection, in part to allow autopsies in cases of suspicious death. Furthermore, the Italian Renaissance created an environment more friendly to innovative scholarship. Dissection gradually found its way into the training of medical students throughout Europe. It was an unpleasant business, however, and most professors considered it beneath their dignity. In those days before refrigeration or embalming, the odor from the decaying cadaver was unbearable. Dissections were a race against decay. Bleary medical students had to fight the urge to vomit, lest they incur the wrath of an overbearing professor. Professors typically sat in an elevated chair, the *cathedra*, reading dryly in Latin from Galen or Aristotle while a lower-ranking *barber-surgeon* removed putrefying organs from the cadaver and held them up for the students to see. Barbering and surgery were considered to be “kindred arts of the knife”; today’s barber poles date from this era, their red and white stripes symbolizing blood and bandages.

Vesalius broke with tradition by coming down from the cathedra and doing the dissections himself. He was quick to point out that much of the anatomy in Galen’s books was wrong, and he was the first to publish accurate illustrations for teaching anatomy (fig. 1.1b). When others began to plagiarize them, Vesalius published the first atlas of anatomy, *De Humani Corporis Fabrica* (*On the Structure of the Human Body*), in 1543. This book began a rich tradition of medical illustration that has been handed down to us through such milestones as *Gray’s Anatomy* (1856) and the vividly illustrated atlases and textbooks of today.

Anatomy preceded physiology and was a necessary foundation for it. What Vesalius was to anatomy, the Englishman **William Harvey** (1578–1657) was to physiology. Harvey is remembered especially for his studies of blood circulation and a little book he published in 1628, known by its abbreviated title *De Motu Cordis* (*On the Motion of the Heart*). He and **Michael Servetus** (1511–53) were the first Western scientists to realize that blood must circulate continuously around the body, from the heart to the other organs and back to the heart again. This flew in the face of Galen’s belief that the liver converted food to blood, the heart pumped blood through the veins to all other organs, and those organs consumed it. Harvey’s colleagues, wedded to the ideas of Galen, ridiculed Harvey for his theory, though we now know he was correct (see chapter 20 prologue). Despite persecution and setbacks, Harvey lived to a ripe old age, served as physician to the kings of England, and later did important work in embryology. Most importantly, Harvey’s contributions represent the birth of experimental physiology—the method that generated most of the information in this book.

Modern medicine also owes an enormous debt to two inventors from this era, Robert Hooke and Antony van Leeuwenhoek, who extended the vision of biologists to the cellular level.

**Robert Hooke** (1635–1703), an Englishman, designed scientific instruments of various kinds, including the compound microscope. This is a tube with a lens at each end—an *objective*

*lens* near the specimen, which produces an initial magnified image, and an *ocular lens* (*eyepiece*) near the observer’s eye, which magnifies the first image still further. Although crude compound microscopes had existed since 1595, Hooke improved the optics and invented several of the helpful features found in microscopes today—a stage to hold the specimen, an illuminator, and coarse and fine focus controls. His microscopes magnified only about 30 times, but with them, he was the first to see and name cells. In 1663, he observed thin shavings of cork and observed that they “consisted of a great many little boxes,” which he called *cellulae* (little cells) after the cubicles of a monastery (fig. 1.2). He later observed living cells “filled with juices.” Hooke became particularly interested in microscopic examination of such material as insects, plant tissues, and animal parts. He published the first comprehensive book of microscopy, *Micrographia*, in 1665.

**Antony van Leeuwenhoek** (an-TOE-nee vahn LAY-wen-hook) (1632–1723), a Dutch textile merchant, invented a *simple* (single-lens) *microscope*, originally for the purpose of examining the weave of fabrics. His microscope was a beadlike lens mounted in a metal plate equipped with a movable specimen clip.



**FIGURE 1.2 Hooke’s Compound Microscope.** (a) The compound microscope had a lens at each end of a tubular body. (b) Hooke’s drawing of cork cells, showing the thick cell walls characteristic of plants.

a: Source: National Museum of Health and Medicine, Silver Spring, MD; b: © Bettman/Corbis

Even though his microscopes were simpler than Hooke's, they achieved much greater useful magnification (up to 200×) owing to Leeuwenhoek's superior lens-making technique. Out of curiosity, he examined a drop of lake water and was astonished to find a variety of microorganisms—"little animalcules," he called them, "very prettily a-swimming." He went on to observe practically everything he could get his hands on, including blood cells, blood capillaries, sperm, muscular tissue, and bacteria from tooth scrapings. Leeuwenhoek began submitting his observations to the Royal Society of London in 1673. He was praised at first, and his observations were eagerly read by scientists, but enthusiasm for the microscope did not last. By the end of the seventeenth century, it was treated as a mere toy for the upper classes, as amusing and meaningless as a kaleidoscope. Leeuwenhoek and Hooke had even become the brunt of satire. But probably no one in history had looked at nature in such a revolutionary way. By taking biology to the cellular level, the two men had laid an entirely new foundation for the modern medicine to follow centuries later.

The Hooke and Leeuwenhoek microscopes produced poor images with blurry edges (*spherical aberration*) and rainbow-like distortions (*chromatic aberration*). These problems had to be solved before the microscope could be widely used as a biological tool. In the nineteenth century, German inventors greatly improved the compound microscope, adding the condenser and developing superior optics. With improved microscopes, biologists began eagerly examining a wider variety of specimens. By 1839, botanist **Matthias Schleiden** (1804–81) and zoologist **Theodor Schwann** (1810–82) concluded that all organisms were composed of cells. Although it took another century for this idea to be generally accepted, it became the first tenet of the **cell theory**, added to by later biologists and summarized in section 3.1. The cell theory was perhaps the most important breakthrough in biomedical history; all functions of the body are now interpreted as the effects of cellular activity.

Although the philosophical foundation for modern medicine was largely established by the time of Leeuwenhoek, Hooke, and Harvey, clinical practice was still in a dismal state. Few doctors attended medical school or received any formal education in basic science or human anatomy. Physicians tended to be ignorant, ineffective, and pompous. Their practice was heavily based on expelling imaginary toxins from the body by bleeding their patients or inducing vomiting, sweating, or diarrhea. They performed operations with filthy hands and instruments, spreading lethal infections from one patient to another and refusing, in their vanity, to believe that they themselves were the carriers of disease. Countless women died of infections acquired during childbirth from their obstetricians. Fractured limbs often became gangrenous and had to be amputated, and there was no anesthesia to lessen the pain. Disease was still widely attributed to demons and witches, and many people felt they would be interfering with God's will if they tried to treat it.

## Living in a Revolution

This short history brings us only to the threshold of modern biomedical science; it stops short of such momentous discoveries as the germ theory of disease, the mechanisms of heredity,

and the structure of DNA. In the twentieth century, basic biology and biochemistry yielded a much deeper understanding of how the body works. Advances in medical imaging enhanced our diagnostic ability and life-support strategies. We witnessed monumental developments in chemotherapy, immunization, anesthesia, surgery, organ transplants, and human genetics. By the close of the twentieth century, we had discovered the chemical "base sequence" of every human gene and begun attempting gene therapy to treat children born with diseases recently considered incurable. As future historians look back on the turn of this century, they may exult about the Genetic Revolution in which you are now living.

Several discoveries of the nineteenth and twentieth centuries, and the men and women behind them, are covered in short historical sketches in later chapters. Yet, the stories told in this chapter are different in a significant way. The people discussed here were pioneers in establishing the scientific way of thinking. They helped to replace superstition with an appreciation of natural law. They bridged the chasm between mystery and medication. Without this intellectual revolution, those who followed could not have conceived of the right questions to ask, much less a method for answering them.

### BEFORE YOU GO ON

Answer the following questions to test your understanding of the preceding section:

3. In what way did the followers of Galen disregard his advice? How does Galen's advice apply to you and this book?
4. Describe two ways in which Vesalius improved medical education and set standards that remain relevant today.
5. How is our concept of human form and function today affected by inventors from the seventeenth to the nineteenth centuries?

## 1.3 Scientific Method

### Expected Learning Outcomes

When you have completed this section, you should be able to

- a. describe the inductive and hypothetico–deductive methods of obtaining scientific knowledge;
- b. describe some aspects of experimental design that help to ensure objective and reliable results; and
- c. explain what is meant by *hypothesis*, *fact*, *law*, and *theory* in science.

Prior to the seventeenth century, science was done in a haphazard way by a small number of isolated individuals. The philosophers **Francis Bacon** (1561–1626) in England and **René Descartes** (1596–1650) in France envisioned science as a far greater, systematic enterprise with enormous possibilities for human health and welfare. They detested those who endlessly debated ancient

philosophy without creating anything new. Bacon argued against biased thinking and for more objectivity in science. He outlined a systematic way of seeking similarities, differences, and trends in nature and drawing useful generalizations from observable facts. You will see echoes of Bacon's philosophy in the discussion of scientific method that follows.

Though the followers of Bacon and Descartes argued bitterly with one another, both men wanted science to become a public, cooperative enterprise, supported by governments and conducted by an international community of scholars rather than a few isolated amateurs. Inspired by their vision, the French and English governments established academies of science that still flourish today. Bacon and Descartes are credited with putting science on the path to modernity, not by discovering anything new in nature or inventing any techniques—for neither man was a scientist—but by inventing new habits of scientific thought.

When we say “scientific,” we mean that such thinking is based on assumptions and methods that yield reliable, objective, testable information about nature. The assumptions of science are ideas that have proven fruitful in the past—for example, the idea that natural phenomena have natural causes and nature is therefore predictable and understandable. The methods of science are highly variable. **Scientific method** refers less to observational procedures than to certain habits of disciplined creativity, careful observation, logical thinking, and honest analysis of one's observations and conclusions. It is especially important in health science to understand these habits. This field is littered with more fads and frauds than any other. We are called upon constantly to judge which claims are trustworthy and which are bogus. To make such judgments depends on an appreciation of how scientists think, how they set standards for truth, and why their claims are more reliable than others.

## The Inductive Method

The **inductive method**, first prescribed by Bacon, is a process of making numerous observations until one feels confident in drawing generalizations and predictions from them. What we know of anatomy is a product of the inductive method. We describe the normal structure of the body based on observations of many bodies.

This raises the issue of what is considered proof in science. We can never prove a claim beyond all possible refutation. We can, however, consider a statement as proven *beyond reasonable doubt* if it was arrived at by reliable methods of observation, tested and confirmed repeatedly, and not falsified by any credible observation. In science, all truth is tentative; there is no room for dogma. We must always be prepared to abandon yesterday's truth if tomorrow's facts disprove it.

## The Hypothetico–Deductive Method

Most physiological knowledge was obtained by the **hypothetico–deductive method**. An investigator begins by asking a question and formulating a **hypothesis**—an educated speculation or possible answer to the question. A good hypothesis must be

(1) consistent with what is already known and (2) capable of being tested and possibly falsified by evidence. **Falsifiability** means that if we claim something is scientifically true, we must be able to specify what evidence it would take to prove it wrong. If nothing could possibly prove it wrong, then it is not scientific.

### ▶▶▶ APPLY WHAT YOU KNOW

*The ancients thought that gods or invisible demons caused epilepsy. Today, epileptic seizures are attributed to bursts of abnormal electrical activity in nerve cells of the brain. Explain why one of these claims is falsifiable (and thus scientific), whereas the other claim is not.*

The purpose of a hypothesis is to suggest a method for answering a question. From the hypothesis, a researcher makes a deduction, typically in the form of an “if–then” prediction: *If my hypothesis on epilepsy is correct and I record the brain waves of patients during seizures, then I should observe abnormal bursts of activity.* A properly conducted experiment yields observations that either support a hypothesis or require the scientist to modify or abandon it, formulate a better hypothesis, and test that one. Hypothesis testing operates in cycles of conjecture and disproof until one is found that is supported by the evidence.

## Experimental Design

Doing an experiment properly involves several important considerations. What shall I measure and how can I measure it? What effects should I watch for and which ones should I ignore? How can I be sure my results are due to the variables that I manipulate and not due to something else? When working on human subjects, how can I prevent the subject's expectations or state of mind from influencing the results? How can I eliminate my own biases and be sure that even the most skeptical critics will have as much confidence in my conclusions as I do? Several elements of experimental design address these issues:

- **Sample size.** The number of subjects (animals or people) used in a study is the sample size. An adequate sample size controls for chance events and individual variations in response and thus enables us to place more confidence in the outcome. For example, would you rather trust your health to a drug that was tested on 5 people or one tested on 5,000? Why?
- **Controls.** Biomedical experiments require comparison between treated and untreated individuals so that we can judge whether the treatment has any effect. A **control group** consists of subjects that are as much like the **treatment group** as possible except with respect to the variable being tested. For example, there is evidence that garlic lowers blood cholesterol levels. In one study, volunteers with high cholesterol were each given 800 mg of garlic powder daily for 4 months and exhibited an average 12% reduction in cholesterol. Was this a significant



reduction, and was it due to the garlic? It is impossible to say without comparison to a control group of similar people who received no treatment. In this study, the control group averaged only a 3% reduction in cholesterol, so garlic *seems* to have made a difference.

- **Psychosomatic effects.** Psychosomatic effects (effects of the subject's state of mind on his or her physiology) can have an undesirable effect on experimental results if we do not control for them. In drug research, it is therefore customary to give the control group a **placebo** (pla-SEE-bo)—a substance with no significant physiological effect on the body. If we were testing a drug, for example, we could give the treatment group the drug and the control group identical-looking sugar tablets. Neither group must know which tablets it is receiving. If the two groups showed significantly different effects, we could feel confident that it did not result from a knowledge of what they were taking.
- **Experimenter bias.** In the competitive, high-stakes world of medical research, experimenters may want certain results so much that their biases, even subconscious ones, can affect their interpretation of the data. One way to control for this is the **double-blind method**. In this procedure, neither the subject to whom a treatment is given nor the person giving it and recording the results knows whether that subject is receiving the experimental treatment or the placebo. A researcher may prepare identical-looking tablets, some with the drug and some with placebo; label them with code numbers; and distribute them to participating physicians. The physicians themselves do not know whether they are administering drug or placebo, so they cannot give the subjects even accidental hints of which substance they are taking. When the data are collected, the researcher can correlate them with the composition of the tablets and determine whether the drug had more effect than the placebo.
- **Statistical testing.** If you tossed a coin 100 times, you would expect it to come up about 50 heads and 50 tails. If it actually came up 48:52, you would probably attribute this to random error rather than bias in the coin. But what if it came up 40:60? At what point would you begin to suspect bias? This type of problem is faced routinely in research—how great a difference must there be between control and experimental groups before we feel confident that it was due to the treatment and not merely random variation? What if a treatment group exhibited a 12% reduction in cholesterol level and the placebo group a 10% reduction? Would this be enough to conclude that the treatment was effective? Scientists are well grounded in **statistical tests** that can be applied to the data—the chi-square test, the *t* test, and analysis of variance, for example. A typical outcome of a statistical test may be expressed, “We can be 99.5% sure that the difference between group A and group B was due to the experimental treatment and not to random variation.” Science is grounded not in statements of absolute truth, but in statements of probability.

## Peer Review

When a scientist applies for funds to support a research project or submits results for publication, the application or manuscript is submitted to **peer review**—a critical evaluation by other experts in that field. Even after a report is published, if the results are important or unconventional, other scientists may attempt to reproduce them to see if the author was correct. At every stage from planning to postpublication, scientists are therefore subject to intense scrutiny by their colleagues. Peer review is one mechanism for ensuring honesty, objectivity, and quality in science.

## Facts, Laws, and Theories

The most important product of scientific research is understanding how nature works—whether it be the nature of a pond to an ecologist or the nature of a liver cell to a physiologist. We express our understanding as *facts*, *laws*, and *theories* of nature. It is important to appreciate the differences among these.

A scientific **fact** is information that can be independently verified by any trained person—for example, the fact that an iron deficiency leads to anemia. A **law of nature** is a generalization about the predictable ways in which matter and energy behave. It is the result of inductive reasoning based on repeated, confirmed observations. Some laws are expressed as concise verbal statements, such as the *law of complementary base pairing*: In the double helix of DNA, a chemical base called adenine always pairs with one called thymine, and a base called guanine always pairs with cytosine (see section 4.1). Other laws are expressed as mathematical formulae, such as *Boyle's law*, used in respiratory physiology: Under specified conditions, the volume of a gas (*V*) is inversely proportional to its pressure (*P*)—that is,

$$V \propto 1/P.$$

A **theory** is an explanatory statement or set of statements derived from facts, laws, and confirmed hypotheses. Some theories have names, such as the *cell theory*, the *fluid-mosaic theory* of cell membranes, and the *sliding filament theory* of muscle contraction. Most, however, remain unnamed. The purpose of a theory is not only to concisely summarize what we already know but, moreover, to suggest directions for further study and to help predict what the findings should be if the theory is correct.

*Law* and *theory* mean something different in science than they do to most people. In common usage, a law is a rule created and enforced by people; we must obey it or risk a penalty. A law of nature, however, is a description; laws do not *govern* the universe—they *describe* it. Laypeople tend to use the word *theory* for what a scientist would call a hypothesis—for example, “I have a theory why my car won't start.” The difference in meaning causes significant confusion when it leads people to think that a scientific theory (such as the theory of evolution) is merely a guess or conjecture, instead of recognizing it as a summary of conclusions drawn from a large body of observed facts. The concepts of gravity and electrons are theories, too, but this does not mean they are merely speculations.

### ▶▶▶ APPLY WHAT YOU KNOW

Was the cell theory proposed by Schleiden and Schwann more a product of the hypothetico–deductive method or of the inductive method? Explain your answer.

### BEFORE YOU GO ON

Answer the following questions to test your understanding of the preceding section:

6. Describe the general process involved in the inductive method.
7. Describe some sources of potential bias in biomedical research. What are some ways of minimizing such bias?
8. Is there more information in an individual scientific fact or in a theory? Explain.

## 1.4 Human Origins and Adaptations

### Expected Learning Outcomes

When you have completed this section, you should be able to

- a. explain why evolution is relevant to understanding human form and function;
- b. define *evolution* and *natural selection*;
- c. describe some human characteristics that can be attributed to the tree-dwelling habits of earlier primates; and
- d. describe some human characteristics that evolved later in connection with upright walking.

If any two theories have the broadest implications for understanding the human body, they are probably the *cell theory* and the *theory of natural selection*. No understanding of human form and function is complete without an understanding of our evolutionary history, of how natural selection adapted the body to its ancestral habitat. As an explanation of how species originate and change through time, natural selection was the brainchild of **Charles Darwin** (1809–82)—certainly the most influential biologist who ever lived. His book, *On the Origin of Species by Means of Natural Selection* (1859), has been called “the book that shook the world.” In presenting the first well-supported theory of how evolution works, it not only caused the restructuring of all of biology but also profoundly changed the prevailing view of our origin, nature, and place in the universe. In *The Descent of Man* (1871), Darwin directly addressed the issue of human evolution and emphasized features of anatomy and behavior that reveal our relationship to other animals. Here we will touch just briefly on how natural selection helps explain some of the distinctive characteristics seen in *Homo sapiens* today.

### Evolution, Selection, and Adaptation

**Evolution** simply means change in the genetic composition of a population of organisms. Examples include the evolution of bacterial resistance to antibiotics, the appearance of new strains of the AIDS virus, and the emergence of new species of organisms.

Evolution works largely through the principle of **natural selection**, which states essentially this: Some individuals within a species have hereditary advantages over their competitors—for example, better camouflage, disease resistance, or ability to attract mates—that enable them to produce more offspring. They pass these advantages on to their offspring, and such characteristics therefore become more and more common in successive generations. This brings about the genetic change in a population that constitutes evolution.

Natural forces that promote the reproductive success of some individuals more than others are called **selection pressures**. They include such things as climate, predators, disease, competition, and the availability of food. **Adaptations** are features of anatomy, physiology, and behavior that have evolved in response to these selection pressures and enable the organism to cope with the challenges of its environment.

Darwin could scarcely have predicted the overwhelming mass of genetic, molecular, fossil, and other evidence of human evolution that would accumulate in the twentieth century and further substantiate his theory. A technique called DNA hybridization, for example, reveals a difference of only 1.6% in DNA structure between humans and chimpanzees. Chimpanzees and gorillas differ by 2.3%. DNA structure thus suggests that a chimpanzee’s closest living relative is not the gorilla or any other ape—it is us, *Homo sapiens*.

Several aspects of our anatomy make little sense without an awareness that the human body has a history (see Deeper Insight 1.1). Our evolutionary relationship to other species is also important in choosing animals for biomedical research. If there were no issues of cost, availability, or ethics, we might test drugs on our close living relatives, the chimpanzees, before approving them for human use. Their genetics, anatomy, and physiology are most similar to ours, and their reactions to drugs therefore afford the best prediction of how the human body would react. On the other hand, if we had no kinship with any other species, the selection of a test species would be arbitrary; we might as well use frogs or snails. In reality, we compromise.



### DEEPER INSIGHT 1.1

#### EVOLUTIONARY MEDICINE

#### Vestiges of Human Evolution

One of the classic lines of evidence for evolution, debated even before Darwin was born, is *vestigial organs*. These structures are the remnants of organs that apparently were better developed and more functional in the ancestors of a species. They now serve little or no purpose or, in some cases, have been converted to new functions.

Our bodies, for example, are covered with millions of hairs, each equipped with a useless little muscle called a *piloerector*. In other mammals, these muscles fluff the hair and conserve heat. In humans, they merely produce goose bumps. Above each ear, we have three *auricular muscles*. In other mammals, they move the ears to receive sounds better or to flick off flies and other pests, but most people cannot contract them at all. As Darwin said, it makes no sense that humans would have such structures were it not for the fact that we came from ancestors in which they were functional.

Rats and mice are used extensively for research because they are fellow mammals with a physiology similar to ours, but they present fewer of the aforementioned issues than chimpanzees or other mammals do. An animal species or strain selected for research on a particular problem is called a **model**—for example, a mouse model for leukemia.

## Our Basic Primate Adaptations

We belong to an order of mammals called the Primates, which also includes the monkeys and apes. Some of our anatomical and physiological features can be traced to the earliest primates, which descended from certain squirrel-sized, insect-eating, African mammals that took up life in the trees 55 to 60 million years ago. This **arboreal**<sup>9</sup> (treetop) habitat probably afforded greater safety from predators, less competition, and a rich food supply of leaves, fruit, insects, and lizards. But the forest canopy is a challenging world, with dim and dappled sunlight, swaying branches, and prey darting about in the dense foliage. Any new feature that enabled arboreal animals to move about more easily in the treetops would have been strongly favored by natural selection. Thus, the shoulder became more mobile and enabled primates to reach out in any direction (even overhead, which few other mammals can do). The thumbs became fully **opposable**—they could cross the palm to touch the

fingertips—and enabled primates to hold small objects and manipulate them more precisely than other mammals could. Opposable thumbs made the hands **prehensile**<sup>10</sup>—able to grasp branches by encircling them with the thumb and fingers (fig. 1.3a). The thumb is so important that it receives highest priority in the repair of hand injuries. If the thumb can be saved, the hand can be reasonably functional; if it is lost, hand functions are severely diminished.

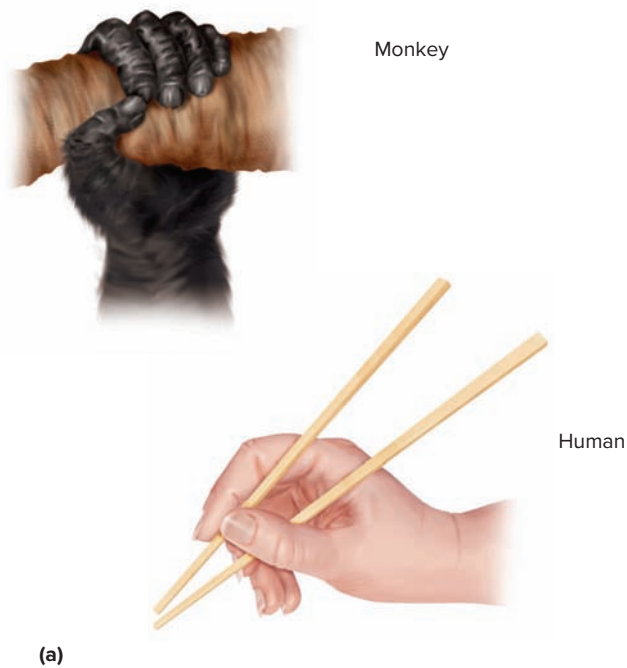
The eyes of primates moved to a more forward-facing position (fig. 1.3b), which allowed for **stereoscopic**<sup>11</sup> vision (depth perception). This adaptation provided better hand–eye coordination in catching and manipulating prey, with the added advantage of making it easier to judge distances accurately in leaping from tree to tree. Color vision, rare among mammals, is also a primate hallmark. Primates eat mainly fruit and leaves. The ability to distinguish subtle shades of orange and red enables them to distinguish ripe, sugary fruits from unripe ones. Distinguishing subtle shades of green helps them to differentiate between tender young leaves and tough, more toxic older foliage.

Various fruits ripen at different times and in widely separated places in the tropical forest. This requires a good memory of what will be available, when, and how to get there. Larger brains may have evolved in response to the challenge of efficient food finding and, in turn, laid the foundation for more sophisticated social organization.

<sup>9</sup>*arbor* = tree; *eal* = pertaining to

<sup>10</sup>*prehens* = to seize

<sup>11</sup>*stereo* = solid; *scop* = vision



**FIGURE 1.3 Human Adaptations Shared with Other Primates.** (a) The opposable thumb makes the hand prehensile, able to encircle and grasp objects. (b) Chimpanzees exhibit the prehensile hands and forward-facing eyes typical of primates. Such traits endow primates with stereoscopic vision (depth perception) and good hand–eye coordination, two factors of enormous importance in human evolution.



None of this is meant to imply that humans evolved from monkeys or apes—a common misconception about evolution that no biologist believes. Monkeys, apes, and humans do, however, share common ancestors. Our relationship is not like parent and child, but more like cousins who have the same grandparents. Observations of monkeys and apes provide insight into how primates adapt to the arboreal habitat and therefore how certain human adaptations probably originated.

## Walking Upright

About 4 to 5 million years ago, parts of Africa became hotter and drier, and much of the forest was replaced by savanna (grassland). Some primates adapted to living on the savanna, but this was a dangerous place with more predators and less protection. Just as squirrels and monkeys stand briefly on their hind legs to look around for danger, so would these early ground dwellers. Being able to stand up not only helps an animal stay alert, but also frees the forelimbs for purposes other than walking. Chimpanzees sometimes walk upright to carry food, infants, or weapons (sticks and rocks), and it is reasonable to suppose that our early ancestors did so too.

These advantages are so great that they favored skeletal modifications that made **bipedalism**<sup>12</sup>—standing and walking on two legs—easier. Fossil evidence indicates that bipedalism was firmly established more than 4 million years ago. The anatomy of the human pelvis, femur, knee, great toe, foot arches, spinal column, skull, arms, and many muscles became adapted for bipedal locomotion (see Deeper Insight 8.4), as did many aspects of human family life and society. As the skeleton and muscles became adapted for bipedalism, brain volume increased dramatically, from 400 mL around 4 million years ago to an average of 1,350 mL today. It must have become increasingly difficult for a fully developed, large-brained infant to pass through the mother's pelvic outlet at birth. This may explain why humans are born in a relatively immature, helpless state compared with other mammals, before their nervous systems have matured and the bones of the skull have fused. The helplessness of human young and their extended dependence on parental care may help to explain why humans have such exceptionally strong family ties.

Most of the oldest bipedal primates are classified in the genus *Australopithecus* (aus-TRAL-oh-PITH-eh-cus). About 2.5 million years ago, hominids appeared with taller stature, greater brain volumes, simple stone tools, and probably articulate speech. These are the earliest members of the genus *Homo*. By at least 1.8 million years ago, *Homo erectus* migrated from Africa to parts of Asia. Anatomically modern *Homo sapiens*, our own species, originated in Africa about 200,000 years ago and is the sole surviving hominid species.

This brief account barely begins to explain how human anatomy, physiology, and behavior have been shaped by ancient selection pressures. Later chapters further demonstrate that the evolutionary perspective provides a meaningful understanding of why humans are the way we are. Evolution is the basis for

comparative anatomy and physiology, which have been so fruitful for the understanding of human biology. If we were not related to any other species, those sciences would be pointless.

The emerging science of **evolutionary medicine** analyzes how human disease and dysfunctions can be traced to differences between the artificial environment in which we now live, and the prehistoric environment to which *Homo sapiens* was biologically adapted. For example, we can relate sleep and mood disorders to artificial lighting and night-shift work, and the rise of asthma to our modern obsession with sanitation. Other examples in this book will relate evolution to obesity, diabetes, low-back pain, skin cancer, and other health issues.

### BEFORE YOU GO ON

Answer the following questions to test your understanding of the preceding section:

- Define *adaptation* and *selection pressure*. Why are these concepts important in understanding human anatomy and physiology?
- Select any two human characteristics and explain how they may have originated in primate adaptations to an arboreal habitat.
- Select two other human characteristics and explain how they may have resulted from later adaptation to a grassland habitat.

## 1.5 Human Structure

### Expected Learning Outcomes

When you have completed this section, you should be able to

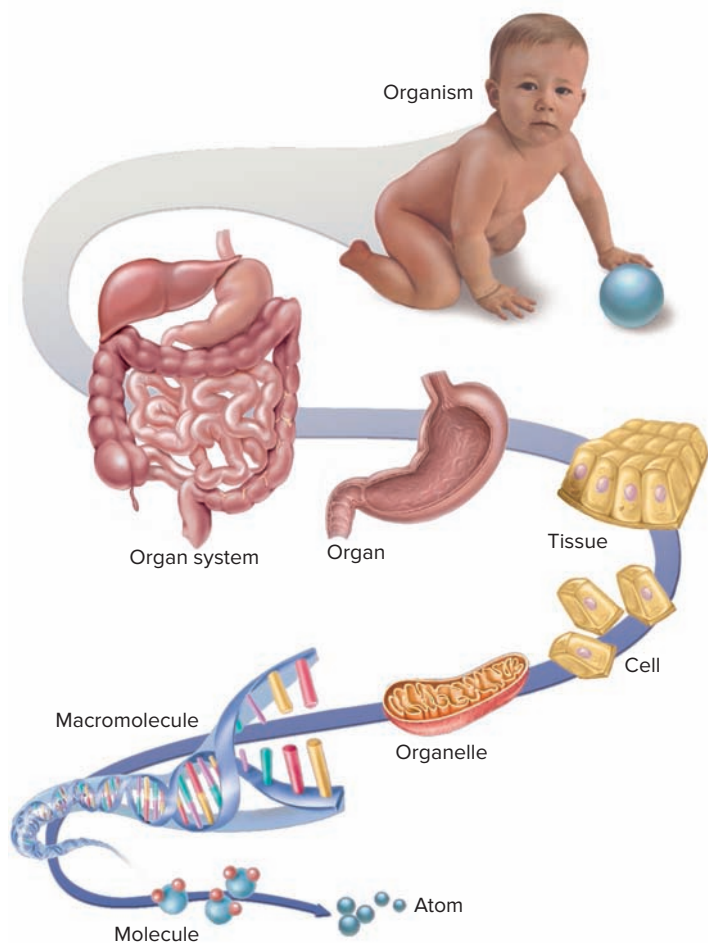
- list the levels of human structure from the most complex to the simplest;
- discuss the value of both reductionistic and holistic viewpoints to understanding human form and function; and
- discuss the clinical significance of anatomical variation among humans.

Earlier in this chapter, we observed that human anatomy is studied by a variety of techniques—dissection, palpation, and so forth. In addition, anatomy is studied at several levels of detail, from the whole body down to the molecular level.

### The Hierarchy of Complexity

Consider for the moment an analogy to human structure: The English language, like the human body, is very complex, yet an infinite variety of ideas can be conveyed with a limited number of words. All words in English are, in turn, composed of various combinations of just 26 letters. Between an essay and an alphabet are successively simpler levels of organization: paragraphs, sentences, words, and syllables. We can say that language exhibits a

<sup>12</sup>bi = two; ped = foot



**FIGURE 1.4** The Body's Structural Hierarchy.

hierarchy of complexity, with letters, syllables, words, and so forth being successive levels of the hierarchy. Humans have an analogous hierarchy of complexity, as follows (fig. 1.4):

The organism is composed of organ systems,  
 organ systems are composed of organs,  
 organs are composed of tissues,  
 tissues are composed of cells,  
 cells are composed partly of organelles,  
 organelles are composed of molecules, and  
 molecules are composed of atoms.

The **organism** is a single, complete individual.

An **organ system** is a group of organs with a unique collective function, such as circulation, respiration, or digestion. The human body has 11 organ systems, illustrated in atlas A immediately following this chapter: the integumentary, skeletal, muscular, nervous, endocrine, circulatory, lymphatic, respiratory, urinary, digestive, and reproductive systems. Usually, the organs of one system are physically interconnected, such as the kidneys, ureters, urinary bladder, and urethra, which compose the urinary system. Beginning with chapter 6, this book is organized around the organ systems.

An **organ** is a structure composed of two or more tissue types that work together to carry out a particular function. Organs have definite anatomical boundaries and are visibly distinguishable from adjacent structures. Most organs and higher levels of structure are within the domain of gross anatomy. However, there are organs within organs—the large organs visible to the naked eye often contain smaller organs visible only with the microscope. The skin, for example, is the body's largest organ. Included within it are thousands of smaller organs: Each hair, nail, gland, nerve, and blood vessel of the skin is an organ in itself. A single organ can belong to two organ systems. For example, the pancreas belongs to both the endocrine and digestive systems.

A **tissue** is a mass of similar cells and cell products that forms a discrete region of an organ and performs a specific function. The body is composed of only four primary classes of tissue: epithelial, connective, nervous, and muscular tissue. Histology, the study of tissues, is the subject of chapter 5.

**Cells** are the smallest units of an organism that carry out all the basic functions of life; nothing simpler than a cell is considered alive. A cell is enclosed in a *plasma membrane* composed of lipids and proteins. Most cells have one nucleus, an organelle that contains its DNA. *Cytology*, the study of cells and organelles, is the subject of chapters 3 and 4.

**Organelles**<sup>13</sup> are microscopic structures in a cell that carry out its individual functions. Examples include mitochondria, centrioles, and lysosomes.

Organelles and other cellular components are composed of **molecules**. The largest molecules, such as proteins, fats, and DNA, are called *macromolecules* (see chapter 2). A molecule is a particle composed of at least two **atoms**, the smallest particles with unique chemical identities.

The theory that a large, complex system such as the human body can be understood by studying its simpler components is called **reductionism**. First espoused by Aristotle, this has proved to be a highly productive approach; indeed, it is essential to scientific thinking. Yet the reductionistic view is not the only way of understanding human life. Just as it would be very difficult to predict the workings of an automobile transmission merely by looking at a pile of its disassembled gears and levers, one could never predict the human personality from a complete knowledge of the circuitry of the brain or the genetic sequence of DNA. **Holism**<sup>14</sup> is the complementary theory that there are “emergent properties” of the whole organism that cannot be predicted from the properties of its separate parts—human beings are more than the sum of their parts. To be most effective, a health-care provider treats not merely a disease or an organ system, but a whole person. A patient's perceptions, emotional responses to life, and confidence in the nurse, therapist, or physician profoundly affect the outcome of treatment. In fact, these psychological factors often play a greater role in a patient's recovery than the physical treatments administered.

<sup>13</sup>*elle* = little

<sup>14</sup>*holo* = whole, entire



## Anatomical Variation

A quick look around any classroom is enough to show that no two humans are exactly alike; on close inspection, even identical twins exhibit differences. Yet anatomy atlases and textbooks can easily give the impression that everyone's internal anatomy is the same. This simply is not true. Books such as this one can teach you only the most common structure—the anatomy seen in about 70% or more of people. Someone who thinks that all human bodies are the same internally would make a very confused medical student or an incompetent surgeon.

Some people lack certain organs. For example, most of us have a *palmaris longus* muscle in the forearm and a *plantaris* muscle in the leg, but these are absent from others. Most of us have five lumbar vertebrae (bones of the lower spine), but some people have six and some have four. Most of us have one spleen and two kidneys, but some have two spleens or only one kidney. Most kidneys are supplied by a single *renal artery* and are drained by one *ureter*, but some have two renal arteries or ureters. Figure 1.5 shows some common variations in human anatomy, and Deeper Insight 1.2 describes a particularly dramatic and clinically important variation.

### ▶▶▶ APPLY WHAT YOU KNOW

*People who are allergic to aspirin or penicillin often wear MedicAlert bracelets or necklaces that note this fact in case they need emergency medical treatment and are unable to communicate. Why would it be important for a person with situs inversus (see Deeper Insight 1.2) to have this noted on a MedicAlert bracelet?*



## DEEPER INSIGHT 1.2 CLINICAL APPLICATION

### Situs Inversus and Other Unusual Anatomy

In most people, the spleen, pancreas, sigmoid colon, and most of the heart are on the left, while the appendix, gallbladder, and most of the liver are on the right. The normal arrangement of these and other internal organs is called *situs* (SITE-us) *solitus*. About 1 in 8,000 people, however, is born with an abnormality called *situs inversus*—the organs of the thoracic and abdominal cavities are reversed between right and left. A selective right–left reversal of the heart is called *dextrocardia*. In *situs perversus*, a single organ occupies an atypical position—for example, a kidney located low in the pelvic cavity instead of high in the abdominal cavity.

Conditions such as dextrocardia in the absence of complete situs inversus can cause serious medical problems. Complete situs inversus, however, usually causes no functional problems because all of the viscera, though reversed, maintain their normal relationships to one another. Situs inversus is often discovered in the fetus by sonography, but many people remain unaware of their condition for decades until it is discovered by medical imaging, on physical examination, or in surgery. You can easily imagine the importance of such conditions in diagnosing appendicitis, performing gallbladder surgery, interpreting an X-ray, auscultating the heart valves, or recording an electrocardiogram.

## BEFORE YOU GO ON

Answer the following questions to test your understanding of the preceding section:

- In the hierarchy of human structure, what is the level between organ system and tissue? Between cell and molecule?
- How are tissues relevant to the definition of an organ?
- Why is reductionism a necessary but not sufficient point of view for fully understanding a patient's illness?
- Why should medical students observe multiple cadavers and not be satisfied to dissect only one?

## 1.6 Human Function

### Expected Learning Outcomes

When you have completed this section, you should be able to

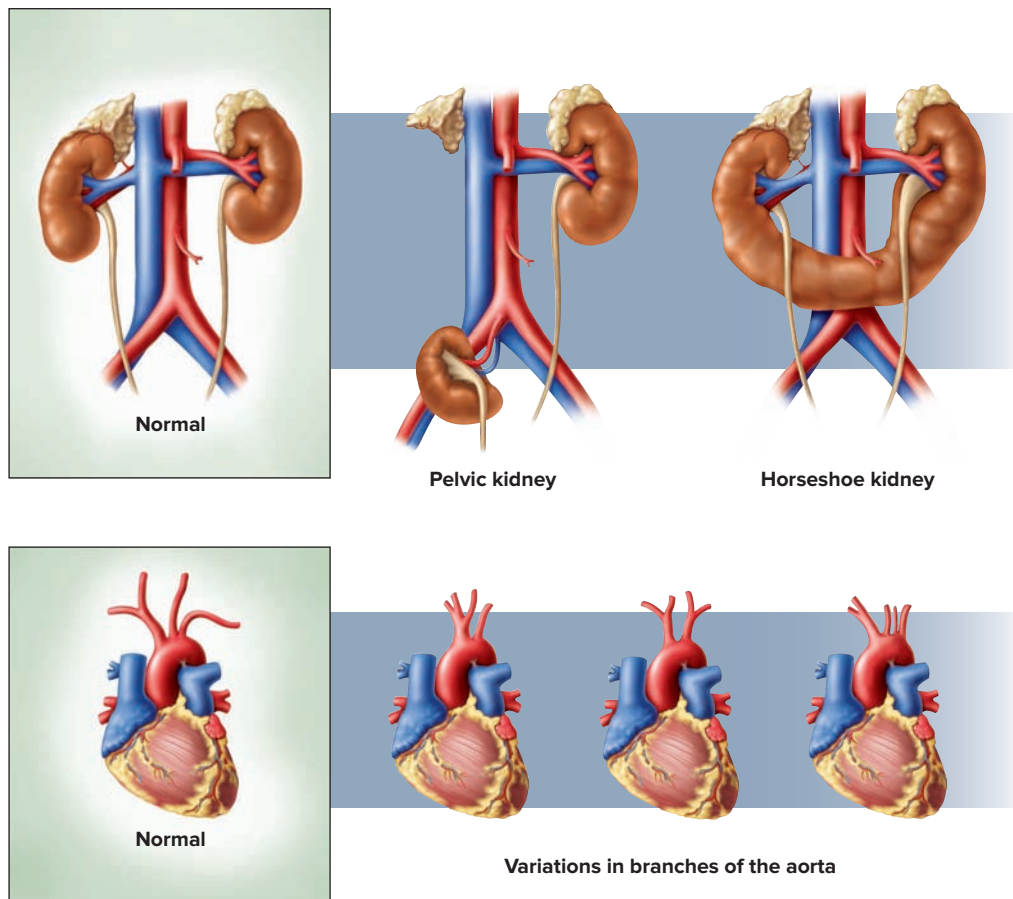
- state the characteristics that distinguish living organisms from nonliving objects;
- explain the importance of physiological variation among persons;
- define *homeostasis* and explain why this concept is central to physiology;
- define *negative feedback*, give an example of it, and explain its importance to homeostasis;
- define *positive feedback* and give examples of its beneficial and harmful effects; and
- define *gradient*, describe the variety of gradients in human physiology, and identify some forms of matter and energy that flow down gradients.

## Characteristics of Life

Why do we consider a growing child to be alive, but not a growing crystal? Is abortion the taking of a human life? If so, what about a contraceptive foam that kills only sperm? As a patient is dying, at what point does it become ethical to disconnect life-support equipment and remove organs for donation? If these organs are alive, as they must be to serve someone else, then why isn't the donor considered alive? Such questions have no easy answers, but they demand a concept of what life is—a concept that may differ with one's biological, medical, legal, or religious perspective.

From a biological viewpoint, life is not a single property. It is a collection of properties that help to distinguish living from nonliving things:

- Organization.** Living things exhibit a far higher level of organization than the nonliving world around them. They expend a great deal of energy to maintain order, and a breakdown in this order is accompanied by disease and often death.
- Cellular composition.** Living matter is always compartmentalized into one or more cells.



**FIGURE 1.5** Variation in Anatomy of the Kidneys and Major Arteries Near the Heart.

- **Metabolism.** Living things take in molecules from the environment and chemically change them into molecules that form their own structures, control their physiology, or provide them with energy. **Metabolism**<sup>15</sup> consists of the internal chemical reactions in the living organism. It inevitably produces chemical wastes, some of which are toxic if they accumulate. Metabolism therefore requires **excretion**, the separation of wastes from the tissues and their elimination from the body. There is a constant turnover of molecules in the body; few of the molecules now in your body have been there for more than a year. It is food for thought that although you sense a continuity of personality and experience from your childhood to the present, nearly all of your body has been replaced within the past year.
- **Responsiveness and movement.** The ability of organisms to sense and react to **stimuli** (changes in their environment) is called *responsiveness*, *irritability*, or *excitability*. It occurs at all levels from the single cell to the entire body, and it characterizes all living things from bacteria to you. Responsiveness is especially obvious in animals because of nerve and muscle cells that exhibit high sensitivity to

environmental stimuli, rapid transmission of information, and quick reactions. Most living organisms are capable of self-propelled movement from place to place, and all organisms and cells are at least capable of moving substances internally, such as moving food along the digestive tract or moving molecules and organelles from place to place within a cell.

- **Homeostasis.** Although the environment around an organism changes, the organism maintains relatively stable internal conditions. This ability to maintain internal stability, called *homeostasis*, is explored in more depth shortly.
- **Development.** Development is any change in form or function over the lifetime of the organism. In most organisms, it involves two major processes: (1) **differentiation**, the transformation of cells with no specialized function into cells that are committed to a particular task; and (2) **growth**, an increase in size. Some nonliving things grow, but not in the way your body does. If you let a saturated sugar solution evaporate, crystals will grow from it, but not through a change in the composition of the sugar. They merely add more sugar molecules from the solution to the crystal surface. The growth of the body, by contrast, occurs through chemical change (metabolism); for the most part, your body

<sup>15</sup>*metabol* = change; *ism* = process

is not composed of the molecules you ate but of molecules made by chemically altering your food.

- **Reproduction.** All living organisms can produce copies of themselves, thus passing their genes on to new, younger containers—their offspring.
- **Evolution.** All living species exhibit genetic change from generation to generation and therefore evolve. This occurs because *mutations* (changes in DNA structure) are inevitable and because environmental selection pressures favor the transmission of some genes more than others. Unlike the other characteristics of life, evolution is a characteristic seen only in the population as a whole. No single individual evolves over the course of its life.

Clinical and legal criteria of life differ from these biological criteria. A person who has shown no brain waves for 24 hours, and has no reflexes, respiration, or heartbeat other than what is provided by artificial life support, can be declared legally dead. At such time, however, most of the body is still biologically alive and its organs may be useful for transplant.

## Physiological Variation

Earlier we considered the clinical importance of variations in human anatomy, but physiology is even more variable. Physiological variables differ with sex, age, weight, diet, degree of physical activity, genetics, and environment, among other things. Failure to consider such variation leads to medical mistakes such as over-medication of the elderly or medicating women on the basis of research done on young men. If a textbook states a typical human heart rate, blood pressure, red blood cell count, or body temperature, it is generally assumed, unless otherwise stated, that such values refer to a healthy 22-year-old weighing 58 kg (128 lb) for a female and 70 kg (154 lb) for a male, and a lifestyle of light physical activity and moderate caloric intake (2,000 and 2,800 kcal/day, respectively).

## Homeostasis and Negative Feedback

The human body has a remarkable capacity for self-restoration. Hippocrates commented that it usually returns to a state of equilibrium by itself, and people recover from most illnesses even without the help of a physician. This tendency results from **homeostasis**<sup>16</sup> (HO-me-oh-STAY-sis), the body's ability to detect change, activate mechanisms that oppose it, and thereby maintain relatively stable internal conditions.

French physiologist **Claude Bernard** (1813–78) observed that the internal conditions of the body remain quite constant even when external conditions vary greatly. For example, whether it is freezing cold or swelteringly hot outdoors, the internal temperature of the body stays within a range of about 36° to 37°C (97°–99°F). American physiologist **Walter Cannon** (1871–1945) coined the

term *homeostasis* for this tendency to maintain internal stability. Homeostasis has been one of the most enlightening theories in physiology. We now see physiology as largely a group of mechanisms for maintaining homeostasis, and the loss of homeostatic control as the cause of illness and death. Pathophysiology is essentially the study of unstable conditions that result when our homeostatic controls go awry.

Do not, however, overestimate the degree of internal stability. Internal conditions are not absolutely constant but fluctuate within a limited range, such as the range of body temperatures noted earlier. The internal state of the body is best described as a **dynamic equilibrium** (balanced change), in which there is a certain **set point** or average value for a given variable (such as 37°C for body temperature) and conditions fluctuate slightly around this point.

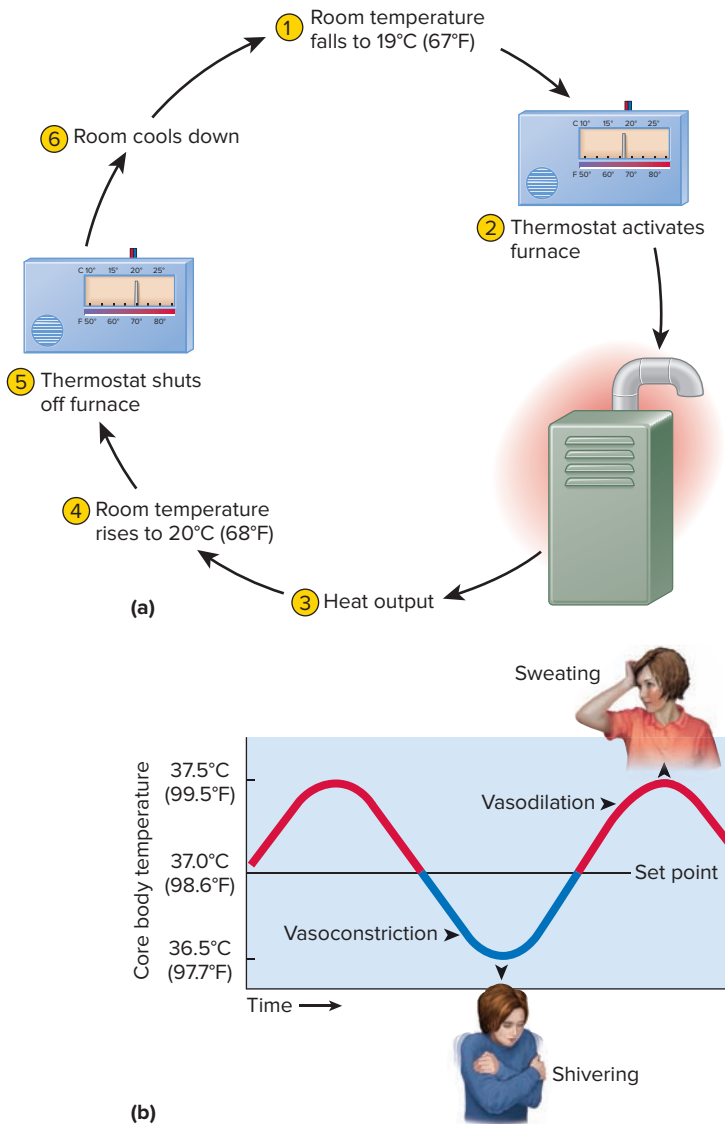
The fundamental mechanism that keeps a variable close to its set point is **negative feedback**—a process in which the body senses a change and activates mechanisms that negate or reverse it. By maintaining stability, negative feedback is the key mechanism for maintaining health.

These principles can be understood by comparison to a home heating system (fig. 1.6a). Suppose it is a cold winter day and you have set your thermostat for 20°C (68°F)—the set point. If the room becomes too cold, a temperature-sensitive switch in the thermostat turns on the furnace. The temperature rises until it is slightly above the set point, and then the switch breaks the circuit and turns off the furnace. This is a negative feedback process that reverses the falling temperature and restores it to the set point. When the furnace turns off, the temperature slowly drops again until the switch is reactivated—thus, the furnace cycles on and off all day. The room temperature does not stay at exactly 20°C but fluctuates slightly—the system maintains a state of dynamic equilibrium in which the temperature averages 20°C and deviates only slightly from the set point. Because feedback mechanisms alter the original changes that triggered them (temperature, for example), they are often called **feedback loops**.

Body temperature is similarly regulated by a “thermostat”—a group of nerve cells in the base of the brain that monitor the temperature of the blood. If you become overheated, the thermostat triggers heat-losing mechanisms (fig. 1.6b). One of these is **vasodilation** (VAY-zo-dy-LAY-shun), the widening of blood vessels. When blood vessels of the skin dilate, warm blood flows closer to the body surface and loses heat to the surrounding air. If this is not enough to return your temperature to normal, sweating occurs; the evaporation of water from the skin has a powerful cooling effect (see Deeper Insight 1.3). Conversely, if it is cold outside and your body temperature drops much below 37°C, these nerve cells activate heat-conserving mechanisms. The first to be activated is **vasoconstriction**, a narrowing of the blood vessels in the skin, which serves to retain warm blood deeper in your body and reduce heat loss. If this is not enough, the brain activates shivering—muscle tremors that generate heat.

Let's consider one more example—a case of homeostatic control of blood pressure. When you first rise from bed in the morning, gravity causes some of your blood to drain away from

<sup>16</sup>homeo = the same; stas = to place, stand, stay



**FIGURE 1.6 Negative Feedback in Thermoregulation.** (a) The negative feedback loop that maintains room temperature. (b) Negative feedback usually keeps the human body temperature within about 0.5°C of a 37°C set point. Cutaneous vasoconstriction and shivering set in when the body temperature falls too low, and soon raise it. Cutaneous vasodilation and sweating set in when body temperature rises too high, and soon lower it.

**?** How does vasodilation reduce the body temperature?

your head and upper torso, resulting in falling blood pressure in this region—a local imbalance in your homeostasis (fig. 1.7). This is detected by sensory nerve endings called *baroreceptors* in large arteries near the heart. They transmit nerve signals to the brainstem, where we have a *cardiac center* that regulates the heart rate. The cardiac center responds by transmitting nerve signals to the heart, which speed it up. The faster heart rate quickly raises the blood pressure and restores normal homeostasis. In elderly people, this feedback loop is sometimes insufficiently responsive, and they may feel dizzy as they rise from a reclining



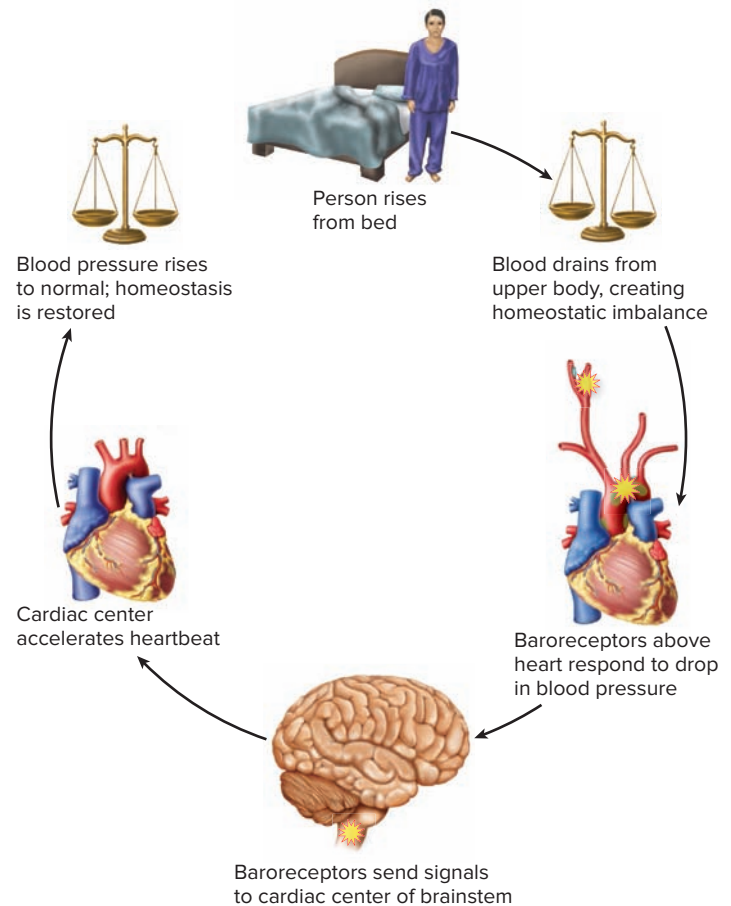
### DEEPER INSIGHT 1.3 MEDICAL HISTORY

#### Men in the Oven

English physician Charles Blagden (1748–1820) staged a rather theatrical demonstration of homeostasis long before Cannon coined the word. In 1775, Blagden spent 45 minutes in a chamber heated to 127°C (260°F)—along with a dog, a beefsteak, and some research associates. Being dead and unable to maintain homeostasis, the steak was cooked. But being alive and capable of evaporative cooling, the dog panted, the men sweated, and all of them survived. History does not record whether the men ate the steak in celebration or shared it with the dog.

position and their cerebral blood pressure falls. This sometimes causes fainting.

This reflexive correction of blood pressure (*baroreflex*) illustrates three common, although not universal, components of a feedback loop: a receptor, an integrating center, and an effector. The **receptor** is a structure that senses a change in the body, such as the stretch receptors that monitor blood pressure. The **integrating (control) center**, such as the cardiac center of the



**FIGURE 1.7 Homeostatic Compensation for a Postural Change in Blood Pressure.**



brain, is a mechanism that processes this information, relates it to other available information (for example, comparing what the blood pressure is with what it should be), and “makes a decision” about what the appropriate response should be. The **effector** is the cell or organ that carries out the final corrective action. In the foregoing example, it is the heart. The response, such as the restoration of normal blood pressure, is then sensed by the receptor, and the feedback loop is complete.

## Positive Feedback and Rapid Change

**Positive feedback** is a self-amplifying cycle in which a physiological change leads to even greater change in the same direction, rather than producing the corrective effects of negative feedback. Positive feedback is often a normal way of producing rapid change. When a woman is giving birth, for example, the head of the fetus pushes against her cervix (the neck of the uterus) and stimulates its nerve endings (fig. 1.8). Nerve signals travel to the brain, which, in turn, stimulates the pituitary gland to secrete the hormone oxytocin. Oxytocin travels in the blood and stimulates the uterus to contract. This pushes the fetus downward, stimulating the cervix

still more and causing the positive feedback loop to be repeated. Labor contractions therefore become more and more intense until the fetus is expelled. Other cases of beneficial positive feedback are seen later in the book in, for example, blood clotting, protein digestion, and the generation of nerve signals.

Frequently, however, positive feedback is a harmful or even life-threatening process. This is because its self-amplifying nature can quickly change the internal state of the body to something far from its homeostatic set point. Consider a high fever, for example. A fever triggered by infection is beneficial up to a point, but if the body temperature rises much above 40°C (104°F), it may create a dangerous positive feedback loop. This high temperature raises the metabolic rate, which makes the body produce heat faster than it can get rid of it. Thus, temperature rises still further, increasing the metabolic rate and heat production still more. This “vicious circle” becomes fatal at approximately 45°C (113°F). Thus, positive feedback loops often create dangerously out-of-control situations that require emergency medical treatment.

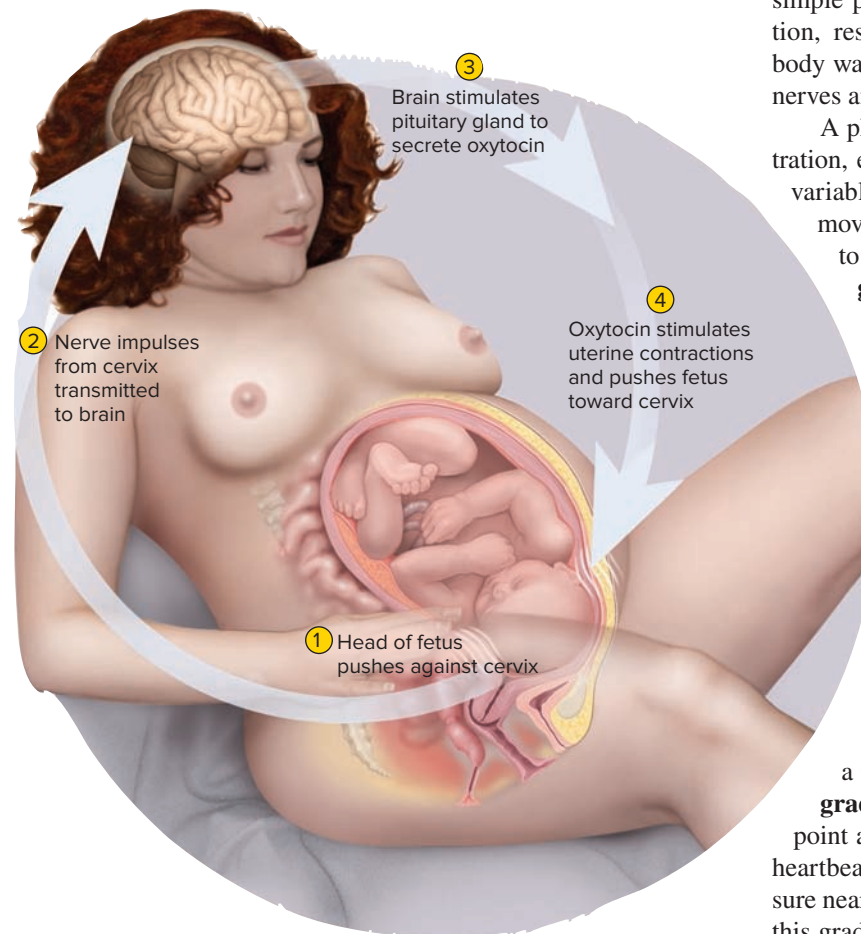
## Gradients and Flow

Another fundamental concept that will arise repeatedly in this book is that matter and energy tend to *flow down gradients*. This simple principle underlies processes as diverse as blood circulation, respiratory airflow, urine formation, nutrient absorption, body water distribution, temperature regulation, and the action of nerves and muscles.

A physiological **gradient** is a difference in chemical concentration, electrical charge, physical pressure, temperature, or other variable between one point and another. If matter or energy moves from the point where this variable has a higher value to the point with a lower value, we say it flows **down the gradient**—for example, from a warmer to a cooler point, or a place of high chemical concentration to one of lower concentration. Movement in the opposite direction is **up the gradient**.

Outside of biology, *gradient* can mean a hill or slope, and this affords us a useful analogy to biological processes (fig. 1.9a). A wagon released at the top of a hill will roll down it (“flow”) spontaneously, without need for anyone to exert energy to move it. Similarly, matter and energy in the body spontaneously flow down gradients, without the expenditure of metabolic energy. Movement up a gradient does require an energy expenditure, just as we would have to push or pull a wagon to move it uphill.

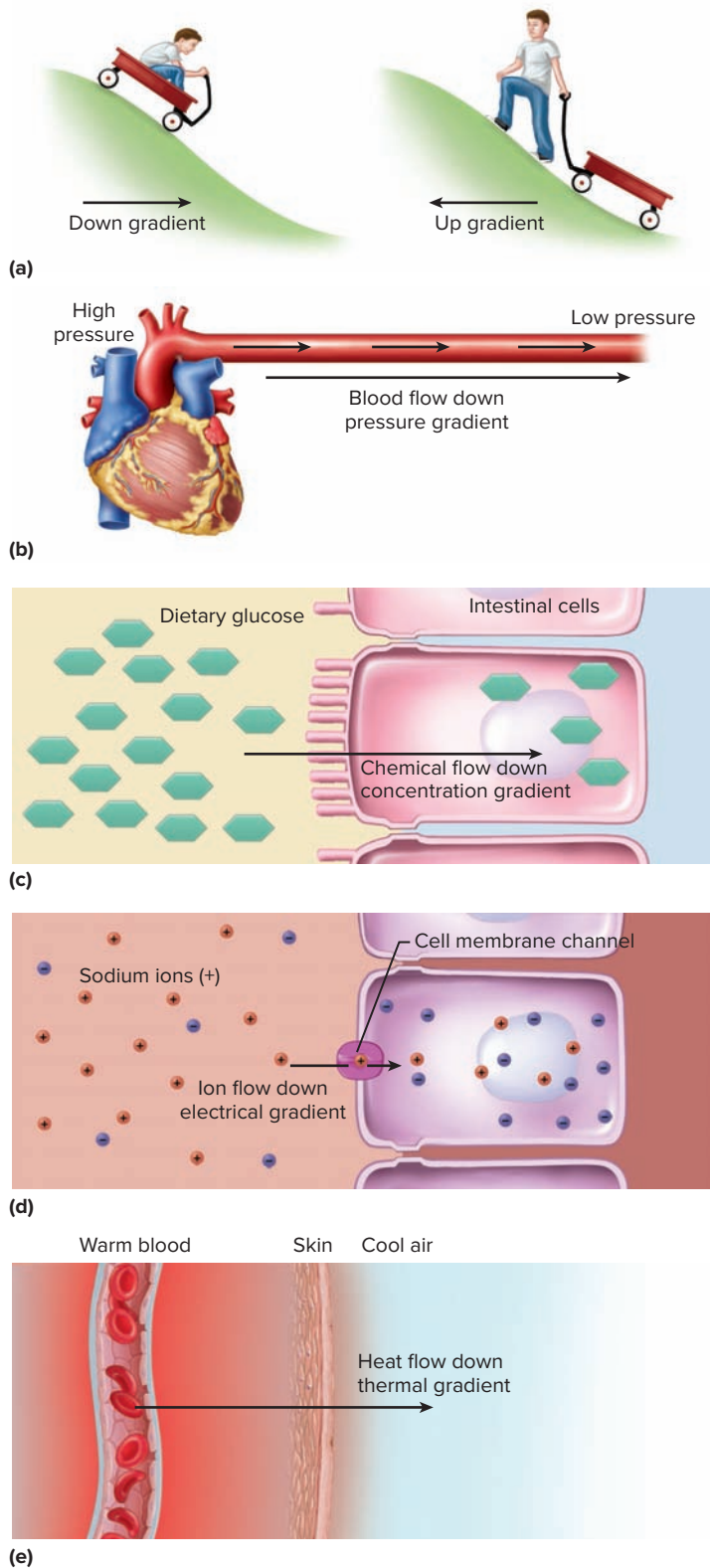
Consider some examples and analogies. If you open a water tap with a garden hose on it, you create a **pressure gradient**; water flows down the hose from the high-pressure point at the tap to the low-pressure point at the open end. Each heartbeat is like that, creating a gradient from high blood pressure near the heart to low pressure farther away; blood flows down this gradient away from the heart (fig. 1.9b). When we inhale, air flows down a pressure gradient from the surrounding atmosphere to pulmonary air passages where the pressure is lower. A pressure gradient also drives the process in which the kidneys filter water and waste products from the blood.



**FIGURE 1.8 Positive Feedback in Childbirth.**

**?** Could childbirth as a whole be considered a negative feedback event? Discuss.





**FIGURE 1.9 Flow Down Gradients.** (a) A wagon rolling downhill (down a gradient) (left) is a useful analogy to spontaneous, gradient-driven physiological processes. Moving up a gradient (right) requires an energy input. (b) Blood flowing down a pressure gradient. (c) Dietary sugars flowing down a concentration gradient into an intestinal cell. (d) Sodium ions flowing down an electrical gradient into a cell. (e) Heat flowing down a thermal gradient to leave the body through the skin.

Chemicals flow down **concentration gradients**. When we digest starch, a high concentration of free sugars accumulates in the small intestine. The cells lining the intestine contain only a low concentration of sugars, so sugars flow from the intestinal space into these cells, thus becoming absorbed into the body's tissues (fig. 1.9c). Water flows through cell membranes and epithelia by *osmosis*, from the side where it is more concentrated to the side where it is less so.

Charged particles flow down **electrical gradients**. Suppose there is a high concentration of sodium ions ( $\text{Na}^+$ ) just outside a cell and much lower concentration inside, so the outer surface of the cell membrane has a relatively positive charge and the inner surface is relatively negative (fig. 1.9d). If we open channels in the membrane that will let sodium pass, sodium ions rush into the cell, flowing down their electrical gradient. Because each  $\text{Na}^+$  carries a positive charge, this flow constitutes an electrical current through the membrane. We tap this current to make our nerves fire, our heart beat, and our muscles contract. In many cases, the flow of ions is governed by a combination of concentration and electrical charge differences between two points, and we say that ions flow down **electrochemical gradients**. These will be studied especially in connection with muscle and nerve action in chapters 11 and 12.

Heat flows down a **thermal gradient**. Suppose there is warm blood flowing through small arteries close to the skin surface, and the air temperature around the body is cooler (fig. 1.9e). Heat will flow from the blood to the surrounding air, down its thermal gradient, and be lost from the body. You will see in chapter 27 that heat flow is also important in preventing the testes from overheating, which would otherwise prevent sperm production.

Thus, you can see there are many applications in human physiology for this universal tendency of matter and energy to flow down gradients. This principle arises many times in the chapters to follow. We will revisit it next in chapter 3 when we consider how materials move into and out of cells through the cell membrane.

### BEFORE YOU GO ON

Answer the following questions to test your understanding of the preceding section:

- List four biological criteria of life and one clinical criterion. Explain how a person could be clinically dead but biologically alive.
- What is meant by *dynamic equilibrium*? Why would it be wrong to say homeostasis prevents internal change?
- Explain why stabilizing mechanisms are called *negative feedback*.
- Explain why positive feedback is more likely than negative feedback to disturb homeostasis.
- Active tissues generate carbon dioxide, which diffuses out of the tissue into the bloodstream, to be carried away. Is this diffusion into the blood a case of flow up a gradient, or down? Explain.

## 1.7 The Language of Medicine

### Expected Learning Outcomes

When you have completed this section, you should be able to

- explain why modern anatomical terminology is so heavily based on Greek and Latin;
- recognize eponyms when you see them;
- describe the efforts to achieve an internationally uniform anatomical terminology;
- break medical terms down into their basic word elements;
- state some reasons why the literal meaning of a word may not lend insight into its definition;
- relate singular noun forms to their plural and adjectival forms; and
- discuss why precise spelling is important in anatomy and physiology.

One of the greatest challenges faced by students of anatomy and physiology is the vocabulary. In this book, you will encounter such Latin terms as *corpus callosum* (a brain structure), *ligamentum arteriosum* (a small fibrous band near the heart), and *extensor carpi radialis longus* (a forearm muscle). You may wonder why structures aren't named in "just plain English," and how you will ever remember such formidable names. This section will give you some answers to these questions and some useful tips on mastering anatomical terminology.

### The History of Anatomical Terminology

The major features of human gross anatomy have standard international names prescribed by a book titled the *Terminologia Anatomica (TA)*. The *TA* was codified in 1998 by an international committee of anatomists and approved by professional associations of anatomists in more than 50 countries.

About 90% of today's medical terms are formed from just 1,200 Greek and Latin roots. Why those two languages? Scientific investigation began in ancient Greece and soon spread to Rome. The Greeks and Romans coined many of the words still used in human anatomy today: *duodenum*, *uterus*, *prostate*, *cerebellum*, *diaphragm*, *sacrum*, *amnion*, and others. In the Renaissance, the fast pace of discovery required a profusion of new terms to describe things. Anatomists in different countries began giving different names to the same structures. Adding to the confusion, they often named new structures and diseases in honor of their esteemed teachers and predecessors, giving us such nondescriptive terms as *fallopian tube* and *duct of Santorini*. Terms coined from the names of people, called **eponyms**,<sup>17</sup> afford little clue as to what a structure or condition is.

In hopes of resolving this growing confusion, anatomists began meeting as early as 1895 to devise a uniform international

terminology. After several false starts, they agreed on a list of terms that rejected all eponyms and gave each structure a unique Latin name to be used worldwide. Even if you were to look at an anatomy atlas in Japanese or Arabic, the illustrations may be labeled with the same Latin terms as in an English-language atlas. That list served for many decades until recently replaced by the *TA*, which prescribes both Latin names and accepted English equivalents. The terminology in this book conforms to the *TA* except where undue confusion would result from abandoning widely used, yet unofficial, terms.

### Analyzing Medical Terms

The task of learning medical terminology seems overwhelming at first, but it is a simple skill to become more comfortable with the technical language of medicine. People who find scientific terms confusing and difficult to pronounce, spell, and remember often feel more confident once they realize the logic of how terms are composed. A term such as *hyponatremia* is less forbidding once we recognize that it is composed of three common word elements: *hypo-* (below normal), *natr-* (sodium), and *-emia* (blood condition). Thus, hyponatremia is a deficiency of sodium in the blood. Those word elements appear over and over in many other medical terms: *hypothermia*, *natriuretic*, *anemia*, and so on. Once you learn the meanings of *hypo-*, *natri-*, and *-emia*, you already have the tools to at least partially understand hundreds of other biomedical terms. In appendix F, you will find a lexicon of the 400 word elements most commonly footnoted in this book.

Scientific terms are typically composed of one or more of the following elements:

- At least one *root (stem)* that bears the core meaning of the word. In *cardiology*, for example, the root is *cardi-* (heart). Many words have two or more roots. In *cardiomyopathy*, for example, the roots are *cardi-* (heart), *my-* (muscle), and *path-* (disease).
- *Combining vowels* that are often inserted to join roots and make the word easier to pronounce. In *cardiomyopathy*, each *o* is a combining vowel. Although *o* is the most common combining vowel, all vowels of the alphabet are used in this way, such as *a* in *ligament*, *e* in *vitreous*, *i* in *fusiform*, *u* in *ovulation*, and *y* in *tachycardia*. Some words, such as *intervertebral*, have no combining vowels. A combination of a root and combining vowel is called a *combining form*; for example, *chrom-* (color) + *o* (a combining vowel) make the combining form *chromo-*, as in *chromosome*.
- A *prefix* may be present to modify the core meaning of the word. For example, *gastric* (pertaining to the stomach or to the belly of a muscle) takes on a variety of new meanings when prefixes are added to it: *epigastric* (above the stomach), *hypogastric* (below the stomach), *endogastric* (within the stomach), and *digastric* (a muscle with two bellies).
- A *suffix* may be added to the end of a word to modify its core meaning. For example, *microscope*, *microscopy*,

<sup>17</sup>*epo* = *epi* = upon, based upon; *nym* = name

*microscopic*, and *microscopist* have different meanings because of their suffixes alone. Often two or more suffixes, or a root and suffix, occur together so often that they are treated jointly as a *compound suffix*; for example, *log* (study) + *y* (process) form the compound suffix *-logy* (the study of).

To summarize these basic principles, consider the word *gastroenterology*, a branch of medicine dealing with the stomach and small intestine. It breaks down into *gastro/entero/logy*:

|               |   |  |
|---------------|---|--|
| <i>gastro</i> | = | a combining form meaning “stomach”         |
| <i>entero</i> | = | a combining form meaning “small intestine” |
| <i>logy</i>   | = | a compound suffix meaning “the study of”   |

“Dissecting” words in this way and paying attention to the word-origin footnotes throughout this book will help you become more comfortable with the language of anatomy. Knowing how a word breaks down and knowing the meaning of its elements make it far easier to pronounce a word, spell it, and remember its definition. There are a few unfortunate exceptions, however. The path from original meaning to current usage has often become obscured by history (see Deeper Insight 1.4). The foregoing approach also is no help with eponyms or **acronyms**<sup>18</sup>—words composed of the first letter, or first few letters, of a series of words. For example, a common medical imaging method is the PET scan, an acronym for *positron emission tomography*. Note that PET is a pronounceable word, hence a true acronym. Acronyms are not to be confused with simple abbreviations such as DNA and MRI, in which each letter must be pronounced separately.

## Plural, Adjectival, and Possessive Forms

A point of confusion for many beginning students is how to recognize the plural forms of medical terms. Few people would fail to recognize that *ovaries* is the plural of *ovary*, but the connection is harder to make in other cases: For example, the plural of *cortex* is *cortices* (COR-ti-sees), the plural of *corpus* is *corpora*, and the plural of *ganglion* is *ganglia*. Table 1.1 will help you make the connection between common singular and plural noun terminals.

In some cases, what appears to the beginner to be two completely different words may be only the noun and adjectival forms of the same word. For example, *brachium* denotes the arm, and *brachii* (as in the muscle name *biceps brachii*) means “of the arm.” *Carpus* denotes the wrist, and *carpi*, a word used in several muscle names, means “of the wrist.” Adjectives can also take different forms for the singular and plural and for different degrees of comparison. The *digits* are the fingers and toes. The word *digiti* in a muscle name means “of a single finger (or toe),” whereas *digitorum* is the plural, meaning “of multiple fingers (or toes).” Thus, the *extensor digiti minimi muscle* extends only the little finger, whereas the *extensor digitorum muscle* extends all fingers except the thumb.



## DEEPER INSIGHT 1.4 MEDICAL HISTORY

### Obscure Word Origins

The literal translation of a word doesn’t always provide great insight into its modern meaning. The history of language is full of twists and turns that are fascinating in their own right and say much about the history of human culture, but they can create confusion for students.

For example, the *amnion* is a transparent sac that forms around the developing fetus. The word is derived from *amnos*, from the Greek for “lamb.” From this origin, *amnos* came to mean a bowl for catching the blood of sacrificial lambs, and from there the word found its way into biomedical usage for the membrane that emerges (quite bloody) as part of the afterbirth. The *acetabulum*, the socket of the hip joint, literally means “vinegar cup.” Apparently the hip socket reminded an anatomist of the little cups used to serve vinegar as a condiment on dining tables in ancient Rome. The word *testicles* can be translated “little pots” or “little witnesses.” The history of medical language has several amusing conjectures as to why this word was chosen to name the male gonads.

TABLE 1.1

Singular and Plural Forms of Some Noun Terminals

| Singular Ending | Plural Ending | Examples                 |
|-----------------|---------------|--------------------------|
| -a              | -ae           | axilla, axillae          |
| -en             | -ina          | lumen, lumina            |
| -ex             | -ices         | cortex, cortices         |
| -is             | -es           | diagnosis, diagnoses     |
| -is             | -ides         | epididymis, epididymides |
| -ix             | -ices         | appendix, appendices     |
| -ma             | -mata         | carcinoma, carcinomata   |
| -on             | -a            | ganglion, ganglia        |
| -um             | -a            | septum, septa            |
| -us             | -era          | viscus, viscera          |
| -us             | -i            | villus, villi            |
| -us             | -ora          | corpus, corpora          |
| -x              | -ges          | phalanx, phalanges       |
| -y              | -ies          | ovary, ovaries           |
| -yx             | -yces         | calyx, calyces           |

The English words *large*, *larger*, and *largest* are examples of the positive, comparative, and superlative degrees of comparison. In Latin, these are *magnus*, *major* (from *maior*), and *maximus*. We find these in the muscle names *adductor magnus* (a *large* muscle of the thigh), the *pectoralis major* (the *larger* of two pectoralis muscles of the chest), and *gluteus maximus* (the *largest* of the three gluteal muscles of the buttock).

Some noun variations indicate the possessive, such as the *rectus abdominis*, a straight (*rectus*) muscle of the abdomen (*abdominis*, “of the abdomen”), and the *erector spinae*, a muscle that straightens (*erector*) the spinal column (*spinae*, “of the spine”).

Anatomical terminology also frequently follows the Greek and Latin practice of placing the adjective after the noun. Thus, we

<sup>18</sup> *acro* = beginning; *nym* = name



have such names as the *stratum lucidum* for a clear (*lucidum*) layer (*stratum*) of the epidermis, the *foramen magnum* for a large (*magnum*) hole (*foramen*) in the skull, and the aforementioned *pectoralis major* muscle of the chest.

This is not to say that you must be conversant in Latin or Greek grammar to proceed with your study of anatomy. These few examples, however, may alert you to some patterns to watch for in the terminology you study and, ideally, will make your encounters with anatomical terminology less confusing.

## Pronunciation

Pronunciation is another stumbling block for many beginning anatomy and physiology students. This book gives simple pro-NUN-see-AY-shun guides for many terms when they are first introduced. Read the syllables of these guides phonetically and accent the syllables in capital letters. You can also hear pronunciations of most of the anatomical terms within Anatomy & Physiology REVEALED®.

## The Importance of Precision

A final word of advice for your study of anatomy and physiology: Be precise in your use of terms. It may seem trivial if you misspell *trapezius* as *trapezium*, but in doing so, you would be changing the name of a back muscle to the name of a wrist bone. Similarly, changing *occipitalis* to *occipital* or *zygomaticus* to *zygomatic* changes other muscle names to bone names. Changing *malleus* to *malleolus* changes the name of a middle-ear bone to the name of a bony protuberance of the ankle. And there is only a one-letter difference between *ileum* (the final portion of the small intestine) and *ilium* (part of the hip bone), and between *gustation* (the sense of taste) and *gestation* (pregnancy).

The health professions demand the utmost attention to detail and precision—people’s lives may one day be in your hands. The habit of carefulness must extend to your use of language as well. Many patients have died simply because of tragic written and oral miscommunication in the hospital. Compared to this, it is hardly tragic if your instructor deducts a point or two for an error in spelling. It should be considered a lesson learned about the importance of accuracy.

### BEFORE YOU GO ON

Answer the following questions to test your understanding of the preceding section:

21. Explain why modern anatomical terminology is so heavily based on Greek and Latin.
22. Distinguish between an eponym and an acronym, and explain why both of these present difficulties for interpreting anatomical terms.
23. Break each of the following words down into its roots, prefixes, and suffixes, and state their meanings, following the example of *gastroenterology* analyzed earlier: *pericardium*, *appendectomy*, *subcutaneous*, *phonocardiogram*, *otorhinolaryngology*. Consult the list of word elements in appendix F for help.
24. Write the singular form of each of the following words: *pleurae*, *gyri*, *ganglia*, *fissures*. Write the plural form of each of the following: *villus*, *tibia*, *encephalitis*, *cervix*, *stoma*.

## 1.8 Review of Major Themes

To close this chapter, let’s distill a few major points from it. These themes can provide you with a sense of perspective that will make the rest of the book more meaningful and not just a collection of disconnected facts. These are some key unifying principles behind all study of human anatomy and physiology:

- **Unity of form and function.** *Form and function complement each other; physiology cannot be divorced from anatomy.* This unity holds true even down to the molecular level. Our very molecules, such as DNA and proteins, are structured in ways that enable them to carry out their functions. Slight changes in molecular structure can destroy their activity and threaten life.
- **Cell theory.** *All structure and function result from the activity of cells.* Every physiological concept in this book ultimately must be understood from the standpoint of how cells function. Even anatomy is a result of cellular function. If cells are damaged or destroyed, we see the results in disease symptoms of the whole person.
- **Evolution.** *The human body is a product of evolution.* Like every other living species, we have been molded by millions of years of natural selection to function in a changing environment. Many aspects of human anatomy and physiology reflect our ancestors’ adaptations to their environment. Human form and function cannot be fully understood except in light of our evolutionary history.
- **Hierarchy of complexity.** *Human structure can be viewed as a series of levels of complexity.* Each level is composed of a smaller number of simpler subunits than the level above it. These subunits are arranged in different ways to form diverse structures of higher complexity. Understanding the simpler components is the key to understanding higher levels of structure.
- **Homeostasis.** *The purpose of most normal physiology is to maintain stable conditions within the body.* Human physiology is essentially a group of homeostatic mechanisms that produce stable internal conditions favorable to cellular function. Any serious departure from these conditions can be harmful or fatal to cells and thus to the whole body.
- **Gradients and flow.** Matter and energy tend to flow down gradients such as differences in chemical concentration, pressure, temperature, and electrical charge. This accounts for much of their movement in human physiology.

### ▶▶▶ APPLY WHAT YOU KNOW

Architect Louis Henri Sullivan coined the phrase, “Form ever follows function.” What do you think he meant by this? Discuss how this idea could be applied to the human body and cite a specific example of human anatomy to support it.





## DEEPER INSIGHT 1.5

### CLINICAL APPLICATION

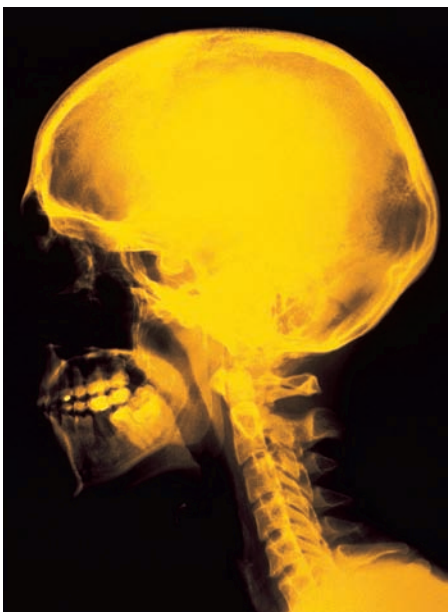#### Medical Imaging

The development of techniques for looking into the body without having to do exploratory surgery has greatly accelerated progress in medicine. A few of these techniques are described here.

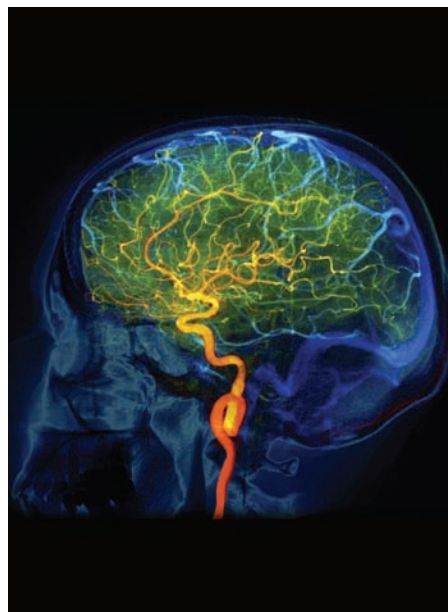#### Radiography

*Radiography*, first performed in 1895, is the process of photographing internal structures with X-rays. Until the 1960s, this was the only widely available imaging method; even today, it accounts for more than 50% of all clinical imaging. X-rays pass through the soft tissues of the body to a photographic film or detector on the other side, where they produce relatively dark images. They are absorbed, however, by dense matter

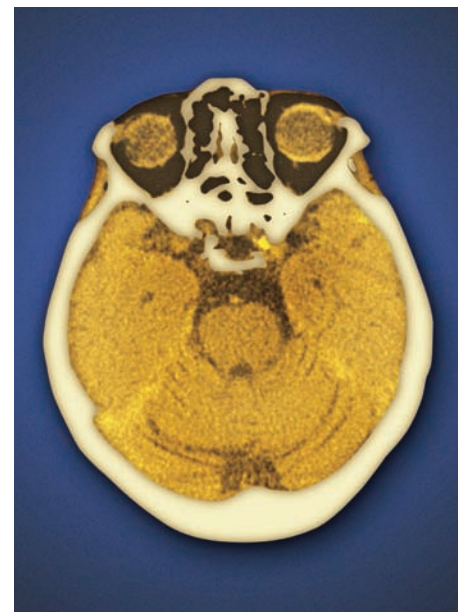
such as bones, teeth, tumors, and tuberculosis nodules, which leave the image lighter in these areas (fig. 1.10a). The term *X-ray* also applies to an image (*radiograph*) made by this method. Radiography is commonly used in dentistry, mammography, diagnosis of fractures, and examination of the chest. Hollow organs can be visualized by filling them with a *radiopaque* substance that absorbs X-rays. Barium sulfate, for example, is given orally for examination of the esophagus, stomach, and small intestine or by enema for examination of the large intestine. Other substances are given by injection for *angiography*, the examination of blood vessels (fig. 1.10b). Some disadvantages of radiography are that images of overlapping organs can be confusing and slight differences in tissue



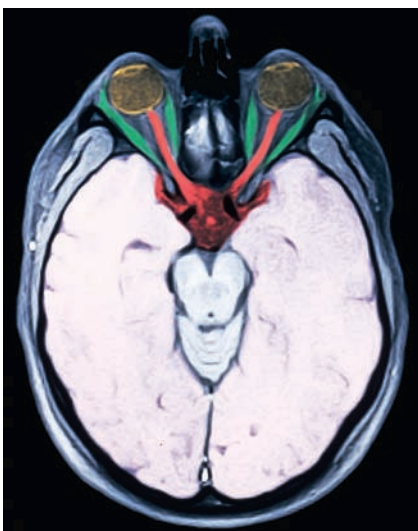
(a) X-ray (radiograph)



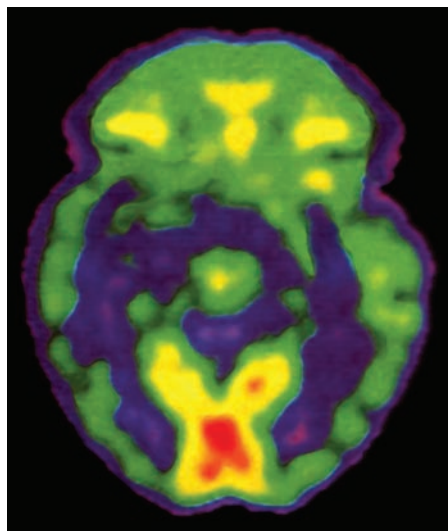
(b) Cerebral angiogram



(c) Computed tomographic (CT) scan



(d) Magnetic resonance image (MRI)



(e) Positron emission tomographic (PET) scan

**FIGURE 1.10 Radiologic Images of the Head.** (a) X-ray (radiograph) showing the bones and teeth. (b) An angiogram of the cerebral blood vessels. (c) A CT scan at the level of the eyes. (d) An MRI scan at the level of the eyes. The optic nerves appear in red and the muscles that move the eyes appear in green. (e) A PET scan of the brain of an unmedicated schizophrenic patient. Red areas indicate regions of high metabolic rate. In this patient, the visual center of the brain at the rear of the head (bottom of photo) was especially active during the scan.

a: ©U.H.B. Trust/Tony Stone Images/Getty Images;  
b: ©Zephyr/Science Source; c: © Miriam Maslo/  
Science Source; d: © UHB Trust/Getty Images;  
e: ©ISM/Phototake

**?** What structures are seen better by MRI than by X-ray? What structures are seen better by X-ray than by PET?

density are not easily detected. In addition, X-rays can cause mutations leading to cancer and birth defects. Radiography therefore cannot be used indiscriminately.

### Computed Tomography

*Computed tomography*<sup>19</sup> (a *CT scan*) is a more sophisticated application of X-rays. The patient is moved through a ring-shaped machine that emits low-intensity X-rays on one side and receives them with a detector on the opposite side. A computer analyzes signals from the detector and produces an image of a “slice” of the body about as thin as a coin (fig. 1.10c). The advantage of such thin planes of view is that there is little overlap of organs, so the image is much sharper than a conventional X-ray. It requires extensive knowledge of cross-sectional anatomy to interpret the images. CT scanning is useful for identifying tumors, aneurysms, cerebral hemorrhages, kidney stones, and other abnormalities.

### Magnetic Resonance Imaging

*Magnetic resonance imaging (MRI)* was conceived as a technique superior to CT for visualizing some soft tissues. The patient lies in a chamber surrounded by a large electromagnet that creates a very strong magnetic field. Hydrogen atoms in the tissues align themselves with this field. The technologist then activates a radio wave signal (heard by the patient as loud, varied noises), causing the hydrogen atoms to absorb additional energy and align in a new direction. When the radio signal is turned off, the hydrogen atoms realign themselves to the magnetic field, giving off their excess energy at rates that depend on the type of tissue. A computer analyzes the emitted energy to produce an image of the body. MRI can “see” clearly through the skull and spinal column to produce images of the nervous tissue (fig. 1.10d). Moreover, it is better than CT for distinguishing between soft tissues such as the white and gray matter of the nervous system. MRI also avoids exposure to harmful X-rays.

A disadvantage of MRI is that it requires a patient to lie still in the enclosed space for up to 45 minutes to scan one region of the body and may entail 90 minutes to scan multiple regions such as the abdominal and pelvic cavities. Some patients find they cannot do this. Also, because of the long exposures involved, MRI is not as good as CT for scanning the digestive tract; stomach and intestinal motility produce blurred images over such long exposures.

*Functional MRI (fMRI)* is a variation that visualizes moment-to-moment changes in tissue function. fMRI scans of the brain, for example, show shifting patterns of activity as the brain applies itself to a specific sensory, mental, or motor task. fMRI has lately replaced the PET scan as the most important method for visualizing brain function. The use of fMRI in brain imaging is further discussed in Deeper Insight 14.4.

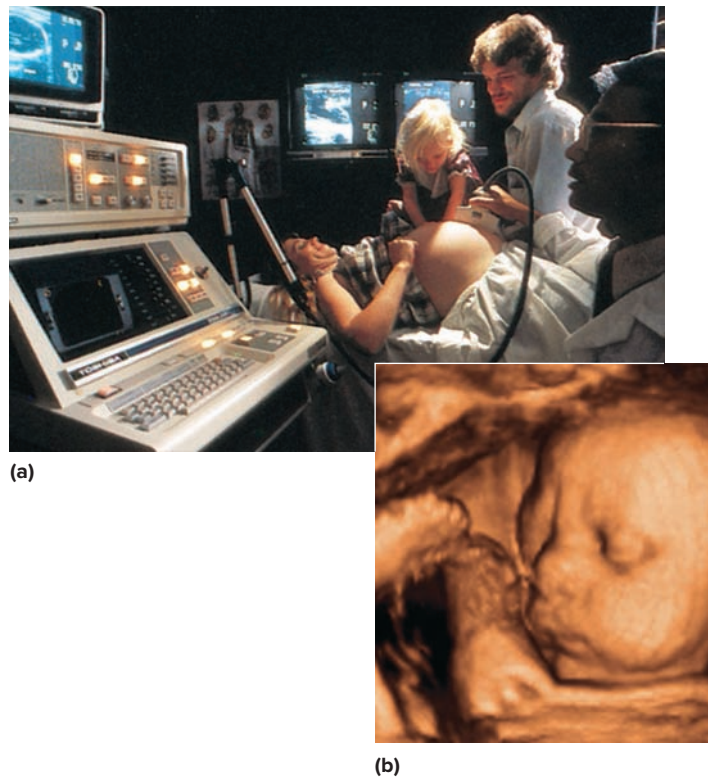
### Positron Emission Tomography

*Positron emission tomography* (the *PET scan*) is used to assess the metabolic state of a tissue and distinguish which tissues are most active at a given moment (fig. 1.10e). The procedure begins with an injection of radioactively labeled glucose, which emits positrons (electron-like particles with a positive charge). When a positron and electron meet,

they annihilate each other and give off a pair of gamma rays that can be detected by sensors and analyzed by computer. The computer displays a color image that shows which tissues were using the most glucose at the moment. In cardiology, PET scans can show the extent of tissue death from a heart attack. Since it consumes little or no glucose, the damaged tissue appears dark. PET scans are also widely used to diagnose cancer and evaluate tumor status. The PET scan is an example of *nuclear medicine*—the use of radioactive isotopes to treat disease or to form diagnostic images of the body.

### Sonography

*Sonography*<sup>20</sup> is the second oldest and second most widely used method of imaging. A handheld device pressed against the skin produces high-frequency ultrasound waves and receives the signals that echo back from internal organs. Sonography is not very useful for examining bones or lungs, but it is the method of choice in obstetrics, where the image (*sonogram*) can be used to locate the placenta and evaluate fetal age, position, and development. Sonography is also used to view tissues in motion, such as fetal movements, actions of the heart wall and valves, and blood ejection from the heart and flow through arteries and veins. Sonographic imaging of the beating heart is called *echocardiography*. Sonography avoids the harmful effects of X-rays, and the equipment is inexpensive and portable. Some disadvantages are that sonography cannot penetrate bone and it usually does not produce a very sharp image (fig. 1.11).



**FIGURE 1.11 Fetal Sonography.** (a) Producing a sonogram. (b) Three-dimensional fetal sonogram at 32 weeks of gestation. a: © Alexander Tsiaras/Science Source; b: © Ken Saladin

<sup>19</sup>*tomo* = section, cut, slice; *graphy* = recording process

<sup>20</sup>*sono* = sound; *graphy* = recording process

# STUDY GUIDE

## ▶ Assess Your Learning Outcomes

To test your knowledge, discuss the following topics with a study partner or in writing, ideally from memory.

### 1.1 The Scope of Anatomy and Physiology

1. The meanings of *anatomy* and *physiology* and what it means to say these two sciences are complementary
2. Methods of study in anatomy and clinical examination
3. Branches of anatomy that study the body at different levels of detail
4. How comparative physiology advances the understanding of human function

### 1.2 The Origins of Biomedical Science

1. Greek and Roman scholars who first gave medicine a scientific basis
2. Ways in which the work of Maimonides, Avicenna, Vesalius, and Harvey were groundbreaking in the context of their time and culture
3. Why medical science today owes such a great debt to Hooke, Leeuwenhoek, and other inventors
4. How Schleiden and Schwann revolutionized and unified the understanding of biological structure, ultimately including human anatomy and physiology

### 1.3 Scientific Method

1. How philosophers Bacon and Descartes revolutionized society's view of science, even though neither of them was a scientist
2. The essential qualities of the scientific method
3. The nature of the inductive and hypothetico-deductive methods, how they differ, and which areas of biomedical science most heavily employ each method
4. The qualities of a valid scientific hypothesis, the function of a hypothesis, and what is meant by *falsifiability* in science
5. How each of the following contributes to the reliability of a researcher's scientific conclusions and the trust that the public may place

in science: sample size, control groups, the double-blind method, statistical testing, and peer review

6. The distinctions between scientific facts, laws, and theories; the purpose of a theory; and how the scientific meanings of *law* and *theory* differ from the common lay meanings

### 1.4 Human Origins and Adaptations

1. The meanings of *evolution*, *natural selection*, *selection pressure*, and *adaptation*, with examples of each
2. The historical origin of the theory of natural selection and how this theory is relevant to a complete understanding of human anatomy and physiology
3. How the kinship among all species is relevant to the choice of model animals for biomedical research
4. Ecological conditions thought to have selected for such key characteristics of *Homo sapiens* as opposable thumbs, shoulder mobility, prehensile hands, stereoscopic vision, color vision, and bipedal locomotion
5. A description of evolutionary medicine

### 1.5 Human Structure

1. Levels of human structural complexity from organism to atom
2. Reductionism and holism; how they differ and why both ideas are relevant to the study of human anatomy and physiology and to the clinical care of patients
3. Examples of why the anatomy presented in textbooks is not necessarily true of every individual

### 1.6 Human Function

1. Eight essential qualities that distinguish living organisms from nonliving things
2. The meaning of *metabolism*
3. Clinical criteria for life and death, and why clinical and biological death are not exactly equivalent
4. The clinical importance of physiological variation between people, and the

assumptions that underlie typical values given in textbooks

5. The meaning of *homeostasis*; its importance for survival; and the historical origin of this concept
6. How negative feedback contributes to homeostasis; the meaning of *negative feedback loop*; how a receptor, integrating center, and effector are involved in many negative feedback loops; and at least one example of such a loop
7. How positive feedback differs from negative feedback; examples of beneficial and harmful cases of positive feedback
8. The concept of matter and energy flowing down gradients and how this applies to various areas of human physiology

### 1.7 The Language of Medicine

1. The origin and purpose of the *Terminologia Anatomica (TA)* and its relevance for anatomy students
2. How to break biomedical terms into familiar roots, prefixes, and suffixes, and why the habit of doing so aids in learning
3. Acronyms and eponyms, and why they cannot be understood by trying to analyze their roots
4. How to recognize when two or more words are singular and plural versions of one another; when one word is the possessive form of another; and when medical terms built on the same root represent different degrees of comparison (such as terms denoting *large*, *larger*, and *largest*)
5. Why precision in spelling and usage of medical terms can be a matter of life or death in a hospital or clinic, and how seemingly trivial spelling errors can radically alter meaning

### 1.8 Review of Major Themes

1. A description of six core themes of this book: unity of form and function, cell theory, evolution, hierarchy of complexity, homeostasis, and gradients and flow



# STUDY GUIDE

## ▶ Testing Your Recall

Answers in Appendix B

- Structure that can be observed with the naked eye is called
  - gross anatomy.
  - ultrastructure.
  - microscopic anatomy.
  - histology.
  - cytology.
- The word prefix *homeo-* means
  - tissue.
  - metabolism.
  - change.
  - human.
  - same.
- The simplest structures considered to be alive are
  - organisms.
  - organs.
  - tissues.
  - cells.
  - organelles.
- Which of the following people revolutionized the teaching of gross anatomy?
  - Vesalius
  - Aristotle
  - Hippocrates
  - Leeuwenhoek
  - Cannon
- Which of the following embodies the greatest amount of scientific information?
  - a fact
  - a law of nature
  - a theory
  - a deduction
  - a hypothesis
- An informed, uncertain, but testable conjecture is
  - a natural law.
  - a scientific theory.
  - a hypothesis.
  - a deduction.
  - a scientific fact.
- A self-amplifying chain of physiological events is called
  - positive feedback.
  - negative feedback.
  - dynamic constancy.
  - homeostasis.
  - metabolism.
- Which of the following is *not* a human organ system?
  - integumentary
  - muscular
  - epithelial
  - nervous
  - endocrine
- \_\_\_\_\_ means studying anatomy by touch.
  - Gross anatomy
  - Auscultation
  - Osculation
  - Palpation
  - Percussion
- The prefix *hetero-* means
  - same.
  - different.
  - both.
  - solid.
  - below.
- Cutting and separating tissues to reveal structural relationships is called \_\_\_\_\_.
  - dissection
  - gross anatomy
  - microscopic anatomy
  - histology
  - cytology
- A difference in chemical concentration between one point and another is called a concentration \_\_\_\_\_.
  - gradient
  - difference
  - change
  - variation
  - ratio
- By the process of \_\_\_\_\_, a scientist predicts what the result of a certain experiment will be if his or her hypothesis is correct.
  - prediction
  - hypothesis
  - deduction
  - induction
  - inference
- Physiological effects of a person's mental state are called \_\_\_\_\_ effects.
  - psychosomatic
  - psychomotor
  - psychic
  - psychic
  - psychic
- The tendency of the body to maintain stable internal conditions is called \_\_\_\_\_.
  - homeostasis
  - metabolism
  - dynamic constancy
  - positive feedback
  - negative feedback
- Blood pH averages 7.4 but fluctuates from 7.35 to 7.45. A pH of 7.4 can therefore be considered the \_\_\_\_\_ for this variable.
  - set point
  - range
  - variation
  - difference
  - ratio
- Self-corrective mechanisms in physiology are called \_\_\_\_\_ loops.
  - homeostatic
  - dynamic
  - constancy
  - positive feedback
  - negative feedback
- A/an \_\_\_\_\_ is the simplest body structure to be composed of two or more types of tissue.
  - organ
  - organism
  - organ system
  - organismal system
  - organismal system
- Depth perception, or the ability to form three-dimensional images, is also called \_\_\_\_\_ vision.
  - stereoscopic
  - stereoscopic
  - stereoscopic
  - stereoscopic
  - stereoscopic
- Our hands are said to be \_\_\_\_\_ because they can encircle an object such as a branch or tool. The presence of an \_\_\_\_\_ thumb is important to this ability.
  - opposable
  - opposable
  - opposable
  - opposable
  - opposable

## STUDY GUIDE

### ► Building Your Medical Vocabulary

Answers in Appendix B

State a meaning of each word element, and give a medical term that uses it or a slight variation of it.

- |              |            |            |
|--------------|------------|------------|
| 1. auscult-  | 5. palp-   | 9. stereo- |
| 2. dis-      | 6. physio- | 10. tomo-  |
| 3. homeo-    | 7. -sect   |            |
| 4. metabolo- | 8. -stasis |            |

### ► What's Wrong with These Statements?

Answers in Appendix B

Briefly explain why each of the following statements is false, or reword it to make it true.

- |  |  |  |
|--|--|--|
| 1. The technique for taking a patient's pulse at the wrist is auscultation.  | 5. Matter does not generally move down a gradient in the body unless the body expends metabolic energy to move it. | physicians and scientists who run the study constitute the control group.  |
| 2. For a pregnant woman to have an MRI scan would expose her fetus to radiation that can potentially cause mutation and birth defects. | 6. Leeuwenhoek was a biologist who invented the simple microscope in order to examine organisms in lake water.     | 9. Human evolution is basically a theory that humans came from monkeys.    |
| 3. We usually depend on positive feedback to restore homeostatic balance and have a beneficial effect on the body.                     | 7. A scientific theory is just a speculation until someone finds the evidence to prove it.                         | 10. Negative feedback usually has a negative (harmful) effect on the body. |
| 4. There are far more cells than organelles in the body.   | 8. In a typical clinical research study, volunteer patients are in the treatment group and the                     |  |

### ► Testing Your Comprehension

- |   |   |  |
|---|---|--|
| 1. Ellen is pregnant and tells Janet, one of her coworkers, that she is scheduled to get a fetal sonogram. Janet expresses alarm and warns Ellen about the danger of exposing a fetus to X-rays. Discuss why you think Janet's concern is warranted or unwarranted. | 3. About 1 out of every 120 live-born infants has a structural defect in the heart such as a hole between two heart chambers. Such infants often suffer pulmonary congestion and heart failure, and about one-third of them die as a result. Which of the major themes in this chapter does this illustrate? Explain your answer. | 5. Suppose you have been doing heavy yard work on a hot day and sweating profusely. You become very thirsty, so you drink a tall glass of lemonade. Explain how your thirst relates to the concept of homeostasis. Which type of feedback—positive or negative—does this illustrate? |
| 2. Which of the characteristics of living things are possessed by an automobile? What bearing does this have on our definition of life?   | 4. How might human anatomy be different today if the forerunners of humans had never inhabited the forest canopy?   |  |

### ► IMPROVE YOUR GRADE



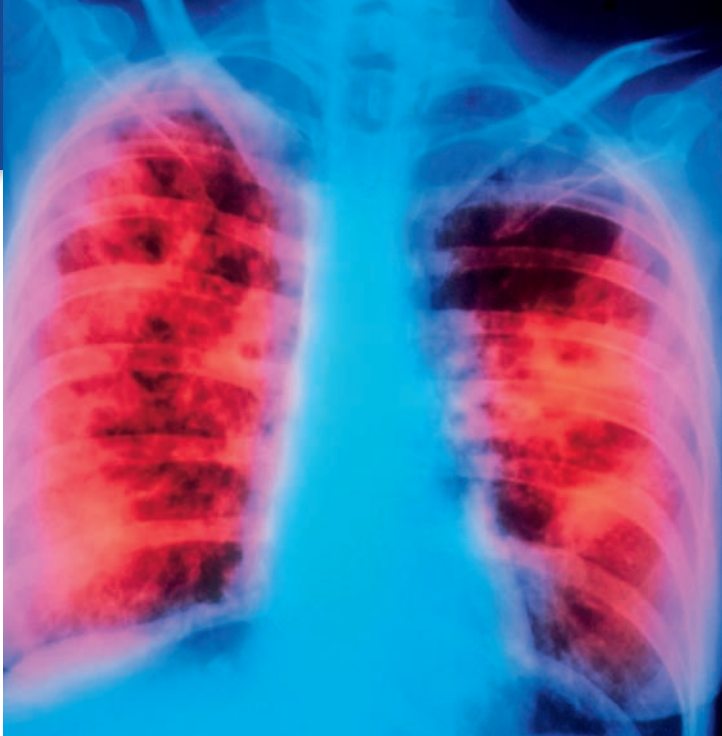**Connect Interactive Questions** Reinforce your knowledge using multiple types of questions: interactive, animation, classification, labeling, sequencing, composition, and traditional multiple choice and true/false.



**SmartBook** Proven to help students improve grades and study more efficiently, SmartBook contains the same content within the print book but actively tailors that content to the needs of the individual.



**Anatomy & Physiology REVEALED®** Dive into the human body by peeling back layers of cadaver imaging. Utilize this world-class cadaver dissection tool for a closer look at the body anytime, from anywhere.



Colorized chest X-ray showing lung damage from tuberculosis

© SPL/Science Source

# ATLAS A

## GENERAL ORIENTATION TO HUMAN ANATOMY

### ATLAS OUTLINE

#### A.1 General Anatomical Terminology

- Anatomical Position
- Anatomical Planes
- Directional Terms

#### A.2 Major Body Regions

- Axial Region
- Appendicular Region

#### A.3 Body Cavities and Membranes

- The Cranial Cavity and Vertebral Canal
- The Thoracic Cavity
- The Abdominopelvic Cavity
- Potential Spaces

#### A.4 Organ Systems

Study Guide

### DEEPER INSIGHT

#### A.1 Clinical Application: Peritonitis

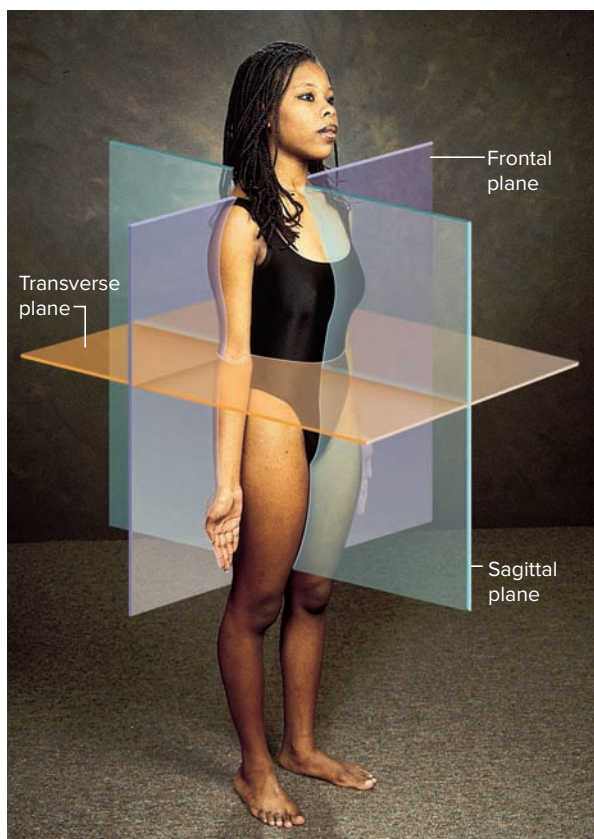


## A.1 General Anatomical Terminology

### Anatomical Position

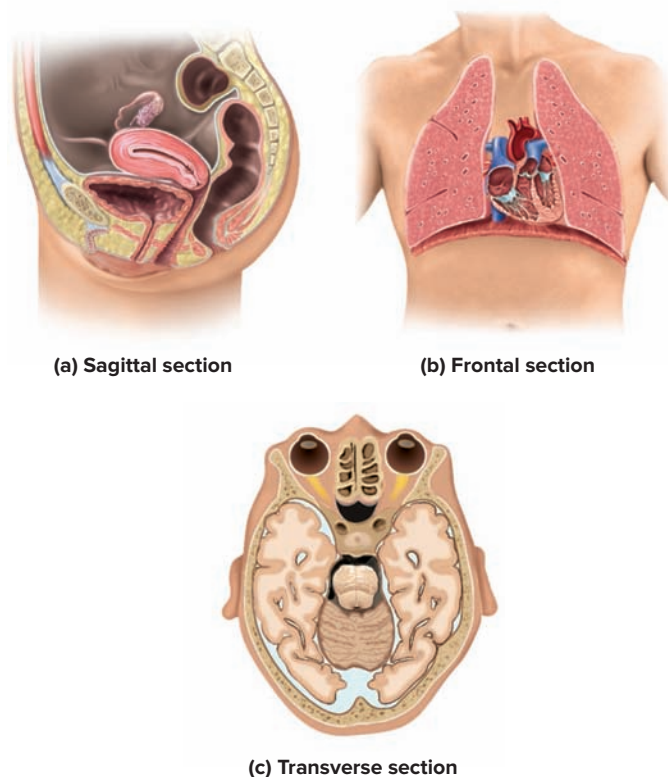
In describing the human body, anatomists assume that it is in **anatomical position** (fig. A.1)—that of a person standing upright with the feet flat on the floor, arms at the sides, and the palms and face directed forward. Without such a frame of reference, to say that a structure such as the sternum, thyroid gland, or aorta is “above the heart” would be vague, since it would depend on whether the subject was standing, lying face down (*prone*), or lying face up (*supine*). From the perspective of anatomical position, however, we can describe the thyroid as *superior* to the heart, the sternum as *anterior* to it, and the aorta as *posterior* to it. These descriptions remain valid regardless of the subject’s position. Even if the body is lying down, such as a cadaver on the medical student’s dissection table, to say the sternum is anterior to the heart invites the viewer to imagine the body is standing in anatomical position and not to call it “above the heart” simply because that is the way the body happens to be lying.

Unless stated otherwise, assume that all anatomical descriptions refer to anatomical position. Bear in mind that if a subject is facing you, the subject’s left will be on your right and vice versa.



**FIGURE A.1** Anatomical Position and the Three Primary Anatomical Planes.

© McGraw-Hill Education/Joe DeGrandis, photographer



**FIGURE A.2** Body Sections Cut Along the Three Primary Anatomical Planes. (a) Sagittal section of the pelvic region. (b) Frontal section of the thoracic region. (c) Transverse section of the head at the level of the eyes.

In most anatomical illustrations, for example, the left atrium of the heart appears toward the right side of the page, and although the appendix is located in the right lower quadrant of the abdomen, it appears on the left side of most illustrations.

### Anatomical Planes

Many views of the body are based on real or imaginary “slices” called sections or planes. *Section* implies an actual cut or slice to reveal internal anatomy, whereas *plane* implies an imaginary flat surface passing through the body. The three major anatomical planes are *sagittal*, *frontal*, and *transverse* (fig. A.1).

A **sagittal**<sup>1</sup> (SADJ-ih-tul) **plane** passes vertically through the body or an organ and divides it into right and left portions (fig. A.2a). The sagittal plane that divides the body or organ into equal halves is also called the **median (midsagittal) plane**. The head and pelvic organs are commonly illustrated on the median plane. Other sagittal planes parallel to this (off center) divide the body into unequal portions. Such planes are sometimes called *parasagittal*<sup>2</sup> planes.

A **frontal (coronal) plane** also extends vertically, but it is perpendicular to the sagittal plane and divides the body into anterior (front) and posterior (back) portions (fig. A.2b). A frontal section

<sup>1</sup>*sagitta* = arrow

<sup>2</sup>*para* = next to

**TABLE A.1** Directional Terms in Human Anatomy **AP|R**

| Term                          | Meaning   | Examples of Usage   |
|-------------------------------|---|---|
| Ventral<br>Dorsal             | Toward the front* or belly<br>Toward the back or spine  | The aorta is ventral to the vertebral column.<br>The vertebral column is dorsal to the aorta.   |
| Anterior<br>Posterior         | Toward the ventral side*<br>Toward the dorsal side*   | The sternum is anterior to the heart.<br>The esophagus is posterior to the trachea.   |
| Cephalic<br>Rostral<br>Caudal | Toward the head or superior end<br>Toward the forehead or nose<br>Toward the tail or inferior end | The cephalic end of the embryonic neural tube develops into the brain.<br>The forebrain is rostral to the brainstem.<br>The spinal cord is caudal to the brain. |
| Superior<br>Inferior          | Above<br>Below  | The heart is superior to the diaphragm.<br>The liver is inferior to the diaphragm.  |
| Medial<br>Lateral             | Toward the median plane<br>Away from the median plane   | The heart is medial to the lungs.<br>The eyes are lateral to the nose.  |
| Proximal<br>Distal            | Closer to the point of attachment or origin<br>Farther from the point of attachment or origin     | The elbow is proximal to the wrist.<br>The fingernails are at the distal ends of the fingers.   |
| Ipsilateral<br>Contralateral  | On the same side of the body (right or left)<br>On opposite sides of the body (right and left)    | The liver is ipsilateral to the appendix.<br>The spleen is contralateral to the liver.  |
| Superficial<br>Deep           | Closer to the body surface<br>Farther from the body surface                                       | The skin is superficial to the muscles.<br>The bones are deep to the muscles.   |

\*In humans only; definition differs for other animals.

of the head, for example, would divide it into one portion bearing the face and another bearing the back of the head. Contents of the thoracic and abdominal cavities are most commonly shown as frontal sections.

A **transverse (horizontal) plane** passes across the body or an organ perpendicular to its long axis; it divides the body or organ into superior (upper) and inferior (lower) portions (fig. A.2c). CT scans are typically transverse sections (see fig. 1.10c).

## Directional Terms

Words that describe the location of one structure relative to another are called the **directional terms** of anatomy. Table A.1 summarizes those most frequently used. Most of these terms exist in pairs with opposite meanings: *anterior* versus *posterior*, *rostral* versus *caudal*, *superior* versus *inferior*, *medial* versus *lateral*, *proximal* versus *distal*, *ipsilateral* versus *contralateral*, and *superficial* versus *deep*. Intermediate directions are often indicated by combinations of these terms. For example, one's cheeks may be described as *inferolateral* to the eyes (below and to the side).

The terms *proximal* and *distal* are used especially in the anatomy of the limbs, with *proximal* used to denote something relatively close to the limb's point of attachment (the shoulder or hip) and *distal* to denote something farther away. These terms do have some applications to anatomy of the trunk, however—for example, in referring to certain aspects of the intestines and microscopic anatomy of the kidneys. But when describing the trunk and referring to a structure that lies above or below another, *superior* and *inferior* are the preferred terms. These terms are not usually used for the limbs. Although it may be technically correct, one would not generally say that the elbow is superior to the wrist, but proximal to it.

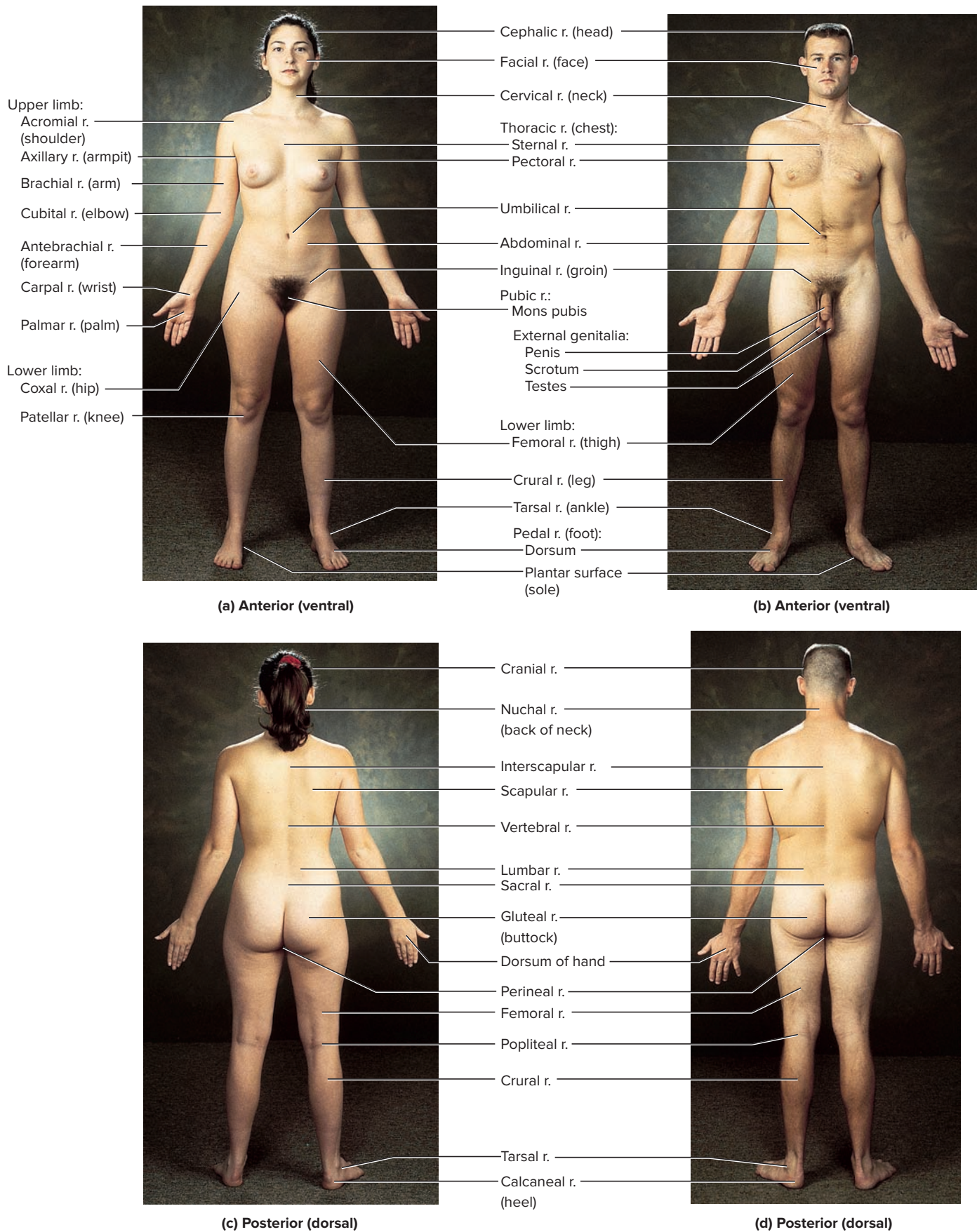
Because of the bipedal, upright stance of humans, some directional terms have different meanings for humans than they do for other animals. *Anterior*, for example, denotes the region of the body that leads the way in normal locomotion. For a four-legged animal such as a cat, this is the head end of the body; for a human, however, it is the front of the chest and abdomen. Thus, *anterior* has the same meaning as *ventral* for a human but not for a cat. *Posterior* denotes the region of the body that comes last in normal locomotion—the tail end of a cat but the dorsal side (back) of a human. In the anatomy of most other animals, *ventral* denotes the surface of the body closest to the ground and *dorsal* denotes the surface farthest away from the ground. These two words are too entrenched in human anatomy to completely ignore them, but we will minimize their use in this book to avoid confusion. You must keep such differences in mind, however, when dissecting other animals for comparison to human anatomy.

One vestige of the term *dorsal* is ***dorsum***, used to denote the upper surface of the foot and the back of the hand. If you consider how a cat stands, the corresponding surfaces of its paws are uppermost, facing the same direction as the dorsal side of its trunk. Although these surfaces of the human hand and foot face entirely different directions in anatomical position, the term *dorsum* is still used.

## A.2 Major Body Regions

Knowledge of the external anatomy and landmarks of the body is important in performing a physical examination and many other clinical procedures. For purposes of study, the body is divided into two major regions called the *axial* and *appendicular* regions. Smaller areas within the major regions are described in the following paragraphs and illustrated in figure A.3.





(a) Anterior (ventral)

(b) Anterior (ventral)

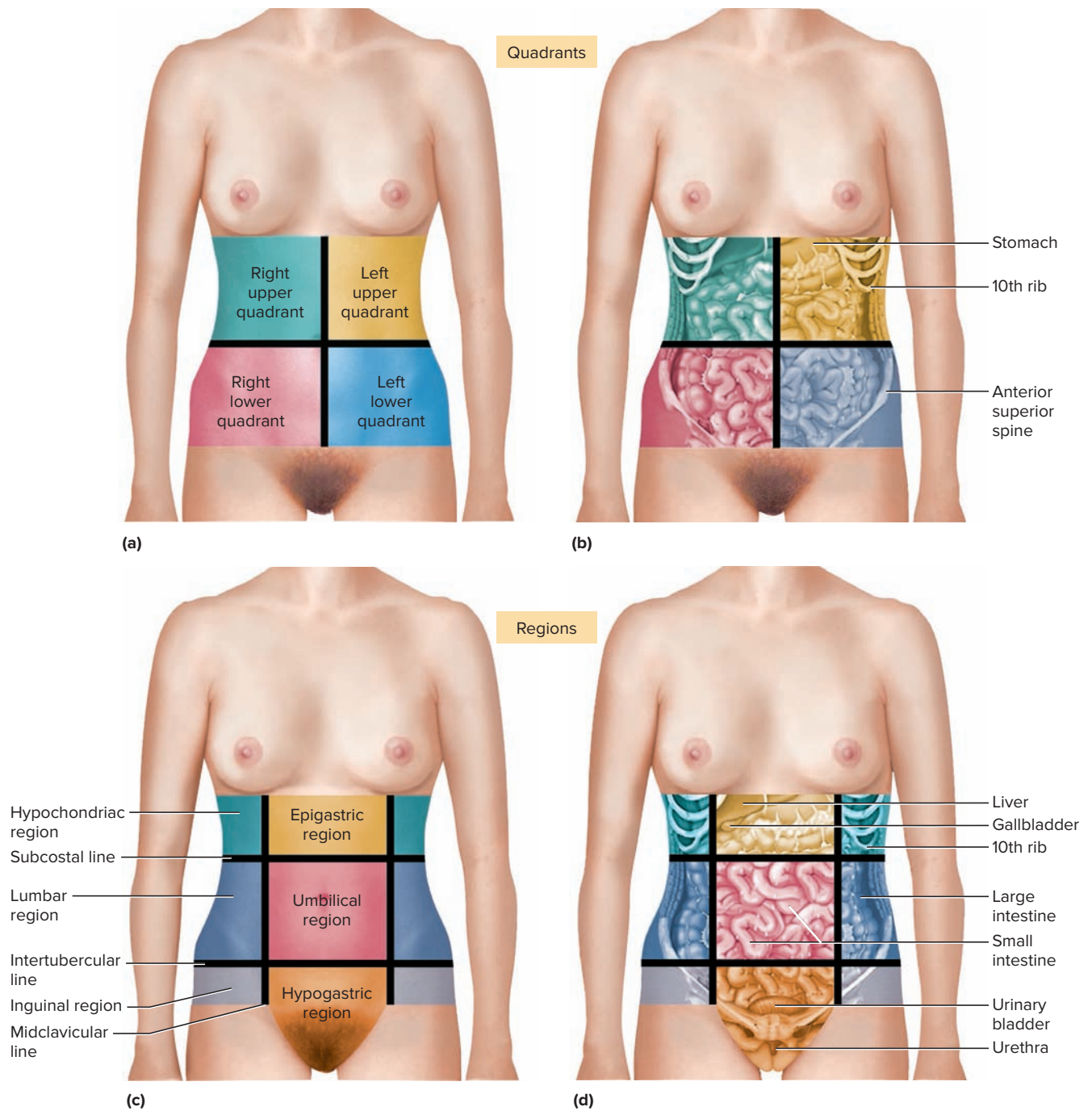
(c) Posterior (dorsal)

(d) Posterior (dorsal)

**FIGURE A.3 The Adult Female and Male Bodies (r. = region).**

a-d: © McGraw-Hill Education/Joe DeGrandis, photographer





**FIGURE A.4 The Four Quadrants and Nine Regions of the Abdomen.** (a) External division into four quadrants. (b) Internal anatomy correlated with the four quadrants. (c) External division into nine regions. (d) Internal anatomy correlated with the nine regions. **APIR**

**?** In what quadrant would the pain of appendicitis usually be felt?

## Axial Region

The **axial region** consists of the **head**, **neck** (**cervical<sup>3</sup> region**), and **trunk**. The trunk is further divided into the **thoracic region** above the diaphragm and the **abdominal region** below it.

One way of referring to the locations of abdominal structures is to divide the region into quadrants. Two perpendicular lines intersecting at the umbilicus (navel) divide the abdomen into a **right upper quadrant (RUQ)**, **right lower quadrant (RLQ)**, **left upper quadrant (LUQ)**, and **left lower quadrant (LLQ)** (fig. A.4a, b). The quadrant scheme is often used to describe the site of an abdominal pain or abnormality.

<sup>3</sup>cervic = neck

The abdomen also can be divided into nine regions defined by four lines that intersect like a tic-tac-toe grid (fig. A.4c, d). Each vertical line is called a *midclavicular line* because it passes through the midpoint of the clavicle (collarbone). The superior horizontal line is called the *subcostal*<sup>4</sup> line because it connects the inferior borders of the lowest costal cartilages (cartilage connecting the tenth rib on each side to the inferior end of the sternum). The inferior horizontal line is called the *intertubercular*<sup>5</sup> line because it passes from left to right between the tubercles (*anterior superior spines*) of the pelvis—two points of bone located about where the front pockets open on most pants. The three lateral regions of this grid, from upper to lower, are the **hypochondriac**,<sup>6</sup> **lumbar**, and **inguinal**<sup>7</sup> (**iliac**) regions. The three medial regions from upper to lower are the **epigastric**,<sup>8</sup> **umbilical**, and **hypogastric (pubic)** regions.

## Appendicular Region

The **appendicular** (AP-en-DIC-you-lur) **region** of the body consists of the **upper** and **lower limbs** (also called *appendages* or *extremities*). The upper limb includes the **arm (brachial region)** (BRAY-kee-ul), **forearm (antebrachial**<sup>9</sup> **region)** (AN-teh-BRAY-kee-ul), **wrist (carpal region)**, **hand (manual region)**, and **fingers (digits)**. The lower limb includes the **thigh (femoral region)**, **leg (crural region)** (CROO-rul), **ankle (tarsal region)**, **foot (pedal region)**, and **toes (digits)**. In strict anatomical terms, *arm* refers only to that part of the upper limb between the shoulder and elbow. *Leg* refers only to that part of the lower limb between the knee and ankle.

<sup>4</sup>*sub* = below; *cost* = rib

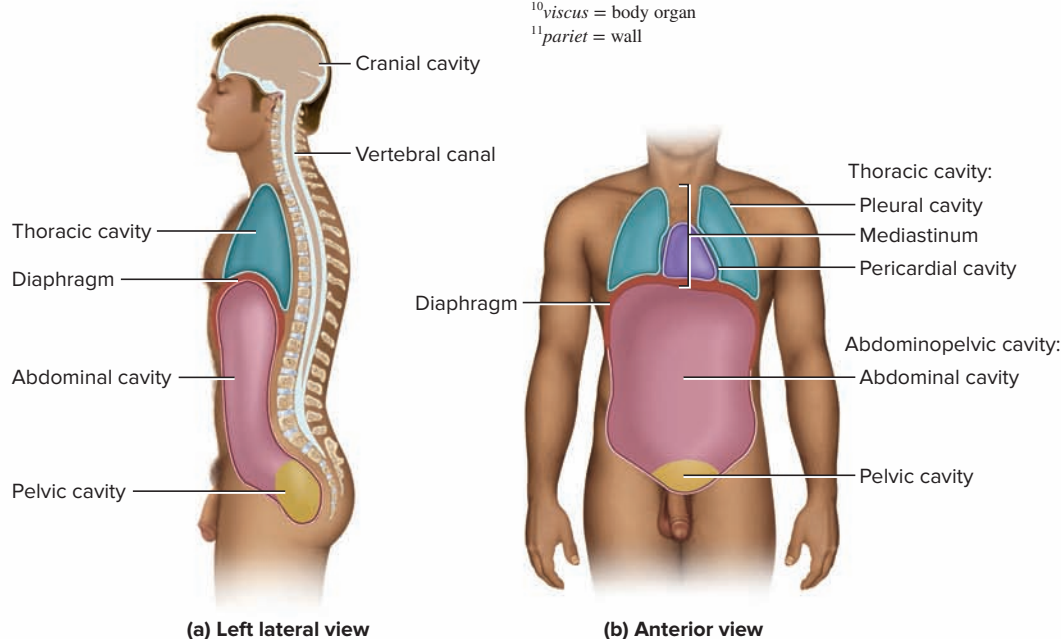
<sup>5</sup>*inter* = between; *tubercul* = little swelling

<sup>6</sup>*hypo* = below; *chondr* = cartilage

<sup>7</sup>*inguin* = groin

<sup>8</sup>*epi* = above, over; *gastr* = stomach

<sup>9</sup>*ante* = fore, before; *brachi* = arm



**FIGURE A.5** The Major Body Cavities.

A **segment** of a limb is a region between one joint and the next. The arm, for example, is the segment between the shoulder and elbow joints, and the forearm is the segment between the elbow and wrist joints. Flexing your fingers, you can easily see that your thumb has two segments (proximal and distal), whereas the other four digits have three segments (proximal, middle, and distal). The segment concept is especially useful in describing the locations of bones and muscles and the movements of the joints.

## A.3 Body Cavities and Membranes

The body wall encloses multiple **body cavities** (fig. A.5, table A.2), each lined with a membrane and containing internal organs called **viscera** (VISS-er-uh) (singular, *viscus*<sup>10</sup>). Some of these membranes are two-layered, having one layer against the organ surface (such as the heart or lung) and one layer against a surrounding structure (forming, for example, the inner lining of the rib cage); there is only a thin film of liquid between them. In such cases, the inner layer, against the organ, is called the **visceral layer** (VISS-er-ul) of the membrane, and the more superficial or outer one, the **parietal**<sup>11</sup> **layer** (pa-RY-eh-tul).

## The Cranial Cavity and Vertebral Canal

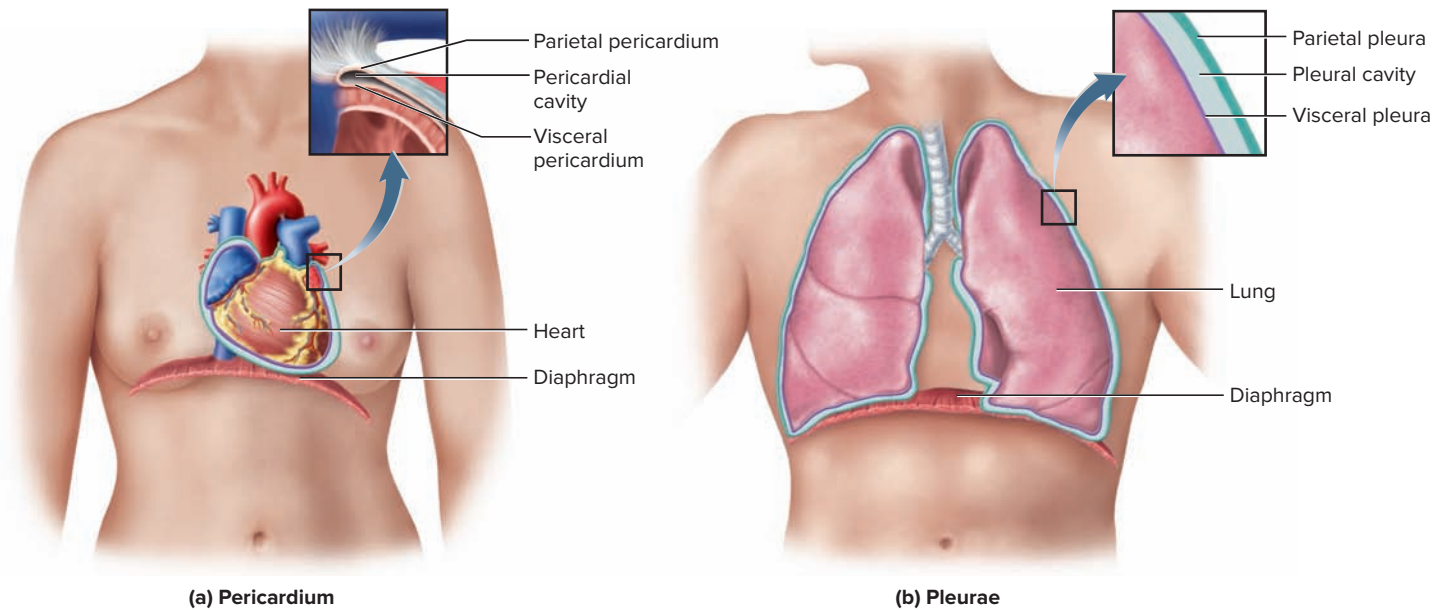
The **cranial cavity** is enclosed by the cranium (braincase) and contains the brain. The **vertebral canal** is enclosed by the vertebral column (spine) and contains the spinal cord. The two are continuous with each other and are lined by three membrane layers called the **meninges** (meh-NIN-jeez). Among other functions, the meninges protect the delicate nervous tissue from the hard protective bone that encloses it.

<sup>10</sup>*viscus* = body organ

<sup>11</sup>*pariet* = wall

**TABLE A.2** Body Cavities and Membranes **AP|R**

| Name of Cavity  | Associated Viscera  | Membranous Lining        |
|---|---|--------------------------|
| Cranial cavity  | Brain   | Meninges                 |
| Vertebral canal   | Spinal cord   | Meninges                 |
| Thoracic cavity<br>Pleural cavities (2)<br>Pericardial cavity | Lungs<br>Heart  | Pleurae<br>Pericardium   |
| Abdominopelvic cavity<br>Abdominal cavity<br>Pelvic cavity    | Digestive organs, spleen, kidneys<br>Bladder, rectum, reproductive organs | Peritoneum<br>Peritoneum |

**FIGURE A.6** Parietal and Visceral Layers of Double-Walled Membranes.

## The Thoracic Cavity

During embryonic development, a space called the **coelom** (SEE-loam) forms within the trunk. It subsequently becomes partitioned by a muscular sheet, the **diaphragm**, into a superior **thoracic cavity** and an inferior **abdominopelvic cavity**. Both cavities are lined with thin **serous membranes**, which secrete a lubricating film of moisture similar to blood serum (hence their name).

The thoracic cavity is divided by a thick wall called the **mediastinum**<sup>12</sup> (ME-dee-ah-STY-num) (fig. A.5b). This is the region between the lungs, extending from the base of the neck to the diaphragm. It is occupied by the heart, the major blood vessels connected to it, the esophagus, the trachea and bronchi, and a gland called the thymus.

The heart is enfolded in a two-layered membrane called the **pericardium**.<sup>13</sup> The inner layer of the pericardium forms the surface of the heart itself and is called the **visceral pericardium**.

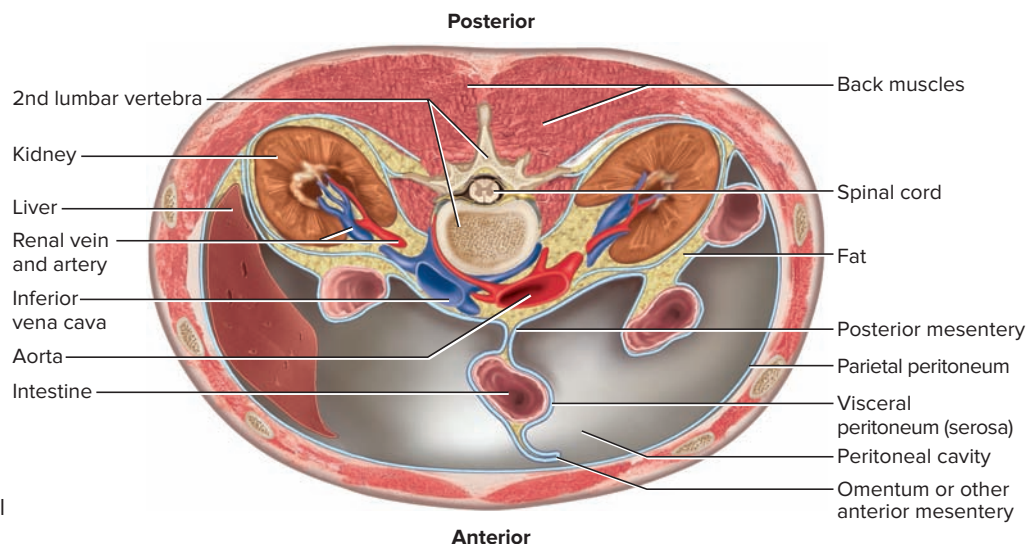
The outer layer is called the **parietal pericardium (pericardial sac)**. It is separated from the visceral pericardium by a space called the **pericardial cavity** (fig. A.6a), which is lubricated by **pericardial fluid**.

The right and left sides of the thoracic cavity contain the lungs. Each lung is enfolded by a serous membrane called the **pleura**<sup>14</sup> (PLOOR-uh) (fig. A.6b). Like the pericardium, the pleura has visceral (inner) and parietal (outer) layers. The **visceral pleura** forms the external surface of the lung, and the **parietal pleura** lines the inside of the rib cage. The narrow space between them is called the **pleural cavity** (see fig. B.11 in atlas B, following chapter 10). It is lubricated by slippery **pleural fluid**.

Note that in both the pericardium and the pleura, the visceral layer of the membrane *covers* an organ surface and the parietal layer *lines* the inside of a body cavity. We will see this pattern elsewhere, including the abdominopelvic cavity.

<sup>12</sup>mediastinum = in the middle<sup>13</sup>peri = around; cardi = heart<sup>14</sup>pleur = rib, side





**FIGURE A.7 Transverse Section**

**Through the Abdomen.** Shows the peritoneum, peritoneal cavity (with most viscera omitted), and some retroperitoneal organs.

## The Abdominopelvic Cavity

The abdominopelvic cavity consists of the **abdominal cavity** superiorly and the **pelvic cavity** inferiorly. The abdominal cavity contains most of the digestive organs as well as the spleen, kidneys, and ureters. It extends inferiorly to the level of a bony landmark called the *brim* of the pelvis (see figs. B.7 and 8.35). The pelvic cavity, below the brim, is continuous with the abdominal cavity (no wall separates them), but it is markedly narrower and tilts posteriorly (see fig. A.5a). It contains the rectum, urinary bladder, urethra, and reproductive organs.

The abdominopelvic cavity contains a two-layered serous membrane called the **peritoneum**<sup>15</sup> (PERR-ih-toe-NEE-um). Its outer layer, the **parietal peritoneum**, lines the cavity wall. Along the posterior midline, it turns inward and becomes another layer, the **visceral peritoneum**, suspending certain abdominal viscera from the body wall, covering their outer surfaces, and holding them in place. The **peritoneal cavity** is the space between the parietal and visceral layers. It is lubricated by **peritoneal fluid**.

Some organs of the abdominal cavity lie against the posterior body wall and are covered by peritoneum only on the side facing the peritoneal cavity. They are said to have a **retroperitoneal**<sup>16</sup> position (fig. A.7). These include the kidneys, ureters, adrenal glands, most of the pancreas, and abdominal portions of two major blood vessels—the aorta and inferior vena cava (see fig. B.6). Organs that are encircled by peritoneum and connected to the posterior body wall by peritoneal sheets are described as **intrapertitoneal**.<sup>17</sup>

The visceral peritoneum is also called a **mesentery**<sup>18</sup> (MESS-en-tare-ee) at points where it forms a translucent, membranous curtain suspending and anchoring the viscera (fig. A.8), and a **serosa** (seer-OH-sa) at points where it enfolds and covers the outer surfaces of organs such as the stomach and small intestine. The intestines are suspended from the posterior (dorsal) abdominal wall



## DEEPER INSIGHT A.1

### CLINICAL APPLICATION

#### Peritonitis

Peritonitis is inflammation of the peritoneum. It is a critical, life-threatening condition necessitating prompt treatment. The most serious cause of peritonitis is a perforation in the digestive tract, such as a ruptured appendix or a gunshot wound. Digestive juices cause immediate chemical inflammation of the peritoneum, followed by microbial inflammation as intestinal bacteria invade the body cavity. Anything that perforates the abdominal wall can also lead to peritonitis, such as abdominal trauma or surgery. So, too, can free blood in the abdominal cavity, as from a ruptured aneurysm (a weak point in a blood vessel) or ectopic pregnancy (implantation of an embryo anywhere other than the uterus); blood itself is a chemical irritant to the peritoneum. Peritonitis tends to shift fluid from the circulation into the abdominal cavity. Death can follow within a few days from severe electrolyte imbalance, respiratory distress, kidney failure, and widespread blood clotting called *disseminated intravascular coagulation*.

by the **posterior mesentery**. The posterior mesentery of the large intestine is called the **mesocolon**. In some places, after wrapping around the intestines or other viscera, the mesentery continues toward the anterior body wall as the **anterior mesentery**. The most significant example of this is a fatty membrane called the **greater omentum**,<sup>19</sup> which hangs like an apron from the inferolateral margin of the stomach and overlies the intestines (figs. A.8a and B.4). The greater omentum is unattached at its inferior border and can be lifted to reveal the intestines. A smaller **lesser omentum** extends from the superomedial margin of the stomach to the liver.

#### Potential Spaces

Some of the spaces between body membranes are considered to be **potential spaces**, so named because under normal conditions, the membranes are pressed firmly together and there is no actual space

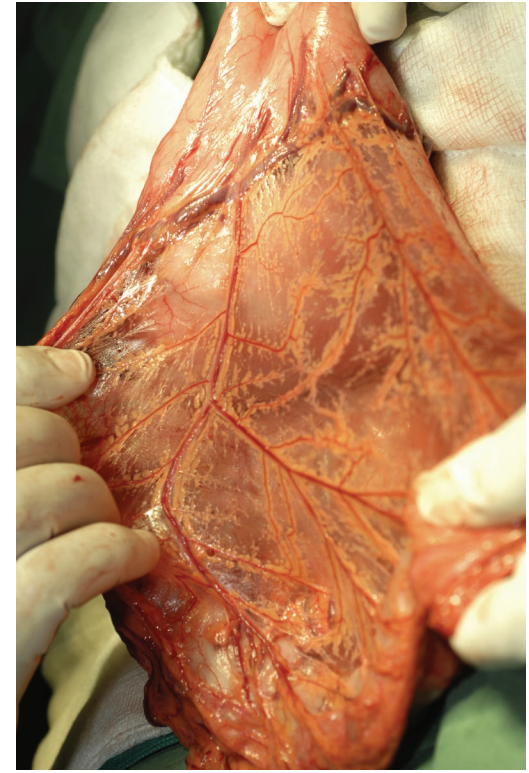
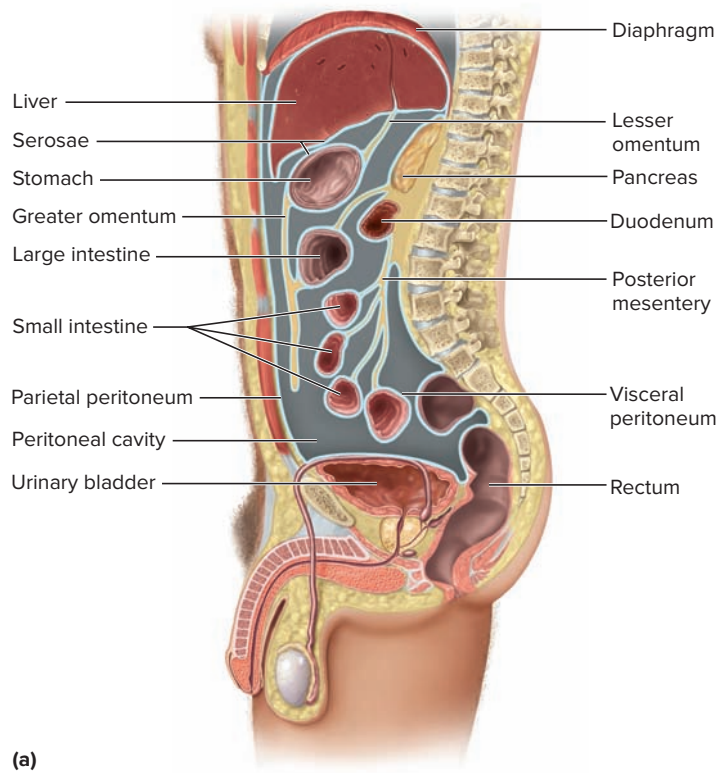
<sup>15</sup>*peri* = around; *tone* = stretched

<sup>16</sup>*retro* = behind

<sup>17</sup>*intra* = within

<sup>18</sup>*mes* = in the middle; *enter* = intestine

<sup>19</sup>*omentum* = covering



**FIGURE A.8 Serous Membranes of the Abdominal Cavity.** (a) Sagittal section, left lateral view. (b) Photo of the mesentery of the small intestine. Mesenteries contain blood vessels, lymphatic vessels, and nerves supplying the viscera. **AP|R**

**?** Is the urinary bladder in the peritoneal cavity?

b: © Medicimage/Getty Images

between them. The membranes are not physically attached, however, and under unusual conditions, they may separate and create a space filled with fluid or other matter. Thus there is normally no actual space, but only a potential for membranes to separate and create one.

The pleural cavity is one example. Normally the parietal and visceral pleurae are pressed together without a gap between them, but under pathological conditions, air or serous fluid can accumulate between the membranes and open up a space. The internal cavity (**lumen**) of the uterus is another. In a nonpregnant uterus, the mucous membranes of opposite walls are pressed together so that there is no open space in the organ. In pregnancy, of course, a growing fetus occupies this space and pushes the mucous membranes apart.

## A.4 Organ Systems

The human body has 11 **organ systems** (fig. A.9) and an immune system, which is better described as a population of cells that inhabit multiple organs rather than as an organ system. The organ systems are classified in the following list by their principal functions, but this is an unavoidably flawed classification. Some organs belong to two or more systems—for example, the male urethra is part of both the urinary and reproductive systems; the pharynx is part of the respiratory and digestive systems; and the mammary glands can be considered part of the integumentary and female reproductive systems. The organ systems are as follows:

### Systems of protection, support, and movement

- Integumentary system
- Skeletal system
- Muscular system

### Systems of internal communication and control

- Nervous system
- Endocrine system

### Systems of fluid transport

- Circulatory system
- Lymphatic system

### Systems of intake and output

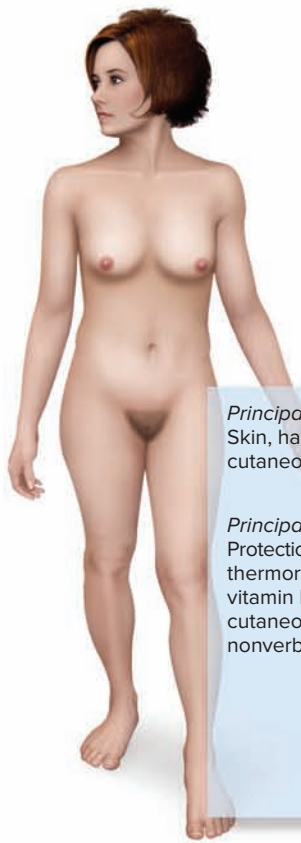- Respiratory system
- Urinary system
- Digestive system

### Systems of reproduction

- Male reproductive system
- Female reproductive system

Some medical terms combine the names of two systems—for example, the *musculoskeletal system*, *cardiopulmonary system*, and *urogenital (genitourinary) system*. These terms serve to call attention to the close anatomical or physiological relationships between two systems, but these are not literally individual organ systems.

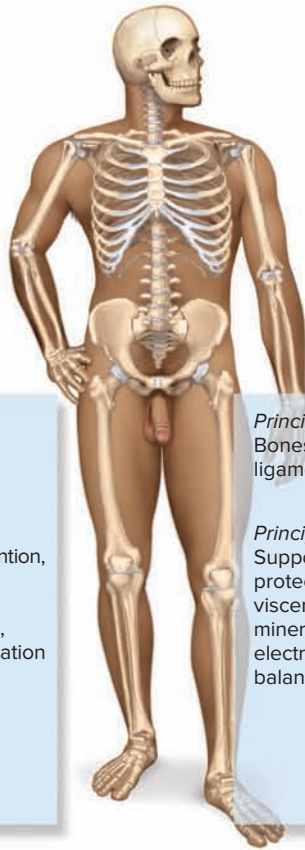




*Principal organs:*  
Skin, hair, nails,  
cutaneous glands

*Principal functions:*  
Protection, water retention,  
thermoregulation,  
vitamin D synthesis,  
cutaneous sensation,  
nonverbal communication

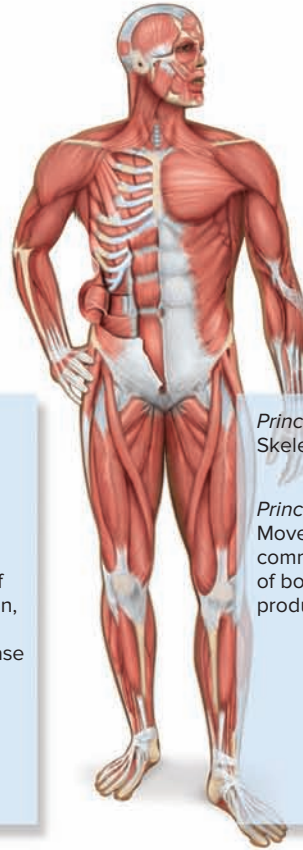
**Integumentary system**



*Principal organs:*  
Bones, cartilages,  
ligaments

*Principal functions:*  
Support, movement,  
protective enclosure of  
viscera, blood formation,  
mineral storage,  
electrolyte and acid–base  
balance

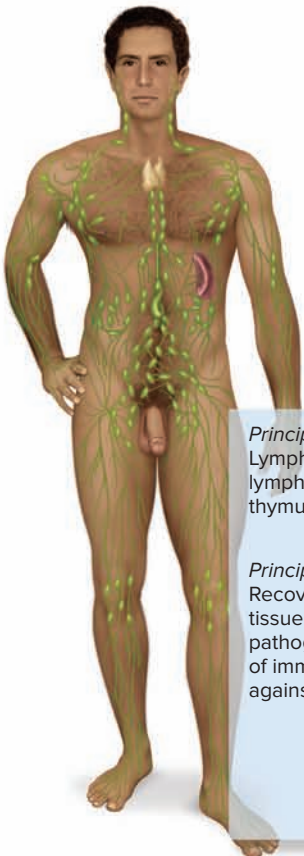
**Skeletal system**



*Principal organs:*  
Skeletal muscles

*Principal functions:*  
Movement, stability,  
communication, control  
of body openings, heat  
production

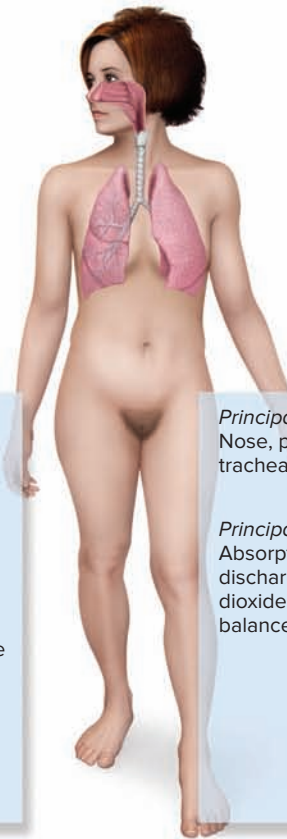**Muscular system**



*Principal organs:*  
Lymph nodes,  
lymphatic vessels,  
thymus, spleen, tonsils

*Principal functions:*  
Recovery of excess  
tissue fluid, detection of  
pathogens, production  
of immune cells, defense  
against disease

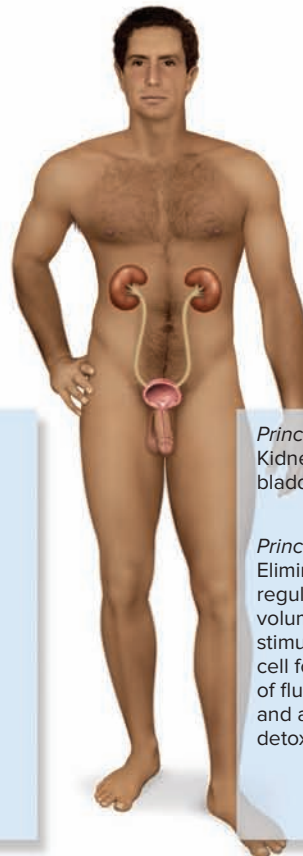
**Lymphatic system**



*Principal organs:*  
Nose, pharynx, larynx,  
trachea, bronchi, lungs

*Principal functions:*  
Absorption of oxygen,  
discharge of carbon  
dioxide, acid–base  
balance, speech

**Respiratory system**

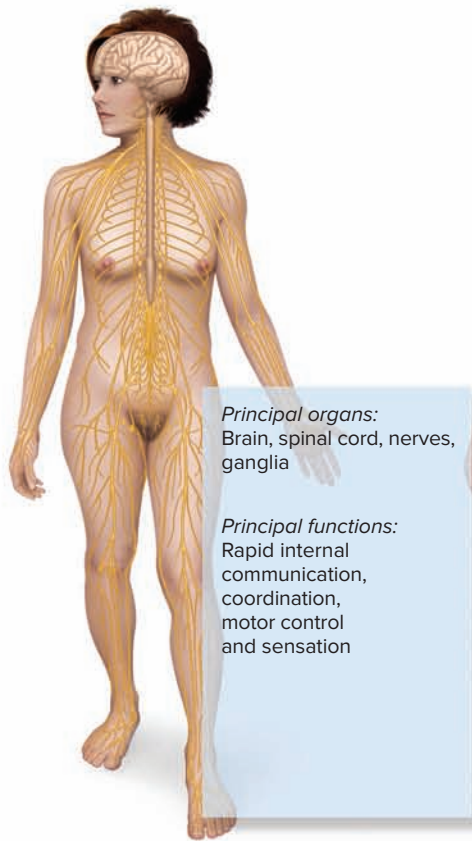


*Principal organs:*  
Kidneys, ureters, urinary  
bladder, urethra

*Principal functions:*  
Elimination of wastes;  
regulation of blood  
volume and pressure;  
stimulation of red blood  
cell formation; control  
of fluid, electrolyte,  
and acid–base balance;  
detoxification

**Urinary system**

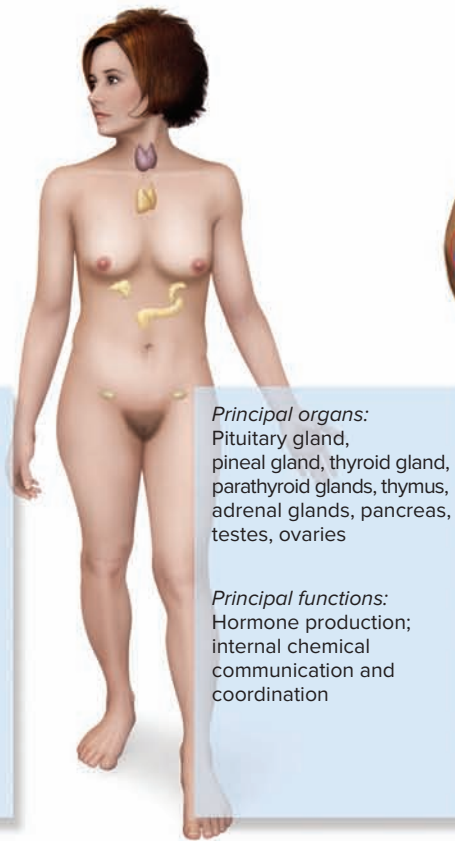
**FIGURE A.9** The Human Organ Systems.



*Principal organs:*  
Brain, spinal cord, nerves,  
ganglia

*Principal functions:*  
Rapid internal  
communication,  
coordination,  
motor control  
and sensation

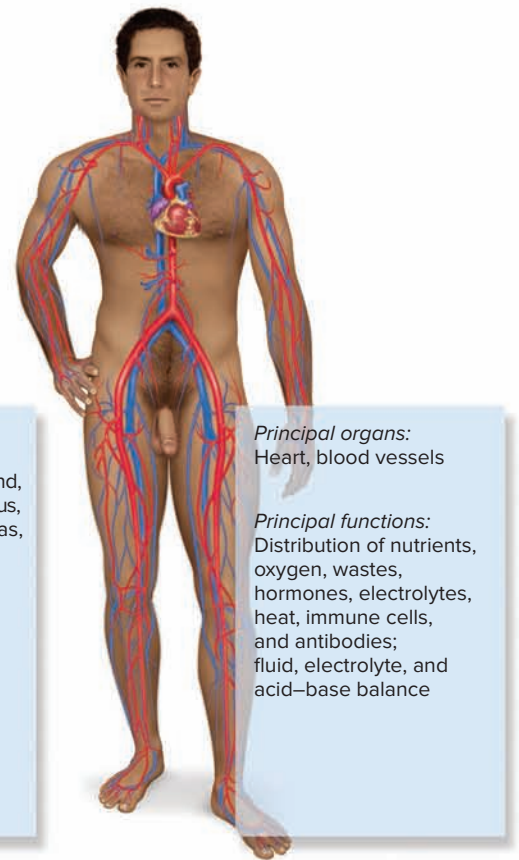
**Nervous system**



*Principal organs:*  
Pituitary gland,  
pineal gland, thyroid gland,  
parathyroid glands, thymus,  
adrenal glands, pancreas,  
testes, ovaries

*Principal functions:*  
Hormone production;  
internal chemical  
communication and  
coordination

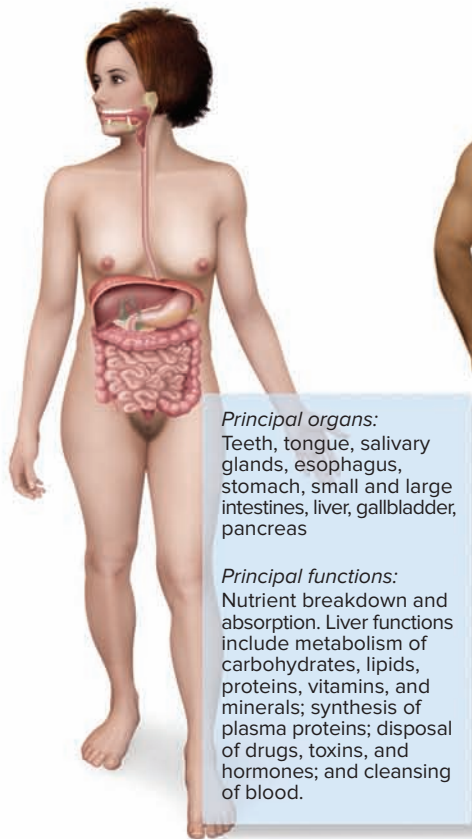
**Endocrine system**



*Principal organs:*  
Heart, blood vessels

*Principal functions:*  
Distribution of nutrients,  
oxygen, wastes,  
hormones, electrolytes,  
heat, immune cells,  
and antibodies;  
fluid, electrolyte, and  
acid–base balance

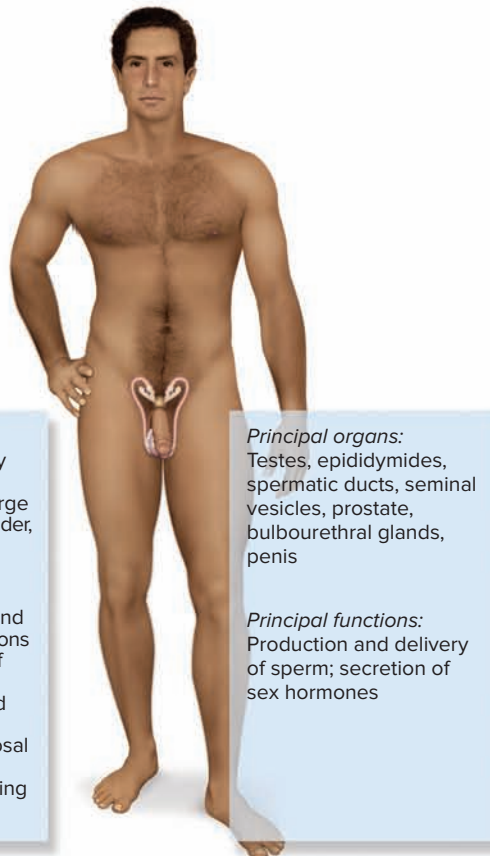
**Circulatory system**



*Principal organs:*  
Teeth, tongue, salivary  
glands, esophagus,  
stomach, small and large  
intestines, liver, gallbladder,  
pancreas

*Principal functions:*  
Nutrient breakdown and  
absorption. Liver functions  
include metabolism of  
carbohydrates, lipids,  
proteins, vitamins, and  
minerals; synthesis of  
plasma proteins; disposal  
of drugs, toxins, and  
hormones; and cleansing  
of blood.

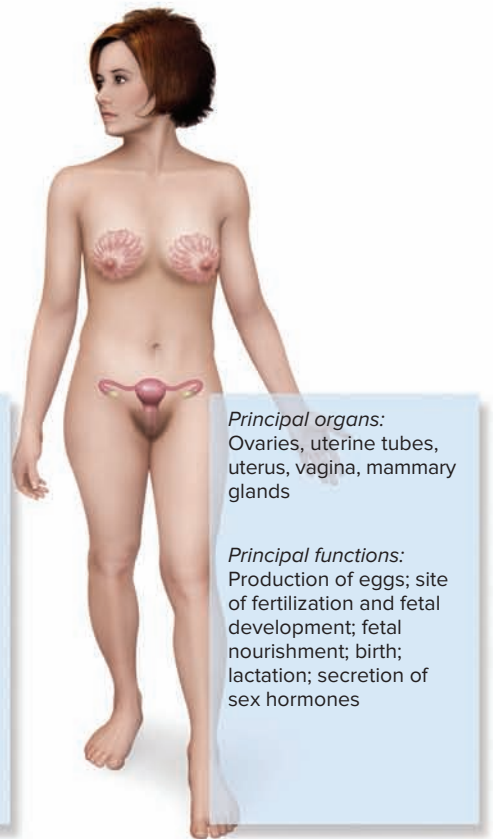
**Digestive system**



*Principal organs:*  
Testes, epididymides,  
spermatic ducts, seminal  
vesicles, prostate,  
bulbourethral glands,  
penis

*Principal functions:*  
Production and delivery  
of sperm; secretion of  
sex hormones

**Male reproductive system**



*Principal organs:*  
Ovaries, uterine tubes,  
uterus, vagina, mammary  
glands

*Principal functions:*  
Production of eggs; site  
of fertilization and fetal  
development; fetal  
nourishment; birth;  
lactation; secretion of  
sex hormones

**Female reproductive system**

**FIGURE A.9 The Human Organ Systems (continued).**



# STUDY GUIDE

## ► Assess Your Learning Outcomes

To test your knowledge, discuss the following topics with a study partner or in writing, ideally from memory.

### A.1 General Anatomical Terminology

- Anatomical position and why it is important for anatomical description
- Directions along which the body or an organ is divided by the sagittal, frontal, and transverse planes; how the median plane differs from other sagittal planes
- Meanings of each of the following pairs or groups of terms, and the ability to describe the relative locations of two body parts using these terms: *ventral* and *dorsal*; *anterior* and *posterior*; *cephalic*, *rostral*, and *caudal*; *superior* and *inferior*; *medial* and *lateral*; *proximal* and *distal*; *superficial* and *deep*
- Why the terms *ventral* and *dorsal* are ambiguous in human anatomy but less so in most other animals; what terms are used in their place in human anatomy; and reasons why they are occasionally appropriate or unavoidable in human anatomy

### A.2 Major Body Regions

- Distinctions between the axial and appendicular regions of the body
- Subdivisions of the axial region and landmarks that divide and define them
- The abdomen's four quadrants and nine regions; their defining landmarks; and why this scheme is clinically useful
- The segments of the upper and lower limbs; how the anatomical meanings of *arm* and *leg* differ from the colloquial meanings

### A.3 Body Cavities and Membranes

- Locations and contents of the cranial cavity, vertebral canal, thoracic cavity, and abdominopelvic cavity; the membranes that line them; and the main viscera contained in each
- Contents of the mediastinum and its relationship to the thoracic cavity as a whole
- The pericardium, its two layers, the space and fluid between the layers, and its function
- The pleurae, their two layers, the space and fluid between the layers, and their function

- The two subdivisions of the abdominopelvic cavity and the skeletal landmark that divides them
- The peritoneum; its functions; its two layers and their relationship to the abdominal viscera; and the peritoneal fluid
- Mesenteries and serosae
- Intraperitoneal versus retroperitoneal organs, examples of both, and how one would identify an organ as being intra- or retroperitoneal
- Names and locations of the posterior and anterior mesenteries
- The serosa of an abdominopelvic organ and how it relates to the peritoneum
- Examples of potential spaces and why they are so named

### A.4 Organ Systems

- The 11 organ systems, the functions of each, and the principal organs of each system

## ► Testing Your Recall

Answers in Appendix B

- Which of the following is *not* an essential part of anatomical position?
  - feet together
  - feet flat on the floor
  - palms forward
  - mouth closed
  - arms down to the sides
- A ring-shaped section of the small intestine would be a \_\_\_\_\_ section.
  - sagittal
  - coronal
  - transverse
  - frontal
  - median
- The tarsal region is \_\_\_\_\_ to the popliteal region.
  - medial
  - superficial
  - superior
  - dorsal
  - distal
- The greater omentum is \_\_\_\_\_ to the small intestine.
  - posterior
  - parietal
  - deep
  - superficial
  - proximal
- A \_\_\_\_\_ plane passes through the sternum, umbilicus, and mons pubis.
  - central
  - proximal
  - midclavicular
  - midsagittal
  - intertubercular
- The \_\_\_\_\_ region is immediately medial to the coxal region.
  - inguinal
  - hypochondriac
  - umbilical
  - popliteal
  - cubital
- Which of the following regions is not part of the upper limb?
  - plantar
  - carpal
  - cubital
  - brachial
  - palmar
- Which of these organs is within the peritoneal cavity?
  - urinary bladder
  - kidneys
  - heart
  - liver
  - brain
- In which area do you think pain from the gallbladder would be felt?
  - umbilical region
  - right upper quadrant
  - hypogastric region
  - left hypochondriac region
  - left lower quadrant

## STUDY GUIDE

10. Which organ system regulates blood volume, controls acid–base balance, and stimulates red blood cell production?
  - a. digestive system
  - b. lymphatic system
  - c. nervous system
  - d. urinary system
  - e. circulatory system
11. The translucent membranes that suspend the intestines and hold them in place are called \_\_\_\_\_.
12. The superficial layer of the pleura is called the \_\_\_\_\_ pleura.
13. The right and left pleural cavities are separated by a thick wall called the \_\_\_\_\_.
14. The back of the neck is the \_\_\_\_\_ region.
15. The manual region is more commonly known as the \_\_\_\_\_ and the pedal region is more commonly known as the \_\_\_\_\_.
16. The cranial cavity is lined by membranes called the \_\_\_\_\_.
17. Organs that lie within the abdominal cavity but not within the peritoneal cavity are said to have a \_\_\_\_\_ position.
18. The sternal region is \_\_\_\_\_ to the pectoral region.
19. The pelvic cavity can be described as \_\_\_\_\_ to the abdominal cavity in position.
20. The anterior pit of the elbow is the \_\_\_\_\_ region, and the corresponding (but posterior) pit of the knee is the \_\_\_\_\_ region.

### ► Building Your Medical Vocabulary

Answers in Appendix B

State a meaning of each word element, and give a medical term that uses it or a slight variation of it.

- |             |             |              |
|-------------|-------------|--------------|
| 1. ante-    | 3. epi-     | 7. parieto-  |
| 2. cervico- | 4. hypo-    | 8. peri-     |
|             | 5. inguino- | 9. retro-    |
|             | 6. intra-   | 10. sagitto- |

### ► What's Wrong with These Statements?

Answers in Appendix B

Briefly explain why each of the following statements is false, or reword it to make it true.

1. Both lungs could be shown in one sagittal section of the body.
2. A single frontal section of the head cannot include both eyes.
3. The knee is distal to the tarsal region.
4. The diaphragm is posterior to the lungs.
5. The esophagus is inferior to the stomach.
6. The liver is in the lumbar region.
7. The heart is in the space between the parietal and visceral pericardium, called the pericardial cavity.
8. The kidneys are in the peritoneal cavity of the abdomen.
9. The peritoneum lines the inside of the stomach and intestines.
10. The sigmoid colon is in the lower right quadrant of the abdomen.

### ► Testing Your Comprehension

1. Identify which anatomical plane—sagittal, frontal, or transverse—is the only one that could *not* show (a) both the brain and tongue, (b) both eyes, (c) both the hypogastric and gluteal regions, (d) both kidneys, (e) both the sternum and vertebral column, and (f) both the heart and uterus.
2. Laypeople often misunderstand anatomical terminology. What do you think people really mean when they say they have “planter’s warts”?
3. Name one structure or anatomical feature that could be found in each of the following locations relative to the ribs: medial, lateral, superior, inferior, deep, superficial, posterior, and anterior. Try not to use the same example twice.
4. Based on the illustrations in this atlas, identify an internal organ that is (a) in the upper left quadrant and retroperitoneal, (b) in the lower right quadrant of the peritoneal cavity, (c) in the hypogastric region, (d) in the right hypochondriac region, and (e) in the pectoral region.
5. Why do you think people with imaginary illnesses came to be called hypochondriacs?