

The cover features three 3D anatomical models of the testis and epididymis. The top-left model shows a cross-section of the testis with internal structures in green, blue, and purple. The top-right model shows a longitudinal section of the epididymis with internal structures in yellow, green, and blue. The bottom model shows a longitudinal section of the testis with internal structures in purple, green, and red. The title is overlaid on these models.

# The Leydig Cell in Health and Disease

Edited by

**Anita H. Payne, PhD**

**Matthew P. Hardy, PhD**

 HUMANAPRESS

## THE LEYDIG CELL IN HEALTH AND DISEASE

# CONTEMPORARY ENDOCRINOLOGY

---

**P. Michael Conn, SERIES EDITOR**

- Genomics in Endocrinology: DNA Microarray Analysis in Endocrine Health and Disease**, edited by STUART HANDWERGER AND BRUCE ARONOW, 2007
- Controversies in Treating Diabetes: Clinical and Research Aspects**, edited by DEREK LEROITH AND AARON I. VINIK, 2007
- Autoimmune Diseases in Endocrinology**, edited by ANTHONY P. WEETMAN, 2007
- When Puberty is Precocious: Scientific and Clinical Aspects**, edited by ORA H. PESCOVITZ AND EMILY C. WALVOORD, 2007
- Insulin Resistance and Polycystic Ovarian Syndrome: Pathogenesis, Evaluation and Treatment**, edited by JOHN E. NESTLER, EVANTHIA DIAMANTI-KANDARAKIS, RENATO PASQUALI, AND D. PANDIS, 2007
- Hypertension and Hormone Mechanisms**, edited by ROBERT M. CAREY, 2007
- The Leydig Cell in Health and Disease**, edited by ANITA H. PAYNE AND MATTHEW P. HARDY, 2007
- Treatment of the Obese Patient**, edited by ROBERT F. KUSHNER AND DANIEL H. BESSESEN, 2007
- Androgen Excess Disorders in Women: Polycystic Ovary Syndrome and Other Disorders, Second Edition**, edited by RICARDO AZZIS, JOHN E. NESTLER, AND DIDIER DEWAILLY, 2006
- Evidence-Based Endocrinology**, edited by VICTOR M. MONTORI, 2006
- Stem Cells in Endocrinology**, edited by LINDA B. LESTER, 2005
- Office Andrology**, edited by PHILLIP E. PATTON AND DAVID E. BATTAGLIA, 2005
- Male Hypogonadism: Basic, Clinical, and Therapeutic Principles**, edited by STEPHEN J. WINTERS, 2004
- Androgens in Health and Disease**, edited by CARRIE J. BAGATELL AND WILLIAM J. BREMNER, 2003
- Endocrine Replacement Therapy in Clinical Practice**, edited by A. WAYNE MEIKLE, 2003
- Early Diagnosis of Endocrine Diseases**, edited by ROBERT S. BAR, 2003
- Type I Diabetes: Etiology and Treatment**, edited by MARK A. SPERLING, 2003
- Handbook of Diagnostic Endocrinology**, edited by JANET E. HALL AND LYNNETTE K. NIEMAN, 2003
- Pediatric Endocrinology: A Practical Clinical Guide**, edited by SALLY RADOVICK AND MARGARET H. MACGILLIVRAY, 2003
- Diseases of the Thyroid, 2nd ed.**, edited by LEWIS E. BRAVERMAN, 2003
- Developmental Endocrinology: From Research to Clinical Practice**, edited by ERICA A. EUGSTER AND ORA HIRSCH PESCOVITZ, 2002
- Osteoporosis: Pathophysiology and Clinical Management**, edited by ERIC S. ORWOLL AND MICHAEL BLIZIOTES, 2002
- Challenging Cases in Endocrinology**, edited by MARK E. MOLITCH, 2002
- Selective Estrogen Receptor Modulators: Research and Clinical Applications**, edited by ANDREA MANNI AND MICHAEL F. VERDERAME, 2002
- Transgenics in Endocrinology**, edited by MARTIN MATZUK, CHESTER W. BROWN, AND T. RAJENDRA KUMAR, 2001
- Assisted Fertilization and Nuclear Transfer in Mammals**, edited by DON P. WOLF AND MARY ZELINSKI-WOOTEN, 2001
- Adrenal Disorders**, edited by ANDREW N. MARGIORIS AND GEORGE P. CHROUSOS, 2001
- Endocrine Oncology**, edited by STEPHEN P. ETHIER, 2000
- Endocrinology of the Lung: Development and Surfactant Synthesis**, edited by CAROLE R. MENDELSON, 2000
- Sports Endocrinology**, edited by MICHELLE P. WARREN AND NAAMA W. CONSTANTINI, 2000
- Gene Engineering in Endocrinology**, edited by MARGARET A. SHUPNIK, 2000
- Endocrinology of Aging**, edited by JOHN E. MORLEY AND LUCRETIA VAN DEN BERG, 2000
- Human Growth Hormone: Research and Clinical Practice**, edited by ROY G. SMITH AND MICHAEL O. THORNER, 2000
- Hormones and the Heart in Health and Disease**, edited by LEONARD SHARE, 1999
- Menopause: Endocrinology and Management**, edited by DAVID B. SEIFER AND ELIZABETH A. KENNARD, 1999
- The IGF System: Molecular Biology, Physiology, and Clinical Applications**, edited by RON G. ROSENFELD AND CHARLES T. ROBERTS, JR., 1999
- Neurosteroids: A New Regulatory Function in the Nervous System**, edited by ETIENNE-EMILE BAULIEU, MICHAEL SCHUMACHER, AND PAUL ROBEL, 1999

# THE LEYDIG CELL IN HEALTH AND DISEASE

---

*Edited by*

**ANITA H. PAYNE, PhD**

*Department of Obstetrics and Gynecology  
Stanford University School of Medicine  
Stanford, CA*

**MATTHEW P. HARDY, PhD**

*Population Council  
Center for Biomedical Research  
New York, NY*

 **HUMANA PRESS**  
TOTOWA, NEW JERSEY

© 2007 Humana Press Inc.  
999 Riverview Drive, Suite 208  
Totowa, New Jersey 07512  
www.humanapress.com

All rights reserved. No part of this book may be reproduced, stored in a retrieval system, or transmitted in any form or by any means, electronic, mechanical, photocopying, microfilming, recording, or otherwise without written permission from the Publisher.

The content and opinions expressed in this book are the sole work of the authors and editors, who have warranted due diligence in the creation and issuance of their work. The publisher, editors, and authors are not responsible for errors or omissions or for any consequences arising from the information or opinions presented in this book and make no warranty, express or implied, with respect to its contents.

Due diligence has been taken by the publishers, editors, and authors of this book to assure the accuracy of the information published and to describe generally accepted practices. The contributors herein have carefully checked to ensure that the drug selections and dosages set forth in this text are accurate and in accord with the standards accepted at the time of publication. Notwithstanding, since new research, changes in government regulations, and knowledge from clinical experience relating to drug therapy and drug reactions constantly occur, the reader is advised to check the product information provided by the manufacturer of each drug for any change in dosages or for additional warnings and contraindications. This is of utmost importance when the recommended drug herein is a new or infrequently used drug. It is the responsibility of the treating physician to determine dosages and treatment strategies for individual patients. Further, it is the responsibility of the health care provider to ascertain the Food and Drug Administration status of each drug or device used in their clinical practice. The publishers, editors, and authors are not responsible for errors or omissions or for any consequences from the application of the information presented in this book and make no warranty, express or implied, with respect to the contents in this publication.

This publication is printed on acid-free paper. (∞)

ANSI Z39.48-1984 (American National Standards Institute) Permanence of Paper for Printed Library Materials.

Production Editor: Amy Thau

Cover design by Karen Schulz

Cover Illustration: Color Plate, Chapter 5, "The Human Leydig Cell: *Functional Morphology and Developmental History*," by Frederick P. Prince.

For additional copies, pricing for bulk purchases, and/or information about other Humana titles, contact Humana at the above address or at any of the following numbers: Tel: 973-256-1699; Fax: 973-256-8341; E-mail: orders@humanapr.com or visit our website at <http://humanapress.com>

**Photocopy Authorization Policy:**

Authorization to photocopy items for internal or personal use, or the internal or personal use of specific clients, is granted by Humana Press Inc., provided that the base fee of US \$30.00 per copy is paid directly to the Copyright Clearance Center at 222 Rosewood Drive, Danvers, MA 01923. For those organizations that have been granted a photocopy license from the CCC, a separate system of payment has been arranged and is acceptable to Humana Press Inc. The fee code for users of the Transactional Reporting Service is: [978-1-58829-754-9/07 \$30.00].

Printed in the United States of America. 10 9 8 7 6 5 4 3 2 1

eISBN: 978-1-59745-453-7

Library of Congress Cataloging-in-Publication Data

The Leydig cell in health and disease / edited by Anita H. Payne, Matthew P. Hardy.

p. : cm. — (Contemporary endocrinology)

Includes bibliographical references and index.

ISBN: 978-1-58829-754-9 (alk. paper)

1. Leydig cells. I. Payne, Anita H. (Anita Hart) II. Hardy, Matthew Phillip. III. Series: Contemporary endocrinology (Totowa, N.J. : Unnumbered)

[DNLM: 1. Leydig Cells—physiology. 2. Testis—physiology. WJ 830 L681 2007]

QP255.L49 2007

612.6'1—dc22

2006026866

# PREFACE

---

Ten years ago, in association with Lonnie Russell, we published *The Leydig Cell* (Cache River Press, Vienna IL). It was the first volume of its kind, devoted entirely to review chapters covering basic and clinical aspects of Leydig cell structure and function. As editors, it became clear to us that such a book filled a gap in the literature on male reproduction. The testis produces both sperm and testosterone, and the two are linked because spermatogenesis is critically dependent on androgen action. However, the role of the Leydig cell in synthesizing the male hormone can be lost in the beautiful and complex series of cellular events leading to the formation of sperm. In addition, Leydig cells, which are far outnumbered by the germ cell population, constitute only 5 to 15% of the testicular volume (depending on the species). Despite their minority status in the testis, knowledge of the biology of Leydig cells is an essential prerequisite to understanding male fertility, sexual function, and reproductive health. And yet, there was no centralized repository for that knowledge. The first book, then, was an attempt to fill this unmet need.

Ten years have passed and science has advanced, but the question arises as to why it would be appropriate and advisable to publish a second volume, again focusing on this one cell type. We would argue that successes in the field have created a new gap. In each of the 30 chapters of *The Leydig Cell in Health and Disease*, we aim to provide closure while simultaneously pointing to new possibilities. We hope to make the case that the Leydig cell merits the reader's time and attention as much as it did in 1996. It would be difficult to highlight some of the developments that made the new book worthwhile without going beyond the scope of a preface and writing a 31st chapter. In more recent years the crystal structures of a gonadotropin receptor and several of the steroid synthesizing and metabolizing enzymes have been solved. In some cases, research groups working at biopharmaceutical companies achieved the structure solutions. Obviously, the potential for applying results related to androgen synthesis to drug development and therapy has not gone unnoticed in the private sector.

We know more about the process of cholesterol transport to the inner mitochondrial membrane and site of side-chain cleavage, the rate-limiting step in testosterone biosynthesis. It appears in 2006 to be like a Virginia reel dance in which the precursor, cholesterol, may arrive with one binding partner, the steroid acute regulatory protein, but finish with another, the peripheral benzodiazepine receptor, which has been clearly shown to form a pore in the mitochondrial membrane. How the cytosol to mitochondrial membrane transfer occurs remains an actively debated research topic.

We are also on the verge of a new male contraceptive after more than 30 years of studying the hormonal approach. Essentially, this method will involve using androgen in combination with another sex steroid to impose negative feedback on the hypothalamus and pituitary Leydig cell function will then be suppressed, lowering testicular testosterone levels below the threshold needed to sustain spermatogenesis. It will soon be known whether this is an effective product and one that will find a niche in the marketplace. Meanwhile, use and abuse of androgen for its effects as an anabolic steroid to increase muscle mass is a phenomenon among professional athletes and teenage boys. The fertility-suppressing effects of exogenous androgen are a potential, if unrecognized, concern within this group.

Whereas boys and younger men seek to boost androgen levels above normal, a potentially more legitimate trend exists for men that are aging. With aging, androgen levels decrease as a result of atrophic changes in Leydig cells. Administering testosterone can counteract the decline. Longitudinal studies, currently in progress, involving testosterone replacement in the aging male will become more acceptable if proven beneficial and safe.

It is now more apparent than it was in 1996 that exposure to environmental toxicants interferes with Leydig cell function. Some of the toxicants in this category, termed endocrine disruptors, are now known to antagonize testosterone synthesis (phthalate esters, for example). It is of vital importance to put all of the above developments into a rigorous scientific perspective, and

the present volume has additional emphasis on clinical applications. We hope to have succeeded in this endeavor. Special thanks are due to Meghan Howard and Jean Schweis at the Population Council for their expertise in the management of the manuscripts as they were received from the authors, and to Richard Lansing of Humana Press for his expert advice during all phases of

production. We also are grateful to Michael Conn for leading us to Humana Press and for including *The Leydig Cell in Health and Disease* in the Contemporary Endocrinology™ series. Finally, we thank the authors and commend their work to our readers.

**Anita H. Payne**  
**Matthew P. Hardy**

# CONTENTS

---

Preface .....	v
Contributors .....	ix
List of Color Plates .....	xi

## PART I. HISTORICAL

1. A History of Leydig Cell Research .....	3
<i>A. Kent Christensen</i>	

## PART II. CELL BIOLOGY

2. Structural and Histological Analysis of Leydig Cell Steroidogenic Function .....	33
<i>Syed G. Haider, Gisela Servos, and Nicole Tran</i>	
3. Fetal Leydig Cells: <i>Origin, Regulation, and Functions</i> .....	47
<i>Humphrey Hung-Chang Yao and Ivraym Barsoum</i>	
4. Regulation of Leydig Cells During Pubertal Development .....	55
<i>Renshan Ge and Matthew P. Hardy</i>	
5. The Human Leydig Cell: <i>Functional Morphology and Developmental History</i> .....	71
<i>Frederick P. Prince</i>	
6. Dynamics of Leydig Cell Regeneration After EDS: <i>A Model for Postnatal Leydig Cell Development</i> .....	91
<i>Katja Teerds and Eddy Rijntjes</i>	
7. Aging and the Decline of Androgen Production .....	117
<i>Haolin Chen, Andrew Midzak, Lin-di Luo, and Barry R. Zirkin</i>	

## PART III. STEROIDOGENESIS

8. Regulation of Leydig Cell Cholesterol Metabolism .....	135
<i>Salman Azhar and Eve Reaven</i>	
9. The Role of StAR in Leydig Cell Steroidogenesis .....	149
<i>Douglas M. Stocco</i>	
10. Steroidogenic Enzymes in Leydig Cells .....	157
<i>Anita H. Payne</i>	
11. Development of Leydig Cell Steroidogenesis .....	173
<i>Peter J. O'Shaughnessy, Heather Johnston, and Paul Joseph Baker</i>	
12. Peripheral Testosterone Metabolism .....	181
<i>Daniel P. Sherbet and Richard J. Auchus</i>	
13. Leydig Cell Aromatase: <i>From Gene to Physiology</i> .....	189
<i>Serge Carreau</i>	
14. The Role of Estrogen Sulfotransferase in Leydig Cells .....	197
<i>Wen-Chao Song</i>	
15. Endocrinology of Leydig Cells in Nonmammalian Vertebrates .....	207
<i>Kelly Bonner Engel and Gloria Vincz Callard</i>	



**PART IV. REGULATION**

16. The Luteinizing Hormone Receptor ..... 227  
*Maria L. Dufau and Chon-Hwa Tsai-Morris*
17. Insights Into Leydig Cell Function From Mice With Genetically Modified  
Gonadotropin Action ..... 253  
*Ilpo Huhtaniemi*
18. Growth Factors in Leydig Cell Function ..... 263  
*Varadaraj Chandrashekar and Andrzej Bartke*
19. Insulin-Like Peptide 3 in Leydig Cells ..... 279  
*Richard Ivell and Ross A. D. Bathgate*
20. Neuronal Signaling Molecules and Leydig Cells ..... 291  
*Artur Mayerhofer*
21. Regulation of Leydig Cell Function as it Pertains  
to the Inflammatory Response ..... 305  
*Dale B. Hales*
22. Activins and Leydig Cell Development, Differentiation, and Disease ..... 323  
*Gail P. Risbridger and Christopher Butler*
23. Transcription Factors as Regulators of Gene Expression During Leydig Cell  
Differentiation and Function ..... 333  
*Jacques J. Tremblay*
24. Androgen Receptor in Leydig Cell Function and Development ..... 345  
*Stephen M. Eacker and Robert E. Braun*

**PART V. PHYSIOLOGY AND APPLIED ASPECTS**

25. Fluid Exchange and Transport of Hydrophilic Factors in the Testis ..... 365  
*Brian Peter Setchell*
26. Immortalized Leydig Cell Lines as Models for Studying Leydig Cell Physiology ..... 373  
*Mario Ascoli*
27. Induction of Leydig Cell Tumors by Xenobiotics ..... 383  
*Paul M. D. Foster*
28. Environmental Factors That Disrupt Leydig Cell Steroidogenesis ..... 393  
*Vassilios Papadopoulos*
29. The Leydig Cell as a Target for Male Contraception ..... 415  
*Craig Marc Luetjens, Joachim Wistuba, Gerhard Weinbauer,  
and Eberhard Nieschlag*
30. Clinical Evaluation of Leydig Cell Function ..... 443  
*Ronald S. Swerdloff and Christina Wang*
- Index ..... 459

# CONTRIBUTORS

---

- MARIO ASCOLI, PhD • *Department of Pharmacology, Carver College of Medicine, The University of Iowa, Iowa City, IA*
- RICHARD J. AUCHUS, MD, PhD • *Division of Endocrinology and Metabolism, Department of Internal Medicine, University of Texas Southwestern Medical Center, Dallas, TX*
- SALMAN AZHAR, PhD • *Geriatric Research, Education and Clinical Center (GRECC), VA Palo Alto Health Care System, Palo Alto, CA; and Division of Gastroenterology and Hepatology, Department of Medicine, Stanford University School of Medicine, Stanford, CA*
- PAUL JOSEPH BAKER, PhD • *Institute of Comparative Medicine, University of Glasgow Veterinary School, Glasgow, UK*
- IVRAYM BARSOUM, MD, MS • *Department of Veterinary Biosciences, University of Illinois, Urbana, IL*
- ANDRZEJ BARTKE, PhD • *Department of Physiology, Southern Illinois University School of Medicine, Carbondale, IL; and Department of Internal Medicine, Southern Illinois University School of Medicine, Springfield, IL*
- ROSS A. D. BATHGATE, PhD • *Howard Florey Institute, University of Melbourne, Melbourne, Victoria, Australia*
- ROBERT E. BRAUN, PhD • *Department of Genome Sciences, School of Medicine, University of Washington, Seattle, WA*
- CHRISTOPHER BUTLER, PhD • *Centre for Urological Research, Monash Institute of Medical Research, Monash University, Melbourne, Clayton, Victoria, Australia*
- GLORIA VINCZ CALLARD, PhD • *Department of Biology, Boston University, Boston, MA*
- SERGE CARREAU, PhD • *Laboratoire Biochimie, USC2006 INRA-EA2608, IBFA-Université, Caen, France*
- HAOLIN CHEN, PhD • *Division of Reproductive Biology, Department of Biochemistry and Molecular Biology, Bloomberg School of Public Health, Johns Hopkins University, Baltimore, MD*
- A. KENT CHRISTENSEN, PhD • *Department of Cell and Developmental Biology, University of Michigan Medical School, Ann Arbor, MI*
- VARADARAJ CHANDRASHEKAR, PhD • *Department of Physiology, Southern Illinois University School of Medicine, Carbondale, IL*
- MARIA L. DUFAU, MD, PhD • *Section of Molecular Endocrinology, Endocrinology and Reproduction, Research Branch, National Institutes of Child Health and Human Development, National Institutes of Health, Bethesda, MD*
- STEPHEN M. EACKER, PhD • *Department of Genome Sciences, School of Medicine, University of Washington, Seattle, WA*
- KELLY BONNER ENGEL, PhD • *Department of Biology, Boston University, Boston, MA*
- PAUL M. D. FOSTER, PhD • *National Institute of Environmental Health Sciences, National Institutes of Health Research, Triangle Park, NC*
- RESHAN GE, MD, MS • *Center for Biomedical Research, Population Council and The Rockefeller University, New York, NY*
- DALE B. HALES, PhD • *Department of Physiology and Biophysics, University of Illinois at Chicago, Chicago, IL*
- MATTHEW P. HARDY, PhD • *Center for Biomedical Research, Population Council and The Rockefeller University, New York, NY*
- SYED G. HAIDER, PhD • *Institute of Anatomy II, Heinrich Heine University, Duesseldorf, Germany*
- ILPO HUHTANIEMI, MD, PhD • *Institute of Reproductive and Developmental Biology, Imperial College London, London, UK*
- RICHARD IVELL, PhD • *School of Molecular and Biomedical Science, University of Adelaide, South Australia, Australia*

- HEATHER JOHNSTON, BSC, PHD • *Institute of Comparative Medicine, University of Glasgow Veterinary School, Glasgow, UK*
- CRAIG MARC LUETJENS, PHD • *Institute of Reproductive Medicine, University of Münster, Münster, Germany*
- LIN-DI LUO, PHD • *Division of Reproductive Biology, Department of Biochemistry and Molecular Biology, Bloomberg School of Public Health, Johns Hopkins University, Baltimore, MD*
- ARTUR MAYERHOFER, MD • *Anatomical Institute, Lehrstuhl IV, Ludwig-Maximilians Universität, Munich, Germany*
- ANDREW MIDZAK, BA • *Division of Reproductive Biology, Department of Biochemistry and Molecular Biology, Bloomberg School of Public Health, Johns Hopkins University, Baltimore, MD*
- EBERHARD NIESCHLAG, MD • *Institute of Reproductive Medicine, University of Münster, Münster, Germany*
- PETER J. O'SHAUGHNESSY, BSC, PHD • *Institute of Comparative Medicine, University of Glasgow Veterinary School, Glasgow, UK*
- VASSILIOS PAPADOPOULOS, PHD • *Department of Biochemistry, Molecular and Cellular Biology, Georgetown University Medical Center, Washington, DC*
- ANITA H. PAYNE, PHD • *Division of Reproductive Biology, Department of Obstetrics and Gynecology, Stanford University School of Medicine, Stanford, CA*
- FREDERICK P. PRINCE, PHD • *Department of Biological Sciences, Plymouth State University, Plymouth, NH*
- EVE REAVEN, PHD • *Geriatric Research, Education and Clinical Center (GRECC), VA Palo Alto Health Care System, Palo Alto, CA*
- EDDY RIJNTJES, MS • *Department of Animal Sciences, Human and Animal Physiology Group, Wageningen University, Marijkeweg 40, Wageningen, The Netherlands*
- GAIL P. RISBRIDGER, PHD • *Centre for Urological Research, Monash Institute of Medical Research, Monash University, Melbourne, Clayton, Victoria, Australia*
- GISELA SERVOS • *Institute of Anatomy II, Heinrich Heine University, Duesseldorf, Germany*
- BRIAN P. SETCHELL, BVSC, PHD, SCD • *Department of Anatomical Sciences, University of Adelaide, Adelaide, Australia*
- DANIEL P. SHERBET, MD • *Division of Endocrinology and Metabolism, Department of Internal Medicine, University of Texas Southwestern Medical Center, Dallas, TX*
- WEN-CHAO SONG, PHD • *Institute for Translational Medicine and Therapeutics and Department of Pharmacology, University of Pennsylvania School of Medicine, Philadelphia, PA*
- DOUGLAS M. STOCCO, PHD • *Department of Cell Biology and Biochemistry, Texas Tech University Health Sciences Center, Lubbock, TX*
- RONALD S. SWERDLOFF, MD • *Department of Medicine, David Geffen School of Medicine, University of California at Los Angeles, Los Angeles, CA; and Division of Endocrinology, Harbor-UCLA Medical Center, Torrance, CA*
- KATJA J. TEERDS, PHD • *Department of Animal Sciences, Human and Animal Physiology Group, Wageningen University, Marijkeweg 40, Wageningen, The Netherlands*
- NICOLE TRAN • *Institute of Anatomy II, Heinrich Heine University, Duesseldorf, Germany*
- JACQUES J. TREMBLAY, MSC, PHD, LLB • *Ontogeny-Reproduction Research Unit, CHUL Research Centre, Québec City, Québec, Canada; and Department of Obstetrics and Gynecology, Faculty of Medicine, Centre for Research in Biology of Reproduction, Université Laval, Québec City, Québec, Canada*
- CHON-HWA TSAI-MORRIS, PHD • *Section of Molecular Endocrinology, Endocrinology and Reproduction, Research Branch, National Institutes of Child Health and Human Development, National Institutes of Health, Bethesda, MD*
- CHRISTINA WANG, MD • *Department of Medicine, David Geffen School of Medicine, University of California at Los Angeles, Los Angeles, CA; and General Clinical Research Center, Harbor-UCLA Medical Center, Torrance, CA*
- GERHARD WEINBAUER, PHD • *Covance Laboratories GmbH, Münster, Germany*
- JOACHIM WISTUBA, PHD • *Institute of Reproductive Medicine, University of Münster, Münster, Germany*
- HUMPHREY HUNG-CHANG YAO, PHD • *Department of Veterinary Biosciences, University of Illinois, Urbana, IL*
- BARRY ZIRKIN, PHD • *Division of Reproductive Biology, Department of Biochemistry and Molecular Biology, Bloomberg School of Public Health, Johns Hopkins University, Baltimore, MD*

# LIST OF COLOR IMAGES

---

The images listed below appear in color within the text:

Chapter 5, Color Plate

Chapter 16, Figure 2

The images listed below appear in the color insert following p. 180:

- Color Plate 1.** *Fig. 1, Chapter 1: Photograph of Franz Leydig. (See full caption on p. 4.)*
- Color Plate 2.** *Fig. 3, Chapter 1: Plate from Reinke's 1896 article describing crystalloids in human Leydig cells. (See full caption on p. 10.)*
- Color Plate 3.** *Fig. 4, Chapter 1: First plate from Bouin and Ancel's 1903 article showing testes of piglets of suckling age. (See full caption on p. 15.)*
- Color Plate 4.** *Fig. 1, Chapter 2: FLCs in rat testis. (See full caption on p. 34.)*
- Color Plate 5.** *Fig. 6, Chapter 2: Bar for (A–D): 10  $\mu$ m. (A,B): Immunohistochemical reaction of procollagen. (See full caption on p. 40.)*
- Color Plate 6.** *Fig. 1, Chapter 3: Origin, specification, and differentiation of FLC. (See full caption on p. 48.)*
- Color Plate 7.** *Fig. 2, Chapter 3: Developmental landmarks in fetal testes of rats and mice. (See full caption on p. 50.)*
- Color Plate 8.** *Fig. 1, Chapter 4: Ontogeny of Leydig cells. (See full caption on p. 57.)*
- Color Plate 9.** *Fig. 2, Chapter 4: Development of rat Leydig cells. (See full caption on p. 59.)*
- Color Plate 10.** *Fig. 4, Chapter 6: Immunolocalization of Fas and Fas ligand in Leydig cells. (See full caption on p. 97.)*
- Color Plate 11.** *Fig. 6, Chapter 6: Immunohistochemical localization of LH receptors. (See full caption on p. 102.)*
- Color Plate 12.** *Fig. 7, Chapter 6: Immunohistochemical localization of TGF- $\alpha$ . (See full caption on p. 104.)*
- Color Plate 13.** *Fig. 2, Chapter 14: Immunohistochemical staining of a mouse testis. (See full caption on p. 199.)*
- Color Plate 14.** *Fig. 3, Chapter 14: Leydig cell and seminiferous tubule abnormalities. (See full caption on p. 202.)*
- Color Plate 15.** *Fig. 1, Chapter 16: The deduced amino acid sequence of the hLHR. (See full caption on p. 230.)*

- 
- Color Plate 16.** *Fig. 3, Chapter 16: Determination of the function domain in the promoter of *hLHR* gene. (See full caption on p. 238.)*
- Color Plate 17.** *Fig. 4, Chapter 16: Schematic representation functional *cis*-element in rat, mouse, and human *LHR* gene. (See full caption on p. 239.)*
- Color Plate 18.** *Fig. 5, Chapter 16: Model of transcriptional regulation in the promoter domain of *hLHR* gene. (See full caption on p. 240.)*
- Color Plate 19.** *Fig. 6, Chapter 16: Comparison of 3' flanking sequences of the rat and human *LHR* genes. (See full caption on p. 243.)*
- Color Plate 20.** *Fig. 1, Chapter 17: Testes and accessory sex organs. (See full caption on p. 255.)*
- Color Plate 21.** *Fig. 2, Chapter 17: Light micrographs of testis sections from homozygous LuRKO and wild-type control mice. (See full caption on p. 256.)*
- Color Plate 22.** *Fig. 3, Chapter 17: Testicular histology of wild-type and transgenic mice. (See full caption on p. 258.)*

# I

---

## HISTORICAL

---



# 1

---

## A History of Leydig Cell Research

---

*A. Kent Christensen, PhD*

### SUMMARY

Franz Leydig first described the testicular cells in 1850 that now bear his name. For the next 50 yr after their discovery, Leydig cells were the subject of further studies by light microscopy, and diverse speculations were offered about their possible function. In 1903, Pol Bouin and Paul Ancel provided the first substantial evidence that Leydig cells constituted an endocrine gland controlling male secondary sexual characteristics. Their evidence seemed compelling at the time, but was necessarily circumstantial, because there was no direct proof that Leydig cells produced a male hormone. Over subsequent decades, workers found additional evidence that these cells had an endocrine function, but there were also other findings that cast doubt on the hypothesis, and increasing skepticism developed about the earlier evidence. By the late 1920s, many influential reproductive biologists suspected that the seminiferous tubules were the actual source of male hormone. During the 1930s, the male hormone was shown to be testosterone, its endocrine actions were studied extensively, and the role of the pituitary in regulating testicular function was demonstrated. From the 1930s through the 1950s, Leydig cells came back into favor as endocrine cells, although some uncertainty persisted and there was still no direct evidence that Leydig cells produced androgen. Finally, direct evidence came from histochemistry in 1958 and from biochemistry in 1965.

**Key Words:** Ancel; androgen; Bouin; endocrine; histology; history; Leydig; male; testis; testosterone.

### INTRODUCTION

In 1850, Franz Leydig described cells in the mammalian testis (1) that were later shown to be the source of testicular hormones that control spermatogenesis, the male reproductive tract, and male secondary sexual characteristics. These Leydig cells, sometimes called


interstitial cells (2), occur in clusters between the seminiferous tubules. Leydig's investigations were part of the great elaboration of histology that took place in the years after Schleiden (3) and Schwann (4) proposed the cell theory in 1838–1839. An earlier technical advance in microscope lenses—the development of achromatic objective lenses in the 1820s—had opened the way for both the cell theory and histology because microscopists could now actually observe cells relatively well (5–7). However, specimen preparation was still rudimentary, and tissues were usually observed in manually cut slices, or in teased or macerated preparations (8). But the foundations of histology were laid during this era, and Franz Leydig was one of the pioneers in these developments.

### FRANZ LEYDIG (1821–1908)

Franz Leydig (refs. 9–15; Fig. 1), was born on May 21, 1821, in Rothenburg ob der Tauber, a charming German town surrounded by a medieval wall. His father was a clerk in a municipal salt shop (*Salzamtstodner*), and adjacent to it owned a piece of land that included a small garden, highly-regarded locally for its beauty. The young Franz was an ardent naturalist who loved nothing better than to search for worms, beetles, and other wildlife in that family garden and field. He knew the scientific names of most of the animals and plants he encountered. He also enjoyed observing tiny objects with a small microscope that had been purchased for him when he was about 12 yr old; it had been made in Nürnberg, with lenses held in wooden mounts and with a cardboard microscope tube.

He went to elementary school (*Volksschule*) and then to Latin school (*Lateinschule*). In Latin school he was the only student in the class and, as a consequence,





**Fig. 1.** Portrait of Franz Leydig in his later years, from a painting that has hung in the library of the Institute of Anatomy at the University of Bonn since the days when Leydig was professor there (1875–1887). (Please see color version of this figure on color insert following p. 180.)

much of his learning from Rothenburg professor Benzen, an inspiring teacher and historical scholar, occurred during daily afternoon walks out in the countryside. This training and his natural ability allowed Franz to enter the Bamberg Gymnasium at the age of 15, and to finish in 3 yr.

In 1840, Franz Leydig entered the University of Munich as a student in philosophy, then a broad subject including mostly sciences. He intended to emphasize zoology in his studies. However, the zoology lessons he received did not meet his expectations, amounting, as he later quipped, mostly to the study of bird bones on his Sunday dinner plate, and fish bones at his Friday meal. After 2 yr, it was clear to Leydig, at the age of 20, that this was not what he wanted to do with his life, and so he gave up his scholarship and in the summer of 1842 began medical studies at the University of Würzburg.

At Würzburg, he studied under exceptional teachers, that included human anatomy from professor Martin

Münz, botany from Friedrich Schenk, and especially a variety of subjects from the highly-regarded clinician Franz von Rinecker (1811–1883). By 1846, to help defray expenses, he had become an assistant in the Physiology Institute, and was also helping out in various anatomy courses. Research in microscopic anatomy was not very well developed at Würzburg at that time. In order to build in that field, and allow research and training, von Rinecker in 1846 decided to establish the beginnings of a “Microscopy Institute,” and asked Franz Leydig to play a major role in setting it up. A small room alongside the gross anatomy area was designated for that purpose. Leydig was able, with advice and help from von Rinecker, to locate a small Oberhäuser microscope with which to outfit the room, and an old wooden incubator (heated by a small oil lamp) that had previously been used for embryology teaching. The microscope had been manufactured by the prominent firm of Georg Oberhäuser, a German living in Paris, whose company at about that time was playing an important role in bringing light microscopes into the general design they have today, by modifying tube length and the base (6). The availability of this room and equipment undoubtedly aided Leydig’s development as a histology researcher, and gave him the means to conduct investigations that would lead to many findings, including the discovery of Leydig cells.

Leydig received his medical degree (Doctor of Medicine) in 1847, after defending three theses and presenting a dissertation entitled “Yolk cleavage, its origin in the animal world and its significance” (*Die Dotterfurchung nach ihrem Vorkommen in der Tierwelt und nach ihrer Bedeutung*). This work was published by Leydig in 1848 (16) and has been said (6) to contain the first clear description of nuclear division. By this time, Leydig had a position as an assistant in the small Microscopy Institute that he had set up under von Rinecker’s direction.

In the fall of 1847, the medical faculty at Würzburg was greatly strengthened by the arrival of a new professor, Rudolph Albert Kölliker (1817–1905) (17,18), an internationally renowned histologist from the University of Zurich, who would be in charge of physiology, anatomy, comparative anatomy, histology, and embryology in the medical faculty at the University of Würzburg. Kölliker was originally hired as the professor of physiology and of comparative anatomy, but when professor Münz died in 1849, Kölliker also replaced him as professor of anatomy. From the time Kölliker arrived at Würzburg, he placed high priority on building up the Microscopy Institute, with Leydig as one of his principal aids in that endeavor. Kölliker

later wrote (in translation): “My friend Rinecker had already set up a Microscopy Institute, with his assistant Leydig, as the first such institute anywhere (not only in Germany). I and Leydig, that meritorious researcher who unfortunately is not with us today [*welchen hochverdienten Forscher ich leider unter den heute Anwesenden vermisse*], further developed this institute such that it could serve as a model for all subsequent organizations of that kind” (ref. 17, p. 39). Kölliker also organized a microscopy course, “strongly aided by Leydig” (17), which was a research course dealing with the use of microscopes, preparation methods for various organs, and relevant histology. This was the first course of its kind offered in Germany or perhaps anywhere else (17). After its beginning in the summer of 1848, the course thereafter was usually held in the winter semester from 6 to 8 PM, twice a week. In Kölliker’s autobiography (ref. 17, p. 33), he spoke of Franz Leydig as one of the three particularly able young men whose help proved highly valuable in Kölliker’s efforts during his first decade at Würzburg, to establish a world-famous research and academic center.

Leydig became a prosector in anatomy at Würzburg in 1848. He then applied for a faculty position as lecturer (*privatdozent*), which had to be earned by a grueling procedure (*habilitation*) that included submitted writings, a competitive examination, and a lecture presentation. The topic he chose for his lecture, delivered in April 1849, was “On the structural relationships of Cowper’s gland and prostate in various mammals” (*Ueber die Strukturverhältnisse der Cowperschen und Vorsteherdrüse bei den verschiedenen Säugetieren*), showing histological results from his studies on the male reproductive system. He was appointed lecturer in June 1849. The rank of lecturer (*privatdozent*) would be roughly comparable to an untenured assistant/associate professor in an American medical school today.

Also in 1849, Rudolph Virchow came to the University of Würzburg from the Charité Hospital in Berlin as the new professor of pathology, further strengthening the medical faculty and enhancing the scientific environment in which Leydig’s career was developing.

It was about this time that Leydig submitted a manuscript, describing his comparative histological studies on the male reproductive system in various mammals, for publication in the *Zeitschrift für wissenschaftliche Zoologie*, a journal edited by von Siebold and Kölliker. The article included the first description of the testicular cells that would come to bear Leydig’s name. It appeared in early 1850, (1) and will be described in more detail later.

Late in 1850, Leydig received a royal Bavarian grant of 500 florins for a half year trip down the Italian Mediterranean coast as far as Naples, as well as to the island of Sardinia, to study comparative histology and embryology in terrestrial and marine animals. The stipend was further supplemented by funds from the Würzburg medical faculty and senate. The trip was an extremely valuable experience for Leydig, and broadened his research outlook beyond mammals to other vertebrates and invertebrates.

Leydig aspired to a permanent faculty position at the University of Würzburg, but in the German academic system there was only one regular professor (*ordentlicher Professor*) in each institute, and Kölliker held that position for the Anatomy and Physiology Institutes at Würzburg. However, a lecturer could achieve permanent faculty status as a nonregular or “extraordinary” professor (*ausserordentlicher Professor*). Leydig applied to the Bavarian State Ministry for this rank in March 1853 and, after lengthy negotiations to demonstrate his worthiness, and the need at Würzburg, he was finally awarded an extraordinary professorship in May 1855, at twice the salary that had been requested.

In August of 1855, Franz Leydig married Katharina Jaeger, daughter of a former Würzburg surgeon who had become professor of surgery at the University of Erlangen before his death in 1838. Franz and Katharina had a happy life together, but did not have any children. Leydig’s histology textbook (19) appeared in 1857. It was entitled *Lehrbuch der Histologie des Menschen und der Thiere* (Textbook of Human and Animal Histology). It was a treatise on comparative histology, describing the microscopic anatomy of the body in man and a variety of vertebrates and invertebrates. Leydig was indeed the father of comparative histology. The earlier histology textbooks of Joseph von Gerlach in 1848 (20) and of Albert Kölliker in 1850/1854 (21) and in 1852 (22) had dealt primarily with human histology.

In the summer of 1857, Franz Leydig left Würzburg to become the professor of zoology and comparative anatomy at the University of Tübingen, replacing Wilhelm Rapp, who had died the previous year. Leydig had been recommended for the position by the famous Johannes Müller of Berlin, who was acting on the advice of one of his former students, Hugo von Mohl, professor of botany at Tübingen. Leydig taught and continued his research in comparative histology for 18 yr at Tübingen. In 1869, he was offered the zoology professorship back at Würzburg, but declined the offer.

In 1875, Leydig accepted a professorship in the Anatomy Institute at the University of Bonn, a position that had become vacant because of the death of Max

J. S. Schultze in 1874. It was decided to replace Schultze with two professors, thus dividing the Institute of Anatomy into two divisions. Leydig became the professor of comparative anatomy, histology, and embryology, and Adolph von la Valette St. George became the professor of normal human anatomy. After the death of zoology's former chair in 1882, and the departure of his replacement, Richard Hertwig 3 yr later, in 1885, Leydig became the professor of zoology, in the philosophy faculty.

At Bonn, Leydig continued his research, and taught microscopic anatomy, and other subjects to medical students. He was remembered as an outstanding teacher. It is said that his students revered him (12), and that at later reunions of medical alumni from the University of Bonn (13), the older alumni remembered Dr. Leydig as one of their most inspiring teachers. Among other things, his students remembered the remarkable blackboard drawings he made, often with colored chalk, to illustrate important points. Figure 1 is a copy of an oil painting of the older Leydig that has hung in the library of the Anatomy Institute at the University of Bonn since the days when Leydig was professor there. A similar engraving had been published elsewhere (10).

Leydig retired from active academic life in 1887, at the age of 66. For several years, he and his wife spent their winters in Würzburg, her hometown, where he could continue his research. The townpeople of Würzburg venerated the aging professor. In the words of someone who grew up in Würzburg during that era (in translation): "I can still hear the admonishing words of my Mother, as she was leading us children along Theater Street in Würzburg: 'Children, now you must take off your caps. Here comes the old Leydig'" (4). During many of the summers Leydig and his wife lived in his hometown, Rothenburg ob der Tauber, about 50 km south of Würzburg. In 1896, after a serious bout of influenza had sapped Leydig's strength, they moved permanently to Rothenburg. Franz Leydig died there on April 11, 1908, at 87 yr of age.

During his research career, Leydig produced some 200 publications (for a complete list, see ref. 15), dealing with a broad range of topics covering most of the major groups of animals, from single-celled organisms to mammals. Usually, his articles were illustrated with drawings he did himself. Because of his wide-ranging interests, Leydig was the first to describe many structures in a variety of animals, and some of these new structures were subsequently named after him. Another "Leydig cell," that has nothing to do with testicular Leydig cells except having been discovered by the same

man, is the dermal Leydig cell of the amphibian epidermis. These large, striking, granule-containing cells were first described by Leydig in the larval skin of the salamander *Salamandra maculosa* in 1853 (ref. 23, pp. 107–108), and were later discussed more broadly in 1876 article (ref. 24, pp. 144–146). Although Leydig called them "mucous cells" (*Schleimzellen*), the function of these dermal Leydig cells is still uncertain.

### THE ORIGINAL DESCRIPTION OF TESTICULAR LEYDIG CELLS (1850)

Franz Leydig's 1850 article (1), published while he was a lecturer at Würzburg, was a comparative study of male reproductive histology in various mammals. The article dealt mainly with the male tract and its accessory glands, thus focusing on seminal vesicle, prostate, epididymis, ductus deferens, Cowper's gland, uterus masculinus, and also anal glands. In addition, he made comments on some aspects of the testis, although the histology of sperm and spermatogenesis in the seminiferous tubules had already received a great deal of attention over the preceding two decades, including pioneering work by Kölliker (25,26). Leydig's remarks on the testis referred to its vasculature, pigmentation, appearance of the seminiferous tubules, and also to prominent clusters of what appeared to be cells, overlooked by previous researchers, that he found consistently between the seminiferous tubules. These of course were the cells that have come to be called "Leydig cells," the subject of this volume.

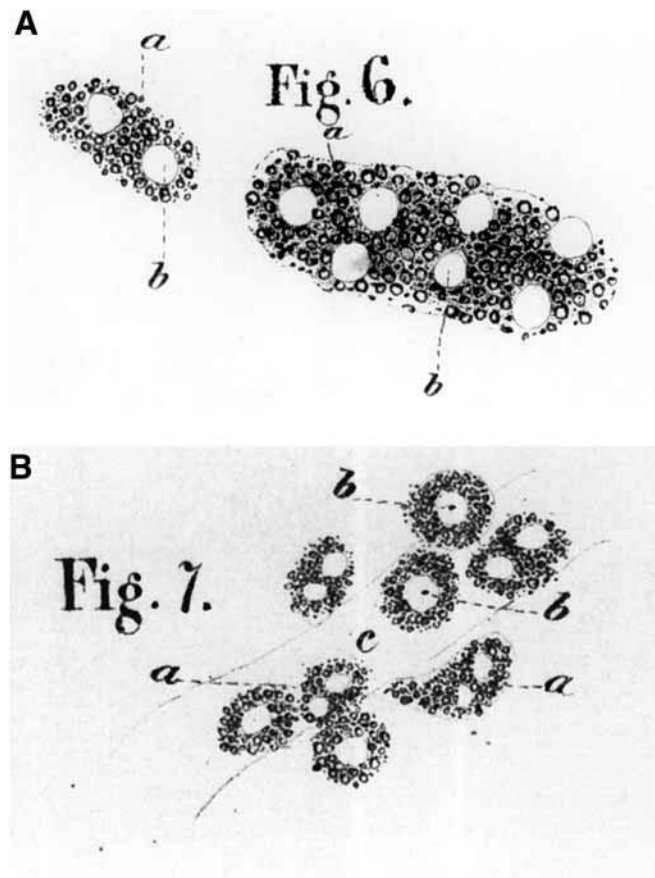
The article is organized on the basis of major mammalian groups, dealing successively with (using common names): nonhuman primates, bats, insectivores, carnivores, marsupials, rodents (and rabbits), pigs, horses, artiodactyls, and a dolphin. Occasional references to Leydig cells are, therefore scattered through the 53 pages of text. Specific descriptions of the cell clusters are given for bat, mole, cat, rat, mouse, rabbit, pig, and horse. Near the end of the article is a 12-page summary of findings for the various organs, including a page on the testis, with a 13-line summary about Leydig cells (ref. 1, pp. 47–48): "From the comparative histology of the testis it is clear that, in addition to seminiferous tubules, blood vessels, and nerves, one finds an additional constant component in the mammalian testis, namely a cell-like mass that when present in smaller amount follows the course of blood vessels between the seminiferous tubules, but when more developed, becomes a mass in which the seminiferous tubules are embedded. Its main constituents are small



granules of fatty appearance, which are unaltered by acetic acid and sodium hydroxide treatment, are colorless, or yellowish, and encompass clear, bubble-like nuclei. Its semifluid ground substance may condense into a cell membrane, and at least in some mammals the entire granular mass is surrounded by a sharp outline. Also, at times the entire structural aggregate is of such an appearance that one can speak of it as a complete cell.”

Of the 43 figures, arranged in four plates, only two figures by Leydig, Figs. 6 and 7, show Leydig cells. These two figures are reproduced here, considerably enlarged, as Fig. 2. The legend for Fig. 2 includes an English translation of Leydig’s legends for his Figs. 6 and 7. If you want to visualize a facsimile of the original German text of the testis summary (ref. 1, pp. 47–48), as well as a complete copy of his Plate 1 (Figs. 1–13) and its German legends, consult Setchell’s *Male Reproduction* (ref. 26, pp. 230–235). The article by Ober and Sciagura (10) includes a facsimile of the title and first paragraph of Leydig 1850, as well as an enlargement of Figs. 6 and 7.

The general features of Leydig’s description agree with what we know today. However, an understanding of the text in Leydig’s article requires some acquaintance with the procedures of tissue preparation for microscopy that were current in the late 1840s, when Leydig made these observations. At that time, the available techniques did not allow a very clear view of tissues. The method of tissue preparation that we take for granted today—fixation, dehydration, embedding, sectioning, staining, and viewing with an oil immersion lens—would not be developed until many years after Leydig’s observations were made. Instead, common procedures of that era (8) included teasing living tissues apart with fine needles, or cutting manual slices as thin as possible of living tissue, or of organs that had been hardened in alcohol (usually a poor histological fixative), or other substances such as chromium trioxide. Another approach was to macerate pieces of tissue by leaving them in various solutions long enough to break down some of the connective tissue, allowing components to be teased apart. Generally, contrast was poor, but could be improved somewhat (at the expense of resolution) by lowering the position of the microscope’s condenser (or closing a condenser diaphragm, if present), or by using one of the rather nonspecific stains available at the time, such as carmine, cochineal, saffron, madder, or indigo. The microscope’s achromatic objective lens was used dry (no oil immersion yet). Although coverslips (of thin glass or mica) had been used before this time, it is not clear whether or



**Fig. 2.** Illustration of Leydig cells from the original Leydig 1850 article (1) in which the cells were first described. Leydig’s Figs. 6 and 7 (from his first plate) are shown here, the only figures of Leydig cells in the article. The two figures have been enlarged here about 2.5 times their original size. The following are translations of the legends Leydig provided for his figures: “Figure 6. Masses found between the seminiferous tubules and also in the mediastinum in the cat testis. (A) Small fat granules, embedded in a soft ground substance. (B) the clear vesicular nuclei that are enclosed in the masses. Figure 7. The same masses seen in the testis of the bat, *Vesperugo pipistrellus*. (A,B) These have the same meaning as in Fig. 6. (C) A blood vessel on which the masses are usually situated.”

not Leydig used them; if not, then irregular water contours on the surface of the specimen being viewed would have further reduced the quality of the image.

In the preparations available to him, Leydig often found it difficult to make out intercellular boundaries between the Leydig cells, or to discern a sharp contour at the surface of cells or masses that would suggest a cell membrane. Most of the “fatty granules” he described filling the cytoplasm of Leydig cells were probably lipid droplets, abundant in the Leydig cells of many species, and which would have been visible as refractile structures in teased living preparations. Lipid droplets would

have been extracted in specimens that had been stored in alcohol. Leydig cells in some species (boar, horse) would also have contained lipofuscin pigment granules, which Leydig described as “yellow, sharply-defined point-like granules,” giving a “chocolate,” or “coffee-brown” color to the interstitial tissue. Leydig often recognized individual Leydig cells, as for example his Fig. 7 (our Fig. 2B), of bat Leydig cells, which shows four individual mononucleate cells, as well as four binucleate cells, or two-cell clusters. He also sometimes stated clearly that the masses between the seminiferous tubules were made up of individual cells. However, in other cases, when he couldn’t discern any intercellular boundaries within a mass, as in the cat (our Fig. 2A), he was forced to consider the possibility that a mass might be an individual multinucleate cell. The closing line of the summary statement (*see pp. 6–7*) might reflect that possibility.

#### FURTHER 19TH CENTURY WORK ON LEYDIG CELLS

In 1854, Albert Kölliker described these cells in the human testis (21), which had not been covered in Leydig’s original 1850 article (1). The description occurred in the male reproductive section of a two-volume advanced histology textbook entitled “Human Microscopic Anatomy or Histology” (*Mikroskopische Anatomie oder Gewebelehre des Menschen*), in volume 2, which was devoted to organ histology. There were no figures illustrating the cells, and the description (ref. 21, p. 392) was brief. (Note: the human testis are divided into 200–300 lobules, each usually, containing one to three seminiferous tubules; the thin connective tissue partitions that lie between the lobules are called septula): “As soon as the testis lobules are completely isolated, then the septula appear as effective separating partitions. These septula contain, in their loose connective tissue, many pale, round cells, similar to those found in embryonic connective tissue. In older men the cells are single or numerous, often gathered together in clusters, becoming enlarged and producing fat droplets, or brown pigment granules in their cytoplasm. Similar cells are found more sparsely among the seminiferous tubules in the connective tissue that hold the lobule together.” The bibliography at the end of that chapter includes Leydig’s 1850 article (1), but it is only cited in the text regarding the male tract and accessory glands.

Leydig’s 1857 textbook of comparative histology (19) contained a description of Leydig cells in the testes of various mammals, most of the information based on his article of 1850 (1). The book does not include any figure that shows Leydig cells. The chapter on the

vertebrate male reproductive system has a half-page summary statement about these cells, similar to the summary in Leydig 1850. The only new information on Leydig cells is that they are present in the testis of the lizard *Lacerta agilis*. At the end of the chapter, information from the 1850 article (the source is clearly stated) describing the male tract and the testis in various mammalian groups, is abstracted in small print, including some mention of Leydig cells. Although the book contains a separate chapter on the human reproductive system, there is no reference to Leydig cells in that chapter.

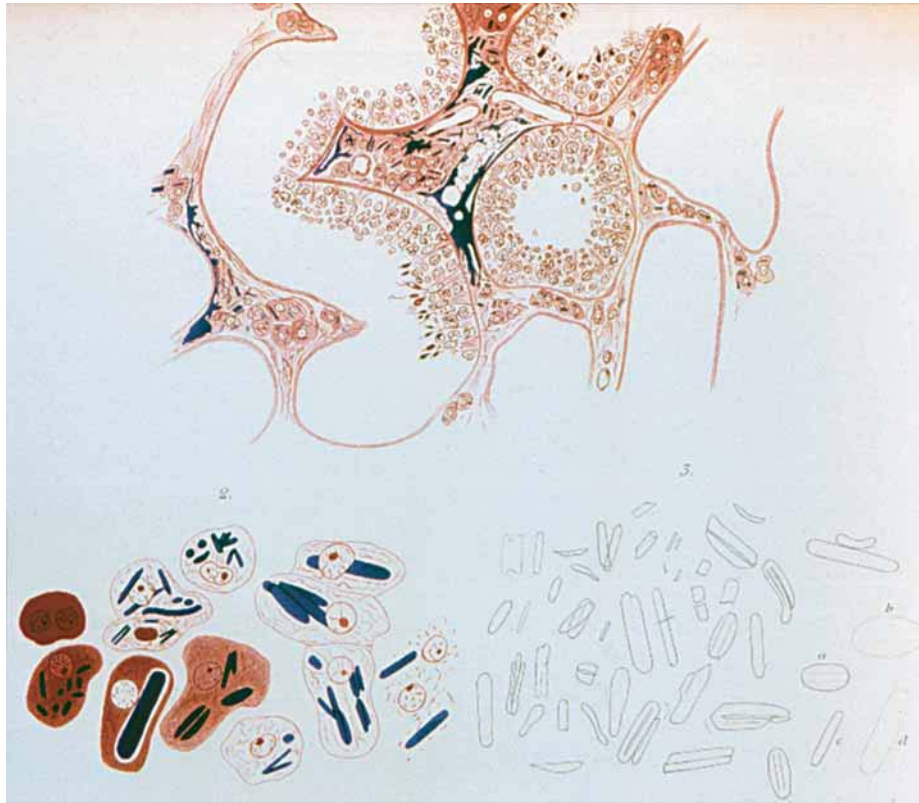
As the methods of specimen preparation for light microscopy improved over the latter half of the 19th century (8), it was possible to observe Leydig cells in more accurate detail. Early microtomes for cutting sections came into serious use for biological investigation in the 1860s. Simple embedding of a specimen in paraffin wax for sectioning dated from 1869, but true infiltration with paraffin began about 1881. Osmium tetroxide was first described as a fixative in 1864, whereas the use of formaldehyde for fixation did not begin until 1893. The first use of two different stains on the same section (double staining) was described in 1867. Hematoxylin was first used with a mordant, allowing effective staining, in 1872. Synthetic dyes for staining sections came out in the 1860s (aniline blue, basic fuchsin), 1870s (eosin, safranin, acid fuchsin, orange G), 1880s (methylene blue, malachite green), and 1890s (toluidine blue, neutral red, azocarmine). The homogeneous oil immersion lens was introduced by Carl Zeiss and Ernst Abbé in 1878, and in 1883 Abbé completed calculations for the first apochromatic objective lens, corrected for chromatic aberration at three wavelengths and also for spherical aberration (6). Utilizing these highly improved preparative techniques and optics, workers were able to provide more exacting descriptions of Leydig cells in animals of various species, at diverse stages of developmental and physiological states. A list of some of these articles is given in Table 1.

One of many examples of fine histological detail achieved during this period was Reinke’s 1896 description of crystalloids in human Leydig cells (27). Friedrich Reinke (1862–1919) (10,28) was in the Anatomical Institute of the University of Rostock, in northeastern Germany. His training included studies at the University of Kiel, where professor Flemming had stimulated his interest in histology. These Leydig cell crystalloids had been overlooked in previous histological studies of the human testis, probably because it was difficult to obtain fresh human material and because the most favorable preparative procedure for this human tissue had not yet been worked out. Reinke was fortunate to obtain fresh testis tissue from a 25-yr-old

Table 1  
Studies on Testicular Leydig Cells in Various Animals (Alphabetical Listing by Common English Name and Year)<sup>a</sup>

<i>Animals</i>	<i>Year</i>
Bat	1850 (1), 1923 (118,119), 1925 (120), 1927 (121), 1939 (122), 1940 (123)
Cat	1850 (1), 1873 (124), 1879 (32), 1897 (31,34), 1898 (29), 1903 (35), 1908 (74), 1912 (79), 1924 (70), 1928 (125)
Cattle	1903 (35), 1908 (74), 1922 (126), 1923 (127), 1944 (103)
Chicken	1904 (128), 1911 (129), 1912 (130,131), 1917 (132), 1919 (133), 1922 (134,135), 1924 (136–138), 1926 (139), 1929 (140)
Deer ( <i>Odocoileus</i> , <i>Cervus</i> )	1949 (141)
Dog	1879 (33), 1901 (142), 1903 (35), 1911 (129)
Dormouse ( <i>Eliomys</i> )	1911 (129)
Duck	1922 (143)
Fish	1921 (144–146), 1923 (148), 1924 (149,150), 1925 (151,152)
Frog	1898 (155), 1908 (156), 1911 (130), 1913 (157), 1923 (158), 1924 (159–162), 1925 (163)
Goose	1926 (140)
Guinea pig	1903 (35), 1904 (164), 1922 (165,166), 1923 (167), 1924 (71,168), 1928 (169)
Hare	1850 (1)
Hedgehog ( <i>Erinaceus europaeus</i> )	1911 (82), 1925 (121), 1927 (122), 1934 (170)
Horse	1850 (1), 1879 (32), 1903 (35), 1904 (61), 1905 (60), 1908 (76), 1933 (171)
Human	1854 (21), 1872 (2), 1879 (32), 1895 (30), 1896 (27), 1897 (34,172), 1903 (35), 1907 (173), 1908 (75,174), 1911 (130), 1912 (175), 1920 (176), 1921 (177), 1923 (167,178), 1927 (179), 1928 (180), 1930 (90), 1934 (181), 1938 (182), 1939 (183), 1948 (184), 1950 (185–187)
Jackdaw ( <i>Corvus monedula</i> )	1919 (188), 1921 (189)
Kangaroo	1879 (32)
Lizard	1857 (19), 1911 (130), 1929 (190), 1930 (191)
Marmot ( <i>Marmota marmota</i> )	1895 (30), 1903 (192), 1927 (122)
Mouse	1850 (1), 1897 (31), 1922 (136), 1923 (193), 1924 (71), 1945 (194)
Mouse ( <i>Peromyscus</i> )	1948 (195)
Mole ( <i>Talpa europea</i> )	1850 (1), 1873 (125), 1904 (196), 1909 (197), 1911 (198), 1912 (199), 1925 (121)
Opossum ( <i>Didelphys virginiana</i> )	1918 (200)
Pig	1850 (1), 1873 (125), 1879 (32), 1895 (30), 1901 (45), 1903 (35), 1904 (73,201), 1905 (74), 1911 (202,203), 1812 (80), 1921 (204), 1925 (205)
Rabbit	1850 (1), 1904 (164,201,206), 1924 (71), 1928 (169), 1950 (207)
Rat	1850 (1), 1871 (208), 1879 (32), 1900 (209,210), 1919 (211), 1920 (70), 1922 (136), 1924 (168), 1939 (212), 1943 (213)
Salamander	1913 (157,214), 1921 (215–217), 1922 (218,219), 1923 (220,221), 1924 (161,222), 1925 (223)
Sheep	1925 (205)
Snake	1911 (130)
Squirrel	1880 (36), 1908 (75)
Sparrow ( <i>Passer domesticus</i> )	1902 (224), 1943 (225)
Starling ( <i>Sturnus vulgaris</i> )	1930 (226,227)
Toad	1898 (155), 1911 (130), 1913 (157)
Weasel ( <i>Mustela ermina</i> )	1935 (228)
Widow bird (in French, <i>Combassou</i> ; <i>Vidua</i> )	1923 (229,230)
Woodchuck ( <i>Marmota monax</i> )	1917 (83), 1918 (231)

<sup>a</sup>A similar but more extensive list, organized phylogenetically and including electron microscopy, is available in the author's 1975 Leydig cell review (118).



**Fig. 3.** Plate from Reinke's 1896 article (27) describing crystalloids in human Leydig cells. (A) Overview of human testis, showing seminiferous tubules and interstitial tissue, with Leydig cells containing crystalloids. The testis was obtained fresh from a 25-yr old executed criminal, and was fixed in absolute alcohol. Sections were stained with Weigert fibrin stain. The artist has omitted the seminiferous epithelium in some areas of the seminiferous tubules. (B) Detail of Leydig cells, containing the crystalloids. (C) Isolated, unstained, alcohol-stabilized crystalloids suspended in water, showing various forms. (Please see color version of this figure on color insert following p. 180.)

executed criminal, and subjected the tissue to a battery of fixatives and stains, obtaining excellent results. A copy of the plate in Reinke's article is shown here as Fig. 3. The crystalloids varied in size and in the number per cell. Having determined the best histological methods for preserving this human material, Reinke did further studies on tissue from 10 other individuals, presumably taken at autopsy, and these results were also described in the 1896 article. The crystalloids were seen in the Leydig cells of all the individuals except a 15-yr-old boy and a 65-yr-old man, neither of whom were producing sperm. A facsimile of the title and introductory paragraph of Reinke 1896, as well as a copy of the plate, have also been reproduced elsewhere (10).

In the Leydig cell articles of this era there were speculations about what kind of cell type this was, as well as what function it performed. We will merely summarize some of these speculations, usually without citing specific references, because most of them were mistaken. If details are desired, they can be found in the

article by Beissner (29). The majority of researchers felt that Leydig cells were connective tissue cells (Leydig, Kölliker, Boll, Messing, Tourneaux, Hansemann), although others proposed that they were peripheral cells associated with lymphatic vessels (Ludwig and Tomsa, Mihalkovics), neural ganglion cells (Letzerich, Harvey), cells related to plasma cells (Waldeyer), an immature form of Sertoli cell (von Bardeleben), epithelial cells (Hofmeister), or embryonic epithelium (Nussbaum). Evidence that Leydig cells were of connective tissue nature included a study (30) on the male reproductive cycle in marmots, showing that the annual atrophy of Leydig cells gave rise to fibroblast-like cells in the interstitial tissue.

The most popular hypothesis for Leydig cell function during this period was that Leydig cells took up materials from the circulation, processed them, and then passed these nutrients to the adjacent seminiferous tubules to support spermatogenesis. Some workers interpreted the crystalloids that were shown by Reinke



in human Leydig cells (27) as a possible example of material prepared by the cells to be presented to the seminiferous tubules. Another substance that could be seen in the Leydig cells, and interpreted as evidence for this hypothesis, was fatty material (lipid droplets or lipid in secondary lysosomes), which could be demonstrated histologically by fixation and staining with osmium tetroxide. An influential article by Plato in 1897 (31) described the fatty material known to be present in the Leydig cells, and compared it with nearby fatty spherules seen in the base of Sertoli cells at the periphery of the seminiferous tubules. Plato showed figures from cat and mouse testes that purported to be intermediary stages in the passage of fatty material from Leydig cells to Sertoli cells, the material appearing to span the boundary layer (myoid cell layer) of the seminiferous tubules. A subsequent study by Beissner in 1898 (29), saw no evidence for passage of lipid across the boundary layer in cat testis, and, in fact, most of the lipid in the seminiferous tubules was near the center of the tubules, not near the periphery.

Franz Leydig did not always get credit for discovering the cells that now bear his name. Many prominent articles on these cells in the late 1800s credited Kölliker, the most renowned histologist of the era, with the original discovery. Once the error had appeared in print, it tended to be repeated by others. Examples of influential articles that contained this mistake included Tourneaux 1879 (32), Jacobson 1879 (33), Hansemann 1895 (30), Reinke 1896 (27), Plato 1897 (31), von Lenhossék 1897 (34), and Bouin and Ancel 1903 (35). Even if these authors had been aware of Leydig's 1850 article (1), it is easy to understand how they could have overlooked its description of these new testicular cells, because the article dealt primarily with accessory glands of the male reproductive tract. The authors assumed that Kölliker's 1854 description of these cells in the human testis (21) was the original discovery. After crediting Kölliker, these authors usually went on to say that a few years later, Leydig, in his 1857 textbook of histology (19), gave a broad description of these cells in various mammals, which of course was true. However, they missed the fact that Leydig had also given essentially the same broad description in 1850. The error was pointed out occasionally, for example by Nussbaum in 1880 (ref. 36, pp. 85–96), and emphatically by Stieda in 1897 (37), and by Beissner in 1898 (29). After the turn of the century, Leydig was usually given clear priority as the discoverer of Leydig cells. Kölliker never claimed priority. The correct information was summarized succinctly by von Ebner in 1902, in the last edition of Kölliker's famous histology

textbook (ref. 38, p. 413), here quoted in translation: "Testicular interstitial cells, first described by Leydig in animals (in 1850), and by Kölliker in man (in 1854), have had a variety of functions attributed to them."

### CONTROL OF MALE SECONDARY SEXUAL CHARACTERISTICS: NERVES VS HORMONES

It might seem surprising to present day readers that virtually none of the numerous articles that appeared in the 1890s on putative Leydig cell functions devoted appreciable attention to the possibility that Leydig cells served an endocrine function in the control of male secondary sexual characteristics. The concept of endocrine glands was coming into prominence during that period, because of work on the endocrine pancreas, thyroid, and other newly-discovered endocrine glands. Possible endocrine factors in the testis had actually received some notoriety in the late 1880s through the well-publicized but controversial experiments of Brown-Séquard (39), a professor at the University of Paris, who injected extracts of animal testes into himself, and claimed beneficial results. However, most of the researchers who were engaged in the study of Leydig cells did not seem to associate these matters with possible Leydig cell function.

This lack of concern about testicular endocrinology was paradoxical because, as would be widely appreciated a few years later, the testis had actually been the organ in which endocrine effects were first demonstrated, back in 1849, a year before Leydig's first description of Leydig cells. This discovery (40), now acknowledged as the beginning of endocrinology, was made by Arnold Adolph Berthold (1803–1861) (41), of the University of Göttingen, Germany. Of course, it had been known since antiquity that castration of a male animal resulted in the reduction or loss of male sexual characteristics. Generally, at the time of Berthold's study it was assumed that the ability of the testis to maintain male characteristics throughout the body was mediated through the nervous system, with nerves from the testis being able to exert their control by way of the central nervous system. Berthold's experiments involved testicular transplantation in male chickens 2–3 mo old. When the testis of an animal was transplanted into the abdominal cavity of another animal that had been castrated, the transplanted testis was sometimes able to become established, with adequate blood supply, usually on an intestinal surface. Six months after the transplantation, these animals showed all the male sexual characteristics of roosters, including



full comb and wattle development, as well as typical rooster behavior. As Berthold pointed out, these male characteristics could not have been under the control of specific testicular nerves, because those nerves had been severed and only gastrointestinal autonomic nerves were available in the gut. However, the blood supply was well established and so the most reasonable explanation was that the testis secreted some product into the blood which was then distributed throughout the body to control male sexual characteristics. Although Berthold's study is now famous, the article was largely ignored at the time, because of initial difficulties others had in reproducing his experiments (41). The concept of neural control of male secondary sexual characteristics, thus continued to be widely believed until the end of the century, which might explain why most of those who studied Leydig cells during the period were not considering an endocrine role for these cells. It was not until after the turn of the century that Berthold's work was "rediscovered" and widely recognized.

Originally, Berthold presented his experimental results in February 1849 as a talk before the Göttingen Royal Scientific Society, and the written article subsequently appeared in the proceedings of that society (42). A slightly shorter version of the same article was also published that year in a more accessible journal (40). Several English translations of the journal articles are available (Bremner 1981 [43], for example), and a facsimile of the article from the society proceedings can be seen in Setchell's *Male Reproduction* (ref. 26, pp. 225–229).

The possibility that Leydig cells might be involved in internal secretion was mentioned in at least two articles before 1903, the year Bouin and Ancel published their initial classic article on the subject. The first of these earlier mentions was in the 1896 article of Reinke on crystalloids in human Leydig cells (27), described earlier. Commenting on the possible significance of the crystalloids, Reinke wrote (ref. 27, p. 43): "It seems to me the most likely *a priori* that, as in the thyroid, these interstitial cells produce an unknown product, which is transported through lymph to the blood and probably carries out unknown functions. Furthermore, when this material is produced in excess, it becomes stored in the form of these crystalloids." He further suggested that "these interstitial cells, with their crystalloids, have something to do with spermatogenesis and probably with sex drive."

The second earlier mention of internal secretion was in the short 1901 article by Regaud and Policard (44) on pig testis. After pointing out a putative fine-granular secretory material seen in the Leydig cell cytoplasm after staining with cupric hematoxylin, and showing that the Leydig cells became abundant before seminiferous

tubules had developed appreciably, the authors concluded (44): "There is thus relative anatomical and functional independence between the interstitial cells and the seminiferous tubules, and these permit us to attach the secretory phenomena that is seen in the interstitial cells to a particular internal secretion that has long been suspected. The phrase "has long been suspected" might have referred to the public excitement over Brown-Séquard's experiments (39), aforementioned which were highly controversial.

#### POL BOUIN (1870–1962) AND PAUL ANCEL (1873–1961)

Bouin and Ancel were the first to strongly emphasize a possible endocrine role for Leydig cells. They presented a well-formulated hypothesis that Leydig cells served as a gland of internal secretion to control male secondary sexual characteristics throughout the body, and they supplied extensive evidence for this hypothesis. Although their evidence was necessarily circumstantial, it was laid out beautifully in careful, detailed, and well-reasoned articles. Before describing the contributions of these pioneers in reproductive endocrinology, we will summarize their lives.

Pol André Bouin (45–51) was born on June 11, 1870, in Vendresse, a small village in the Ardenne region of France, near the Belgian border northeast of Reims. His father was a veterinary surgeon who had a strong interest in the physiology of domestic animals, a subject he sometimes discussed with his son, including observations on cryptorchidism. His mother was a very cultured woman who read English and German fluently. His grandfather had been a veterinarian in the imperial stables of Napoléon Bonaparte.

After completing Vendresse primary school, and receiving degrees in letters and sciences from the lycée in Charleville-Mézière (about 20 km northwest of Vendresse), in 1891 Bouin began medical training in the faculty of medicine at University of Nancy, living with relatives in that city. Two of his professors particularly caught his attention, Adolphe Nicolas, professor of anatomy, and especially Auguste Prenant (1861–1927), professor of histology. Prenant was an excellent teacher and an individual of broad erudition, who did research on seminiferous tubules. Under his inspiration, the young Bouin developed a strong interest in histology and soon began doing research on the testis in Prenant's lab, receiving a position as histological preparator (*préparateur d'histologie*) in 1892. One of Bouin's studies became his medical thesis, a project to show the effects that blockage of the ductus deferens or