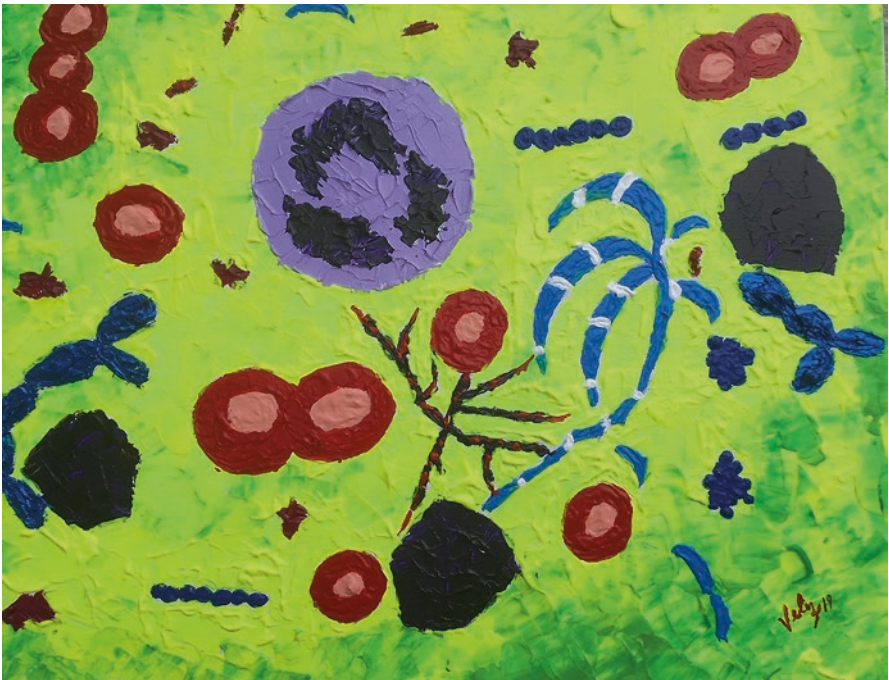

Ana Paula Velez · Jorge Lamarche
John N. Greene *Editors*

Infections in Neutropenic Cancer Patients

 Springer

Infections in Neutropenic Cancer Patients



Infections in Neutropenia

Ana Paula Velez • Jorge Lamarche
John N. Greene
Editors

Infections in Neutropenic Cancer Patients

 Springer

Editors

Ana Paula Velez
Associate Professor
University of South Florida
Tampa, FL, USA

Jorge Lamarche
James Haley VA Hospital
USF Morsani College of Medicine
Tampa, FL, USA

John N. Greene
Moffitt Cancer Center and Research Institute
USF Morsani College of Medicine
Tampa, FL, USA

ISBN 978-3-030-21858-4 ISBN 978-3-030-21859-1 (eBook)
<https://doi.org/10.1007/978-3-030-21859-1>

© Springer Nature Switzerland AG 2019

This work is subject to copyright. All rights are reserved by the Publisher, whether the whole or part of the material is concerned, specifically the rights of translation, reprinting, reuse of illustrations, recitation, broadcasting, reproduction on microfilms or in any other physical way, and transmission or information storage and retrieval, electronic adaptation, computer software, or by similar or dissimilar methodology now known or hereafter developed.

The use of general descriptive names, registered names, trademarks, service marks, etc. in this publication does not imply, even in the absence of a specific statement, that such names are exempt from the relevant protective laws and regulations and therefore free for general use.

The publisher, the authors, and the editors are safe to assume that the advice and information in this book are believed to be true and accurate at the date of publication. Neither the publisher nor the authors or the editors give a warranty, express or implied, with respect to the material contained herein or for any errors or omissions that may have been made. The publisher remains neutral with regard to jurisdictional claims in published maps and institutional affiliations.

This Springer imprint is published by the registered company Springer Nature Switzerland AG
The registered company address is: Gewerbestrasse 11, 6330 Cham, Switzerland

*With love to my parents, my supportive
husband, and kids. With all the respect
to my colleagues and co-authors,
my mentors, and especially to my patients...*

Ana Paula Velez

Contents

Central Nervous System Infections in Neutropenic Cancer Patients.	1
Shylah M. Moore-Pardo and Olga Klinkova	
Head and Neck Infections	13
Ana Paula Velez, John N. Greene, and Jorge A. Lamarche	
Respiratory Infections	23
Olga Klinkova	
Gastrointestinal and Genitourinary Infections	37
Ana Paula Velez, John N. Greene, and Jorge Lamarche	
Skin Infections.	49
Nancy Rihana and Mindy Sampson	
Bacteremia in Neutropenic Patients	73
Sheila Hernandez, Ana Paula Velez, Jorge Lamarche, and John N. Greene	
Fungal Infections.	89
Ana Paula Velez, Jorge Lamarche, and John N. Greene	
Neutropenic Fever	105
Aliyah Baluch and Sarah Shewayish	
Antifungal Medications in Neutropenia	119
Rod Quilitz	
Antimicrobial Prophylaxis	151
Yanina Pasikhova	
Antimicrobial Stewardship in Immunocompromised Hosts.	163
Wonhee So	
Index.	181

Central Nervous System Infections in Neutropenic Cancer Patients



Shylah M. Moore-Pardo and Olga Klinkova

Abstract Neutropenic cancer patients are more susceptible to central nervous system (CNS) infections due to impaired host defense mechanisms (Zunt, *Neurol Clin* 20(1):1–22, 2002). Clinical diagnosis can be challenging due to subtle or atypical presentation or symptoms (Zunt, *Neurol Clin* 20:1–22, 2002; Lukes et al. *Neurology* 34(3):269–275, 1984; Schmidt-Hieber et al. *Ann Oncol* 27(7):1207–1225, 2016). CNS infections typically manifest as four clinical syndromes that may overlap. These are meningitis, encephalitis, brain abscess, and post-surgical neurological infections (Schmidt-Hieber et al. *Ann Oncol* 27(7):1207–1225, 2016).

Risk factors for CNS infections in this patient population depend on age, type of malignancy, duration of neutropenia, treatment used (type of a transplant, chemotherapy, steroids, immunosuppressant agents, neurosurgical interventions), and environmental exposures.

Keywords Central nervous infections · Bacterial meningitis · Viral meningitis · Non infectious meningitis · Enterovirus meningitis · HSV encephalitis · VZV meningitis · HHV6 encephalitis · JC progressive leukoencephalopathy (PML) · Candida meningitis · Rhomboencephalitis · Brain abscess

Meningitis/Encephalitis

Meningitis is an inflammatory process involving the meninges and is defined by a pleocytosis or abnormal white blood cell count in cerebrospinal fluid (CSF). Encephalitis is a syndrome characterized by inflammation of the brain parenchyma. When these two entities co-exist, meningoencephalitis is diagnosed.

S. M. Moore-Pardo, MD (✉)
Division of Infectious Diseases, Department of Internal Medicine,
University of South Florida, Tampa, FL, USA

O. Klinkova, MD
Moffitt Cancer Center, Tampa, FL, USA

Bacterial meningitis can be classified as community acquired or nosocomial. In neutropenic cancer patients actively receiving chemotherapy, acute bacterial meningitis is a relatively rare diagnosis and the acquisition of infection most commonly occurs through hematogenous spread from other infectious sites or contiguous spread of a pre-existing infection of the head and neck [2]. Patients with prior history of neurosurgical interventions, intraventricular shunts or indwelling vascular devices are at higher risk for bacterial meningitis as well [3, 4]. A true community-acquired meningitis can be seen more frequently in chronically neutropenic patients living in the community.

Noninfectious causes of meningitis that are also important to rule out in cancer patients includes tumor spread (meningeal or parenchymal), vasculitis, and medications (chemotherapy, nonsteroidal anti-inflammatory drugs, sulfa, antithymocyte globulin, intravenous globulin, among others).

Microbiology and Specific Risk Factors

Bacterial Pathogens

Among neutropenic cancer patients, acute bacterial meningitis can be caused by gram positive, gram negative pathogens as well as viruses and atypical bacteria (Table 1). Important gram positive pathogens to consider in this population include *Streptococcus pneumoniae*, *Staphylococcus aureus*, and coagulase-negative staphylococci [4–6]. Patients undergoing active chemotherapy treatment and with ongoing mucositis are at an increased risk for meningitis caused by *Rothia mucilaginosa* [7, 8] or other gram positive cocci such as Viridans group streptococcus that are a part of normal oral flora. *Corynebacterium jeikeium* meningitis in neutropenic patients has been described in the literature as well [9]. Compared to the general population, *Neisseria meningitidis* is a rare cause of meningitis in neutropenic cancer patients [6]. Currently, *Haemophilus influenzae* is rarely seen as a result of Haemophilus influenza type b (Hib) vaccine. *Listeria monocytogenes* is an important cause of meningitis in neonates, older adults, pregnant women, and

Table 1 Meningitis/encephalitis

Bacteria	Virus	Fungi
<i>Streptococcus spp</i>	HSV 1, and HSV 2	<i>Candida spp</i>
<i>Neisseria meningitidis</i>	VZV	
<i>Listeria monocytogenes</i>	CMV	
<i>Staphylococcus aureus</i>	EBV	
Coagulase negative staphylococcus (if device in place)	HHV6	
<i>Rothia mucilaginosa</i>	WNV	
<i>Corynebacterium jeikeium</i>	JC virus	
Enterobacteriaceae		
<i>Pseudomonas spp</i>		

immunosuppressed patients (AIDS, chronic steroid use, organ transplants, and those receiving fludarabine chemotherapy) and must be considered in neutropenic patients that live in the community [6, 10, 11].

Gram negative pathogens such as *Enterobacteriaceae* group of organisms and *Pseudomonas aeruginosa* are also an important cause of CNS infection in this population [6].

Viral Pathogens

Enterovirus is by far the most common cause of viral meningitis and should be considered in neutropenic patients that reside in the community [12].

Herpes Simplex Virus-1, 2 (HSV-1, 2), Varicella Zoster Virus (VZV), cytomegalovirus (CMV), and Epstein Barr Virus (EBV) are potential causative agents of meningoencephalitis in the immunocompromised host. These infections are caused by primary infection or reactivation of latent infection in cancer patients undergoing chemotherapy [1, 13, 14]. VZV is implicated as a cause of not only meningoencephalitis but vasculopathies including vasculitis and cerebro-vascular accidents [15]. CMV spectrum of CNS disease includes meningitis, meningoencephalitis, encephalomyelitis, and radiculopathy [16].

Human Herpes Virus-6 and -8 (HHV-6, -8) frequently reactivate in cancer patients undergoing active chemotherapy. Clinical disease such as encephalitis occurs rarely but should be considered in neutropenic patients with unexplained encephalopathy or other encephalitis symptoms [17, 18]. The most important risk factor for the development of HHV-6 associated encephalitis in this group is a prior history of hematopoietic stem cell transplant (HSCT) with ongoing immunosuppression [17].

Encephalitis due to West Nile Virus (WNV) can be mosquito borne, blood borne, or donor derived in HSCT patients and should be considered in chronically neutropenic patients presenting from the community with encephalitis symptoms.

JC poliovirus (JC virus) is the cause of progressive multifocal leukoencephalopathy (PML). It is most commonly seen in AIDS patients, but the incidence is increased in cancer patients with certain risk factors [19]. The risk factors that are associated with increased incidence of PML include an underlying diagnosis of lymphoproliferative disease (e.g., B-CLL, Hodgkin's disease), chemotherapy regimens that include purine analogs (e.g., fludarabine, cladribine), rituximab therapy, or low CD4 count [19–21]. Therefore, JC virus should be considered in the differential diagnosis of a neutropenic cancer patient with progressively worsening neurologic symptoms.

Fungal Pathogens

Profound neutropenia and use of total parenteral nutrition have been shown to be risk factors for the development of *Candida* meningitis in children with malignancies [22]. Other risk factors include preceding fungemia, presence of intra-vascular catheter, or a CNS device. *Candida* meningitis can also be a result of disseminated candidiasis.

Neutropenic cancer patients are at increased risk for mold infections. *Aspergillus*, *Zygomycetes*, and *Fusarium spp.* are well-recognized causes of a brain abscess in cancer patients, however, the incidence of an isolated mold meningitis is low [23].

Patients with hematologic malignancies have a higher risk for *Cryptococcus* meningitis [24], however, this is still rare in neutropenic patients.

Clinical Presentation

In those with severely altered immunity and profound neutropenia, symptoms of meningitis/encephalitis can be very subtle, therefore, a high index of suspicion is required to pursue and diagnose these conditions [3, 4]. Based on a prior study by Safdieh et al., only 5% of cancer patients had a classic triad of fever, nuchal rigidity, and altered mental status on presentation [4]. Encephalitis symptoms commonly include altered mentation, confusion, headaches, visual disturbances, focal neurological deficits or seizures.

Laboratory Diagnosis and Imaging

If meningitis or encephalitis is suspected in an immunocompromised host, neuroimaging should be performed as a first step to rule out any focal structural brain abnormalities [3, 25]. Brain CT scan or, if readily available, brain MRI with and without contrast should be performed as soon as possible.

Some MRI findings can highlight clues for specific pathogens. *Listeria monocytogenes* occasionally can cause rhomboencephalitis (inflammation of the brainstem and/or cerebellum). Temporal lobe changes can be seen with HSV, VZV, and HHV6. EBV can cause changes in the caudate nuclei, basal ganglia, thalami, and cortex. CMV as well as HHV6 typically causes ventriculoencephalitis with periventricular enhancement. WNV classically causes changes in the basal ganglia, thalami, and cerebellum, and lastly, JC virus causes multifocal areas of white matter demyelination. (Table 2).

Table 2 Neuroimaging

Organism	Findings
<i>Listeria monocytogenes</i>	Rhomboencephalitis
HSV, VZV, HHV6	Temporal lobe changes
EBV	Caudate nuclei, basal ganglia, thalami, and cortex changes
CMV	Periventricular enhancement
WNV	Basal ganglia, thalami, and cerebellum changes
JC Virus	Multifocal areas of white matter demyelination

Once a space-occupying brain lesion causing brain herniation or a midline shift is ruled out, cerebro-spinal fluid (CSF) analysis should be performed. Blood cultures should be collected as soon as possible and prior to administration of antimicrobial agents if bacterial meningitis is suspected.

During the lumbar puncture, opening pressure should be measured and CSF analysis should be submitted for cell count and differential, cytology, glucose and protein levels. Stains and cultures for bacterial, fungal, and acid-fast organisms should be submitted to the microbiology lab [25, 26]. Currently, most centers have meningitis/encephalitis panels by PCR which is highly sensitive for the detection of common bacterial, viral, and fungal pathogens that cause meningitis and/or encephalitis [27, 28]. However, this test is costly and may not be available in some centers.

CSF pleocytosis is typically seen in cases of acute bacterial meningitis; however, CSF white blood cell count can be either normal or marginally elevated in neutropenic patients [4]. Low CSF glucose and elevated protein are typical findings that are seen in patients with acute bacterial meningitis. The diagnostic yield of Gram-stained smears was shown to be lower in cancer patients compared to the general population [6]. The yield is also lower in patients that have received prior antibiotic therapy [25].

Treatment

If bacterial meningitis is suspected, empiric antimicrobial therapy should be initiated as soon as possible after initial imaging, blood cultures, and CSF studies have been obtained. Antibiotics administration must not be delayed as these infections are associated with high morbidity and mortality [29, 30].

The initial antibiotic regimen in neutropenic cancer patients should cover pathogens seen in the general population with acute bacterial meningitis in addition to methicillin resistant *Staphylococcus aureus* (MRSA) and *Pseudomonas aeruginosa*. Expanded antimicrobial coverage is necessary due to frequently present indwelling devices such as central lines and internalized/externalized CNS shunts. Selected antibiotics must penetrate CNS and achieve an adequate CNS concentration [31]. Third generation cephalosporins such as cefepime or ceftazidime or a carbapenem with anti-pseudomonal activity (such as meropenem or imipenem) plus an anti-MRSA agent are used for the initial therapy [3]. Aztreonam or Ciprofloxacin can be used as an alternative agent in patients with a documented penicillin allergy.

Coverage against *Listeria monocytogenes* should be included with the initial regimen in neutropenic cancer patients that reside in the community and/or have specific risk factors (neutropenia, organ transplant, old age, chronic steroids, pregnant, ingestion of unpasteurized milk or cheese) and clinical presentation concerning for *Listeria* meningitis. Ampicillin or Penicillin G are considered the most active drugs against *Listeria*; Bactrim or Meropenem can be used as alternatives [3, 25].

Table 3 Treatment of viral encephalitis

Virus	Treatment
HSV, VZV	Acyclovir
CMV, HHV6	Gancyclovir/foscarnet
EBV	No specific treatment
WNV	No specific treatment
JC virus	Reversal of immunosuppression if possible

Intravenous acyclovir should be added if there is a concern for HSV encephalitis based on the initial presentation. Gancyclovir or foscarnet can be used to treat CMV or HHV6 encephalitis (Table 3).

Lack of clearance of enterovirus meningitis in lymphoma patients may require the use of intravenous immunoglobulin [32].

Brain Abscess

Patients with neutropenia are at an increased risk for developing a brain abscess [33]. In this patient population, hematogenous spread from other infection sites or a contiguous spread from adjacent structures (face, sinuses, middle ear, teeth) are the most common mechanisms of development of a brain abscess [33]. Cancer patients with history of recent neurosurgeries or CNS catheters such as ventriculo-peritoneal shunts are at increased risk for the development of brain abscess as well [33].

Microbiology

Bacterial Pathogens

The microbiology of the brain abscess differs based on the mechanism of infection acquisition. In patients with neutropenia, gram-negative organisms including Enterobacteriaceae and *Pseudomonas aeruginosa* as well as fungal pathogens are the most important pathogens to be considered [33, 34] (Table 4). Other pathogens such as *Staphylococcus aureus*, streptococci, and anaerobes are also common, especially with hematogenous or contiguous infection spread [33, 35]. If the abscess results from penetrating trauma, *S. aureus*, *S. epidermidis*, Enterobacteriaceae, and Clostridium species may be the culprit [33]. Polymicrobial infections are commonly seen in the general patient population [35] but would be less common in neutropenic patients. Infections with rare bacterial pathogens such as *Nocardia* or *Actinomyces* spp. are likely to be more common in cancer patients especially while on chronic steroids. *Listeria* as an etiology of a brain abscess should be considered in chronically neutropenic patients that reside in the community.

Table 4 Brain abscess

Bacteria	Fungi
<i>Streptococcus spp</i>	<i>Candida spp</i>
<i>Staphylococcus aureus</i>	<i>Aspergillus spp</i>
Anaerobes	<i>Mucorales spp</i>
Enterobacteriaceae	<i>Scedosporium spp</i>
<i>Pseudomonas</i>	<i>Fusarium spp</i>
<i>Nocardia spp</i>	Dematiaceous fungi

Fungal Pathogens

A high incidence of a fungal brain abscess is reported in neutropenic patients with hematologic malignancies [34]. Most of these infections are acquired through a continuous spread from mold sinusitis causing angioinvasion to the CNS, or from hematogenous spread of the infection from a distal site. Based on the prior studies, *Aspergillus* as well as *Mucorales spp* account for the majority of these infections [34, 36]. Other fungal pathogens such as *Candida spp*, *Scedosporium spp*, *Fusarium spp*, and dematiaceous molds have been reported as well [33, 34, 37] (Table 4).

Clinical Presentation

Patients typically present with headache, fever, focal neurological deficits, seizures, and/or altered mental status. Acute rupture of the abscess into the ventricles may cause meningeal signs. Herniation may occur if intracranial pressure is increased. The presence of coma at the time of presentation is associated with increased mortality.

Laboratory Diagnosis and Imaging

MRI of the brain is the preferred diagnostic modality for the diagnosis of a brain abscess and is considered more sensitive and specific compared to other imaging modalities such as brain CT scan [3, 38]. It typically appears as a single ring enhancing lesion on imaging.

Aspiration of the brain abscess via a stereotactic needle biopsy is frequently needed to establish the causative organism and rule out other potential etiologies such as malignancy [3]. However, when a brain biopsy cannot be obtained or surgery cannot be performed, positive blood cultures and/or identification of an extra neural site of infection may aid the diagnosis. Lumbar puncture might be of low utility in this patient population as it frequently cannot be performed due to concomitant thrombocytopenia. Furthermore, the procedure may increase the risk of herniation when a space-occupying lesion is present.

Treatment

The principles of empiric antimicrobial therapy are similar as described in the “Meningitis/Encephalitis” section. Third generation cephalosporins such as cefepime or ceftazidime or a carbapenem with anti-pseudomonal activity (such as meropenem or imipenem) plus an anti-MRSA agent are used for the initial therapy [3]. Aztreonam or Ciprofloxacin can be used as an alternative agent in patients with a documented penicillin allergy. We recommend addition of anaerobic coverage to the initial antibiotic regimen that could be achieved by addition of metronidazole to a third generation cephalosporin, ciprofloxacin, or Aztreonam.

Coverage for *Listeria monocytogenes* should be included into the initial regimen in neutropenic cancer patients that reside in the community and/or have specific risk factors and clinical presentation concerning for *Listeria* brain abscess. Ampicillin or Penicillin G are considered the most active drugs against *Listeria*; Bactrim or Meropenem can be used as alternatives [3, 25].

Antifungal therapy either with intravenous voriconazole or liposomal amphotericin B should be included in the initial antimicrobial regimen in the patients with suspected brain abscess [3].

If nocardia is suspected, the addition of trimethoprim/sulfamethoxazole plus imipenem should also be included as part of the initial regimen [39].

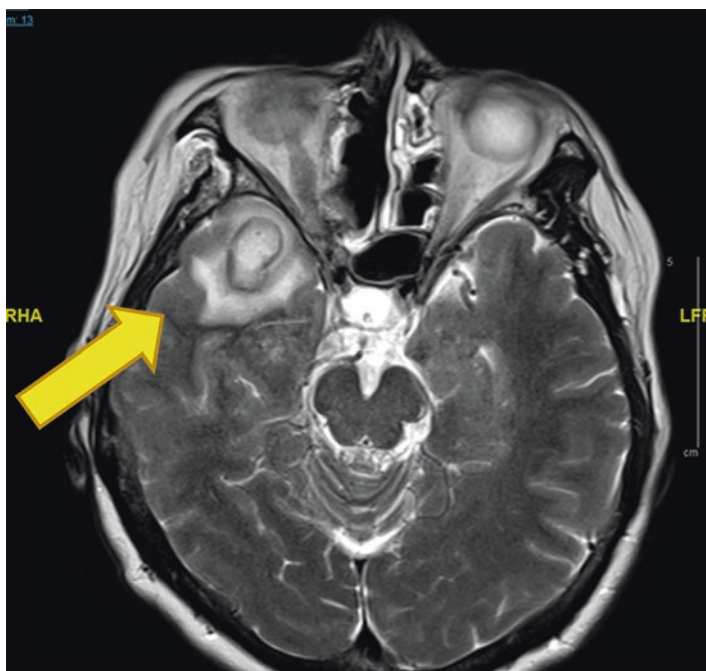


Fig. 1 *Strep intermedius* brain abscess