

CARDIAC MRI
IN THE DIAGNOSIS,
CLINICAL MANAGEMENT
AND PROGNOSIS
OF ARRHYTHMOGENIC
RIGHT VENTRICULAR
CARDIOMYOPATHY/
DYSPLASIA



ELSEVIER *science & technology books*



Companion Web Site:

www.store.elsevier.com/9780128012833

*Cardiac MRI in the Diagnosis, Clinical Management and Prognosis of Arrhythmogenic Right Ventricular
Cardiomyopathy/Dysplasia*
Aiden Abidov, Isabel B. Oliva, Frank I. Marcus, Editors

Available Resources:

Extra content and support files.



TOOLS FOR ALL YOUR TEACHING NEEDS
textbooks.elsevier.com



ACADEMIC
PRESS

To adopt this book for course use, visit <http://textbooks.elsevier.com>.

CARDIAC MRI
IN THE DIAGNOSIS,
CLINICAL MANAGEMENT
AND PROGNOSIS
OF ARRHYTHMOGENIC
RIGHT VENTRICULAR
CARDIOMYOPATHY/
DYSPLASIA

Edited by

AIDEN ABIDOV

ISABEL B. OLIVA

FRANK I. MARCUS

*Department of Medicine/Division of Cardiology
and Department of Medical Imaging,
University of Arizona, Tucson, AZ, USA*



ELSEVIER

AMSTERDAM • BOSTON • HEIDELBERG • LONDON
NEW YORK • OXFORD • PARIS • SAN DIEGO
SAN FRANCISCO • SINGAPORE • SYDNEY • TOKYO

Academic Press is an Imprint of Elsevier



Academic Press is an imprint of Elsevier
125 London Wall, London EC2Y 5AS, UK
525 B Street, Suite 1800, San Diego, CA 92101-4495, USA
50 Hampshire Street, 5th Floor, Cambridge, MA 02139, USA
The Boulevard, Langford Lane, Kidlington, Oxford OX5 1GB, UK

Copyright © 2016 Elsevier Inc. All rights reserved.

No part of this publication may be reproduced or transmitted in any form or by any means, electronic or mechanical, including photocopying, recording, or any information storage and retrieval system, without permission in writing from the publisher. Details on how to seek permission, further information about the Publisher's permissions policies and our arrangements with organizations such as the Copyright Clearance Center and the Copyright Licensing Agency, can be found at our website: www.elsevier.com/permissions.

This book and the individual contributions contained in it are protected under copyright by the Publisher (other than as may be noted herein).

Notices

Knowledge and best practice in this field are constantly changing. As new research and experience broaden our understanding, changes in research methods, professional practices, or medical treatment may become necessary.

Practitioners and researchers must always rely on their own experience and knowledge in evaluating and using any information, methods, compounds, or experiments described herein. In using such information or methods they should be mindful of their own safety and the safety of others, including parties for whom they have a professional responsibility.

To the fullest extent of the law, neither the Publisher nor the authors, contributors, or editors, assume any liability for any injury and/or damage to persons or property as a matter of products liability, negligence or otherwise, or from any use or operation of any methods, products, instructions, or ideas contained in the material herein.

British Library Cataloguing-in-Publication Data

A catalogue record for this book is available from the British Library

Library of Congress Cataloging-in-Publication Data

A catalog record for this book is available from the Library of Congress

ISBN: 978-0-12-801283-3

For information on all Academic Press publications
visit our website at <http://store.elsevier.com/>



Working together
to grow libraries in
developing countries

www.elsevier.com • www.bookaid.org

Publisher: Mica Haley

Acquisition Editor: Stacy Masucci

Editorial Project Manager: Sam W. Young

Production Project Manager: Chris Wortley

Designer: Matthew Limbert

Typeset by Thomson Digital

Printed and bound in United States of America

Dedication

To my dear wife, Yulia: thank you for always being there for me, being my pillar of strength, and supporting me through anything and everything I aspired to achieve.

To my dear kids Elnur, Amir, Meira, and Dan: thank you for always inspiring me and making me strive to be the best dad I could be. I love you all so much.

Aiden Abidov

To my caring husband, Felipe: You are the love of my life! Thank you for your continuous support and love, you make me a better person.

To my little Sophia: You are my life, we love you more than anything in this world.

To my parents, brother, and sister: Thank you for your love and for raising me to be the best I can be. Your successes have always inspired me; I miss you all every day!

Isabel Oliva

To my understanding wife, Janet who has tolerated her workaholic husband for many years.

Frank I. Marcus

Acknowledgment

The authors are indebted to Mrs Yvette M. Barnes, MEd for technical assistance in the preparation and submission of the manuscript.

List of Contributors

Aiden Abidov Department of Medicine/Division of Cardiology and
Department of Medical Imaging, University of Arizona, Tucson, AZ, USA

Cristina Basso Department of Cardiac, Thoracic and Vascular Sciences,
University of Padua Medical School, Padua, Italy

Maarten J. Cramer Department of Cardiology, University Medical Center
Utrecht, Utrecht, The Netherlands

Pieter A. Doevendans Department of Cardiology, University Medical Center
Utrecht, Utrecht, The Netherlands

Arun Kannan Department of Medicine/Division of Cardiology and
Department of Medical Imaging, University of Arizona, Tucson, AZ, USA

Frank I. Marcus Department of Medicine/Division of Cardiology and
Department of Medical Imaging, University of Arizona, Tucson, AZ, USA

Thomas P. Mast Department of Cardiology, University Medical Center Utrecht,
Utrecht, The Netherlands

Luisa Mestroni Cardiovascular Institute, University of Colorado Anschutz
Medical Campus, Aurora, CO, USA

Isabel B. Oliva Department of Medicine/Division of Cardiology and
Department of Medical Imaging, University of Arizona, Tucson, AZ, USA

Ahmed K. Pasha Department of Medicine/Division of Cardiology and
Department of Medical Imaging, University of Arizona, Tucson, AZ, USA

Amit Patel Cardiovascular Institute, University of Colorado Anschutz Medical
Campus, Aurora, CO, USA

Kalliopi Pilichou Department of Cardiac, Thoracic and Vascular Sciences,
University of Padua Medical School, Padua, Italy

Stefania Rizzo Department of Cardiac, Thoracic and Vascular Sciences,
University of Padua Medical School, Padua, Italy

Arco J. Teske Department of Cardiology, University Medical Center Utrecht,
Utrecht, The Netherlands

Gaetano Thiene Department of Cardiac, Thoracic and Vascular Sciences,
University of Padua Medical School, Padua, Italy

Introduction

Frank I. Marcus, Aiden Abidov

Department of Medicine/Division of Cardiology
and Department of Medical Imaging,
University of Arizona, Tucson, AZ, USA

This book aims to evaluate the role of the MRI in the diagnosis, clinical management, and prognosis of arrhythmogenic right ventricular cardiomyopathy/dysplasia (ARVC/D). You may ask “Isn’t this too narrow a focus for this rare disease?” Let us evaluate this concern.

First, ARVC/D is now more frequently diagnosed as it is becoming better known. It is estimated that it occurs in 1:5000 individuals but it may be present in a higher incidence since one may have a pathological gene for this disease yet have little or no clinical manifestations. This is known as a lack of association of genotype and phenotype. Thus, ARVC/D may be a less rare disease than is presently thought. In addition, since it is a cause of sudden cardiac death, particularly in the young, it is important to be able to recognize it in order to prevent this catastrophic event.

Another question is, why should we focus our attention on one imaging modality, the MRI, particularly when this imaging modality is more expensive and less readily available than 2D echocardiography? In contrast to echocardiography, an MRI can provide more accurate quantitative evaluation of the right ventricular function and structure. Specifically, it can accurately access right ventricular ejection fraction as well as segmental wall motion abnormalities of the right ventricle. Based on hundreds of published papers, cardiac MRI is a useful diagnostic imaging modality in patients suspected of having ARVC/D and is particularly valuable since important limitations of MRI (such as the need for breath-holding, inability to scan patients with permanent pacemakers or ICDs, etc.) have largely been overcome. The finding of abnormal right ventricular function or structure by 2D echocardiogram in a patient suspected of having ARVC/D should be confirmed by MRI since the latter is more reliable for the diagnosis. It is also important that the radiologist/cardiologist who is interpreting the MRI should be aware of normal variants of the

right ventricular contractility patterns, particularly that of an apparent bulging of the right ventricular free wall at the insertion of the right ventricular papillary muscle.

Other questions include the age at which ARVC/D is manifest. Should an MRI be done in children who have the genetic abnormality but no clinical manifestation of the disease? How rapidly do the abnormalities of the RV change in this disease? This would determine how frequently the MRI should be reassessed in first-degree relatives who may have no or minimal symptoms.

An important consideration is the increased safety of MRI, especially absence of exposure to ionizing radiation and nephrotoxic iodine contrast. This allows sequential MRI studies in young patients without increased associated risk of imaging. Excellent spatial resolution and safety of cardiac MRI makes it an ideal methodology for follow-up of patients with known or suspected ARVC/D.

Finally, the MRI is useful in differential diagnosis that includes several conditions mimicking ARVC/D, such as cardiac sarcoidosis, left-to-right supraventricular shunts, and myocarditis. Also, in some cases, myocardial-pericardial adhesions can cause abnormal right ventricular wall motion. The use of gadolinium contrast to detect and localize scar/fibrosis in the left or right ventricular myocardium is unique to MRI, as is the ability of cardiac MRI to provide effective tissue characterization, including fibro-fatty infiltration, inflammation, thrombosis, etc.

Recent developments in the field of advanced echocardiography, cardiac CTA, and nuclear cardiology have many interesting applications that could significantly enhance the armamentarium of physicians in the diagnosis and management of ARVC/D. In this book, we included a brief overview of novel non-MRI-based imaging methodologies that are useful in this disease.

In summary, there are many important clinical areas of interest reflecting the role of the MRI and other rapidly developing cardiac imaging methodologies in patients with ARVC/D. In our book, we provide our readers with a convenient overview of these areas.

However, there are three types of problems with cardiac imaging in general, and cardiac MRI in particular for the evaluation of ARVC/D. (Fig. 1.1):

- 1. The problem of ordering the right test for the patient's age and clinical presentation.** Patients with known or suspected ARVC/D are a highly heterogeneous group and include patients with confirmed ARVC/D, asymptomatic gene carriers, and relatives of patients with ARVC/D, as well as patients with suspected or possible ARVC/D. There is significant disagreement about which test should be utilized in these populations, which one is the most effective for screening, and whether the layered testing concept should be considered in the

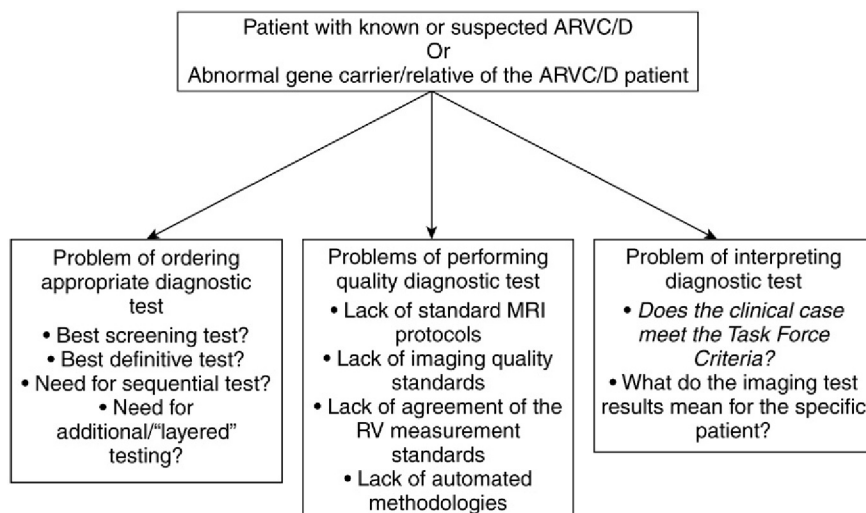


FIGURE 1.1 Problems encountered in evaluation and management of patients with known or suspected ARVC/D.

“borderline” cases. The Modified Task Force criteria focused on the specificity of echo and MRI measurements of ARVC/D and possibly at the expense of sensitivity, particularly of early or clinically “silent” disease cases.

2. **The problem of performing a good-quality diagnostic MRI.** For years, we have been reviewing MRI studies of patients with either known or probable disease performed in imaging laboratories from many centers in the United States and abroad. There is marked variability of the diagnostic quality of these studies. Also, there are many MRI protocols utilized in different centers. Current lack of standardization in MRI protocols for the ARVC/D patients is concerning. There is an urgent need to improve this situation.
3. **The problem of interpreting results of the MRI study.** Even negative results in particular clinical populations may mean just one negative diagnostic criterion among many others that must be considered in such a complex diagnosis as ARVC/D. At times the decision-making process is based completely on the imaging study. A false-negative study can be associated with increased risk, and a false-positive test may dramatically change the patient’s life and have long-lasting consequences both for the patient and for the society. One of these situations we have encountered is implantation of ICDs in young patients who have borderline tests, or tests that are negative but are interpreted as positive even though other diagnostic tests were

not considered. Recently, with the development of genetic testing, interpretation of imaging test results in association with genetic defects in asymptomatic individuals raises important clinical decisions. These patients may be subjected to changes in their occupation, limitations in their athletic activities (such as college sports) and lifestyle even though their anatomic data do not suggest an increased risk.

In this book, we address these problems and provide quick access to evidence-based algorithms and methods utilized currently in the state-of-the-art imaging laboratories. We have utilized an exhaustive literature search, but we also give readers flow diagrams, clinical algorithm schemes, and figures. Easy access to these data may save time and effort in reaching important clinical decisions and utilize an important principle of the modern imaging: “The right test for the right patient.”

This book provides a quick reference to assist with standardization of the imaging protocols, particularly for the practicing imagers and clinicians who may encounter patients with known or suspected ARVC/D. This book is designed to be user friendly. We provide clinical examples as well as online tools and videos to illustrate interesting cases from our practice.

We hope to have the readers’ feedback and maintain online communication with interested clinicians and researchers in order to further enhance the potential of cardiac MRI and other imaging modalities in the diagnosis and management of ARVC/D.

Arrhythmogenic Cardiomyopathy: History and Pathology

Gaetano Thiene, Stefania Rizzo,
Kalliopi Pilichou, Cristina Basso

Department of Cardiac, Thoracic and Vascular Sciences,
University of Padua Medical School, Padua, Italy

INTRODUCTION

Arrhythmogenic right ventricular cardiomyopathy dysplasia (ARVC/D) is a life-threatening entity, which has drawn the attention of the scientific community for the last 30 years since it is a significant cause of premature death [1,2]. Young people, especially athletes, may die suddenly because of abrupt lethal cardiac arrhythmias, namely ventricular fibrillation, precipitated by exercise [3]. The present chapter will deal with some aspects of the disease: history, terminology, biological background, pathology, and morphological criteria for diagnosis, endomyocardial biopsy, and recapitulation of the disease in transgenic mice.

HISTORY

It is a “rediscovered” disease, since its knowledge dates back centuries. The early description belongs to the pathologist Giovanni Maria Lancisi, who first described its heredofamilial peculiarity [4]. In a chapter on hereditary predisposition to cardiac aneurysms and bulgings in his book *De Motu Cordis et Aneurysmatibus* (on the movements of the heart and aneurysms), he reported the history of a family with disease recurrence in four generations, featured by cardiac palpitations and sudden death.

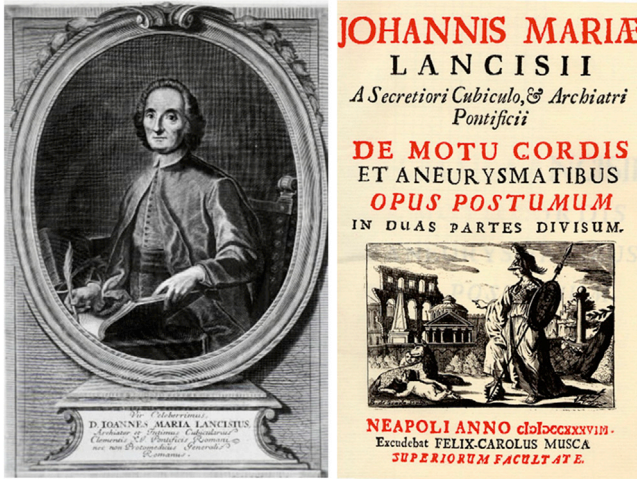

FIGURE 2.1 First historical description of ARVC/D in the book *De Motu Cordis et Aneurysmatibus* published in 1736 by Giovanni Maria Lancisi, Professor of Anatomy in Rome and Pope's Physician. Courtesy of Arnold Katz.

Dilatation and aneurysms of the right ventricle (RV), which filled the right chest, were observed at autopsy (Fig. 2.1).

René Laennec, the French doctor and inventor of the stethoscope, in the book "*De l'auscultation mediate ou traite' du diagnostic des maladies des poumons et du Coeur*" (on the mediated auscultation and treatise of the diagnosis of lung and heart disease) published in 1819, first drew attention to the relationship between fatty tissue in the right ventricle (RV) and sudden death [5]. The walls were described as extremely thin "especially at the apex of the heart and the posterior side of the right ventricle." The risk of sudden death in a fatty heart was confirmed by the protagonist Dr. Lydate in *Middlemarch* of George Eliot in 1871, who, talking to his patient, said, "You are suffering from what is called fatty degeneration of the heart... it is my duty to tell you that death from the disease is often sudden..." [6]. In 1905 William Osler, in his famous treatise "*The Principles and Practice of Medicine*", described a case of a 40-year-old man, who died suddenly while climbing up a hill. The heart showed biventricular massive myocardial atrophy with very thin walls, as to be named "parchment heart" [7]. The specimen is now part of the Abbott collection in Montreal and was reviewed by Segall in 1950 [8].

In 1952, Uhl reported the fatal case of an infant, which has been the source of misconception and controversy [9]. A female infant died at the age of 8 months, with congestive heart failure and at autopsy showed "almost total absence of the myocardium in the right ventricle in the absence of fatty tissue." "Examination of the cut edge of the ventricle wall reveals it to be paper-thin with no myocardium visible...."

The eponym Uhl's anomaly has been employed in adults with parchment RV. It is now also clear that the papyraceous appearance of the ventricular free wall is the end stage of an acquired, genetically determined progressive loss of myocardium, as in the Osler case [10].

The infant reported by Uhl was affected by a cardiac structural defect present at birth and, as such, falls into the category of congenital heart disease. Nonetheless, we cannot exclude that in infants with Uhl's anomaly the myocyte loss might have started during fetal life.

The history of the disease at our university started in the 1960s, when Professor Sergio Dalla Volta, the founder of modern cardiology in Padua with cardiac catheterization, published a series of cases featured haemodynamically by "auricularization of the right ventricular pressure" to underlie the absence of an effective systolic contraction of the RV, when a pressure curve was recorded in the RV similar to that of the right atrium, with the blood pushed from the right atrium directly to the pulmonary artery [11,12]. Thirty years later the heart of one of these patients was studied following cardiac transplantation at the age of 65, and had a parchment RV with an almost intact left ventricle [2].

In 1978, the late Professor Vito Terribile of our institute performed an autopsy of a woman with a history of palpitations and congestive heart failure, who died of pulmonary thromboembolism. The heart showed dilatation of the RV with mural thrombosis, "adipositas cordis" even at the posterior wall and apex (like the Laennec description), and "myocardial sclerosis of the left ventricle" in the absence of coronary artery disease, in keeping with what we now call biventricular arrhythmogenic cardiomyopathy.

The arrhythmic propensity of this substrate was first discovered in the 1970s by Guy Fontaine who demonstrated that life-threatening ventricular tachyarrhythmias with left bundle branch block morphology can originate from the RV [13]. The basal ECG may show delayed depolarization with an epsilon wave at the end of the QRS complex, which he named post-excitation syndrome. This differs from the pre-excitation syndrome (Wolff-Parkinson-White syndrome) with delta wave preceding the QRS complex.

In the 1980s, Marcus and Fontaine [14] reported a series of adult patients with this disease presenting with ventricular arrhythmias with left bundle branch block morphology. Microscopic examination of myocardial samples, removed at surgical disconnection of the right from the left ventricle, disclosed fibrofatty replacement that the authors interpreted as a maldevelopmental defect, and called the disease "right ventricular dysplasia." The term was then replaced by cardiomyopathy in the WHO nomenclature and classification of heart muscle disease [15].

The study of Marcus et al. was limited to adult patients and the ventricular arrhythmias of RV origin that were neither considered malignant nor interpreted as an inherited disease [14].

Meanwhile knowledge of the disease made progress in Padua, thanks to Andrea Nava, a true pioneer in the field of cardiovascular clinical genetics. He realized the genetic inheritance of the disease with a Mendelian dominant transmission, introducing the concept of “genetically determined cardiomyopathy,” since he showed the onset of the phenotype in childhood [16,17].

Thiene et al. [3] first draw the attention to the malignant aspect of the disease, presenting in youths with sudden death, even as its first manifestation. By collecting and studying all the cases of juvenile sudden death (<35 years) occurring in the Veneto region, Italy (nearly 5 million inhabitants), they showed that ARVC/D is a leading cause of sudden death in young athletes (Fig. 2.2). The subjects had inverted T waves in right precordial leads and apparently benign premature ventricular beats with left bundle branch block morphology in the ECG, which is compulsory in Italy for sports eligibility. In other words, it was demonstrated that the

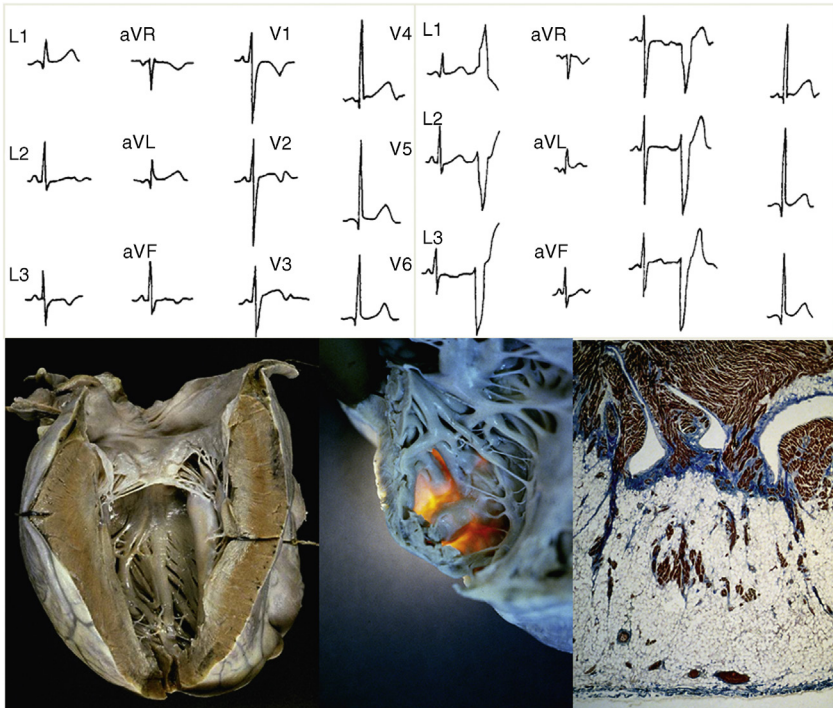


FIGURE 2.2 A 30-year-old athlete who died suddenly during a soccer game and included in the original series published in 1988: note the inverted T waves in the right precordial leads. At postmortem, the left ventricle was normal, whereas the right ventricle showed fibrofatty replacement of the free wall with inferior aneurysm. *Modified from Ref. [1].*