

Antibiotic and Antifungal Therapies in Dermatology

Jón Hjaltalín Ólafsson
Roderick James Hay
Editors

 Springer

Antibiotic and Antifungal Therapies in Dermatology

Jón Hjaltalín Ólafsson • Roderick James Hay
Editors

Antibiotic and Antifungal Therapies in Dermatology

 Springer

Editors

Jón Hjaltalín Ólafsson
Department of Dermatology and Venereology
University of Iceland, (Hudlaeknastodin
Dermatology Clinic)
Kopavogur
Iceland

Roderick James Hay
Cutaneous Infection Clinic, Dermatology
Kings College Hospital NHS Trust
London
UK

ISBN 978-3-319-39422-0

ISBN 978-3-319-39424-4 (eBook)

DOI 10.1007/978-3-319-39424-4

Library of Congress Control Number: 2016954981

© Springer International Publishing Switzerland 2016

This work is subject to copyright. All rights are reserved by the Publisher, whether the whole or part of the material is concerned, specifically the rights of translation, reprinting, reuse of illustrations, recitation, broadcasting, reproduction on microfilms or in any other physical way, and transmission or information storage and retrieval, electronic adaptation, computer software, or by similar or dissimilar methodology now known or hereafter developed.

The use of general descriptive names, registered names, trademarks, service marks, etc. in this publication does not imply, even in the absence of a specific statement, that such names are exempt from the relevant protective laws and regulations and therefore free for general use.

The publisher, the authors and the editors are safe to assume that the advice and information in this book are believed to be true and accurate at the date of publication. Neither the publisher nor the authors or the editors give a warranty, express or implied, with respect to the material contained herein or for any errors or omissions that may have been made.

Printed on acid-free paper

This Springer imprint is published by Springer Nature
The registered company is Springer International Publishing AG Switzerland

Preface

This book deals with the treatment of skin infections as well as those skin diseases that are treated with antibiotics and antifungals.

Infective skin diseases can often be difficult to diagnose whereas in other instances the treatment is the problem. In addition some diseases that are rare where the reader lives, may be common and easy to diagnose and treat for colleagues living in another part of the world.

The purpose of this book has been to make those who practice dermatology and venereology aware of skin infections and their treatment, including those that may be unfamiliar in everyday practice. A further aim was to present details of treatments for both rare and common infectious skin diseases that included the latest therapeutic advances. We have deliberately avoided discussion of viral skin diseases as well as most parasitic skin diseases, believing that these merit separate attention.

Kopavogur, Iceland
London, UK

Jón Hjaltalín Ólafsson, MD PhD
Roderick James Hay, DM, FRCP

Contents

1	Common Skin Bacterial Infections	1
	S. Ingen-Housz-Oro, P. Del Giudice, and O. Chosidow	
2	Antibiotics in the Management of Acne	21
	Alison M. Layton	
3	Antimicrobial Treatment of Rosacea	41
	Christos C. Zouboulis, Martin Schaller, and Harald P. M. Gollnick	
4	Venereal Disease I: Syphilis	57
	Erwin Tschachler and George-Sorin Tiplica	
5	Venereal Disease II: <i>Chlamydia trachomatis</i> Infection, Gonorrhoea	69
	George-Sorin Tiplica and Erwin Tschachler	
6	Mycobacterial (Skin) Infections	81
	Bernard Naafs, Colette L.M. van Hees, and Jakko van Ingen	
7	The Antifungal Drugs Used in Skin Disease	141
	Bárður Sigurgeirsson and Roderick J. Hay	
8	Fungal Infections of the Skin	157
	Roderick J. Hay	
9	Fungal Infections of the Hair	187
	Roderick J. Hay	
10	Onychomycosis	203
	Bárður Sigurgeirsson	
11	Cutaneous Leishmaniasis	291
	Colette L.M. van Hees and Ben Naafs	
	Index	339

Chapter 1

Common Skin Bacterial Infections

S. Ingen-Housz-Oro, P. Del Giudice, and O. Chosidow

1.1 Background

1.1.1 Definition

Common skin bacterial infections are very frequent in daily dermatological practice. Superficial pyodermas, characterized by involvement of the epidermis, the upper dermis, and the superficial part of the adnexal structures (hair follicles and nails) [1], include impetigo and impetiginization of dermatoses, folliculitis, furuncles and furunculosis, carbuncle, and suppurative paronychia. Other common skin infections are erythrasma, involving the upper epidermis, primary abscesses, and erysipelas, involving the deep dermis and the hypodermis.

S. Ingen-Housz-Oro
Dermatology Department, AP-HP, Henri Mondor Hospital, Créteil, France
e-mail: saskia.oro@aphp.fr

P. Del Giudice
Unit of Dermatology and Infectiology, Centre Hospitalier Intercommunal Fréjus Saint Raphaël, Fréjus, France

O. Chosidow (✉)
Dermatology Department, AP-HP, Henri Mondor Hospital, Créteil, France
INSERM, Centre d'Investigation Clinique 1430, APHP, Créteil, France
Université Paris Est Créteil Val de Marne UPEC, Créteil, France
e-mail: olivier.chosidow@aphp.fr

1.1.2 Bacteriology

Staphylococcus aureus is the main pathogen involved in these infections, group A hemolytic *Streptococcus* being the second in frequency [2].

In contrast with the normal cutaneous flora residing on the superficial epidermal layers and pilotropic adnexa, mainly comprising *Staphylococcus epidermidis* and gram-positive rods such as *corynebacteria* and *Propionibacterium acnes*, *Staphylococcus aureus* is not a permanent part of the normal skin flora but colonizes inflamed skin (psoriasis, atopic dermatitis, cutaneous lymphoma, bullous diseases, erythroderma) [3–5]. *S. aureus* may also colonize the newborn's umbilicus for several weeks after birth.

However, 20–60% of normal individuals have a persistent or intermittent nasal carriage of *S. aureus*, depending on bacterial adherence and host factors [6]. Other sites of carriage are the perineum, axillary folds, and umbilicus. Nasal carriage is mostly a risk factor for chronic or recurrent furuncles (furunculosis) [7].

Important advances concerning *S. aureus* virulence mechanisms have been made over last decades. For instance Pantone-Valentine leukocidin (PVL), carried by methicillin-sensitive or methicillin-resistant *S. aureus*, is responsible for necrosis and apoptosis of neutrophils and is thus frequently involved in the pathogenesis of follicular infections and abscesses [8–10].

It has also been shown that *S. aureus* produces exfoliative toxins responsible for blistering bacterial infections such as bullous impetigo [7] and staphylococcal scalded skin syndrome (SSSS) by cleaving the cell adhesion cadherin desmoglein 1, which plays an important role in the barrier function of the upper epidermal layers [11, 12].

The emergence of community-acquired methicillin-resistant *S. aureus* (CA-MRSA) must also be considered today. Since the emergence of MRSA as a nosocomial agent during the 1960s, several clones have spread out of hospitals and health-care facilities: (1) health-care-associated MRSA clones, responsible for infections in patients with risk factors such as recently hospitalized patients, patients with chronic diseases, and drug abusers, and (2) true de novo community producing PVL, responsible for cutaneous or, less frequently, necrotizing pulmonary infections in patients without any risk factors and being now a true public health problem worldwide [13–16].

Group A hemolytic *Streptococcus* (*S. pyogenes* A, C, G) is present in the mouth in 10% of the population, periorificial regions but skin carriage in normal individuals is rare. M proteins, pyrogenic and erythrogenic SPE exotoxins and streptolysin are the main virulence factors of the bacteria [17, 18].

The current increasing resistance of *S. pyogenes* to macrolides must be taken in account in some countries but is being better controlled by a lower use of antibiotics [19–21]. However, there is no resistance to penicillin, and clindamycin and pristinamycin (if available) which remain good alternatives in case of allergy to penicillin [22, 23].

1.2 Impetigo

1.2.1 Definition

Impetigo is a contagious primary infection of the skin, involving the stratum corneum, due to *S. aureus*, less frequently *S. pyogenes*, or both. It is particularly common in children and disadvantaged areas. Self-inoculation and small family or communities outbreaks are frequent.

Two types of clinical form are described: (1) crusted impetigo is due to *S. aureus* or *S. pyogenes*, and (2) bullous impetigo is due to the cleavage of very superficial epidermal layers by staphylococcal toxins (exfoliatins) and can be either disseminated (SSSS) or more limited. However, in general practice, both bacteria should be considered when prescribing treatment because bacteriological sampling is often not performed or feasible in general practice unless there is a specific epidemiological context or resistance to classical treatment.

1.2.2 Clinical Presentation

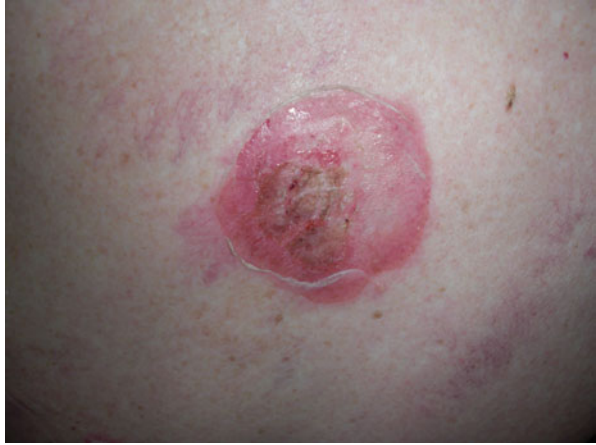
The diagnosis is based on clinical examination. Early lesions are isolated or confluent and polycyclic vesicles or blisters, followed by erosions and yellowish crusts (“honey-colored”) (Figs. 1.1 and 1.2).

Typical location in children is around orifices, especially the mouth, but all areas of the skin may be affected. There are usually no systemic symptoms such as fever, although there may be local lymphadenopathy.

Ecthyma, more frequent in patients with poor hygiene, is a necrotic complication of streptococcal impetigo, clinically characterized by deep dermal ulcerations.

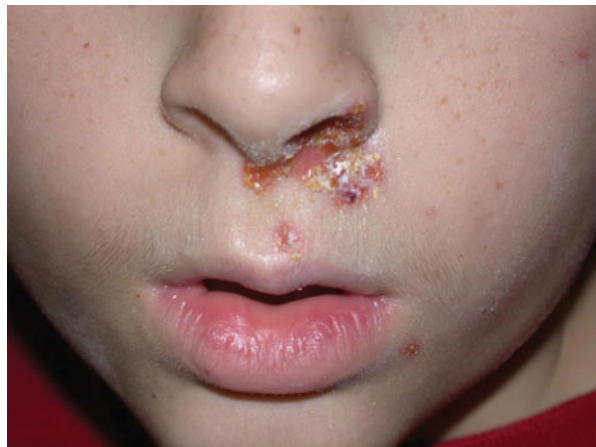

Fig. 1.1 Periorificial crusted impetigo

Fig. 1.2 Bullous impetigo

1.2.3 Prognosis

Without treatment, impetigo usually resolves without sequelae within 2 weeks.

Although systemic complications of childhood impetigo are rare today, infectious or post-infectious glomerulonephritis may occur after extensive, chronic, and/or neglected streptococcal or staphylococcal superficial pyodermas in patients with risk factors such as alcoholism, diabetes mellitus, or drug abuse [24]. Furthermore, glomerulonephritis is a major complication of scabies-related streptococcal impetigo in resource-poor countries [25]. In contrast, rheumatic fever does not complicate impetigo except possibly in tropical areas in association with scabies. Other rare complications include sepsis, osteomyelitis, arthritis, endocarditis, lymphangitis, erysipelas, guttate psoriasis, and SSSS [26].

1.2.4 Treatment

Improving personal hygiene with daily showers, washing hands, brushing nails, and frequent change of clothes is important. Washing lesions with soap and water or topical antiseptics (povidone-iodine, chlorhexidine, hexamidine, Dakin's solution) is usually sufficient for very limited lesions. However, topical antibiotics are widely recommended and may be the treatment of choice for impetigo of limited extent (one site and/or five to ten lesions) [27]. Topical fusidic acid and mupirocin have a comparable effectiveness and are as effective as oral flucloxacillin [28, 29]. Furthermore, moisturizing ointments are useful to remove crusts and enhance healing.

With more extensive lesions, systemic antibiotics against both *S. aureus* and *S. pyogenes* are recommended: penicillin M (oxacillin or rather cloxacillin for better oral route bioavailability), amoxicillin-clavulanic acid, first or second generation cephalosporin, fusidic acid, or pristinamycin [30]. Given the emerging resistance of

S. aureus and *S. pyogenes*, macrolides (except erythromycin because of its effect on QT interval [31]) should only be used as a second line where there is intolerance or allergy to beta-lactams [32].

1.3 Folliculitis, Furuncle, Chronic Furunculosis, and Carbuncle

1.3.1 Definition

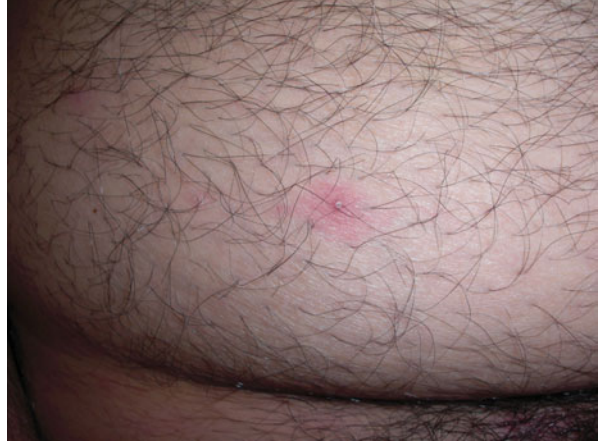Folliculitis and furuncles, the most common forms of skin infection, are acute hair follicle infections (infection of the ostium or follicular opening in superficial folliculitis or infection of the entire hair follicle in furuncles), due to *S. aureus* including strains secreting PVL. In the case of superficial folliculitis, other strains of *Staphylococcus*, or other microorganisms such as *Candida albicans*, may be involved. Apart from climatic factors such as humidity or heat, folliculitis and furuncles are more frequent in patients with immunosuppression, diabetes mellitus, long-term antibiotic use, obesity, occlusive clothes, or recurrent shaving, especially in pubic area. Chronic furunculosis is mainly associated with nasal carriage of *S. aureus* [10, 33]. We have recently seen several patients with *Enterobacter aerogenes* folliculitis acquired after spa baths.

Gram-negative folliculitis, especially folliculitis due to *Pseudomonas*, has been described since the late 1970s as case reports or outbreaks in swimming pools, whirlpools, hot tubs, spa, and recently rubber gloves with an incubation period of from 2 to 5 days [34–36].

In patients with acne in whom treatment with tetracyclines has not shown a significant improvement after 3–6 months, a gram-negative infection should be considered and investigated if possible. The gram-negative bacteria include *Escherichia coli*, *Pseudomonas aeruginosa*, *Serratia marcescens*, *Klebsiella*, and *Proteus mirabilis* [37].

1.3.2 Clinical Presentation

- *Folliculitis* is characterized by scattered or extensive follicular pustules surrounded by a macular or papular erythema, mainly located on thighs, buttocks, back, and beard (Fig. 1.3).
- *Pseudofolliculitis (pili incarnati)* results from the penetration into the skin of shaved hairs within follicles. This condition [38] affects people with curly hair. Papules and pustules may lead to discomfort and small scars or postinflammatory hyperpigmentation.
- *Furuncle (boil)* is the consequence of an acute and sometimes necrotic PVL-positive staphylococcal infection of the entire hair follicle and presents as an

Fig. 1.3 Folliculitis

inflammatory papule then a painful nodule with a central follicular pustule, evolving after a few days leading to spontaneous necrosis and suppuration with discharge of a necrotic core then a permanent scar. Lesions may be single or multiple, involving the face, buttocks, arms, thighs, and anogenital area. There is seldom fever and systemic complications are quite rare. However, with facial furuncles, cavernous sinus thrombosis may constitute a dangerous complication [39].

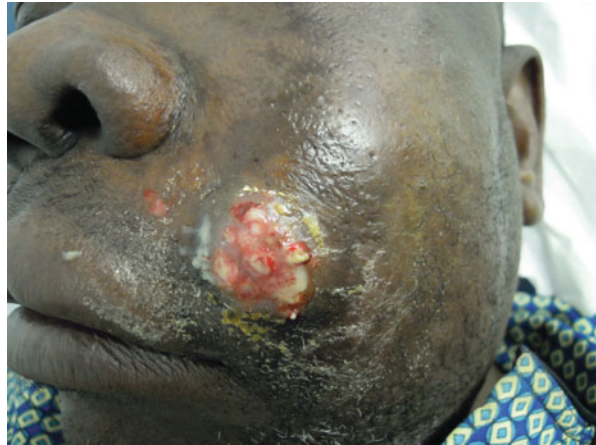- *Chronic furunculosis* is the recurrence of furuncles over a number of months and is, favored by obesity, diabetes mellitus, immunodepression, iron deficiency, alcoholism, and malnutrition. However, staphylococcal nasal carriage and exposure to an infected family member are the main risk factors, and antiseptic decontamination is most important in order to avoid recurrences [40–42].
- *Carbuncles* are the aggregation of furuncles and form broad, swollen, painful, and often fluctuant nodules and deep masses with spontaneous multiple drainage tracts. Patients are often febrile may be unwell [43] (Fig. 1.4).

1.3.3 Treatment

1.3.3.1 Superficial Folliculitis

Any external causal agent should be removed or controlled if appropriate. Cleaning with water and soap and/or antiseptics, with a broad antimicrobial activity [44], is effective in most cases. Topical antibiotics such as mupirocin or fusidic acid are usually effective twice a day for 5–7 days with a low rate of resistance but are not always prescribed. Systemic antistaphylococcal antibiotics are recommended in more severe cases defined as extensive, persistent, and/or recurrent lesions, after bacteriological sampling [27, 29, 45].

Fig. 1.4 Carbuncle of the face



1.3.3.2 Pseudofolliculitis

In the acute phase, shaving should be stopped for several weeks until improvement, and local treatments such as topic erythromycin or fusidic acid, antiseptics or tretinoin may be useful [46]. Shaving must subsequently be performed with individual adjustment, for example, electric razors preferentially over manual razors for beard folliculitis. Hair should be left 1 mm long. Hair removal with chemical depilatories may be effective, and laser, with or without eflornithine hydrochloride, could provide long-term remission, especially for beard folliculitis in patients with dark skin [46–49].

1.3.3.3 Gram-Negative Folliculitis

Lesions usually cure either spontaneously or with antiseptics such as acetic acid, chlorhexidine, povidone, and potassium permanganate within a few days. Silver sulfadiazine cream may also be useful, but other topical anti-gram-negative antibiotics such as polymyxin are disappointing.

Prevention is based on adequate maintenance of bathing facilities, chlorine level, and disinfecting procedures of public equipments [34].

The best treatment of tetracycline-induced gram-negative folliculitis occurring during the course of acne is isotretinoin [50].

1.3.3.4 Furuncles and Carbuncles

Systemic antistaphylococcal antibiotics such as penicillin M (oxacillin, cloxacillin, flucloxacillin) should be prescribed for 5–7 days [51], associated with topical antibiotics applied on the lesion and the surrounding skin. Occlusive clothes must be

avoided. Hygiene measures should be reinforced (hand washing, nail brushing, repeated showers with soap and/or antiseptics).

In case of recurrences, an underlying condition must be sought (staphylococcal nasal and extranasal carriage in the patient and his household members, diabetes, immunodepression, etc.) and treated (see below). Nasal carriage is found in 60% of patients with recurrent furunculosis [40].

Carbuncles require the same antibiotics approach as furuncles associated with surgical excision [52].

1.3.3.5 Staphylococcal Carriage

Due to the risk of spreading in the close environment of the patient, staphylococcal carriage must be sought and treated in the patient and his family but is not definitive, with progressive recolonization within 6 months [53, 54]. Prevention of the bacterial spread in the family or close contact persons (sportsmen [55]), especially in case of CA-MRSA, is based on hygiene, no sharing of personal clothes, and regular hand washing. Carriage decontamination procedures, based on antiseptics as chlorhexidine baths or showers associated with prolonged and intermittent topical antibiotics as mupirocin or fusidic acid [41, 56–58], remain unproven and have been mainly studied for MRSA in health-care facilities [42, 59–61].

1.4 Abscesses

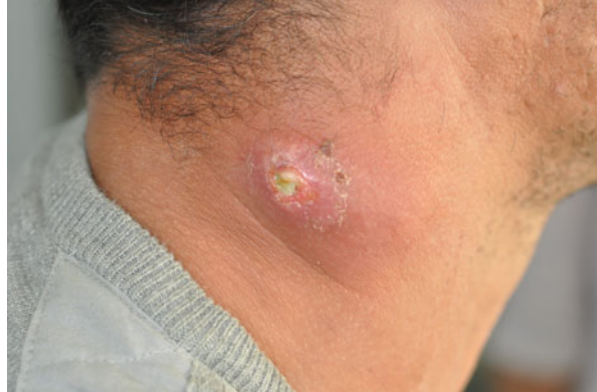1.4.1 Definition and Clinical Presentation

An abscess is a collection of pus. It is not clear in the literature which size of collection can define an abscess, but some consider 2 cm diameter as the lower limit for defining an abscess [62]. The abscess forms a nodule or painful and inflammatory erythematous plaque. After a few days of development, palpation reveals a soft consistency indicating a purulent collection (Fig. 1.5).

Fever is rare, and lymphangitis and satellite nodes may be experienced. The majority of primary or spontaneous abscesses are caused by *S. aureus* producing Panton-Valentine leukocidin [63]. Secondary abscesses (accidental direct inoculation, addiction, septic injections, etc.) are most often due to *S. aureus* but not exclusively. The bacteriological analysis allows the identification of the bacteria. There is worldwide an emergence of *S. aureus* resistant in the community (CA-MRSA) responsible for suppurative infections including abscesses [64, 65].

1.4.2 Treatment

The first treatment is surgery, incision, and drainage [64, 65]. The benefit of antibiotic therapy is low. The Infectious Diseases Society of America (IDSA) recommends systemic antibiotics in the following cases: “critical” location

Fig. 1.5 Abscess of the neck

(face for example, etc.), immunosuppression, large volume of the abscess (>5 cm), failure of drainage, extreme age, and the presence of systemic symptoms. In all other cases, antibiotic therapy is not indicated.

1.5 Suppurative Paronychia

1.5.1 Definition

Acute suppurative paronychia is an acute superficial infection or abscesses of the perionychium. Nail biting, finger sucking, aggressive manicuring, and trauma of the nail are the most frequent causes for a portal of entry of the bacteria [66]. *S. aureus* is the most frequent causative agent, followed by *Streptococcus*, *Pseudomonas*, anaerobes, and other microorganisms such as *C. albicans* and herpes. Acrodermatitis continua of Hallopeau is a differential diagnosis [67]. Acute paronychia must be differentiated from chronic paronychia, which is usually nonsuppurative, due to multiple physical external causes and/or *Candida albicans*.

1.5.2 Clinical Presentation

The patient complains of pain and tenderness of the perionychium that appears swollen, purulent, or even fluctuant. The nail coloration and consistency may be altered.

1.5.3 Treatment

If there is no abscess, treatment is based on warm water soaks three times a day and oral antistaphylococcal antibiotics such as amoxicillin-clavulanic acid or clindamycin, also effective on anaerobes, if persistence and after bacteriological