

*Hurwitz*  
CLINICAL  
PEDIATRIC  
DERMATOLOGY

---

*Commissioning Editor:* Claire Bonnett / Russell Gabbedy  
*Development Editor:* Alexandra Mortimer  
*Editorial Assistant:* Kirsten Lowson / Rachael Harrison  
*Project Manager:* Jess Thompson  
*Design:* Kirsteen Wright  
*Illustrator:* Richard Prime  
*Marketing Manager(s) (UK/USA):* Gaynor Jones/ Helena Mutak

FOURTH EDITION

*Hurwitz*  
CLINICAL  
PEDIATRIC  
DERMATOLOGY


A Textbook of Skin Disorders of Childhood and Adolescence

**AMY S. PALLER MD**

Walter J. Hamlin Professor and Chair of  
Dermatology  
Professor of Pediatrics  
Feinberg School of Medicine  
Northwestern University;  
Attending Physician  
Children's Memorial Hospital  
Chicago, Illinois  
USA

**ANTHONY J. MANCINI MD**

Professor of Pediatrics and Dermatology  
Feinberg School of Medicine  
Northwestern University;  
Head, Division of Pediatric Dermatology  
Children's Memorial Hospital  
Chicago, Illinois  
USA



**ELSEVIER**  
SAUNDERS

Edinburgh, London, New York, Oxford, Philadelphia, St Louis, Sydney, Toronto 2011

First edition 1981  
Second edition 1993  
Third edition 2006  
Fourth edition 2011

No part of this publication may be reproduced or transmitted in any form or by any means, electronic or mechanical, including photocopying, recording, or any information storage and retrieval system, without permission in writing from the publisher. Details on how to seek permission, further information about the Publisher's permissions policies and our arrangements with organizations such as the Copyright Clearance Center and the Copyright Licensing Agency, can be found at our website: [www.elsevier.com/permissions](http://www.elsevier.com/permissions).

This book and the individual contributions contained in it are protected under copyright by the Publisher (other than as may be noted herein).

### Notices

Knowledge and best practice in this field are constantly changing. As new research and experience broaden our understanding, changes in research methods, professional practices, or medical treatment may become necessary. Practitioners and researchers must always rely on their own experience and knowledge in evaluating and using any information, methods, compounds, or experiments described herein. In using such information or methods they should be mindful of their own safety and the safety of others, including parties for whom they have a professional responsibility.

With respect to any drug or pharmaceutical products identified, readers are advised to check the most current information provided (i) on procedures featured or (ii) by the manufacturer of each product to be administered, to verify the recommended dose or formula, the method and duration of administration, and contraindications. It is the responsibility of practitioners, relying on their own experience and knowledge of their patients, to make diagnoses, to determine dosages and the best treatment for each individual patient, and to take all appropriate safety precautions.

To the fullest extent of the law, neither the Publisher nor the authors, contributors, or editors, assume any liability for any injury and/or damage to persons or property as a matter of products liability, negligence or otherwise, or from any use or operation of any methods, products, instructions, or ideas contained in the material herein.

### Saunders

#### British Library Cataloguing in Publication Data

Hurwitz's clinical pediatric dermatology : a textbook of skin disorders of childhood and adolescence. – 4th ed.

1. Pediatric dermatology.

I. Paller, Amy. II. Mancini, Anthony J., 1964- III. Hurwitz, Sidney, 1925–Clinical pediatric dermatology. 618.9'25–dc22

ISBN–13: 9781437704129

A catalogue record for this book is available from the British Library

#### Library of Congress Cataloging in Publication Data

A catalog record for this book is available from the Library of Congress

**ELSEVIER** your source for books,  
journals and multimedia  
in the health sciences


[www.elsevierhealth.com](http://www.elsevierhealth.com)

Working together to grow  
libraries in developing countries

[www.elsevier.com](http://www.elsevier.com) | [www.bookaid.org](http://www.bookaid.org) | [www.sabre.org](http://www.sabre.org)

**ELSEVIER** BOOK AID International Sabre Foundation

The  
publisher's  
policy is to use  
paper manufactured  
from sustainable forests



Sidney Hurwitz, MD

# Foreword

After 15 years of practicing pediatrics and at 40 years of age, Dr. Sidney Hurwitz returned to Yale University School of Medicine to pursue a residency in dermatology, and subsequently, to embark upon a career dedicated to the advancement of research, knowledge and treatment of skin disorders in the young. During the next 25 years, Dr. Hurwitz became a legend in pediatric dermatology as Clinical Professor of Pediatrics and Dermatology at Yale University School of Medicine. He was a founder and President of both the Society for Pediatric Dermatology (U.S.) and the International Society of Pediatric Dermatology, and an author of more than 100 articles on childhood skin diseases and two single-authored textbooks, *The Skin and Systemic Disease in Children*, and *Clinical Pediatric Dermatology*, first published in 1981. According to Dr. Hurwitz, the first edition took six years of nights, weekends and holidays, and the second edition four years. He dedicated the texts to his family: wife, Teddy, and three daughters Wendy, Laurie, and Alison.

Dr. Hurwitz died of overwhelming viral pneumonia at the age of 67 in November 1995, during his tenure as Honorary President of the International Society of Pediatric Dermatology. In a tribute to him at their International Congress, it was noted: "Professor Sidney Hurwitz was truly a giant among men – a dedicated and learned physician, an outstanding clinician, a medical pioneer, noted author, exceptional teacher, and superb humanitarian. His contributions to medicine and mankind have left an indelible mark upon the world. He mentored and encouraged younger pediatric dermatologists. He single-authored the textbook *Clinical Pediatric Dermatology*, recognized throughout the world as 'the classic' in our field. He found great joy in the love of his family – and in the love of learning, teaching, writing, and sharing with colleagues. He embraced us all with his ready smile, his warmth, his affection, and his friendship. Sidney Hurwitz was a role model for all of us."

Dr. Amy S. Paller was new to the field of pediatric dermatology when she met Dr. Sidney Hurwitz in 1980. It was Dr. Hurwitz who invited her to give her first lecture at the Society for Pediatric Dermatology meeting in 1983, and he served as President while Dr. Paller was Secretary-Treasurer to the new Section on Pediatric Dermatology of the American Academy of Pediatrics that they co-founded. As a leader in pediatric dermatology, he inspired her research into the knowledge and treatment of difficult and challenging pediatric skin diseases. Dr. Paller became the head of the Division of Pediatric Dermatology at Children's Memorial Hospital in Chicago in 1988, following in the footsteps of her teacher and mentor, Dr. Nancy B. Esterly. She is currently Walter J. Hamlin Professor and Chair of Dermatology and Professor of Pediatrics at Northwestern University. True to the example set by Dr. Hurwitz, she has served as Secretary-Treasurer and then President of the Society for Pediatric Dermatology and President of the Society for

Investigative Dermatology. She has been or is currently a Director for these organizations, as well as the American Academy of Dermatology (AAD), the Women's Dermatological Society, the American Dermatological Association, and the American Board of Dermatology. As both an NIH-funded bench scientist and clinical investigator, in addition to her almost 30 years of practice in pediatric dermatology, Dr. Paller has contributed to the specialty through a busy international and national lectureship schedule and publication of almost 300 papers, 60 chapters, and four textbooks, among them *Clinical Pediatric Dermatology*. In common with Dr. Hurwitz, Dr. Paller relishes her years of working with young pediatric dermatologists. She has been honored for her mentorship skills and has helped to launch the careers of more than 80 pediatric dermatologists.

Dr. Anthony J. Mancini first learned of the field of pediatric dermatology as a fourth year medical student. As a pediatrics intern at Stanford, he was introduced to Dr. Alfred T. Lane, who would become his role model and primary mentor. After completing his dermatology and pediatric dermatology training, Dr. Mancini accepted a position at Children's Memorial Hospital and Northwestern University Feinberg School of Medicine, where he ultimately became Head of the Division of Pediatric Dermatology in 2004. Following in the footsteps of his mentors, he has dedicated his career to pediatric and dermatology education, as well as patient care and clinical research. Dr. Mancini is currently Professor of Pediatrics and Dermatology at Northwestern, where he also directs the pediatric dermatology fellowship program, established in 1983 as the first fellowship program in the county. He is serving his second 5-year term as Secretary-Treasurer of the Society for Pediatric Dermatology, has served as an elected member to the Executive Committee of the Section on Dermatology of the American Academy of Pediatrics (AAP), and has held numerous posts within both the AAP and the AAD. Dr. Mancini, who lectures extensively at the national and international levels, has published over 140 scientific papers, abstracts and chapters, as well as 3 textbooks, including *Clinical Pediatric Dermatology* and the pediatric dermatology guide published by the AAP, for which he serves as Co-Editor. One of his greatest senses of accomplishment is that of mentoring his trainees in the fellowship program, including both U.S.-trained and international fellows who come from abroad, and the pediatric residents at his institution, who have recognized Dr. Mancini with the "Faculty Excellence in Education" award for 12 of the last 15 years. As such, he too embraces Dr. Hurwitz's love of the specialty and his philosophy in the care of children with skin diseases.

It is fitting that Drs. Paller and Mancini, authors of the third and now fourth edition of *Clinical Pediatric Dermatology*, continue to immortalize Dr. Hurwitz's legacy.



Anthony J. Mancini, MD



Amy S. Paller, MD

# Preface

We were truly honored when asked to consider updating *Hurwitz Clinical Pediatric Dermatology*. Dr. Hurwitz was a true icon of our specialty, and one of its founding fathers. Thanks to Dr. Hurwitz, the widely recognizable book sits on many a shelf, and has educated and enlightened pediatricians, dermatologists, family practitioners, medical students, residents, nurses and other allied pediatric care providers for decades. It is our hope that this tradition will continue, and we have made every effort to maintain the practicality, relevance and usability of the text.

What lies between these covers will be familiar, but many additions have been made. The field of pediatric dermatology has exploded during the past decade. The molecular bases for many established skin diseases, as well as syndromes with cutaneous features, have been elucidated. Several new disease and syndrome associations have been recognized and described. The therapeutic armamentarium for cutaneous disease has broadened, with further elucidation of mechanisms of disease and, as a result, several newer classes of drugs available to the clinician. We have strived to maintain a text that is a marriage between cutting edge review and practical clinical application, while keeping the look and flavor of Dr. Hurwitz's first two editions and our third edition, each of them a balance between narrative text, useful tables and enlightening clinical photographs.

Several new features have been added to this fourth edition, including access to the complete fully-searchable contents online, and over 370 new clinical images. We have reorganized our discussion of genetic disorders to include the new classifications of the ichthyoses, epidermolysis bullosa and ectodermal dysplasia, as well as mention of new disorders and our new understanding. We have noted the shift of attention in treating atopic dermatitis to defects in the epidermal barrier, and discussed evolving therapeutic advances for many common childhood skin disorders, from

infantile hemangiomas to head lice. This edition includes many new tables and clinical photographs. The references have been extensively updated, and we have shifted all but some excellent reviews and landmark articles to our companion online edition, to allow for more complete textual content for our readers in the print version.

We are indebted to several individuals, without whom this work would not have been possible. First and foremost, we must thank Dr. Sidney Hurwitz, whose vision, dedication and enthusiasm for the specialty of pediatric dermatology lives on as a legacy in this text, initially published in 1981. To Teddy Hurwitz, his wife, who entrusted to us the ongoing tradition of this awesome project. To Dr. Alvin Jacobs, a "father" of pediatric dermatology who kindled the flame of the specialty in both of us through his teaching at Stanford. To Dr. Nancy B. Esterly, the "mother" of pediatric dermatology, whose superb clinical acumen and patient care made her the perfect role model for another female physician who yearned to follow in her footsteps. And to Dr. Alfred T. Lane, who believed in a young pediatric intern and mentored him through the process of becoming a mentor himself.

To the staff at Elsevier, most notably Claire Bonnett and Alex Mortimer, who worked tirelessly to meet the many demands of two finicky academicians;

To our patients, who continue to educate us on a daily basis and place their trust in us to provide them care;

To the clinicians who referred many of the patients seen in these pages;

To our pediatric dermatology fellow and photographer, Daniela Russi M.D., who contributed enormously through maintaining our photography archival system;

And to our families, whose understanding, sacrifice, support and unconditional love made this entire endeavor possible.



# Dedicated to

---

Our Families:

Etahn	Nicki
Josh	Mallory
Max	Chris
&	Mack
Ben	&
	Alex

whose patience, understanding, support and  
personal sacrifice enabled us to  
complete this project.

And to the memory of

Sidney Hurwitz, MD  
A role model par excellence

# An Overview of Dermatologic Diagnosis

# 1

Accurate diagnosis of cutaneous disease in infants and children is a systematic process that requires careful inspection, evaluation, and some knowledge of dermatologic terminology and morphology to develop a prioritized differential diagnosis. The manifestations of skin disorders in infants and young children often vary from those of the same diseases in older children and adults. The diagnosis may be obscured, for example, by different reaction patterns or a tendency towards easier blister formation. In addition, therapeutic dosages and regimens frequently differ from those of adults, with medications prescribed on a per kilogram (/kg) basis and with liquid formulations.

Nevertheless, the same basic principles that are used to detect disorders affecting viscera apply to the detection of skin disorders. An adequate history should be obtained, a thorough physical examination performed, and, whenever possible, the clinical impression verified by appropriate laboratory studies. The easy visibility of skin lesions all too frequently results in a cursory examination and hasty diagnosis. Instead, the entire skin should be examined routinely and carefully, including the hair, scalp, nails, oral mucosa, anogenital regions, palms, and soles, because visible findings often hold clues to the final diagnosis.

The examination should be conducted in a well-lit room. Although natural daylight is the most effective type of illumination for an examination, fluorescent or incandescent lighting of adequate intensity may be satisfactory. A properly sequenced examination requires initial viewing of the patient at a distance in an effort to establish the overall status of the patient. By this overall evaluation, distribution patterns and clues to the appropriate final diagnosis frequently can be recognized. This initial evaluation is followed by careful scrutiny of primary and subsequent secondary lesions in an effort to discern the characteristic features of the disorder.

Although not always diagnostic, the morphology and configuration of cutaneous lesions are of considerable importance to the classification and diagnosis of cutaneous disease. Unfortunately, a lack of understanding of dermatologic terminology frequently poses a barrier to the description of cutaneous disorders by clinicians who are not dermatologists. Accordingly, a review of dermatologic terms is included here (Table 1.1). The many examples to show primary and secondary skin lesions refer to specific figures in the text that follows.

## Configuration of lesions

A number of dermatologic entities assume *annular*, *circinate*, or *ring* shapes and are interpreted as 'ringworm' or superficial fungal infections. Although tinea is a common annular dermatosis of childhood, other disorders that must be included in the differential diagnosis of ringed lesions include pityriasis rosea, seborrheic dermatitis, nummular eczema, lupus erythematosus, granuloma annulare, psoriasis, erythema multiforme, erythema annulare

centrifugum, erythema migrans, secondary syphilis, sarcoidosis, urticaria, pityriasis alba, tinea versicolor, lupus vulgaris, drug eruptions, and cutaneous T-cell lymphoma.

The terms *arciform* and *arcuate* refer to lesions that assume arc-like configurations. Arciform lesions may be seen in erythema multiforme, urticaria, pityriasis rosea, and bullous dermatosis of childhood.

Lesions that tend to merge are said to be *confluent*. Confluence of lesions is seen in childhood exanthems, *Rhus* dermatitis, erythema multiforme, tinea versicolor and urticaria.

Lesions localized to a dermatome supplied by one or more dorsal ganglia are referred to as *dermatomal*. Herpes zoster occurs in a dermatomal distribution.

*Discoid* is used to describe lesions that are solid, moderately raised, and disc-shaped. The term has largely been applied to discoid lupus erythematosus, in which the discoid lesions usually show atrophy and dyspigmentation.

*Discrete* lesions are individual lesions that tend to remain separated and distinct. *Eczematoid* and *eczematous* are adjectives relating to eczema and suggest inflammation with a tendency to thickening, oozing, vesiculation, and/or crusting.

*Grouping* and *clustering* are characteristic of vesicles of herpes simplex or herpes zoster, insect bites, lymphangioma circumscriptum, contact dermatitis, and bullous dermatosis of childhood.

*Guttate* or drop-like lesions are characteristic of flares of psoriasis in children and adolescents that follow an acute upper respiratory tract infection, usually streptococcal.

*Gyrate* refers to twisted, coiled, or spiral-like lesions, as may be seen in patients with urticaria and erythema annulare centrifugum.

*Iris* or target-like lesions are concentric ringed lesions characteristic of erythema multiforme.

*Keratosis* refers to circumscribed patches of horny thickening, as seen in seborrheic or actinic keratoses, keratosis pilaris, and keratosis follicularis (Darier disease). Keratotic is an adjective pertaining to keratosis and frequently refers to the horny thickening of the skin seen in chronic dermatitis and callus formation.

The *Koebner phenomenon* or *isomorphic response* refers to the appearance of lesions along the site of injury. The linear lesions of warts and molluscum contagiosum, for example, occur from autoinoculation of virus from scratching; those of *Rhus* dermatitis (poison ivy) result from the spread of the plant's oleoresin. Other examples of disorders that show a Koebner phenomenon are psoriasis, lichen planus, lichen nitidus, pityriasis rubra pilaris, and keratosis follicularis (Darier disease).

Lesions in a *linear* or band-like configuration appear in the form of a line or stripe and may be seen in epidermal nevi, Conradi's syndrome, linear morphea, lichen striatus, striae, *Rhus* dermatitis, deep mycoses (sporotrichosis or coccidioidomycosis), incontinentia pigmenti, pigment mosaicism, porokeratosis of Mibelli, or factitial dermatitis.

Table 1.1 Glossary of dermatologic terms

Lesion	Description	Illustration	Examples
<b>Primary lesions</b>			
The term <i>primary</i> refers to the most representative, but not necessarily the earliest, lesions; it is distinguished from the cutaneous features of secondary changes, such as excoriation, eczematization, infection, or results of previous therapy.			
Macule	Flat, circumscribed change of the skin. It may be of any size, although this term is often used for lesions <1 cm. A macule may appear as an area of hypopigmentation or as an area of increased coloration, most commonly brown (hyperpigmented) or red (usually a vascular abnormality). It is usually round, but may be oval or irregular; it may be distinct or may fade into the surrounding area.		Freckle or ephelide (Fig. 11.38); lentigo (Fig. 11.41); flat nevus (Fig. 9.1), and tinea versicolor (Fig. 17.28).
Patch	Flat, circumscribed lesion with color change that is >1 cm in size.		Mongolian spot (Fig. 11.58); port-wine stain (Fig. 12.54); nevus depigmentosus (Fig. 11.21); larger café au lait spot (Figs 11.37, 11.46), and areas of vitiligo (Figs 11.1–11.9).
Papule	Circumscribed, non-vesicular, non-pustular, elevated lesion that measures <1 cm in diameter. The greatest mass is above the surface of the skin. When viewed in profile it may be flat-topped, dome-shaped, acuminate (tapering to a point), digitate (finger-like), smooth, eroded, or ulcerated; it may be covered by scales, crusts, or a combination of secondary features.		Elevated nevus (Fig. 9.2); verruca (Fig. 15.18); molluscum contagiosum (Fig. 15.37); perioral dermatitis (Fig. 8.21), and individual lesions of lichen planus (Fig. 4.39).
Plaque	Broad, elevated, disk-shaped lesion that occupies an area of >1 cm. It is frequently formed by a confluence of papules.		Psoriasis (Fig. 4.4); lichen simplex chronicus (neurodermatitis) (Fig. 3.33); granuloma annulare (Fig. 9.51); nevus sebaceus (Figs 9.34–9.37), and lesions of lichen planus (Fig. 4.42).

Table 1.1 Continued

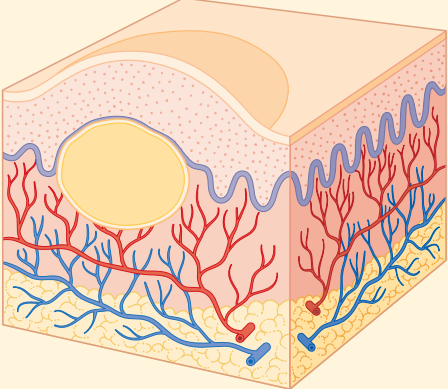
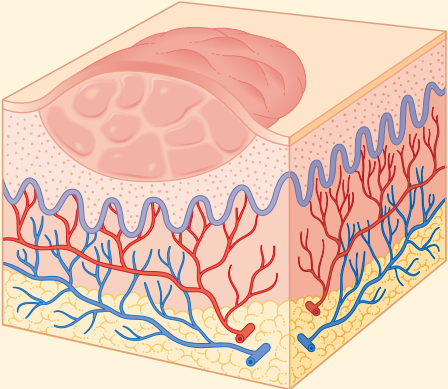
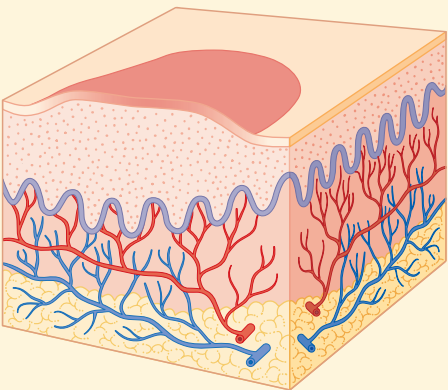
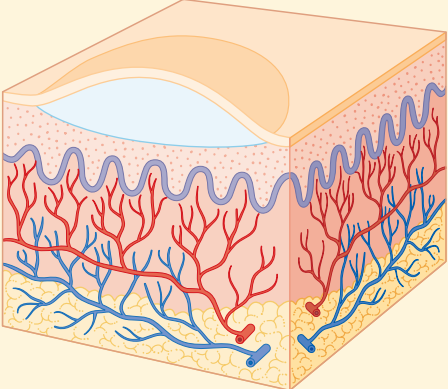
Lesion	Description	Illustration	Examples
Nodule	Circumscribed, elevated, usually solid lesion that measures 0.5–2 cm in diameter. It involves the dermis and may extend into the subcutaneous tissue, with its greatest mass below the surface of the skin.		Neurofibroma (Fig. 11.49); pilomatricoma (Fig. 9.41); subcutaneous granuloma annulare (Fig. 9.52), and nodular scabies (Fig. 18.9).
Tumor	Deeper circumscribed solid lesion of the skin or subcutaneous tissue that measures >2 cm in diameter. It may be benign or malignant.		Deep hemangioma (Fig. 12.8) and sarcoma (Fig. 10.22).
Wheal	Distinctive type of elevated lesion characterized by local, superficial, transient edema. White to pink or pale red, compressible, and evanescent, they often disappear within a period of hours. They vary in size and shape.		Darier's sign of mastocytosis (Fig. 9.45); urticarial vasculitis (Fig. 21.14), and various forms of urticaria (Fig. 20.1).
Vesicle	Sharply circumscribed, elevated, fluid-containing lesion that measures 1 cm in diameter or less.		Herpes simplex (Figs 2.41, 15.17); hand-foot-and-mouth disease (Fig. 16.38); pompholyx (Fig. 3.38); varicella (Fig. 16.2), and contact dermatitis (Fig. 3.51).

Table 1.1 Continued

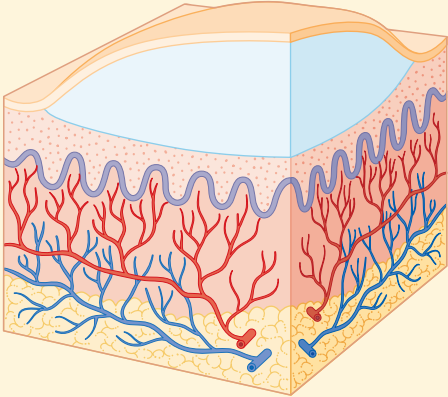
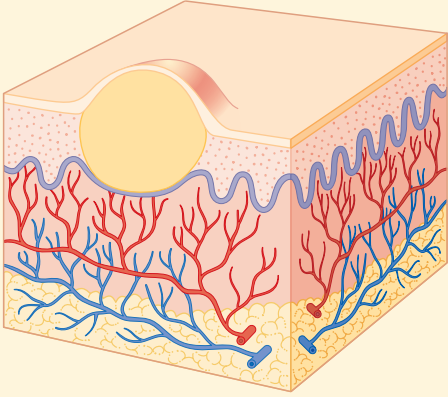
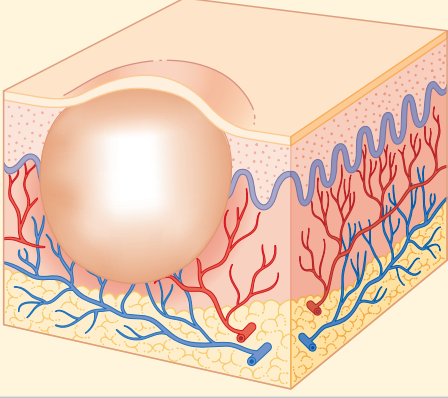
Lesion	Description	Illustration	Examples
Bulla	Larger circumscribed, elevated fluid-containing lesion that measures >1 cm in diameter.		Blistering distal dactylitis (Fig. 14.17); bullous pemphigoid (Fig. 13.23); chronic bullous disease of childhood (Fig. 13.26); bullous systemic lupus erythematosus (Fig. 13.30), and epidermolysis bullosa (Fig. 13.4).
Pustule	Circumscribed elevation <1 cm in diameter that contains a purulent exudate. It may be infectious or sterile.		Folliculitis (Fig. 14.8); transient neonatal pustular melanosis (Figs 2.5 and 2.16); pustular psoriasis (Fig. 4.18), and infantile acropustulosis (Fig. 2.17).
Abscess	Circumscribed, elevated lesion >1 cm in diameter, often with a deeper component, and filled with purulent material.		Staphylococcal abscess (in a neonate, Fig. 2.5; in a patient with hyperimmunoglobulinemia E, Fig. 3.31).
<b>Other primary lesions</b>			
Comedone	Plugged secretion of horny material retained within a pilosebaceous follicle. It may be flesh-colored (as in closed comedone or whitehead), or slightly raised brown or black (as in open comedone or blackhead). Closed comedones, in contrast to open comedones, may be difficult to visualize. They appear as pale, slightly elevated small papules without a clinically visible orifice.		Acne comedones (Figs 8.2, 8.3); nevus comedonicus (Fig. 9.38).
Burrow	Linear lesion produced by tunneling of an animal parasite in the stratum corneum.		Scabies (Fig. 18.3) and cutaneous larva migrans (creeping eruption, Fig. 18.37).

Table 1.1 Continued

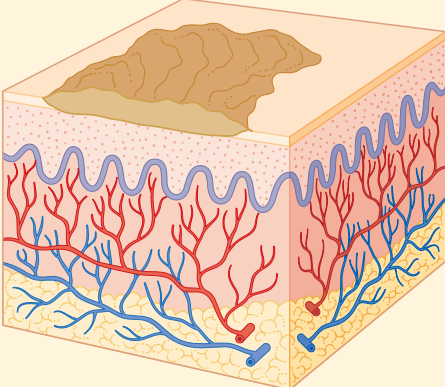
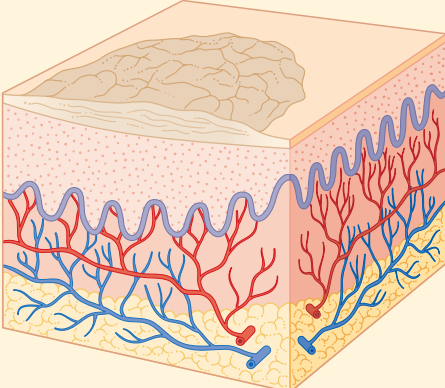
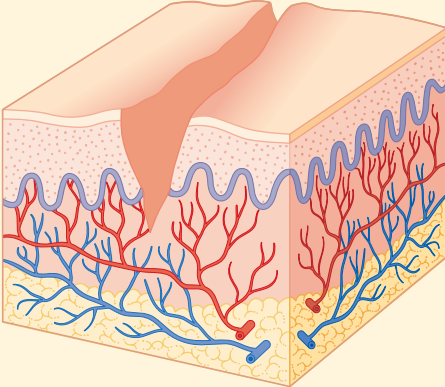
Lesion	Description	Illustration	Examples
Telangiectasia	Persistent dilatation of superficial venules, capillaries, or arterioles of the skin.		Spider angioma (Fig. 12.80); periungual lesion of dermatomyositis (Fig. 22.23), and Goltz syndrome (Fig. 6.13).
<b>Secondary lesions</b>			
Secondary lesions represent evolutionary changes that occur later in the course of the cutaneous disorder. Although helpful in dermatologic diagnosis, they do not offer the same degree of diagnostic aid as that afforded by primary lesions of a cutaneous disorder.			
Crust	Dried remains of serum, blood, pus, or exudate overlying areas of lost or damaged epidermis. Crust is yellow when formed by dried serum, green or yellowish green when formed by purulent exudate, and dark red or brown when formed by bloody exudative serum.		Herpes simplex (Fig. 15.4); weeping eczematous dermatitis (Fig. 3.1) and dried honey-colored lesions of impetigo (Figs 3.22 and 14.1).
Scale	Formed by an accumulation of compact desquamating layers of stratum corneum as a result of abnormal keratinization and exfoliation of cornified keratinocytes.		Seborrheic dermatitis (greasy and yellowish, Figs 3.4 and 3.34); psoriasis (silvery and mica-like, Fig. 4.2); pityriasis alba (fine and barely visible, Fig. 3.29), and lamellar ichthyosis (large and adherent, Fig. 5.10).
Fissure	Dry or moist, linear, often painful cleavage in the cutaneous surface that results from marked drying and long-standing inflammation, thickening, and loss of elasticity of the integument.		Angular cheilitis (Fig. 17.33), and the perianal lesions of streptococcal dermatitis (Fig. 14.16).

Table 1.1 Continued

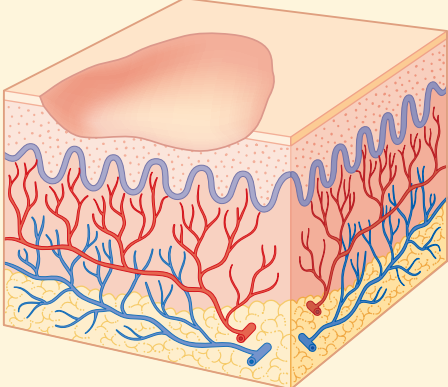
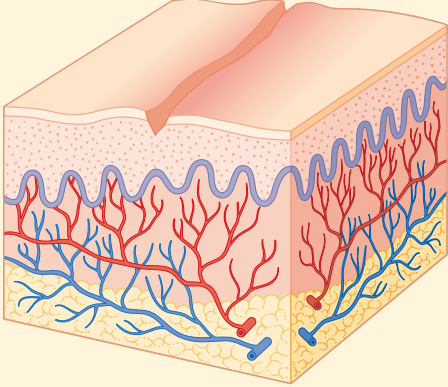
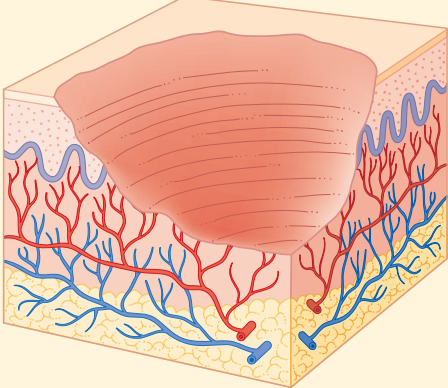
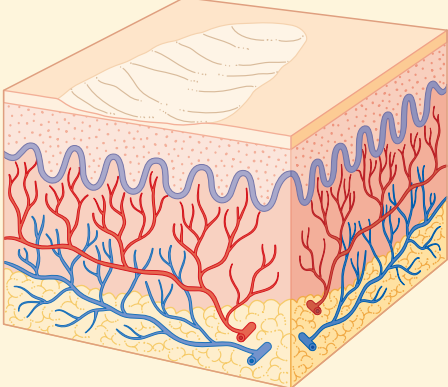
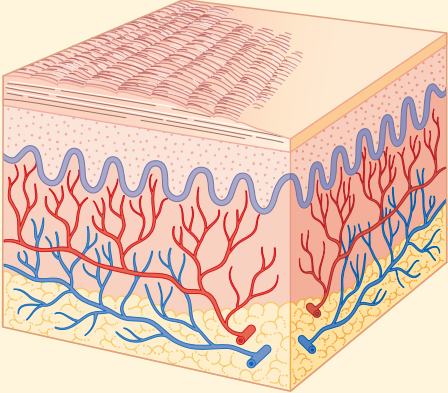
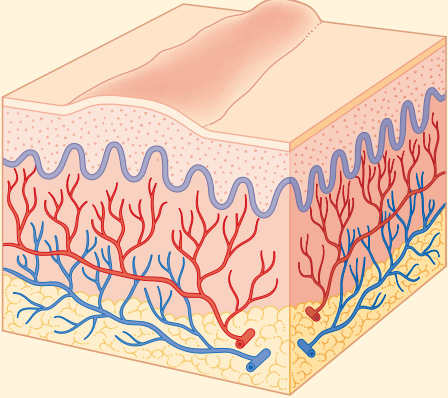
Lesion	Description	Illustration	Examples
Erosion	Moist, slightly depressed vesicular or bullous lesions in which part or all of the epidermis has been lost. Since erosions do not extend into the underlying dermis or subcutaneous tissue, healing occurs without subsequent scar formation.		Herpes simplex (Figs 3.25, 15.1); epidermolytic ichthyosis in a neonate (Fig. 5.4); and acrodermatitis enteropathica (Fig. 2.25).
Excoriation	Traumatized or abraded (usually self-induced) superficial loss of skin caused by scratching, rubbing, or scrubbing of the cutaneous surface.		Atopic dermatitis (Fig. 3.21), and acne excoriée (Fig. 8.19).
Ulcer	Necrosis of the epidermis and part or all of the dermis and/or the underlying subcutaneous tissue.		Pyoderma gangrenosum (Fig. 25.26) and ulcerated hemangioma of infancy (Figs 12.14, 12.23).
Atrophy	Cutaneous changes that result in depression of the epidermis, dermis, or both. Epidermal atrophy is characterized by thin, almost translucent epidermis, a loss of the normal skin markings, and wrinkling when subjected to lateral pressure or pinching of the affected area. In dermal atrophy the skin is depressed.		Anetoderma (Fig. 22.54); morphea (Fig. 22.47); steroid-induced atrophy (Fig. 3.28), and Goltz syndrome (Fig. 6.15).

Table 1.1 Continued

Lesion	Description	Illustration	Examples
Lichenification	Thickening of the epidermis with associated exaggeration of skin markings. Lichenification results from chronic scratching or rubbing of a pruritic lesion.		Atopic dermatitis (Fig. 3.14); chronic contact dermatitis (Fig. 3.46), and lichen simplex chronicus (Fig. 3.33).
Scar	A permanent fibrotic skin change that develops after damage to the dermis. Initially pink or violaceous, scars are permanent white, shiny and sclerotic as the color fades. Although fresh scars often are hypertrophic, they usually contract during the subsequent 6–12 months and become less apparent. Hypertrophic scars must be differentiated from keloids, which represent an exaggerated response to skin injury. Keloids are pink, smooth, and rubbery and are often traversed by telangiectatic vessels. They tend to increase in size long after healing has taken place and can be differentiated from hypertrophic scars by the fact that the surface of keloidal scars tends to proliferate beyond the area of the original wound.		Keloid (Fig. 9.71); healed areas of recessive dystrophic epidermolysis bullosa (Fig. 13.17); acne scarring (Fig. 8.8), acne keloidalis (Fig. 7.28), and amniocentesis scars (Fig. 2.4).

*Moniliform* refers to a banded or necklace-like appearance. This is seen in monilethrix, a hair deformity characterized by beaded nodularities along the hair shaft.

*Multiform* refers to disorders in which more than one variety or shape of cutaneous lesions occurs. This configuration is seen in patients with erythema multiforme, early Henoch–Schönlein purpura, and polymorphous light eruption.

*Nummular* means coin-shaped and is usually used to describe nummular dermatitis.

*Polycyclic* refers to oval lesions containing more than one ring, as frequently is seen in patients with urticaria.

A *reticulated* or net-like pattern may be seen in erythema ab igne, livedo reticularis, cutis marmorata, cutis marmorata telangiectatica congenita, and lesions of confluent and reticulated papillomatosis.

*Serpiginous* describes the shape or spread of lesions in a serpentine or snake-like configuration, particularly those of cutaneous larva migrans (creeping eruption) and elastosis perforans serpiginosa.

*Umbilicated lesions* are centrally depressed or shaped like an umbilicus or navel. Examples include lesions of molluscum contagiosum, varicella, vaccinia, variola, herpes zoster, and Kaposi's varicelliform eruption.

*Universal (universalis)* implies widespread disorders affecting the entire skin, as in alopecia universalis.

*Zosteriform* describes a linear arrangement along a nerve, as typified by lesions of herpes zoster, although herpes simplex infection can also manifest in a zosteriform distribution.

## Distribution and morphologic patterns of common skin disorders

The regional distribution and morphologic configuration of cutaneous lesions are frequently helpful in dermatologic diagnosis.

*Acneiform* are those having the form of acne, and an acneiform distribution refers to lesions primarily seen on the face, neck, chest, upper arms, shoulders, and back (Figs 8.2–8.13).

Sites of predilection of *atopic dermatitis* include the face, trunk, and extremities in young children; the antecubital and popliteal fossae are the most common sites in older children and adolescents (Figs 3.1–3.12).

The lesions of *erythema multiforme* may be widespread but have a distinct predilection for the hands and feet (particularly the palms and soles) (Figs 20.33–20.37).



Lesions of *herpes simplex* may appear anywhere on the body but have a distinct predisposition for the areas about the lips, face, and genitalia (Figs 15.1–15.12). *Herpes zoster* generally has a dermatomal or nerve-like distribution and is usually but not necessarily unilateral (Figs 15.13, 15.14). More than 75% of cases occur between the second thoracic and second lumbar vertebrae. The fifth cranial nerve frequently is involved, and only rarely are lesions seen below the elbows or knees.

*Lichen planus* frequently affect the limbs (Figs 4.37–4.40). Favorite sites include the lower extremities, the flexor surface of the wrists, the buccal mucosa, the trunk, and the genitalia.

The lesions of *lupus erythematosus* most frequently localize to the bridge of the nose, the malar eminences, scalp, and ears, although they may be widespread (Figs 22.3–22.7). Patches tend to spread at the border and clear in the center, with atrophy, scarring, dyspigmentation, and telangiectases. The malar or butterfly rash is neither specific for nor the most frequent sign of lupus erythematosus; telangiectasia without the accompanying features of erythema, scaling, or atrophy is never a marker of this disorder.

*Molluscum contagiosum* is a common viral disorder characterized by dome-shaped skin-colored to erythematous papules, often with a central white core or umbilication (Figs 15.35–15.44). These papules most commonly localize to the trunk and axillary areas. Although molluscum lesions can be found anywhere, the scalp, palms and soles are infrequent sites of involvement.

*Photodermatoses* are cutaneous disorders caused or precipitated by exposure to light. Areas of predilection include the face, ears, anterior 'V' of the neck and upper chest, the dorsal aspect of the forearms and hands, and exposed areas of the legs. The shaded regions of the upper eyelids, subnasal, and submental regions tend to be spared. The major photosensitivity disorders are lupus erythematosus, dermatomyositis, polymorphous light eruption, drug photosensitization, and porphyria (see Ch. 19).

Photosensitive reactions cannot be distinguished on a clinical basis from lesions of photocontact allergic conditions. They may reflect internal as well as external photoallergens, and may simulate contact dermatitis from air-borne sensitizers. Lupus erythematosus can be differentiated by the presence of atrophy, scarring, hyperpigmentation or hypopigmentation, and the presence of periungual telangiectases. Dermatomyositis with swelling and erythema of the cheeks and eyelids should be differentiated from allergic contact dermatitis by the heliotrope hue and other associated changes, particularly those of the fingers (periungual telangiectases and Gottron's papules).

*Pityriasis rosea* begins as a solitary round or oval scaling lesion known as the herald patch in 70–80% of cases, often misdiagnosed as tinea corporis (Figs 4.32–4.35). After an interval of days to 2 weeks, affected individuals develop a generalized symmetrical eruption that involves mainly the trunk and proximal limbs. The clue to diagnosis is the distribution of lesions, with the long axis of these oval lesions parallel to the lines of cleavage in what has been termed a *Christmas-tree pattern*. A common variant, inverse pityriasis rosea often localizes in the inguinal region, but the parallel nature of the long axis of lesions remains characteristic.

*Psoriasis* classically consists of round, erythematous, well-margined plaques with a rich red hue covered by a characteristic grayish or silvery-white mica-like (micaceous) scale, which, on removal, may result in pinpoint bleeding (Auspitz sign) (Figs 4.1–4.10). Although exceptions occur, lesions generally are seen in a bilaterally symmetrical pattern with a predilection for the elbows, knees, scalp, and lumbosacral, perianal, and genital regions. Nail involvement, a valuable diagnostic sign, is characterized by pitting of the nail plate, discoloration, separation of the nail from the nail bed (onycholysis), and an accumulation of subungual scale

(subungual hyperkeratosis). A characteristic feature of this disorder is the Koebner or isomorphic response in which new lesions appear at sites of local injury.

*Scabies* is an itchy disorder in which lesions are characteristically distributed on the wrists and hands (particularly the interdigital webs), forearms, genitalia, areolae, and buttocks in older children and adolescents (Figs 18.1–18.11). Other family members may be similarly affected or complain of itching. In infants and young children, the diagnosis is often overlooked because the distribution typically involves the palms, soles, and often the head and neck. Obliteration of demonstrable primary lesions (burrows) due to vigorous hygienic measures, excoriation, crusting, eczematization, and secondary infection is particularly common in infants.

*Seborrheic dermatitis* is an erythematous, scaly or crusting eruption that characteristically occurs on the scalp, face, and postauricular, presternal, and intertriginous areas (Figs 3.34–3.36). The classic lesions are dull or pinkish yellow or salmon colored, with fairly sharp borders and overlying yellowish greasy scale. Morphologic and topographic variants occur in many combinations and with varying degrees of severity, from mild involvement of the scalp with occasional blepharitis to generalized, occasionally severe erythematous scaling eruptions. The differential diagnosis may include atopic dermatitis, psoriasis, various forms of diaper dermatitis, Langerhans cell histiocytosis, scabies, tinea corporis or capitis, pityriasis alba, contact dermatitis, Darier disease, and lupus erythematosus.

*Warts* are common viral cutaneous lesions characterized by the appearance of skin-colored small papules of several morphologic types (Figs 15.16–15.33). They may be elevated or flat lesions and tend to appear in areas of trauma, particularly the dorsal surface of the face, hands, periungual areas, elbows, knees, feet, and genital or perianal areas. Close examination may reveal capillaries appearing as punctate dots scattered on the surface.

## Changes in skin color

The color of skin lesions frequently assists in making the diagnosis. Disorders of brown hyperpigmentation include post-inflammatory hyperpigmentation, pigmented and epidermal nevi, café-au-lait spots, incontinentia pigmenti, fixed drug eruption, photodermatitis and phytophoto-dermatitis, chloasma, acanthosis nigricans, and Addison disease. Blue coloration is seen in mongolian spots, blue nevi, nevus of Ito and nevus of Ota, and cutaneous neuroblastomas. Cysts, deep hemangiomas, and pilomatricomas often show a subtle blue color, whereas the blue of venous malformations and glomovenous malformations is often a more intense, dark blue. Yellowish discoloration of the skin is common in infants, related to the presence of carotene derived from excessive ingestion of foods, particularly yellow vegetables containing carotenoid pigments. Jaundice may be distinguished from carotenemia by scleral icterus. Localized yellow lesions may be juvenile xanthogranulomas, nevus sebaceous, xanthomas, or mastocytomas. Red lesions are usually vascular in origin, such as superficial hemangiomas, spider telangiectases, and nevus flammeus, or inflammatory, such as the scaling lesions of atopic dermatitis or psoriasis.

Localized lesions with decreased pigmentation may be hypopigmented or depigmented (totally devoid of pigmentation); Wood's lamp examination may help to differentiate depigmented lesions, which fluoresce a bright white, from hypopigmented lesions. Localized depigmented lesions may be seen in vitiligo, Vogt-Koyanagi syndrome, halo nevi, chemical depigmentation, piebaldism, and Waardenburg syndrome. Hypopigmented lesions are more typical of post-inflammatory hypopigmentation, pityriasis alba, tinea versicolor, leprosy, nevus achromicus, tuberous sclerosis, and the

hypopigmented streaks of pigment mosaicism. A generalized decrease in pigmentation can be seen in patients with albinism, untreated phenylketonuria, and Menkes syndrome. The skin of patients with Chediak–Higashi and Griscelli syndromes takes on a dull silvery sheen and may show decreased pigmentation.

## Racial variations in the skin and hair

The skin of African-American and other darker-skinned children varies in several ways from that of lighter-skinned children based on genetic background and customs.<sup>1,2</sup> The erythema of inflamed black skin may be difficult to see, and likely accounts for the purportedly decreased incidence of macular viral exanthems such as erythema infectiosum. Erythema in African-American children frequently has a purplish tinge that can be confusing to unwary observers. The skin lesions in several inflammatory disorders, such as in atopic dermatitis, pityriasis rosea, and syphilis, frequently show a follicular pattern in African-American children.

Post-inflammatory hypopigmentation and hyperpigmentation occur readily and are more obvious in darker-skinned persons, regardless of racial origin. Pityriasis alba and tinea versicolor are more commonly reported in darker skin types, perhaps because of the easy visibility of the hypopigmented lesions in marked contrast to uninvolved surrounding skin. Lichen nitidus is more apparent and reportedly more common in African-American individuals; lichen planus is reported to be more severe, leaving dark post-inflammatory hyperpigmentation. Vitiligo is particularly distressing to patients with darker skin types, whether African-American or Asian, because of the easy visibility in contrast with surrounding skin.

Although darker skin may burn, in general sunburn and chronic sun-induced diseases of adults such as actinic keratosis and carcinomas of the skin induced by ultraviolet light exposure (e.g., squamous cell carcinoma, keratoacanthoma, basal cell carcinoma, and melanoma) have an extremely low incidence in African-Americans and Hispanics. Congenital melanocytic nevi also tend to have a lower tendency to transform to malignancy in darker-skinned individuals. Café-au-lait spots are more numerous and seen more often in African-Americans, although the presence of six or

more should still raise suspicion about neurofibromatosis. Dermatitis papulosa nigra commonly develop in adolescents, especially female, of African descent. Mongolian spots occur more frequently in persons of African or Asian descent. Physiologic variants in children with darker skin include increased pigmentation of the gums and tongue, pigmented streaks in the nails, and Voight–Futcher lines, lines of pigmentary demarcation between the posterolateral and lighter anteromedial skin on the extremities.

Qualities of hair may also differ among individuals of different races. African-American hair tends to tangle when dry and becomes matted when wet. As a result of its naturally curly or spiral nature, pseudofolliculitis barbae is more common in African-Americans than in other groups. Tinea capitis is particularly common in prepubertal African-Americans; the tendency to use oils because of hair dryness and poor manageability may obscure the scaling of tinea capitis. Pediculosis capitis, in contrast, is relatively uncommon in this population. Prolonged continuous traction on hairs may result in traction alopecia, particularly with the common practice of making tight corn row braids. The use of other hair grooming techniques, such as chemical straighteners, application of hot oils, and use of hot combs, increases the risk of hair breakage and permanent alopecia. Frequent and liberal use of greasy lubricants and pomades produces a comedonal and sometimes papulopustular form of acne (pomade acne).

Keloids form more often in individuals of African descent, often as a complication of a form of inflammatory acne, including nodulocystic acne and acne keloidalis nuchae. Other skin disorders reportedly seen more commonly are transient neonatal pustular melanosis, infantile acropustulosis, impetigo, papular urticaria, sickle cell ulcers, sarcoidosis, and dissecting cellulitis of the scalp. Atopic dermatitis and Kawasaki disease have both been reported most frequently in children of Asian descent.

### Key References

1. Laude TA, Kenney JA Jr, Prose NS, et al. Skin manifestations in individuals of African or Asian descent. *Pediatr Dermatol.* 1996;13:158–168.
2. Dinulos JC, Graham EA. Influence of culture and pigment on skin conditions in children. *Pediatr Rev.* 1998;19:268–275.

# 2

## Cutaneous Disorders of the Newborn

### Neonatal skin

The skin of the infant differs from that of an adult in that it is thinner (40–60%), is less hairy, and has a weaker attachment between the epidermis and dermis.<sup>1</sup> In addition, the body surface area-to-weight ratio of an infant is up to five times that of an adult. The infant is therefore at a significantly increased risk for skin injury, percutaneous absorption, and skin-associated infection. Premature infants born prior to 32–34 weeks' estimated gestational age may have problems associated with an immature stratum corneum (the most superficial cell layer in the epidermis), including an increase in transepidermal water loss (TEWL). This increased TEWL may result in morbidity because of dehydration, electrolyte imbalance, and thermal instability. Interestingly, in the majority of premature infants, an acceleration of skin maturation occurs after birth such that most develop intact barrier function by 2–3 weeks of life.<sup>2</sup> However, in extremely low-birthweight infants, this process may take significantly longer, up to 4–8 weeks.<sup>3</sup> In light of the elevated TEWL levels seen in premature infants, a variety of studies have evaluated the use of occlusive dressings or topical emollients in an effort to improve compromised barrier function.<sup>4–7</sup>

The risk of percutaneous toxicity from topically applied substances is increased in infants, especially those born prematurely.<sup>8,9</sup> Percutaneous absorption is known to occur through two major pathways: (1) through the cells of the stratum corneum and the epidermal malpighian layer (the transepidermal route) and (2) through the hair follicle-sebaceous gland component (the transappendageal route). Increased neonatal percutaneous absorption may be due to the increased skin surface area-to-weight ratio, as well as the stratum corneum immaturity seen in premature neonates. Although transdermal delivery methods may be distinctly advantageous in certain settings, extreme caution must be exercised in the application of topical substances to the skin of infants, given the risk of systemic absorption and potential toxicity. Table 2.1 lists some compounds reported in association with percutaneous toxicity in the newborn.

### Skin Care of the Newborn

The skin of the newborn is covered with a grayish-white greasy material termed *vernix caseosa*. The vernix represents a physiologic protective covering derived partially by secretion of the sebaceous glands and in part as a decomposition product of the infant's epidermis. Although its function is not completely understood, it may act as a natural protectant cream to 'waterproof' the fetus *in utero*, while submerged in the amniotic fluid.<sup>10</sup> Some studies suggest that vernix be left on as a protective coating for the newborn skin and that it be allowed to come off by itself with successive changes of clothing (generally within the first few weeks of life).

The skin acts as a protective organ. Any break in its integrity, therefore, affords an opportunity for initiation of infection. The

importance of skin care in the newborn is compounded by several factors:

1. The infant does not have protective skin flora at birth.
2. The infant has at least one, and possibly two, open surgical wounds (the umbilicus and circumcision site).
3. The infant is exposed to fomites and personnel that potentially harbor a variety of infectious agents.

Skin care should involve gentle cleansing with a non-toxic, non-abrasive neutral material. During the 1950s, the use of hexachlorophene-containing compounds became routine for the skin care of newborns as prophylaxis against *Staphylococcus aureus* infection. In 1971 and 1972, however, the use of hexachlorophene preparations as skin cleansers for newborns was restricted because of studies demonstrating vacuolization in the central nervous system of infants and laboratory animals after prolonged application of these preparations.<sup>11</sup> At the minimum, neonatal skin care should include gentle removal of blood from the face and head, and meconium from the perianal area, by gentle water rinsing. Ideally, vernix caseosa should be removed from the face only, allowing the remaining vernix to come off by itself. However, the common standard of care is for gentle drying and wiping of the newborn's entire skin surface, which is most desirable from a thermoregulatory standpoint. For the remainder of the infant's stay in the hospital nursery, the buttocks and perianal regions should be cleansed with water and cotton or a gentle cloth. A mild soap with water rinsing may also be used at diaper changes if desired.

There is no single method of umbilical cord care that has been proven to limit colonization and disease. Several methods include local application of isopropyl alcohol, triple dye (an aqueous solution of brilliant green, proflavine, and gentian violet), and antimicrobial agents such as bacitracin or silver sulfadiazine cream. The routine use of povidone-iodine should be discouraged, given the risk of iodine absorption and transient hypothyroxinemia or hypothyroidism. A safer alternative is a chlorhexidine-containing product.<sup>12</sup>

### Physiologic phenomena of the newborn

Neonatal dermatology, by definition, encompasses the spectrum of cutaneous disorders that arise during the first 4 weeks of life. Many such conditions are transient, appearing in the first few days to weeks of life, only to disappear shortly thereafter. The appreciation of normal phenomena and their differentiation from the more significant cutaneous disorders of the newborn is critical for the general physician, obstetrician, and pediatrician, as well as for the pediatric dermatologist.

At birth, the skin of the full-term infant is normally soft, smooth, and velvety. Desquamation of neonatal skin generally takes place

Table 2.1 Reported hazards of percutaneous absorption in the newborn

Compound	Product	Toxicity
Aniline	Dye used as laundry marker	Methemoglobinemia, death
Mercury	Diaper rinses; teething powders	Rash, hypotonia
Phenolic compounds Pentachlorophenol Hexachlorophene Resorcinol	Laundry disinfectant Topical antiseptic Topical antiseptic	Tachycardia, sweating, hepatomegaly, metabolic acidosis, death Vacuolar encephalopathy, death Methemoglobinemia
Boric acid	Baby powder	Vomiting, diarrhea, erythroderma, seizures, death
Lindane	Scabicide	Neurotoxicity
Salicylic acid	Keratolytic emollient	Metabolic acidosis, salicylism
Isopropyl alcohol	Topical antiseptic	Cutaneous hemorrhagic necrosis
Silver sulfadiazine	Topical antibiotic	Kernicterus, argyria
Urea	Keratolytic emollient	Uremia
Povidone-iodine	Topical antiseptic	Hypothyroidism, goiter
Neomycin	Topical antibiotic	Neural deafness
Corticosteroids	Topical anti-inflammatory	Skin atrophy, adrenal suppression
Benzocaine	Mucosal anesthetic	Methemoglobinemia
Prilocaine	Epidermal anesthetic	Methemoglobinemia
Methylene blue	Amniotic fluid leak	Methemoglobinemia

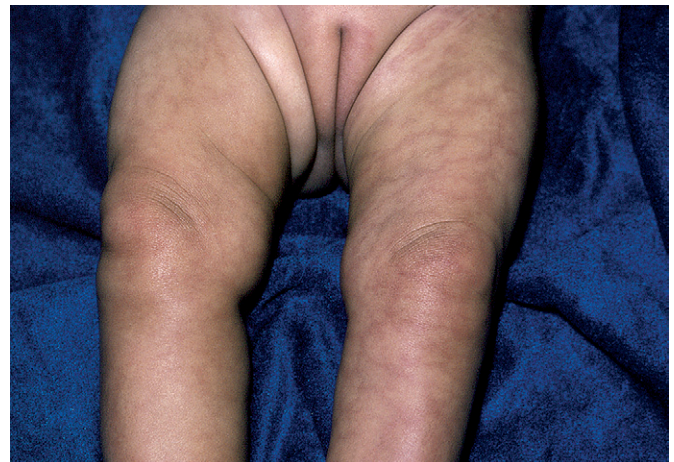Reprinted with permission from Siegfried EC. Neonatal skin care and toxicology. In: Eichenfield LF, Frieden IJ, Esterly NB, eds. Textbook of neonatal dermatology. Philadelphia: WB Saunders; 2001:62–72.

24–36 h after delivery and may not be complete until the third week of life. Desquamation at birth is an abnormal phenomenon and is indicative of postmaturity, intrauterine anoxia, or congenital ichthyosis.

The skin at birth has a purplish-red color that is most pronounced over the extremities. Except for the hands, feet, and lips, where the transition is gradual, this quickly changes to a pink hue. In a great number of infants, a purplish discoloration of the hands, feet, and lips occurs during periods of crying, breath holding, or chilling. This normal phenomenon, termed *acrocyanosis*, appears to be associated with an increased tone of peripheral arterioles, which in turn creates vasospasm, secondary dilatation, and pooling of blood in the venous plexuses, resulting in a cyanotic appearance to the involved areas of the skin. The intensity of cyanosis depends on the degree of oxygen loss and the depth, size, and fullness of the involved venous plexus. *Acrocyanosis*, a normal physiologic phenomenon, should not be confused with true cyanosis.

## Cutis Marmorata

*Cutis marmorata* is a normal reticulated bluish mottling of the skin seen on the trunk and extremities of infants and young children (Fig. 2.1). This phenomenon, a physiologic response to chilling with resultant dilatation of capillaries and small venules, usually disappears as the infant is rewarmed. Although a tendency to *cutis marmorata* may persist for several weeks or months, this disorder bears no medical significance and treatment generally is unnecessary. In some children *cutis marmorata* may tend to recur until early childhood, and in patients with Down syndrome, trisomy 18, and the Cornelia de Lange syndrome, this reticulated marbling pattern may be persistent. When the changes are persistent (even with rewarming) and are deep violaceous in color, *cutis marmorata telangiectatica congenita* (Fig. 2.2; see also Ch. 12) should be considered. In some infants a white negative pattern of *cutis marmorata* (*cutis marmorata alba*) may be created by a transient hypertonia of

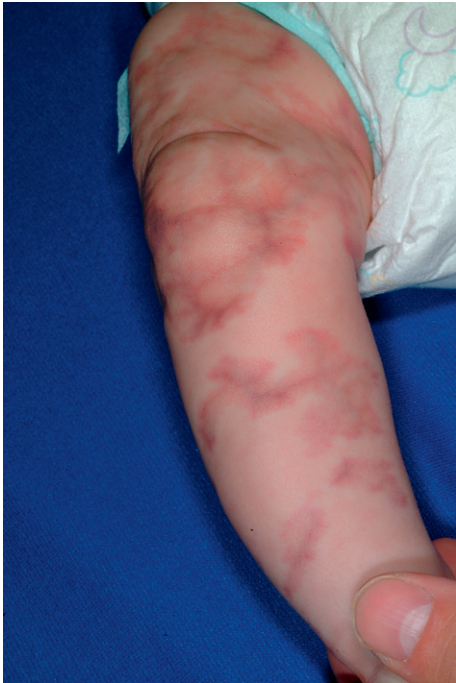

**Figure 2.1** *Cutis marmorata*. Reticulate bluish mottling that resolves with rewarming.

the deep vasculature. *Cutis marmorata alba* is also a transitory disorder and appears to have no clinical significance.

## Harlequin Color Change

Harlequin color change, not to be confused with harlequin ichthyosis (see Ch. 5), is occasionally observed in full-term infants but usually occurs in premature infants. It occurs when the infant is lying on his or her side and consists of reddening of one half of the body with simultaneous blanching of the other half. Attacks develop suddenly and may persist for 30 s–20 min. The side that lies uppermost is paler, and a clear line of demarcation runs along the midline of the body. At times, this line of demarcation may be incomplete; and when attacks are mild, areas of the face and genitalia may not be involved.

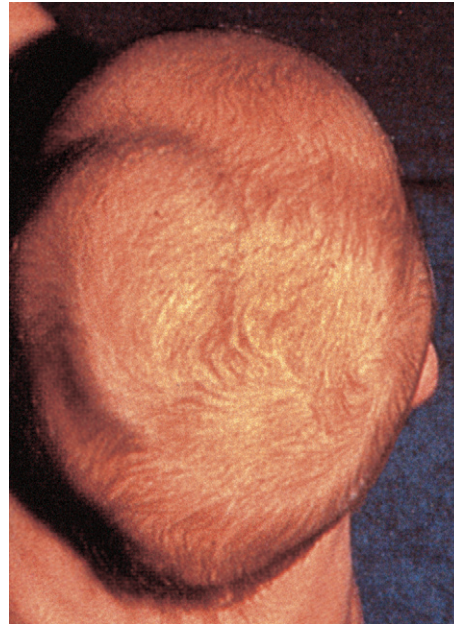

**Figure 2.2** Cutis marmorata telangiectatica congenita. Violaceous, reticulate patches with subtle atrophy. These changes did not resolve with rewarming, and were associated with mild ipsilateral limb hypoplasia.

This phenomenon appears to be related to immaturity of hypothalamic centers that control the tone of peripheral blood vessels and has been observed in infants with severe intracranial injury as well as in infants who appear to be otherwise perfectly normal. Although the peak frequency of attacks of harlequin color change generally occurs between the second and fifth days of life, attacks may occur anywhere from the first few hours to as late as the second or the third week of life.<sup>13</sup>

### Bronze Baby Syndrome

The *bronze baby syndrome* is a term used to describe infants who develop a grayish-brown discoloration of the skin, serum, and urine while undergoing phototherapy for hyperbilirubinemia. Although the exact source of the pigment causing the discoloration is not clear, the syndrome usually begins 1–7 days after the initiation of phototherapy, resolves gradually over a period of several weeks after phototherapy is discontinued, and appears to be related to a combination of photoisomers of bilirubin or biliverdin or a photoproduct of copper-porphyrin metabolism.<sup>14–16</sup> Infants who develop bronze baby syndrome may have modified liver function, particularly cholestasis, of various origins.<sup>17</sup> The disorder should be differentiated from neonatal jaundice, cyanosis associated with neonatal pulmonary disorders or congenital heart disease, an unusual progressive hyperpigmentation (universal-acquired melanosis, the ‘carbon baby’ syndrome),<sup>18</sup> and chloramphenicol intoxication (the ‘gray baby’ syndrome), which is a disorder in infants with immature liver function, who are unable to conjugate chloramphenicol characterized by elevated serum chloramphenicol levels, progressive cyanosis, abdominal distention, hypothermia, vomiting, irregular respiration, and vasomotor collapse.<sup>19</sup> A distinctive purpuric eruption on exposed skin has also been described in newborns receiving phototherapy, possibly related to a transient increase in circulating



**Figure 2.3** Cephalohematoma. Note the sharp demarcation at the midline.

porphyrins.<sup>20</sup> This condition, however, is unlikely to be confused with bronze baby syndrome.

### Cephalohematoma

A cephalohematoma is a subperiosteal hematoma overlying the calvarium. These lesions are more common following prolonged labor, instrument-assisted deliveries, and abnormal presentations. They usually develop over the first hours of life and present as subcutaneous swellings in the scalp. They do not cross the midline (Fig. 2.3), as they are limited to one cranial bone, which helps to distinguish them from caput succedaneum (see below). Occasionally, a cephalohematoma may occur over a linear skull fracture. Other potentially associated complications include calcification (which may persist radiographically for years), hyperbilirubinemia, and infection. Although infected lesions (which are rare) may require aspiration,<sup>21</sup> most lesions require no therapy, with spontaneous resorption and resolution occurring over several months.

### Caput succedaneum

Caput succedaneum is a localized edema of the newborn scalp related to the mechanical forces involved in parturition. It is probably related to venous congestion and edema secondary to cervical and uterine pressure, and as such, is more common with prolonged parturition and seen most often in primigravidas. Caput presents as a boggy scalp mass, and may result in varying degrees of bruising and necrosis in addition to the edema, at times with tissue loss. In distinction to cephalohematoma, caput succedaneum lesions often cross the midline. These lesions tend to resolve spontaneously over 48 h, and treatment is generally unnecessary. One possible complication in cases of severe caput succedaneum is permanent alopecia. ‘Halo scalp ring’ refers to an annular alopecia that presents in a circumferential ring around the scalp in infants with a history of caput.<sup>22</sup> It represents a pressure necrosis phenomenon, and the hair loss may be transient or, occasionally, permanent.

## Complications from fetal and neonatal diagnostic procedures

Fetal complications associated with invasive prenatal diagnostic procedures include cutaneous puncture marks, scars or lacerations, exsanguination, ocular trauma, blindness, subdural hemorrhage, pneumothorax, cardiac tamponade, splenic laceration, porencephalic cysts, arteriovenous or ileocutaneous fistulas, digital loss (in 1.7% of newborns whose mothers had undergone early chorionic villus sampling), musculoskeletal trauma, disruption of tendons or ligaments, and occasionally gangrene. Cutaneous puncture marks, which occur in 1–3% of newborns whose mothers had undergone amniocentesis, may be seen as single or multiple 1–6 mm pits or dimples on any cutaneous surface of the newborn (Fig. 2.4).<sup>23,24</sup>

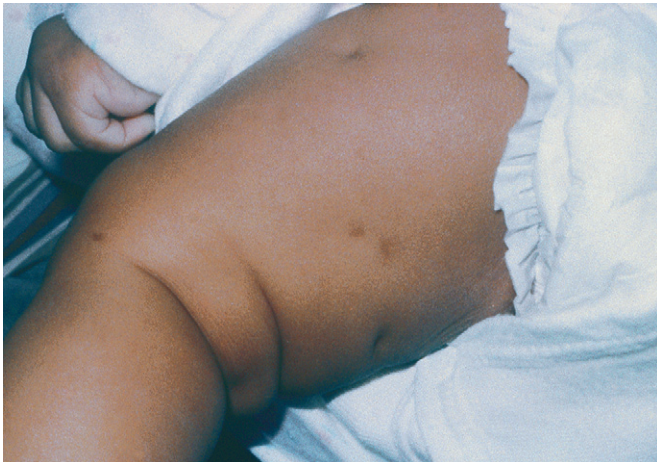Fetal scalp monitoring can result in infection, bleeding, or fontanelle puncture, and prenatal vacuum extraction can produce a localized area of edema, ecchymosis, or localized alopecia. The incidence of scalp electrode infection varies from 0.3% to 5.0%, and although local sterile abscesses account for the majority of adverse sequelae, *S. aureus* or Gram-negative infections, cellulitis, tissue necrosis, subgaleal abscess, osteomyelitis, necrotizing fasciitis, and neonatal herpes simplex infections may also occur as complications of this procedure (Fig. 2.5).<sup>25–27</sup>

Transcutaneous oxygen monitoring (application of heated electrodes to the skin for continuous detection of tissue oxygenation) and pulse oximetry may also result in erythema, tissue necrosis, and first- or second-degree burns. Although lesions associated with transcutaneous oxygen monitoring generally resolve within 48–60 h, persistent atrophic hyperpigmented craters may at times be seen as a complication. Frequent (2- to 4-h) changing of electrode sites and reduction of the temperature of the electrodes to 43 °C, however, can lessen the likelihood of this complication.<sup>28,29</sup>

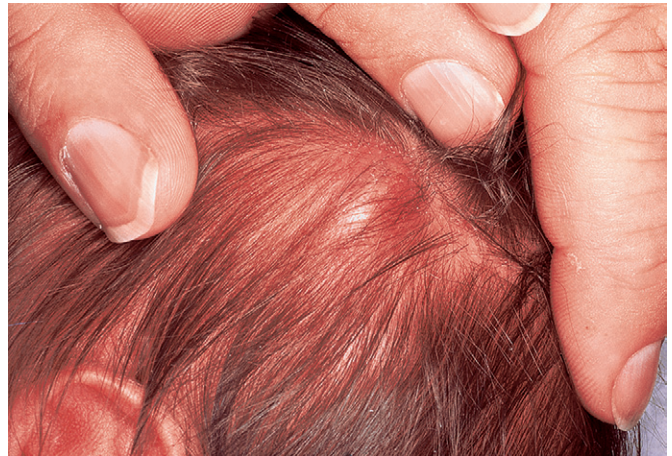
*Anetoderma of prematurity* refers to macular depressions or outpouchings of skin associated with loss of dermal elastic tissue seen in premature infants. Reports suggest that these cutaneous lesions may correlate with placement of electrocardiographic or other monitoring electrodes or leads.<sup>30,31</sup>

*Calcinosis cutis* may occur on the scalp or chest of infants or children at sites of electroencephalograph or electrocardiograph electrode placement, as a result of diagnostic heel sticks performed

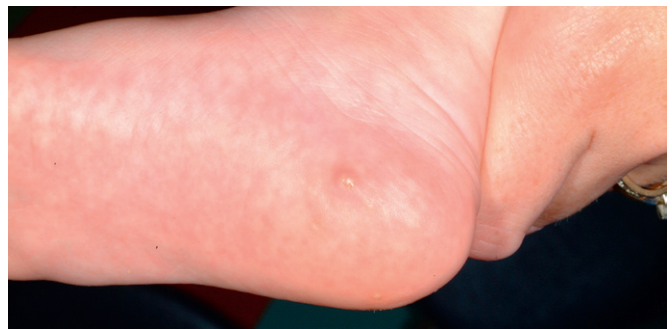during the neonatal period, or following intramuscular or intravenous administration of calcium chloride or calcium gluconate for the treatment of neonatal hypocalcemia. Seen primarily in high-risk infants who receive repeated heel sticks for blood chemistry determinations, calcified nodules usually begin as small depressions on the heels. With time, generally after 4–12 months, tiny yellow or white papules appear (Fig. 2.6), gradually enlarge to form nodular deposits, migrate to the cutaneous surface, extrude their contents, and generally disappear spontaneously by the time the child reaches 18–30 months of age. Although calcified heel nodules are usually asymptomatic, children may at times show signs of discomfort with standing or with the wearing of shoes. In such instances, gentle cryosurgery and curettage can be both diagnostic and therapeutic. Calcinosis cutis following electroencephalography or electrocardiography is more likely to be seen in infants and young children or individuals where the skin has been abraded and usually disappears spontaneously within 2–6 months. It can be avoided by the use of an electrode paste that does not contain calcium chloride and, like calcified heel sticks, may be treated by gentle cryosurgery and curettage.<sup>32,33</sup>



**Figure 2.4** Amniocentesis scars. Multiple depressed scars on the thigh of an infant born to a mother who had amniocentesis during pregnancy. (Courtesy of Lester Schwartz MD.)



**Figure 2.5** Staphylococcal scalp abscess. Fluctuant, erythematous nodule on the scalp of this 9-day-old infant as a complication of intrauterine fetal monitoring.



**Figure 2.6** Heel stick calcinosis. Firm, white-yellow papules on the plantar and lateral heel in an infant who had multiple heel sticks as a newborn.

## Abnormalities of subcutaneous tissue

Skin turgor is generally normal during the first few hours of life. As normal physiologic dehydration occurs during the first 3 or 4 days of life (up to 10% of birthweight), the skin generally becomes loose and wrinkled. Subcutaneous fat, normally quite adequate at birth, increases until about 9 months of age, thus accounting for the traditional chubby appearance of the healthy newborn. A decrease or absence of this normal panniculus is abnormal and suggests the possibility of prematurity, postmaturity, or placental insufficiency.

Sclerema neonatorum and subcutaneous fat necrosis are two disorders that affect the subcutaneous fat of the newborn. Although there is considerable diagnostic confusion between these two entities, there are several distinguishing features that enable a clinical differentiation (Table 2.2). Sclerema neonatorum seems to occur with significantly less frequency than subcutaneous fat necrosis.

### Sclerema Neonatorum

Sclerema neonatorum is a diffuse, rapidly spreading, waxlike hardening of the skin and subcutaneous tissue that occurs in premature or debilitated infants during the first few weeks of life. The disorder, usually associated with a serious underlying condition such as sepsis or other infection, congenital heart disease, respiratory distress, diarrhea, or dehydration, is characterized by a diffuse non-pitting woody induration of the involved tissues. The process is symmetrical, usually starting on the legs and buttocks, and may progress to involve all areas except the palms, soles, and genitalia.<sup>34</sup> As the disorder spreads, the skin becomes cold, yellowish white, mottled, stony hard, and cadaver-like. The limbs become immobile, and the face acquires a fixed mask-like expression. The infants become sluggish, feed poorly, show clinical signs of shock, and in a high percentage of cases die.

Although the etiology of this disorder is unknown, it appears to represent a nonspecific sign of severe illness rather than a primary disease. Infants with this disorder are characteristically small or premature, debilitated, weak, cyanotic, and lethargic. In 25% of cases the mothers are ill at the time of delivery. Exposure to cold, hypothermia, peripheral chilling with vascular collapse, and an

increase in the ratio of saturated to unsaturated fatty acids in the triglyceride fraction of the subcutaneous tissue (because of a defect in fatty acid mobilization) have been hypothesized as possible causes for this disorder but lack confirmation.<sup>35</sup>

The histopathologic findings of sclerema neonatorum consist of edema and thickening of the connective tissue bands around the fat lobules. Although necrosis and crystallization of the subcutaneous tissue have been described, these findings are more characteristically seen in lesions of subcutaneous fat necrosis.

The prognosis of sclerema neonatorum is poor, and mortality occurs in 50–75% of affected infants. In those infants who survive, the cutaneous findings resolve without residual sequelae. There is no specific therapy, although steroids and exchange transfusion have been used.<sup>34</sup>

### Subcutaneous Fat Necrosis

Subcutaneous fat necrosis (SCFN) is a benign self-limited disease that affects apparently healthy full-term newborns and young infants. It is characterized by sharply circumscribed, indurated, and nodular areas of fat necrosis (Fig. 2.7). The etiology of this disorder remains unknown but appears to be related to perinatal trauma, asphyxia, hypothermia, and, in some instances, hypercalcemia.<sup>36,37</sup> Although the mechanism of hypercalcemia in SCFN is not known, it has been attributed to aberrations in vitamin D or parathyroid homeostasis. Birth asphyxia and meconium aspiration seem to be frequently associated. In one large series, 10 out of 11 infants with SCFN had been delivered via emergency cesarean section for fetal distress, and 9 of the 11 had meconium staining of the amniotic fluid.<sup>38</sup> The relationship between subcutaneous fat necrosis, maternal diabetes and cesarean section, if any, is unclear. SCFN following icebag application for treatment of supraventricular tachycardia has been reported.<sup>39</sup>

The onset of SCFN is generally during the first few days to weeks of life. Lesions appear as single or multiple localized, sharply circumscribed, usually painless areas of induration. Occasionally, the affected areas may be tender and infants may be uncomfortable and cry vigorously when they are handled. Lesions vary from small erythematous, indurated nodules to large plaques, and sites of predilection include the cheeks, back, buttocks, arms, and thighs. Many lesions have an uneven lobulated surface with an elevated margin separating it from the surrounding normal tissue. Histologic examination of SCFN reveals larger than usual fat lobules and an

Table 2.2 Features of sclerema neonatorum and subcutaneous fat necrosis

Sclerema neonatorum	Subcutaneous fat necrosis
Premature infants	Full-term or postmature infants
Serious underlying disease (sepsis, cardiopulmonary disease, diarrhea, or dehydration)	Healthy newborns; may have history of perinatal asphyxia or difficult delivery
Wax-like hardening of skin and subcutaneous tissue	Circumscribed, indurated, erythematous nodules and plaques
Whole body except palms, soles	Buttocks, thighs, arms, face, shoulders
Poor prognosis; high mortality	Excellent prognosis; treat associated hypercalcemia, if present

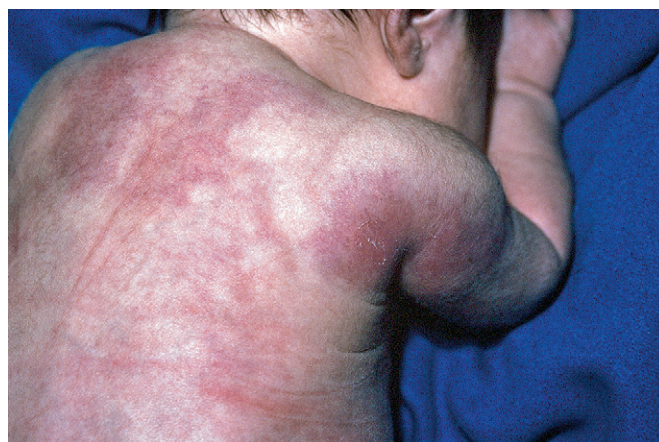

Figure 2.7 Subcutaneous fat necrosis. Indurated, erythematous plaques on the shoulders and back of this 1-week-old boy.

extensive inflammatory infiltrate, needle-shaped clefts within fat cells, necrosis, and calcification. Magnetic resonance imaging (MRI) reveals decreased T1 and increased T2 signal intensity in affected areas.<sup>40</sup>

The prognosis for SCFN is excellent. Although lesions may develop extensive deposits of calcium, which may liquefy, drain, and heal with scarring, most areas undergo spontaneous resolution within several weeks to months. Hypercalcemia is a rare association, and infants with this finding may require low calcium intake, restriction of vitamin D, and/or systemic corticosteroid therapy. Etidronate therapy has been reported for treatment of recalcitrant SCFN-associated hypercalcemia.<sup>41</sup> Infants should be followed for several months following delivery, as the onset of hypercalcemia can be delayed for several months.<sup>38,42</sup> Other rare systemic complications may include thrombocytopenia, hypoglycemia and hypertriglyceridemia, all of which tend to be mild and/or self-limited.

## Miscellaneous cutaneous disorders

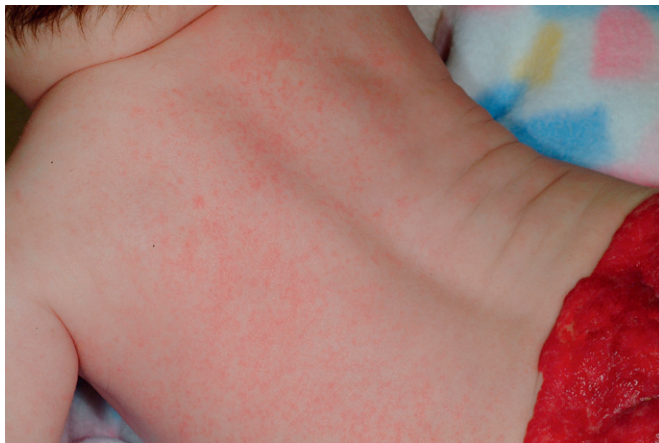### Miliaria

Differentiation of the epidermis and its appendages, particularly in the premature infant, is frequently incomplete at birth. As a result of this immaturity, a high incidence of sweat-retention phenomena may be seen in the newborn. Miliaria, a common neonatal dermatosis caused by sweat retention, is characterized by a vesicular eruption with subsequent maceration and obstruction of the eccrine ducts. The pathophysiologic events that lead to this disorder are keratinous plugging of eccrine ducts and the escape of eccrine sweat into the skin below the level of obstruction (see Ch. 8).

Virtually all infants develop miliaria under appropriate conditions. There are two principal forms of this disorder:

1. *Miliaria crystallina* (sudamina), which consists of clear superficial pinpoint vesicles without an inflammatory areola
2. *Miliaria rubra* (prickly heat), representing a deeper level of sweat gland obstruction, and characterized by small discrete erythematous papules, vesicles, or papulovesicles (Fig. 2.8).

The incidence of miliaria is greatest in the first few weeks of life owing to the relative immaturity of the eccrine ducts, which favors poral closure and sweat retention. A pustular form of miliaria rubra



**Figure 2.8** Miliaria rubra. Multiple, erythematous, pinpoint macules and papules, especially prominent on the occluded surface of the back. This infant was being followed for the segmental infantile hemangioma present on her lower back.

has been observed in association with pseudohypoaldosteronism during salt-losing crises.<sup>43</sup>

Therapy for miliaria is directed toward avoidance of excessive heat and humidity. Light-weight cotton clothing, cool baths, and air conditioning are helpful in the management and prevention of this disorder. Avoidance of emollient overapplication (i.e., in infants with atopic dermatitis) should also be recommended, especially in warm, humid climates or in the winter when infants are bundled under heavy clothing.

### Milia

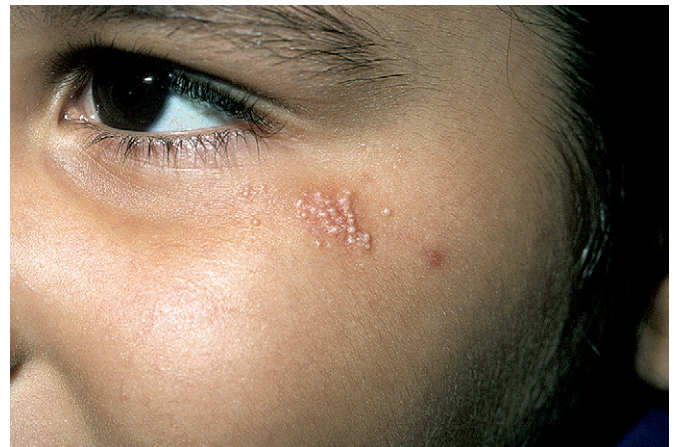Milia, small retention cysts, commonly occur on the face of newborns. Seen in 40–50% of infants, they result from retention of keratin within the dermis. They appear as tiny 1–2 mm pearly white or yellow papules. Particularly prominent on the cheeks, nose, chin, and forehead, they may be few or numerous and are frequently grouped (Fig. 2.9). Lesions may occasionally occur on the upper trunk, limbs, penis, or mucous membranes. Although milia of the newborn may persist into the second or third month, they usually disappear spontaneously during the first 3 or 4 weeks of life and, accordingly, require no therapy. Persistent milia in an unusual or widespread distribution, particularly when seen in association with other defects, may be seen as a manifestation of hereditary trichodysplasia (Marie-Unna hypotrichosis), dystrophic forms of epidermolysis bullosa, Bazex or Rombo syndromes, or the oral-facial-digital syndrome type I.

### Bohn's Nodules and Epstein's Pearls

Discrete, 2–3 mm round, pearly white or yellow, freely movable elevations at the gum margins or midline of the hard palate (termed *Bohn's nodules* and *Epstein's pearls*, respectively) are seen in up to 85% of newborns. Clinically and histologically, the counterpart of facial milia, they disappear spontaneously, usually within a few weeks of life, and require no therapy.

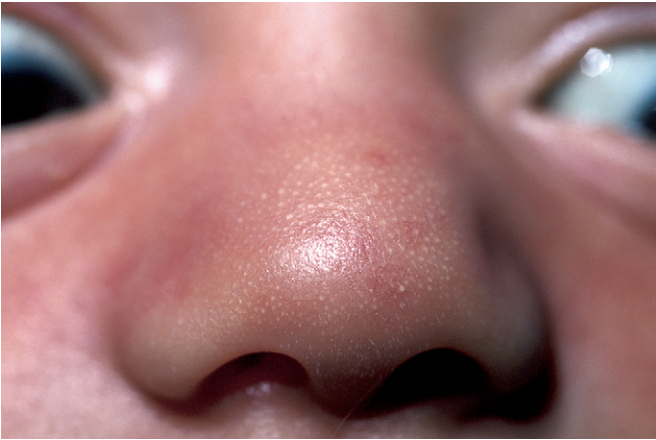### Sebaceous Gland Hyperplasia

Sebaceous gland hyperplasia represents a physiologic phenomenon of the newborn manifested as multiple, yellow to flesh-colored tiny

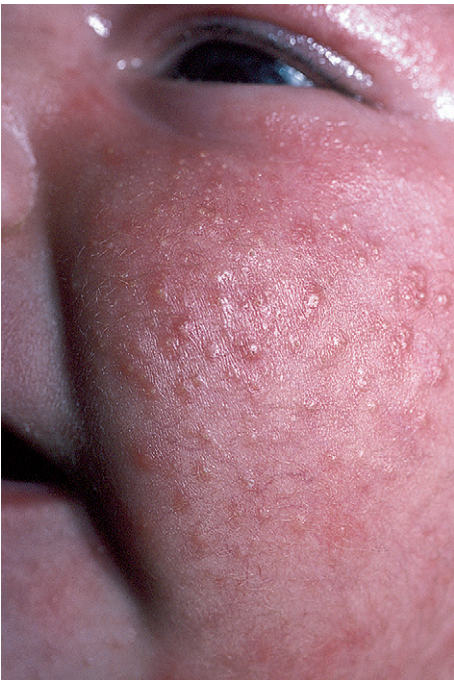

**Figure 2.9** Milia. Clustered, small white papules on the lateral cheek.





**Figure 2.10** Sebaceous gland hyperplasia. Yellow-white, pinpoint papules on the nasal tip of this 2-day-old boy.

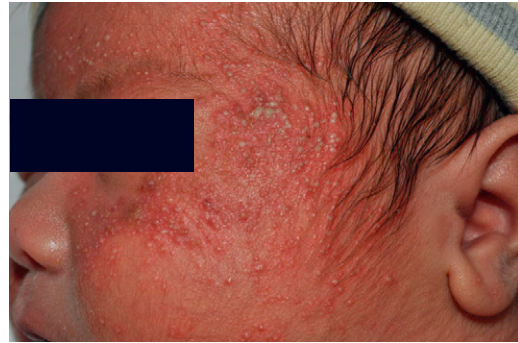

**Figure 2.11** Acne neonatorum. Erythematous papules and papulopustules on the cheek.

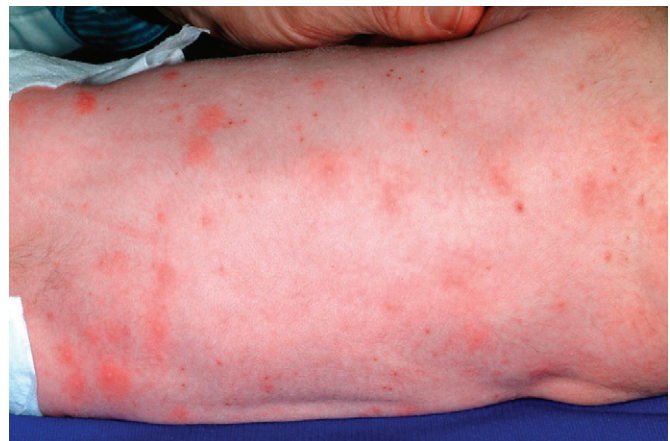
papules that occur on the nose (Fig. 2.10), cheeks, and upper lips of full-term infants. A manifestation of maternal androgen stimulation, these papules represent a temporary disorder that resolves spontaneously, generally within the first few weeks of life.

### Acne Neonatorum

Occasionally infants develop a facial eruption that resembles acne vulgaris as seen in adolescents (Fig. 2.11). Although the etiology of this disorder is not clearly defined, it appears to develop as a result of hormonal stimulation of sebaceous glands that have not yet involuted to their childhood state of immaturity. In mild cases of



**Figure 2.12** Neonatal cephalic pustulosis. This 1-week-old male had numerous small and large pustules on the forehead, cheeks and chin. They cleared rapidly with ketoconazole cream.



**Figure 2.13** Erythema toxicum neonatorum. Blotchy, erythematous macules and edematous papules.

acne neonatorum, therapy is often unnecessary; daily cleansing with soap and water may be all that is required. Occasionally, mild keratolytic agents or topical antibiotics may be helpful (see Ch. 8). Unusually severe or recalcitrant cases of acne neonatorum warrant investigation for underlying androgen excess.

A facial acneiform eruption in infants has been associated with the saprophytic *Malassezia* species, and has been termed *neonatal cephalic pustulosis*. Lesions consist of pinpoint papules, papulopustules, or larger pustules, and they are located on the cheeks, (Fig. 2.12), chin, and forehead. A correlation may exist between the clinical severity of lesions and the colonization with this fungal saprophyte.<sup>44,45</sup> In these infants, topical antifungal agents may lead to more rapid resolution of lesions.

### Erythema Toxicum Neonatorum

Erythema toxicum neonatorum (ETN), also known as toxic erythema of the newborn, is an idiopathic, asymptomatic, benign self-limiting cutaneous eruption of full-term newborns. Lesions consist of erythematous macules, papules, and pustules (Fig. 2.13), or a combination of these, and may occur anywhere on the body, especially the forehead, face, trunk, and extremities. The

fact that these lesions (which histologically reveal follicular-centered eosinophils) frequently tend to spare the palms and soles may be explained by the absence of pilosebaceous follicles in these areas.

ETN often initially appears as a blotchy, macular erythema that then develops firm 1–3 mm, pale-yellow or white papules and pustules. The erythematous macules are irregular or splotchy in appearance, varying from a few millimeters to several centimeters in diameter. They may be seen in sharp contrast to the surrounding unaffected skin, may blend into a surrounding erythema, or may progress to a confluent eruption.

Although ETN appears most frequently during the first 3–4 days of life, it has been seen at birth and may be noted as late as 10 days of age.<sup>46</sup> Exacerbations and remissions may occur during the first 2 weeks of life, and the duration of individual lesions varies from a few hours to several days. The etiology of ETN remains obscure. One study suggested that it represents an immune response to microbial colonization of the skin at the hair follicle.<sup>47</sup> ETN incidence data are variable. Some authors report an incidence as low as 4.5%; others report incidences varying from 31% to 70% of newborns.<sup>48</sup> The incidence of ETN clearly appears to increase with increasing gestational age of the infant.<sup>49</sup> No sexual or racial predisposition has been noted.

ETN is usually diagnosed clinically. Skin biopsy, which is rarely necessary, reveals a characteristic accumulation of eosinophils within the pilosebaceous apparatus. The diagnosis can be rapidly differentiated from other newborn pustular conditions by cytologic examination of a pustule smear that, with Wright's or Giemsa staining, reveals a predominance of eosinophils. Affected infants may have a peripheral eosinophilia. Although the eosinophilic response has led some observers to attribute the etiology of this disorder to a hypersensitivity reaction, specific allergens have never been implicated or confirmed.

Since erythema toxicum is a benign self-limiting asymptomatic disorder, no therapy is indicated. Occasionally, however, it may be confused with other pustular eruptions of the neonatal period, including transient neonatal pustular melanosis, milia, miliaria, and congenital infections including candidiasis, herpes simplex, or bacterial processes. Of these, the congenital infections are the most important diagnostic considerations because of the implications for possible systemic involvement. Table 2.3 lists the differential diagnosis of the newborn with vesicles or pustules.

## Eosinophilic Pustular Folliculitis

Eosinophilic pustular folliculitis (EPF) is an idiopathic dermatosis that occurs in both adults and infants, and when occurring in neonates or young infants, it may be clinically confused with other vesiculopustular disorders. Lesions consist of follicular pustules, most commonly occurring on the scalp and the extremities. They tend to recur in crops, in a similar fashion to acropustulosis of infancy (see below), and some suggest that these conditions may be related.<sup>50,51</sup> As opposed to the adult form of EPE, the infancy-associated type does not reveal lesions grouped in an annular arrangement.

Histologic evaluation reveals an eosinophilic, follicular inflammatory infiltrate, and peripheral eosinophilia may be present. EPF of infancy appears to be distinct from classic (adult) and HIV-associated EPE, although an HIV-infected infant with EPF has been reported.<sup>52</sup> Importantly, infantile EPF may occasionally be the presenting sign of hyperimmunoglobulinemia E syndrome (HIES) (see Ch. 3). Treatment for EPF is symptomatic, including topical corti-

Table 2.3 Differential diagnosis of vesicles or pustules in a newborn

Clinical disorder	Comments
Acrodermatitis enteropathica	Periorificial erosive dermatitis common
Acropustulosis of infancy	Recurrent crops of acral pustules
Eosinophilic folliculitis	Scalp and extremities most common sites
Epidermolysis bullosa	Trauma-induced blistering; bullae, and erosions
Erythema toxicum neonatorum	Blotchy erythema, evanescent
Incontinentia pigmenti	XLD; linear and whorled patterns
Infectious	
Bacterial	
Group A or B streptococci	
<i>Staphylococcus aureus</i>	Superficial blisters rupture easily
<i>Listeria monocytogenes</i>	
<i>Pseudomonas aeruginosa</i>	
Other Gram-negatives	
Fungal	
Candidiasis	Palms and soles involved; nail changes
Viral	
Herpes simplex	3 types: SEM, CNS, disseminated
Varicella zoster	
Cytomegalovirus	'Blueberry muffin' more common
Spirochetal	
Syphilis	Red macules, papules; palm and sole scaling
Langerhans cell histiocytosis	Crusting, erosions, palms and soles, LAD
Miliaria	Especially intertriginous, occluded sites
Neonatal Behçet's	
Pustular psoriasis	
Scabies	Crusting, burrows
Transient neonatal pustular melanosis	Mainly blacks; pigment persists for months
Urticaria pigmentosa	Stroking leads to urtication (Darier's sign)

XLD, X-linked dominant; SEM, skin-eyes-mouth; CNS, central nervous system; LAD, lymphadenopathy.

costeroids and antihistamines, with eventual spontaneous resolution by 3 years of age in the majority of patients.

## Impetigo Neonatorum

Impetigo in newborns may occur as early as the second or third day or as late as the second week of life. It usually presents as a superficial vesicular, pustular, or bullous lesion on an erythematous base. Vesicles and bullae are easily denuded, leaving a red, raw, and moist surface, usually without crust formation. Blisters are often wrinkled, contain some fluid, and are easily denuded. Lesions tend to occur

on moist or opposing surfaces of the skin, as in the diaper area, groin, axillae, and neck folds. *S. aureus pustulosis* (or *neonatal pustulosis*) is a characteristic manifestation of cutaneous *S. aureus* infection in the neonate or infant. Patients present with small pustules on an erythematous base (Fig. 2.14A), often distributed in the diaper region. The lesions denude easily upon swabbing (Fig. 2.14B), and culture is positive for *S. aureus*. In term or late pre-term neonates with localized involvement, and without fever or systemic symptoms, evaluation for serious bacterial illness is generally not required, and treatment in the outpatient setting is often sufficient.<sup>53</sup>

The term *pemphigus neonatorum* is an archaic misnomer occasionally applied to superficial bullous lesions of severe impetigo widely distributed over the surface of the body. However, a transient neonatal form of pemphigus vulgaris does exist, and is caused by transplacental passage of antibodies from a mother with the same disease (see Ch. 13).

### Sucking Blisters

Sucking blisters, presumed to be induced by vigorous sucking on the affected part *in utero*, are seen in up to 0.5% of normal newborns as 0.5–2 cm oval bullae or erosions on the dorsal aspect of the fingers, thumbs, wrists, lips, or radial aspect of the forearms. These lesions, which must be differentiated from bullous impetigo,

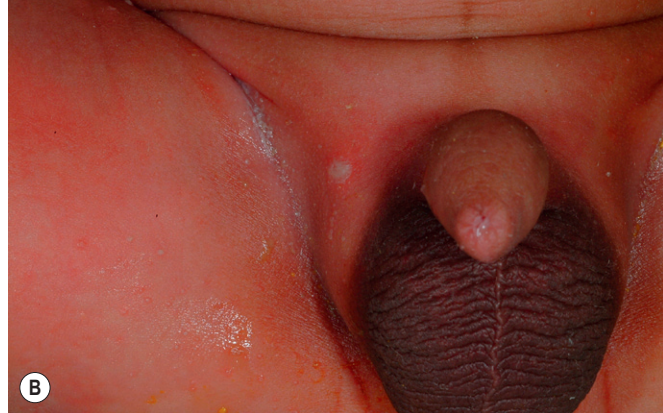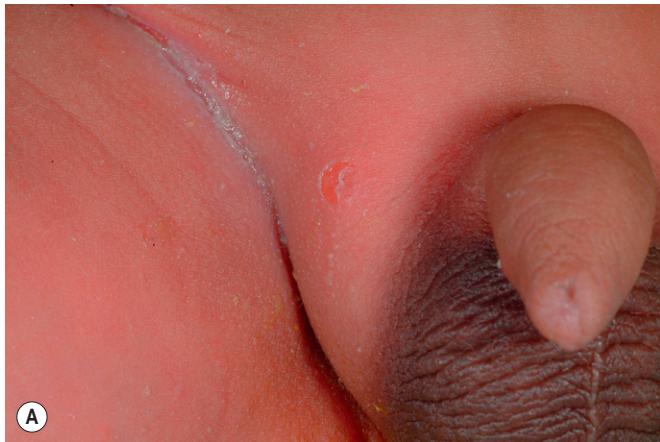epidermolysis bullosa, and herpes neonatorum, resolve rapidly and without sequelae.

### Transient Neonatal Pustular Melanosis

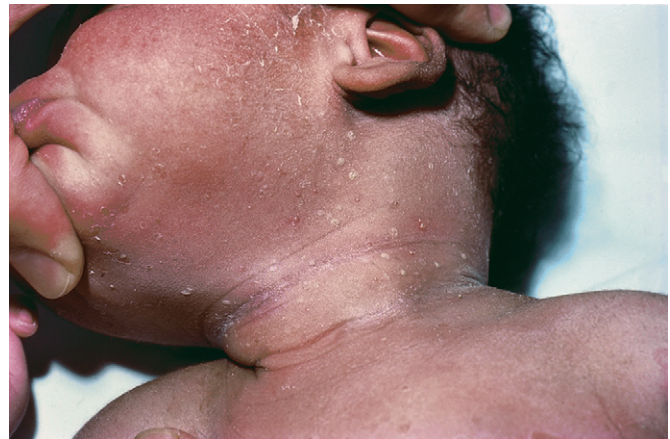Transient neonatal pustular melanosis (TNPM) is a benign self-limiting disorder of unknown etiology characterized by superficial vesiculopustular lesions that rupture easily and evolve into hyperpigmented macules (Fig. 2.15). This disorder is seen in <1% of newborns,<sup>54</sup> and occurs most commonly in infants with black skin. Lesions begin as superficial sterile pustules (Fig. 2.16) that rupture easily to leave a collarette of fine white scale around a small hyperpigmented macule. Although the distribution may be diffuse, common areas of involvement include the inferior chin, forehead, neck, lower back, and shins. Rarely, vesicles that do not progress to pigmented macules may be detected on the scalp, palms, and soles.

Wright-stained smears of the pustules of TNPM, in contrast to lesions of erythema toxicum neonatorum, demonstrate variable numbers of neutrophils, few or no eosinophils, and cellular debris. Histopathologic evaluation is usually unnecessary.

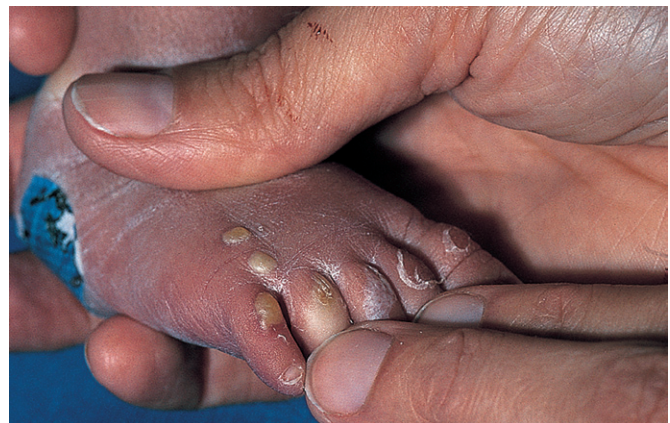TNPM is a benign disorder without associated systemic manifestations, and therapy is unnecessary. The pustular lesions usually



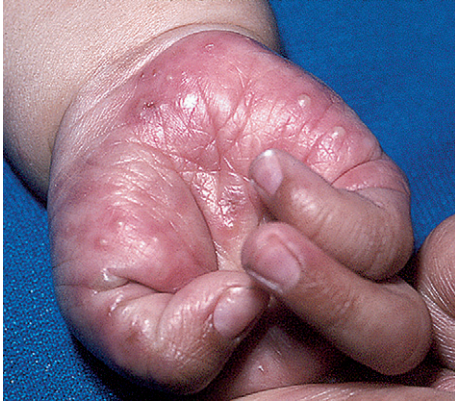**Figure 2.14** Neonatal *S. aureus* pustulosis. Pustule on a red base in the groin of a 6-day-old male (A). Note easy denudation and superficial erosion following skin swabbing (B). The culture was positive for *Staphylococcus aureus*.



**Figure 2.15** Transient neonatal pustular melanosis. Papules and papulopustules which rupture to leave a collarette of fine scales and eventual hyperpigmentation. (Courtesy of Nancy B. Esterly MD)



**Figure 2.16** Transient neonatal pustular melanosis. Tense pustules and collarettes of scale at sites of older lesions.



**Figure 2.17** Acropustulosis of infancy. Multiple tense erythematous papules and pustules on the palm of this 4-month-old girl.

disappear within 24–48 h, leaving behind hyperpigmented macules that fade gradually, usually over several weeks to months.

### Acropustulosis of Infancy

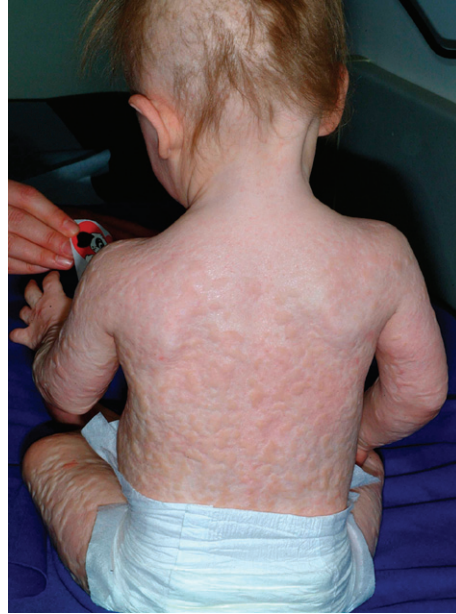Acropustulosis of infancy, also known as infantile acropustulosis (IA), is an idiopathic pustular disorder with onset usually between birth and 2 years of age. It is characterized by recurrent, pruritic vesiculopustular lesions that recur every few weeks to months. The lesions begin as pinpoint erythematous papules and enlarge into well-circumscribed discrete pustules.<sup>55</sup> They are concentrated on the palms (Fig. 2.17) and soles and appear in lesser numbers on the dorsal aspect of the hands, feet, wrists, and ankles. Occasional lesions may occur on the face and scalp.

The differential diagnosis of IA includes dyshidrotic eczema, pustular psoriasis, erythema toxicum neonatorum, transient neonatal pustular melanosis, scabies, impetigo, and subcorneal pustular dermatosis. However, the characteristic presentation and course of IA is usually distinctive enough to render a clinical diagnosis. A smear of pustule contents (or histologic evaluation) reveals large numbers of neutrophils, and occasionally eosinophils.<sup>55–58</sup> Although the etiology of IA remains unclear, several authors have noted a possible association with preceding scabies infestation.<sup>59–61</sup>

Patients with IA experience fewer and less intense flares of their lesions with time, and the entire process usually subsides within 2–3 years. Pruritus, however, may be severe early in the course, making therapy desirable. Possible associations include irritability, sleeplessness, excoriation, and secondary bacterial infection. Systemic antihistamines, usually in high doses, may relieve pruritus. High-potency topical corticosteroids are quite effective for this condition,<sup>59</sup> and given the limited distribution of lesions, the epidermal thickness at affected (acral) sites, and the periodicity of flares, concerns regarding systemic absorption of these medications should be minimal. Dapsone has long been a recommended therapy for severe cases, but the risk-to-benefit ratio of this agent is not generally justified in patients with IA.

### Congenital Erosive and Vesicular Dermatitis

Congenital erosive and vesicular dermatitis healing with reticulated supple scarring is an uncommon disorder characterized by erosive and bullous lesions that, as the name implies, are present at birth and heal with characteristic scarring. Although its cause is



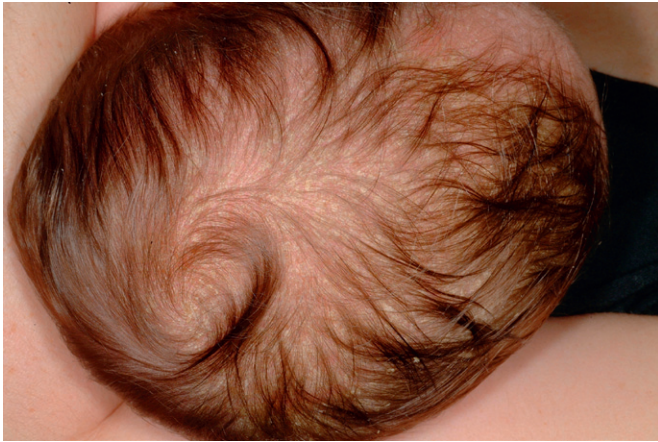**Figure 2.18** Congenital erosive and vesicular dermatitis healing with reticulated supple scarring. Generalized, supple, reticulated scarring. Note also the associated scalp alopecia.

unknown, it appears to represent a non-hereditary intrauterine event, such as infection or amniotic adhesions, or perhaps an unusual healing defect of immature skin. The disorder generally involves skin of the trunk, extremities, scalp, face, and occasionally the tongue, with sparing of the palms, and soles.

Congenital erosive and vesicular dermatitis occurs most often in premature infants, and patients present with extensive cutaneous ulcerations and intact vesicles that develop crusting and then heal during the first month of life. Occasionally, blistering may continue to occur beyond infancy.<sup>62</sup> Generalized, supple reticulated scars occur with alternating elevated and depressed areas (Fig. 2.18). Up to 75% of the cutaneous surface may be involved, and the skin lesions have been described as having depressed hypopigmented regions alternating with normally hyperpigmented zones.<sup>63,64</sup> Scars on the trunk and head, which often have a cobblestone-like appearance, may be oriented along the cutaneous lines of cleavage; on the limbs they tend to follow the long axes of the extremities.<sup>64–66</sup> Although the eyebrows are usually normal, alopecia may be noted on the scalp. Nails may be absent or hypoplastic, and affected areas on the tongue may manifest scarring and absence of papillae. Hyperthermia, especially in warm weather or after exertion, is common and although sweating is absent in scarred areas, compensatory hyperhidrosis in normal-appearing skin may be noted. Chronic conjunctivitis is a major continuing problem for these patients, and corneal scarring may occur.<sup>62,63</sup> Some patients have also been found to have neurologic defects, including mental and motor retardation, hemiparesis, cerebral palsy, and seizures.<sup>63</sup>

### Seborrheic Dermatitis

Seborrheic dermatitis is a common, self-limiting condition of the scalp, face, ears, trunk, and intertriginous areas characterized by greasy scaling, redness, fissuring, and occasional weeping. It appears to be related to the sebaceous glands and has a predilection for so-called 'seborrheic' areas where the density of these glands is high. It usually presents in infants with a scaly dermatitis of the scalp termed *cradle cap* (Fig. 2.19), and may spread over the face,



**Figure 2.19** Seborrheic dermatitis of the scalp (cradle cap). Erythema and greasy yellow scales involving the scalp of an infant male, who also had similar changes in the eyebrows.

including the forehead, ears, eyebrows, and nose. Other areas of involvement include the intertriginous zones, umbilicus, and anogenital region. (For a more detailed discussion of seborrheic dermatitis and its therapy, see Ch. 3.)

### Leiner Disease

The term *Leiner disease* refers to a shared phenotype for a number of nutritional and immunologic disorders, characterized by severe seborrheic dermatitis with exfoliation, failure to thrive, and diarrhea. The disorder may occur during the first week of life but generally starts around 2–4 months of age. Patients are particularly prone to recurrent yeast and Gram-negative infections. Among disorders that may show this phenotype are: deficiency or dysfunction of complement, Bruton's hypogammaglobulinemia, severe combined immunodeficiency, and HIES.<sup>67–71</sup>

### Diaper Dermatitis

Diaper dermatitis is perhaps the most common cutaneous disorder of infancy and early childhood. The term is used to describe an acute inflammatory skin reaction in the areas covered by the diaper. The incidence of diaper dermatitis is estimated to be between 7% and 35%, with a peak incidence at 9–12 months of age.<sup>72–74</sup>

The term *diaper rash* is frequently used as a diagnosis, as though the diverse dermatoses that may affect this region constitute a single clinical entity. In actuality, diaper dermatitis is not a specific diagnosis and is best viewed as a variable symptom-complex initiated by a combination of factors, the most significant being prolonged contact with urine and feces, skin maceration, and, in many cases, secondary infection with bacteria or *Candida albicans*. Although diaper dermatitis may frequently be no more than a minor nuisance, eruptions in this area may not only progress to secondary infection and ulceration, but may become complicated by other superimposed cutaneous disorders or represent a manifestation of a more serious disease.

The three most common types of diaper dermatitis are chafing dermatitis, irritant contact dermatitis, and diaper candidiasis. However, the differential diagnosis of diaper dermatitis is broad (Table 2.4). In patients in whom a response to therapy is slow or absent, alternative diagnoses should be considered and appropriate diagnostic evaluations performed. The following is a brief

Table 2.4 Differential diagnosis of diaper dermatitis

Chafing dermatitis
Irritant contact dermatitis
Diaper candidiasis
Seborrheic dermatitis
Psoriasis
Intertrigo
Jacquet's dermatitis
Perianal pseudoverrucous papules and nodules
Miliaria
Folliculitis
Impetigo
Scabies
Nutritional deficiency (i.e., acrodermatitis enteropathica, cystic fibrosis, biotin deficiency)
Allergic contact dermatitis
Atopic dermatitis
Granuloma gluteale infantum
Langerhans cell histiocytosis
Burns
Child abuse
Epidermolysis bullosa
Congenital syphilis
Varicella/herpes
Tinea cruris
Chronic bullous dermatosis of childhood
Bullous mastocytosis

discussion of several potential causes of diaper dermatitis. Many of these entities are discussed in more detail in other chapters.

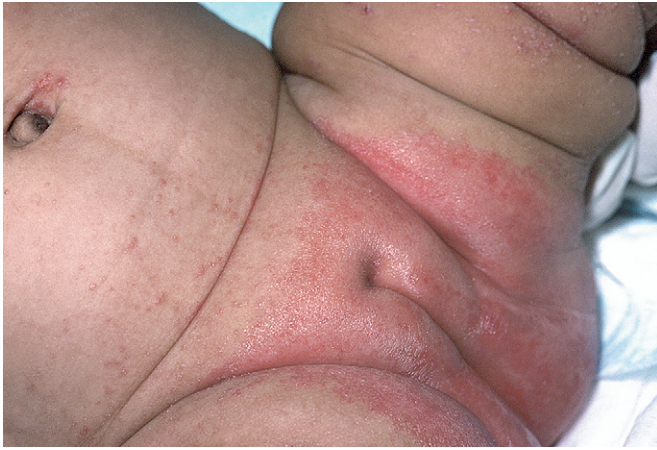#### Chafing dermatitis

The most prevalent form of diaper dermatitis is the chafing or frictional dermatitis that affects most infants at some time. Generally present on areas where friction is the most pronounced (the inner surfaces of the thighs, the genitalia, buttocks, and the abdomen), the eruption presents as mild redness and scaling and tends to wax and wane quickly. This form responds quickly to frequent diaper changes and good diaper hygiene.

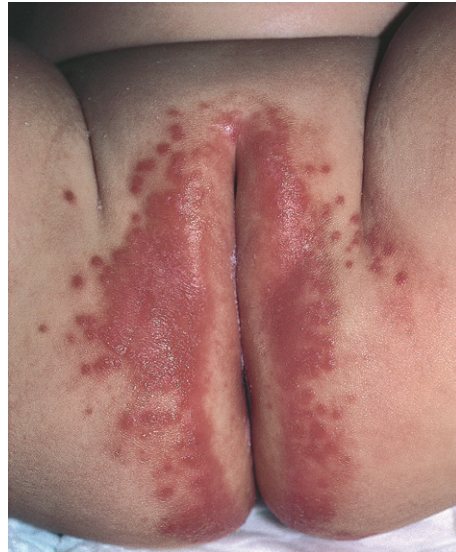#### Irritant contact dermatitis

Irritant contact diaper dermatitis usually involves the convex surfaces of the buttocks, the vulva, perineal area, lower abdomen, and proximal thighs, with sparing of the intertriginous creases (Fig. 2.20). The disorder may be attributable to contact with proteolytic enzymes in stool and irritant chemicals, such as soaps, detergents, and topical preparations. Other significant factors appear to be excessive heat, moisture, and sweat retention associated with the warm local environment produced by the diaper.

The etiology of irritant contact diaper dermatitis is multifactorial, and past hypotheses have included potential roles for ammonia, bacteria, and bacterial products and urine pH. In 1921, when Cooke demonstrated that an aerobic Gram-positive bacillus (*Bacillus ammoniagenes*) was capable of liberating ammonia from urea, this organism was pinpointed as the etiologic agent of most diaper dermatoses.<sup>75</sup> More recent studies, however, have refuted the role of urea-splitting bacteria in the etiology of this disorder and incriminate a combination of wetness, frictional damage, impervious diaper coverings, and increase in skin pH. It is suggested that urinary wetness increases the permeability of the skin to irritants as well as the pH of the diaper environment, thus intensifying the activities of the fecal proteases and lipases, the major irritants responsible for this disorder.<sup>76,77</sup>



**Figure 2.20** Irritant contact diaper dermatitis. Erythema of the vulva, buttocks, and medial thighs. The inguinal creases were relatively spared.



**Figure 2.21** Diaper candidiasis. Beefy-red, erythematous plaques with multiple red satellite papules and papulopustules.

Several technological innovations in the design of disposable diapers and other diapering products have aimed to reduce moisture and irritancy in this environment, thus decreasing the risk of irritant dermatitis. The introduction of absorbent gelling materials into diaper technology was one such breakthrough, and has been shown to result in less diaper dermatitis than conventional cellulose core disposable diapers.<sup>78</sup> Other recent innovations include non-irritating disposable diaper wipes and diapers designed to deliver petrolatum-based formulations to the skin.<sup>79</sup>

### Diaper candidiasis

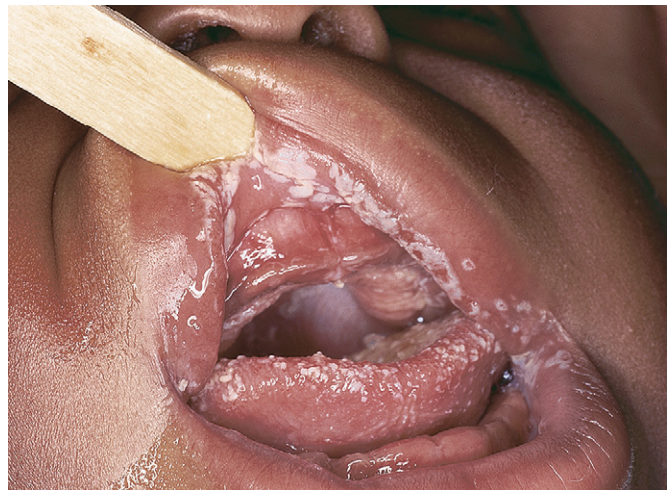Candidal (monilial) diaper dermatitis is a commonly overlooked disorder and should be suspected whenever a diaper rash fails to respond to usual therapeutic measures. Cutaneous candidiasis is a possible sequela of systemic antibiotic therapy and should be considered in any diaper dermatitis that develops during or shortly following antibiotic administration.<sup>80</sup>

Candidal diaper dermatitis presents as a widespread, beefy red erythema on the buttocks, lower abdomen, and inner aspects of the thighs. Characteristic features include a raised edge, sharp marginization with white scales at the border, and pinpoint pustulovesicular satellite lesions (the diagnostic hallmark) (Fig. 2.21). Although cutaneous candidiasis frequently occurs in association with oral thrush (Fig. 2.22), the oral mucosa may be uninvolved. Infants harbor *C. albicans* in the lower intestine, and it is from this focus that infected feces present the primary source for candidal diaper eruptions.

If necessary, the diagnosis of candidal diaper dermatitis may be confirmed by microscopic examination of a potassium hydroxide preparation of skin scrapings, which reveals egg-shaped budding yeasts and hyphae or pseudohyphae. Growth of yeast on Sabouraud's medium implanted with skin scrapings can also confirm the diagnosis, usually within 48–72 h.

### Seborrheic dermatitis

Seborrheic dermatitis of the diaper area may be recognized by the characteristic salmon-colored, greasy plaques with a yellowish scale and a predilection for intertriginous areas (see above). Coincident involvement of the scalp, face, neck, and postauricular and flexural areas helps to establish the diagnosis.



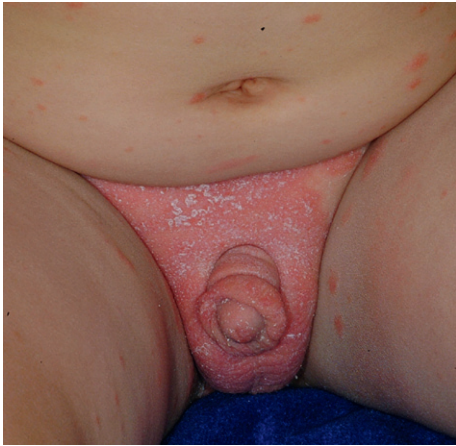**Figure 2.22** Oral candidiasis (thrush). Gray-white, cheesy patches and plaques of the buccal mucosa, tongue, and gingiva.

### Psoriasis

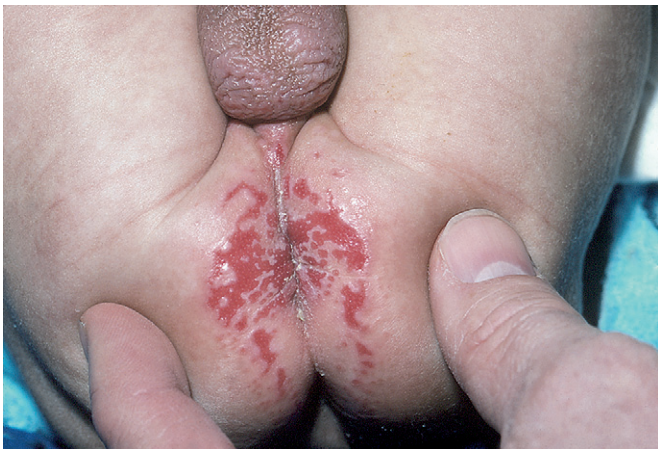Psoriasis of the diaper area must also be considered in persistent diaper eruptions that fail to respond to otherwise seemingly adequate therapy (Fig. 2.23). The sharp demarcation of lesions suggests diaper area psoriasis, but the typical scaling of psoriasis may be obscured because of the moisture of the diaper region. The presence of nail changes and red, well-margined plaques with silvery mica-like scales on the trunk, face, axillae, umbilicus, or scalp may help confirm this diagnosis (see Ch. 4), although affected infants may have involvement limited to the diaper area.

### Intertrigo

Intertrigo (see Ch. 17) is a common skin eruption in the diaper area, particularly in hot weather or when infants are overdressed. It usually involves the inguinal creases, the intergluteal area, and the thigh creases (especially in chubby babies), and presents as bright red erythema often with a mild white-yellow exudate.



**Figure 2.23** Psoriasis (diaper). Sharply demarcated, erythematous, scaly plaques involving the genitals and suprapubic region in this infant male.



**Figure 2.24** Jacquet's dermatitis. Severe diaper area erythema with ulcerated papules and islands of re-epithelialization.

Nondiapered areas of involvement include the anterior neck fold and the axillae.

#### Jacquet's dermatitis

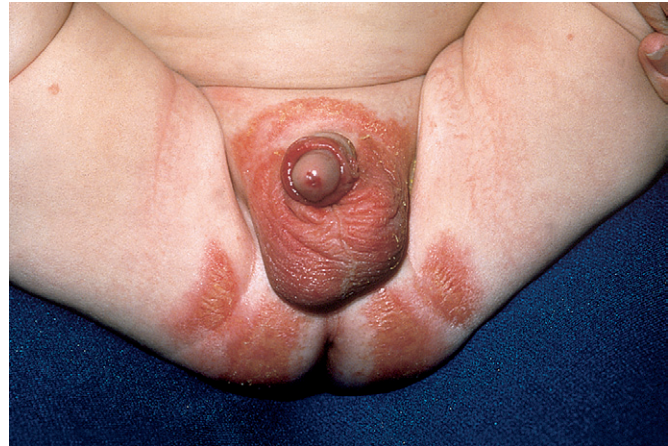The term *Jacquet's dermatitis* is used to describe a severe erosive diaper eruption with ulcerated papules or nodules (Fig. 2.24). In male infants, erosion and crusting of the glans penis and urinary meatus may result in painful or difficult urination.

#### Perianal pseudoverrucous papules and nodules

An eruption composed of verrucous (wart-like) papules has been observed to occur in children with incontinence of stool or urine. These patients present with verrucous papules and nodules of the perianal and suprapubic regions, possibly representing a distinct reaction to severe irritant diaper dermatitis. Reported patients had a history of delayed ileoanal anastomosis for Hirschsprung disease, encopresis, or urinary incontinence.<sup>81-83</sup> The importance of this diagnosis lies in differentiating it from condylomata acuminata or other more serious dermatoses.

#### Acrodermatitis enteropathica

Acrodermatitis enteropathica, a disorder of zinc deficiency, may mimic a severe irritant contact dermatitis in the diaper area (see Ch.



**Figure 2.25** Acrodermatitis enteropathica. Eroded, erythematous patches and plaques in this 4-month-old boy with zinc deficiency. Note the associated balanoposthitis.

24). Patients present with a periorificial erosive dermatitis, which is often most accentuated in the diaper region (Fig. 2.25) but also may involve the perioral face. Erythema and pustules may involve intertriginous or acral sites, and diarrhea, failure to thrive, and alopecia are frequently present.

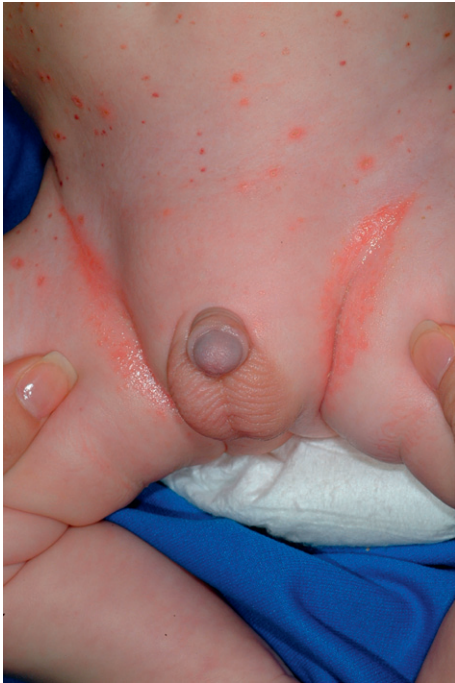#### Langerhans cell histiocytosis

Lesions of Langerhans cell histiocytosis (LCH; see Ch. 10) may also have a predilection for the diaper area. This eruption, which often presents in a seborrheic dermatitis-like fashion, classically involves the groin, axillae, and retroauricular scalp. Palms and soles may also be involved. Characteristic lesions consist of yellowish to red-brown papules, often with concomitant erosive or purpuric qualities (Fig. 2.26). LCH should be considered in any infant with a recalcitrant or hemorrhagic seborrheic dermatitis-like eruption and/or flexural papules with erosions. Lymphadenopathy is common, and multi-organ involvement (especially bones, liver, lung, mucosa, and middle ear) is possible. Skin biopsy with special stains for Langerhans cells is diagnostic.

#### Treatment of diaper dermatitis

Prior to any consideration for therapy of diaper dermatitis, the appropriate etiology must be identified. Educating parents that diaper dermatitis is often recurrent is vital in an effort to prevent perceived management failure. The primary goals in preventing and treating diaper dermatitis include keeping the skin dry, protected, and infection-free.<sup>84</sup>

The primary goal in irritant or chafing dermatitis is to keep the area as clean and dry as possible. Frequent diaper changes, gentle cleansing with a moistened soft cloth or fragrance-free diaper wipe, exposure to air whenever possible, and the judicious use of topical therapy may be sufficient in most cases. Zinc oxide and petrolatum-based formulations tend to be most effective in forming a barrier to further skin contact with urine and feces. These products should be applied at every diaper change when acute dermatitis is present. Parents should be taught that diaper area cleansing is necessary only when stool is present, as overwashing in itself can lead to irritation. A low-potency, non-fluorinated topical corticosteroid (i.e., 1% hydrocortisone) applied two to three times daily is appropriate until improvement is noted. Stronger steroids and combination antifungal-corticosteroid preparations should be avoided, given risks of local cutaneous side-effects and, more important, systemic



**Figure 2.26** Langerhans cell histiocytosis. Red-brown, purpuric eroded papules in a 3-month-old male. Note intertrigo-like erythema of the inguinal creases with superficial erosions.

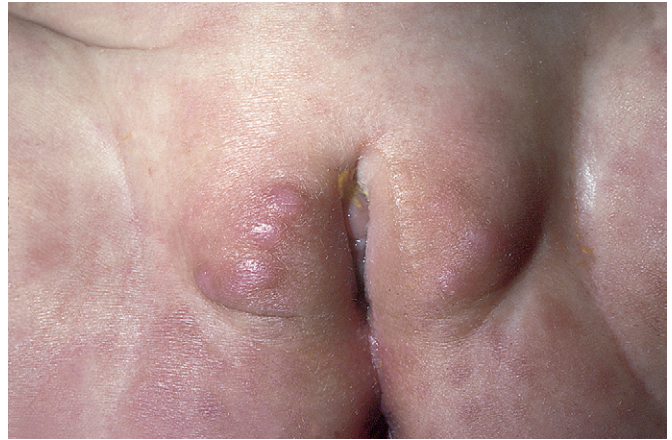absorption because of increased skin penetration from occlusion effect.

Secondarily infected (bacterial) dermatitis should be treated with the appropriate systemic antibiotic. Candidal infection requires the use of a topical antifungal agent (i.e., nystatin, clotrimazole, econazole, miconazole). If there is evidence of *Candida* in the mouth (i.e., thrush) as well as the diaper area, topical therapy may be supplemented by oral nystatin. Oral fluconazole is useful for severe cutaneous candidiasis. Although gentian violet has been used for decades for the treatment of oral and diaper candidiasis, reports of bacterial infection and hemorrhagic cystitis, in addition to the staining associated with its use, suggest that gentian violet be avoided.<sup>85,86</sup> A newer combination product (0.25% miconazole nitrate, 15% zinc oxide, and 81.35% white petrolatum) is also available.

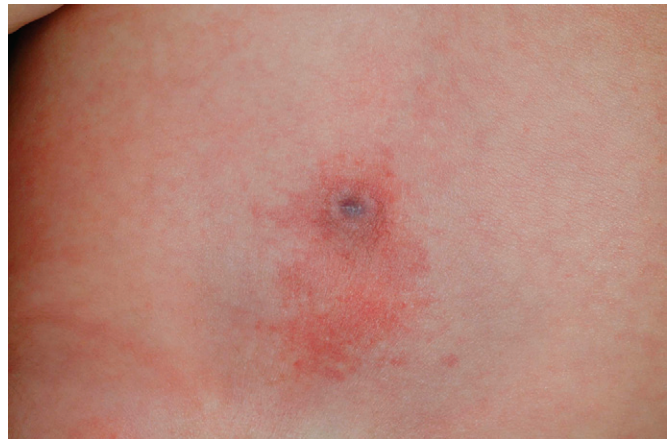### Granuloma Gluteale Infantum

*Granuloma gluteale infantum* is a benign disorder of infancy characterized by purple-red nodules in the skin of the groin (Fig. 2.27), lower abdomen, and inner thighs. Patients have usually received preceding therapy with topical corticosteroids. Although the appearance of these lesions may suggest a malignant process, granuloma gluteale infantum seems to represent a unique response to local inflammation, maceration, and possibly secondary infection (usually *C. albicans*). A similar eruption has been observed in elderly adults.<sup>87</sup> Histologic evaluation of granuloma gluteale infantum reveals a nonspecific inflammatory infiltrate, sometimes with giant cells.<sup>88,89</sup>

Lesions of granuloma gluteale infantum resolve completely and spontaneously within a period of several months after treatment of the initiating inflammatory process. Although intralesional corticosteroids or steroid-impregnated tape have been used, such therapy is not recommended.



**Figure 2.27** Granuloma gluteale infantum. Erythematous to violaceous papulonodules on the labia majora of this infant with a history of potent topical corticosteroid use in the diaper region.



**Figure 2.28** Lumbosacral port-wine stain associated with occult spinal dysraphism. Note the associated central depression in this boy who also had an underlying tethered spinal cord.

## Developmental abnormalities of the newborn

### Skin Signs of Occult Spinal Dysraphism

Spinal dysraphism is a spectrum of disorders defined by absent or incomplete fusion of the midline bony elements and may include congenital spinal cord anomalies.<sup>90</sup> Because occult spinal dysraphism (OSD) can lead to irreversible neurologic complications, early recognition is desirable. Cutaneous or subcutaneous stigmata may be the presenting sign of OSD, and as such, a working knowledge of potentially associated lesions is vital. Lumbosacral skin lesions that may be associated with OSD and spinal cord defects include hypertrichosis (the classic 'faun tail' or finer, lanugo hair), lipomas, vascular lesions (infantile hemangioma, port-wine stain) (Fig. 2.28), prominent sacral dimples, sinuses, appendages (skin tag, tail), aplasia cutis congenita, and melanocytic nevi.<sup>91</sup> Gluteal cleft asymmetry or deviation is another useful finding. The presence of multiple findings increases the risk of OSD.<sup>92</sup> In one study, 11 of 18 patients with two or more congenital midline skin lesions has OSD, and the most common midline cutaneous lesion to be associated with OSD was lipomas (either isolated or in combination with other lesions).<sup>93</sup>



The majority of simple midline dimples are not associated with OSD. Atypical dimples (>5 mm in size, further than 2.5 cm from the anus, associated with other lumbosacral lesions), on the other hand, have a significant risk of associated OSD.<sup>92</sup> The association of nevus simplex (small dull-pink vascular malformation, most commonly seen on the occipital scalp, glabella, or eyelids) of the sacrum and OSD is unclear, although most agree that these lesions, when occurring alone, do not predict an increased risk of underlying malformations. Cervical OSD is significantly less common, and in those cases associated with cutaneous stigmata, more than one lesion is usually present.<sup>94</sup> It is important to remember that an isolated nevus simplex ('stork bite') of the posterior nuchal or occipital region is *not* an indicator of underlying OSD.

When OSD is being considered, radiographic imaging must be performed. Magnetic resonance imaging is the diagnostic modality of choice, especially with higher-risk cutaneous findings. Ultrasound screening may be considered in infants younger than 4 months (before ossification of the vertebral bodies is complete), with the advantages being that it is non-invasive and does not require sedation. However, ultrasonography is limited in that small cord lesions (i.e., lipoma or dermal sinus tracts) may be missed,<sup>92</sup> and the overall sensitivity is quite dependent on the experience of the ultrasonographer. In infants with low-risk lesions such as simple dimples or gluteal cleft deviation, without other higher-risk findings (i.e., hypertrichosis, skin tags, lipoma or other mass), the need for imaging is unclear. If it is performed, however, ultrasound may provide a reliable screening when interpreted by an experienced pediatric radiologist.<sup>95</sup> Early neurosurgical referral is indicated if underlying defects are diagnosed.

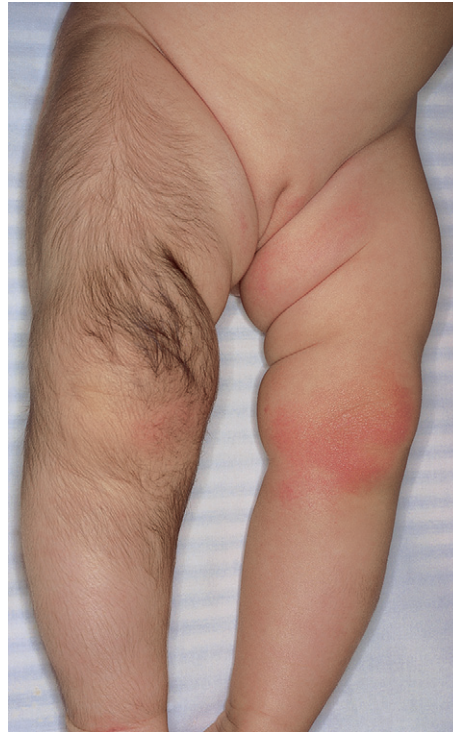### Drug-induced Fetal Skin Malformations

There are numerous drugs, including alcohol, hydantoin, valproic acid, warfarin, aminopterin, and isotretinoic acid, that, when taken by pregnant women, produce an adverse effect on the fetus and newborn. Exposure to these drugs *in utero* may result in a variety of organ malformations, although specific skin malformations are rare. Teratogenic risks as they relate to skin have most frequently focused on antithyroid drugs, especially methimazole (MMI), and their possible role in causing the congenital skin defect known as *aplasia cutis congenita* (ACC, see below).

### Congenital Hemihypertrophy

Idiopathic congenital hemihypertrophy is a developmental defect in which one side of the body is larger than the other. Although differences in symmetry are often detectable during the newborn period, they usually become more striking with growth of the child. The cutaneous findings most often associated with hemihypertrophy are hyperpigmentation, telangiectasia, abnormal nail growth, and hypertrichosis (Fig. 2.29). Body temperature and sweating differences have also been reported in patients with this disorder.<sup>96</sup>

Of particular significance is the fact that about 50% of persons with hemihypertrophy may have associated anomalies, including Wilms' tumor, aniridia, cataracts, ear deformities, internal hemanangiomas, genitourinary tract anomalies, adrenocortical neoplasms, and brain tumors. Patients who exhibit congenital hemihypertrophy, therefore, should be evaluated for potentially associated conditions. Associated tumors most commonly involve the kidney, adrenal gland, and liver.<sup>97</sup> In patients with hemihypertrophy combined with cutaneous vascular malformations (i.e., port-wine stain), the possibility of Klippel-Trenaunay or Proteus syndrome should be considered (see Ch. 12).



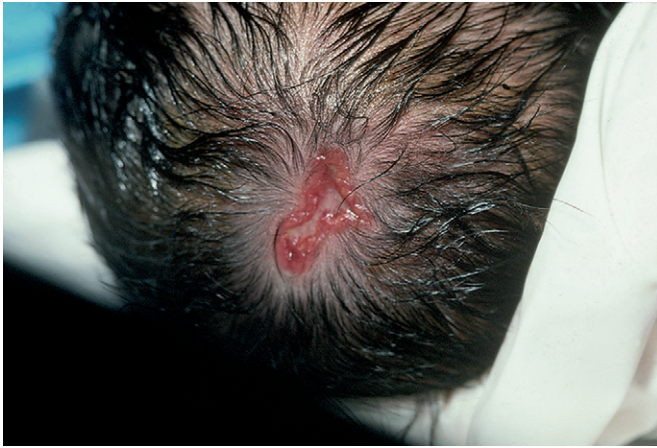**Figure 2.29** Congenital hemihypertrophy with hypertrichosis. (From Hurwitz S, Klaus SN. Congenital hemihypertrophy with hypertrichosis. *Arch Dermatol* 1971;103:98–100. © 1971 American Medical Association. All rights reserved.)<sup>96</sup>

### Aplasia Cutis Congenita

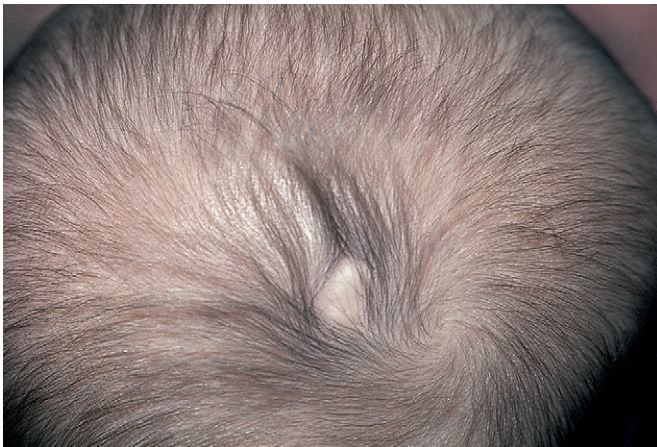*Aplasia cutis congenita* (ACC) is a congenital defect of the skin characterized by localized absence of the epidermis, dermis, and at times, subcutaneous tissues. Although ACC generally occurs on the scalp, it may also involve the skin of the face, trunk, and extremities. The diagnosis of ACC is usually a clinical one, and the histologic picture varies. Although most cases appear to be sporadic, a variety of potential associations, including teratogens, limb abnormalities, epidermal nevi, underlying embryologic malformations, epidermolysis bullosa, malformation syndromes, and infections, have been proposed.<sup>98</sup>

ACC classically presents as solitary or multiple, sharply demarcated, weeping or granulating, oval to circular, stellate defects ranging from 1 to 3 cm in diameter. Some 70% of scalp lesions are isolated, 20% are double, and in 8% of patients three or more defects may be present.<sup>99</sup> The most common location for ACC is the scalp, and in those cases, 80% occur in close proximity to the hair whorl.<sup>100</sup> Although aplasia cutis may also affect the occiput, the postauricular areas, and the face, involvement of these areas appears to be relatively uncommon. Whereas most scalp defects are small, larger lesions may occur and can extend to the dura or the meninges. Although treatment is generally unnecessary, large scalp lesions (i.e., >4 cm<sup>2</sup>) may require surgery with grafting to prevent the potential complications of hemorrhage, venous (sagittal sinus) thrombosis, and meningitis.

At birth, the skin defect may vary from an ulceration with a granulating base (Fig. 2.30) to a superficial erosion or even a well-formed scar. As healing of open lesions occurs, the defect is replaced by smooth, hairless scar tissue (Fig. 2.31), although sometimes raised and keloidal. Some lesions may present as a translucent, glistening membrane ('membranous aplasia cutis'), and when



**Figure 2.30** Aplasia cutis congenita. Sharply demarcated ulceration on the scalp of an infant with this disorder.

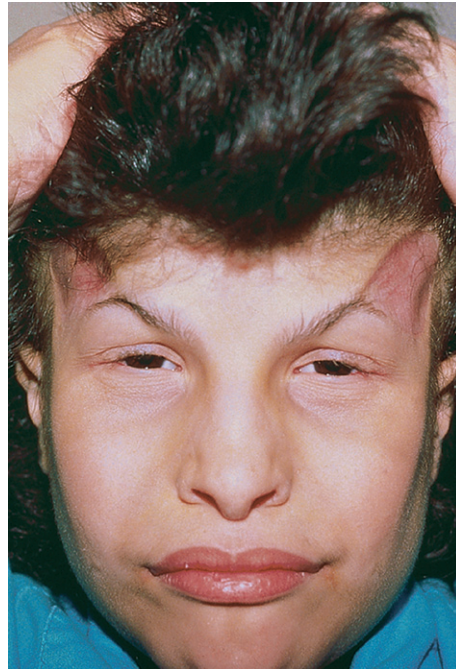

**Figure 2.31** Aplasia cutis congenita. Healed scar with alopecia near the hair whorl in this 8-month-old girl.

surrounded by a ring of long, dark hair (the 'hair collar sign'), may represent a form fruste of a neural tube defect.<sup>101</sup>

Although most infants with ACC are otherwise well, defects that may occasionally be present include cleft lip and palate, ophthalmologic defects, limb reduction defects, cardiac anomalies, gastrointestinal tract malformations, spinal dysraphism, hydrocephalus, defects of the underlying skull, congenital midline porencephaly, spastic paralysis, seizures, mental retardation, and vascular anomalies.<sup>98</sup> *Adams–Oliver syndrome*, an autosomal dominant malformation syndrome, is the association of ACC with transverse limb defects and cardiac and central nervous system abnormalities.<sup>102,103</sup> Up to 50% of patients with *trisomy 13* may have scalp ACC, and it may also occur with increased frequency in patients with *4p-* syndrome. Therefore, any patient presenting with scalp ACC and congenital anomalies warrants chromosomal evaluation. *Oculocerebrocutaneous (Delleman) syndrome* is the association of orbital cysts, cerebral malformations, and focal skin defects including ACC-like lesions and skin tags.<sup>104,105</sup> Other findings in this syndrome include central nervous system malformations, clefting, and microphthalmia/anophthalmia.

The etiology of aplasia cutis congenita remains unknown. Although most cases are sporadic, familial case reports have suggested autosomal dominant inheritance with reduced penetrance.



**Figure 2.32** Setleis syndrome. A child with bilateral depressed oval areas on the temples, upwardly slanting eyebrows, narrowed palpebral fissures, and large lips. (Courtesy of Seth Orlow, MD.)

Incomplete closure of the neural tube or an embryologic arrest of skin development has been suggested as an explanation for midline lesions. This hypothesis, however, fails to account for lesions of the trunk and limbs. In such instances, vascular abnormality of the placenta, with a degenerative rather than an aplastic or traumatic origin, has been postulated as the cause of the cutaneous defects.<sup>106</sup> Antithyroid drugs, most notably methimazole (MMI), have long been hypothesized as causative teratogens in some cases of ACC. Although causality remains unproven, there are multiple reports of affected infants born to mothers treated with MMI during pregnancy, both as an isolated manifestation and as part of the presentation of 'MMI embryopathy', which includes dysmorphism, gastrointestinal tract malformations, and developmental delay.<sup>107</sup> Propylthiouracil has been recommended as the first-line agent in the management of hyperthyroidism during pregnancy, given its equal effectiveness and lack of reports of teratogenic ACC.<sup>108</sup>

Recognition of ACC and differentiation of it from forceps or other birth injury will help prevent possible medicolegal complications occasionally encountered with this disorder. In patients with localized sporadic lesions, aside from cutaneous scarring, the prognosis of ACC is excellent. With conservative therapy to prevent further tissue damage and secondary infection, most small defects of the scalp heal well during the first few weeks to months of life. With aging of the child, most scars become relatively inconspicuous and require no correction. Those that are large and obvious can be treated with plastic surgical reconstruction.

### Setleis syndrome

*Setleis syndrome* was initially described in 1963 by Setleis and colleagues, who described five children of three families, all of Puerto-Rican ancestry, who presented with unique characteristic clinical defects confined to the face.<sup>109</sup> Patients present with atrophic skin at the temples (historically likened to 'forceps marks'), coarse facial appearance, absent or duplicated eyelashes, eyebrows that slant sharply upward and laterally, and periorbital puffiness (Fig. 2.32).

Lips may be large with an inverted 'V' contour. Although traditionally believed to have normal intelligence, patients with Setleis syndrome may have associated developmental delay.<sup>110</sup>

Reports of Setleis syndrome have suggested both autosomal recessive and autosomal dominant modes of inheritance,<sup>110,111</sup> and variable expressivity and reduced penetrance may be observed.<sup>112</sup> Setleis syndrome is considered by some to be a form of *focal facial dermal dysplasias* (see Ch. 6).<sup>113</sup>

### Other Developmental Defects

A congenital *dermal sinus* or *dermoid cyst* is a developmental epithelium-lined tract (or cyst) that extends inward from the surface of the skin. Since midline fusion of ectodermal and neuroectodermal tissue occurs at the cephalic and caudal ends of the neural tube, the majority of such defects are seen in the occipital and lumbosacral regions. Dermoids, however, can occur anywhere.

Dermal sinus openings may be difficult to visualize, particularly in the occipital scalp region where they may be hidden by hair. A localized thickening of the scalp, hypertrichosis, or dimpling in the midline of the neck or back should alert the physician to the possibility of such an anomaly. These sinuses are of clinical importance as portals for infection that may give rise to abscesses, osteomyelitis, or meningitis.

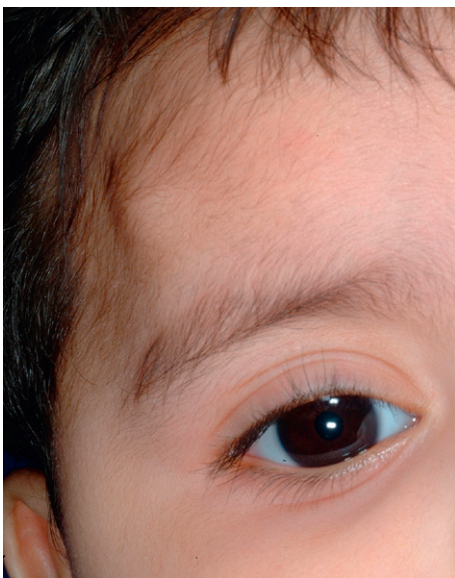Dermoid cysts most commonly occur on the orbital ridge, presenting as a non-tender, mobile subcutaneous nodule in the eyebrow/orbital ridge region (Fig. 2.33). In this location, there is no association with deep extension. About 3% of dermoids are located in the nasal midline<sup>91</sup> (including glabella, nasal dorsum, and columella), and recognition of these lesions is vital because of the potential for deep extension and CNS communication. Congenital midline nasal masses may represent not only dermoids, but also cephaloceles, gliomas, hemangiomas, and a variety of less common neoplasms or malformations. It is vital to consider the diagnostic possibilities carefully when a child presents with a nasal midline mass, given the potential for intracranial connection seen with some of these disorders. Invasive diagnostic procedures

should never be performed until radiologic evaluation has been completed.

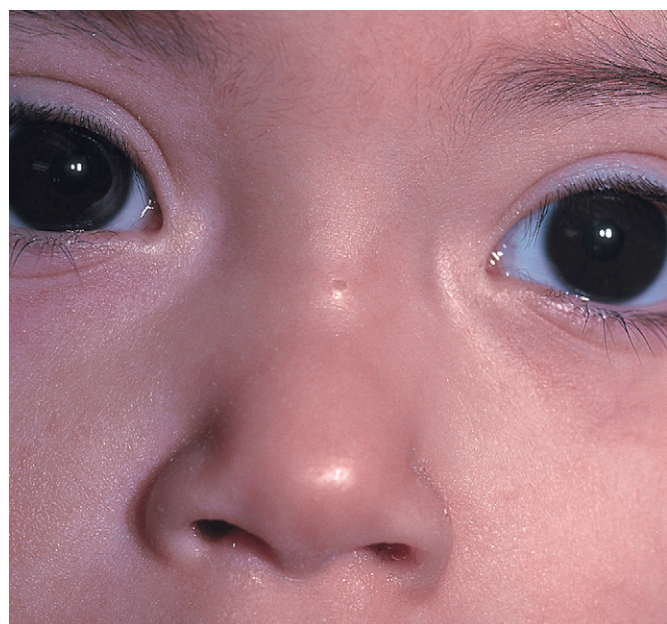In midline nasal dermoid cysts or dermal sinuses, an overlying sinus ostium may be present, sometimes with a white discharge or protruding hairs (Fig. 2.34). Presence of such a pit may indicate a higher likelihood of intracranial extension.<sup>114</sup> Magnetic resonance (MR) or computed tomographic (CT) imaging of suspicious areas should be performed to evaluate for an underlying tract and CNS connection. Management of dermal sinuses and dermoid cysts consists of surgical excision, in an effort to prevent local infection and, in the case of intracranial extension, meningitis and/or abscess formation. Lesions of the lateral forehead or orbital ridge do not require radiographic imaging prior to surgical excision.

A *cephalocele* is a herniation of cranial contents through a defect in the skull. Cephaloceles develop as a result of faulty separation of neuroectoderm from surface ectoderm in early gestation, and occur most commonly at the occiput, followed by the dorsal nose, orbits, and forehead. These lesions present as a compressible mass that transilluminates with light.<sup>91</sup> Occasionally, an overlying blue hue may be present, which at times can suggest the incorrect diagnosis of deep hemangioma. A useful diagnostic feature is the enlargement of the lesion that may be seen with any maneuver that results in increased intracranial pressure (such as crying or straining). This temporary change is due to the patent connection between a cephalocele and the CNS. Hypertelorism, facial clefting, and brain malformations may be seen in conjunction with a cephalocele.<sup>115</sup> Surgical resection is the treatment of choice, and multidisciplinary care (plastic surgery, neurosurgery) may be indicated.

A *nasal glioma* represents ectopic neuroectoderm from early development, and may occur in extranasal (60%) or intranasal (30%) locations, and less commonly in both extranasal and intranasal sites. This lesion presents as a firm, non-compressible flesh-colored nodule, sometimes with a blue-red hue, and most often situated at the root of the nose. Hypertelorism may result, and no fluctuation in size is seen, as these lesions have no intracranial connection. Intranasal lesions present as a protruding mass from the nose, simulating a nasal polyp. *Heterotopic brain tissue* is a term that



**Figure 2.33** Dermoid cyst. This mobile, non-tender, subcutaneous nodule was present at birth in this 5-month-old girl. The lateral mid-forehead distribution is slightly higher than most dermoids, which present most often in the lateral eyebrow region.



**Figure 2.34** Dermoid sinus. Small sinus ostium at the superior nasal bridge. This patient had no intracranial extension.