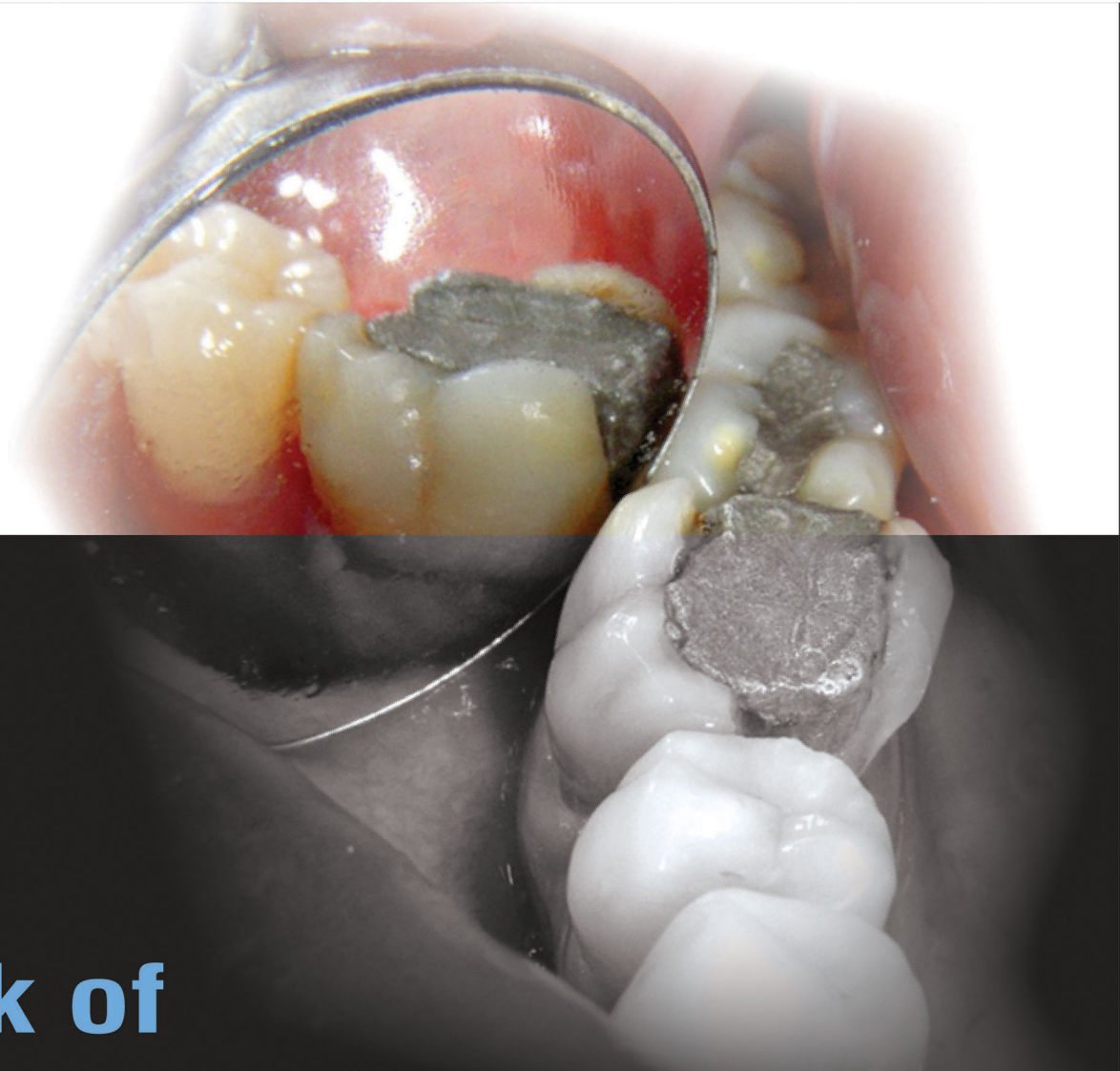
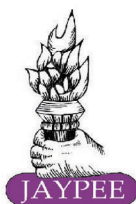


**Textbook of**

# **OPERATIVE DENTISTRY**

**3<sup>rd</sup> Edition**

*Foreword*  
**Ibrahim Abu Tahun**

**Nisha Garg  
Amit Garg**

**Textbook of  
OPERATIVE DENTISTRY**



# Textbook of OPERATIVE DENTISTRY

THIRD EDITION

## *Editors*

**Nisha Garg** MDS

(Conservative Dentistry and Endodontics)

Associate Professor

Sri Sukhmani Dental College and Hospital  
Dera Bassi, Mohali, Punjab, India

Ex-Resident

Postgraduate Institute of Medical Education and Research (PGIMER)  
Chandigarh, India

Ex-Resident, Government Dental College  
Patiala, Punjab, India

**Amit Garg** MDS

(Oral and Maxillofacial Surgery)

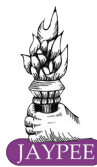Associate Professor

Sri Sukhmani Dental College and Hospital  
Dera Bassi, Mohali, Punjab, India

Ex-Resident, Postgraduate Institute of Medical Sciences  
Rohtak, Haryana, India

## *Foreword*

**Ibrahim Abu Tahun**



*The Health Sciences Publisher*

New Delhi | London | Philadelphia | Panama





**Jaypee Brothers Medical Publishers (P) Ltd.**

#### **Headquarters**

Jaypee Brothers Medical Publishers (P) Ltd.  
4838/24, Ansari Road, Daryaganj  
New Delhi 110 002, India  
Phone: +91-11-43574357  
Fax: +91-11-43574314  
E-mail: [jaypee@jaypeebrothers.com](mailto:jaypee@jaypeebrothers.com)

#### **Overseas Offices**

J.P. Medical Ltd.  
83, Victoria Street, London  
SW1H 0HW (UK)  
Phone: +44-20 3170 8910  
Fax: +44(0)20 3008 6180  
E-mail: [info@jpmepub.com](mailto:info@jpmepub.com)

Jaypee-Highlights Medical Publishers Inc.  
City of Knowledge, Bld. 237, Clayton  
Panama City, Panama  
Phone: +1 507-301-0496  
Fax: +1 507-301-0499  
E-mail: [cservice@jphmedical.com](mailto:cservice@jphmedical.com)

Jaypee Medical Inc.  
The Bourse  
111, South Independence Mall East  
Suite 835, Philadelphia, PA 19106, USA  
Phone: +1 267-519-9789  
E-mail: [jpmmed.us@gmail.com](mailto:jpmmed.us@gmail.com)

Jaypee Brothers Medical Publishers (P) Ltd.  
17/1-B, Babar Road, Block-B, Shaymali  
Mohammadpur, Dhaka-1207  
Bangladesh  
Mobile: +08801912003485  
E-mail: [jaypeedhaka@gmail.com](mailto:jaypeedhaka@gmail.com)

Jaypee Brothers Medical Publishers (P) Ltd.  
Bhotahity, Kathmandu, Nepal  
Phone: +977-9741283608  
E-mail: [kathmandu@jaypeebrothers.com](mailto:kathmandu@jaypeebrothers.com)

Website: [www.jaypeebrothers.com](http://www.jaypeebrothers.com)

Website: [www.jaypeedigital.com](http://www.jaypeedigital.com)

© 2015, Jaypee Brothers Medical Publishers

The views and opinions expressed in this book are solely those of the original contributor(s)/author(s) and do not necessarily represent those of editor(s) of the book.

All rights reserved. No part of this publication may be reproduced, stored or transmitted in any form or by any means, electronic, mechanical, photocopying, recording or otherwise, without the prior permission in writing of the publishers.

All brand names and product names used in this book are trade names, service marks, trademarks or registered trademarks of their respective owners. The publisher is not associated with any product or vendor mentioned in this book.

Medical knowledge and practice change constantly. This book is designed to provide accurate, authoritative information about the subject matter in question. However, readers are advised to check the most current information available on procedures included and check information from the manufacturer of each product to be administered, to verify the recommended dose, formula, method and duration of administration, adverse effects and contraindications. It is the responsibility of the practitioner to take all appropriate safety precautions. Neither the publisher nor the author(s)/editor(s) assume any liability for any injury and/or damage to persons or property arising from or related to use of material in this book.

This book is sold on the understanding that the publisher is not engaged in providing professional medical services. If such advice or services are required, the services of a competent medical professional should be sought.

Every effort has been made where necessary to contact holders of copyright to obtain permission to reproduce copyright material. If any have been inadvertently overlooked, the publisher will be pleased to make the necessary arrangements at the first opportunity.

**Inquiries for bulk sales may be solicited at:** [jaypee@jaypeebrothers.com](mailto:jaypee@jaypeebrothers.com)

#### ***Textbook of Operative Dentistry***

*First Edition:* 2010

*Second Edition:* 2013

*Third Edition:* **2015**

ISBN: 978-93-5152-633-9

*Printed at*

**Dedicated to**  
*Prisha and Vedant*



# Contributors

**Ajay Nagpal** MDS

Reader  
Conservative Dentistry and Endodontics  
KD Mathura College and Hospital  
Mathura, UP, India  
(Chapter 29)



**Amit Garg** MDS

Associate Professor  
Oral and Maxillofacial Surgery  
Sri Sukhmani Dental College and Hospital  
Dera Bassi, Mohali, Punjab, India  
(Chapters 3, 9, 11, 12, 25, 31, 32)



**Amita** MDS

Associate Professor  
Conservative Dentistry and Endodontics  
BRS Dental College and Hospital  
Panchkula, Haryana, India  
(Chapter 30)



**Amol Bansal** MDS

Reader  
Orthodontics  
Sri Sukhmani Dental College and Hospital  
Dera Bassi, Mohali  
Punjab, India  
(Chapter 2)



**Anil Chandra** MDS

Professor  
Conservative Dentistry and Endodontics  
King George Medical College  
Lucknow, Uttar Pradesh, India  
(Chapter 6)



**Anil Dhingra** MDS

Professor and Head  
Conservative Dentistry and Endodontics  
DJ Institute of Dental Sciences and  
Research, Modinagar, Ghaziabad  
Uttar Pradesh, India  
(Chapter 8)



**Anil R Kumar** MDS

Professor  
Conservative Dentistry and Endodontics  
Ragas Dental College and Hospital  
Chennai, India  
(Chapter 19)



**Jaidev Dhillon** MDS

Professor and Head  
Conservative Dentistry and Endodontics  
Gian Sagar Dental College and Hospital  
Banur, Punjab, India  
(Chapters 20, 27)



**J William Robbins** DDS MA

Clinical Professor  
Comprehensive Dentistry  
University of Texas Health Science Center  
Dental School, San Antonio  
Texas, USA  
(Chapter 19)



**JS Mann** MDS

Associate Professor and Head  
Conservative Dentistry and Endodontics  
Government Dental College  
Patiala, Punjab, India  
(Chapters 7, 21)



**Lekha Santosh** MDS

Professor  
Conservative Dentistry and Endodontics  
Oxford Dental College  
Bengaluru, Karnataka, India  
(Chapter 23)



**Manoj Hans** MDS

Associate Professor  
Conservative Dentistry and Endodontics  
Vyas Dental College and Hospital  
Jodhpur, Rajasthan, India  
(Chapters 18, 19, 23, 27)



**Martin J Tyas**

AM BDS PhD (Birm) DDSc (Melb)  
Graduate Diploma Health Science (WAIT)  
FADM FICD FRACDS FADI  
Professor  
Professorial Fellow  
Melbourne Dental School  
University of Melbourne  
Carlton, Australia  
(Chapter 2)



**Navjot Singh Khurana** MDS

Lecturer  
Conservative Dentistry and Endodontics  
Government Dental College  
Patiala, Punjab, India  
(Chapters 9, 14)



**Neelam Mittal** MDS  
Professor  
Former Dean and Head  
Faculty of Dental Sciences  
Institute of Medical Sciences  
Banaras Hindu University  
Varanasi, UP, India  
(Chapter 18)

**Niels Oestervemb** DDS  
Dental Sciences  
College of Dentistry  
Iowa City, US  
(Chapter 16)

**Nisha Garg** MDS  
Associate Professor  
Conservative Dentistry and Endodontics  
Sri Sukhmani Dental College and Hospital  
Dera Bassi, Mohali, Punjab, India  
(Chapters 4, 5, 7, 10, 14, 16, 20)

**Poonam Bogra** MDS  
Professor  
Conservative Dentistry and Endodontics  
DAV Dental College  
Yamuna Nagar, Haryana, India  
(Chapters 5, 17)

**RS Kang** MDS  
Former Associate Professor and Head  
Conservative Dentistry and Endodontics  
Government Dental College  
Patiala, Punjab, India  
(Chapters 20, 22)

**Rakesh Singla** MDS  
Associate Professor  
Conservative Dentistry and Endodontics  
Jan Nayak Chaudhary Devi Lal  
Dental College  
Sirsa, Haryana, India  
(Chapter 23)

**Régia Luzia Zanata** PhD  
Operative Dentistry  
Bauru School of Dentistry  
University of São Paulo  
Health Department  
University Health Care Centre  
(UBAS /Bauru), Alameda Octavio  
Pinheiro Brisolla  
Bauru, SP, Brazil  
(Chapter 24)

**Ruchi Vashisht** MDS  
Reader  
Conservative Dentistry and Endodontics  
National Dental College  
Dera Bassi, Mohali, Punjab, India  
(Chapter 23)



**S Ramchandran** MDS  
Professor  
Conservative Dentistry and Endodontics  
Principal, Ragas Dental College and Hospital  
Chennai, India  
(Chapters 19, 23)

**Sachin Passi** MDS  
Professor and Head  
Conservative Dentistry and Endodontics  
Sri Sukhmani Dental College  
Dera Bassi, Mohali, Punjab, India  
(Chapter 29)

**Sandhya Kapoor Punia** MDS  
Reader  
Conservative Dentistry and Endodontics  
Darshan Dental College  
Udaipur, Rajasthan, India  
(Chapter 26)

**Sanjay Miglani** MDS  
Associate Professor  
Faculty of Dentistry  
Jamia Millia Islamia  
New Delhi, India  
(Chapters 7, 15)

**Sarjeev Yadav** MDS  
Professor and Head  
Conservative Dentistry and Endodontics  
Government Dental College and Hospital  
Hyderabad, Andhra Pradesh, India  
(Chapter 25)

**Saru Kumar** MDS  
Consultant Endodontist  
Faridabad, Haryana, India  
(Chapter 28)

**Suresh K Saini** MDS  
Associate Professor  
Department of Prosthodontics  
BRS Dental College and Hospital  
Panchkula, Haryana, India  
(Chapter 30)

**Vikas Punia** MDS  
Reader  
Department of Prosthodontics  
Darshan Dental College  
Udaipur, Rajasthan, India  
(Chapter 30)

**Vipin Arora** MDS  
Senior Professor  
Conservative Dentistry and Endodontics  
Subharti Dental College  
Subharti University  
Meerut, UP, India  
(Chapters 13, 17, 26)



# Foreword



First, I would really like to confess how fortunate and honored I feel to be invited to write the Foreword for this new edition that addresses all aspects of esthetic and restorative discipline in dentistry in a remarkable fashion.

For the third time, Dr Nisha Garg creates a new edition of her well-known book *Textbook of Operative Dentistry*, which is, perhaps, one of the smartest cover-to-cover textbooks, and best described in an easy-to-learn and easy-to-teach manner.

Embracing and presenting a modern practical guide to provide a sound operative outcome through the highest quality of educational illustration and clinical case presentation. These wonderful thirty-two chapters are characterized by clinical and teaching excellence expressing the authors' dedication and legacy to update learners with the art and science of this rapidly and dramatically changing field.

From the Introduction to Operative Dentistry in chapter one starting with the evolutionary history of Operative Dentistry, its indications and objectives going through Tooth Nomenclature, Physiology of Tooth Form, Cariology, Types and Classification of Instruments, Principles of Tooth Preparation, the hot topic of Pulp Protection and ending up with all what a student or a practitioner needs to know regarding Bonding Agents and Techniques, Amalgam and Cast Metal Restorations that all together make a formidable edition to those interested in mastering this craft in this branch of dentistry.

This copiously illustrated edition with high-quality photographs, line diagrams and clinical cases, demonstrates comprehensive evidence-based theoretical and clinical knowledge for continuous education. This would meet the increasing demand and expectations of the dental professionals, who strive for enhanced patient care.

Although an associate not a substitute for essential training and clinical practice, this text will continue to provide practitioners from all around the globe and, particularly, in the Asia Pacific region with a reliable, exceptional reference and manual written by great teachers and authors that addresses specialists as well as general practitioners.

The direct and indirect acquired benefits include increased confidence and craftsmanship to provide a quality service of even difficult clinical situations. Although many books have been written on this subject, every professional, including myself, acknowledges the genuine and sincere efforts and expresses the deepest gratitude and appreciation for this unique adjunct educational resource that spreads enthusiasm and optimism.



**Ibrahim Abu Tahun** DDS PhD (Endodontics)  
Assistant Professor, University of Jordan  
President, Asian Pacific Endodontic Confederation  
President, Jordanian Endodontic Society  
President, Pan Arab Endodontic Society  
Chairman, Higher Education Committee, Jordan Medical Council  
Chairman, Scientific Committee, Jordanian Board in Endodontics, Jordan Medical Council  
Chairman, Training and Planning Committee, Jordanian Board in Endodontics, Jordan Medical Council  
Certified Member, European and Greek Society of Endodontology



# Preface to the Third Edition

---

It gives us immense pleasure to connect with you all again, through this third edition of *Textbook of Operative Dentistry*. We once again thank almighty God for his blessings in all our endeavors.

The book attempts to incorporate most recent advances in Operative Dentistry while at the same time not losing the sight of basics, therefore, making the study of Operative Dentistry easier and interesting. The main feature of this new edition is a new format wherein the flow charts and photographs are in plenty. All the chapters have stand-out boxes which will help the reader to have a quick review of the concept. Many boxes, such as facts, viva-voce, recapitulation and examiner's choice questions, have been added to help the students undertake review and revision. This third edition would not have been possible without the help and motivation of our friends and colleagues. In an attempt to improve the book further, many eminent personalities were invited to edit, write and modify the important chapters in the form of text and photographs. We are thankful to all the contributors for their respective help in this book in the form of photographs and critically evaluating the chapters.

We offer our humble gratitude and sincere thanks to Professor Avtar Singh (Chairman), and Mr Daman Jeet Singh (Director), Sri Sukhmani Dental College (SSDC), Dera Bassi, Punjab, India, for providing healthy and encouraging environment for our work.

We wish to thank all our colleagues at Sri Sukhmani Dental College, Dera Bassi, Mohali, Punjab, India, who gave helpful advice while editing of the text. We would be failing in our duty if we do not acknowledge the readers, senior lecturers and post-graduates of Darshan Dental College, Udaipur, for their contribution in the book in the form of clinical photographs.

We are grateful to dental companies: Dentsply, GC Fuji, Coltene Whaledent, and AMT dental products for providing high resolution images of products related to Operative Dentistry.

We are thankful to our passionate publisher, Shri Jitendar P Vij (Group Chairman), Mr Ankit Vij (Group President), Mr Tarun Duneja (Director-Publishing), Dr Priya Verma (Editor-in-Chief-Dental), Ms Samina Khan (Executive Assistant to Director-Publishing), Mr KK Raman (Production Manager), Mr Sunil Kumar Dogra (Production Executive), Mr Neelambar Pant (Production Coordinator), Mr Ashutosh Srivastava (Asstt. Editor), Mr Manoj Pahuja (Senior Graphic Designer), Mr Chandra Dutt (Typesetter) and the other staff of M/s Jaypee Brothers Medical Publishers (P) Ltd, New Delhi, India, for showing personal interest and trying their level best to bring the book in the present form.

Last but not least, we would like to thank all the authors, editors and publishers of Operative Dentistry and other books whose sources have provided great help in editing the third edition of this book.

It is hoped that all these modifications will be appreciated and render the book more valuable basis for Operative Dentistry.

We shall be highly indebted to our readers, if they analyze the text critically and send us useful suggestions for improving quality of this book for the next edition.

**Nisha Garg**  
**Amit Garg**





# Preface to the First Edition

---

Operative Dentistry is one of the oldest branches of dental sciences forming the central part of dentistry as practiced in primary care. The clinical practice of operative dentistry is ever-evolving as a result of improved understanding of etiology, prevention and management of common dental diseases. The advances and developments within the last two decades have drastically changed the scope of this subject.

Since effective practice of operative dentistry requires not only excellent manual skills but also both understanding of disease process and properties of dental materials available for use. The main objective of the book is to provide students with the knowledge required while they are developing necessary clinical skills and attitude in their undergraduate and postgraduate training in Operative Dentistry. We have tried to cover wide topics such as cariology, different techniques and materials available for restorations, recent concepts in management of carious lesions, infection control, minimally intervention dentistry and nanotechnology.

So we can say that after going through this book, the reader should be able to:

- Understand basics of cariology, its prevention and conservative management
- Tell indications and contraindications of different dental materials
- Apply modern pulp protective regimens
- Know the importance of treating the underlying causes of patient's problems, not just the restoration of the damage that has occurred
- Select suitable restorative materials for restoration of teeth
- Know recent advances and techniques like minimally intervention dentistry (MID), nanotechnology, lasers, diagnosis of caries and advances in dental materials.

**Nisha Garg**  
**Amit Garg**



# Contents

---

<b>1. Introduction to Operative Dentistry</b>	<b>1</b>
Introduction 1; Definitions 1; History 1; Indications 3; Objectives 5; Recent Advancements 5	
<b>2. Tooth Nomenclature</b>	<b>7</b>
Introduction 7; Dental Arches and Quadrants 7; Types of Human Teeth 7; Types of Dentition 8; Tooth Notation Systems 8; Nomenclature of Tooth Surfaces 11; Nomenclature Related to Dental Caries 14; Noncarious Defects of Teeth 15	
<b>3. Structure of Teeth</b>	<b>17</b>
Introduction 17; Enamel 17; Dentin 20; Dental Pulp 23; Periradicular Tissue 26	
<b>4. Physiology of Tooth Form</b>	<b>29</b>
Introduction 29; Functions of Teeth 29; Physiology of Tooth Form 29; Protective Functional Form of the Teeth 30; Trauma from Occlusion (TFO) 34; Occlusion and Operative Dentistry 35	
<b>5. Dental Caries</b>	<b>40</b>
Introduction 40; Definitions 40; Sites 40; Epidemiology 41; Dental Biofilm 41; Theories 42; Etiology 44; Classification 47; Histopathology 51; Diagnosis 55; Arrested Caries 65; Recurrent Caries (Secondary Caries) 65; Root Caries 67; Caries Risk Assessment 68; Prevention 69; Current Methods of Caries Prevention 75; Management 76	
<b>6. Cutting Instruments</b>	<b>80</b>
Introduction 80; Materials used for Manufacturing Cutting Instruments 80; Classification 81; Nomenclature 81; Parts of Hand Cutting Instruments 82; Instrument Formula 83; Different Instrument Designs 84; Exploring Instruments 85; Hand Cutting Instruments 87; Restorative Instruments 91; Instrument Grasps 94; Finger Rests 95; Methods of Use of Instruments 96; Sharpening of Hand Instruments 96; Rotary Cutting Instruments 98; Recent Advances in Rotary Instruments 105; Abrasive Instruments 106; Ultrasonic Instruments 108; Hazards and Precautions with Ultraspeed Cutting Instruments 109; Use of Laser 109	
<b>7. Principles of Tooth Preparation</b>	<b>115</b>
Introduction 115; Definition 115; Purpose 115; Objectives 115; Types of Restoration 115; Factors Affecting Restorations of a Tooth 116; Terminology 116;	

Number of Line and Point Angles 118; Guidelines 121; Classification 121; Steps 123; Initial Stage 124; Final Stages 130	
<b>8. Patient Evaluation, Diagnosis and Treatment Planning</b>	<b>134</b>
Introduction 134; Patient Evaluation 134; Examination and Diagnosis 136; Treatment Planning 145; Treatment Record 146	
<b>9. Patient and Operator Position</b>	<b>148</b>
Introduction 148; Dental Chair and Patient Positions 149; Operating Position 149; Considerations for Dentists while Doing Cases 151; Sitting Arrangement of Operator and Assistant 152	
<b>10. Isolation of the Operating Field</b>	<b>155</b>
Introduction 155; Components of Oral Environment 155; Equipment Needed for Isolation 156; Methods of Moisture Control 156; Direct Methods 156; Pharmacological Means 167; Methods Used for Gingival Tissue Management 167	
<b>11. Infection Control</b>	<b>173</b>
Introduction 173; Rationale 173; Cross-infection 173; General Precautions 174; Spaulding's Classification of Instruments 177; Instrument Processing Procedures 177; Sterilization of Instruments 179; Causes of Sterilization Failure 182; Management of Dental Equipment 182; Needle Stick Injury 183; Disinfection 184; Infection Control Checklist 185	
<b>12. Pain Management in Operative Dentistry</b>	<b>188</b>
Introduction 188; Pharmacosedation 188; Iatrosedation 188; Pain Control 188	
<b>13. Matricing and Tooth Separation</b>	<b>193</b>
Introduction 193; Matricing 193; Classification 194; Tooth Separation 205; Methods of Tooth Separation 205	
<b>14. Pulp Protection</b>	<b>213</b>
Introduction 213; Pulpal Irritants 213; Effect of Dental Caries on Pulp 214; Effect of Tooth Preparation on Pulp 214; Effect of Chemical Irritants on Pulp 215; Pulp Protection Procedures 215; Materials Used for Pulp Protection 217; Defense Mechanism of Pulp 221; Prevention of Pulpal Damage due to Operative Procedure 221	
<b>15. Interim Restoration</b>	<b>223</b>
Introduction 223; Objectives 223; Requirements 223; Purpose 223; Materials 223; Conclusion 231	

<b>16. Bonding Agents and Techniques</b>	<b>233</b>
Introduction 233; Evolution of Adhesive Dentistry 233; Indications for Use of Adhesives 233; History 234; Definitions 234; Mechanism of Adhesion 234; Enamel Bonding 235; Dentin Bonding 237; Dentin Bonding Agents 239; Evolution of Dentin Bonding Agents 240; Hybridization 247; Smear Layer 247; Classification of Modern Adhesives 249; Glass Ionomer Based Adhesive System 249; Failure of Dentin Bonding 250	
<b>17. Composite Restorations</b>	<b>252</b>
Introduction 252; Definition 252; History 252; Composition 253; Classification 254; Types 255; Recent Advances 256; Properties of Composite 260; Degree of Conversion 264; Indications 265; Contraindications 267; Clinical Techniques for Composite Placement 268; Failures 278; Indirect Restorations 279; Resin Cements 281	
<b>18. Tooth Preparation for Composite Restorations</b>	<b>285</b>
Introduction 285; Class III Tooth Preparation 285; Class IV Tooth Preparation 288; Class V Tooth Preparation 288; Tooth Preparation for Posterior Composite Restoration 291; Class I Tooth Preparation 292; Class II Tooth Preparation 293; Restorative Technique for Composites 295; Repair of Composite Restorations 298; Indirect Composite Inlays and Onlays 298	
<b>19. Esthetic Dentistry</b>	<b>302</b>
Introduction 302; Elements of Dental Esthetics 302; Esthetics and Operative Dentistry 307; Conclusion 315	
<b>20. Dental Amalgam</b>	<b>317</b>
Introduction 317; Historical Developments 317; Definitions 318; Classification 318; Composition 318; Types 320; Proportioning 320; Setting Reaction 320; Physical Properties 321; Indications 323; Contraindications 324; Recent Advances 324; Principles of Tooth Preparation 326; Steps for Amalgam Restoration 338; Failures 345; Reasons for Failure 347; Mercury Hygiene 349; Is Dental Amalgam Safe? 352	
<b>21. Pin-retained Restorations</b>	<b>355</b>
Introduction 355; Definition 355; Indications 356; Contraindications 356; Retentive Pins 356; Principles and Techniques of Pin Placement 360; Factors Affecting Retention of Pins in Tooth Structure 364; Factors Affecting Retention of Pins in Restorative Material 365; Pins and Stresses 365; Failure 366; Pin Amalgam Foundation 368; Alternatives to Pins for Additional Retention in Amalgam Restoration 368	
<b>22. Direct Filling Gold</b>	<b>371</b>
Introduction 371; Properties 371; Indications 372; Contraindications 372; Types of Gold 373; Forms of Gold 374; Storage of Gold 374; Principles of Tooth Preparations 375; Steps of Direct Filling Gold Restoration 380; Future of Gold in Dentistry 383	

- 23. Cast Metal Restorations** **385**  
Introduction 385; Definitions 386; Properties of Dental Casting Alloys 386; Classification and Composition 387; Indications 387; Contraindications 388; Basic Design of Cast Metal Inlay 388; Steps of Tooth Preparation 391; Modifications in Class II 399; Tooth Preparation for Cast Metal Onlay 402; Additional Retention and Resistance 404; Technique of Making Cast Metal Restoration 405; Casting Defects 414; Pin-retained Cast Restorations 417
- 24. Glass Ionomer Cements** **420**  
Introduction 420; Classification 420; History 421; Composition 421; Setting Reaction 423; Indications 425; Contraindications 425; Properties 425; Uses 427; Clinical Steps for Placement 431
- 25. Tooth Hypersensitivity** **439**  
Introduction 439; Definition 439; Mechanism of Dentin Sensitivity 439; Incidence and Distribution 440; Etiology and Predisposing Factors 441; Differential Diagnosis 442; Diagnosis 442; Treatment 442
- 26. Management of Discolored Teeth** **447**  
Introduction 447; Classification 447; Etiology 448; Bleaching 452; Bleaching Agents 452; Home Bleaching Technique 453; In-office Bleaching 455; Bleaching of Nonvital Teeth 458; Effects of Bleaching Agents on Tooth and its Supporting Structures 461; Effects on Restorative Materials 462
- 27. Minimally Intervention Dentistry** **463**  
Introduction 463; Definition 463; Concepts (Given by Tyas et al) 463; Early Diagnosis 463; Caries Classification Based on Site and Size of Lesion 464; Assessment of Caries Risk 465; Decreasing the Risk of Further Demineralization and Arresting Active Lesion 465; Remineralization of Initial Lesions and Reduction in Cariogenic Bacteria 465; Minimal Intervention of Cavitated Lesions 469; Repair Instead of Replacement of the Restoration 472; Disease Control 473; Conclusion 473
- 28. Cervical Lesions** **475**  
Introduction 475; Classification 475; Carious Cervical Lesions 475; Noncarious Cervical Lesions 476; Management 480
- 29. Dental Ceramics** **485**  
Introduction 485; Definitions 485; History 486; Classification 486; Composition 486; Methods of Strengthening Porcelain 487; Metal Ceramic Restorations 488; Condensation of Porcelain 490; Firing of Porcelain 490; Cooling 490; Grinding for Final Adjustments 490; Glazing 491; All Ceramic System 491; Ceramic Inlays and Onlays 493; Porcelain Laminate Veneers 494; Full Ceramic Crowns 495; Fabrication of Ceramic Restorations 497

<b>30. Selection of Restorative Materials</b>	<b>500</b>
Introduction 500; Factors Regulating Selection 500; Site Specific Selection 503; Success and Failure of a Restoration 505	
<b>31. Evidence-based Dentistry</b>	<b>508</b>
Introduction 508; Definition 508; Steps 509; Clinical Application 509; Conclusion 510	
<b>32. Nanodentistry and Its Applications</b>	<b>511</b>
Introduction 511; Definition 511; Mechanism of Action 512; Limitations 513; Challenges Faced by Nanodentistry 513; Research Challenges in Nanotechnology 513	
<i>Index</i>	<i>515</i>



# Introduction to Operative Dentistry

## Chapter Outline

- Introduction
- Definitions
- History
- Indications
- Objectives
- Recent Advancements

## INTRODUCTION

Operative dentistry is foundation of the dentistry from which other branches have evolved. It plays an important role in enhancing dental health and now branched into dental specialties. Operative dentistry deals with diagnosis, prevention, interception and restoration of the defects of natural teeth. Goal of the operative dentistry is to maintain the health and integrity of teeth and their supporting structures.

## DEFINITIONS

**Mosby's dental dictionary**—"Operative dentistry deals with the functional and esthetic restoration of the hard tissues of individual teeth".

**Sturdevant**—"Operative dentistry is defined as science and art of dentistry which deals with diagnosis, treatment and prognosis of defects of the teeth which do not require full coverage restorations for correction. Such treatment should result in the restoration of proper form, function and esthetics while maintaining the physiologic integrity of the teeth in harmonious relationship with the adjacent hard and soft tissues, all of which should enhance the general health and welfare of the patient".

**Gilmore**—"Operative dentistry is that subject which includes diagnosis, prevention, and treatment of defects of the natural teeth, both vital and nonvital, so as to preserve the natural dentition and restore it to the best state of health, function and esthetics.

## Scope

Scope of operative dentistry includes the following:

- To know the condition of the affected tooth and other teeth.
- To examine not only the affected tooth but also the oral and systemic health of the patient.
- To diagnose the dental problem and the interaction of problem area with other tissues.
- To provide optimal treatment plan to restore the tooth to return to health and function, and increase the overall well-being of the patient.
- Thorough knowledge of dental materials which can be used to restore the affected areas.
- To understand the biological basis and function of the various tooth tissues.
- To maintain the pulp vitality and prevent occurrence of pulpal pathology.
- To have knowledge of dental anatomy and histology.
- To understand the effect of the operative procedures on the treatment of other disciplines.
- An understanding and appreciation for infection control to safeguard both the patient and the dentist against disease transmission.

## HISTORY

The profession of dentistry was born during the early middle ages. Barbers were doing well for dentistry by removing teeth with dental problems. Till 1900 AD, the term 'Operative dentistry' included all the dental services rendered to the patients, because all the dental treatments were considered to be an operation which was performed in the dental

operating room or operatory. As dentistry evolved, dental surgeons began filling teeth with core metals. In 1871, GV Black gave the philosophy of “extension for prevention”, for cavity preparation design. Dr GV Black (1898) is known as the “Father of operative dentistry”. He provided scientific basis to dentistry because his writings developed the foundation of the profession and made the field of operative dentistry organized and scientific. The scientific foundation

for operative dentistry was further expanded by Black’s son, Arthur Black.

In early part of 1900s, progress in dental sciences and technologies was slow. Many advances were made during the 1970s in materials and equipment. By this time, it was also proved that dental plaque was the causative agent for caries. In the 1990s, oral health science started moving toward an evidence-based approach for treatment of decayed teeth (**Table 1.1**).

**Table 1.1**  
Evolution of Operative Dentistry

Era	Year	Major inventions/events
Prehistoric era	5000 BC	A Sumerian text describes “tooth worms” as the cause of dental decay.
	500-300 BC	Hippocrates and Aristotle wrote about dentistry, including the eruption pattern of teeth, treating decayed teeth.
	166-201 AD	The Etruscans practiced dental prosthetics using gold crowns and fixed bridgework.
	700	A medical text in China mentioned the use of “silver paste,” a type of amalgam.
Pre 1700	1530	Artzney Buchlein, wrote the first book solely on dentistry. It was written for barbers and surgeons who used to treat the mouth, it covered topics like oral hygiene, tooth extraction, drilling teeth and placement of gold fillings.
	1563	Bartolomeo Eustachius published the first book on dental anatomy, ‘Libellus de dentibus’.
	1683	Antonie van Leeuwenhoek identified oral bacteria using a microscope.
	1685	Charles Allen wrote first dental book in English ‘The operator for the teeth’.
1700-1800	1723	Pierre Fauchard published “Le Chirurgien dentiste”. He is credited as ‘Father of Modern Dentistry’ because his book was the first to give a comprehensive system for the practice of dentistry.
	1746	Claude Mouton described a gold crown and post for root canal treated tooth.
	1764	James Rae gave first lecture on the teeth at the Royal College of Surgeons, Edinburgh.
	1771	John Hunter published “The natural history of human teeth” giving a scientific basis to dental anatomy.
	1780	William Addis manufactured the first modern toothbrush.
	1790	John Greenwood constructed the first known dental foot engine by modifying his mother’s foot-treadle spinning wheel to rotate a drill.
1800-1900	1832	James Snell invented the first reclining dental chair.
	1830s-1890s	The ‘Amalgam War’ conflict and controversy generated over the use of amalgam as filling material.
	1855	Robert Arthur introduced the cohesive gold foil method for inserting gold into a preparation with minimal pressure.
	1864	Sanford C Barnum developed the rubber dam.
	1871	James Beall Morrison invented foot engine.
	1890	WD Miller formulated his “chemicoparasitic” theory of caries in “Microorganisms of the human mouth”.
	1895	Lilian Murray became the first woman to become a dentist in Britain.
1896	GV Black established the principles of cavity preparation.	
1900-2000	1900	Federation Dentaire Internationale (FDI) was founded.
	1903	Charles Land introduced the porcelain jacket crown.
	1907	William Taggart invented a “lost wax” casting machine.
	1930-1943	Frederick S McKay, a Colorado dentist showed brown stains on teeth because of high levels of naturally occurring fluoride in drinking water.
	1937	Alvin Strock developed Vitallium dental screw implant.
	1950s	The first fluoride toothpastes were marketed.
	1949	Oskar Hagger developed the first system of bonding acrylic resin to dentin.
	1955	Michael Buonocore described the acid etch technique.
	1957	John Borden introduced a high-speed air-driven contra-angle handpiece running up to 300,000 rpm.
	1960s	Lasers were developed.
	1962	Rafael Bowen developed Bis-GMA.
	1989	The first commercial home tooth bleaching product was made available.
	1990s	New advances in esthetic dentistry including tooth-colored restorative materials, bleaching materials, veneers and implants.

The recent concept of treatment of dental caries comes under minimally invasive dentistry. In December 1999, the World Congress of Minimally Invasive Dentistry (MID) was formed. Initially MI dentistry focused on minimal removal of diseased tooth structure but later it evolved for preventive measures to control disease.

Current minimally intervention philosophy follows three concepts of disease treatment:

1. Identify—identify and assess risk factors early.
2. Prevent—prevent disease by eliminating risk factors.
3. Restore—restore the health of the oral environment.



#### Facts

- First dental chair was manufactured by SS White Dental Company, it was called “Harris”
- First hydraulic dental chair was manufactured in 1877, it was called ‘Wilkinson dental chair’.

## INDICATIONS

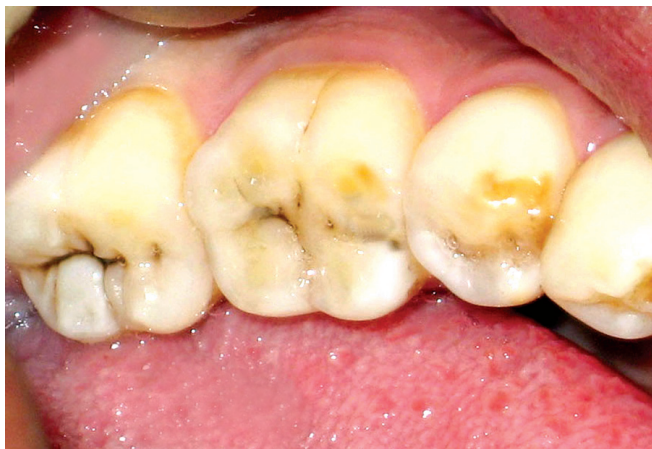Following are the indications of operative dentistry:

### Caries

Caries is most common disease affecting the teeth. Dental caries is microbiological disease of the teeth which results in localized dissolution and destruction of the calcified tissue, caused by the action of microorganisms and fermentable carbohydrates.

Based on anatomy of the surface involved, dental caries can be of the following types:

- Pit and fissures carious lesions (**Fig. 1.1**)
- Smooth surface carious lesions (**Fig. 1.2**)
- Root caries (**Fig. 1.3**).



**Figure 1.1:** Clinical picture showing pit and fissure caries in molars

### Noncarious Loss of the Tooth Structure

#### Attrition

Mechanical wear of opposing teeth commonly seen on contacting occlusal, incisal and proximal surfaces (**Fig. 1.4**).

#### Abrasion

Loss of tooth material by mechanical wear other than contacting surfaces. It commonly occurs due to improper brushing and use of abrasive tooth powder (**Fig. 1.5**).

#### Erosion

Loss of dental hard tissue as a result of a chemical process not involving bacteria.

### Malformed, Traumatized, or Fractured Teeth

Traumatic injuries may involve the hard dental tissues and the pulp which require restoration (**Figs 1.6 and 1.7**).

### Esthetic Improvement

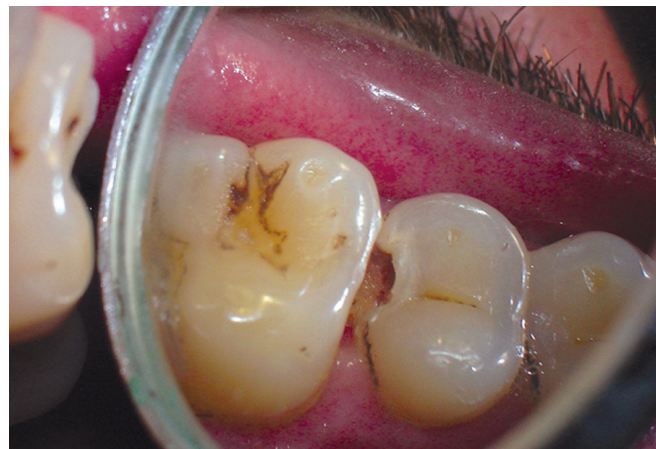Discolored teeth because of staining or other reasons look unesthetic and require restoration (**Fig. 1.8**).

### Replacement or Repair of Restoration

Repair or replacement of previous defective restoration is indicated for operative treatment (**Fig. 1.9**).

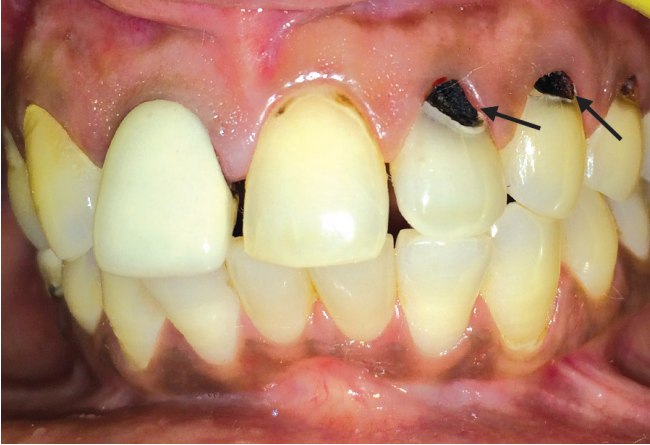### Developmental Defects

Defects like enamel and dentin hypoplasia, hypomineralization, amelogenesis and dentinogenesis imperfecta

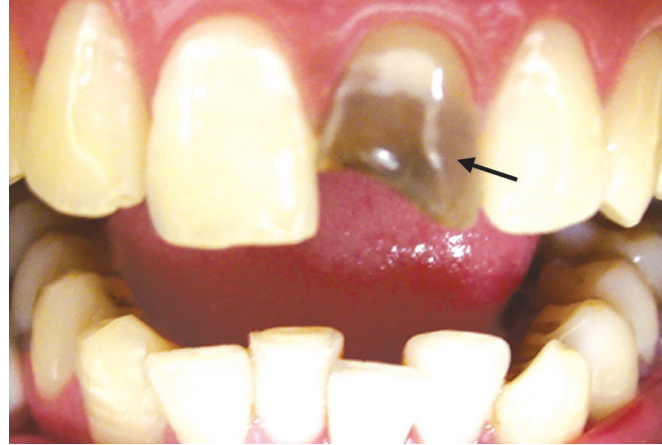

**Figure 1.2:** Clinical picture showing smooth surface caries in maxillary second premolar

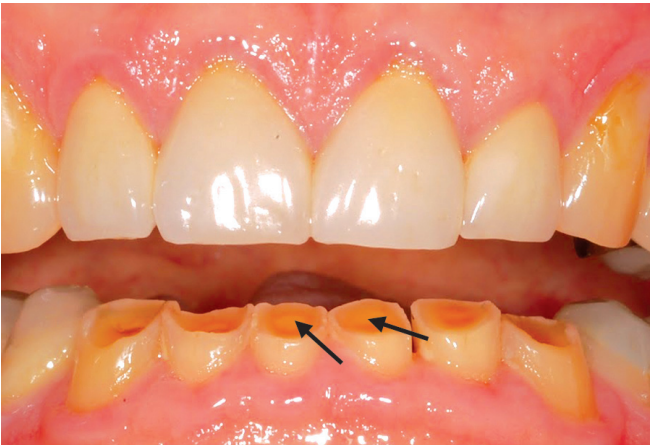



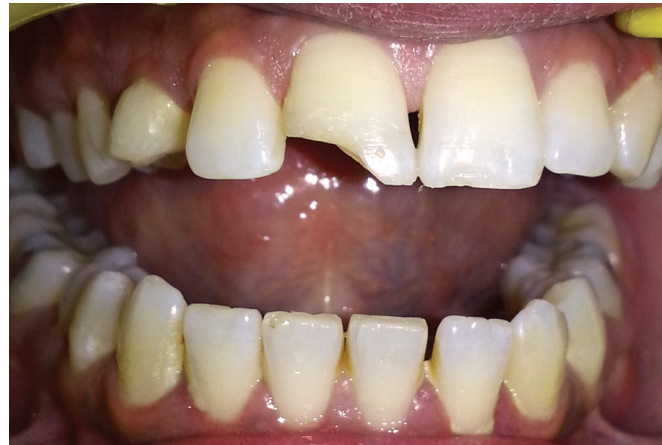**Figure 1.3:** Clinical picture showing root caries in 22, 23, 24



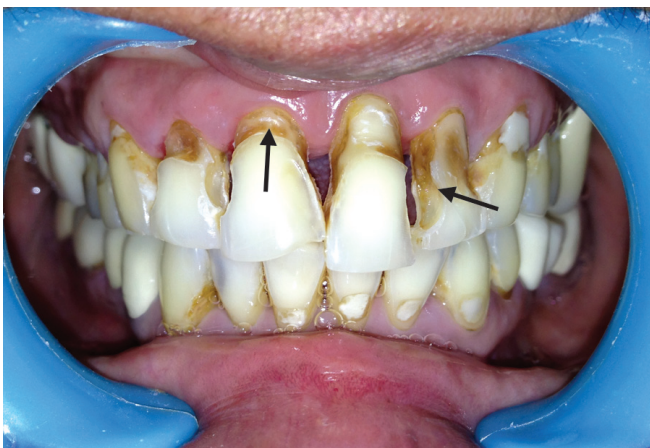**Figure 1.6:** Fractured and discolored maxillary tooth



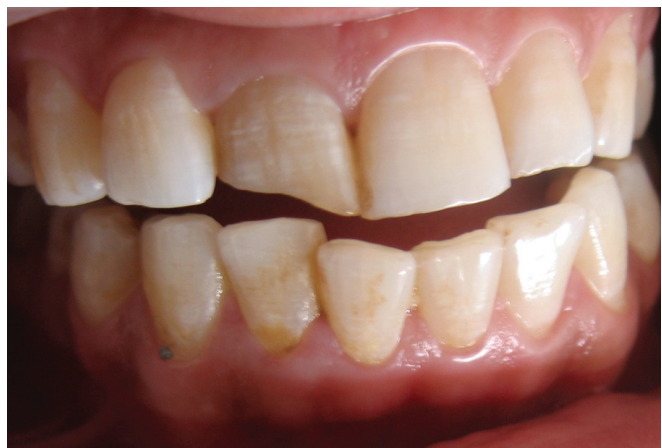**Figure 1.4:** Clinical picture showing attrition of mandibular teeth



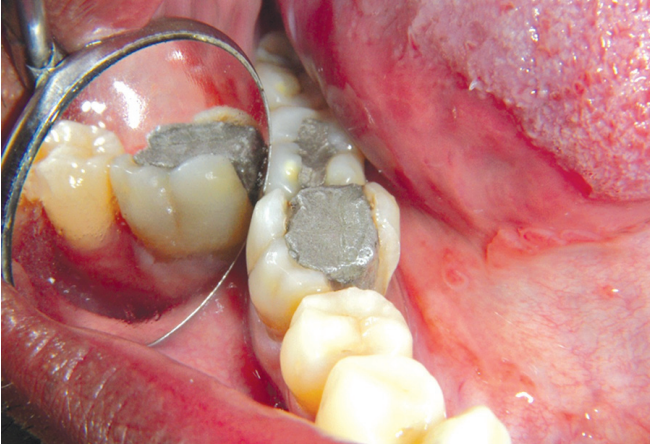
**Figure 1.7:** Fractured 11 can be repaired by esthetic composite restoration



**Figure 1.5:** Clinical picture showing generalized abrasion of upper anterior



**Figure 1.8:** Discolored teeth can be corrected by esthetic treatment



**Figure 1.9:** Clinical presentation of defective amalgam restoration

tetracycline stains, peg-shaped laterals need operative intervention.

## OBJECTIVES

Objectives of operative dentistry are as follows:

### Diagnosis

Diagnosis is determination of nature of disease, injury or other defect by examination, test and investigation.

### Prevention

To prevent any recurrence of the causative disease and their defects, it includes the procedures done for prevention before the manifestation of any sign and symptom of the disease.

### Interception

It includes the procedures undertaken after signs and symptoms of disease have appeared, in order to prevent the disease from developing into a more serious or full extent.

### Preservation

Preservation of the vitality and periodontal support of remaining tooth structure is obtained by preventive and interceptive procedures.

### Restoration

Includes restoring form, function, phonetics and esthetics.

### Maintenance

After restoration is done, it must be maintained for providing service for longer duration.

## RECENT ADVANCEMENTS

Earlier concept of tooth preparation was the same as given by GV Black for many decades, that is extension for prevention. But modern concept of operative dentistry is based on the conservation and prevention of the diseases. Many advancements have been made in the area of operative dentistry so as to meet its goals in better ways.

1. **Development in the diagnostic aids**
  - Ultrasonic illumination
  - Fiberoptic transillumination (FOTI)
  - Digital imaging
  - Tuned aperture computerized tomography (TACT)
  - Magnetic resonance microimaging (MRMI).
  - Qualitative laser fluorescence
  - Diagnodent (quantitative laser fluorescence)
2. **Recent advances in treatment planning**
  - Minimal intervention dentistry
  - Ozone therapy.
3. **Recent advances in tooth preparation**
  - Use of air abrasion technique
  - Chemomechanical caries removal
  - Use of lasers in tooth preparation
  - Use of ultrasonics in tooth preparation
  - Management of smear layer.
4. **Improvements in adhesive dentistry**
  - Introduction of bonded amalgam restorations
  - Packable composites
  - Flowable composites
  - Modifications in glass ionomers cements
  - Compomers
  - Giomers
5. **Recent advances in techniques and equipment**
  - Incremental packing and C-factor concept in composites
  - Soft start polymerization
  - High intensity QTH polymerization.
6. **Recent advances in handpieces and rotary instruments**
  - Fiberoptic handpiece
  - Smart prep burs
  - CVD burs
  - Fissurite system.

## SUMMARY

- According to Mosby's dental dictionary, "Operative dentistry deals with the functional and esthetic restoration of the hard tissues of individual teeth".
- According to Sturdevant, "Operative dentistry is defined as science and art of dentistry which deals with diagnosis, treatment and prognosis of defects of the teeth which do not require full coverage restorations for correction".

- In 1871, GV Black gave the philosophy of “extension for prevention”, for cavity preparation design.
- DrGVBlackis known as the “Father of operative dentistry”. The scientific foundation for operative dentistry was further expanded by Black’s son, Arthur Black.
- Indications of operative dentistry:
  - Dental caries
  - Loss of enamel structure due to attrition, abrasion, abfraction and erosion
  - Malformed, traumatized or fractured teeth
  - Esthetic improvement
  - Replacement or repair of restoration
  - Developmental defects
- Purpose of operative dentistry
  - Diagnosis
  - Prevention
  - Interception
  - Preservation
  - Restoration
  - Maintenance.

### EXAMINER’S CHOICE QUESTIONS

1. Define operative dentistry. What is the scope of operative dentistry?
2. List the indications for operative dental procedures.
3. Discuss various advancements that have revolutionized the current practice of operative dentistry.
4. Write short notes on:
  - a. Scope and purpose of operative dentistry.
  - b. Recent advances in operative dentistry.

---

### BIBLIOGRAPHY

---

1. Berry J. The demographics of dentistry. J Am Dent Assoc. 1996;127:1327-30.
2. Brown LJ, et al. Dental caries, restoration and tooth conditions in US adults, 1988-1991. J Am Dent Assoc. 1996; 127:1315-25.
3. Grainger DA. What are you, operative dentistry, and why are they saying all of those nasty things about you? Amer Aced Gold Foil Oper J. 1972;15:67.



# Tooth Nomenclature

## Chapter Outline

- Introduction
- Dental Arches and Quadrants
- Types of Human Teeth
- Types of Dentition
- Tooth Notation Systems
- Nomenclature of Tooth Surfaces
- Nomenclature Related to Dental Caries
- Noncarious Defects of Teeth

## INTRODUCTION

### Dental Anatomy

It is the branch of anatomy which deals with the study of human teeth structures. It includes development, appearance and classification of teeth. Dental anatomy is also a taxonomical science; it is concerned with the naming of teeth and the structures of which they are made.

### Rationale of Tooth Anatomy

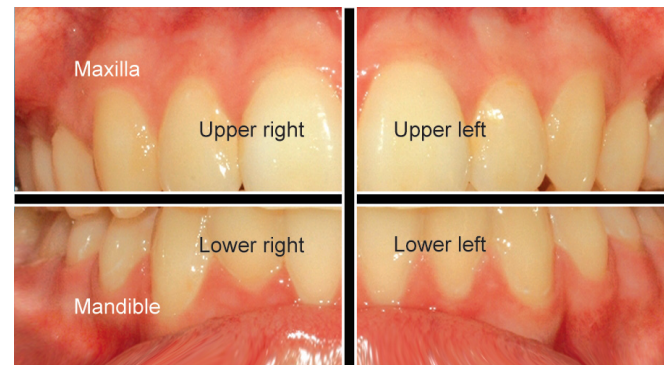
It is important to understand anatomy of teeth because of following reasons:

- Maintenance of supporting tissues in a healthy state
- Restoration of a damaged tooth to its original form
- Optimal function of teeth.

## DENTAL ARCHES AND QUADRANTS

Mouth has two arches viz; maxillary and mandibular. Each arch has two quadrants, i.e. right and left. Thus the set of teeth has four quadrants viz (**Fig. 2.1**):

1. Upper (maxillary) right
2. Upper (maxillary) left
3. Lower (mandibular) right
4. Lower (mandibular) left.



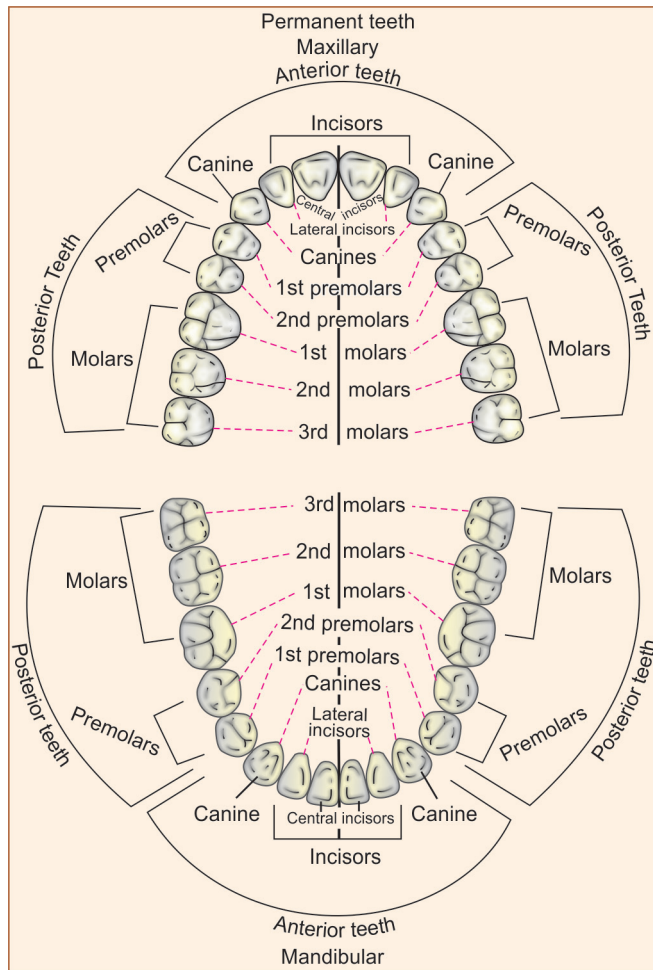
**Figure 2.1:** Division of whole dentition into four quadrants, i.e. upper right, upper left, lower right and lower left. Right and left relate to patient's right and left

## TYPES OF HUMAN TEETH

Depending upon their form and function human teeth can be divided into following types (**Fig. 2.2**):

### Incisors

- Incisors are the square-shaped teeth located in front of the mouth, with four in upper and four in lower jaw.
- Incisors are important teeth for phonetics and esthetics.
- They help in cutting and shearing the food.



**Figure 2.2:** Different classes and types of teeth in permanent dentition

### Canines (Cuspids)

- Canines are sharp teeth located near the corner of the mouth.
- Because of their anatomy and long root, they are strong teeth. They help in tearing, seizing, piercing and cutting of food.

### Premolars (Bicuspid)

- They are similar to canine in tearing the food, and similar to molar in grinding the food. So, they serve dual role in function.
- Premolars are present in permanent dentition only, not in primary dentition.
- There are a total of eight premolars, four premolars are present in upper and lower arch, two on each side of the canine.
- Facially they resemble canines and lingually as molars.

### Molars

- Distal to premolars are the molars.
- There are six molars in each arch (three in each side), therefore, a total of 12.
- They have multi-cusped which help in crushing and grinding the food.
- Also help in maintenance of vertical height of the face.

### TYPES OF DENTITION

There are two sets of teeth that develop in a person's mouth (**Fig. 2.3**).

- First set of teeth is termed as “milk”, “baby”, “deciduous” or “primary” teeth.
- Total number of teeth in one set are twenty. Maxilla and mandible each has six anterior teeth which includes four incisors, two canines and four posterior teeth (molars).
- Primary teeth erupt at between 6 months and 2 years of age.
- Second set of teeth, i.e. **permanent teeth**, erupt at the age of six years.
- There are 32 permanent teeth in an adult mouth.
- Teeth are present in two jaws (arches), i.e. an upper and a lower arch each, being the upper and lower jaws respectively. Normally, 16 teeth are found in each complete arch.
- Maxilla and mandible each has six anterior teeth which includes four incisors, two canines, ten posterior teeth which include four premolars and six molars.

### TOOTH NOTATION SYSTEMS

There are different tooth notations for identifying specific tooth. The three most common systems are the “FDI World Dental Federation” notation, the “Universal” system and the “Zsigmondy-Palmer” system. The FDI system is used worldwide and the universal is used predominantly in the USA.

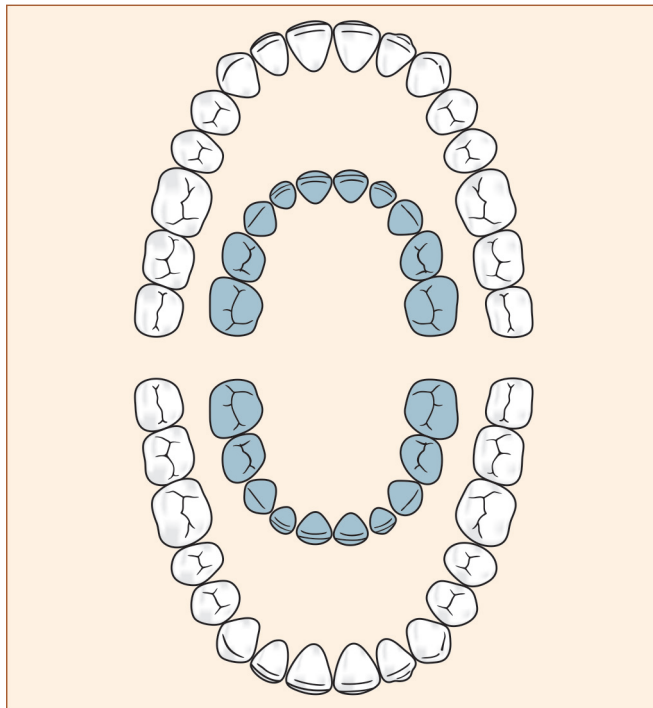
### Zsigmondy-Palmer System/Angular/Grid System

- This is the oldest method introduced by Zsigmondy in 1861.
- Also known as angular or grid system.
- Adult teeth are numbered 1 to 8, where 1 is central incisor and 8 is third molar (**Fig. 2.4**).
- Primary teeth are designated as A, B, C, D, E, where A is central incisor and E is second molar.

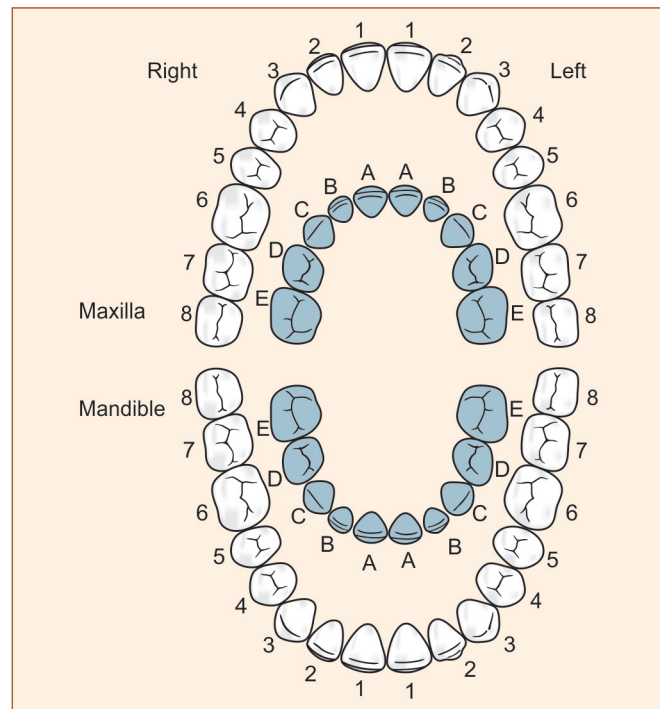
### Advantages

- *Simple and easy to use*
- *Less chances of confusion between primary and permanent tooth as there is different notation, e.g. permanent teeth are described by numbers while primary teeth by alphabets.*





**Figure 2.3:** Two sets of teeth. The outer ring represents the permanent teeth. The inner ring represents the deciduous teeth



**Figure 2.4:** Presentation of Zsigmondy-Palmer notation of both deciduous and permanent dentitions

### Viva Voce

- Zsigmondy-Palmer system was originally termed as “Zsigmondy system” after the Austrian dentist Adolf Zsigmondy who developed the idea in 1861. Adult teeth were numbered 1 to 8 and the primary dentition as Roman numerals I, II, III, IV, V from the midline. Palmer changed this to A, B, C, D, E. This makes it less confusing and less prone to errors in interpretation.
- Universal system—Given by ADA in 1968. Use a unique number/letter for each tooth. Permanent teeth are numbered 1 → 32 starting from upper right molar, while deciduous teeth are designated A → T, in this A → upper right second molar.

### Disadvantages

- *Difficulty in communication*
- *Confusion between upper and lower quadrants, while communication and transferring a data.*

### Universal (National) System/ADA System

- This system was introduced by the American Dental Association in 1968. It is most popular in the United States.
- Universal numbering system uses a unique letter or number for each tooth.
- Numbering starts from maxillary right posterior tooth where tooth number 1 is the patient’s upper right third

molar and follows around the upper arch to the upper left third molar, tooth 16, descending to the lower left third molar, tooth 17, and following around the lower arch to the lower right third molar, tooth 32 (**Fig. 2.5**).

- If a third molar (“wisdom tooth”) is missing, the first number will be 2 instead of 1, acknowledging the missing tooth (**Fig. 2.6**).
- If teeth have been extracted or teeth are missing, the missing teeth will be numbered as well.
- In the original system, children’s 20 primary teeth were numbered in the same order, except that a small letter “d” followed each number, thus a child’s first tooth on the upper right side would be 1d and the last tooth on the lower right side would be 20d.

### Modified Version of Universal System Order for Primary Dentition

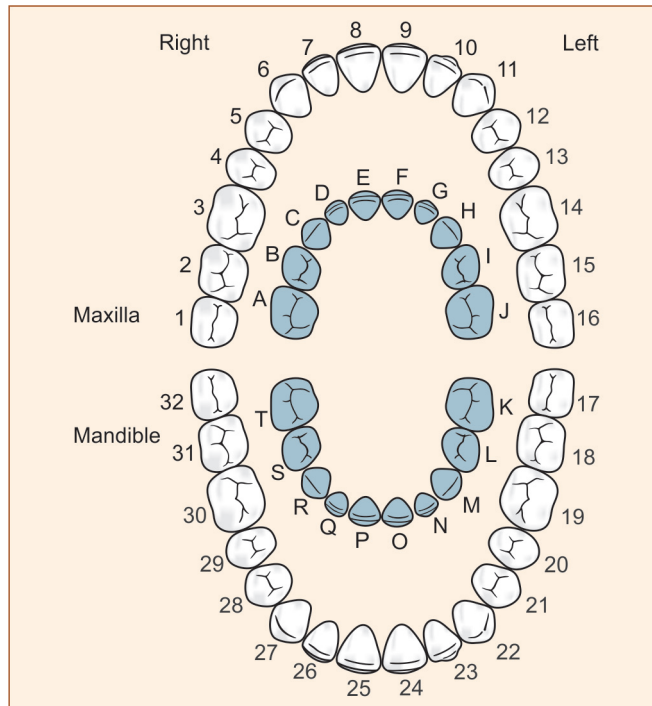
Primary teeth are by English upper case letters A through T instead of numbers 1 to 20, with A being the patient’s upper right second primary molar and T being the lower right second primary molar, for example:

- B is maxillary right deciduous first molar
- P is mandibular right deciduous central incisor
- 5 is maxillary right permanent first premolar.

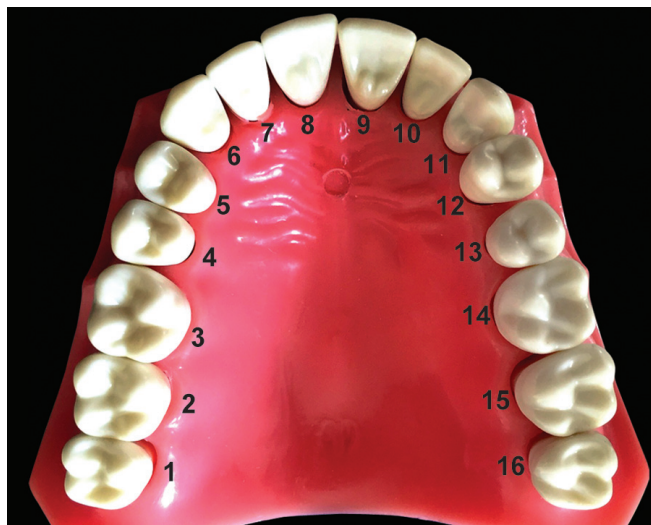
### Viva Voce

#### Features

- Given by American Dental Association in 1968.
- Use a unique number/letter for each tooth.
- Permanent teeth are numbered 1 to 32 starting from upper right molar.
- Deciduous teeth are designated as A to T, in this A is upper right second molar.



**Figure 2.5:** Presentation of modified version of universal system of tooth nomenclature for both deciduous and permanent teeth



**Figure 2.6:** Photograph showing tooth notation according to universal system

#### Advantage

*Unique letter or number for each tooth avoiding confusions.*

#### Disadvantage

*Difficult to remember each letter or number of tooth.*

#### Federation Dentaire International (FDI) System

- This two-digit system was first introduced in 1971 and subsequently adopted by the American Dental Association (1996).
- FDI system is known as a **'Two-Digit' system** because it uses two digits; the first number represents a tooth's quadrant, and the second number represents the number of the tooth from the midline of the face.
- Both digits should be pronounced separately in communication. For example, the lower left permanent second molar is '37'; it is not termed as 'thirty-seven', but 'three seven'.

#### Permanent Teeth

- In FDI notation, teeth are numbered as 1, 2,....8 where;
  - 1- central incisor,
  - 2- lateral incisor,
  - 3- canine,
  - 4 and 5 - 1st and 2nd premolars respectively
  - 6, 7, and 8- 1st, 2nd and 3rd molars (**Fig. 2.7**).
- Quadrants are designated 1 to 4,
  - 1- upper right,
  - 2- upper left
  - 3- lower left
  - 4- lower right.
- This results in tooth identification a two-digit combination of the quadrant and tooth, e.g. the upper right canine is '13' (one three) and the upper left canine is '23' (two three) (**Figs 2.8 and 2.9**).

#### Deciduous Teeth

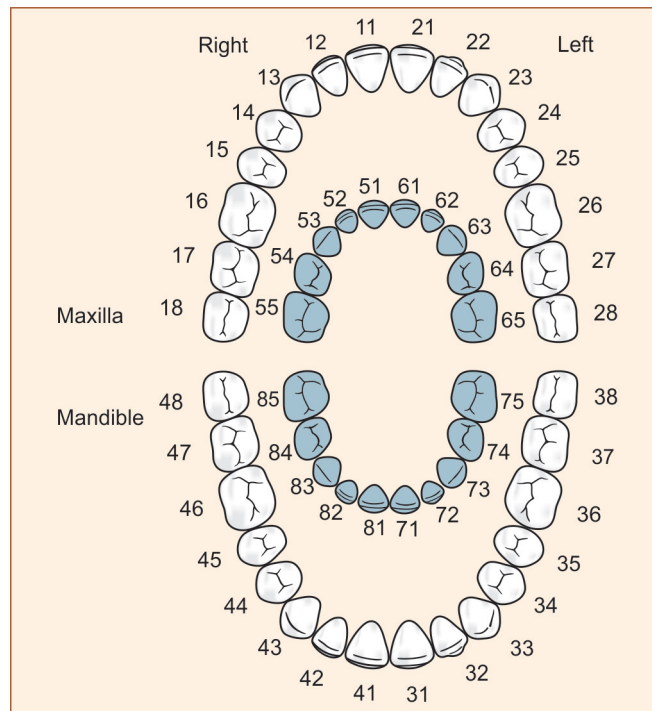
- In the deciduous dentition the numbering is correspondingly similar except that the quadrants are designated 5, 6, 7 and 8.
- Teeth are numbered from number 1 to 5, 1 being central incisor and 5 is second molar.

#### Advantages

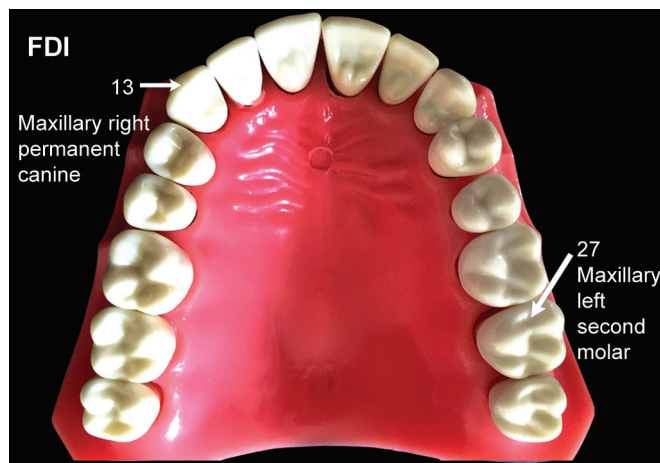- *Simple to understand*
- *Simple to learn*
- *Simple to pronounce*
- *No confusion*
- *Each tooth has specific number*
- *Easy to record on computers*
- *Easy for charting.*

#### Disadvantage

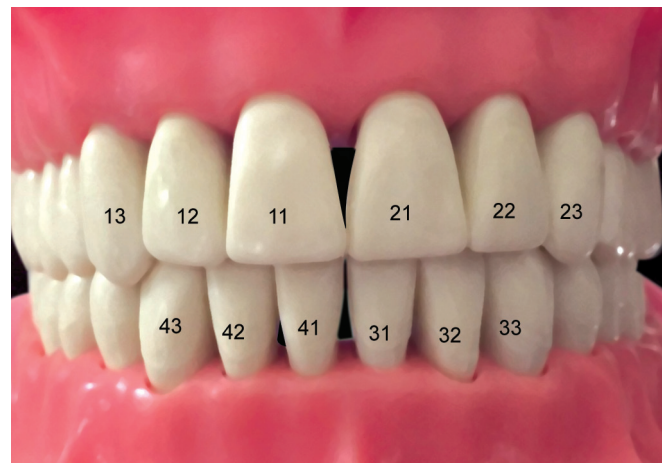*May be confused with universal tooth numbering system.*



**Figure 2.7:** Presentation of FDI system of tooth nomenclature for permanent and primary teeth



**Figure 2.8:** FDI notation of maxillary right canine and left second molar



**Figure 2.9:** FDI system for permanent teeth

**Figure 2.10** showing comparison of Zsigmondy palmer, universal and FDI system of tooth nomenclature. **Tables 2.1 and 2.2** summarizing Zsigmondy palmer, universal and FDI system in permanent and primary teeth respectively.

### NOMENCLATURE OF TOOTH SURFACES

The clinical crown of each tooth is divided into surfaces that are designated according to their related anatomic structures and landmarks (**Fig. 2.11**).

**Buccal surface:** Tooth surface facing the cheek.

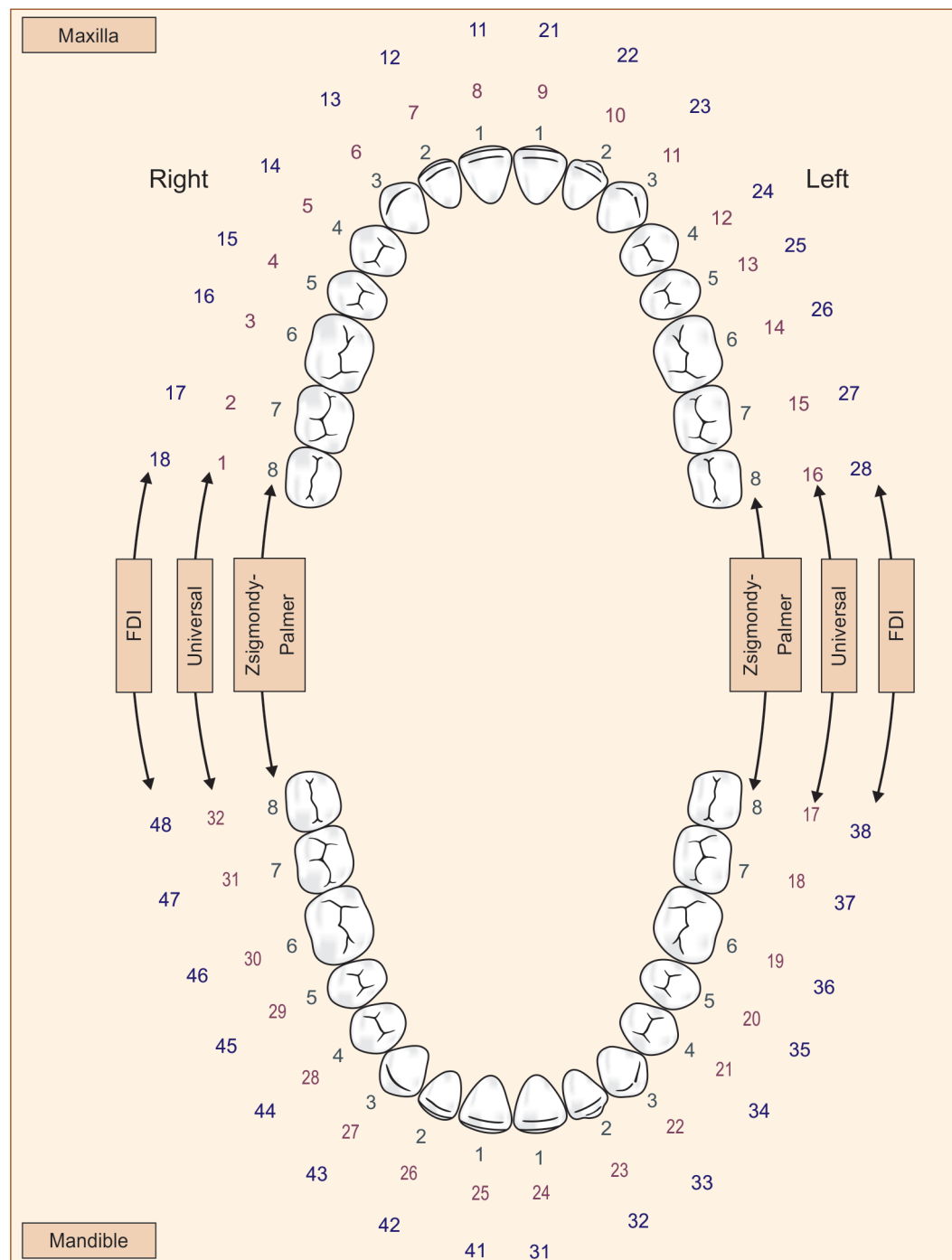
**Labial surface:** Tooth surface facing the lip.

**Facial surface:** Labial and buccal surface collectively form the facial surface.

**Mesial surface:** Tooth surface towards the anterior midline.

**Distal surface:** Tooth surface away from the anterior midline.

**Lingual surface:** Tooth surface towards the tongue.



**Figure 2.10:** From inner to outer ring. First row (Inner row)—Zsigmondy Palmer; Second row (middle row)—Universal; Third row (Outer row)—FDI

**Occlusal surface:** Masticating surface of posterior teeth (in molars and premolars).

**Incisal surface:** Functioning/cutting edge of anterior tooth of incisors and canines (cuspid).

**Gingival surface:** Tooth surface near to the gingiva.

**Cervical surface:** Tooth surface near the cervix or neck of the tooth.

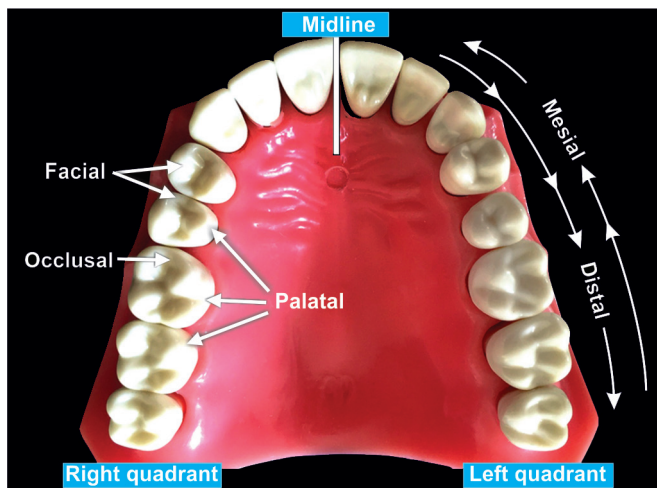
**Anatomic crown:** It is part of tooth that is covered with enamel (**Fig. 2.12**). It extends from cemento-enamel junction (CEJ) to occlusal or incisal surface.

**Table 2.1**  
Permanent teeth

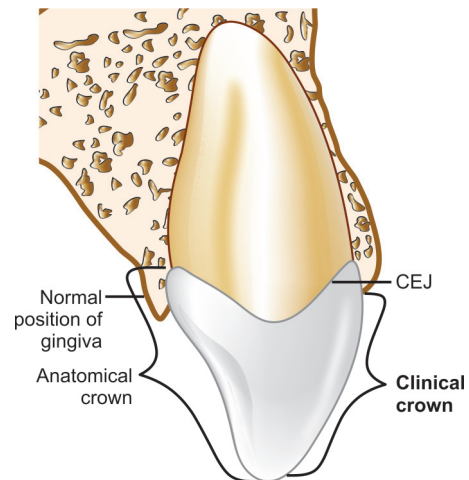
Zsigmondy-Palmer Notation															
8	7	6	5	4	3	2	1	1	2	3	4	5	6	7	8
8	7	6	5	4	3	2	1	1	2	3	4	5	6	7	8
Universal Numbering System															
Upper right								Upper left							
1	2	3	4	5	6	7	8	9	10	11	12	13	14	15	16
32	31	30	29	28	27	26	25	24	23	22	21	20	19	18	17
Lower right								Lower left							
FDI Two-digit Notation															
18	17	16	15	14	13	12	11	21	22	23	24	25	26	27	28
48	47	46	45	44	43	42	41	31	32	33	34	35	36	37	38

**Table 2.2**  
Deciduous teeth

Palmer Notation															
			E	D	C	B	A	A	B	C	D	E			
			E	D	C	B	A	A	B	C	D	E			
Universal Numbering System															
Upper right								Upper left							
			A	B	C	D	E	F	G	H	I	J			
			T	S	R	Q	P	O	N	M	L	K			
Lower right								Lower left							
FDI Two-digit Notation															
			55	54	53	52	51	61	62	63	64	65			
			85	84	83	82	81	71	72	73	74	75			



**Figure 2.11:** Diagrammatic representation of different surfaces of teeth



**Figure 2.12:** Schematic representation of anatomical crown and clinical crown



**Clinical crown:** It is part of tooth that is visible in oral cavity. In case of gingival recession, the clinical crown is longer than anatomical crown (**Fig. 2.13**).

### NOMENCLATURE RELATED TO DENTAL CARIES

#### Dental Caries

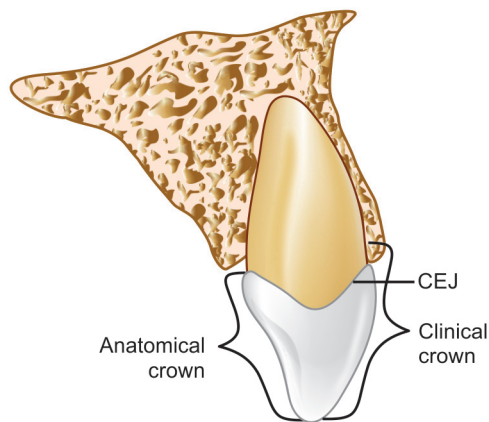
It is defined as a microbiological disease of the hard structure of teeth, which results in localized demineralization of the inorganic substance and destruction of the organic substance of the tooth (**Fig. 2.14**).

#### Primary Caries

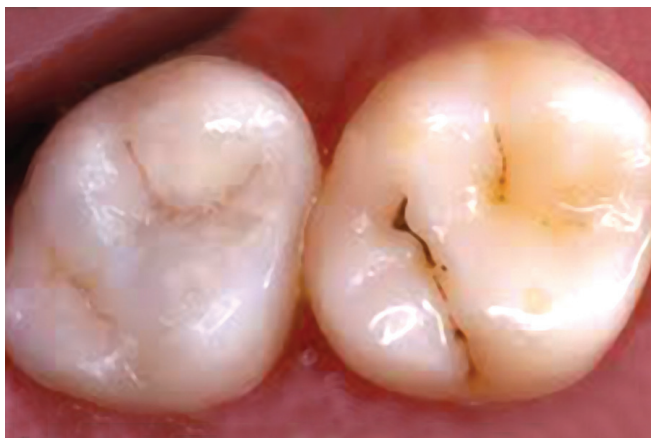Denotes lesions on unrestored surfaces, in other words it is the first attack on a tooth.

#### Secondary (Recurrent) Caries

Lesions developing adjacent or beneath existing restorations are referred to as 'secondary' or 'recurrent' caries (**Fig. 2.15**).



**Figure 2.13:** Schematic representation of a longer clinical crown than anatomical crown in case of gingival recession



**Figure 2.14:** Clinical presentation of dental caries in maxillary molar

#### Residual Caries

Demineralized tissue left in place before a restoration is placed. It can occur as a result of the clinician's neglect or intentionally.

#### Active Carious Lesion

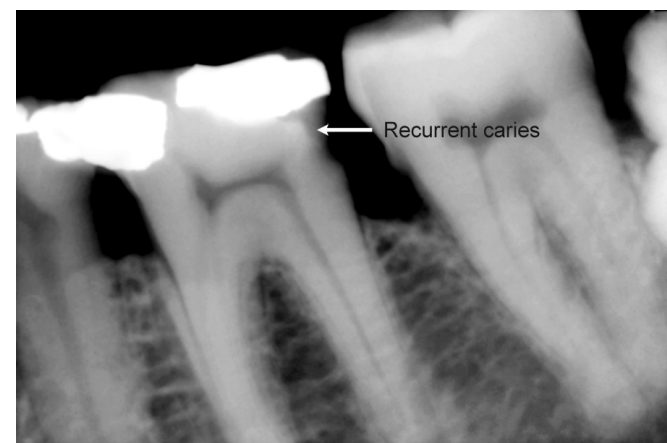
A lesion which is progressing is described as an active carious lesion.

#### Inactive/Arrested Carious Lesion

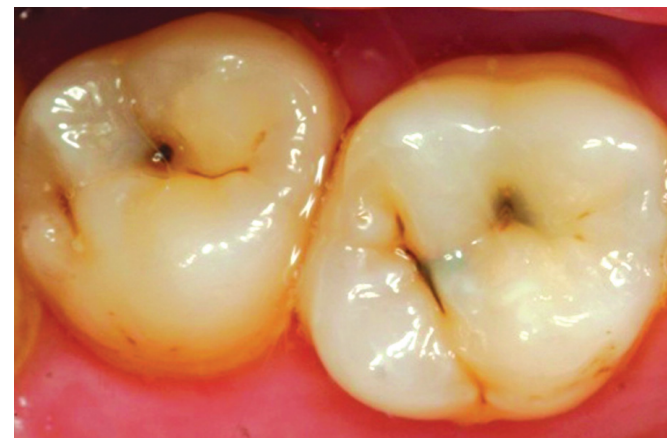A lesion that has formed and then not progressed is referred to as an 'arrested' or 'inactive' carious lesion. Arrested carious lesions are often characterized by a large open cavities which no longer retain food and become self-cleansing.

#### Pit and Fissure Caries

Pit and fissure caries describes caries which occurs on occlusal surface of posterior teeth, buccal and lingual surfaces of molars and on lingual surfaces of maxillary incisors (**Fig. 2.16**).



**Figure 2.15:** Radiograph showing recurrent caries



**Figure 2.16:** Clinical picture of pit and fissure caries

### Smooth Surface Caries

Smooth surface caries occurs on the gingival third of buccal and lingual surfaces and on approximal surfaces (**Fig. 2.17**).

### Root Caries

Root caries occur on exposed root cementum and dentin, usually following gingival recession (**Fig. 2.18**).

### Acute Dental Caries

Acute caries travels towards the pulp at a very fast speed.

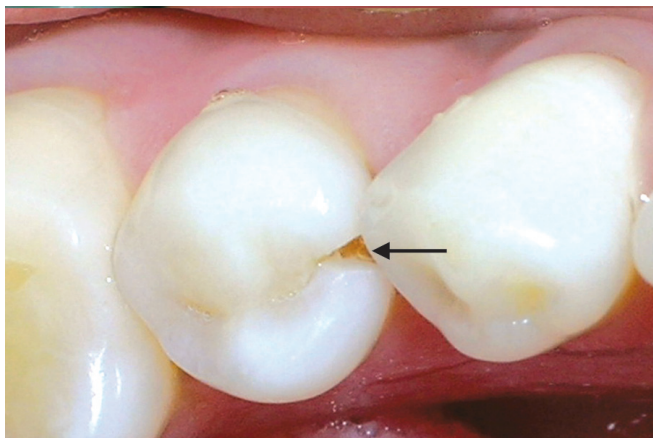
### Rampant Caries

The name given to multiple active carious lesions occurring in the same patient, frequently involving surfaces of teeth that are usually caries-free. Rampant caries can be of following three types:

1. Early childhood caries is a term used to describe dental caries presenting in the primary dentition of young children.
2. Bottle caries or nursing caries is seen in the primary dentition of infants and young children as a consequence of sucking on a bottle or dummy containing cariogenic liquids. The clinical pattern is characteristic, with the four maxillary deciduous incisors most severely affected.
3. Xerostomia induced rampant caries is commonly seen after radiotherapy of malignant lesions of the jaws, as the salivary glands may be damaged by the radiation resulting in reduced salivary flow.

### Chronic Dental Caries

Chronic caries progresses very slowly towards the pulp. Such lesions appear dark in color and hard in consistency.



**Figure 2.17:** Clinical picture of smooth surface caries

## NONCARIOUS DEFECTS OF TEETH

### Attrition

It is defined as a physiological, continuous, process resulting in loss of tooth structure from direct frictional forces between contacting teeth. It occurs both on occlusal and approximal surfaces. Attrition is accelerated by parafunctional mandibular movements, especially bruxism.

### Abrasion

It refers to the loss of tooth substance induced by mechanical wear other than that of mastication. Abrasion results in saucer-shaped or wedge-shaped indentations with a smooth, shiny surface (**Fig. 2.19**).

### Erosion

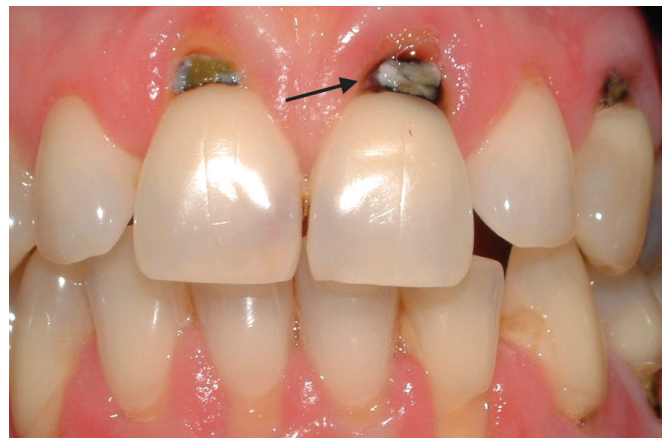It can be defined as a loss of tooth substance by a chemical process that does not involve known bacterial action. The eroded area appears smooth, hard and polished (**Fig. 2.20**).

### Abfraction

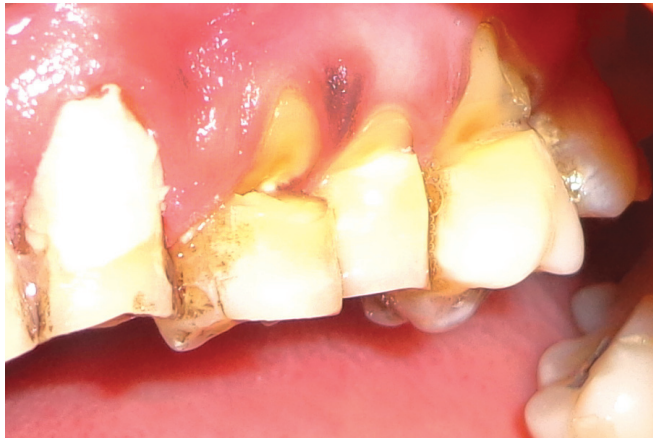Abfractions are the microfractures which appear in the enamel and possibly the dentine caused by flexion of the cervical area of the tooth under heavy loads. These lesions usually appear as wedge-shaped defects with sharp line angles.

### Resorption

'Resorption' is defined as "a condition associated with either a physiologic or a pathologic process resulting in the loss of dentin, cementum or bone".



**Figure 2.18:** Clinical picture of radicular caries



**Figure 2.19:** Clinical picture showing generalized abrasion of teeth

If resorption occurs, it is often because of some pathological process, although deciduous tooth roots undergo physiological resorption in order to be shed.

### Localized Nonhereditary Enamel Hypoplasia

Refers to the localized defects in the crown of the portion tooth caused by injury to ameloblasts during the enamel matrix formation stage. These lesions may appear as isolated pits or widespread linear defects, depressions or loss of a part of the enamel. Injury to ameloblasts may be caused by:

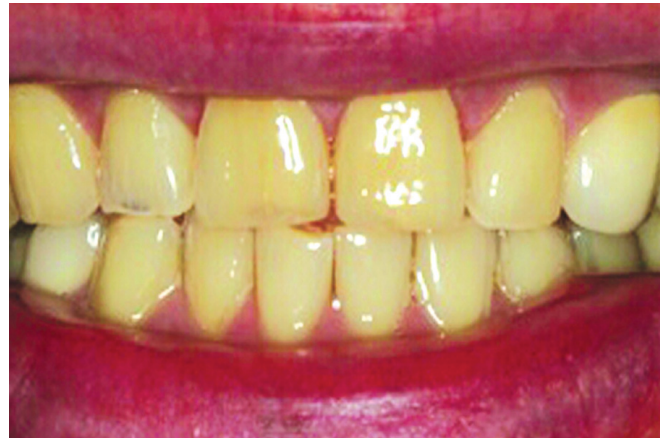- Traumatic intrusion of deciduous teeth
- Fluorosis
- Exanthematous diseases
- Deficiency of vitamins A, C or D
- Hypocalcemia.

### Localized Nonhereditary Enamel Hypocalcification

Refers to localized defects in the crown of a tooth due to injury to the ameloblasts during the mineralization stage. In these defects, the enamel is normal in structure but its mineralization is defective. The color of lesion varies from chalky to yellow, brown, dark brown or grayish.

### SUMMARY

- Dental anatomy or anatomy of teeth is the branch of anatomy which deals with the study of human teeth structures.
- For convenience human dentition is divided into four quadrants viz; upper (maxillary) right, upper (maxillary) left, lower (mandibular) right and lower (mandibular) left.
- Three most common systems are the FDI system, Universal numbering system and Zsigmondy-Palmer system.



**Figure 2.20:** Erosion of teeth results in their shiny and smooth appearance

- Universal system was given by American Dental Association in 1968. The universal numbering system uses a unique letter or number for each tooth.
- Zsigmondy-Palmer system was introduced in 1861. Primary teeth designated by A → E. Permanent teeth designated by 1 → 8. Simple and easy to use. Less chances of confusion.
- FDI system was introduced in 1971. Known as two-digit notation in two-digit system. First number represents tooth's quadrant while second number is the number of tooth from midline.

### EXAMINER'S CHOICE QUESTIONS

1. What are different nomenclature of teeth? Explain FDI nomenclature in detail.
2. What are the different nomenclatures of teeth? Discuss the FDI system in detail. Why is it widely used?
3. Write short notes on:
  - a. Zsigmondy-Palmer system.
  - b. Universal system.
  - c. FDI system.
  - d. Two-digit notation.

### BIBLIOGRAPHY

1. Ash Major M, Stanley J Nelson. Wheeler's Dental Anatomy, Physiology, and Occlusion. 8th ed. 2003.p.198.
2. Blinkhorn AS, Choi CLK, Paget HE. An investigation into the use of the FDI tooth notation system by dental schools in the UK. Eur J Dent Educ. 1998;2:39.
3. Ten Cate AR, Oral Histology. Development, Structure, and Function, 5th ed. Saint Louis: Mosby-Year Book, 1998.p.95.
4. Ten Cate AR, Oral Histology. Development, Structure, and Function, 5th ed. Saint Louis: Mosby-Year Book, 1998.pp.86 and 102.



# Structure of Teeth

## Chapter Outline

- Introduction
- Enamel
- Dentin
- Dental Pulp
- Periradicular Tissue

## INTRODUCTION

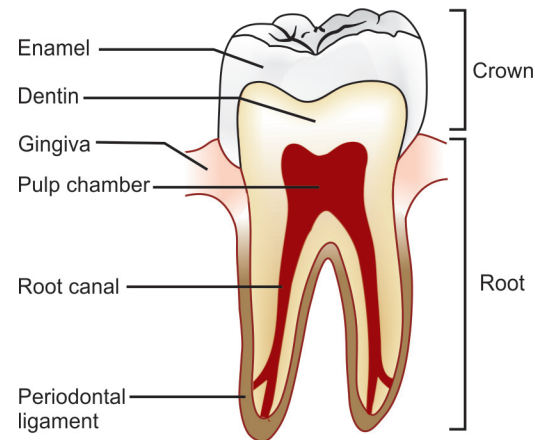
The tooth is composed of three hard mineralized tissues, i.e. and one soft tissue viz; pulp. The outermost layer of enamel, is mostly inorganic and is the hardest tissue in the body. It covers part or all of the crown of the tooth. The middle layer of the tooth is composed of dentin, which is less hard than enamel and similar in composition to bone. Dentin forms the main bulk of each tooth and extends almost the entire length of the tooth, being covered by enamel on the crown portion and by cementum on the roots. Dentin is nourished by the pulp, which is the innermost portion of the tooth. In this chapter we will discuss the structures present in teeth and their clinical significance.

## ENAMEL

Tooth enamel is the hardest and highly mineralized tissue which covers crown of the tooth. It is responsible for color, esthetics, texture and translucency of the tooth (**Fig. 3.1**).

## Composition

It is highly mineralized structure which mainly contains inorganic contents in the form of crystalline structure. Main inorganic content in the enamel is hydroxyapatite. In addition to inorganic content, it also contains a small portion of organic matrix along with small amount of water which is present in intercrystalline spaces.



**Figure 3.1:** Enamel, dentin, pulp and supporting structures

### Composition of enamel

- **Inorganic contents (by volume)**
  - Hydroxyapatite—90 to 92 percent
  - Other minerals and trace elements—3 to 5 percent
- **Organic contents (by volume)**
  - Proteins and lipids—1 to 2 percent
  - Water—4 percent.

## Structure

- Mainly composed of enamel rods or prisms as well as sheaths and a cementing inter-rod substance.

- Each rod has a head and tail, head is directed occlusally and the tail is directed cervically.
- In transverse sections, enamel rods appear as hexagonal, round or oval. These may resemble fish scales.
- Rods or the prisms run in an alternating course of clockwise and anticlockwise direction (twisting course). Initially there is wavy course in one-third of enamel thickness adjacent to DEJ, then the course becomes more straight in the remaining thickness.
- Rods are oriented at perpendicular to the dentinoenamel junction. Towards the incisal edge these become increasingly oblique and are almost vertical at the cusp tips. In the cervical region, there is difference in the direction of the enamel rods of deciduous and permanent teeth (**Fig. 3.2**).

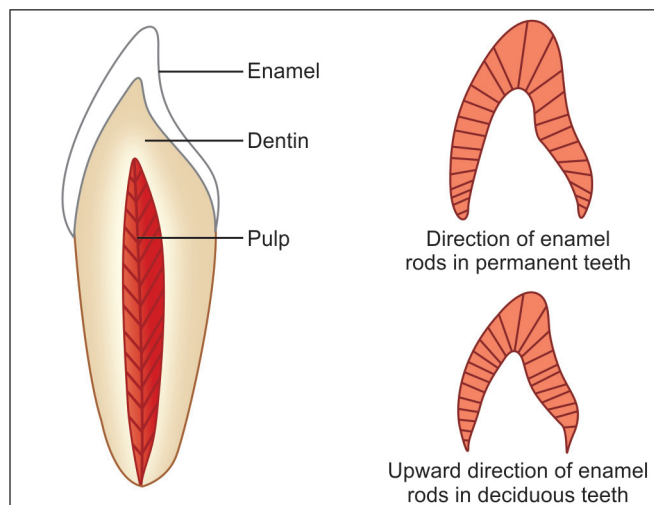
### Significance

Cervical enamel rods of deciduous teeth are inclined incisally or occlusally, while in permanent teeth they are inclined apically. This change in direction of enamel rods should be kept in mind during tooth preparation so as to avoid unsupported enamel rods at gingival seat.

### Thickness

- Average thickness of enamel at the incisal edges of incisors is 2 mm; at the cusp of premolar and molar it ranges from 2.3 to 3.0 mm.
- Thickness decreases gradually from cusps or incisal edges to cemento-enamel junction.

Tooth type	Enamel Thickness
• Anterior tooth (incisal edges)	2.0 mm
• Premolar tooth (cusp)	2.3 to 2.5 mm
• Molar tooth (cusp)	2.5 to 3.0 mm



**Figure 3.2:** Direction of enamel rods in deciduous and permanent teeth

### Color

- Enamel is translucent in nature. Color of tooth mainly depends upon three factors:
  1. Color of underlying dentin
  2. Thickness of enamel
  3. Amount of stains in enamel.
- Translucency of enamel is directly related to the degree of mineralization and homogeneity.
- Anomalies occurring during developmental and mineralization stage, antibiotic usage and excess fluoride intake, affect the color of the tooth.

### Strength

- Enamel is brittle, has a high modulus of elasticity.
- Specific gravity of enamel is 2.8.
- Hardness of enamel is different in different areas of the external surface of a tooth. Hardness decreases from outer surface to its inner surface.

### Significance

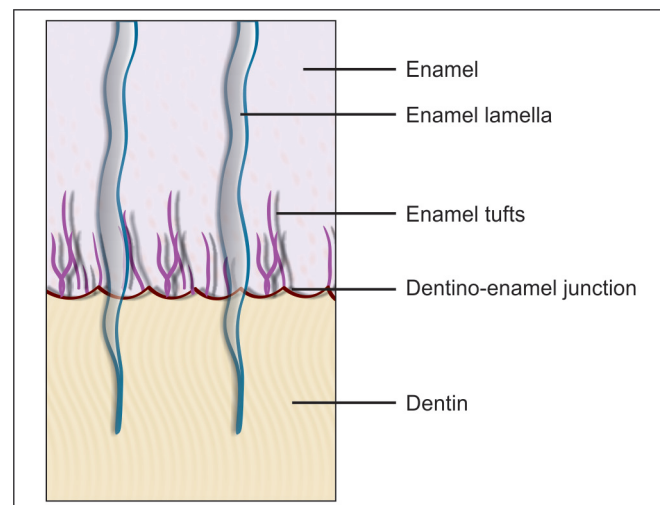
Because of more compressive strength of dentin than enamel, the dentin acts as a cushion for enamel when masticatory forces are applied on it. For this reason, during tooth preparation, for maximal strength of underlying remaining tooth structure, all enamel rods should be supported by healthy dentin base.

### Structures

Different structures present in enamel are shown in **Fig. 3.3**.

### Gnarled Enamel

- There are group of irregular enamel that is more resistant to cleavage, called **Gnarled enamel**, present mostly in cervical, incisal and occlusal portion.



**Figure 3.3:** Schematic representation of different structures present in enamel

- This consists of bundles of enamel rods which intertwine in an irregular manner with other group of rods, finally taking a twisted and irregular path towards the tooth surface.

**Significance:** The orientation of enamel rod heads and tails, and gnarling of enamel rods provide strength by resisting, and dissipating impact forces.

### *Bands of Hunter-Schreger*

- Hunter-Schreger bands occur because of alteration of light reflection (optical phenomenon) due to changes in rod direction. This results in alternating light and dark zones under the microscope.

**Significance:** They are considered to resist and disperse the strong forces.

### *Enamel Tufts*

- Enamel tufts are ribbon-like structures which run from dentin to enamel. They are named so because they resemble tufts of grass.

**Significance:** Enamel tufts are hypomineralized structure in the enamel, thus play a role in spread of dental infection.

### *Enamel Lamellae*

- These are leaf-like defects present in enamel and may extend to DEJ. They contain organic substances.
- Lamellae are commonly found at the base of occlusal pits and fissures.
- These are caused by 'imperfect calcification of enamel tissue'.

**Significance:** A lamella at the base of an occlusal fissure provides an appropriate pathway for bacteria and initiates caries.

### *Enamel Spindles*

Odontoblastic processes sometimes cross DEJ and their ends are thickened, called enamel spindles.

**Significance:** Spindles serve as pain receptors, that is why, when we cut in the enamel, patient complains of pain.

### *Striae of Retzius*

- They appear as brownish bands in the ground sections and illustrate the incremental pattern of enamel.
- These represent the rest periods of ameloblast during enamel formation, therefore, also called as growth circles.
- Striae of Retzius are stripes that appear on enamel when viewed microscopically in cross-section. Formed from changes in diameter of 'Tomes' processes, these stripes demonstrate the growth of enamel, similar to the annual rings on a tree.

### *Prismless Layer*

- There is structureless layer of enamel near the cervical line and to a lesser extent on the cusp tip which is more mineralized.

### *Dentino-enamel Junction*

- Dentino-enamel junction is pitted/scalloped in which crests are toward enamel and shallow depressions are in dentin. This helps in better interlocking between enamel and dentin. Surface area of dentin is much larger at DEJ than on cavity or pulp side.

**Significance:** Scalloped shape and interlocking of enamel and dentin at dentino-enamel junction prevents tearing of enamel during functions.

### *Occlusal Pits and Fissures*

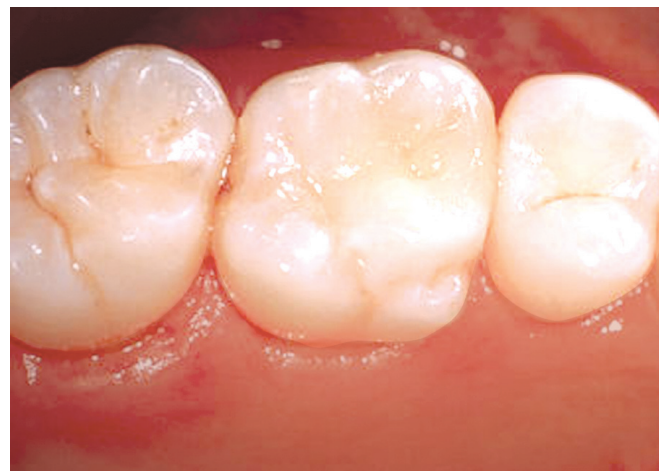- Pits and fissures are formed by faulty coalescence of developmental lobes of premolars and molars (**Fig. 3.4**).
- These are commonly seen on occlusal surfaces of premolars and molars.

### **Significance:**

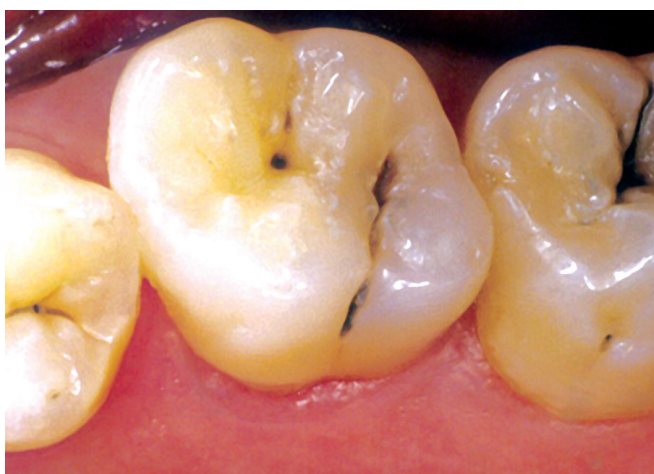- Thickness of enamel at the base of pit and fissure is less.
- Pits and fissures are the areas of food and bacteria impaction which make them caries prone (**Fig. 3.5**).
- V-shaped grooves provide escapement of food when cusps of teeth of opposite arch occlude during mastication.

### **Functions**

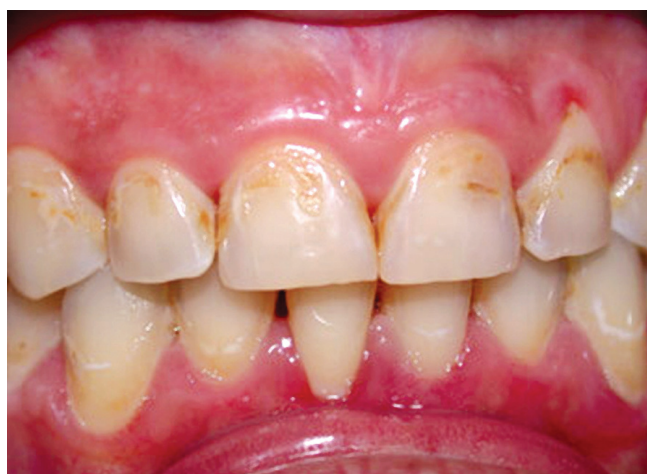- It is hardest structure of tooth which supports masticatory forces.
- It is mainly responsible for color, esthetics, surface texture and translucency of the tooth.
- It also supports the underlying dentin and pulp.



**Figure 3.4:** Pits and fissures of premolars and molars



**Figure 3.5:** Deep pits and fissures making areas favorable for food impaction



**Figure 3.6:** Photograph showing discolored teeth due to fluorosis

### Clinical Significance

- **Color:** Color of the enamel varies because of the following factors:
  - Age
  - Ingestion of tetracycline during the formative stages
  - Ingestion of fluoride (**Fig. 3.6**)
  - Extrinsic stains
  - Developmental defects of tooth.
- **Attrition:** It is mechanical wear of enamel on occlusal surfaces and proximal contact. Sometimes bruxism or contacts with porcelain also lead to attrition. So, in these patients, try to avoid placing the margins of restoration in occlusal contact area or place a restorative material that wears at a same rate as enamel.
- **Acid etching:** Acid etching causes preferential dissolution of enamel surface and helps in increasing the bonding between resin and enamel.
- **Permeability:** Hypomineralized areas present in the enamel are more permeable than mineralized area.
- Defective surfaces like hypoplastic areas, pits and fissures are at more risk for dental caries.
- Cracks present on the enamel surface, sometimes, lead to pulpal death and fracture of the tooth.
- To avoid fracture of tooth and restoration, enamel walls should be supported by underlying dentin. Also the preparation walls should be made parallel to direction of enamel rods since enamel rod boundaries are natural cleavage lines through which fracture can occur.
- **Remineralization:** Remineralization is only because of enamel's permeability to fluoride, calcium and phosphate (available from saliva or other sources).

### DENTIN

Dentin is the most voluminous mineralized connective tissue of the tooth. Enamel covers the dentin in crown portion while cementum covers the dentin in root portion.

### Composition

- Dentin contains 70 percent inorganic hydroxyapatite crystals and the rest is organic substance and water making it more resilient than enamel. Organic components consist of collagen Type 1.

<i>Composition of Dentin</i>	<i>(By weight)</i>
• Inorganic material	70%
• Organic material	20%
• Water	10%

### Color

- Dentin is slightly darker than enamel and is generally light yellowish in young individuals while it becomes darker with age.
- On constant exposure to oral fluids and other irritants, the color becomes light brown or black (**Fig. 3.7**).

### Thickness

- Dentin thickness is usually more on the cuspal heights and incisal edges and less in the cervical areas of tooth. It is around 3 to 3.5 mm on the coronal surface.
- With advancing age and various irritants, the thickness of secondary and tertiary dentin increases.