

Volume 2

# Fundamentals of Implant Dentistry

## *Surgical Principles*

*Edited by*

Peter K. Moy, DMD

Alessandro Pozzi, DDS, PhD

John Beumer III, DDS, MS

## Fundamentals of Implant Dentistry: Surgical Principles



Volume 2

# Fundamentals of Implant Dentistry

## *Surgical Principles*

*Edited by*

**Peter K. Moy, DMD**

Nobel Biocare Chair of Surgical Implant Dentistry  
Director, Straumann Implant Surgery Clinic  
Clinical Professor, Section of Oral and Maxillofacial Surgery  
School of Dentistry  
University of California, Los Angeles

Private Practice  
Los Angeles, California

**Alessandro Pozzi, DDS, PhD**

Interim Chair  
Oral Surgery and Implant Dentistry  
Marche Polytechnic University  
Ancona, Italy

Private Practice  
Rome, Italy

**John Beumer III, DDS, MS**

Distinguished Professor Emeritus  
Division of Advanced Prosthodontics  
School of Dentistry  
University of California, Los Angeles  
Los Angeles, California

 **QUINTESSENCE PUBLISHING  
USA**

Chicago, Berlin, Tokyo, London, Paris, Milan, Barcelona, Istanbul,  
Moscow, New Delhi, Prague, São Paulo, Seoul, and Warsaw

**Library of Congress Cataloging-in-Publication Data**

Fundamentals of implant dentistry / edited by John Beumer III, Robert F. Faulkner, Kumar C. Shah, and Peter K. Moy.  
p. ; cm.

Includes bibliographical references and index.

ISBN 978-0-86715-585-3 (v. 2)

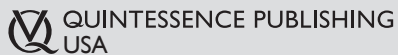
I. Beumer, John, III, 1941- , editor. II. Faulkner, Robert F., editor. III. Shah, Kumar C., editor. IV. Moy, Peter K., editor.

[DNLM: 1. Dental Implants. 2. Dental Implantation--methods. 3. Tooth Diseases--surgery. WU 640]

RK667.I45

617.6'93--dc23

2014028016



© 2016 Quintessence Publishing Co, Inc

Quintessence Publishing Co, Inc  
4350 Chandler Drive  
Hanover Park, IL 60133  
www.quintpub.com

5 4 3 2 1

All rights reserved. This book or any part thereof may not be reproduced, stored in a retrieval system, or transmitted in any form or by any means, electronic, mechanical, photocopying, or otherwise, without prior written permission of the publisher.

Editor: Leah Huffman  
Production: Sue Robinson

Printed in China

# Dedication

*To my loving and devoted wife and life partner, Irene, who has graciously given me the needed time and space to complete this book, and my wonderful children, Janine and Geoffrey, for their understanding and for accepting the many missed tennis tournaments, jumping competitions, ball games, and wrestling matches. Thank you for your support and unconditional love.*

– Peter K. Moy

*To my mother, Anna, for guidance and discipline. And to my brother, Giuseppe—his passion for minimally invasive surgery encouraged me to pursue my dreams.*

– Alessandro Pozzi

*To Jan, for her continuing love and support.*

– John Beumer III

# Contents

---

In Memoriam *viii*

Preface *ix*

Contributors *x*


1. **History and Introduction to Implant Surgery** 1  
*Peter K. Moy, John Beumer III, and Tomas Janson*
2. **The Evolution of Modern Dental Implant Surfaces** 25  
*Takahiro Ogawa, Basil Al-Amleh, Ichiro Nishimura, and John Beumer III*
3. **Medical History and Physical Examination** 51  
*Nora Kahenasa, Peter K. Moy, John Beumer III, and Alessandro Pozzi*
4. **Workup and Diagnostic Procedures** 77  
*Peter K. Moy, John Beumer III, Robert F. Faulkner, and Alessandro Pozzi*
5. **Implant Surgery Basics** 115  
*Peter K. Moy, Patrick Palacci, Alessandro Pozzi, and John Beumer III*
6. **Computer-Guided Planning and Surgery** 159  
*Alessandro Pozzi, Peter K. Moy, Robert F. Faulkner, and John Beumer III*
7. **Tilted and Zygomatic Implants** 185  
*Joan Pi-Urgell, Jay Jayanetti, Peter K. Moy, and John Beumer III*
8. **Hard and Soft Tissue Augmentation** 205  
*Peter K. Moy, Alessandro Pozzi, Patrick Palacci, Ravi Chandran, Daniel Spagnoli, Giovanni Cricchio, Stefan Lundgren, Tara Aghaloo, Joan Pi-Anfruns, Oz Simel, and Anil Danda*

9. **Reconstruction of Major Maxillary and Mandibular Defects with Implants** 259  
*Beomjune B. Kim, Waleed Zaid, Daniel Spagnoli, Peter K. Moy, and W. Howard Davis*
10. **Surgical Considerations for the Esthetic Zone** 291  
*Alessandro Pozzi, Peter K. Moy, Robert F. Faulkner, and John Beumer III*
11. **Immediate Loading, Immediate Provisionalization, and Delayed Loading** 333  
*Alessandro Pozzi, John Beumer III, Peter K. Moy, and Robert F. Faulkner*
12. **Maintenance and Follow-Up** 375  
*David B. Krill and Robert F. Faulkner*
13. **Surgical Complications of Implant Placement** 397  
*Peter K. Moy, Alessandro Pozzi, and John Beumer III*
- Glossary** 409
- Index** 419



# In Memoriam

---



**Per-Ingvar Brånemark**, MD, PhD

May 3, 1929–December 20, 2014

In today's world we instantly recognize great entrepreneurs, innovators, and people who have made a profound difference in our world and transformed our daily lives. Today more than 8 million people have benefited from Brånemark's landmark discovery of osseointegration and surgical techniques since he treated his first implant patient in 1965. Professor Brånemark has played the quintessential role in transforming the world of dentistry with his discovery.

# Preface

Although it is accepted that implant dentistry is restoratively driven, the surgical aspects are none the less critical to producing successful outcomes. In volume 1 we stressed that sound prosthodontic principles and an interdisciplinary approach are key to managing dental implant patients. This volume demonstrates how the surgeon plays a leading role in the decision-making process during treatment planning and surgical management. When restorative dentists and nonsurgical specialists place dental implants, the accountability is the same as it is for a trained surgical specialist. Therefore, we strongly encourage restorative specialists to seek further surgical training before taking on this responsibility. We continue to believe that an interdisciplinary approach is best and will provide better outcomes, especially in more complex implant cases.

It is virtually impossible for one individual to stay abreast of the many significant and rapid advancements in implant dentistry. These include technologic advancements in computer-aided design/computer-assisted manufacturing (CAD/CAM), new implant designs and surfaces, compatibility and effectiveness of new biomaterials, and evolving surgical approaches enabling more accurate and ideal positioning of dental implants. Thus, the team approach as initially taught by Professor P-I Brånemark, whereby the surgical and restorative specialists work together, still holds true. This volume promotes this concept throughout.

The first four chapters illustrate the basic approach that should be taken in implant dentistry, emphasizing the importance of the patient's medical history and the need for an interdisciplinary diagnostic workup. The middle chapters present both the routine surgical procedures used in implant dentistry and more novel techniques such as tilting the implant to gain additional length and better biomechanical distribution. Advanced surgical techniques

such as hard and soft tissue grafting, managing the esthetic zone, and various loading protocols are then described, and the concluding chapters discuss maintenance and complications. Because success rates for dental implants are high, novice surgeons sometimes forget that the hard and soft tissue support around implants can be disrupted and will be lost with time if the patient does not maintain adequate home care. Dental implants are not impervious to poor surgical and prosthetic techniques, lack of maintenance and home care, or overloading forces. The clinician providing implant treatment must maintain a watchful eye from start to finish.

Finally, as in volume 1, we have included an illustrated glossary to bring the implant surgeon up to date on the ever-changing terminology associated with the new concepts, techniques, and materials introduced to the field of implant dentistry.

## Acknowledgments

The editors would like to acknowledge and thank our friends and colleagues from around the world in this wonderful profession who have been mentors, instructors, and advisors, setting shining examples of how to be the consummate professional in dentistry. We also want to thank all of the authors and coauthors who have given their time and tremendous effort to complete this second volume and shared their vast knowledge and expertise. Last but not least, we would like to thank Professor P-I Brånemark for imparting to all of us his infinite wisdom, enthusiasm, determination to find answers and solutions to problems, and compassion for the patient. We truly hope he is reading this book with a smile on his face, a gleam in his eyes, and a nod of approval.

# Contributors

## **Tara Aghaloo**, DDS, PhD

Professor

Section of Oral and Maxillofacial Surgery

UCLA School of Dentistry

Los Angeles, California

- *Chapter 8: Primary section author, "Growth Factors in Implant Dentistry"*

## **Basil Al-Amleh**, BDS, DClinDent (Otago),

MRACDS(Pros)

Senior Lecturer

Department of Oral Rehabilitation

Faculty of Dentistry

University of Otago

Dunedin, New Zealand

- *Chapter 2: Primary section author, "Ceramic Dental Implants"*

## **John Beumer III**, DDS, MS

Distinguished Professor Emeritus

Division of Advanced Prosthodontics

UCLA School of Dentistry

Los Angeles, California

- *Chapter 1: Secondary author*
- *Chapter 2: Secondary author*
- *Chapter 3: Primary section author, "Impact of cancerocidal doses of radiation to potential implant sites," "Impact of chemotherapy and concomitant chemoradiation," and "Impact of bisphosphonates and related medications"*
- *Chapter 4: Secondary author*
- *Chapter 5: Secondary author*
- *Chapter 6: Secondary author*
- *Chapter 7: Secondary author*
- *Chapter 10: Secondary author*
- *Chapter 11: Secondary author*
- *Chapter 13: Secondary author*

## **Ravi Chandran**, DMD, PhD

Assistant Professor

Oral and Maxillofacial Surgery

University of Mississippi Medical Center

Jackson, Mississippi

- *Chapter 8: Secondary section author, "The Need for Hard Tissue Augmentation"*

## **Giovanni Cricchio**, DDS, PhD

Department of Oral and Maxillofacial Surgery

Umeå University

Umeå, Sweden

Private Practice

Palermo, Italy

- *Chapter 8: Primary section author, "Sinus Augmentation Techniques"*

## **Anil Danda**, BDS

Advanced Clinical Training Program, Surgical Implant

Dentistry

Division of Diagnostic and Surgical Sciences

UCLA School of Dentistry

Los Angeles, California

- *Chapter 8: Secondary section author, "Growth Factors in Implant Dentistry"*

## **W. Howard Davis**, DDS

Retired Oral and Maxillofacial Surgeon

Long Beach, California

- *Chapter 9: Secondary author*

## **Robert F. Faulkner**, DDS, MS

Lecturer

Division of Advanced Prosthodontics

UCLA School of Dentistry

Los Angeles, California

Private Practice

Cincinnati, Ohio

- *Chapter 4: Secondary author*
- *Chapter 6: Secondary author*
- *Chapter 10: Secondary author*
- *Chapter 11: Secondary author*
- *Chapter 12: Secondary author*
- *Chapter 13: Secondary author*

## **Tomas Janson**, DDS

Retired Prosthodontist

San Diego, California

- *Chapter 1: Secondary author*

**Jay Jayanetti**, DDS

Assistant Clinical Professor  
Division of Advanced Prosthodontics  
UCLA School of Dentistry  
Los Angeles, California

- *Chapter 7: Primary section author, "Zygomatic Implants"*

**Nora Kahenasa**, DMD

Lecturer  
Section of Oral and Maxillofacial Surgery  
UCLA School of Dentistry

Private Practice  
Los Angeles, California

- *Chapter 3: Primary author*

**Beomjune B. Kim**, DMD, MD

Assistant Professor  
Department of Oral and Maxillofacial Surgery  
School of Dentistry  
Louisiana State University  
New Orleans, Louisiana

- *Chapter 9: Primary author*

**David B. Krill**, DMD

Private Practice  
Cincinnati, Ohio

- *Chapter 12: Primary author*

**Stefan Lundgren**, DDS, PhD

Professor and Chairman  
Department of Oral and Maxillofacial Surgery  
Umeå University  
Umeå, Sweden

- *Chapter 8: Secondary section author, "Sinus Augmentation Techniques"*

**Peter K. Moy**, DMD

Nobel Biocare Chair of Surgical Implant Dentistry  
Director, Straumann Implant Surgery Clinic  
Clinical Professor, Section of Oral and Maxillofacial Surgery  
UCLA School of Dentistry

Private Practice  
Los Angeles, California

- *Chapter 1: Primary author*
- *Chapter 3: Secondary author*
- *Chapter 4: Primary author*
- *Chapter 5: Primary author*
- *Chapter 6: Secondary author*
- *Chapter 7: Secondary author*
- *Chapter 8: Primary author*
- *Chapter 9: Secondary author*
- *Chapter 10: Secondary author*
- *Chapter 11: Secondary author*
- *Chapter 13: Primary author*

**Ichiro Nishimura**, DDS, PhD

Professor  
Division of Advanced Prosthodontics  
UCLA School of Dentistry  
Los Angeles, California

- *Chapter 2: Secondary author*

**Takahiro Ogawa**, DDS, PhD

Professor  
Division of Advanced Prosthodontics  
UCLA School of Dentistry  
Los Angeles, California

- *Chapter 2: Primary author*

**Patrick Palacci**, DDS

Private Practice  
Marseilles, France

- *Chapter 5: Secondary author*
- *Chapter 8: Primary section author, "Soft Tissue Augmentation Techniques"*

## Contributors

---

### **Joan Pi-Anfruns**, DDS

Assistant Clinical Professor  
Division of Diagnostic and Surgical Sciences and  
Restorative Dentistry  
UCLA School of Dentistry  
Los Angeles, California

- *Chapter 8: Secondary section author, "Growth Factors in Implant Dentistry"*

### **Joan Pi-Urgell**, MD, DDS

Private Practice  
Barcelona, Spain

- *Chapter 7: Primary author*

### **Alessandro Pozzi**, DDS, PhD

Interim Chair  
Oral Surgery and Implant Dentistry  
Marche Polytechnic University  
Ancona, Italy

Private Practice  
Rome, Italy

- *Chapter 3: Secondary author*
- *Chapter 4: Secondary author*
- *Chapter 5: Secondary author*
- *Chapter 6: Primary author*
- *Chapter 8: Secondary author*
- *Chapter 10: Primary author*
- *Chapter 11: Primary author*
- *Chapter 13: Secondary author*

### **Oz Simel**, DDS

Resident, Section of Oral and Maxillofacial Surgery  
Division of Diagnostic and Surgical Sciences  
UCLA School of Dentistry  
Los Angeles, California

- *Chapter 8: Secondary section author, "Growth Factors in Implant Dentistry"*

### **Daniel Spagnoli**, DDS, MS, PhD

Private Practice  
Southport, North Carolina

- *Chapter 8: Secondary section author, "The Need for Hard Tissue Augmentation"*
- *Chapter 9: Secondary author*

### **Waleed Zaid**, DDS, MSc

Assistant Clinical Professor  
Department of Oral and Maxillofacial Surgery  
School of Dentistry  
Louisiana State University  
New Orleans, Louisiana

- *Chapter 9: Secondary author*

Peter K. Moy  
John Beumer III  
Tomas Janson

# History and Introduction to Implant Surgery

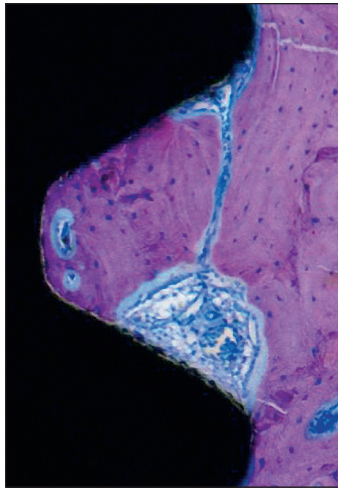
# 1

The phenomenon of osseointegration has had a greater impact on the practice of dentistry than any technology introduced during the last 35 years. Since its introduction, significant advances have been achieved in implant surface bioreactivity; methods used in diagnosis and treatment planning, particularly three-dimensional (3D) imaging and computer-aided design/computer-assisted manufacturing (CAD/CAM) techniques; enhancement of bone and soft tissues of potential implant sites; and prosthodontic approaches and techniques. A degree of predictability with implants has been achieved that was unthinkable before the introduction of the concept of osseointegration.

What is meant by the term *osseointegration*? The first definition, and the definition used by most clinicians and researchers today, was coined in the 1960s by the discoverer of the concept, the late Per-Ingvar Brånemark, Professor of Anatomy at the University of Gothenburg in Sweden. He defined *osseointegration* as the “direct structural and functional contact between ordered, living bone and the surface of a load-carrying implant” (Fig 1-1). This definition has been refined and expanded as researchers have gained additional insight into the process of osseointegration by electron microscopy and other sophisticated research tools.

## Management of a Dental Implant Patient

Since the introduction of osseointegration, the evolution of implant dentistry has achieved a high level of sophistication, resulting in highly predictable and successful clinical outcomes. The management of a dental implant patient is similar to that of a dental patient with complex dental needs. The treatment for an implant patient requires the same meticulous workup and diagnostic evaluations/measurements, regardless of whether a single tooth, multiple teeth, or the fully edentulous arches are to be restored. Patients requiring complex dental treatment often require the expertise of numerous dental specialists and close coordination and cooperation between all dental care providers. The patient will often need treatment provided by an orthodontist for realignment of the dentition and correction of occlusal discrepancies, a surgeon for correction of skeletal discrepancies and to enhance hard and soft tissue volume or improve gingival health and quality, an endodontist to manage adjacent teeth with periapical pathology, and a restorative specialist to manage the sequence of treatment and to design and fabricate the definitive dental



**Fig 1-1** Bone is deposited on the surface of the implant, firmly anchoring the implant in bone. (Courtesy of Dr M. Weinländer, Vienna, Austria.)

prostheses. Interdisciplinary collaboration and management is especially important for the dental implant patient because the esthetic and functional outcomes of the dental implant-retained prosthesis is dependent on the health of the adjacent natural dentition and supporting structures.

Due to the significant advancements in implant dentistry, including improved bioreactivity of modern implant surfaces, advances in the configuration of the implant body design and thread pattern, new methods and use of growth factors to enhance bone and soft tissue, use of allogeneic stem cells to provide new means for augmenting peri-implant mucosa, computer-based planning and guided surgical placement of implants, computer-designed and -manufactured abutments, prosthetic frameworks and prostheses, and improvement of implant-abutment connections, the implant team members providing implant treatment must learn and master several new technologies if ideal outcomes and long-term success are to be achieved. The implant team must also be aware and make known to the patient that appropriate esthetic and functional outcomes can be achieved with conventional treatment approaches and that these options are often in the best interest of the patient.

If the implant treatment option is selected, the implant team must be well aware of clinical conditions that affect treatment outcomes. The implant patient may require significant augmentation of bone and soft tissues. The clinician is dealing with missing teeth in a variety of intraoral sites (functional versus esthetic zones), and often these teeth have been lost over extended periods, thus seriously impacting hard and soft tissue volumes. The impact of these tissue changes is time-dependent and may be exacerbated by the use of a poorly designed and ill-fitting removable prosthesis.

The ability of the clinician to achieve acceptable functional and esthetic outcomes with implant treatment will be dependent on the clinician's knowledge of surgical and prosthetic principles and his or her application of these principles to cor-

rect the clinical deficiencies. When an augmentation procedure is required, regardless of the need to embellish hard and/or soft tissues, special consideration must be given to the donor graft materials selected. With advancements in stem cell research and the identification of growth factors, there are many new viable options and solutions. The clinician performing these augmentation procedures must understand basic biologic principles and use sound surgical techniques to achieve optimal outcomes for their patients.

Prior to the actual implant placement, the clinician must determine the best implant design to meet the specific requirements of the prosthetic plan and the expectations of the patient. Due to the improved understanding of the osseointegration process and improvements in the osteoconductivity of modern implant surfaces, most implants commercially available today achieve successful clinical outcomes. The choices made by the implant team are often dependent on the prosthetic components available and the particular needs of the dental prosthesis (eg, is the esthetic zone or the posterior quadrants to be restored?). The selection of the appropriate implant design is dependent on the restorative plan, the type of prosthesis anticipated (eg, will it be fixed or removable?), whether it will be screwed-retained or cement-retained, whether the patient demands that the prosthesis be placed into immediate function, and perhaps other factors.

Once the implants have been placed, the implant team members must make critical decisions regarding the appropriate length of healing times, loading protocols, and postsurgical prosthetic management. The implant team should be well versed in managing potential adverse side effects of the surgical procedures that are performed. Not all planned treatments proceed as expected, so the implant team must be prepared to manage unexpected setbacks or delays in treatment. When the implant team prepares and plans well, unexpected delays or complications may be managed appropriately to minimize poor outcomes.

Close collaboration between the implant surgeon and the restorative dentist is mandatory if satisfactory outcomes are to be achieved. The implant surgeon and the restorative dentist obtain diagnostic information, the data is collated and shared, the basic issues are discussed, and a tentative diagnosis and plan of treatment are agreed upon. Once the tentative treatment plan is determined, additional diagnostic studies are performed, a definitive diagnosis is formulated, and a definitive plan of treatment is then developed. In the past, logistics made collaboration between team members difficult, but today, with the continued refinement of CAD/CAM programs, these collaborations are facilitated because needed information can be exchanged digitally and treatment-planning conferences conducted live over the Internet. The pros and cons of the variety of options available can be considered and debated with the central idea being that the implant therapy should be prosthodontically driven. Successful collaborations are based on mutual trust and an open and frank exchange of views regarding the merits of treatment options available.

## Disconcerting Trends in Implant Dentistry

Implant treatment is elective, so the old maxim “Do no harm” is especially relevant when considering implant treatment. This maxim is particularly important to consider when restoring the esthetic zone, because form and function can be restored for most patients with conventional treatment methods (eg, fixed dental prostheses, bonded partial dentures, removable partial dentures, complete dentures). Although the outcomes of implant treatment achieve very high levels of predictability when executed by experienced implant teams, when treatment is delivered by ill-prepared or poorly trained teams or individuals, outcomes may be suboptimal.

Regrettably, the authors of this textbook, because of our association with academic institutions, have seen far too many failures of implants and implant prostheses. Moreover, negative outcomes are underreported in the literature. They can be secondary to poor treatment planning, inattention to detail, poor knowledge and appreciation of implant biomechanics, poor surgical execution, poor prosthetic designs, and inadequate knowledge and appreciation of the basic principles of occlusion as they relate to implant prostheses. Unfortunately, it has become far too common for restorative dentists to expect the surgeon to place and uncover the implants, make an impression, and send the impression to the dental laboratory for design and fabrication of the prosthesis, so that the only function executed by the restorative dentist is to deliver the prosthesis. Conversely, all too frequently a surgeon will place implants without consulting with the restorative dentist. Under these circumstances, implants may not be positioned or aligned consistent with fabricating a prosthesis that is esthetic and/or functional. Both of these practices often lead to negative out-

comes, and frequently the implants and/or prostheses do not meet the expectations of the patient or the standard of care.

Osseointegrated implants enable implant teams to restore functional and esthetic deficits with a degree of success only dreamed of prior to their introduction. However, in order to achieve a high level of predictability, the implant team must be aware of factors that predispose to failure as well as successful outcomes. Furthermore, most implant treatment is complex, and it is incumbent upon the implant team to possess detailed knowledge of the basic principles of surgery and prosthodontics before entering into the exciting and yet challenging milieu of implant dentistry. All too many of our colleagues do not understand the complexities of implant dentistry, including the basic biomechanical limitations of these systems regarding numbers, the lengths and diameters of implants needed to withstand occlusal forces, the impact of misaligned implants, the risks associated with immediate loading, and the special requirements for restoration of the esthetic zone.

## Historical Overview

### Previous implant systems: Their biology and why they failed

When the concept of osseointegration was introduced to the international dental community in the early 1980s, it represented a radically new concept in implant dentistry<sup>1,2</sup> (Table 1-1). Most of the previous implant systems were made of chrome-cobalt alloys, which were subject to corrosion. Corrosion, with release of metallic ions into the surrounding tissue, triggered both acute and chronic inflammatory responses, resulting in encapsulation of the implant with fibrous connective tissue (Fig 1-2). Subsequently, epithelial migration along the interface between the implant and the fibrous connective tissue led to development of extended peri-implant pockets, and the chronic infections originating in these pockets led to exposure of the implant framework and its eventual loss (see Fig 1-2). In general, these implant systems survived for 5 to 7 years before the infections prompted their removal (see Table 1-1).

When subperiosteal implants failed in the mandible, alveolar bone was often lost, but the patient retained most of the basal bone. The principle damage was caused to the overlying mucosa. Most of the keratinized, attached tissues were lost, and that which remained was heavily scarred. The chronic infections associated with failing implant frameworks in the maxilla were much more damaging because of extensive loss to bone and soft tissue, exposing vital anatomical structures such as the floor of the nose/nasal cavity and sinus cavity (Fig 1-3). Frequently, large volumes of alveolar and basal bone were lost, and on occasion, large oral defects developed with extension into the paranasal sinuses (see Fig 1-3d).

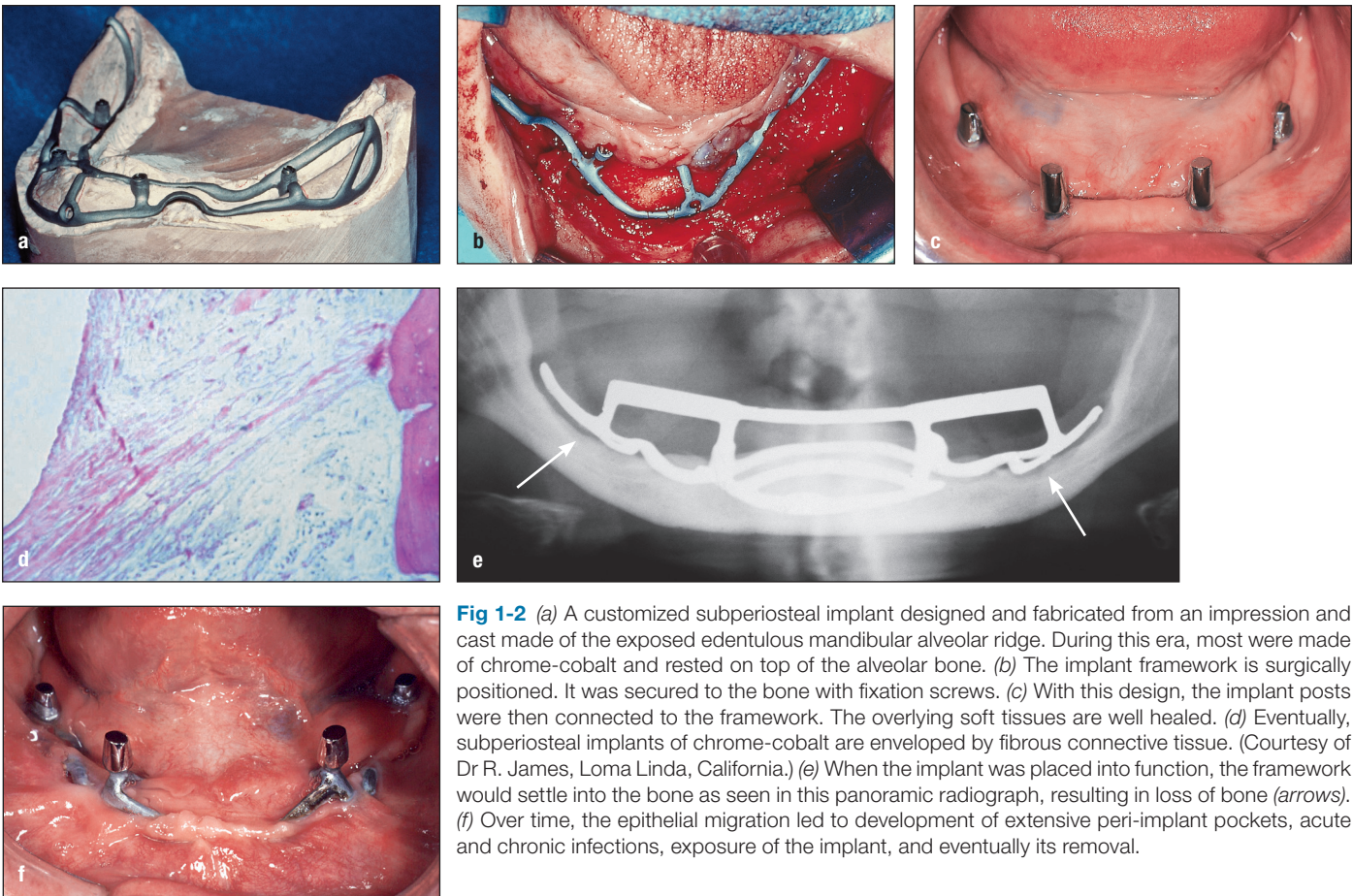
Most metals are not suitable as implant biomaterials because of the aforementioned corrosion and continuous release



**Table 1-1** Implant survival rates reported in the 1978 Harvard-NIH Implant Consensus Conference<sup>3</sup>

Implant type	Survival rate		Notes
	5 years	10 years	
Subperiosteal	90%	65%	200 patients (5 investigators)
	46%	39%	94 patients (1 investigator)
Staple	95%	NA	Unreliable due to self-reported data
Transosteal	Undetermined		Small sample size
Vitreous carbon	50%–60%	NA	3-year data (2 investigators)
Blade	90%	NA	200 implants (1 investigator)
	65%	NA	70 implants (2 investigators)
	75%	NA	89 patients; full-arch blade implants (self-reported data from 1 investigator)

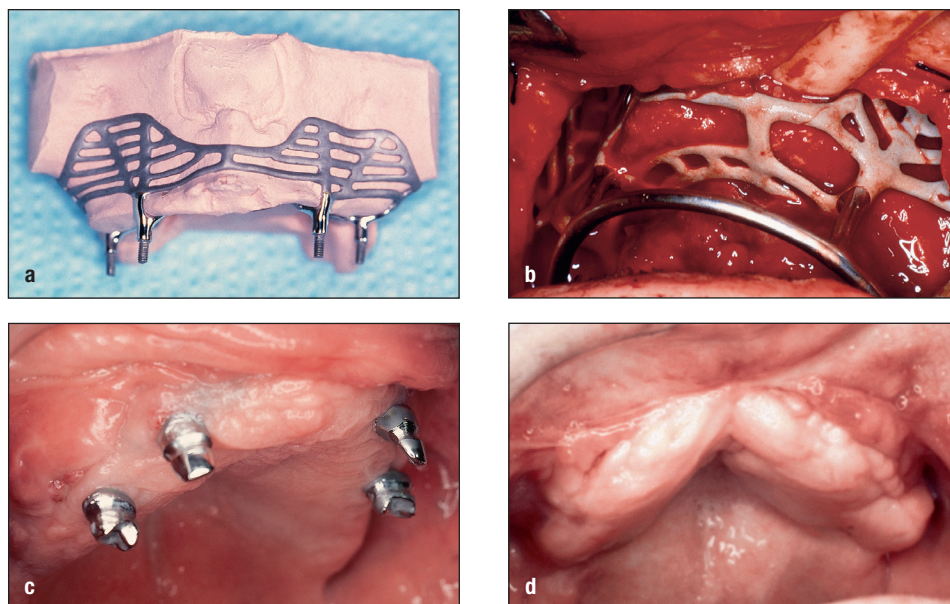
NA, not available.



**Fig 1-2** (a) A customized subperiosteal implant designed and fabricated from an impression and cast made of the exposed edentulous mandibular alveolar ridge. During this era, most were made of chrome-cobalt and rested on top of the alveolar bone. (b) The implant framework is surgically positioned. It was secured to the bone with fixation screws. (c) With this design, the implant posts were then connected to the framework. The overlying soft tissues are well healed. (d) Eventually, subperiosteal implants of chrome-cobalt are enveloped by fibrous connective tissue. (Courtesy of Dr R. James, Loma Linda, California.) (e) When the implant was placed into function, the framework would settle into the bone as seen in this panoramic radiograph, resulting in loss of bone (arrows). (f) Over time, the epithelial migration led to development of extensive peri-implant pockets, acute and chronic infections, exposure of the implant, and eventually its removal.

of metal ions into adjacent tissues. The presence of these metal ions triggers acute and chronic inflammatory responses, which eventually result in fibrous encapsulation of the implant. If the implant extends through the skin or mucosa, the epithelium slowly migrates (1 to 2 mm per year if the patient has been compliant with oral hygiene) along the interface between the

implant and the fibrous connective tissue capsule. The result is peri-implant pockets of significant depths, often exceeding 15 to 20 mm. These pockets are subject to local infections. Titanium, however, is resistant to corrosion and spontaneously forms a coating of titanium dioxide, which is stable, biologically inert, and promotes the deposition of a mineralized bone ma-



**Fig 1-3** (a) A subperiosteal implant fabricated for an edentulous maxilla. (b) The implant framework is secured to the alveolar bone. This particular chrome-cobalt implant framework was coated with hydroxyapatite. (Courtesy of Dr R. James, Loma Linda, California.) (c) A subperiosteal implant that had been in position for 3 years has become infected and mobile. (d) Following removal of the implant framework in another patient, the patient lost significant portions of the anterior maxilla.

trix on its surface. In addition, it is strong and easily machined into useful shapes.

### The groundbreaking work of P-I Brånemark

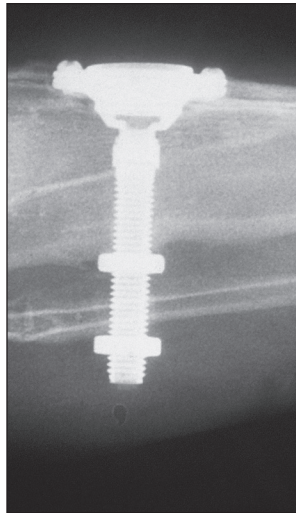
Professor Per-Ingvar Brånemark discovered the phenomenon of osseointegration while he was conducting a series of *in vivo* animal experiments studying revascularization and wound healing in traumatically induced bone defects. In these experiments, he used an optical chamber made of titanium placed into a rabbit tibia that was connected to a specially prepared microscope (Fig 1-4). A thin layer of newly formed tissue was transilluminated, and tissue repair and maturation processes were visualized *in vivo*. When Brånemark attempted to remove the chamber from its bone site, he noticed that the bone adhered tenaciously to the surfaces of the titanium chamber. He immediately recognized the importance of this discovery, and during the next several years he experimented with various sizes and shapes of dental implants, including designs with features of both subperiosteal and endosteal implants (Fig 1-5). Over 50 designs were tested.

Research was then conducted aimed at developing clinical procedures that permitted the osseointegration of implants on a consistent basis (ie, gentle surgical preparation, absence of

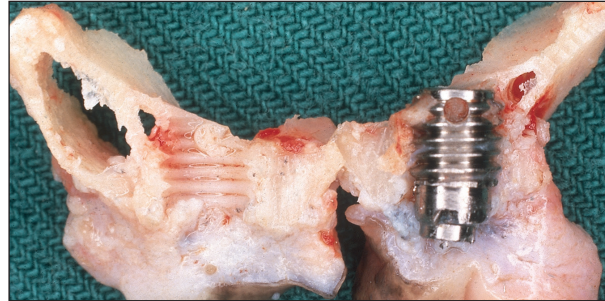
contamination of the implant surface, and immobilization of the implant during healing). Investigations conducted in dogs using radiographic and histologic analysis indicated that the implants remained osseointegrated with little loss of bone for as long as 10 years in function in spite of the fact that the fixed prostheses supported by the implants were only cleaned twice per year (Fig 1-6).

### Clinical studies

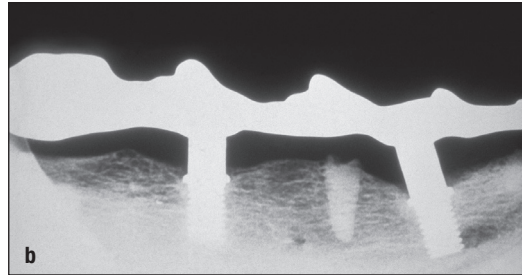
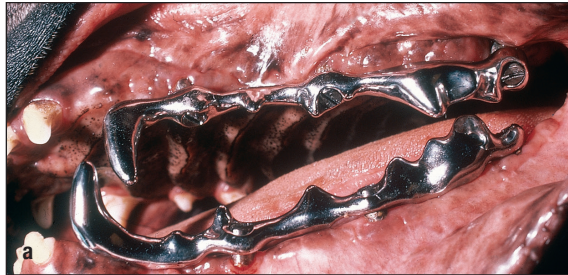
Following an extensive period of animal testing, human studies were begun (Fig 1-7). Initial human studies were conducted in edentulous patients, and the first patient was restored in 1965. Clinical outcome studies were designed and conducted by his team, but Brånemark did not attempt to commercialize his invention until long-term clinical follow-up data (10 years) was available.<sup>1,2</sup> This data confirmed the clinical efficacy of titanium implants, so he began the long and difficult process of disseminating this information to the professional community. Brånemark and his team finally settled on a screw-shaped design with a hex on the top (Fig 1-8). Since then, several additional designs have been introduced, particularly aimed at improving initial implant stability.



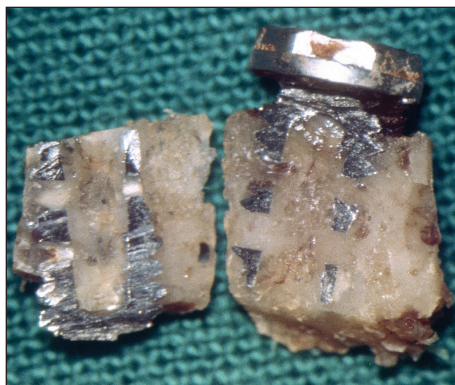**Fig 1-4** A radiograph of the titanium optical chamber embedded in bone. When Brånemark attempted to remove the device from the bone, he noticed that the bone had grown against the surface of the titanium. (Courtesy of Professor P-I Brånemark, Gothenburg, Sweden.)



**Fig 1-5** One of the early implant designs tested in dogs. Note that the bone has become closely adapted to the surface of the implant threads. (Courtesy of Professor P-I Brånemark, Gothenburg, Sweden.)



**Fig 1-6** (a) Fixed implant-supported prostheses in a dog. (b) Radiograph of a fixed implant-supported prosthesis in a dog after 4 years in function. (Courtesy of Professor P-I Brånemark, Gothenburg, Sweden.)

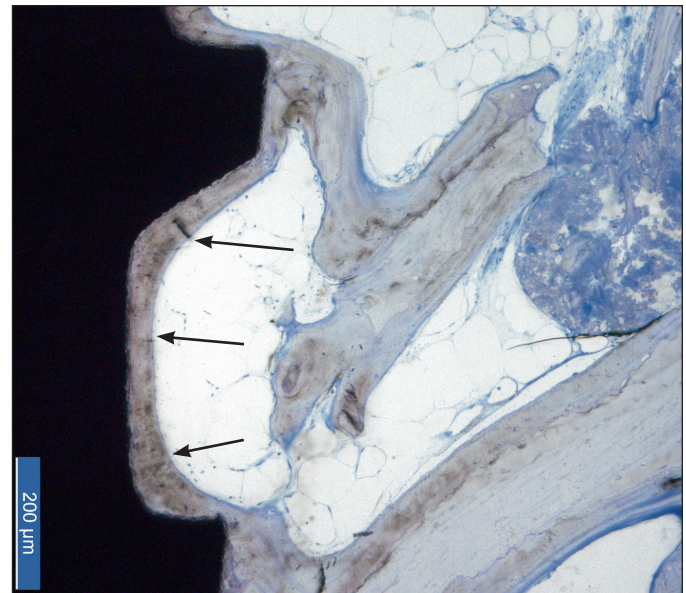


**Fig 1-7** One of the early designs tested in humans. It was removed with a trephine. The implant has been sectioned longitudinally. Note that bone is firmly adherent to the implant surface. (Courtesy of Professor P-I Brånemark, Gothenburg, Sweden.)



**Fig 1-8** The final design: a screw with a hex on top.

**Fig 1-9** The bone that is deposited onto a microrough implant surface (arrows) becomes harder and stiffer than trabecular bone as it matures. (Courtesy of Dr P. Schüpbach, Zurich, Switzerland.)



## Biologic Basis of Osseointegration

### Biologic processes

Titanium is a unique metal and has been used for many years to reconstruct a variety of types of bony defects by oral and maxillofacial surgeons, orthopedic surgeons, and neurosurgeons. It is resistant to corrosion and spontaneously forms a coating of titanium dioxide on its surface. Following creation of the osteotomy sites and placement of the implant, a blood clot forms between the surface of the implant and the walls of the osteotomy site,<sup>4</sup> and plasma proteins are attracted to the area and adsorbed onto the surface of the implant. The vascular injury associated with the surgical procedure immediately activates platelets. These platelets adhere to each other, and the injured tissue releases a variety of enzymes and growth factors that are essential for the cascade of events leading to coagulation and the development of the fibrin clot. The activated platelets also regulate the subsequent inflammatory response and the processes associated with wound healing.<sup>5-7</sup>

As a fibrin clot fills the interface between the surface of the implant and the osteotomy site, angiogenesis begins almost instantaneously. The structure of the fibrin network is determined by multiple factors such as pH, clotting rate, coagulation factor concentrations, and polymerization of fibrin molecules and generally occurs within the first 24 hours following placement of the implant. The organized fibrin network is further modified by the incorporation of fibronectin molecules, which effects bone formation in the fibrin scaffold. Fibronectin is a large glycoprotein with active binding sites not only to fibrin but also to other extracellular matrix molecules and integrin-expressing

cells. A subset of macrophages originating in the bone marrow (referred to as *myeloid suppressor cells*) regulates inflammatory responses by suppressing T-cell activities. In addition, these cells induce angiogenesis and secrete a set of growth factors that support rapid wound healing.<sup>8</sup> The presence of these macrophages appears to be essential for creating a tissue repair environment for wound healing and bone formation.

Mesenchymal stem cells are attracted by chemotaxis to the surface of the implant and the osteotomy site and migrate via the fibrin scaffold associated with the clot. These cells differentiate into osteoblasts and begin to deposit bone on the surface of the implant and the walls of the osteotomy site, eventually leading to anchorage of the implant in bone as the result of contact and distance osteogenesis<sup>9</sup> (Fig 1-9). Distance osteogenesis associated with the bony walls of the osteotomy site is initiated first, and the osteotomy site undergoes an ordinary sequence of bone wound healing similar to that seen in the tooth extraction socket. Initially, woven bone is deposited in this area. This bone is characterized by high cellularity, a haphazard arrangement of collagen fibrils, and poor mineralization. At this stage, its biomechanical resistance to functional loads is poor. However, this bone will eventually remodel into dense lamellar bone. This process may take as long as 18 months.

Once the fibrin network adjacent to and in contact with the implant surface is remodeled and modified by the incorporation of fibronectin, osteogenesis begins within this network. There is a small but distinct time lag between distance osteogenesis and contact osteogenesis, but recent modifications of the implant surfaces appear to significantly accelerate contact osteogenesis (see chapter 2). The small gaps between regenerating bone and the implant surface may be filled as early as 7 days, depending on the osteoconductivity (the recruitment of osteogenic cells and their migration to the surface

of the implant) of the implant surface, provided the surface is free of contaminants. In clinical settings, this process plus the maturation of the bone deposited on the surface of the implant requires anywhere from 8 weeks to 4 months to complete, depending on the osteoconductivity of the implant surface.

## The unique nature of peri-implant bone

The nature and characteristics of the bone formed in close proximity to the implant surface play an essential role in the sustained support of the implant after it is placed into function (for details, see volume 1, chapter 2). Bone is a composite tissue composed of collagen-based fibers and crystalline hydroxyapatite (HA). The bone-mineral content is regulated by the composition of the organic collagen matrix, which is largely composed of type I collagen. The quality of the bone that ultimately anchors the implant and sustains it during function appears to be affected by the nature of this organic collagen matrix. The bone deposited within the fibrin scaffold adjacent to the implant surface is formed in response to the implant itself and is likely different than the bone created in the osteotomy site; it is probably influenced by the implant surface topography, chemistry, and charged energy. Indeed, it has been demonstrated that the presence of the implant and its specific physiognomies affect the unique characteristics of the bone deposited onto the surface of the implant.<sup>10-12</sup>

It has been shown that the hardness and stiffness of peri-implant bone in direct contact with the implant surface may be associated with specific implant fixture surface modifications.<sup>11</sup> The hardness of peri-implant bone adjacent to the original machined titanium implant introduced in the 1980s by Brånemark progressively increases from 2 weeks to 4 weeks after surgical implant placement and eventually reaches the equivalent hardness of trabecular bone. The bone hardness associated with moderately rough (double acid-etched) implants likewise undergoes a progressive increase; however, this bone was found to be much harder and reached the equivalent hardness of cortical bone.<sup>11</sup> Recently, a similar experiment using a rabbit model revealed that the hardness of peri-implant bone almost doubled when a moderately rough (airborne-particle abraded/acid-etched) implant surface was further modified with nano-HA coating.<sup>12</sup> The increased presence of collagen cross-linking enzymes associated with bone adjacent to the surface of implants with microrough surface topography is thought to contribute to the formation of stronger peri-implant bone.<sup>10</sup>

Direct bone attachment to the implant surface has been considered the foundation of osseointegration, and as a result, histologic assessment of osseointegration commonly used the percent area of bone-to-implant contact (BIC). Recently, increasing numbers of studies have reported that BIC does not correlate with mechanical load as shown by pull-out tests and microcomputed tomography (microCT) analysis. Using the implant push-in test and microCT-based 3D BIC in the rat model, the moderately rough implant with double acid etching

showed three times higher shear strength than the relatively smooth surface machined implant.<sup>13</sup> This increase could not be accounted for by the differences in BIC between these surfaces. The discrepancy between the BIC measurement and the mechanical withstanding load assay suggests that while bone formation around the implant must be a prerequisite, the development of osseointegration may rely on the actual bonding between the bone and the implant surface.

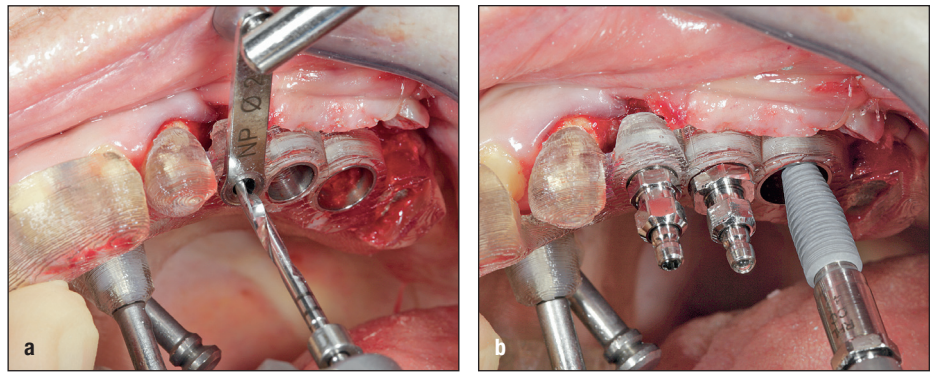
For many years, the existence of a thin layer of tissue between the bone and the surface of the implant has been reported. This tissue layer has been described as an electron-dense zone of 20 to 50 nm<sup>14,15</sup> and a zone of 100 to 200 nm without typical collagen fibers<sup>16</sup> followed by the collagen-rich bone tissue. The precise molecular composition of the interface tissue has not been elucidated. The molecules composing this interface tissue between the bone and the implant surface (proteoglycans, osteopontin, type X collagen) no doubt hold the key to understanding the mechanical withstanding force of osseointegrated implants (for details, see volume 1, chapter 2).

The rapid formation of bone marrow trabecular bone, with woven bone characteristics, immediately following implant placement may occur within 1 to 2 weeks and may potentially contribute to the immediate implant stability. Whether this early woven bone can support the occlusal load has not been established. During the transition stage from resorption of a large volume of new woven bone to the maturation of well-organized trabecular bone, there may be a vulnerable period during which the degree of implant anchorage may temporarily drop. This phenomenon has been observed in an animal model and may have clinical significance.<sup>17</sup> The initial stability created by mechanically engaging the bone site may therefore be suboptimal, and if the implants were loaded immediately, they may be vulnerable to mobilization during this period (see chapter 11).

The woven bone formed in response to ablation wounding is subject to intensive remodeling and is largely resorbed to create fatty bone marrow. Following maturation and remodeling, the bone just adjacent to but not contacting the implant surface is composed of osteones arranged parallel to the long axis of the implant. Uniquely, bone deposited in the vicinity of implant surfaces appears to resist this catabolic bone remodeling and thus maintains the osseointegration for an extended period.<sup>18</sup> Trabecular bone derived from distance osteogenesis around an implant may be relatively unstable and can disappear due to physiologic bone remodeling. On the contrary, peri-implant bone derived from contact osteogenesis appears to avoid bone marrow remodeling and remains around the implant fixture for long periods unless the implant is exposed to excessive loads.

Osteoclasts play a central role in resorption and remodeling. These cells are formed by the fusion of monocytes as a result of being exposed to chemical stimuli, including receptor activator of nuclear factor  $\kappa$ B ligand (RANKL). During the developmental stage, RANKL is secreted from osteoblasts and hypertrophic chondrocytes. However, when bone matures, RANKL

**Fig 1-10** The implant osteotomy sites must be prepared precisely with minimal trauma (a) before the implant is placed (b).



is primarily secreted from osteocytes embedded in bone as a result of exposure to mechanical stimuli.<sup>19</sup> It follows that before remodeling can be initiated, the occlusal load applied to an implant fixture must be sensed by osteocytes in the implant-supporting bone. It is conceivable that the mechanical properties of peri-implant bone adjacent to implants with micro-rough surfaces (harder and stiffer) may insulate the embedded osteocytes, which as a result may not secrete RANKL when favorable occlusal forces are generated. Indeed, there may be an increased threshold for mechanical stimulation required for peri-implant bone osteocytes. However, implant overloading beyond this threshold may stimulate the osteocytes to initiate the secretion of RANKL, resulting in osteoclast formation and initiation of the so-called resorptive remodeling response.<sup>20-26</sup> This is most likely the cascade of biologic events associated with implant overload, bone loss, and implant failure.

## Prerequisites for Achieving Osseointegration

### Uncontaminated implant surfaces

The osteoconductivity of implant surfaces is impaired if they become contaminated with organic molecules (see chapter 2, “Biologic Aging and Photofunctionalization of Implants”). The surface charge is changed from positive to negative, the surface becomes less wettable, and upon implant placement, adsorption of plasma proteins is suppressed. Recent studies indicate that implant surfaces can be decontaminated by exposure to ultraviolet light.<sup>27,28</sup> Decontaminating implant surfaces with ultraviolet light (photofunctionalization) enhances adsorption of plasma proteins and activation of platelets, which leads to more rapid differentiation of mesenchymal stem cells into osteoblasts once they reach the surface of the implant. Implants that have been stored in plastic packaging for extensive time periods become less bioreactive because of contamina-

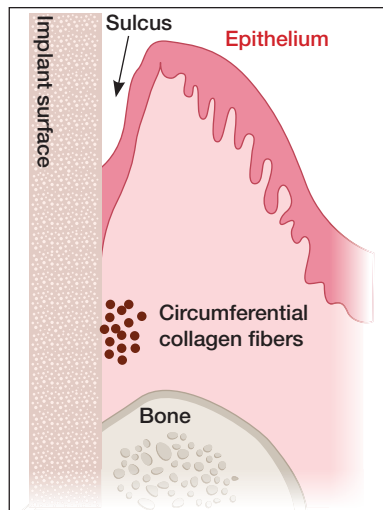
tion secondary to carbon-containing molecules. Therefore, it is advised that implants be used prior to their expiration dates.

### Creation of congruent, nontraumatized implant sites

Careful preparation of the implant osteotomy site is essential to obtaining osseointegration of a titanium dental implant in bone on a consistent basis (Fig 1-10). Because the adjacent bone is an important source of cells, regulatory and growth factors, and vasculature that contribute to bone healing, it is essential to minimize trauma when preparing the implant osteotomy sites. In ideal situations, the gap between the wall of the osteotomy and the implant is small, the amount of bone traumatized during surgical preparation of the bone site is minimal, and the implant remains immobilized during the period of bone repair. Under these circumstances, the implant becomes osseointegrated a very high percentage of the time (at least 95% with modern microrough implant surfaces). The smaller the gap between the osteotomy site and the implant surface, the better. In addition, during surgical preparation of the implant osteotomy site, excessive bone temperatures should be avoided, because this leads to the creation of a zone of necrotic bone in the wall of the osteotomy site, impairing healing and increasing the likelihood of a connective tissue interface forming between the implant fixture and the bone.

### Primary implant stability

Osseointegration is obtained more consistently when initial primary stability of the implant is achieved with the surrounding bone. This is particularly important when single-stage surgical procedures are employed, and it is an obvious necessity if the implant is to be immediately placed into function. In attempting to establish initial primary stability, surgeons often underprepare the implant site when the bone is porous or soft. If the



**Fig 1-11** The soft tissue–implant interface. The sum total of the junctional epithelial attachment and the connective tissue zone represents the biologic width.

implant is not stable after placement into its prepared osteotomy site, many clinicians prefer to replace it with an implant of a slightly larger diameter. This was particularly necessary when machined-surface implants were routinely employed. Today, the modern microrough implant surfaces are osteoconductive, and unstable implants (so-called “spinners”) that are buried and remain immobile during the healing process have an excellent chance of achieving osseointegration as long as the clot remains undisturbed during the initial period of healing.

### No relative movement of the implant during the healing phase

Micromovement of the implant is thought to disturb the tissue and vascular structures necessary for initial bone healing.<sup>29–31</sup> Excessive micromotion (greater than 100 to 150 micrometers) of the implant during the initial healing period may detach the fibrin clot from the implant surface. Furthermore, movement of this magnitude impairs differentiation of osteoblasts. The healing processes are then reprogrammed, leading to a fibrous connective tissue–implant interface as opposed to the creation of a bone–implant interface. These phenomena have clinical significance. Implants placed into function immediately must have sufficient initial stability to resist functional forces so as to reduce micromovement to physiologic levels during healing. Otherwise, the implant will fail to osseointegrate (see chapter 11).

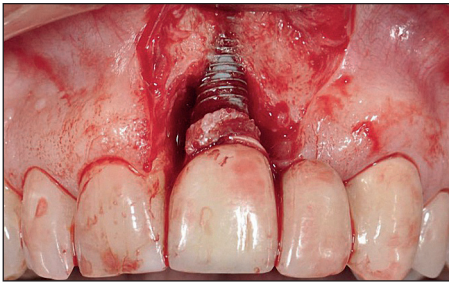
## The Implant–Soft Tissue Interface

The implant–soft tissue interface is similar to the gingival tissue interface circumscribing natural teeth and serves as a barrier to microbial invasion. It is composed of nonkeratinizing epi-

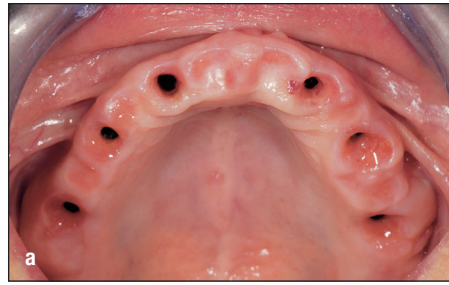
thelium in the sulcus, junctional epithelium, and a supracrestal zone of connective tissue. The connective tissue layer contains a dense zone of circumferential collagen fibers intermingled with fibers extending outward from the alveolar crest. These fibers run parallel to the long axis of the implant. The zone of connective tissue adjacent to the implant is relatively avascular and acellular and similar to scar tissue histologically. The soft tissue barrier (interface) assumes a specific dimension (biologic width) during the healing process.

The epithelial–implant interface (junctional epithelial attachment) is based on the hemidesmosome basal lamina system, similar to that seen between gingiva and teeth. When implants emerge through attached keratinized mucosa, collagen fibers circumferentially configured around the neck of the implant, interwoven with collagen fibers running from the crest of the alveolus and the periosteum to the peri-implant mucosa, hold the epithelium in close proximity to the surface of the implant. The epithelial cells in the sulcus epithelium secrete a sticky substance (a protein network composed of glycoproteins) onto the surface of the implants, enabling the epithelial cells to adhere to the implant surface via hemidesmosomes. The epithelial cuffs that form as a result of the basal lamina hemidesmosomal system and the zone of connective tissue just apical to it effectively seal the bone from oral bacteria (Fig 1-11).

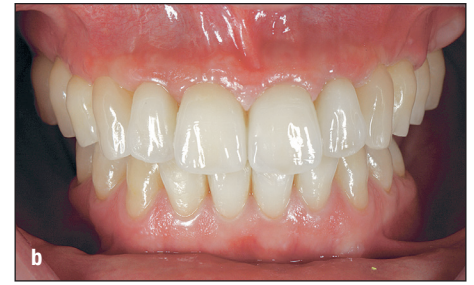The zone of dense connective tissue between the crestal bone and the epithelium helps seal off the oral environment. The connective tissue fibers run parallel to the implant surface and are arranged in a cufflike circular orientation. However, what is lacking and what differentiates the soft tissues around implants from the gingival tissues around natural teeth is the absence of gingival fibers inserting into a cementum-like tissue. Hence, the soft tissues around implants are much more easily detached from the surfaces of the implant than from the surfaces of natural teeth. This difference is clinically significant for a number of reasons, especially when using cement systems for retention of implant prostheses, because of the risk of embedding cement subgingivally during cementation of the



**Fig 1-12** Peri-implantitis triggered by excess cement beneath the peri-implant soft tissues. Note that the bone loss has compromised the anchorage of the adjacent central incisor. (Courtesy of Dr C. Wadhvani, Seattle, Washington.)



**Fig 1-13 (a and b)** The contours of the peri-implant tissues are primarily determined by the support provided by the underlying bone.



prosthesis,<sup>32</sup> thereby triggering peri-implantitis<sup>33</sup> (Fig 1-12). Moreover, this lack of gingival fibers inserting into or attaching to the surface of the implants probably impacts the health and maintenance of the peri-implant tissues in the long term, especially when the peri-implant mucosa is poorly keratinized and mobile. Keratinized epithelium tends to be attached more effectively to the underlying periosteum than nonkeratinized mucosa and is preferred. Increased mobility of peri-implant mucosa appears to predispose to peri-implant mucositis and peri-implantitis and perhaps implant loss. The blood supply provided to the peri-implant soft tissues is limited compared with the gingival tissues circumscribing the natural dentition. However, the response to dental plaque appears to be comparable, and the inflammatory response of the peri-implant mucosa seems to be similar to that of the periodontal tissue enveloping natural teeth.

Similar to the natural dentition, the phenomenon of biologic width applies to the soft tissues around implants. *Biologic width* is defined as the combined length of the supracrestal connective tissue and the zone of junctional epithelium associated with the epithelial attachment. This dimension averages approximately 3 mm around implants<sup>34</sup> and is slightly greater than that associated with the natural dentition. In general, the width of the epithelial component is greater and demonstrates more variability than the width of the connective tissue zone. This phenomenon has particular impact in the esthetic zone, because, similar to the natural dentition, the level and contours of the underlying bone primarily determine the contours and level of the overlying soft tissues (Fig 1-13).

Proprioception in the natural dentition is provided by special receptors in the periodontal ligament, and these are obviously lacking or absent in the peri-implant bone and soft tissues. As a result, tactile sensitivity and reflex function is dramatically compromised, particularly when an implant-supported prosthesis opposes another implant-supported prosthesis. This fact makes implants susceptible to overload. Implant overload can be triggered by any number of factors, including insufficient numbers of implants to support the functionally or para-

functionally generated occlusal forces, persistent parafunctional activity, improper design of the occlusal relationships, improper implant alignment, short implants, and perhaps other factors. The resulting microfractures and delaminations seen within bone provoke a resorptive remodeling response of the bone anchoring the implants, and if the overloading is unchecked, the implants may fail.<sup>20-26</sup>

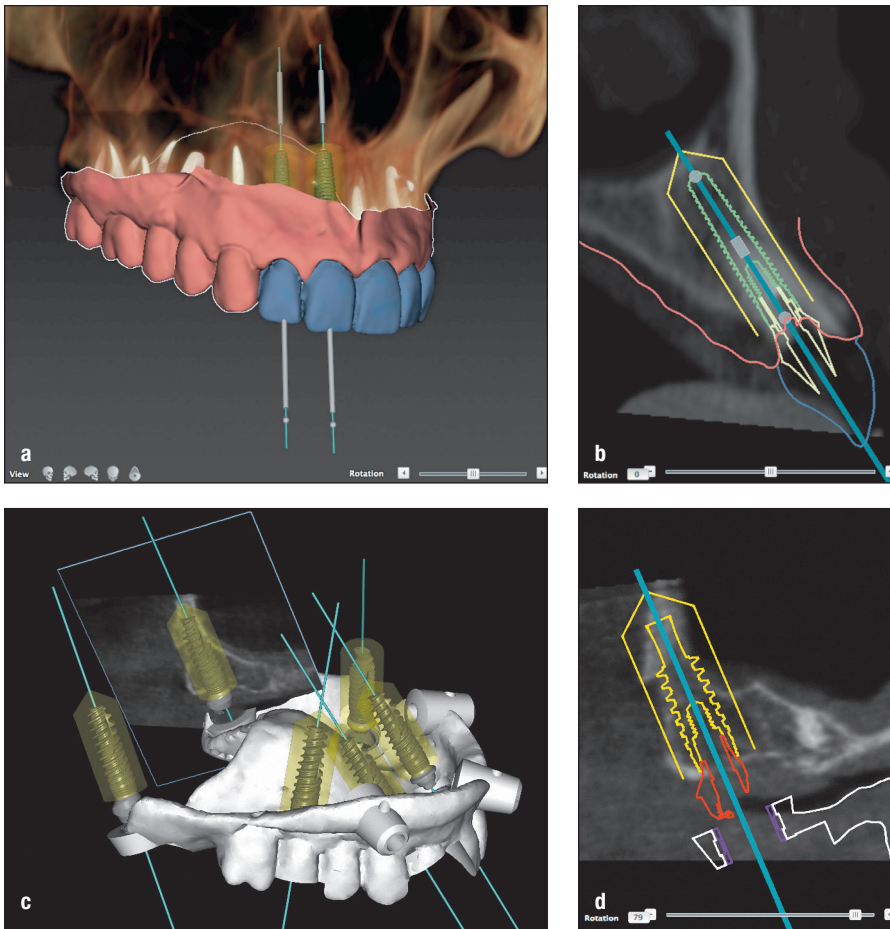
## The Continuing Evolution of Implant Surgery

Countless numbers of innovations in workup, implant design, and surgical procedures have impacted the practice of implant surgery. The numbers of patients now considered excellent candidates for implant treatment have expanded dramatically because of recent advances in the bioreactivity of modern implant surfaces (see chapter 2) and our ability to enhance the bone and soft tissues of the potential implant sites (see chapters 8 and 9). Initially, osseointegration was limited primarily to edentulous patients. Few partially edentulous patients were treated, and those that were treated suffered from an unacceptable rate of failure, particularly when attempts were made to restore the posterior quadrants. Today, because of more bioreactive implant surfaces, the ability to surgically enhance the 3D bone volume of potential implant sites (eg, sinus augmentation), and improved prosthetic designs, success rates in these patients approach those of edentulous patients.

### Impact of medical and dental workup

Our understanding of the impact of implant-retained prostheses compared with conventional prosthodontic therapies has improved, enabling clinicians to make better choices for our patients consistent with their goals and with the limits inherent with implant-supported restorations. Moreover, our under-





**Fig 1-14** Computer-guided planning allows the clinician to scrutinize the potential implant sites, select implants of suitable length and diameter, and position them to be compatible with the prosthetic design. (a and b) A digital rendering of a patient in need of implants to restore the esthetic zone. These software programs are particularly valuable in the esthetic zone to identify thin layers of bone overlying the labial surface of the implant that are at risk of resorption. (c) A patient planned for a full-arch restoration using tilted implants. (d) Each site can be carefully evaluated and the implants ideally positioned. In this instance, the posterior implants will be placed into the maxillary tuberosity region (NobelGuide, Nobel Biocare).

standing of the basic processes of osseointegration have evolved to the point where we can better predict whether a patient with a particular medical history is a suitable candidate for osseointegrated implants. For example, a sizable portion of the patient population presenting with osteoporosis is being treated with bisphosphonates. When the phenomenon of medication-related osteonecrosis of the jaws (MRONJ) became known, clinicians were hesitant to offer implant treatment to this group of patients. However, as the biologic mechanisms associated with osteoporosis were elucidated and the risks of MRONJ were better defined in relation to the types and potency of the drugs used to treat the disease, it became clear that a substantial number of these patients were also excellent candidates for implant treatment.

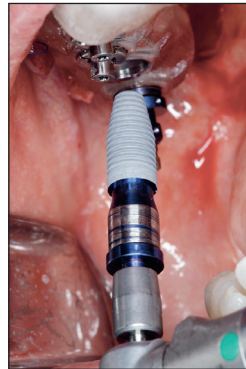
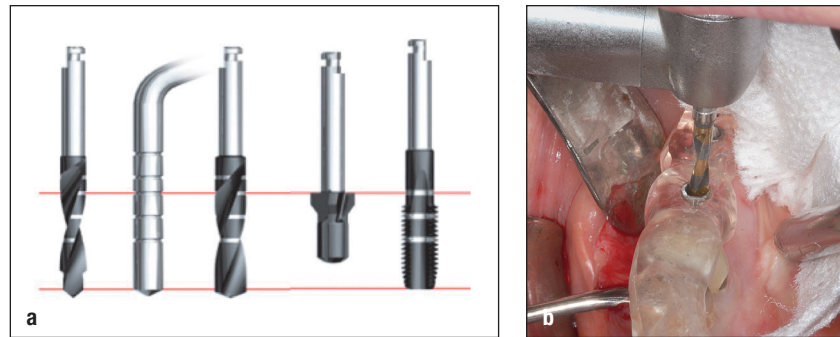
In addition, we now better understand the risks of implant failure in patients with a long history of tobacco use, patients receiving radiation treatment for head and neck cancer, and organ transplant patients receiving immunosuppressive therapy. Some of these patients are excellent candidates for implant treatment with only minimal additional risk of implant failures (tobacco users), while others are very poor candidates for implant treatment, for example patients with cancer-precipitated hypercalcemia treated with potent bisphosphonates adminis-

tered intravenously, due to the significant incidence of MRONJ (see chapter 3).

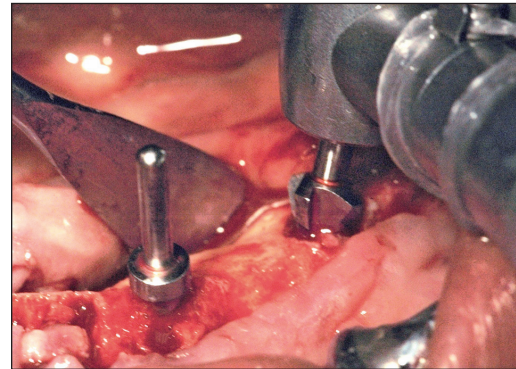
### Impact of CAD/CAM systems used in the diagnostic workup

Initially, the workup of potential implant patients was surgically driven; that is, the suitability of a patient was determined primarily by the 3D volume and quality of the bone sites and to some degree the associated soft tissues. Today, the development and the improving sophistication of CAD/CAM programs permits the workup to be driven by the needs of the prosthetic design, especially in partially edentulous patients, most notably when implants are to be placed in the esthetic zone (Figs 1-14a and 1-14b). Furthermore, the methods of working up the patients and assessing the nature of the implant sites in relation to the proposed prosthetic design have become increasingly more sophisticated and precise. During the 1980s, evaluation of potential bone sites consisted primarily of a panoramic radiograph and perhaps a lateral cephalometric radiograph. Today, when implants must be placed exactly in tooth positions with specific angulations (eg, if a metal-ceramic pros-

**Fig 1-15** (a) Stainless steel twist drills of increasing diameter, a counterbore (countersink), and a titanium tap were used to develop the implant sites. (b) The goal was to develop the implant sites as atraumatically as possible.



**Fig 1-16** Implant mounts are used to deliver the implant into the osteotomy site.



**Fig 1-17** A counterbore was used to develop the countersink area. This is now only used in bone with high density. (Courtesy of Dr N. Barakat, Beirut, Lebanon.)


thesis is planned for the edentulous maxilla) or when tilted implants are to be placed (Figs 1-14c and 1-14d), a cone beam computed tomography (CBCT) scan is recommended. CBCT scans and the associated software allow visualization of the bone contours of the maxilla and mandible in three dimensions as well as the adjacent structures, such as the maxillary sinus, the floor of the nose, and the inferior alveolar nerve canal. In addition, a digital rendering of the prosthesis can be superimposed onto the bony contours of the alveolar process. Implant sites are selected based on an analysis of the 3D bone contours and the probable tooth positions. Positions and angulation of the implants can be determined and a surgical template fabricated that permits semiguided or fully guided controlled directional drilling, ensuring precision of implant placement and alignment (see chapter 6).

## Impact of surgical innovations

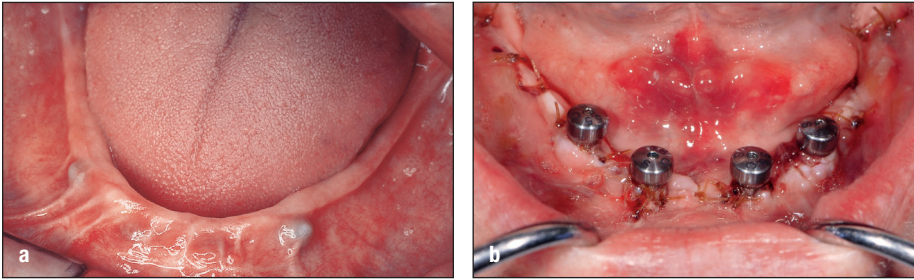
The original surgical protocol established by Brånemark and his team emphasized the need for atraumatic preparation of the implant bone sites in order to promote healing (osseointegration). They recognized that if the bone sites were overheated and traumatized, the implant was likely to be circumscribed with fibrous connective tissue and fail. By developing a strict

surgical protocol to deliver the dental implant, highly successful outcomes were achieved.

This surgical protocol required a sterile approach for all surgical procedures and use of specialized surgical instrumentation. The surgical instrumentation was divided into stainless steel and titanium components (Fig 1-15). These were kept in separate containers so as to minimize cross-contamination between the two different metals. The stainless steel twist drills were designed to prepare the osteotomy sites and were used at high speeds (maximum of 2,000 rpm). Copious irrigation with saline was employed to minimize the risk of overheating the bone site. After the site had been prepared with the 3-mm twist drill, the site was completed with a titanium tap in order to avoid contaminating the implant osteotomy site. Tapping of the osteotomy site was performed at low speed (15 to 20 rpm) to minimize the risk of overheating the bone and to increase the diameter of the site to accommodate the diameter of the implant (3.75 or 4.0 mm). Special carriers called *mounts* (Fig 1-16) made of titanium were designed to deliver the implant to the osteotomy site. A special drill was used to countersink the site in order to allow the implant to seat appropriately (Fig 1-17). However, this step had to be performed with great care, especially when preparing sites of poor quality (density) and thin cortical layers; otherwise, the initial stability of the implant would be compromised (see chapter 5).



**Fig 1-18** Improved initial anchorage can be achieved with tapered, self-tapping implants.



**Fig 1-19** (a) The original protocol established by Brånemark called for the implants to be buried beneath the mucosa during the healing period. During a second surgery, the implants were exposed, and transmucosal healing abutments were attached. (b) Recently, it has become common practice in selected patients to perform these procedures in a single stage.

Today, most (if not all) of the implant systems available use the same surgical sequence of twist drills to incrementally increase the osteotomy site to the final diameter prior to placement of the implant. There is no evidence that the stainless steel twist drills contaminate the osteotomy site.

### Impact of changes in the design of the implant body

Another change is the increased use of self-tapping implants (Fig 1-18). These are used primarily in poor-quality bone sites (poor density), such as the posterior maxilla, or when there is diminished bone quantity (lacking volume). Still another innovation is the development of implants designed specifically for earlier or immediate loading. These implants are tapered. With this change in design, during insertion of the implant the trabecular bone of the implant site is compressed, leading to improved primary stability of the implant. Furthermore, tapered implants allow the widest portion of the implant to engage the cortical bone at the crest of the edentulous ridge. When implants with a tapered design are properly anchored, the improved initial anchorage combined with the dramatic improvement in the osteoconductivity of the microrough implant surfaces enables the clinician to place the implant into function within 6 to 8 weeks as opposed to the 4 to 6 months of the original Brånemark design. In addition, in selected patients the improved initial anchorage allows for immediate loading (see chapter 11).

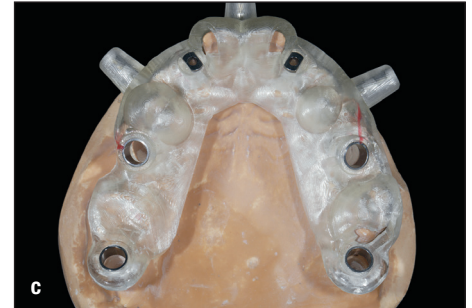
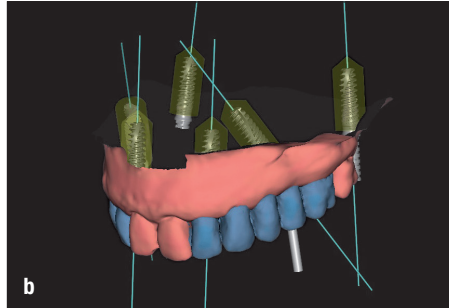
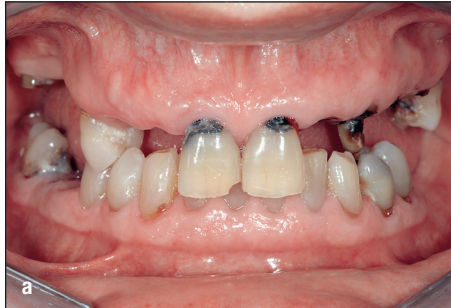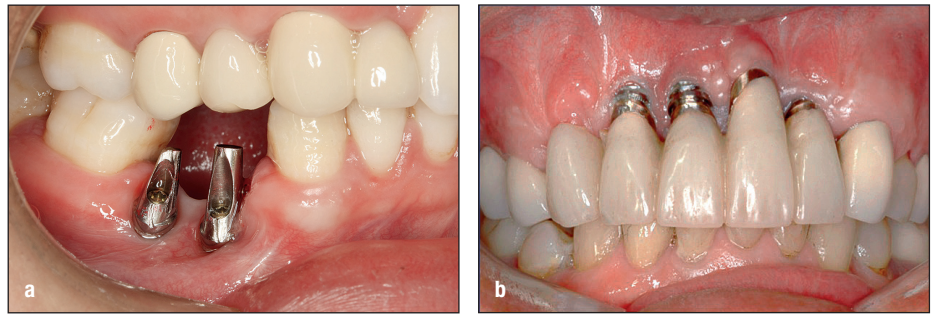
### Impact of single-stage vs two-stage surgery

The initial surgical protocol proposed by Professor Brånemark employed two surgical procedures before the prosthesis could be fabricated and delivered. The implants were placed and buried beneath the oral mucosa and allowed to heal for several months (Fig 1-19a). This was done in order to minimize the risk of implant movement during the initial period of healing. Then 4 to 6 months after implant placement, the implants were uncovered, and transmucosal abutments were connected. Today with new implant designs and the ability to achieve higher levels of initial implant anchorage and stabilization, single-stage procedures are employed in selected patients (Fig 1-19b) (see chapter 5).

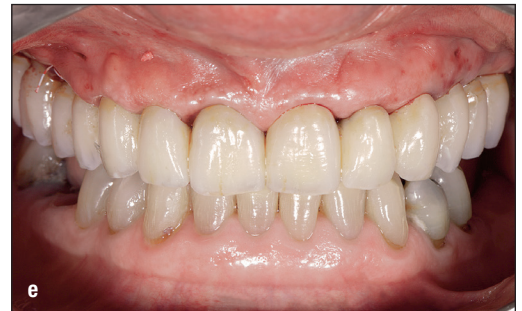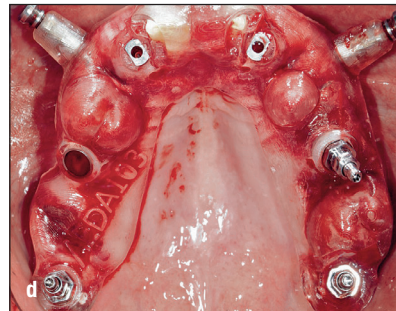
### Impact of computer-guided workup and computer-guided surgical techniques

In the 1980s, almost all implant osteotomy sites were prepared with freehand drilling techniques. As a result, all too frequently implants were misaligned and improperly positioned, often significantly compromising the biomechanics or the esthetics of the implant-retained prosthesis (Fig 1-20). During the last 20 years, with the introduction of computerized axial tomography scans and the development of CAD/CAM software, implant sites can be visualized in three dimensions, implants of suitable length and diameter can be selected, and a surgical template

**Fig 1-20** When freehand drilling was used, mistakes were often made in angulation and alignment. (a) These implants are angled excessively to the buccal. Angled abutments corrected the angulations, but the biomechanics are unfavorable and will predispose to implant overload. (b) Excessive labial placement led to the loss of bone and apical migration of the peri-implant tissues, exposing the abutments and the implants.



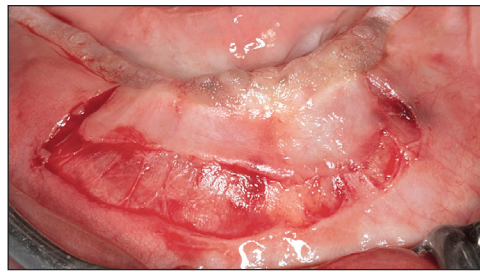
**Fig 1-21** When fully guided and semiguided implant surgical procedures are used, osteotomy sites can be created and implants can be positioned with great precision. (a) Pretreatment presentation. Teeth were to be extracted because of caries. (b) Digital rendering of the prosthetic replacements in relation to the proposed implant positions and angulations. Note that the two anterior implants will be placed with semiguided directional drilling. (c) The surgical template on the master cast. (d) Surgical template in position. It has been retained with anchor pins. (e) Immediately loaded prosthesis.



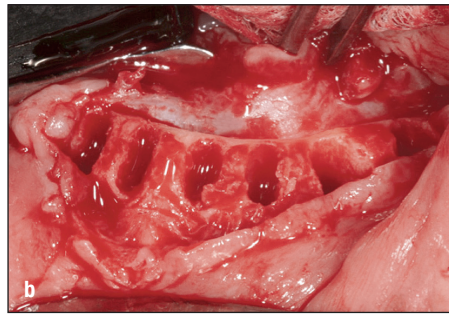
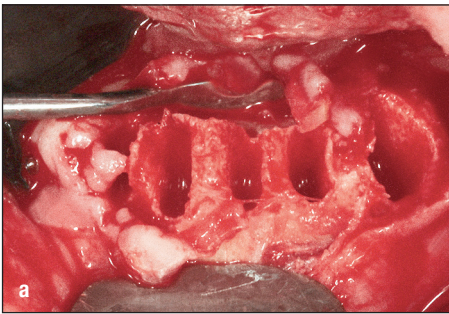
can be designed and fabricated with a number of techniques, including stereolithography (Fig 1-21). Using these tools, two methods have evolved for developing the osteotomy sites and placing the implants: the semiguided approach and the fully guided approach. Guided surgery employs surgical templates developed with CBCT scans and software programs. Once the surgical templates are secured firmly in position, the drill sleeves (bushings, which can be either metal or zirconia and are incorporated within the surgical template) and the drill keys allow for precise preparation of the osteotomy sites and positioning of the implants.<sup>35-37</sup> As a result, the implants can be placed with great precision and consistent with the planned prosthetic design, there is less risk of impinging upon vital structures such as the inferior alveolar nerve, abutments and prostheses can be fabricated prior to implant placement, and in selected cases implants can be placed with a flapless surgical approach (see chapter 6).

### Impact of soft tissue flap: Vestibular vs crestal

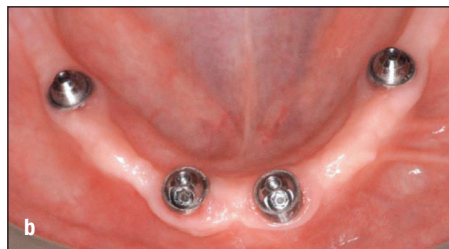
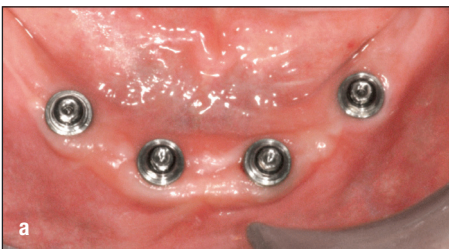
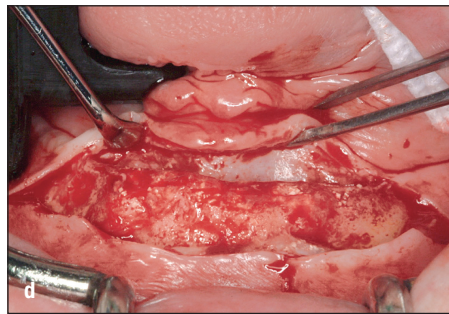
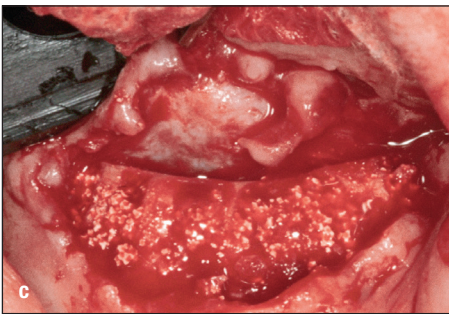
The original cohort of patients treated by the Brånemark group was fully edentulous, and the flap design was developed to maximize the exposure of the edentulous implant sites. In the edentulous mandible, implants were placed anteriorly between the mental foramen. A semilunar-shaped incision was made in the depth of the labial vestibule (Fig 1-22), and a full-thickness flap was reflected extending to the lingual aspect. This permitted the surgeon to visualize the mental nerves and to perform an alveoplasty of the alveolar ridge if necessary to flatten a knife-edge or sloping ridge (Fig 1-23). Implants were aligned so that they were perpendicular to the plane of occlusion. Today, if necessary, the posterior implants can be tilted posteriorly, so as to increase the anteroposterior (AP) spread and reduce the length of the posterior cantilever of the fixed prosthesis (Fig 1-24) (see chapter 7).



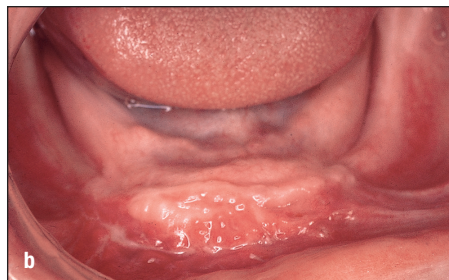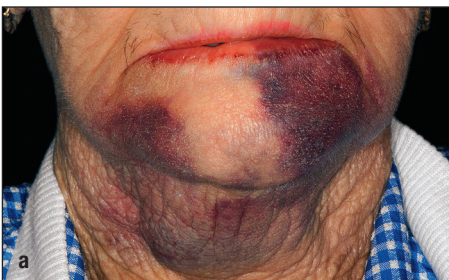**Fig 1-22** The vestibular incision proposed by Brånemark in the 1980s. (Courtesy of Dr N. Barakat, Beirut, Lebanon.)



**Fig 1-23** (a) Following extraction, the alveolar ridge is irregular. (b) The ridge following alveoplasty. (c) The extraction sockets were grafted with hydroxyapatite and beta-tricalcium phosphate. (d) Three months later, the alveolar ridge was exposed. Note the ideal alveolar ridge contours.

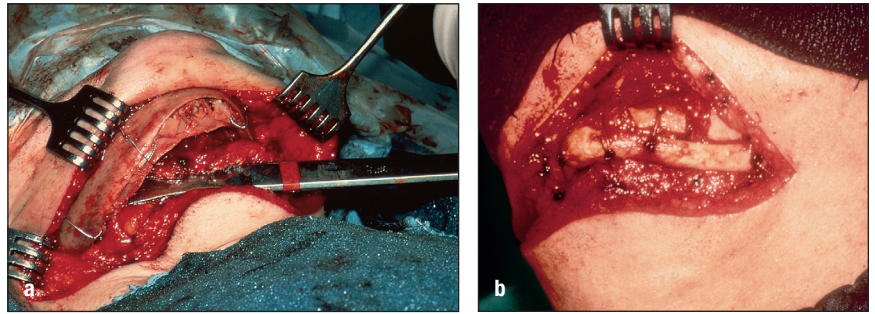


**Fig 1-24** (a) Implants placed with conventional angulation and spacing. (b) Implants placed with the posterior implants tilted distally. The two anterior implants are placed as anterior as possible to maximize AP spread, consistent with the need for appropriate spacing. Note the difference in AP spread between the two arrangement patterns. (Courtesy of Dr N. Barakat, Beirut, Lebanon.)



**Fig 1-25** (a) The ecchymosis associated with the original flap design proposed by Brånemark. (b) Another patient with the same incision following healing. Note the prominent scar associated with the incision.

**Fig 1-26** Prior to implant placement, the edentulous mandible sometimes must be augmented with autogenous bone grafts. (a) The inferior border rib graft technique. (Courtesy of Dr B. Sanders, Los Angeles, California.) (b) Superior border augmentation with iliac crest block grafts. (Courtesy of Dr W. Ware, San Francisco, California.)



Once the implants were placed, the extended flap design provided sufficient relaxation of the soft tissues to allow primary closure of the soft tissue wound without tension. There were a number of disadvantages of the original flap design, and today most surgeons prefer crestal incisions. The original flap design triggered significant edema and bruising, and the scar associated with the vestibular incision was often painful when in contact with a denture flange (Fig 1-25). Today, many surgeons use crestal incisions because there is considerably less bleeding, postoperative edema, and bruising and the scar associated with the incision is not clinically significant.

Furthermore, new techniques permit the surgeon to widen the zone of keratinized tissue around the implants, for example by splitting the band of attached tissue, if present, to leave equal amounts of attached tissue on the lingual and buccal. In addition, many surgeons now prefer a single-stage technique in selected patients as opposed to burying the implants beneath the mucosa during the healing period. The need to maximize the zone of keratinized tissue and retain or restore the interdental papilla has led to the development of many new flap designs, particularly in the esthetic zone (see chapters 5 and 10). Some disadvantages of these flap designs include less visibility of the edentulous ridge, more tension on the soft tissue flap, and closure of the soft tissue wound directly on the crest of the alveolar ridge, where the removable denture may apply undue pressure on the healing wound, increasing the possibility of soft tissue wound dehiscence. A detailed discussion of flap design changes is covered in chapter 5.

## Impact of evolving hard tissue procedures

The original surgical protocol for implant placement was designed to manage the fully edentulous arch, and hard tissue augmentation was rarely necessary. As the use of dental implants to replace missing teeth became more popular, this form of dental treatment extended to the partially edentulous and single missing tooth situations. In these clinical situations, depending on the length of time the alveolar ridge has been edentulous and the cause of edentulism (trauma, avulsion, congenitally missing, tumor resection), the clinician may find the resorption of the alveolar ridge significant and not suitable

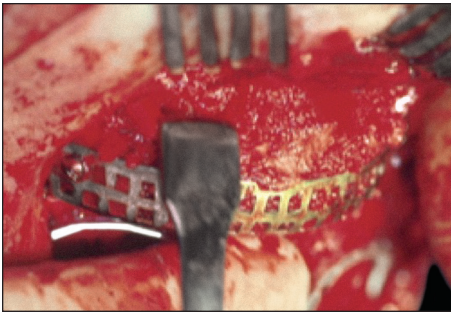
for placement of a dental implant. In these moderate to advanced resorption cases, the deficient alveolar ridge must be augmented prior to or during dental implant placement.

The grafting procedures performed today have evolved from the preprosthetic procedures used for the edentulous patients developed in the 1950s and 1960s. For these patients, moderate to severe resorption of the alveolar ridge resulted in very loose-fitting dentures, chronic soreness, and loss of masticatory efficiency. Attempts were made to reconstruct the height of the alveolar ridge by performing interpositional bone grafts for the maxillary arch and inferior/superior border bone grafting for the mandibular arch (Fig 1-26).

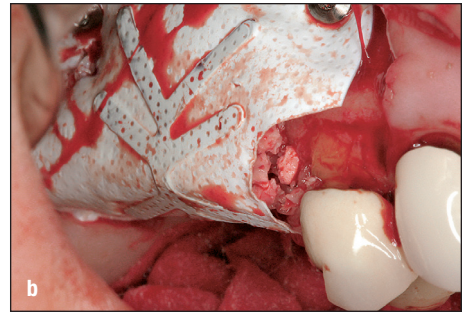
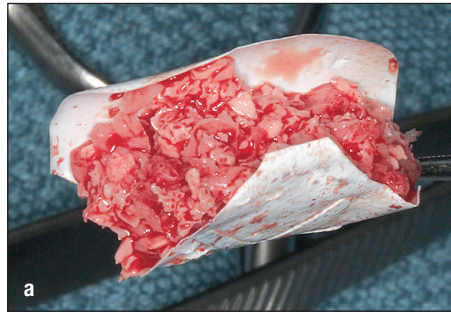
Sinus floor augmentation was initially described by Boyne and James<sup>38</sup> and employed to increase bone volume in the posterior maxilla. When the resorbed ridges were located in the anterior alveolar ridges or posterior mandibular quadrant, the grafting techniques devised to deal with these deficiencies included autogenous block bone or particulated autogenous bone to graft the deficiency. Because of the need to contain the particulated graft material, the use of membranes became popular. The term used to describe this augmentation technique eventually became known as *guided bone regeneration* (GBR).

One of the first nonocclusive, nonresorbable barriers used was titanium mesh. First described in 1985,<sup>39</sup> the titanium mesh was used in reconstruction of large mandibular discontinuity defects (Fig 1-27). Titanium mesh is becoming popular again with the use of newer grafting materials (recombinant human bone morphogenetic protein-2) and techniques and is used to contain the graft material and maintain space for bone formation. The original occlusive membrane used was a non-resorbable material (Teflon) made from expanded polytetrafluoroethylene (ePTFE) and marketed as Gore-Tex (WL Gore). As more extensive ridge augmentations were attempted, titanium strips were added between the two layers of ePTFE material (TR Gore-Tex) (Fig 1-28). This permitted the clinician to bend the metal strips to achieve the desired contour and height of the augmentation.

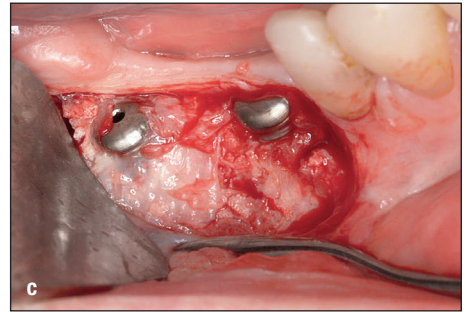
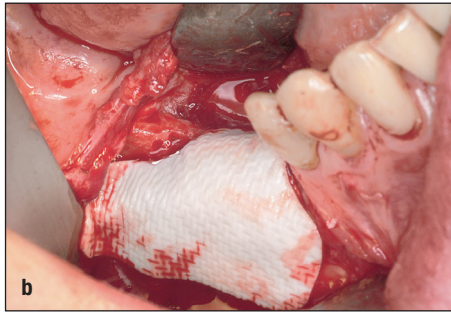
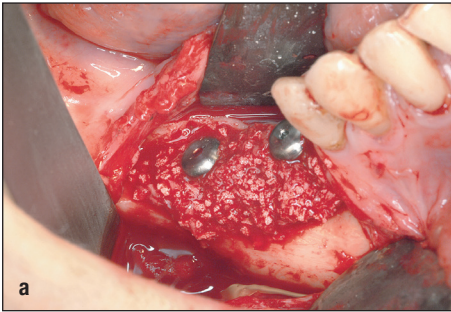
One of the disadvantages reported with the use of non-resorbable membranes was wound dehiscence resulting in exposure of the membrane. It was found in 31% to 44% of cases.<sup>40,41</sup> Once the membrane was exposed, the exposed surface would quickly build up with plaque, thus increasing



**Fig 1-27** Trays of titanium mesh originally were used to confine particulate bone grafts when reconstructing mandibular discontinuity defects.



**Fig 1-28** (*a and b*) Titanium-reinforced membranes are used today to confine graft material and maintain space during healing.



**Fig 1-29** Recently, resorbable membranes have been favored. (*a*) Graft material in position. (*b*) The membrane secured in position. (*c*) Several months later, the membrane has resorbed.

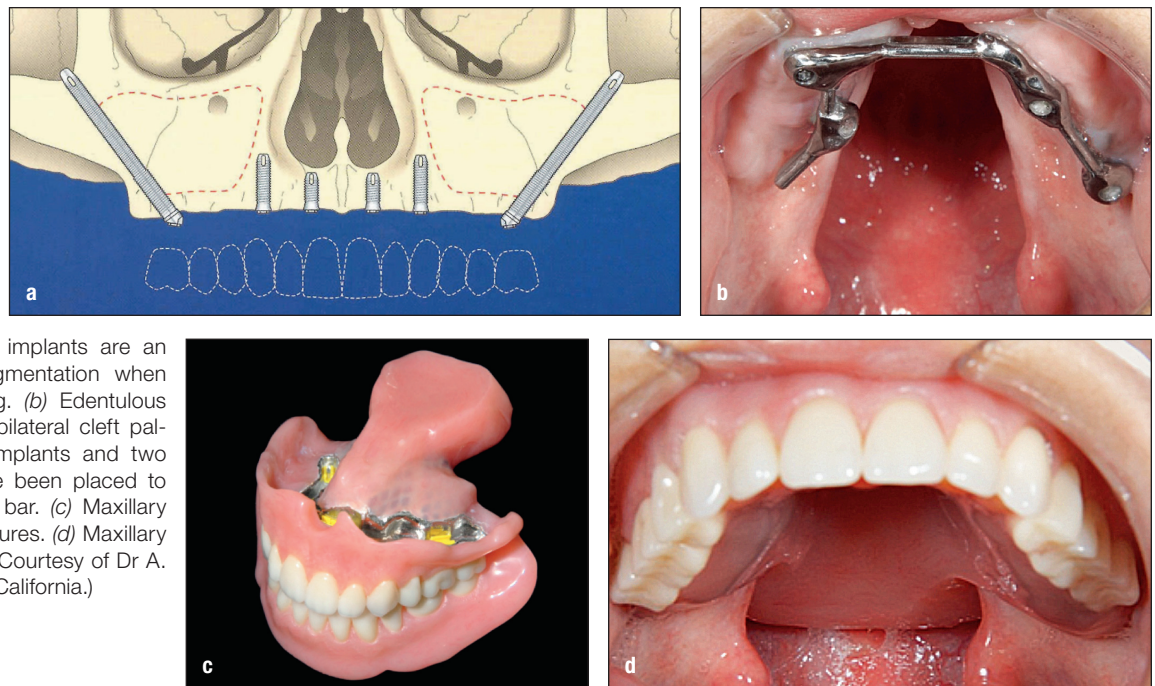
the risk of infection and reducing the total volume of new bone regenerated.<sup>42</sup> This finding led to the development of resorbable membranes fabricated from porcine/bovine-derived, type I or type III collagen and polyglycoside synthetic copolymers such as poly(L-lactide) (PLLA) (Fig 1-29). The benefits of using resorbable membranes were immediately appreciated. They eliminated the need for a second surgery to retrieve the nonresorbable membrane, there was less risk of soft tissue dehiscence, and the collagen-based membranes assisted in clot formation and potentially added volume to the soft tissue<sup>43</sup> (see chapter 8).

The use of donor graft materials remains a requisite for alveolar ridge augmentation where significant vertical and/or horizontal augmentation is desired. When selecting the appropriate donor material, the surgeon must take into consideration the working biologic mechanism of the graft material, the reactivity of the donor material with the recipient, and the anticipated purpose for using a particular graft material (providing space maintenance, active biologic process, or scaffolding). Autogenous bone remains the gold standard simply because of the length of time this donor material has been used along with the other benefits of using an autogenous scaffold con-

taining viable cells. However, autogenous grafts may not be the best donor material for all clinical situations. The significant improvements made with other graft materials (allogeneic, xenograft, alloplastic, and osteogenic proteins) must be taken into consideration when the surgeon recommends a specific donor material. It is advised that the patient be included in the selection process so that his or her concerns and/or objections are considered (see chapter 8).

### Impact of evolving soft tissue procedures

Implant surgeons today believe that correction of residual soft tissue deficiencies presents a greater challenge than correction of hard tissue deficiencies. The soft tissue procedures performed for dental implants evolved from well-established surgical procedures performed for the natural dentition. These include free gingival grafts, mucosal advancement/repositioning techniques, and connective tissue grafts. The critical decision for the surgeon to make with today's implant patient is whether the soft tissue procedures (resective or additive) are performed prior to or after the implant placement (see chapter 9).



**Fig 1-30** (a) Zygomatic implants are an alternative to sinus augmentation when implant sites are lacking. (b) Edentulous patient with unrepaired bilateral cleft palate. Two conventional implants and two zygomatic implants have been placed to support this connecting bar. (c) Maxillary and mandibular overdentures. (d) Maxillary overdenture in position. (Courtesy of Dr A. Sharma, San Francisco, California.)

### Impact of tilted implants on patient selection and treatment planning

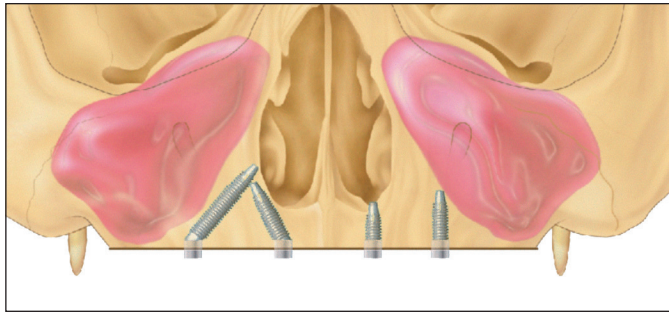
Tilted implants, placed parallel to and adjacent to the anterior wall of the maxillary sinus, posterior to the maxillary sinus through the maxillary tuberosity region, and into the zygomatic arch, are being used with increasing frequency, especially in edentulous patients. Placing implants into the zygoma has been especially useful in patients with large bony defects of the maxilla secondary to tumor ablation surgery or unrepaired cleft lip and palate (Fig 1-30) but has seen limited use in patients with fully intact jaws. Conventional tilted implants, however, have made a significant impact on the care of the patient with normal jaw anatomy.

During the 1980s and 1990s, the implants placed in edentulous patients were aligned axially, and attempts were made during surgery to place them parallel to one another. Often, cantilevers of significant lengths were employed to restore the posterior dentition. However, the edentulous maxilla of most patients contains only four implant sites (because of sinus pneumatization), and if the implants are aligned axially, AP spread is usually insufficient to permit the use of an implant-supported prosthesis (where all the occlusal forces are born by the implants) with acceptable levels of predictability. As a result, most implant-retained restorations designed and fabricated for the edentulous maxilla were removable and implant assisted.

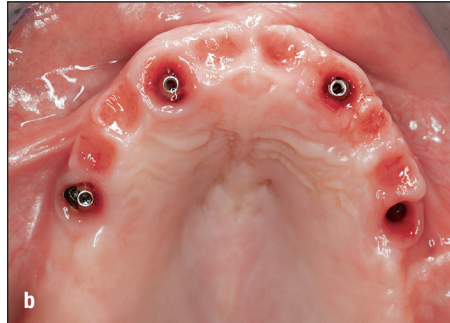
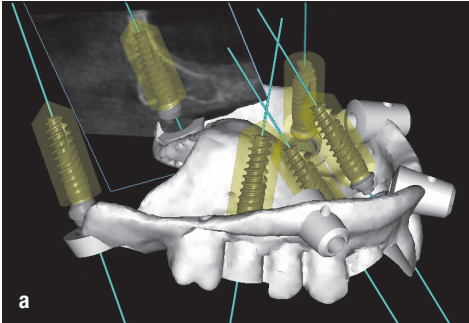
Until recently, most clinicians were reluctant to place tilted (angled) implants into the maxilla, particularly in the posterior positions, because of suspected unfavorable biomechanics. However, when multiple implants with a favorable AP spread are splinted together with rigid metal frameworks and the apical portions of these implants are firmly anchored in cortical bone, the forces appear to be distributed more favorably than first assumed. Histologic studies and finite element analysis have indicated that such angulations may actually be beneficial.<sup>44-46</sup> With this approach, the implant lengths are increased, the tips and necks of the implants are initially anchored in cortical bone, and the implants exit the mucosa more distally, increasing the AP spread (Fig 1-31). This permits the fabrication of a fully implant-supported prosthesis. Recent reports indicate that when two distally angled implants are positioned just anterior and parallel to the anterior wall of the maxillary sinus and splinted to two angled or axially aligned implants in the anterior region, very high levels of implant success can be achieved.<sup>47-51</sup>

In some patients, when initial implant anchorage is appropriate and the conditions are favorable, the implants can be placed into immediate function (the All-on-4 treatment concept [Nobel Biocare]). When a full-arch implant-supported prosthesis is planned, implant support can be enhanced posteriorly by placing tilted implants through the maxillary tuberosity bilaterally (Fig 1-32). This combination of tilted implants has also been used successfully to restore the posterior quadrants of partially edentulous patients in lieu of sinus augmentation (Fig 1-33).

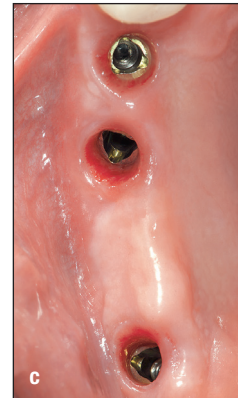
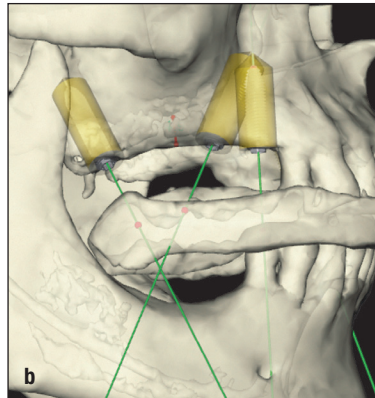
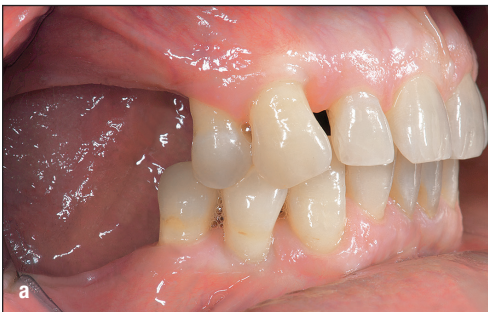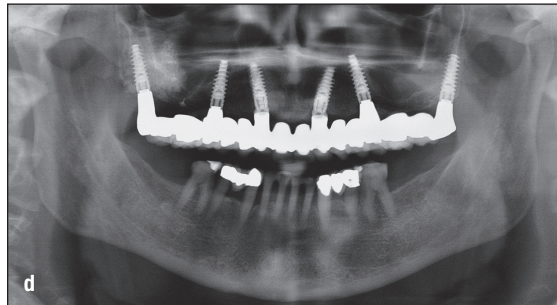

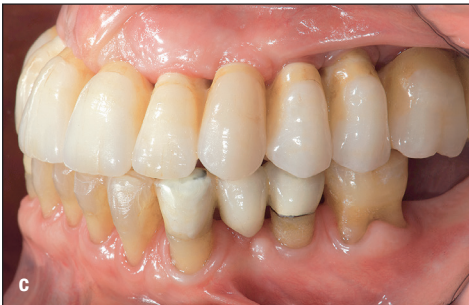


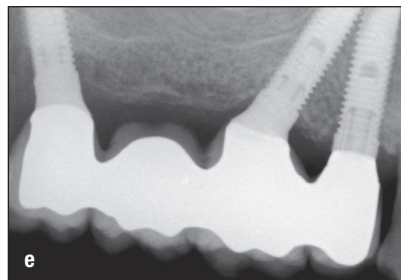
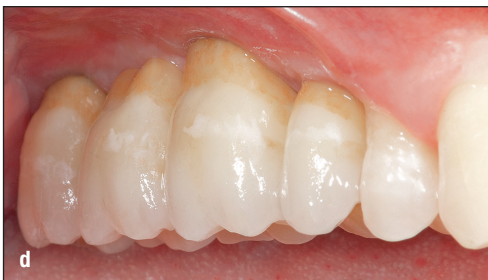**Fig 1-31** Angled implants (*on left*) as opposed to axially aligned implants (*on right*). Angling the implants enables the use of longer implants and increases AP spread and anchorage of the apical portion of the implants in cortical bone. (Courtesy of Dr O. Jensen, Denver, Colorado.)

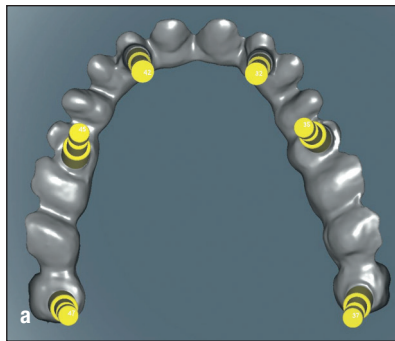


**Fig 1-32** The use of angled implants enables the fabrication of a fixed implant-supported prosthesis in the edentulous maxilla. (a) Angled implants are planned for the anterior wall of the maxillary sinus and posteriorly to engage the pterygoid plates. (b) The four anterior implants. (c) The finished prosthesis in place. (d) Panoramic radiograph of the prosthesis in position.

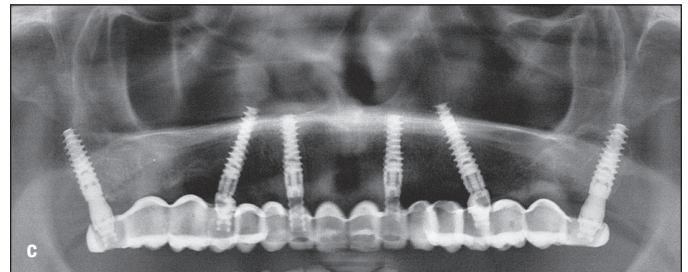
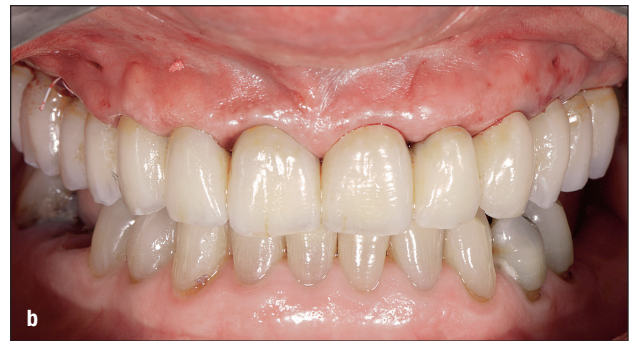

**Fig 1-33** Maxillary tuberosity implants in combination with implants tilted against the anterior wall of the maxillary sinus can also be used to support a unilateral implant-supported fixed dental prosthesis. (a) Pretreatment. (b) Rendering of the proposed positions of the implants. (c) Implants after healing. (d) Definitive prosthesis in position. (e) Periapical radiograph.





**Fig 1-34** An immediately loaded prosthesis. The four posterior implants have been tilted. (a) Digital representation of the metal framework to be used to reinforce the prosthesis. (b) The immediately loaded prosthesis in position. (c) Radiograph of the prosthesis.



## Impact of the evolution of loading principles

The original treatment protocols using machined-surface implants required the patient to wait for several months after implant placement, while the implants became osseointegrated, before the prosthesis could be fabricated. The concern was that excessive micromovement during the initial period of healing would disturb the tissue and vascular structures necessary for initial bone healing.<sup>29-31</sup> In most instances, the patients were required to use removable prostheses during this period. As mentioned earlier in this chapter, implant surfaces have been made to be more bioreactive and have accelerated the events associated with osseointegration, and as a result implants can be placed into function much earlier than had previously been possible.

Furthermore, during the last 25 years, various immediate loading protocols (ie, placement of the prosthesis onto an implant that has just been placed or within 24 hours of placement) have been proposed as implant macroshapes and implant surface textures have evolved. The success of this immediately loaded prosthesis is dependent on several factors. Clinical experience has shown that the most important factors are (1) establishing sufficient initial stabilization of the implants and (2) designing the prosthesis and the occlusion so that functional forces are distributed equitably and do not result in mobilizing the implants during the initial period of healing.

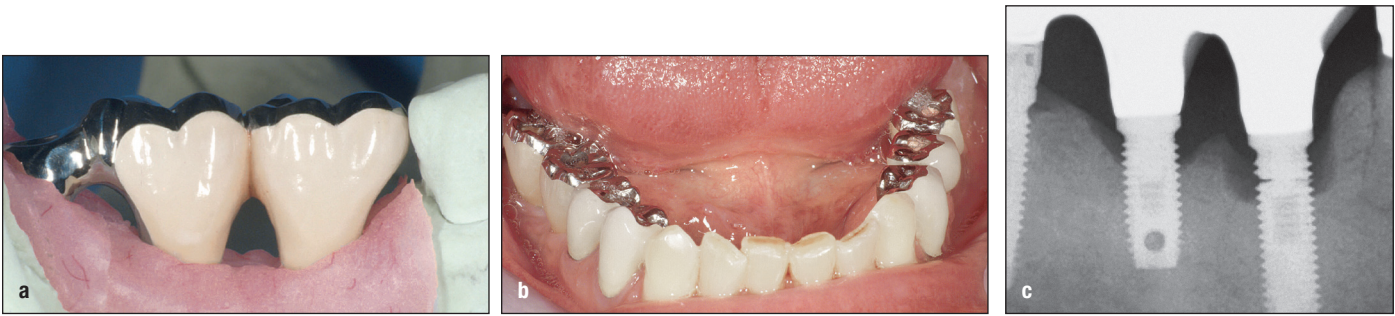Implants have been designed specifically to improve initial stabilization (see Fig 1-18). Moreover, the assessment of implant anchorage has evolved from the simple percussion test to the analysis of implant insertion torque and resonance fre-

quency analysis. In addition, the rapid development of CAD/CAM technologies has permitted the restorative dentist to fabricate rigid, precise-fitting prostheses prior to implant placement. The result of these developments is that selected patients can be offered immediately loaded prostheses with outcomes approaching the levels of success achieved with conventional loading protocols (Fig 1-34). This topic is thoroughly discussed in chapter 11.

## Changes in the pattern of implant failures and complications

Initially when implants were first introduced, most implants were lost because the implants did not become osseointegrated. These machined-surface implants were not osteoconductive, and as a result, most failures occurred early and/or in poor-quality bone sites and were probably secondary to the inability to achieve appropriate initial implant stability. With the development of osteoconductive, microrough implant surfaces and tapered, self-tapping implants, few implants fail to achieve a state of osseointegration. Most early implant failures are probably due to surgical errors (ie, overpreparation or overheating the implant osteotomy sites). Most late implant failures are probably due to peri-implantitis or implant overload and, in the esthetic zone, placement of the implant with insufficient thickness of bone on the labial side of the implant.

When implants with a diameter of 3.75 mm were used, a high rate of implant fracture was noted by the Brånemark group (about 7%). This was a significant problem when they began to



**Fig 1-35** Implant-supported fixed dental prosthesis supported and retained by implants 4 mm in diameter. This patient was a heavy bruxer. (a and b) Two-unit fixed dental prosthesis supported by three implants. (c) Three-year follow-up radiograph. The anterior implant is fractured.

be used in the late 1980s to restore the posterior quadrants of partially edentulous patients exhibiting parafunctional activity<sup>52</sup> (Fig 1-35). However, the fracture rate was dramatically reduced with the introduction of wider-diameter implants.

When implants were first introduced, the most common complication was screw loosening and fracture of abutment and prosthetic screws. Over the years, the designs improved and new alloys were introduced (see volume 1, chapter 9, “Implant screw mechanics,” pages 259–262). As a result, screw loosening and fracture are much less common today. More common findings today are screw fractures and prostheses failures secondary to poorly designed and ill-fitting implant-supported fixed dental prostheses. Training programs in implant prosthodontics have not kept pace with the rapid expansion of the numbers of dental practitioners and dental laboratories employing dental implants. In addition, few dental schools offer comprehensive didactic and clinical training programs in implant dentistry for their students. Most recent dental graduates have never restored a patient with dental implants. As a result, increasing numbers of practicing dentists are unfamiliar with the basic principles of implant surgery and prosthodontics. In addition, there are few (if any) implant training programs available in implant prosthodontics for dental technicians. The result is a higher rate of implant complications secondary to poor design, to inattention to the occlusal factors, and to imprecise fit of implant prostheses to implants or abutments.

Initially, all implant restorations were screw retained. By the mid 1990s, prefabricated and custom abutments were introduced that permitted the prosthesis to be cemented. It has

become clear in recent years that most dental practitioners were not aware of the risks or consequences of excessive accumulation of subgingival cement. Indeed, the tenuous nature of peri-implant soft tissue attachment to the implant or abutment predisposes to this phenomenon, and it should be no surprise that subgingival accumulation of cement has become the most common cause of peri-implantitis<sup>33</sup> (see Fig 1-12).

## Summary

To understand the significance of osseointegration and the impact this concept has on the surgical aspects of implant dentistry, the clinician must have working knowledge, understanding, and respect for the basic principles established by P-I Brånemark and his team. These fundamental principles, concepts, and surgical protocols have withstood the test of time. Respect for biologic processes, atraumatic surgery, well-designed prosthetics, and close collaboration with other specialists are prerequisites for providing implant patients with successful clinical outcomes in the short term as well as long term. Since the introduction of osseointegration, there has been continuing advancement of the surgical techniques employed, including enhancement of bone and soft tissues, and techniques and implant designs used to achieve initial stability of the implants. Moreover, clinicians today have a better understanding of loading principles that permit immediate loading of implant-retained and/or -supported restorations in selected patients.

## References

1. Brånemark PI, Hansson BO, Adell R, et al. Osseointegrated implants in the treatment of the edentulous jaw. Experience from a 10-year period. *Scand J Plast Reconstr Surg* 1977;16:1–132.
2. Adell R, Lekholm U, Rockler B, Brånemark PI. A 15-year study of osseointegrated implants in the treatment of the edentulous jaw. *Int J Oral Surg* 1981;10:387–416.
3. Dental Implants: Benefit and Risks. NIH Consensus Statement Online 1978;1:13–19.
4. Steinberg AD, Willey R, Drummond JL. In-vivo comparisons of clot formation on titanium and hydroxyapatite-coated titanium. *J Periodontol* 1992;63:990–994.
5. Park JY, Gemmell CH, Davies JE. Platelet interactions with titanium: Modulation of platelet activity by surface topography. *Biomaterials* 2001;22:2671–2682.
6. Thor A, Rasmusson L, Wennerberg A, et al. The role of whole blood in thrombin generation in contact with various titanium surfaces. *Biomaterials* 2007;28:966–974.
7. Kammerer PW, Gabriel M, Al-Nawas B, Scholz T, Kirchmaier CM, Klein MO. Early implant healing: Promotion of platelet activation and cytokine release by topographical, chemical and biomimetic titanium surface modifications in vitro. *Clin Oral Implants Res* 2012;23:504–510.
8. Nagaraj S, Youn JI, Gabrilovich DI. Reciprocal relationship between myeloid-derived suppressor cells and T cells. *J Immunol* 2013;191:17–23.
9. Davies JE. Understanding peri-implant endosseous healing. *J Dent Educ* 2003;67:932–949.
10. Takeuchi K, Saruwatari L, Nakamura HK, Yang JM, Ogawa T. Enhanced intrinsic biomechanical properties of osteoblastic mineralized tissue on roughened titanium surface. *J Biomed Mater Res A* 2005;72:296–305.
11. Butz F, Aita H, Wang CJ, Ogawa T. Harder and stiffer bone osseointegrated to roughened titanium. *J Dent Res* 2006;85:560–565.
12. Jimbo R, Sotres J, Johansson C, Breeding K, Currie F, Wennerberg A. The biological response to three different nanostructures applied on smooth implant surfaces. *Clin Oral Implants Res* 2012;23:706–712.
13. Butz F, Ogawa T, Nishimura I. Interfacial shear strength of endosseous implants. *Int J Oral Maxillofac Implants* 2011;26:746–751.
14. Albrektsson T, Hansson HA. An ultrastructural characterization of the interface between bone and sputtered titanium or stainless steel surfaces. *Biomater* 1986;7:201–205.
15. Linder L. Ultrastructure of the bone-cement and the bone-metal interface. *Clin Orthopaed Relat Res* 1992;276:147–156.
16. Sennerby L, Ericson LE, Thomsen P, Lekholm U, Astrand P. Structure of the bone-titanium interface in retrieved clinical oral implants. *Clin Oral Implants Res* 1991;2:103–111.
17. Cha JY, Pereira MD, Smith AA. Multiscale analysis of the bone implant interface. *J Dent Res* 2015;94:482–490.
18. Ogawa T, Nishimura I. Different bone integration profiles of turned and acid-etched implants associated with modulated expression of extracellular matrix genes. *Int J Oral Maxillofac Implants* 2003;18:200–210.
19. O'Brien CA, Nakashima T, Takayanagi H. Osteocyte control of osteoclastogenesis. *Bone* 2013;54:258–263.
20. Howshaw SJ, Brunski JB, Cochran GV. Mechanical overloading of Brånemark implants affects interfacial bone modeling and remodeling. *J Oral Surg* 1994;9:345–360.
21. Brunski JB, Puleo DA, Nance A. Biomaterials and biomechanics of osseointegrated implants: Current status and future developments. *Int J Oral Maxillofac Implants* 2000;15:15–46.
22. Miyata T, Kobayashi Y, Araki H, Motomura Y, Shin K. The influence of controlled occlusal overload on peri-implant tissue: A histologic study in monkeys. *Int J Oral Maxillofac Implants* 1998;13:677–683.
23. Miyata T, Kobayashi Y, Araki H, Ohto T, Shin K. The influence of controlled occlusal overload on peri-implant tissue. Part 3: A histologic study in monkeys. *Int J Oral Maxillofac Implants* 2000;15:425–431.
24. Miyata T, Kobayashi Y, Araki H, Ohto T, Shin K. The influence of controlled occlusal overload on peri-implant tissue. Part 4: A histologic study in monkeys. *Int J Oral Maxillofac Implants* 2002;17:384–390.
25. Myamoto Y, Koretake K, Hirata M, Kubo T, Akawgawa Y. Influence of static overload on the bony interface around implants in dogs. *Int J Prosthodont* 2008;21:437–444.
26. Nagasawa M, Takano R, Maeda T, Uoshima K. Observation of the bone surrounding an overloaded implant in a novel rat model. *Int J Oral Maxillofac Implants* 2013;28:109–116.
27. Aita H, Hori N, Takeuchi M, et al. The effect of ultraviolet functionalization of titanium on integration with bone. *Biomater* 2009;30:1015–1025.
28. Att W, Ogawa T. Biological aging of implant surfaces and their restoration with ultraviolet light treatment: A novel understanding of osseointegration. *Int J Oral Maxillofac Implants* 2012;27:753–761.
29. Pillar RM, Lee JM, Maniatopoulos C. Observations on the effect of movement on bone ingrowth into porous-surfaced implants. *Clin Orthop Relat Res* 1986;208:108–113.
30. Szmukler-Moncler, Piattelli A, Favero GA, Dubruille JH. Considerations preliminary to the application of early and immediate loading protocols in dental implantology. *Clin Oral Implants Res* 2000;11:12–25.
31. Duyck J, Vandamme K, Geris L, et al. The influence of micro-motion on the tissue differentiation around immediately loaded cylindrical turned titanium implants. *Arch Oral Biol* 2006;51:1–9.
32. Linkevicius T, Vindasiute E, Puisys A, Linkeviciene L, Maslova N, Puriene A. The influence of the cementation margin position on the amount of undetected cement. A prospective clinical study. *Clin Oral Implants Res* 2013;24:71–76.
33. Wilson TG. The positive relationship between excess cement and peri-implant disease: A prospective clinical study. *J Periodontol* 2009;80:1388–1392.
34. Berglundh T, Lindhe J. Dimension of the peri-implant mucosa. Biological width revisited. *J Clin Periodontol* 1996;23:971–973.
35. Verstreken K, Van Cleynenbreugel J, Marchal G, Naert I, Suetens P, van Steenberghe D. Computer-assisted planning of oral implant surgery: A three-dimensional approach. *J Oral Maxillofac Implants* 1996;11:806–810.
36. Verstreken K, Van Cleynenbreugel J, Marchal G, van Steenberghe D, Suetens P. Computer-assisted planning of oral implant surgery. An approach using virtual reality. *Stud Health Technol Inform* 1996;29:423–434.
37. van Steenberghe D, Naert I, Andersson M, Brajnovic I, Van Cleynenbreugel J, Suetens P. A custom template and definitive prosthesis allowing immediate implant loading in the maxilla: A clinical report. *Int J Oral Maxillofac Implants* 2002;17:663–670.
38. Boyne PJ, James RA. Grafting of the maxillary sinus floor with autogenous marrow and bone. *J Oral Surg* 1980;38:613–616.
39. Boyne PJ, Lilly LC, Marx RE, et al. De novo bone induction by recombinant human bone morphogenetic protein-2 (rhBMP-2) in maxillary sinus floor augmentation. *J Oral Maxillofac Surg* 2005;63:1693–1707.
40. Lang NP, Hämmerle CH, Brägger U, Lehmann B, Nyman SR. Guided tissue regeneration in jawbone defects prior to implant placement. *Clin Oral Implants Res* 1994;5:7–92.
41. Zitzmann NU, Naef R, Schärer P. Resorbable vs nonresorbable membranes in combination with Bio-Oss for guided bone regeneration. *Int J Oral Maxillofac Implants* 1997;12:844–852.
42. Becker W, Dahlin C, Becker BE, et al. The use of e-PTFE barrier membranes for bone promotion around titanium implants placed into extraction sockets: A prospective multicenter study. *Int J Oral Maxillofac Implants* 1994;9:31–40.
43. Hämmerle CHF, Jung RE. Bone augmentation by means of barrier membranes. *Periodontology* 2000 2003;33:36–53.

44. Celletti R, Pameijer CH, Bracchetti G, Donath K, Persichetti G, Visani I. Histologic evaluation of osseointegrated implants restored in nonaxial functional occlusion with pre-angled abutments. *Int J Periodontics Restorative Dent* 1995;15:562–573.
45. Bevilacqua M, Tealdo T, Menini M, et al. The influence of cantilever length and implant angulation on stress distribution for maxillary implant-supported fixed prostheses. *J Prosthet Dent* 2011;105:5–13.
46. Zampelis A, Rangert B, Heijl L. Tilting of splinted implants for improved prosthodontic support: A two-dimensional finite element analysis. *J Prosthet Dent* 2007;97(6 suppl):35–43.
47. Tealdo T, Bevilacqua M, Pera P, et al. Immediate function with fixed implant-supported maxillary denture: A 12-month pilot study. *J Prosthet Dent* 2008;99:351–356.
48. Bevilacqua M, Tealdo T, Menini M, et al. The influence of cantilever length and implant angulation on stress distribution for maxillary implant-supported fixed prostheses. *J Prosthet Dent* 2011;105:5–13.
49. Jensen OT, Adams MW. The maxillary M-4: A technical and biomechanical note for all on four management of severe maxillary atrophy—Report of 3 cases. *J Oral Maxillofac Surg* 2009;67:1739–1744.
50. Jensen OT, Cottam JR, Ringeman JL, Adams M. Angled dental implant placement into the vomer/nasal crest of atrophic maxillae for All-on-Four immediate function: A 2-year clinical study of 100 consecutive patients. *Int J Oral Maxillofac Implants* 2014;29:e30–e35.
51. Jensen OT, Adams MW. Secondary stabilization of maxillary M-4 treatment with unstable implants for immediate function: Biomechanical considerations and report of 10 cases after 1 year in function. *Oral Craniofac Tissue Eng* 2012;2:294–302.
52. Rangert BR, Sullivan RM, Jemt TM. Load factor control for implants in the posterior partially edentulous segment. *Int J Oral Maxillofac Implants* 1997;12:360–370.

# The Evolution of Modern Dental Implant Surfaces

Takahiro Ogawa  
Basil Al-Amleh  
Ichiro Nishimura  
John Beumer III


# 2

Since titanium implants were introduced more than 30 years ago, a sustained effort has been made to make their surfaces more osteoconductive. Following placement of a dental implant made of titanium, a blood clot forms between the surface of the implant and the walls of the osteotomy site.<sup>1</sup> Plasma proteins are attracted to the area, platelets are activated, and cytokines and growth factors are released.<sup>2-4</sup> Angiogenesis begins, and mesenchymal stem cells migrate via the fibrin scaffold of the clot to the osteotomy site and the surface of the implant. These cells differentiate into osteoblasts and begin to deposit bone on the surface of the implant and the walls of the osteotomy site, eventually leading to anchorage of the implant in bone.<sup>5</sup> This process takes anywhere from 2 weeks to 4 months, depending on the osteoconductivity of the implant surface.

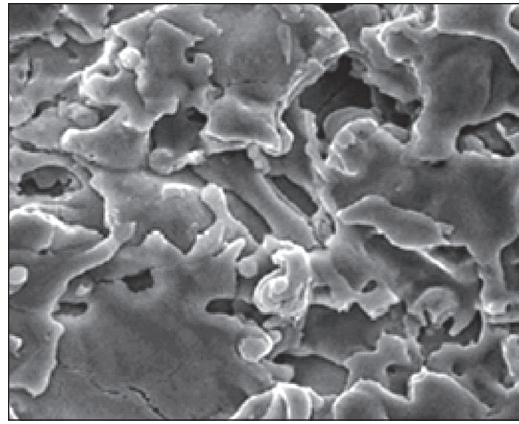
The process of machining the implants to create their screw-shaped macrostructure was responsible for the implant surface texture of the original Brånemark implant introduced in the 1980s. A wavy surface irregularity was created, depending on the methods employed during machining (Fig 2-1). The machined implant surfaces were osteo-inert (the passive process by which osteogenesis initiates exogenously and approaches the implant surface) as opposed to osteoconductive (the recruitment of osteogenic cells and their migration to the surface of the implant); in the early years,

osseointegrated implants were used with great success in edentulous patients when the implant sites were composed of relatively dense cortical bone. However, initial attempts to restore partially edentulous patients, particularly those with poor-quality type IV bone were met with frustration and an unacceptable rate of failure.<sup>6</sup> Unfortunately, these frustrations and failures were underreported in the literature. Significant difficulty was encountered when restoring posterior quadrants in the maxilla with implants in partially edentulous patients, especially when cortical layers of bone were thin and the trabecular bone exhibited poor density. Successful results with machined-surface implants in these sites were achieved primarily when the implants were stabilized by so-called bi-corticalization (ie, positively engaging the cortical layers of bone associated with the floor of the maxillary sinus and the alveolar process). This procedure was technically demanding, particularly prior to the introduction of computed tomography scans, which allow accurate assessment of the bone sites in three dimensions. As a result, there began a sustained effort to develop implant shapes that could achieve improved initial mechanical stabilization and whose surfaces were more osteoconductive.

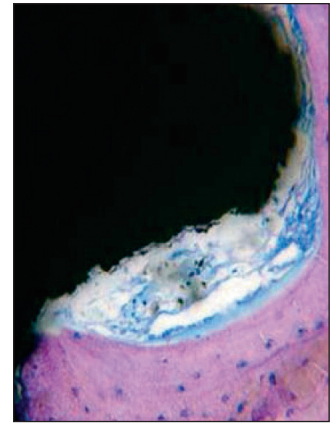
Several different types of implants were introduced during the 1980s, with surface topography modified by titanium plasma spray (TPS) or airborne-particle abrasion and titanium



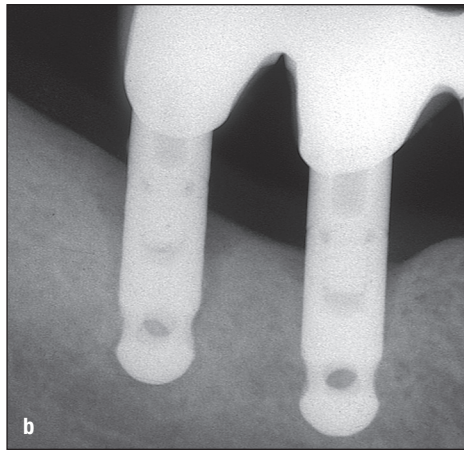
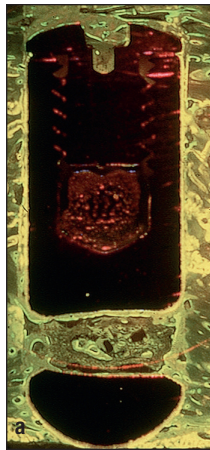
**Fig 2-1** Machined-surface implant. Note the surface morphology. It has been shown that this surface is less bioreactive and osteoconductive than the modern implant surfaces with more favorable surface topography.



**Fig 2-2** TPS surface. Note the surface irregularities, which range from 10 to 200 microns in size.



**Fig 2-3** Note the particles of titanium within the tissues. In some instances, this will lead to so-called particle disease.



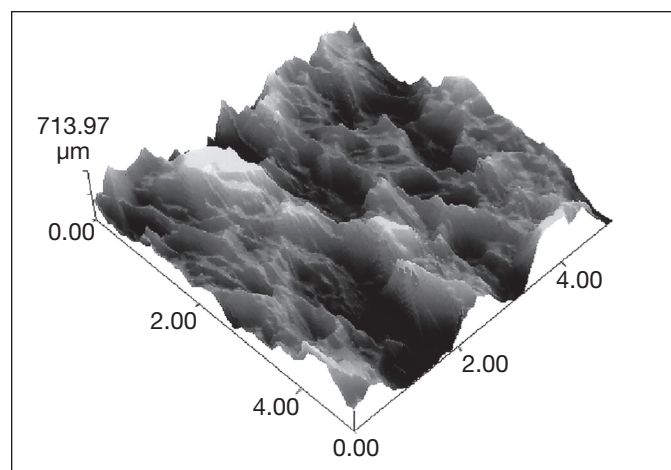
**Fig 2-4** (a) An HA-coated implant 6 weeks after implantation. The new bone is easily seen with the tetracycline label (yellow). (b) HA-coated implants 3 years after insertion. The HA coating has become exposed, leading to irritation of the peri-implant tissues. Note the bone loss associated with the implants.

implants purportedly coated with hydroxyapatite (HA). All had dramatically different surface topographies compared with implants with machined surfaces. However, none of these surfaces provided a significant improvement in clinical outcomes. The surfaces of implants prepared with TPS were quite rough and irregular; the surface irregularities ranged from 10 to 200 microns in size (Fig 2-2). The surface roughness did increase the surface area of the implant, resulting in improved implant anchorage compared with machined-surface implants.<sup>7,8</sup> However, when the roughened implant surfaces became exposed to the oral cavity, they retained plaque and calculus tenaciously, leading to inflammation of the peri-implant tissues and loss of bone (peri-implantitis).<sup>9,10</sup> Also, during placement, small particles of titanium were often sheared off the surface of the implant, attracting macrophages and giant cells into the area intent upon phagocytizing these particles (Fig 2-3). This process was accompanied by an inflammatory response in the local tissues (so-called particle disease).

The surface roughness of implants treated with airborne-particle abrasion, like the TPS surfaces, varied considerably depending on the size of the abrasive particles and air pressure. However, these implants presented clinicians with an additional problem: Given the technologies available during the 1980s, it was difficult to completely remove the surface contaminants associated with the process of airborne-particle abrasion, leaving the surface of the implant contaminated and negatively affecting the process of osseointegration.

Plasma spray HA-coated titanium implants were initially thought to be advantageous because of their chemical similarity to bone. The so-called HA-calcium phosphate (HA-CaP) surface was more osteoconductive than the titanium surfaces then available. The enhanced osteoconductivity led to rapid deposition of bone onto the entire surface of the implant following placement. Within 6 weeks, almost the whole implant surface was covered with bone<sup>11</sup> (Fig 2-4a). During healing, calcium and phosphate ions were released from the HA-CaP

**Fig 2-5** The surface topography resulting from double acid etching. This three-dimensional image was taken by atomic force microscopy.



coating in the peri-implant region. This led to the precipitation of a biologic apatite on the surface of the implant, which served as a substrate for osteoblasts producing bone. The biologic apatite substrate also facilitated adhesion of migrating mesenchymal stem cells and accelerated the differentiation of these cells into bone-producing cells.

However, the surfaces of the original plasma spray HA-surface implants were mostly composed of tricalcium phosphate (TCP) rather than HA.<sup>12</sup> This occurred because the techniques used to apply the HA to the surface transformed its crystalline structure to TCP, which is rapidly resorbed. Also, when the so-called plasma spray HA-CaPO<sub>4</sub> surface became exposed to the oral cavity, it was colonized by oral microorganisms, which in turn provoked an aggressive inflammatory response of the peri-implant tissues. The bacterial colonization, bone loss (Fig 2-4b), and occasional delamination of the so-called HA layer from the titanium surfaces (the adhesion of the HA to the titanium implant surface was purely mechanical) led to high failure rates compared with titanium implants.<sup>13</sup>

By the end of the 1980s, it became apparent that these surface treatments had not significantly improved clinical outcomes, particularly in patients with poor-quality bone sites. Machined surfaces remained the standard. However, several new technologies were evolving that allowed researchers to gain insight into the initial molecular events associated with the process of osseointegration and that eventually would lead to the development of implant surfaces that were osteoconductive as opposed to osteo-inert machined-surface implants.

## Microrough Surfaces

Research efforts in the last 20 years have attempted to improve the bioreactivity of the implant surface in order to decrease healing time, improve the quality of the bone anchorage, and enable more predictable use in marginal or poor-quality bone sites. In the early 1990s, several new methods were introduced to roughen the surfaces of titanium implants (eg, acid

etching, combined airborne-particle abrasion and acid etching, titanium grit blasting, anodic oxidation). The implant surfaces created by these methods were considerably less rough than those created by the TPS method or by airborne-particle abrasion and were more consistent; the surface irregularities ranged from 0.5 to 2.0 microns in size (Fig 2-5).

At first, the main advantage appeared to be improved mechanical anchorage. The initial studies concentrated on the bone-to-implant contact (BIC) area. The early publications showed that the BIC for implants with microrough surfaces was greater than that seen with machined-surface implants.<sup>11,14-18</sup> This was initially thought to be secondary to the improved retention of the fibrin clot, which immediately forms between the implant and the osteotomy sites upon placement of the implant.<sup>19</sup> As a result, the initial events (adsorption of plasma proteins, platelet activation, clot formation, angiogenesis, mesenchymal stem cell migration and attachment, cell differentiation) associated with osseointegration were facilitated. Subsequent reports indicated that in addition to improved BIC, the process of osseointegration was accelerated.<sup>20-22</sup>

However, it soon became evident that the substantial improvement in anchorage seen in implants with microrough surfaces was not entirely due to the increased BIC. In one representative study using a rabbit femur model, removal torque studies using screw-shaped implants comparing machined surfaces and microrough surfaces indicated that the torque value needed to remove the implants from bone was 1.5 to 3.5 times greater for the microrough surfaces at 1 month and 2 months following placement of the implants.<sup>16</sup>

Similar experiments were carried out using a rat model. In order to isolate the effect of surface topography from the macroscopic implant form (screw shape), cylindrical implants with machined surfaces and those with microrough surfaces created by double acid etching were placed into the distal femur of rats. The strength of osseointegration was evaluated by determining the interfacial breakage strength (referred to as *push-in value*) while the implant was being pushed into the bone marrow with an Instron machine (Fig 2-6). Acid-etched microrough surfaces showed three to four times greater strength