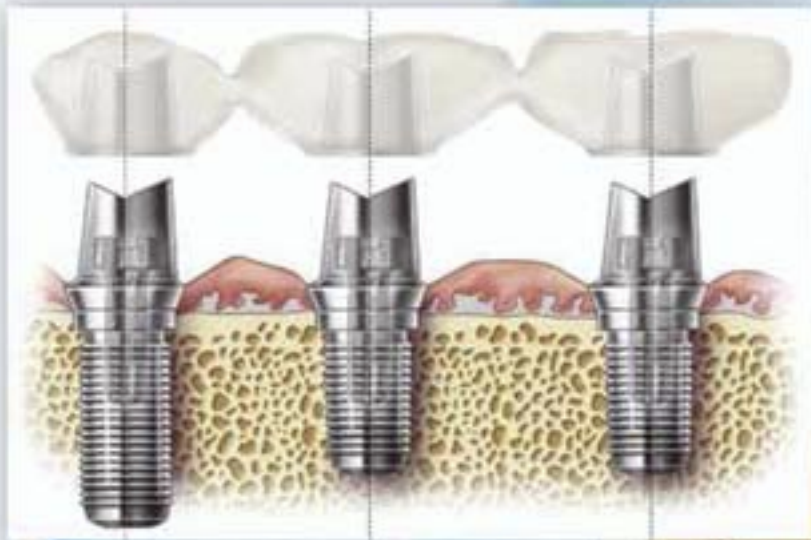
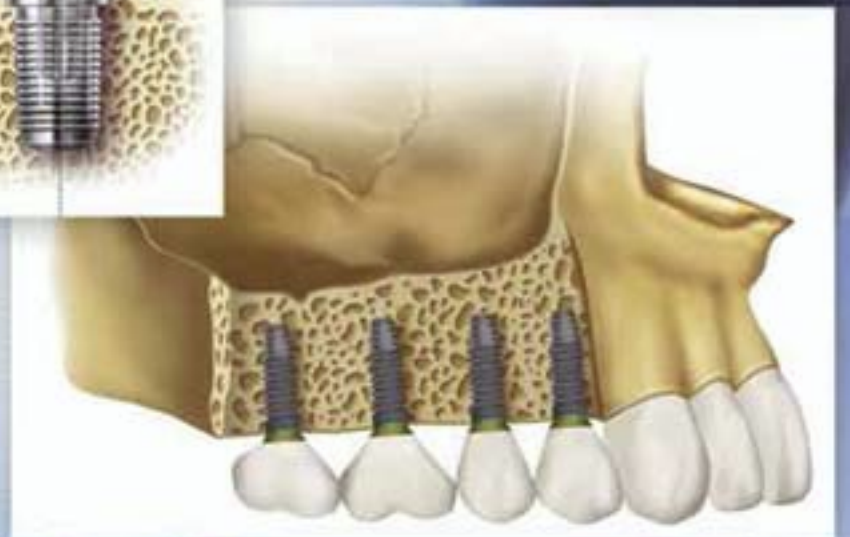

Carl E. Misch

# Dental Implant Prosthetics



2  
EDITION





# Dental Implant Prosthetics

2  
EDITION

**Carl E. Misch, DDS, MDS, PhD(HC)**

Clinical Professor and Past Director  
Oral Implant Dentistry  
Temple University  
Kornberg School of Dentistry  
Department of Periodontics and Implant Dentistry  
Philadelphia, Pennsylvania

**Past Clinical Professor**  
University of Michigan  
School of Dentistry  
Department of Periodontics/Geriatrics  
Ann Arbor, Michigan

**Past Adjunct Professor**  
University of Detroit  
School of Dentistry  
Department of Restorative Dentistry  
Detroit, Michigan

**Adjunct Professor**  
University of Alabama at Birmingham  
School of Engineering  
Birmingham, Alabama

**Founder**  
Misch International Implant Institute  
Beverly Hills, Michigan

ELSEVIER

**ELSEVIER**  
MOSBY

3251 Riverport Lane  
St. Louis, Missouri 63043

DENTAL IMPLANT PROSTHETICS, SECOND EDITION  
Copyright © 2015 by Mosby, an imprint of Elsevier Inc.  
Copyright © 2005 by Mosby, Inc., an affiliate of Elsevier Inc.

ISBN: 978-0-323-07845-0

All rights reserved. No part of this publication may be reproduced or transmitted in any form or by any means, electronic or mechanical, including photocopying, recording, or any information storage and retrieval system, without permission in writing from the publisher. Details on how to seek permission, further information about the Publisher's permissions policies and our arrangements with organizations such as the Copyright Clearance Center and the Copyright Licensing Agency, can be found at our website: [www.elsevier.com/permissions](http://www.elsevier.com/permissions).

This book and the individual contributions contained in it are protected under copyright by the Publisher (other than as may be noted herein).

#### Notices

Knowledge and best practice in this field are constantly changing. As new research and experience broaden our understanding, changes in research methods, professional practices, or medical treatment may become necessary.

Practitioners and researchers must always rely on their own experience and knowledge in evaluating and using any information, methods, compounds, or experiments described herein. In using such information or methods they should be mindful of their own safety and the safety of others, including parties for whom they have a professional responsibility.

With respect to any drug or pharmaceutical products identified, readers are advised to check the most current information provided (i) on procedures featured or (ii) by the manufacturer of each product to be administered, to verify the recommended dose or formula, the method and duration of administration, and contraindications. It is the responsibility of practitioners, relying on their own experience and knowledge of their patients, to make diagnoses, to determine dosages and the best treatment for each individual patient, and to take all appropriate safety precautions.

To the fullest extent of the law, neither the Publisher nor the authors, contributors, or editors, assume any liability for any injury and/or damage to persons or property as a matter of products liability, negligence or otherwise, or from any use or operation of any methods, products, instructions, or ideas contained in the material herein.

#### Library of Congress Cataloging-in-Publication Data

Misch, Carl E., author.

Dental implant prosthetics / Carl E. Misch.—Second edition.

p. ; cm.

Includes bibliographical references and index.

ISBN 978-0-323-07845-0

I. Title.

[DNLM: 1. Dental Implantation—methods. 2. Dental Implants. 3. Patient Care Planning.

WU 640]

RK667.I45

617.6'93—dc23

2014000620

*Executive Content Strategist:* Kathy Falk  
*Senior Content Development Specialist:* Brian Loehr  
*Publishing Services Manager:* Catherine Jackson  
*Senior Project Manager:* Carol O'Connell  
*Design Direction:* Maggie Reid

Printed in China

Last digit is the print number: 9 8 7 6 5 4 3 2 1



# Contributors

**Martha Warren Bidez, PhD**

Professor, School of Engineering  
University of Alabama at Birmingham  
Birmingham, Alabama

**Lee Culp, CDT**

Chief Technology Officer  
Microdental Laboratories  
Research Triangle  
Morrisville, North Carolina

**Jack E. Lemons, PhD**

University Professor  
University of Alabama at Birmingham  
Birmingham, Alabama

**Michael S. McCracken, DDS, PhD**

Professor  
University of Alabama at Birmingham  
Birmingham, Alabama

**Carl E. Misch, DDS, MDS, PhD(HC)**

Clinical Professor and Past Director  
Oral Implant Dentistry  
Temple University  
Kornberg School of Dentistry  
Department of Periodontics and Implant Dentistry  
Philadelphia, Pennsylvania;  
Past Clinical Professor  
University of Michigan  
School of Dentistry  
Department of Periodontics/Geriatrics  
Ann Arbor, Michigan;  
Past Adjunct Professor  
University of Detroit  
School of Dentistry  
Department of Restorative Dentistry  
Detroit, Michigan;  
Adjunct Professor  
University of Alabama at Birmingham  
School of Engineering  
Birmingham, Alabama;  
Founder  
Misch International Implant Institute  
Beverly Hills, Michigan

**Francine Misch-Dietsch, DDS, MDS, FICD**

Private Practice  
Miami, Florida  
Rome, Italy

**Girish Ramaswamy, PhD**

Postdoctoral Researcher  
Department of Orthopedic Surgery  
Perelman School of Medicine  
University of Pennsylvania  
Philadelphia, Pennsylvania

**Randolph R. Resnik, DMD, MDS**

Clinical Professor  
Department of Periodontology and Oral Implantology  
Kornberg School of Dentistry  
Temple University  
Philadelphia, Pennsylvania  
Surgical Director  
Misch Implant Institute  
Beverly Hills, Michigan

**J. Todd Strong, MS**

COO and Executive Vice President  
BioHorizons  
Birmingham, Alabama

**Jon B. Suzuki, DDS, PhD, MBA**

Professor, Chairman, and Program Director  
Department of Periodontology and Oral Implantology  
School of Dentistry  
Professor  
Department of Microbiology and Immunology  
School of Medicine  
Temple University  
Philadelphia, Pennsylvania

**Lynn D. Terracciano-Mortilla, RDH**

Private Practice  
Trinity, Florida

**Natalie Y. Wong, DDS, Cert. Prostho, FRCD(C),  
DABP, DABOI**

Private Practice  
Toronto, Ontario, Canada



---

*To my parents, MaryAnn Misch and Carl Otto Misch.  
And to my children, Paula Angeline Mather, Carl Patrick Misch,  
Lara Elizabeth Vandekerckhove, David John Misch, Jonathan Edward  
Misch, and Angela Marie Misch.  
I love you all very much.*

---

Feast your mind on the writings of a master dental implant clinician and teacher.

This second edition of *Dental Implant Prosthetics* is more than an update of the widely read and referenced first edition. It is more than a juxtaposition of old and new relevant implant prosthetic thinking. It is a confluence, a continuum, and an expansion of encyclopedic knowledge by a pre-eminent implant prosthodontist, Dr. Carl E. Misch.

Dr. Misch's professional background, that includes decades of practice and teaching, encompasses both the infancy and emergence of dental implantology, its renaissance, and its current prominence in the panoply of total and advanced dental treatment. This book is a reflection of this expansive sum of accumulated knowledge.

It includes the solid footing of implant biomechanics, implant biomaterials, pretreatment prostheses, radiographic imaging, and the otherwise too often neglected subject of occlusion. It is a text. It is a learning tool. It brings us back to basics and then proceeds beyond the basics into the current realm of

patient treatment. This book tells us where we have been and where we should be. It is not a glossy picture book that satisfies our eyes, but rather a book of words that are essential to the sound practice of implant dentistry.

These words teach not only the neophyte clinician but also renew the clinical platform that sustains the experienced practitioner. You are not an "experienced clinician" unless you renew and refresh why you are doing what you are doing. The end result of oral implantology is the well-planned fabrication and insertion of a viable prosthesis. The reconstructive principles described in this book fulfill the guidelines and parameters that constitute the processes of dental implant prosthetic reconstruction.

Dr. Misch has done the dental implant clinician a favor by compiling this updated edition. It is a reflection of his sense of duty to continue to educate. This book is "boot camp" for us all.

**Morton L. Perel, DDS, MScD, FACD, FICD**

In 2005, I had the honor to write a brief foreword to Dr. Carl E. Misch's book *Dental Implant Prosthetics*, which has since become a classic, translated into many languages and influencing many thousands of his colleagues. A true dental "best seller" of all time.

Dr. Misch, as a member of the healing arts and sciences, has greatly benefited from the previous valuable contributions of many. Let us not forget Semmelweis, who introduced the concept of surgical cleanliness involving hands, instruments, clothing, drapes, and bandages, thereby saving hundreds of thousands of lives by preventing puerperal fever and, by extension, positively altering basic wound healing therapy. In the end, he was condemned by none other than the brilliant surgeon Virchow. It was ironic that Semmelweis died after contracting septicemia at the young age of 47, and at his own hand. In rapid order we were bombarded by the works of Lister, Pasteur, and Koch. Dentistry contributed greatly to the growing field of anesthesia, which allowed a burgeoning number of surgical procedures. Three areas, however, remained untouchable: the heart, brain, and spinal cord.

In 1896, long before the introduction of antibiotics, Dr. Louis Rehn, of the Frankfurt City Hospital, treated a patient who had been stabbed with a knife between the ribs through the pericardium and into the heart itself. Rehn acted decisively and made an incision in the fourth intercostal space, severed the fifth rib, and probed the thoracic cavity. The patient's left lung then collapsed. However, Rehn was able to clasp the pericardium, remove copious clots and blood, and visualize the still beating heart. In between beats, the wound to the right ventricle was sutured. In short order, the hemorrhage stopped and the patient survived. The principles of aseptic surgery were

followed. And while some complications ensued, the patient returned to complete health and was presented by Dr. Rehn at a surgical conference in Berlin.

What does this all have to do with Dr. Misch's new edition? Carl has often personally told me that his ultimate goal in dedicating his life to dental implantology was "to advance the field" as others mentioned above clearly have. If we recognize that our patients do not necessarily want implants *per se*, but rather they want the prosthodontic results (i.e., teeth that permit function, smiles, social interactions, self-confidence, etc.), which would be in many cases supported by implants, then, and only then, will we all realize the great contribution that will be made for decades to come by the second edition of *Dental Implant Prosthetics*.

Another consideration that we should all appreciate is who will be the beneficiaries of this expanded work? Over the past 40 years, thousands of our dental colleagues have been introduced to implantology by Dr. Misch's lectures. Almost five thousand seriously committed dentists, specialists as well as generalists, have graduated from the Misch Implant Institutes in the United States and abroad. Dental educators, as well as students, rely on Dr. Misch's prosthodontic continuum not only for understanding but also for basic language, treatment planning, multiple updates, and clinical techniques.

Dr. Misch's second edition is not a prolegomena. It is a Bible.

This short commentary is submitted with great personal and professional admiration and respect.

**Kenneth W.M. Judy, DDS, FACD, FICD**  
Co-Chairman, International Congress of Oral Implantologists

# Preface

In the early 1900s, fixed partial dentures to replace missing teeth in a partially edentulous patient were vehemently opposed, and removable partial dentures were strongly encouraged. In 1911, Hunter blamed the “mausoleum of gold over a mass of sepsis” for complicating systemic conditions of anemia, gastritis, kidney disease, and lesions of the spinal cord.<sup>1</sup> Despite this popular belief, fixed partial dentures became the standard of care to replace missing teeth and are still taught in every dental school in North America. In fact, if a dental student does not perform a traditional fixed partial denture, they do not graduate and join the dental community.

In the 1970s, the mere mention of dental implants was controversial. Organized dentistry feared that these devices would always fail and could lead to a brain abscess or heart failure, because it was believed there was no barrier between the oral bacteria and the systemic pathways. However, in spite of this obstacle, a few hundred dentists around the world observed that patients readily accepted dental implants to support a mandibular complete denture or believed that a fixed implant prosthesis was more desirable than using removable restorations or preparing and joining adjacent teeth for fixed prostheses.

Today we are in the midst of a dental implant revolution. There are more scientific and clinical articles written on dental implants than any other topic in dentistry. From 1950 to 1985, there were approximately 500 referred articles published on dental implants. Between the years 1985 and 1995, there were more than 1500 articles published on dental implants. More recently, from 1995 to 2005, there were over 5000 articles published in referred journals on topics related to dental implants. Today, the dental implant is now accepted as a primary method to replace a single tooth or multiple adjacent missing teeth, or to support a removable or fixed prosthesis for a completely edentulous patient.

In the United States, the total sales of implant products to the dental profession from 1950 to 1985 was less than \$1 million each year, and from 1985 to 1995 the sales increased to \$100 million per year. The sale of implant-related products from 1995 to 2005 skyrocketed to \$1 billion per year, and today is estimated at \$4 billion each year. However, this dramatic increase in sales has a downside. The rapid growth of dental implants as man-made abutments to replace missing teeth has caused technology to develop quickly and often without guidelines for evaluation. The driving force behind implant treatment should not be directed by dental advertising from manufacturers. Procedures should be based on scientific and clinical studies to determine what is predictable.

Implant dentistry has become a vital part of prosthodontics for partially and completely edentulous patients. All U.S. dental undergraduate programs and all U.S. specialty programs in prosthodontics must teach implant prosthetics to gain accreditation by their governing bodies. Several dental schools now

recommend that almost all mandibular dentures be retained by implants and that three-unit fixed prostheses may be replaced by single-tooth implants. More than 90% of all U.S. general dentists have restored implants or referred a patient for an implant prosthesis. However, most dentists who perform implant restorations have not completed a structured, supervised program specific for implant prostheses. Instead, the implant is restored in a similar scenario as natural teeth. However, although only a minority of practitioners take the time and effort to learn all aspects of this rapidly growing and evolving field, the majority of dentists can provide various aspects of implant treatment.

The good news is that dental implant restorations have the highest survival rate compared with any other type of prosthesis to replace missing teeth. They do not decay or require endodontic treatment. They are also less prone to fracture and resist periodontal-like disease better than a tooth. The bad news is that the treatment plan, the fabrication of the restoration, the occlusion, the maintenance, and the treatment of complications (such as screw loosening, crestal bone loss, prosthesis fracture, or implant failure) are most often unique to implant dentistry.

The second edition of *Dental Implant Prosthetics* addresses the science and discipline of implant dentistry. Compared to the first edition, this book has nearly doubled in size and has added new chapters in treatment planning and implant prosthetics. In addition, more than 2000 illustrations have been used to detail related concepts.

An underlying theme of *Dental Implant Prosthetics* is to base the treatment of missing teeth on the sciences related to implant dentistry. This book does not attempt to be an encyclopedia of all that is possible in the restoration of an implant patient. Instead, it is a text that relates one chapter to every other chapter and presents a common thread of science and past experience to the art of replacing teeth. Every chapter is carefully blended to be consistent in purpose: to provide a predictable outcome.

The first part of *Dental Implant Prosthetics* sets the stage for understanding the importance of implants to a dental restorative practice. The second part of the book covers the related basic sciences of biomechanics and biomaterials, exploring why biomechanics should be used as a basis of implant treatment planning as a way to reduce complications. Implant dentistry does not guarantee a result, nor is it without complications. However, there is a consistent theme to reduce and eliminate many complications, and this theme starts with a biomechanically based treatment plan.

Implant treatment planning, the focus of the third part of this book, has been expanded in this edition. More than 50 implant dental criteria may influence treatment planning and prognosis. A generic seven-step process for treatment planning is presented. Chapters in this part look at stress treatment theorem for implant dentistry, prosthetic options, force factors, bone density, implant body size, preimplant prosthodontics, and diagnostic casts, surgical templates, and provisionalization.

<sup>1</sup>Hunter W: The role of sepsis and antisepsis in medicine, *Dent Briefs* 16:852, 1911.




The fourth part of this book on special treatment options looks at single tooth replacement and restoration, maxillary posterior edentulism, the edentulous mandible, and maxillary arch implant considerations. The single tooth replacement is often the first introduction to implant dentistry for restoring dentists. The posterior missing single tooth is addressed separately from the anterior missing tooth. The posterior regions missing a single tooth can be the easiest restoration. On the other hand, the maxillary anterior region can be the most difficult treatment to render in implant dentistry. The two extremes are detailed in separate chapters. The completely edentulous patient is a prime candidate for implant prostheses and is the topic of the several chapters in this section. Specific issues related to edentulism are addressed and unique treatment planning concepts are presented in a logical fashion. The principles of implant overdentures with bar and attachment support, retention, and stability are presented. The mandible and maxilla are addressed as separate chapters, since their complications are unique to each other.

Principles for fixed implant restorations are discussed in Part V. These guidelines may be used in almost every implant prosthesis for a partially edentulous patient. In addition, progressive loading is presented for softer bone types and as a concept has matured since I introduced it in the late 1980s. Occlusion also is specifically addressed for both fixed and removable prostheses.

The final part of *Dental Implant Prosthetics* presents the long-term evaluation and maintenance of dental implants.

*Dental Implant Prosthetics* and my other book, *Contemporary Implant Dentistry*, published by Elsevier, have been used over the years as textbooks for dental students, interrelated dental residents, postgraduate programs, implant residents, specialists, and generalists. Their translation into more than 10 languages and their widespread acceptance have provided a thinking process for oral implantology. This most recent edition attempts to help further elevate the science and discipline of implant dentistry and allow predictable treatment to replace missing teeth for the patients we treat and the doctors we train.

## About the Author



Carl E. Misch is a Clinical Professor and Past Director of Implant Dentistry in the Department of Periodontology and Implant Dentistry at Temple University Kornberg School of Dentistry. He is also a past Clinical Professor in the Department of Periodontics/Geriatrics at the University of Michigan School of Dentistry. Dr. Misch is also a past Clinical Professor in the Department of Restorative Dentistry at the University of Detroit–Mercy School of Dentistry. He is also a past Board of Trustee member-at-large for the University of Detroit Mercy School. In addition, he is an Adjunct Professor at the University of Alabama at Birmingham, School of Engineering, Department of Biomechanics. He was Co-Director or Director of the Oral Implantology Residency Program at the University of Pittsburgh School of Dental Medicine from 1986 to 1996.

Dr. Misch graduated *Magna cum laude* in 1973 from the University of Detroit Dental School and received his Prosthodontic Certificate, Implantology Certificate, and Master's Degree in Dental Science from the University of Pittsburgh. He has been awarded two honoris causa PhD degrees, from the University of Yeditepe in Istanbul, Turkey, and Carol Davila University of Medicine and Pharmacy in Bucharest, Romania. Other graduate honors include 13 fellowships in dentistry, including Fellow of the American College of Dentistry, Fellow of the International College of Dentists, Fellow of the International College of Dentists, Fellow of the American Association of Hospital Dentistry, Fellow of the Academy of Dentistry International, and Fellow of the Pierre Fauchard Academy. Dr. Misch has more than 10 patents related to implant dentistry and is the co-inventor of the Biohorizons Dental Implant System.

Dr. Misch is a diplomate and past president of the American Board of Oral Implantology/Implant Dentistry and served as

member of the diplomate examining committee for 7 years. He is a past president of the International Congress of Oral Implantologists, which represents more than 100 countries and is the world's largest implant organization, the American Academy of Implant Dentistry, the Academy of Implants and Transplants, and the American College of Oral Implantologists.

In 1984, Dr. Misch founded the Misch Implant Institute. Currently, training centers for the institute are located in Florida, Michigan, Nevada, and Toronto, Canada. Over the years, the Misch Implant Institute has had training centers in Korea, Italy, Brazil, Japan, the United Kingdom, Monaco and Spain. In the United States and Canada, the Institute has had centers in Florida, Georgia, Maryland, Texas, New York, Illinois, Vancouver, and Montreal. As Director, Dr. Misch has trained more than 5000 doctors in a hands-on yearly forum of education in implant dentistry. Programs are offered in both the surgical and prosthetics aspects of patient care.

Dr. Misch has now edited three editions of *Contemporary Implant Dentistry* and two editions of *Dental Implant Prosthetics*. These five textbooks have been translated into Italian, Korean, Portuguese, Turkish, Spanish, Farsi, Japanese, Chinese (Simplified), Greek, and Russian, and they are used in dental schools around the world for graduate and postgraduate programs. Dr. Misch has published more than 250 articles related to implant dentistry. During the past 30 years, Dr. Misch has lectured more than 1000 times in all 50 states of the United States and in more than 47 countries throughout the world.

Dr. Misch has six children: Paula, Carl, Lara, David, Jonathan, and Angela.

# Acknowledgments

This is the fifth book I have written that shares my experience, training, and knowledge in a discipline to which I have dedicated my life. This process began with my three original mentors: Ken Judy, Leonard I. Linkow, and O. Hilt Tatum. They will always be acknowledged in my lectures, articles, and chapters. Implant dentistry needed early pioneers to blaze the trails for the profession. Their concepts of bone grafting, implant surgery, prosthetics, implant education, and leadership created a foundation 40 to 50 years ago that allowed the profession to build the current structure we have today in implant dentistry. Through the years, all three of these gentlemen have become great friends, and I continue to learn from them. I especially thank each of them for providing their personal continued guidance and support to me over the last 40 years.

There also are many people to acknowledge and thank in preparation of *Dental Implant Prosthetics*, second edition. Allow me to begin with all participating authors: Martha Warren Bidez, Lee Culp, Jack E. Lemons, Michael S. McCracken, Francine Misch-Dietsh, Girish Ramaswamy, Randolph R. Resnik, J. Todd Strong, Jon B. Suzuki, Lynn D. Terracciano-Mortilla, and Natalie Y. Wong. Each co-author was selected for his or her unique additional knowledge. Their dedication to implant dentistry and their friendship and personal support to me is greatly appreciated.

Thank you to Jill Bertelson. Since I hand write every chapter and hand write every chapter edit more than 20 times, she types

and retypes every sentence in this book. She also coordinated the chapters with the publisher.

Each book takes a toll on my immediate family. During this project, my youngest son and daughter, Jonathan and Angela, bore the brunt to the time and pressures to write this book. Thank you for understanding and giving up our personal time.

I also would like to thank Brian Loehr and Kathy Falk of Elsevier/Mosby. Thank you for your patience, experience, and guidance during this process.

Thank you to Heidi Cartegena and Jennifer Luczak, my executive and private assistants, for all the coordination required in organizing this text. I would also like to thank the Dental Laboratory Team: Nemer Hussain, Tom and Beatrice Dabrowsky, LDT, BIT Dental Studios, Dillon, CO. Kim Bradshaw-Sickinger, President and CEO Micro Dental Laboratories (DTI), and Rebecca Caprroso (Tata) my surgical and prosthetic assistant.

The second edition of *Dental Implant Prosthetics* is also a reflection of the five thousand doctors I have trained around the world at the Misch International Implant Institute since 1984. Those doctors contributed by the questions asked and their desire for an organized approach to help their patients. I wish to thank each of them for their professional support.

Carl E. Misch



## Rationale for Dental Implants\*

Carl E. Misch

The goal of modern dentistry is to restore the patient to normal contour, function, comfort, esthetics, speech, and health, whether restoring a single tooth with caries or replacing several teeth. What makes implant dentistry unique is the ability to achieve this goal regardless of the atrophy, disease, or injury of the stomatognathic system.<sup>1</sup> However, the more teeth a patient is missing, the more challenging this task becomes. As a result of continued research, diagnostic tools, treatment planning, implant designs, materials, and techniques, predictable success is now a reality for the rehabilitation of many challenging clinical situations.

The number of dental implants used in the United States increased more than 10-fold from 1983 to 2002, and that number increased another 10-fold from 2000 to 2010. More than 5 million dental implants are inserted each year in the United States. This number continues to increase steadily, with an expected yearly growth sustained at 12% to 15% for the next several years.<sup>2</sup> More than \$1 billion in implant products was sold in the United States in 2010, up from \$550 million of implant products sold in 2005 and compared with \$10 million in 1983. When bone grafting materials are included in implant products, it is estimated the field of implant dentistry in 2010 sold \$10 billion in products to provide services to patients.<sup>3</sup> More than 90% of interfacing surgical specialty dentists currently provide dental implant treatment on a routine basis in their practices, 90% of prosthodontists restore implants routinely, and more than 80% of general dentists have used implants to support fixed and removable prostheses compared with fewer than 50% of specialists and fewer than 25% of general dentists 20 years ago.<sup>4-8</sup>

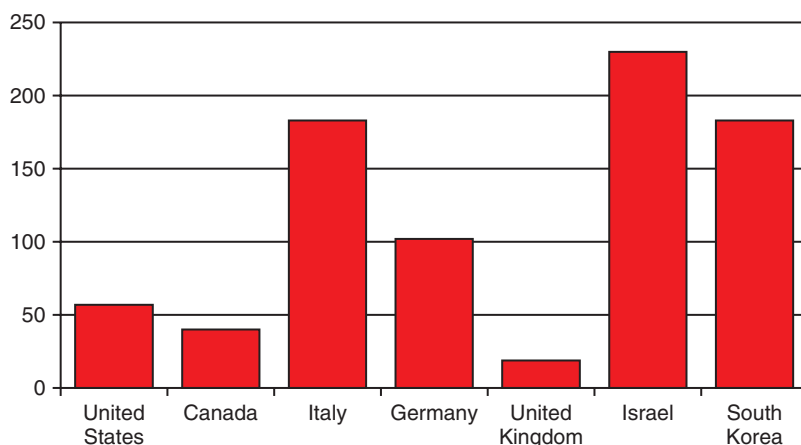
Despite these figures demonstrating implants are incorporated into dentistry more than ever before, there is still much

room for continued growth. Utilization of dental implants varies widely in different countries of the world. For example, it is estimated that the number of implants each year per 10,000 people is 230 for Israel (the greatest number); 180 for South Korea and Italy; 140 for Spain and Switzerland; 100 for Germany; and 60 each for Brazil, the Netherlands, and the United States (Figure 1-1). Japan and France (50), Canada and Australia (40), and Taiwan and United Kingdom at 20 per year use implants less often. The six countries with greatest use of implants (Europe and South Korea) accounted for more than half the total market growth from 2002 to 2007. A long-term growth of 12% to 15% is expected in the future in most countries using implants at this time.

The percentage of teeth replaced with an implant, rather than traditional fixed or removable prostheses, also dramatically varies by country. In Israel, Italy, and South Korea, 30% to 40% of teeth replaced incorporate an implant. In Spain, Switzerland, Germany, and Sweden, 20% to 26% of restorations to replace teeth are supported by an implant. Brazil and Belgium come in at 13% to 16% of restorations use and implant. Surprisingly, the United States, Japan, France, and Canada use implants in 10% or fewer of the teeth replaced.<sup>8</sup> In other words, in a 2011 report, only one of 10 teeth replaced in the United States uses an implant for an abutment (Figure 1-2).

The increased need and use of implant-related treatments in the future result from the combined effect of several factors, including (1) aging population living longer, (2) tooth loss related to age, (3) consequences of fixed prosthesis failure,

\*Note: This chapter is written in terms for dentists, staff, and the lay public.

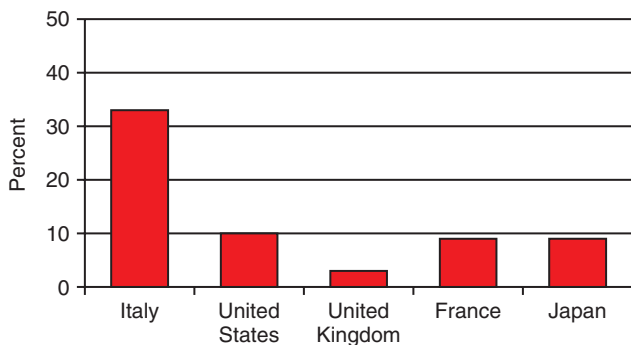


**FIGURE 1-1.** Implant use to replace teeth varies by country. Estimated implant use per 10,000 people per year is greatest in Israel, South Korea, and Italy.

(4) anatomical consequences of edentulism, (5) poor performance of removable prostheses, (6) consequences of removable partial dentures, (7) psychological aspects of tooth loss and needs and desires of aging baby boomers, (8) predictable long-term results of implant-supported prostheses, (9) advantages of implant-supported restorations, and (10) increased public awareness.

### Effects of an Aging Population

According to the literature, age is directly related to every indicator of tooth loss.<sup>9,10</sup> Therefore, the aging population is an important factor to consider in implant dentistry. Although some famous individuals in the past have lived past the age of 80 years (e.g., Ramses II, King Louis XIV), the average life span remained below 40 years until the 18th century. For example, when Alexander the Great conquered the ancient world, he was only 17 years old. However, life expectancy at that time was only 22 years of age. From 1000 BC to 1800 AD, life span remained



**FIGURE 1-2.** Implant versus nonimplant tooth replacement (by %) varies greatly by country. In the United States, only one of every 10 teeth replaced incorporates an implant.

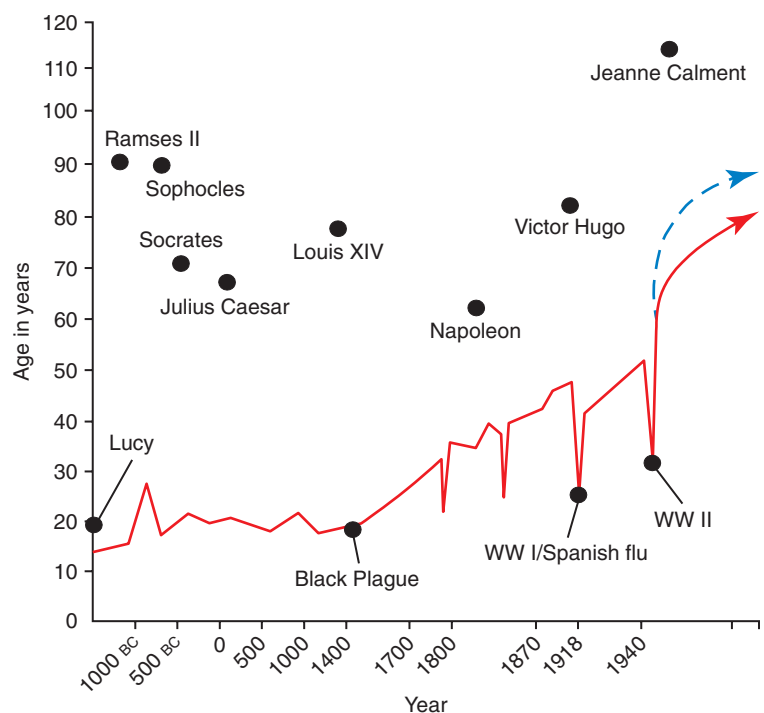
less than 30 years (Figure 1-3). Since 1960, the increase in life expectancy has been more rapid than at any other time in history (Figure 1-4). In 1980, 30% of the U.S. population was older than age 45 years, 21% was older than 50 years, and 11% was older than 65 years. In 1995, 15 years later, these individuals were older than age 60 years. The group older than age 65 years is projected to increase from 12% in 2000 to more than 20% of the population within the next 15 years<sup>11</sup> (Figure 1-5).

In addition, not only is the percentage of the population over 65 years of age increasing, but the overall population is also increasing. The population in 2000 was 282 million and is projected to increase 49% to 420 million by 2050. Considering the effect of both a population increase and a greater percentage of that population being older than age 65 years, a dramatic overall increase in geriatric patient numbers can be expected. In 2003, 35 million people were older than age 65 years. This number is expected to increase 87% by 2025, resulting in almost 70 million people being older than age 65 years in the United States<sup>12</sup> (Figure 1-6). Because older people are more likely to be missing teeth, the need for implant dentistry will dramatically increase over the next several decades.

Life expectancy has increased significantly past the age of retirement. In 1965, the average life span was 65 years; in 1990, it was 78 years. Life expectancy in 2001 was 85 years for a non-smoking individual of normal weight.<sup>13</sup> A 65-year-old woman can now expect to live 25 more years 40% of the time and 30 more years 19% of the time<sup>14-16</sup> (Figure 1-7). Women represent two thirds of the population older than age 65 years and are more likely to use implants to replace their teeth compared with men.<sup>17</sup> It is not unusual for a 70-year-old patient to ask, "Is it worth it for me to spend more than \$30,000 to repair my mouth at my age?" The response should be very positive because the patient's life expectancy may extend for two more decades, and his or her current oral situation will normally become worse if not corrected.

Social pleasures, including dining and dating, continue throughout advanced life. In the past, geriatric dentistry meant

**FIGURE 1-3.** Average life expectancy remained approximately 20 to 30 years for several hundred years of human civilization. Since the late eighteenth century, there has been a gradual increase in life span. (Redrawn from *Le Figaro Magazine*, Paris, 2004.)



inexpensive treatment emphasizing nonsurgical approaches. The poverty rate for elderly adults, however, is less than 10%, and retiree median income has grown 8% in recent years. The median net worth of retirees is 15 times the net worth of those younger than age 35 years and three times as high as “working families” ages 35 to 44 years.<sup>17,18</sup> Close to 20% of today’s retirees have a net worth of more than a quarter of a million dollars.

Today, the full scope of dental services for elderly patients is increasing in importance to both the public and the profession because of the increasing age of our society. Treatment alternatives that consider fixed prostheses with implant support should be presented to almost any patient. Only when all treatment options are discussed can a person’s desires related to the benefit of implant dentistry be truly appreciated.

Dental services for elderly patients clearly represent a growing demand for the dental profession. In 2000, 28.8% of all income

from a dentist came from patients age 60 years and older—a group that represented only 12% of income in 1988. When the dentist is older than age 40 years, income from those older patients represents 64.3% of the dentist’s income; in 1988, it was 30.3%.<sup>19</sup> Clearly, the demographics of our population have dramatically changed the economics of dental practice.

## Age-Related Tooth Loss

### Single-Tooth Edentulism (Single-Tooth Loss)

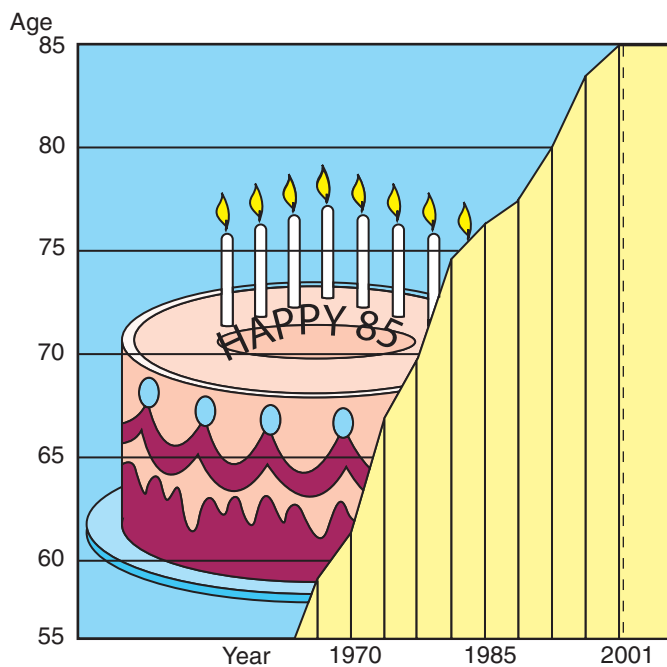
Adult patients often have one or more crowns as a consequence of previous larger restorations required to repair the integrity of the tooth. Longevity reports of crowns have yielded very disparate results. The mean life span at failure has been reported as 10.3 years. Other reports range from a 3% failure rate at 23 years to a 20% failure rate at 3 years. It has been estimated that a \$425 crown for a 22-year-old patient will cost \$12,000 during the patient’s lifetime to replace or repair.<sup>20</sup>

The primary cause of failure of the crown is caries followed by endodontic therapy.<sup>21–29</sup> The tooth is at risk for extraction as a result of these complications, which are the leading causes of single posterior tooth loss in adults (Figure 1-8).

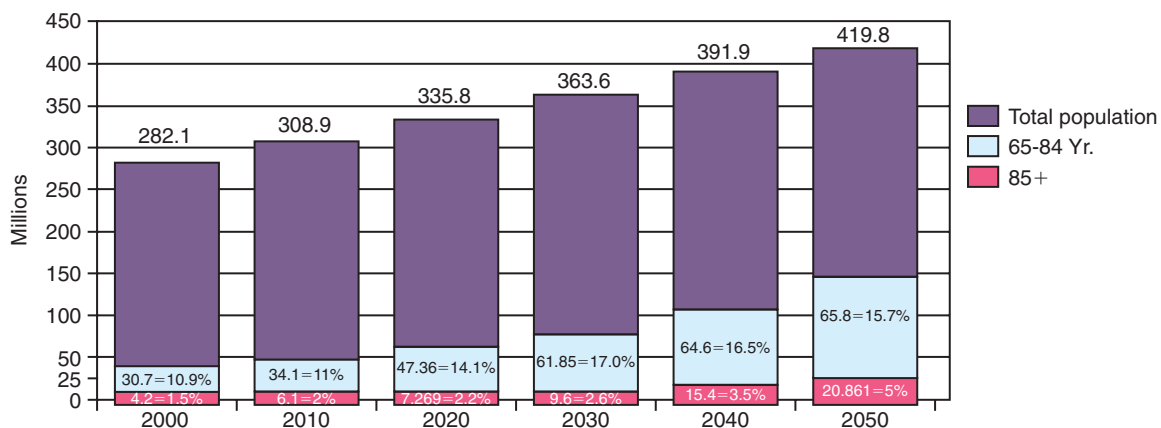
As a consequence, the posterior regions of the mouth often require the replacement of a single tooth.<sup>30–32</sup> The first molars are the first permanent teeth to erupt in the mouth and, unfortunately, are often the first teeth lost as a result of decay, failed endodontic therapy, or fracture (usually after endodontics). They are important teeth for maintenance of the arch form and proper occlusal schemes (Figure 1-9).

### Fixed Partial Dentures (Dental Bridges)

The most common choice to replace posterior missing teeth is a fixed partial denture (FPD). The adjacent teeth next to the missing tooth are prepared, and crowns are inserted that are connected to the missing tooth (pontic) (Figure 1-10). This three-tooth restoration can be fabricated within 1 to 2 weeks and satisfies the criteria of normal contour, comfort, function, esthetics, speech, and health. Because of these benefits, FPD has been the treatment of choice for the past 6 decades. Bone and soft tissue considerations in the missing tooth site in the posterior regions are few. Every dentist is familiar with the procedure, and it is widely accepted by the profession, patients, and dental insurance companies.

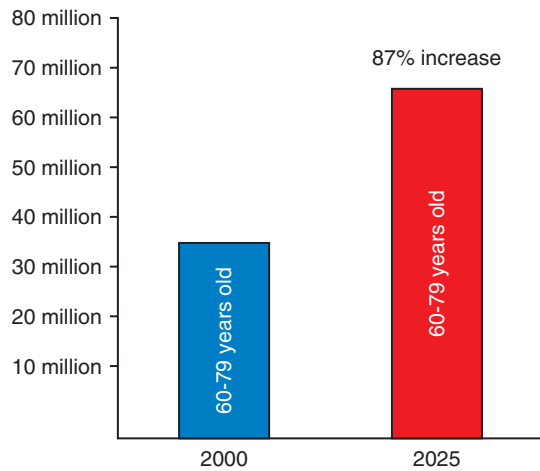


**FIGURE 1-4.** Life expectancy has increased more rapidly since 1960 than at any other time in history. Because tooth loss is directly related to age, a growing number of adults are missing teeth.

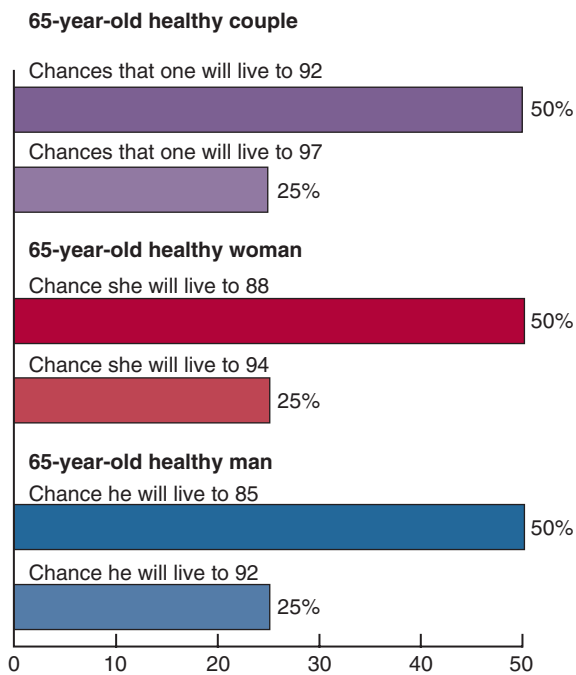


**FIGURE 1-5.** By 2050, 20.7% of the population will be older than age 65 years. In addition to the increasing percentage of 65-year-old adults, the population is also increasing. As a result, 34.9 million people were older than 65 years in 2000, and 86.6 million people will reach this milestone by 2050.





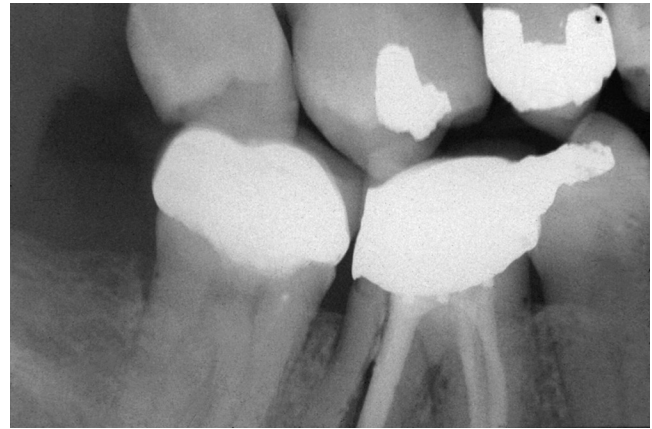
**FIGURE 1-6.** The adult population older than the age of 60 years old will increase by 87% from the year 2000 to the year 2025.



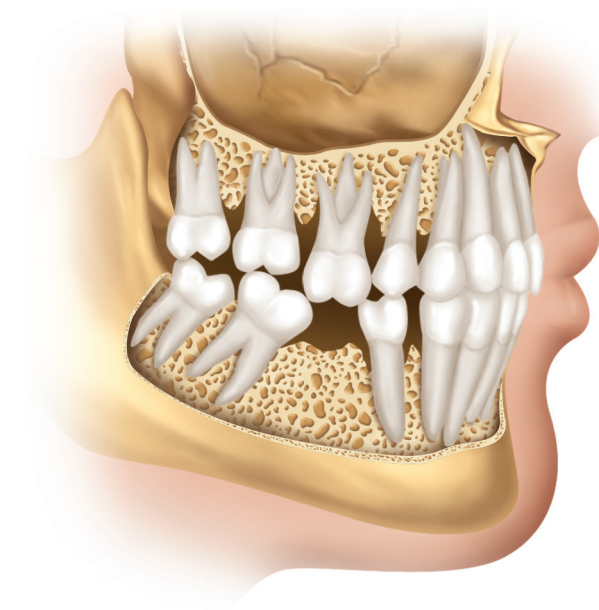
**FIGURE 1-7.** When a person reaches age 65 years, he or she often feels an investment in health is less appropriate. A 65-year-old healthy woman will live 23 more years 50% of the time and 29 more years 25% of the time. Her present oral condition will become worse during this extended time frame if treatment is not rendered.

Almost 30% of the 50- to 59-year-old adults examined in a U.S. National Survey exhibited either single or multiple edentulous spaces bordered by natural teeth. In 1990, more than 4 million FPDs were placed in the United States.<sup>21,22,32</sup> Treatments to replace single teeth with a fixed prosthesis represent 7% of the annual dental reimbursement from insurance companies and more than \$3 billion each year. Less than half of our population in the United States has dental insurance, and of those who do, only 50% of treatment costs are reimbursed. Hence, the entire three-unit FPD costs in the United States may approach more than \$10 billion each year.

A three-unit FPD presents survival limitations to the restoration and, more importantly, to the abutment teeth.<sup>27,29</sup> The survival rate of a FPD is lower than for a single crown



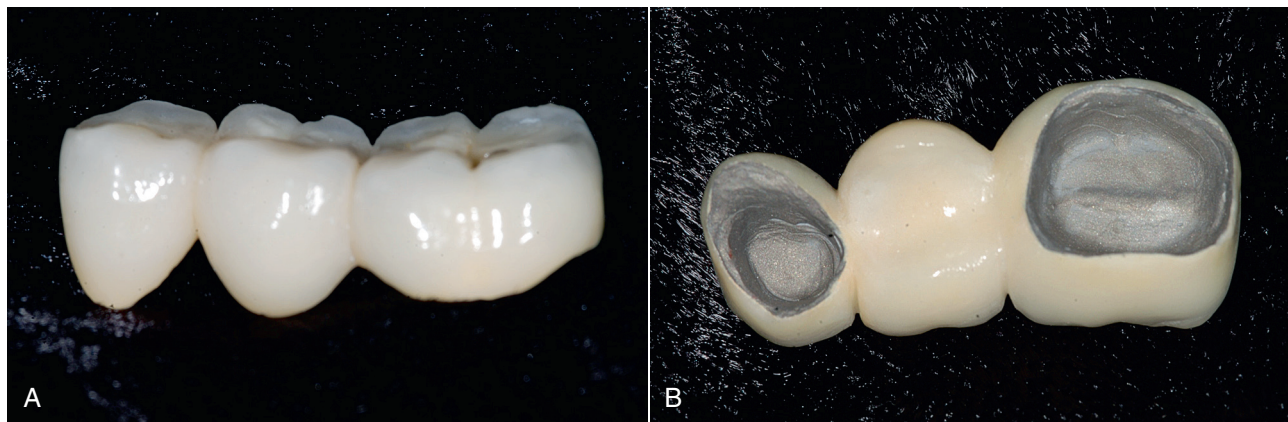
**FIGURE 1-8.** A posterior endodontically treated tooth has an increased risk of failure or fracture compared with a vital tooth.



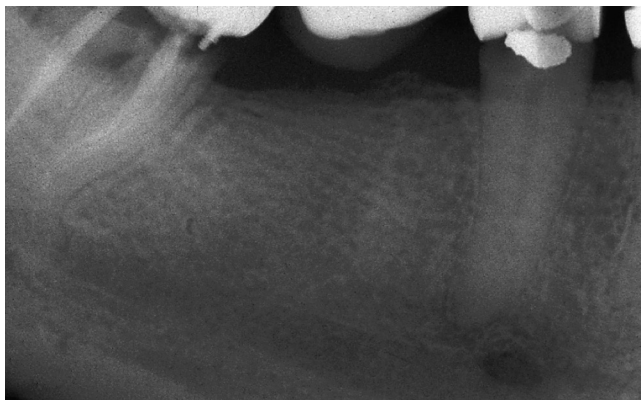**FIGURE 1-9.** A posterior missing tooth is a frequent occurrence in a general practice. The most common single tooth missing is a first molar.

restoration. In an evaluation of 42 reports since 1970, Creugers et al. calculated a 74% survival rate for FPDs for 15 years.<sup>25</sup> Mean life spans of 9.6 to 10.3 years have been reported by Walton et al.<sup>27</sup> and Schwartz et al.,<sup>21</sup> respectively. However, reports are very inconsistent, with as little as 3% loss over 23 years to 20% loss over 3 years.<sup>21-29,32</sup>

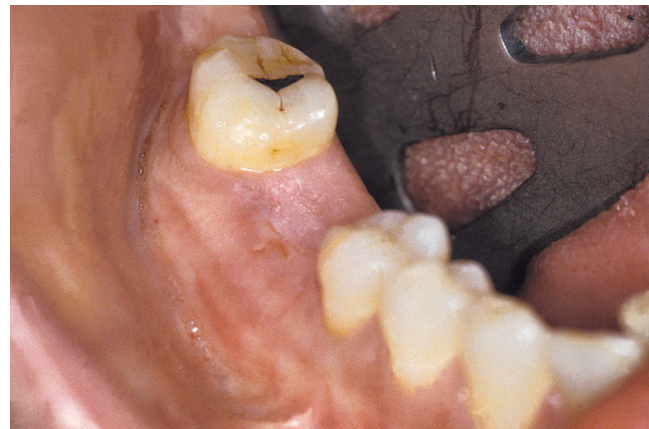The incidence of failure is greater for a FPD compared with a single crown and places the abutment teeth at more risk. Caries (decay) and endodontic (root canal) failure of the abutment teeth are the most common causes of prostheses failure.<sup>27,28</sup> Whereas the caries risk for a crown at 5 years is 1%, the caries risk for a FPD is over 20%. The pontic acts as a plaque reservoir in a FPD and the abutment teeth often decay (Figure 1-11). As a result of structural failure from decay or failed endodontic therapy, the abutment teeth are at increased risk of loss. Up to 15% of abutment teeth for a FPD require endodontic therapy compared with 3% of nonabutment teeth that have crown preparations<sup>25</sup> (Box 1-1). In addition, the prepared and crowned



**FIGURE 1-10.** **A**, A three-unit fixed partial denture is the most common method to replace missing teeth in the posterior regions of the jaws. **B**, To replace the missing teeth, the teeth adjacent to the space are crowned, and the missing tooth is attached to the crowns.



**FIGURE 1-11.** The abutment teeth of a fixed partial denture often decay at the margin next to the pontic because it acts as a plaque reservoir and rarely has adequate daily hygiene.



**FIGURE 1-12.** Almost 80% of the time when a posterior tooth is missing, the adjacent teeth have no or only minimal restorations.

### BOX 1-1 Fixed Partial Denture versus Crown Complications

Caries: 22%–27% vs. 1%  
 Endodontic related (e.g., failure, fracture): 11%–15% vs. 3%  
 Unretained restoration: 7%–11% vs. 2%  
 Porcelain fracture: 7%–10% vs. 3%

abutments may be sensitive to cold from hyperemia related to the trauma of a tooth preparation.

Unfavorable outcomes of FPD failure include both the need to replace the failed prosthesis and the loss of an abutment and the need for additional pontics (replacement teeth) and abutment teeth in the replacement bridge. Approximately 8% to 12% of the abutment teeth holding a FPD are lost within 10 years.<sup>8</sup> The abutment teeth of a FPD may be lost at rates as high as 30% within 14 years.<sup>26</sup> The most common reason for single-tooth loss is endodontic failure or fracture of a tooth (usually after endodontic therapy). Because 15% of abutment teeth require endodontics and root canal therapy may have a 10% failure rate at the 8-year mark, abutment teeth are at increased risk of loss.

### BOX 1-2 Single-Tooth Replacement—Fixed Partial Denture

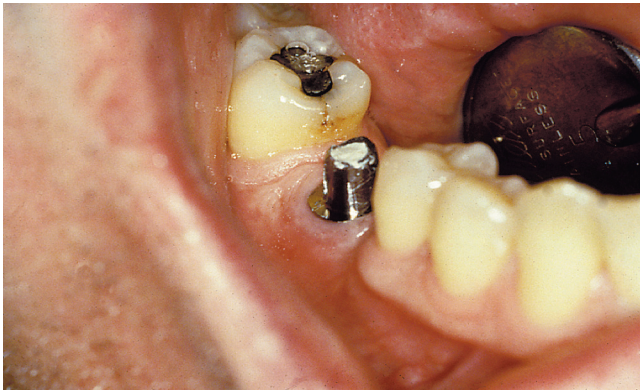
- Estimated mean life span of a fixed partial denture (FPD) (50% survival) is reported at 15 years
- Caries and endodontic problems are the most common causes of FPD failure (>20%)
- Loss of FPD abutment teeth at 8% to 12% within 10 years and 30% within 15 years
- 80% of teeth adjacent to missing teeth have no or minimal restoration

Almost 80% of abutments prepared for a three-unit FPD have no existing or only minimal restorations<sup>33,34</sup> (Figure 1-12). Rather than removing sound tooth structure and crowning two or more teeth—thus increasing the risk of decay and endodontic therapy (and splinting teeth together with pontics, which have the potential to cause additional tooth loss)—a dental implant may replace the single tooth (Box 1-2).

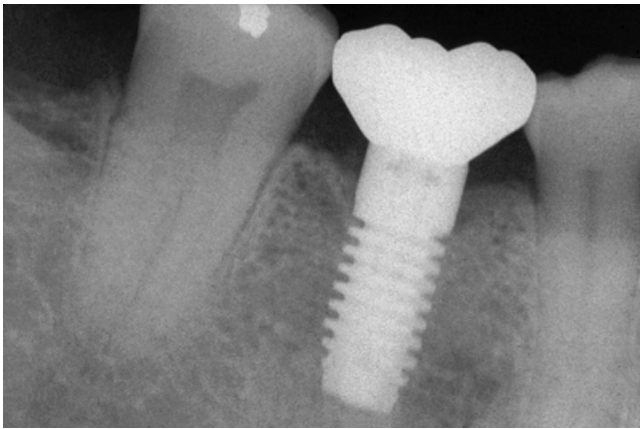
### Single-Tooth Implants

A primary treatment option to replace a posterior single missing tooth is a single-tooth implant (Figure 1-13). For years, patients





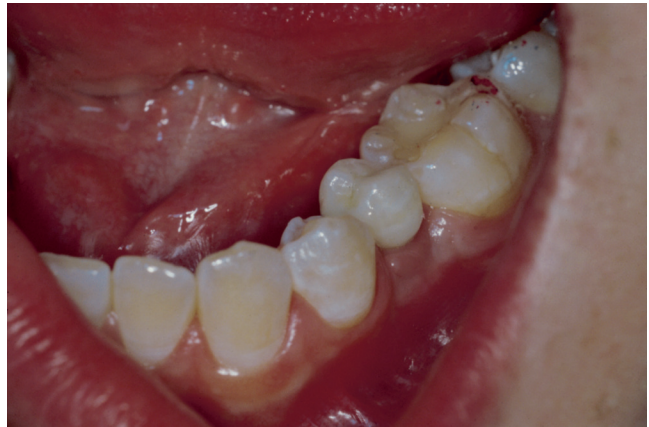**FIGURE 1-13.** A single-tooth implant in the posterior region of the mouth is most often the treatment of choice.



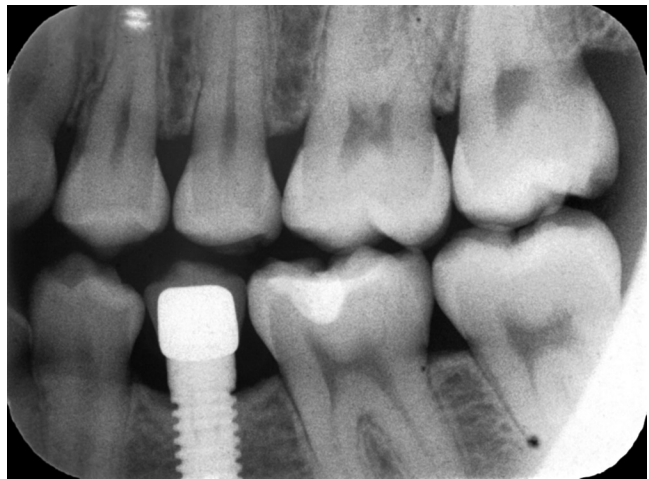
**FIGURE 1-14.** A single-tooth implant to replace a missing tooth has the highest success rate, and the adjacent teeth are less likely to decay, require endodontics, or result in additional tooth loss.

were advised to put their desires aside and accept the limitations of a FPD. However, many believe the most natural method to replace a tooth is to use an implant rather than preparing adjacent teeth and joining them together with a prosthesis. The primary reasons for suggesting the FPD were its clinical ease, reduced cost, and reduced treatment time. However, if this concept were expanded, extractions would replace endodontics, and removable partial dentures would be used instead of fixed prostheses. The primary reason to suggest or perform a treatment should not be related to treatment time, costs, or difficulty of the procedure but instead should consider the best possible long-term solution for each individual.

From 1993 to the present, single-tooth implant survival reports have validated this procedure as the most predictable method of tooth replacement. There are more refereed reports in the literature for single-tooth implant replacement than for any other method of tooth replacement,<sup>35</sup> and all reports demonstrate a higher survival rate for single-tooth implants. In 1995, Haas et al. reported on 76 single-tooth implants over a 6-year period and found a 97% survival rate and a 2.6% implant loss.<sup>36</sup> Fugazzotto evaluated 1472 implants over a 13-year period and found a 97% survival rate during that period.<sup>37</sup> In 2008, Misch et al. reported on more than 1300 implants over a 10-year period and found over a 99% survival rate.<sup>34</sup> As important, the adjacent teeth survival and restoration rate was greater than with any other treatment method to replace a tooth (Figure 1-14).



**FIGURE 1-15.** A postoperative picture of a 10-year-old single-tooth implant replacing the second premolar.



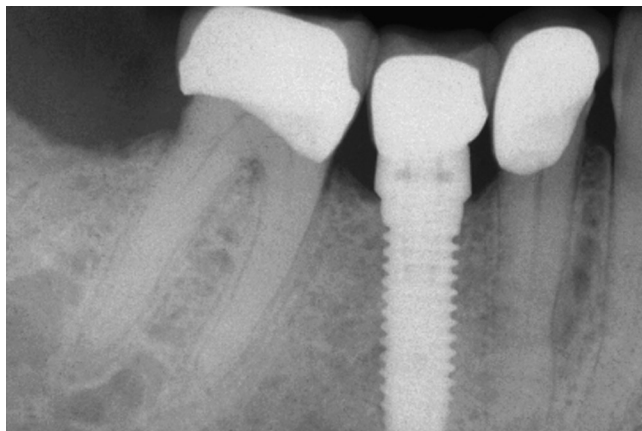
**FIGURE 1-16.** A bitewing radiograph of a single tooth implant after 10 years. The adjacent teeth had no additional restoration during this time frame.

Goodacre et al. performed a Medline literature review from 1980 to 2001 and found the single-tooth implant success rate to be in the range of 97%—higher than any other implant restoration.<sup>35</sup> In comparison, FPD failure rates may be as high as 20% within 3 years, and 50% rates at 10 to 15 years are expected. As a result, the single-tooth implant exhibits the highest survival rates presented for single-tooth replacement. As important, reports indicate less restoration or loss of an adjacent tooth, which is a considerable advantage<sup>33,34</sup> (Figures 1-15 and 1-16). Despite some limitations and obvious clinical challenges, the single-tooth implant represents the treatment of choice from both a health and value standpoint.<sup>38</sup>

When adjacent teeth are healthy or when the patient refuses their preparation for the fabrication of a traditional three-unit fixed partial restoration, a posterior single-tooth implant is an excellent solution. Health-related advantages of this modality over a fixed partial restoration are listed in Box 1-3 and include a decreased risk of decay and periodontal disease, decreased risk of abutment tooth loss from endodontic failure or caries, and improved esthetics (because the adjacent teeth may remain unrestored). In fact, even when the adjacent teeth require crowns, a single-tooth implant is often the treatment of choice because a crown decays less often than abutments for a FPD

**BOX 1-3 Single-Tooth Implants—Advantages**

- High success rates (above 97% for 10 years)
- Decreased risk of caries of adjacent teeth
- Decreased risk of endodontic problems on adjacent teeth
- Improved ability to clean the proximal surfaces of the adjacent teeth
- Improved esthetics of adjacent teeth
- Improved maintenance of bone in the edentulous site
- Decreased cold or contact sensitivity of adjacent teeth
- Psychological advantage
- Decreased risks of adjacent tooth loss



**FIGURE 1-17.** Even when teeth adjacent to the missing tooth require crowns, an implant is the treatment of choice because single crowns on teeth adjacent to implants have fewer complications and increased longevity compared with abutments for a three-unit fixed partial denture.

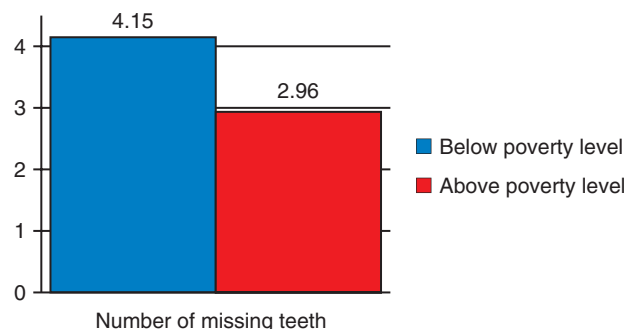
(Figure 1-17). Psychological advantages, especially with congenitally missing teeth or the loss of a tooth after a crown restoration, are significant as well. These advantages are so significant to the health and periodontal condition of the adjacent teeth and maintenance of the arch form that the single-tooth implant has become the treatment of choice in most situations.

Economic considerations may play in disfavor of the implant restoration only during the first several years. Compared with a FPD, a single-tooth implant becomes more advantageous economically, not only for health considerations but also financially after the break-even point of 7 years, at which time the patient will not need a replacement prosthesis. As a result, the future savings will offset the initial higher cost, especially because the adjacent teeth are more likely to survive longer and replacement of a restoration is unnecessary.<sup>39,40</sup>

### Partial Edentulism (Tooth Loss)

The prevalence of partial edentulism is also of interest because a growing number of implants are used in these patients. A 1988 to 1991 survey in the United States found that only 30% of patients had all 28 teeth. Partially dentate patients had an average of 23.5 teeth.<sup>9,32,41</sup> In the 1999 to 2004 follow-up survey, the average number of missing teeth was fewer than two of 28 teeth for the 20- to 39-year-old group. However, this number rapidly increased to an average of nine teeth missing in adults older than age 60 years.<sup>42</sup> The average missing teeth in the

**Missing teeth USA adults  
(1999-2004) ages 20-64 years**



**FIGURE 1-18.** The number of teeth missing in the U.S. adult population is not affected very much by economic factors.

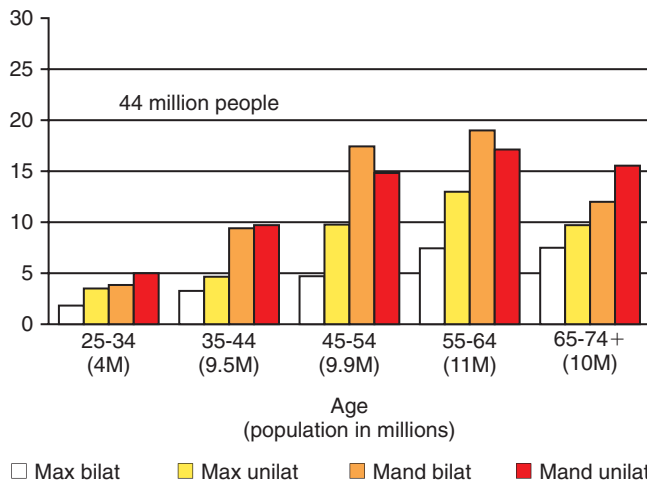
population below the poverty level was four teeth compared with three missing teeth above the poverty level (Figure 1-18). Hence, income was not a major factor for the number of teeth loss. Partially edentulous seniors older than age 60 years have lost an average of 10 teeth, with older seniors having lost three more teeth than the younger seniors. Statistics for partial edentulism are similar for both men and women.

The greatest transition from an intact dental arch to a partially edentulous condition in the 1987 study occurred in the 35- to 54-year-old group.<sup>19,32</sup> The growth rate of this portion of the population was approximately 30% in 1982 and is continuing to increase, more than any other age group. For example, in 1982, this 35- to 54-year-old group increased from 39 million Americans to 79 million in 2005. Although the number of teeth missing per patient may seem to decrease, the overall number of missing teeth will continue to increase as a result of the aging population. Therefore, the need for implant services in partially edentulous patients will dramatically increase during the next several decades.<sup>14</sup>

The most common missing teeth are molars.<sup>31</sup> Partial free-end edentulism is of particular concern because in these patients, teeth are often replaced with removable partial prostheses. This condition is rarely found in persons younger than age 25 years. Mandibular free-end edentulism is greater than its maxillary counterpart in all age groups. Unilateral free-end edentulism is more common than bilateral edentulism in both maxillary and mandibular arches in the younger age groups (ages 25 to 44 years). About 13.5 million persons in these younger age groups have free-end edentulism in either arch (Figure 1-19).

In 45- to 54-year-old patients, 31.3% have mandibular free-end edentulism, and 13.6% have free-end edentulism in the maxillary arch. Approximately 9.9 million persons in the 45- to 54-year-old group have at least one free-end edentulous quadrant, and almost half of these have bilateral partial edentulism.<sup>10</sup> The pattern of posterior edentulism evolves in the 55- to 64-year-old group, in whom 35% of mandibular arches show free-end edentulism compared with 18% of maxillary arches. As a result, approximately 11 million individuals in this age group are potential candidates for implants. An additional 10 million show partial free-end edentulism at age 65 or older.

Additional studies have documented that in the population of noninstitutionalized U.S. civilians, one of five had a removable prosthesis of some type.<sup>43-45</sup> The total number of potential patients in the U.S. survey with at least one quadrant of



**FIGURE 1-19.** There are more than 44 million people in the United States missing at least one quadrant of posterior teeth (most often in the mandible).

posterior missing teeth is more than 44 million people.<sup>10</sup> If each of these arches requires three implants to support a fixed prosthesis, 132 million implants would be required.

### Removable Partial Dentures

Removable soft tissue-borne partial dentures have one of the lowest patient acceptance rates in dentistry. Half of patients with a removable partial denture chew better without the device. A 44-year Scandinavian study revealed that only 80% of patients were wearing such prostheses after 1 year. The number further decreased to only 60% of the free-end partial dentures worn by the patients after 4 years. This rate was reduced to only 35% at 10 years.<sup>46-50</sup> In another study, few partial dentures survived more than 6 years.<sup>51</sup> Although one of five U.S. adults have worn a removable dental prosthesis of some type, 60% reported at least one problem with it.<sup>44</sup>

Reports of removable partial dentures indicate the health of the remaining dentition and surrounding oral tissues often deteriorates.<sup>46,52</sup> In a study that evaluated the need for repair of an abutment tooth as the indicator of failure, the “success” rates of conventional removable partial dentures were 40% at 5 years and 20% at 10 years.<sup>48</sup> Patients wearing the partial dentures often exhibit greater mobility of the abutment teeth, greater plaque retention, increased bleeding upon probing, higher incidence of caries, speech inhibition, taste inhibition, and non-compliance of use.<sup>49-52</sup> A report by Shugars et al. found abutment tooth loss for a removable partial denture may be as high as 23% within 5 years and 38% within 8 years.<sup>26</sup> Aquilino et al. reported a 44% abutment tooth loss within 10 years for a removable partial denture<sup>53</sup> (Box 1-4).

The natural abutment teeth, on which direct and indirect retainers are designed, must submit to additional lateral forces. Because these teeth are often compromised by deficient periodontal support, many partial dentures are designed to minimize the forces applied to them. The result is an increase in mobility of the removable prosthesis and greater soft tissue support. These conditions protect the remaining teeth but accelerate the bone loss in the edentulous regions.<sup>54</sup> It should be noted that bone loss is accelerated in the soft tissue support regions in patients wearing the removable device compared with the case in patients not wearing the device (Figure 1-20).

### BOX 1-4 Problems with Removable Partial Dentures

- Low survival rate—60% at 4 years
- 35% survival rate at 10 years
- Repair of abutment teeth rate—60% at 5 years and 80% at 10 years
- Increased mobility, plaque, bleeding upon probing, and caries of abutment teeth
- 44% abutment tooth loss within 10 years
- Accelerated bone loss in edentulous region if wearing removable partial denture

Therefore, alternative therapies that improve oral conditions and maintain bone are often warranted.

### Total Edentulism

Complete edentulism is not an eventual, healthy occurrence in an adult population. Rather, it is most often the result of repeated tooth extractions from the combined pathologic processes of dental caries, periodontal disease, or a method to reduce the costs associated with dental treatment.<sup>55-57</sup> Similar to other pathologic outcomes of disease, the occurrence of total loss of teeth is directly related to the age of the patient. The rate of edentulism increases by 4% per 10 years in early adult years and increases to more than 10% per decade after age 70 years.<sup>57</sup>

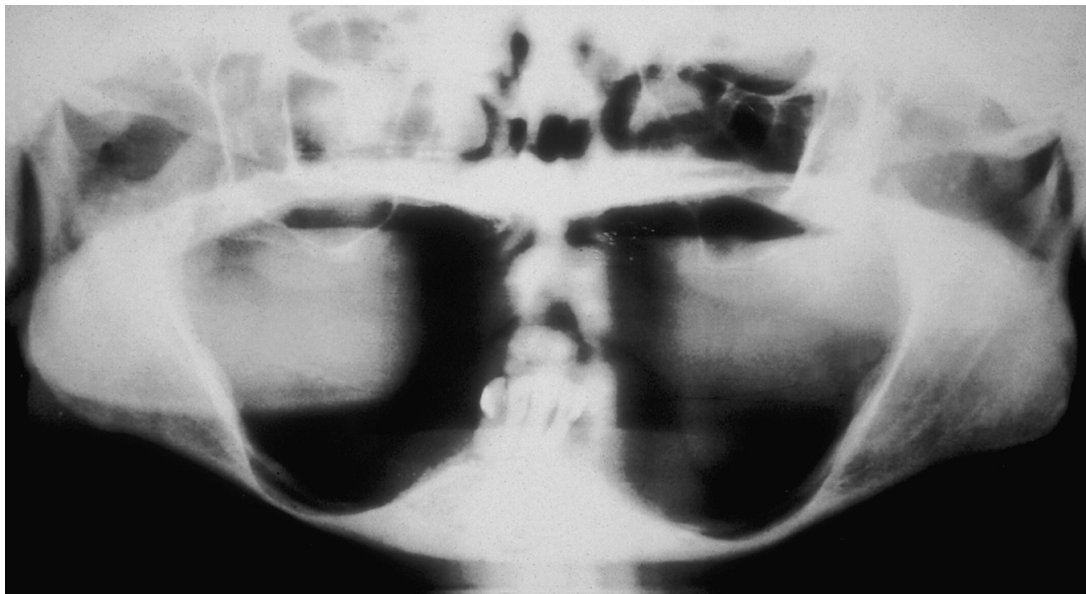
The average total edentulous rate around the world is 20% of the adult population at age 60 years, although there is wide disparity from the countries with the highest and lowest rates.<sup>57</sup> For example, from the 65- to 74-year-age group, the total edentulous rate in Kenya and Nigeria was 4%, but the Netherlands and Iceland have a 65.4% and 71.5% rate, respectively. The edentulous Canadian rate was 47% at 65 to age 69 years and 58% from ages 70 to 98 years (with Quebec at 67% for those older than age 65 years compared with Ontario with a 41% rate).

One of the factors influencing total edentulism is the level of education. In data from the Canadian Health Promotion Survey from 1990, whereas the least educated population had an edentulous rate of 50%, those with a college education had a low 4% rate.<sup>58</sup> The United States showed a similar pattern in the period 1988 to 1994, with an edentulous rate of 22% for those with less than 8 years of education, 12% for those with 9 to 11 years of school, 8% for those with 12 years of school, and 5% for individuals with more than 12 years of education.<sup>41</sup>

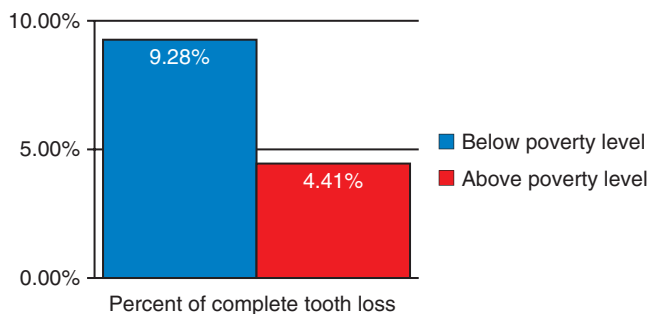
Although income is often related to education, it plays less of a role in the rate of edentulism. The complete tooth loss in the U.S. adult below the poverty level from 1999 to 2004 was 9.28% and 4.41% above the poverty level, only a 5% difference (Figure 1-21). Countries with higher income levels do not necessarily have less tooth loss. For example, whereas Iceland and the Netherlands have the greatest complete tooth loss by age 70 years with a gross domestic product (GDP) of \$17,000, Kenya and Gambia have one of the least complete edentulism rate with a GDP of less than \$2500 (Figure 1-22). An interesting note is that an increasing number of dentists in a country (per 10,000 inhabitants) does not reduce the complete edentulous rate. In fact, countries with the most dentists often have a higher complete edentulous rate (Figure 1-23).

A 1999 to 2002 survey found that total edentulism in the United States of both arches occurred in 7.7% of the adult





**FIGURE 1-20.** Panoramic radiograph demonstrating that more bone is maintained below the anterior periodontal diseased teeth compared with the basal bone loss and severe atrophy of the posterior edentulous segment. Wearing of a mandibular class I removable partial denture has escalated the posterior bone loss. Even periodontal involved teeth may maintain more bone than a removable partial denture because the denture may cause basal bone loss.



**FIGURE 1-21.** Complete edentulism in the United States averages over 9% in the 20- to 64-year-old age group below the poverty level and 4.4% above the poverty level, a difference of less than 5%.

population in the United States, or almost 20 million people.<sup>41</sup> The present younger population is benefiting from today's advanced knowledge and restorative techniques. Total edentulism has been noted in 5% of employed adults ages 40 to 44 years, gradually increasing to 26% at age 65 years and almost 44% in seniors older than age 75 years<sup>9</sup> (Figure 1-24). As expected, older persons are more likely to be missing all their teeth. Gender was not found to be associated with tooth retention or tooth loss after adjustments were made for age.

The maxillary (upper) arch may be completely edentulous, opposing at least some teeth in the mandible (lower jaw). This condition occurs 35 times more often than the reverse situation. At age 45 years, 11% of the population has maxillary total edentulism opposing teeth, which increases to 15% by 55 years of age and then remains relatively constant.<sup>45</sup> Therefore, a total of approximately 12 million individuals in the United States have total edentulism in one arch, representing 7% of the adult population overall.

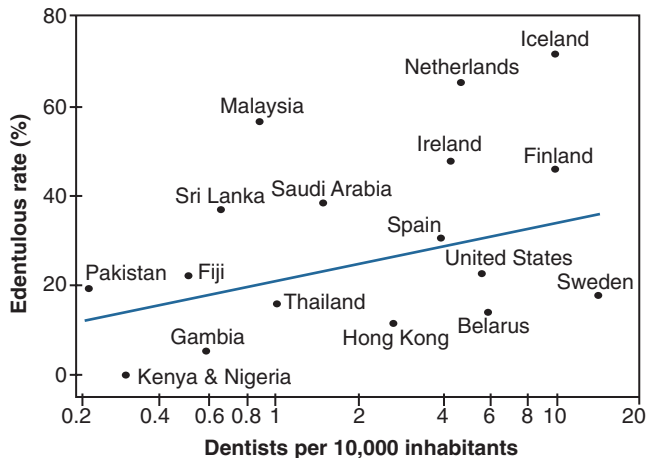
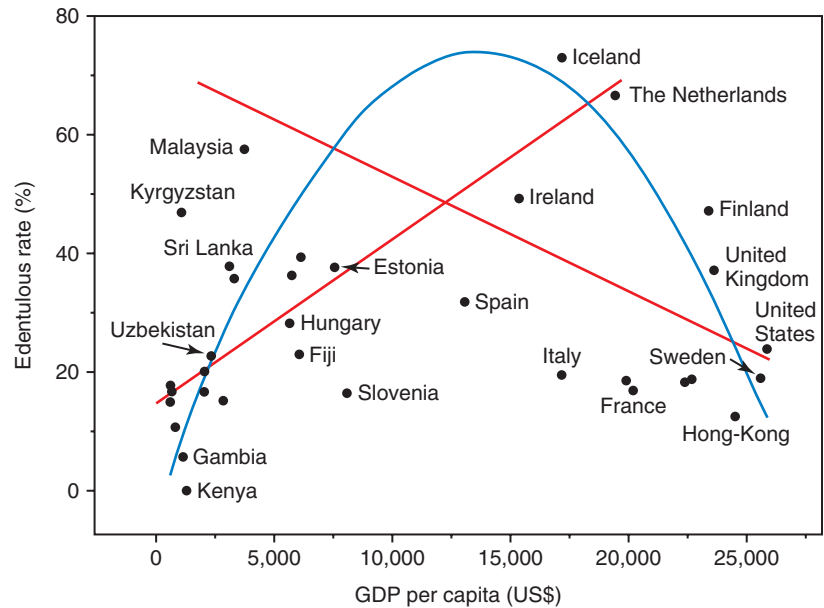
The percentages of one or two arch total edentulism translate into more than 30 million people or about 17% of the entire

U.S. adult population.<sup>45</sup> To put these numbers in perspective, 30 million people represent approximately the entire U.S. African American population, the U.S. Hispanic population, the whole population of Canada, or the total population in the United States older than 65 years of age.

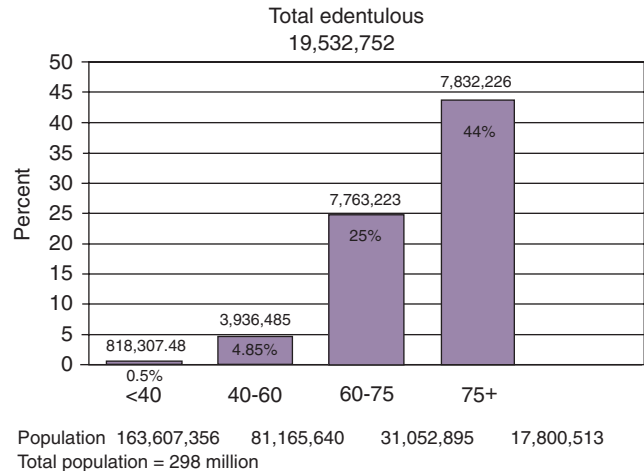
Although the edentulism rate is decreasing every decade, the elderly population is rising so rapidly that the adult population in need of one or two complete dentures will actually *increase* from 33.6 million adults in 1991 to 37.9 million adults in 2020. The total numbers of edentulous arches are estimated at 56.5 million in 2000, 59.3 million in 2010, and 61 million in 2020.<sup>59</sup> Complete edentulism, therefore, remains a significant concern, and affected patients often require implant dentistry to solve several related problems. If four implants were used to help support each complete edentulous arch, a total of 226 million implants would be required. Yet only 10 million implants were inserted in 2010 for all patient treatment. Almost 70% of dentists spend less than 1% to 5% of their treatment time on edentulous patients, leaving a great unfulfilled need for implant dentistry.

When the posterior partially edentulous figures are added to the complete edentulous percentages, more than 30% of the adult U.S. population are candidates for a complete or partial removable prosthesis. The need for additional retention, support, and stability and the desire to eliminate a removable prosthesis are common indications for dental implants. As a result, 74 million adults (90 million arches) are potential candidates for dental implants. Because a minimum of five appointments is required to implant and restore a patient, every U.S. dentist would need approximately 20 appointments every month for 20 years to treat the present posterior partial and complete edentulous population with implant-supported prostheses.<sup>60</sup> The population's evolution to an increased average age, combined with the existing population of partially and completely edentulous patients, guarantees implant dentistry's future for several generations of dentists.

**FIGURE 1-22.** Gross domestic product (GDP) around the world is not related to the edentulous rate. Many of the richest countries have a greater rate of complete edentulism by 70 years of age than the poorer countries.



**FIGURE 1-23.** The incidence of complete edentulism averages 20% of the adult population around the world. It is interesting to note that often the greater the number of dentists per population, the greater the rate of edentulism. (Adapted from Mojon P: The world without teeth: demographic trends. In Feine JS, Carlsson GE, editors: *Implant overdentures: the standard of care for edentulous patients*, Carol Stream, IL, 2003, Quintessence.)



**FIGURE 1-24.** The U.S. population completely edentulous rate ranges from 0.5% for 40-year-old adults to 44% for those older than age 75 years. As a result, 20 million people (10.5% of the population) in the United States have no teeth. An additional 12 million people (7% of the adult population) have no maxillary teeth opposing at least some mandibular teeth.

## Anatomical Consequences of Edentulism

There are many negative consequences for completely edentulous patients. They include continued bone loss of the jaws, soft tissue consequences that support the prostheses, facial esthetic consequences of the bone loss, decreased masticatory performance, and diet-related health issues and psychological aspects of a total tooth loss (Box 1-5).

### Bone Loss

Basal bone forms the dental skeletal structure, contains most of the muscle attachments, and begins to form in the fetus before teeth develop. Alveolar bone (bone around teeth) first appears when Hertwig's root sheath of the tooth bud evolves<sup>61</sup> (Figure 1-25). The alveolar bone does not form in the absence of

## BOX 1-5 Consequences of Complete Edentulism

- Continued bone loss of the jaws
- Negative soft tissue changes of the jaws
- Negative facial esthetic changes
- Decreased masticatory dynamics
- Negative diet effects on health
- Psychological issues

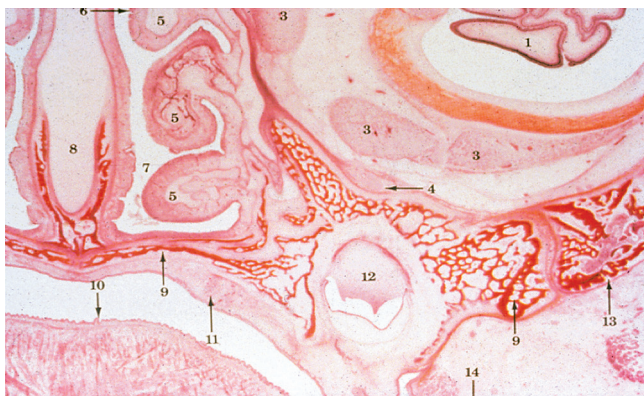primary or secondary tooth development (Figure 1-26). The close relationship between the tooth and the alveolar process continues throughout life.

Wolff's law (1892) states that bone remodels in relationship to the forces applied.<sup>62</sup> Every time the function of bone is

modified, a definite change occurs in the internal architecture and external configuration.<sup>63</sup> In dentistry, the consequences of complete edentulism and remaining bone volume was noted by J. Misch in 1922, when he described the skeletal structure of a 90-year-old woman without teeth for several decades<sup>64</sup> (Figure 1-27).

Bone needs stimulation to maintain its form and density. Roberts et al. report that a 4% strain to the skeletal system maintains bone and helps balance the resorption and formation phenomena.<sup>65</sup> Teeth transmit compressive and tensile forces to the surrounding bone. These forces have been measured as a piezoelectric effect in the imperfect crystals of durapatite that compose the inorganic portion of bone.<sup>66</sup> When a tooth is lost, the lack of stimulation to the residual bone causes a decrease in trabeculae and bone density in the area, with loss in external width, then height, of the bone volume.<sup>67</sup> There is a 25% decrease in width of bone during the first year after tooth loss and an overall 4-mm decrease in height during the first year after extractions for an immediate denture.<sup>68</sup> In a longitudinal 25-year study of edentulous patients, lateral cephalograms demonstrated continued bone loss during this time span, with a fourfold greater loss observed in the mandible.<sup>69,70</sup> In 1963, Atwood introduced five different stages of bone loss in an anterior mandible after tooth loss<sup>71</sup> (Figure 1-28). However, because initially the mandibular height of bone is twice that of the maxilla, maxillary bone loss is also significant in long-term edentulous patients.

A tooth is necessary for the development of alveolar bone, and stimulation of this bone is required to maintain its density



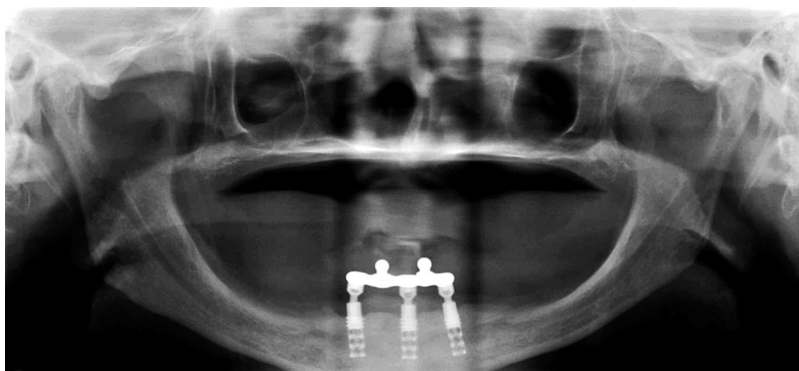
**FIGURE 1-25.** The alveolar bone forms as a result of the formation of Hertwig's root sheath, which forms the tooth root.

and volume. A removable denture (complete or partial) does not stimulate and maintain bone; rather, it accelerates bone loss. Even periodontally involved teeth stimulate and maintain bone volume better than missing teeth and replacement with a removable partial denture (see Figure 1-20). The load from mastication of a soft tissue prosthesis is transferred to the bone surface only, not the bone structure. As a result, blood supply is reduced and total bone volume loss occurs.<sup>70</sup> This issue, which is of utmost importance, has been observed but not addressed in the past by traditional dentistry.

Dentists most often overlook the insidious bone loss that will occur after tooth extraction. The patient is often not educated about the anatomical changes and the potential consequences of continued bone loss. The bone loss accelerates when the patient wears a poorly fitting soft tissue-borne prosthesis. Patients do not understand that bone is being lost over time and at a greater rate beneath poorly fitting dentures. Patients do not return for regular visits for evaluation of their condition; instead, they return after several years when denture teeth are worn down or can no longer be tolerated. In fact, the average denture wearer sees a dentist every 14.8 years after having a complete denture. Hence, the traditional method of tooth replacement (dentures) often affects bone loss in a manner not sufficiently considered by the dentist and the patient. The doctor should inform the patient that a denture replaces more bone and soft tissue than teeth, and every 5 years a relines or new denture is suggested to replace the additional bone loss by atrophy that will occur (Figure 1-29).

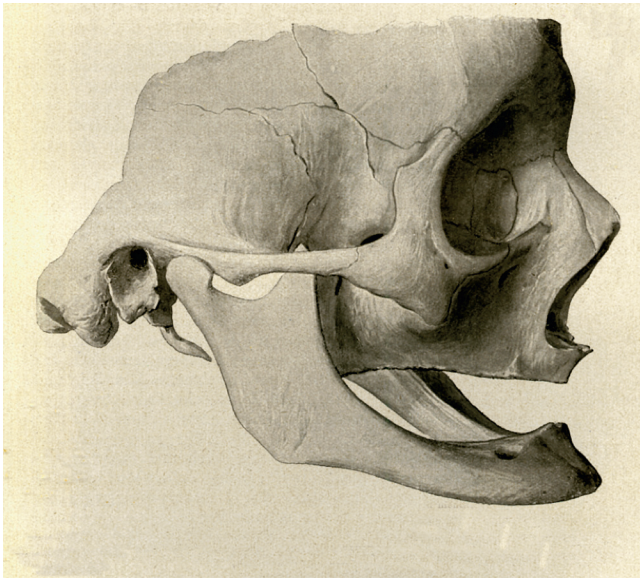
Preventive dentistry has traditionally emphasized methods to decrease tooth loss or the surrounding bone supporting a tooth. This bone loss is often monitored by the millimeter. No therapy had been promoted and accepted by the profession to avoid the bone changes resulting from tooth loss. The bone changes after total tooth loss may be measured by the centimeter. Today the profession must consider the loss of both teeth and bone. The loss of teeth causes remodeling and resorption of the surrounding residual bone and eventually leads to atrophic edentulous ridges.

Almost every woman past the age of 14 years is aware of osteoporosis after menopause. Diet and exercise are encouraged over their entire lifetimes to decrease this risk. Yet osteoporosis primarily affects bone density, not bone volume. The only place in the body bone volume is lost to an extreme is in the jaws after tooth loss. Yet nobody in the public and very few in the profession ever address this issue. It is malpractice if a dentist does not monitor the bone loss around teeth by the millimeter with a probe. Yet the centimeter bone loss of the edentulous regions are often ignored.<sup>72</sup>

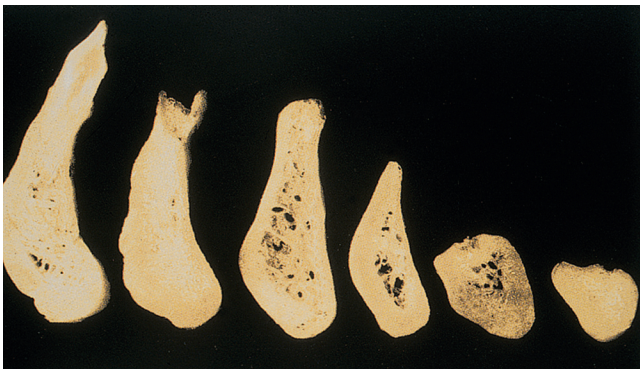

**FIGURE 1-26.** When no primary or secondary tooth root is present, the alveolar process does not form. For example, this panoramic radiograph is from a 35-year-old patient with ectodermal dysplasia with complete anodontia (tooth loss) of both primary and secondary teeth. The basal bone developed, but not the alveolar process. Three anterior implants in the mandible help retain the lower denture.





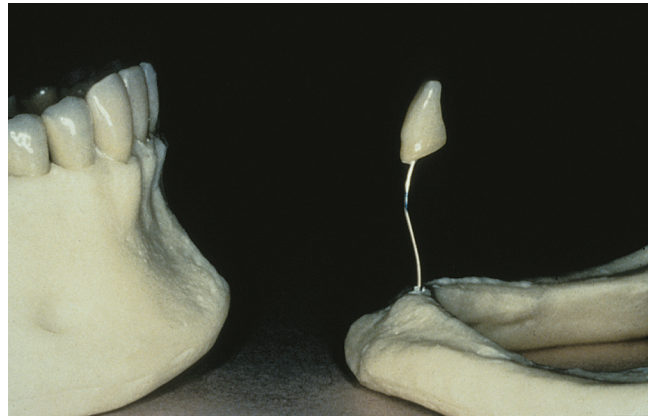
**FIGURE 1-27.** After the initial extraction of teeth, the average first-year bone loss is more than 4 mm in height and 30% in crestal bone width. Although the rate of bone loss is slower after the first year, the bone loss is continuous throughout life. This picture is from a book written by Julius Misch in 1922, demonstrating long-term complete edentulism and bone loss.<sup>64</sup>



**FIGURE 1-28.** Atwood described five different stages of resorption in the anterior mandible. Stage 1 represents the tooth and surrounding alveolar process and basal bone. Stages II and III illustrate the initial residual ridge after tooth loss. Stages IV to VI primarily describe a continuous loss in height of anterior residual bone.

Although the patient often is not aware or informed of the potential consequences, over time consequences will occur. The rate and amount of bone loss may be influenced by such things as gender, hormones, metabolism, parafunction, and ill-fitting dentures. Yet almost 40% of denture wearers have been wearing an ill-fitting prosthesis for more than 10 years.<sup>73</sup> Patients wearing dentures day and night place greater forces on the hard and soft tissues, which accelerates bone loss. Nonetheless, 80% of dentures are worn both day and night.<sup>74</sup> Masticatory forces generated by short facial types (brachiocephalics) can be three to four times those of long facial types (dolichocephalics). Short facial-type patients are at increased risk for developing severe atrophy<sup>75,76</sup> (Box 1-6).

Atrophic edentulous ridges are associated with anatomical problems that often impair the predictable results of traditional dental therapy. Several of these anatomical problems are listed



**FIGURE 1-29.** A dentate mandible on the *left* and a long-term edentulous mandible on the *right*. Note the amount of bone loss in height. Loss of bone height in the mandible may be measured by the centimeter and often is ignored. Such bone loss is often more significant than the bone loss (in millimeters) from periodontal disease. The patient should understand that a denture often replaces more bone than teeth to restore the proper dimensions of the face.

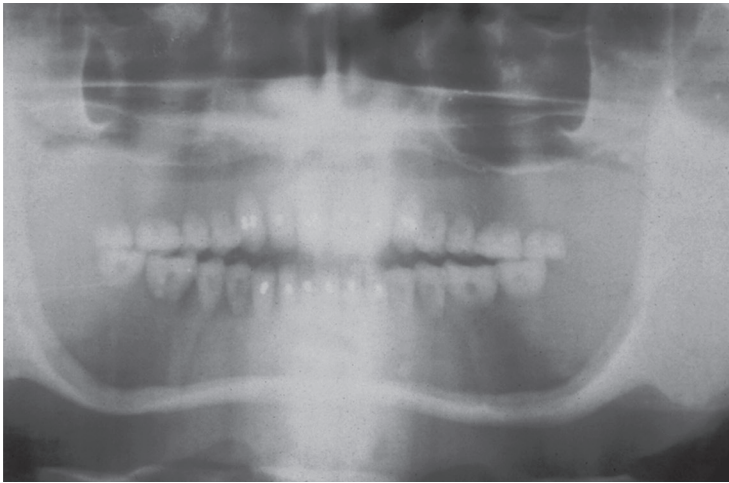
#### BOX 1-6 Rate and Amount of Bone Loss Influenced By

- Gender
- Hormones
- Metabolism
- Parafunction
- Ill-fitting dentures
- Facial type (brachiocephalic vs. dolichocephalic)
- Time period dentures are worn

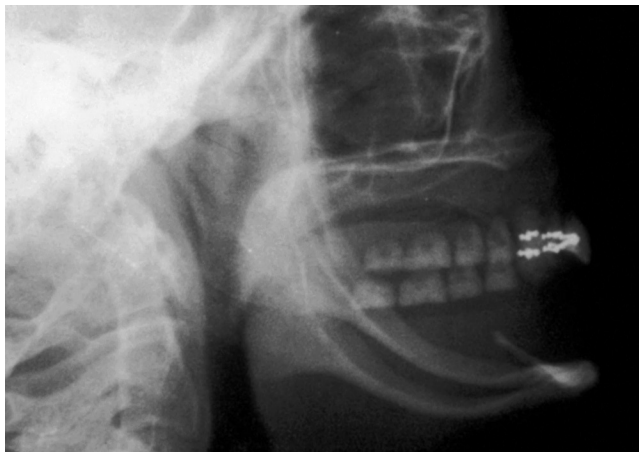
in Box 1-7. Loss of bone in the maxilla or mandible is not limited to alveolar bone; portions of the basal bone may also be resorbed (Figures 1-30 and 1-31), especially in the posterior aspect of the mandible, where severe resorption may result in more than 80% bone loss.<sup>70</sup> The contents of the mental foramen or mandibular canal eventually become dehiscent and serve as part of the support area of the prosthesis.<sup>77</sup> As a result, acute pain and transient to permanent paresthesia of the areas supplied by the mandibular nerve are possible. The body of the mandible also is at increased risk of fracture, even under very low impact forces (Figure 1-32). The mandibular fracture causes the jaw to shift to one side and makes stabilization and an esthetic result most difficult to obtain during treatment of the fracture. The complete anterior ridge and even the nasal spine may be resorbed in the maxilla, causing pain and an increase in maxillary denture movement during function.<sup>70</sup>

#### Soft Tissue Consequences

As bone loses width, then height, then width and height again, the attached gingiva gradually decreases. A very thin attached tissue usually lies over the advanced atrophic mandible or is entirely absent. The increasing zones of mobile, unkeratinized gingiva are prone to abrasions caused by the overlaying prosthesis. In addition, unfavorable high muscle attachments and hypermobile tissue often complicate the situation (Figure 1-33). The loss of bone first causes decreased bone width. The



**FIGURE 1-30.** This panoramic radiograph demonstrates a denture may restore the vertical dimension of the face, but the bone loss of the jaws can continue until the basal bone is paper thin in the maxilla and the mandible becomes the size of a toothpick.



**FIGURE 1-31.** Lateral cephalogram of a patient demonstrates the restored vertical dimension of occlusion with a denture. However, because of the advanced basal bone loss in the mandible, the superior genial tubercles are positioned above the residual anterior ridge. The body of the mandible is only a few millimeters thick, and the mandibular canal is completely dehiscant (one posterior body of the mandible is superimposed on top of the other in this view). In the maxillary anterior ridge, only the nasal spine remains (not the original alveolar ridge), and the posterior maxillary bone is paper thin because of basal bone loss at the crest and the pneumatization of the maxillary sinus. (This is a different patient from the one in Figure 1-30.)

remaining narrow residual ridge often causes discomfort when the thin overlying tissues are loaded under a soft tissue-borne removable prosthesis. The continued atrophy of the posterior mandible eventually causes prominent mylohyoid and internal oblique ridges covered by thin, movable, unattached mucosa. The anterior residual alveolar process also continues to resorb, and the superior genial tubercles (which are 20 mm below the crest of bone when teeth are present) eventually become the most superior aspect of the anterior mandibular ridge. There is little to prevent the prosthesis from moving forward against the lower lip during function or speech. This condition is further compromised by the vertical movement of the distal aspect of the prosthesis during contraction of the mylohyoid and buccinator muscles and the anterior incline of the atrophic mandible compared with that of the maxilla.<sup>78</sup>

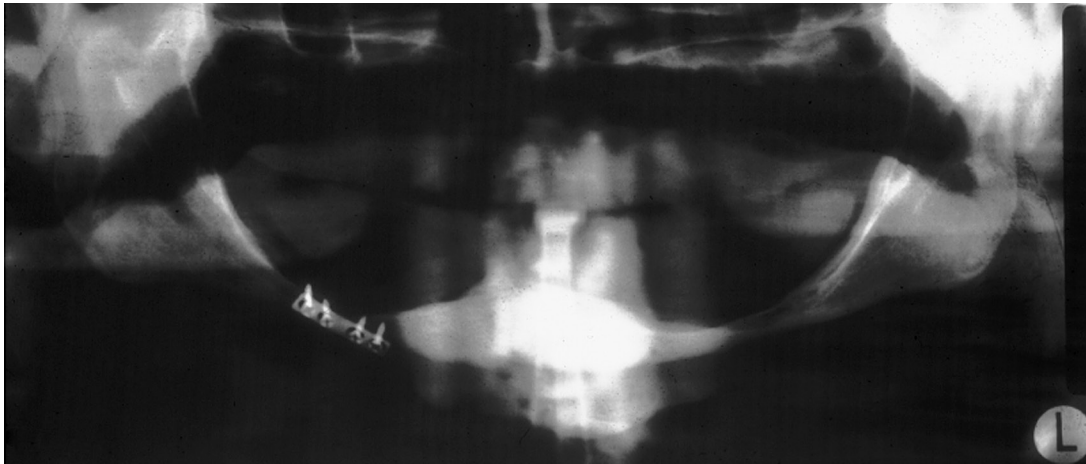
### BOX 1-7 Consequences of Bone Loss in Fully Edentulous Patients

- Decreased width of supporting bone
- Decreased height of supporting bone
- Prominent mylohyoid and internal oblique ridges with increased sore spots
- Progressive decrease in keratinized mucosa surface
- Prominent superior genial tubercles with sore spots and increased denture movement
- Muscle attachment near the crest of the ridge
- Elevation of prosthesis with contraction of mylohyoid and buccinator muscles serving as posterior support
- Forward movement of prosthesis from anatomical inclination (angulation of mandible with moderate to advanced bone loss)
- Thinning of mucosa with sensitivity to abrasion
- Loss of basal bone
- Paresthesia from dehiscant mandibular neurovascular canal
- More active role of tongue in mastication
- Effect of bone loss on esthetic appearance of lower third of face
- Increased risk of mandibular body fracture from advanced bone loss
- Loss of anterior ridge and nasal spine, causing increased denture movement and sore spots during function

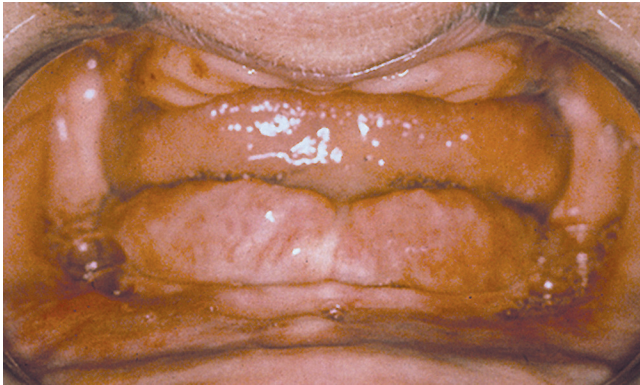
The thickness of the mucosa on the atrophic ridge is also related to the presence of systemic disease and the physiologic changes that accompany aging. Conditions such as the patient's age, hypertension, diabetes, anemia, and nutritional disorders have deleterious effects on the vascular supply and soft tissue quality under removable prostheses. These disorders result in a decreased oxygen tension to the basal cells of the epithelium (Box 1-8). Surface cell loss occurs at the same rate, but the cell formation at the basal layer is slowed. As a result, thickness of the surface tissues gradually decreases. Therefore, sore spots and uncomfortable removable prostheses result.

The tongue of a patient with edentulous ridges often enlarges to accommodate the increase in space formerly occupied by teeth. At the same time, it is used to limit the movements of the removable prostheses and takes a more active role in the





**FIGURE 1-32.** Resorption of an edentulous mandible may result in dehiscence of the mandibular canal and associated paresthesia. The patient may fear that a tumor is growing against the nerves. The body of the mandible may continue to resorb until minor trauma causes fracture as in this panoramic radiograph (e.g., during mastication, the bump of a baby's head held closely to the face, an accidental bump from the elbow).



**FIGURE 1-33.** A patient with moderate to severe atrophy usually has the intraoral muscles above the residual ridge, including the floor of the mouth and the mentalis and buccinator muscles. The tongue is also larger in size and plays a more active role in mastication.

#### BOX 1-8 Conditions That Have an Effect on Vascular Supply and Soft Tissue Quality Under Removable Prostheses

- Patient's age
- Hypertension
- Diabetes
- Anemia
- Nutritional disorders

mastication process. As a result, the removable prosthesis decreases in stability. The decrease in neuromuscular control, often associated with aging, further compounds the problems of traditional removable prosthodontics. The ability to wear a denture successfully may be largely a learned, skilled performance. An aged patient who recently became edentulous may lack the motor skills needed to adjust to the new conditions (Box 1-9).

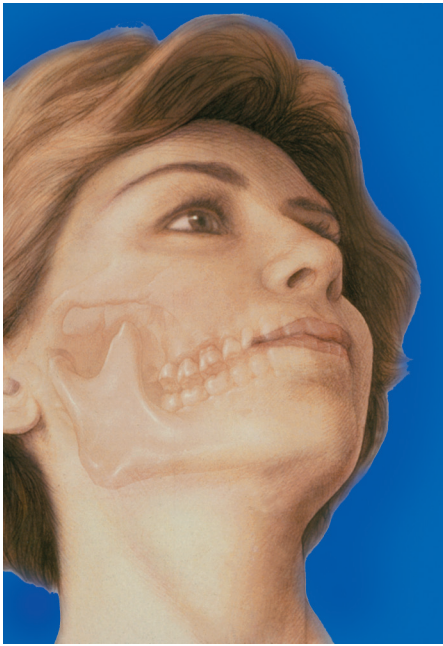
#### BOX 1-9 Soft Tissue Consequences of Edentulism

- Attached, keratinized gingiva is lost as bone is lost
- Unattached mucosa for denture support causes increased soft spots
- Thickness of tissue decreases with age and systemic disease that causes more sore spots for dentures
- Tongue increases in size, which decreases denture stability
- Tongue has more active role in mastication, which decreases denture stability
- Decreased neuromuscular control of jaw in elderly adults

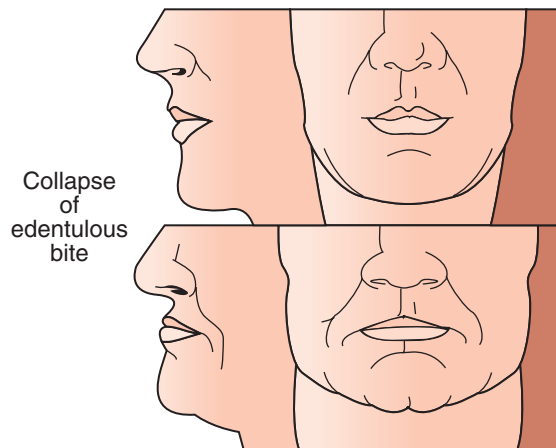
#### Esthetic Consequences

The facial changes that naturally occur in relation to the aging process can be accelerated and potentiated by the loss of teeth. Every dentist is aware that the dental skeletal position will affect facial esthetics. Yet the face is more supported by the bone than the teeth (Figure 1-34). Several esthetic consequences result from the loss of alveolar bone. A decrease in facial height from a collapsed vertical dimension causes several facial changes (Figure 1-35). The loss of labiomental angle and deepening of vertical lines in the area create a harsh appearance. As the vertical dimension progressively decreases, the occlusion evolves toward a pseudo class III malocclusion. As a result, the chin rotates forward and creates a prognathic facial appearance (Figure 1-36). These conditions result in a decrease in the horizontal labial angle at the corner of the lips; the patient appears unhappy when the mouth is at rest (Figures 1-37 and 1-38). People with short facial types have higher bite forces, greater bone loss, and more dramatic facial changes with edentulism compared with others.

A thinning of the vermilion border of the lips results from the poor lip support provided by the prosthesis and the loss of muscle tone. The maxillary retruded position is related to the loss of the premaxillary ridge and the loss of tonicity of the

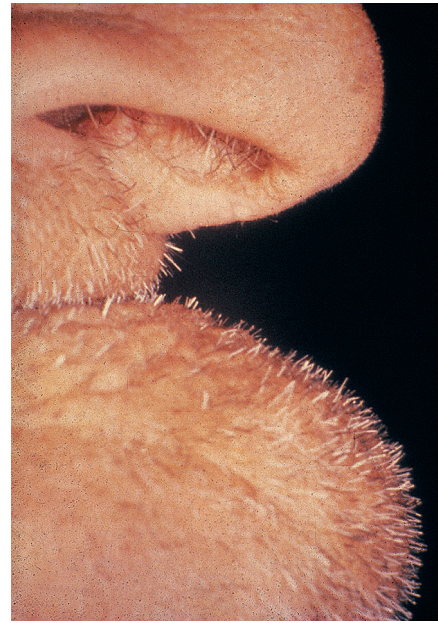


**FIGURE 1-34.** Esthetic aspects of the inferior third of the face are not only related to the position of the teeth but even more important is the position and amount of bone in the jaws and include the muscles that attach to the bone.



**FIGURE 1-35.** A patient often wears a denture for more than 15 years. The loss of bone height during this time is associated with many extraoral facial changes as a closed bite, a mandible that rotates forward, a receding maxilla, a reverse smile line, increased number and depth of lines in the face, more acute angle between the nose and the face, loss of vermilion border in the lips and jowls, and witch's chin from loss of muscle attachment.

muscles involved in facial expression. In a study of 179 white patients at different stages of jaw atrophy, the collapse of the lips and circumoral musculature was evaluated by Sutton et al.<sup>79</sup> The contraction of the orbicularis oris and buccinator muscles in a patient with moderate to advanced bone atrophy displaces the modiolus and muscles of facial expression medially and posteriorly. As a result, a narrowing of the commissure, inversion of the lips, and hollowing of the cheeks were very characteristic findings. Women often use one of two techniques to



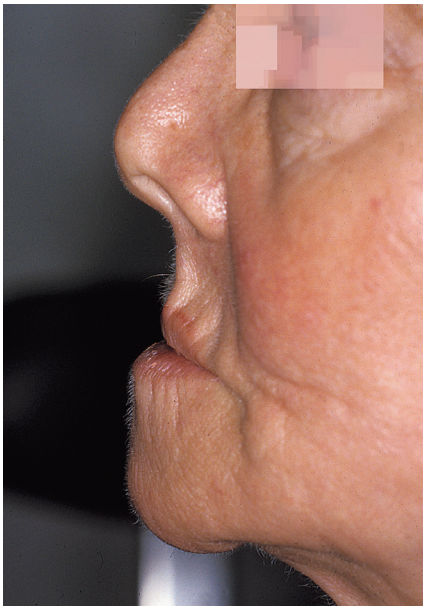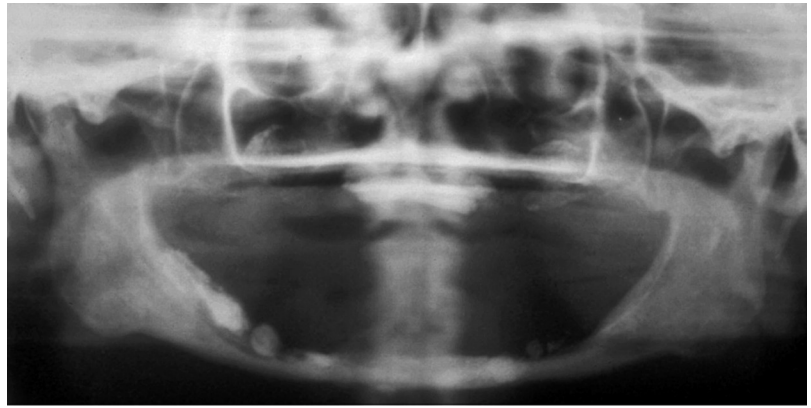
**FIGURE 1-36.** Loss of bone height can lead to a closed bite with rotation of the chin anterior to the tip of the nose. The top picture is a patient with the teeth and jawbone. The bottom picture represents the face of someone without teeth and advanced bone loss.

hide this cosmetically undesirable appearance: either no lipstick and minimal makeup so that little attention is brought to this area of the face or lipstick drawn on the skin over the vermilion border to give the appearance of fuller lips.

A deepening of the nasolabial groove and an increase in the depth of other vertical lines in the upper lip are related to normal aging but are accelerated with bone loss. This usually is accompanied by an increase in the columella–philtrum angle. This can make the nose appear larger than if the lip had more support (Figures 1-39 and 1-40). Men often grow a moustache to minimize this effect. The maxillary lip naturally becomes longer with age as a result of gravity and loss of muscle tone, resulting in less of the anterior teeth shown when the lip is at rest. This has a tendency to “age” the smile because the younger the patient, the more the teeth show in relation to the upper lip at rest or when smiling. Loss of muscle tone is accelerated in edentulous patients, and the lengthening of the lip occurs at a younger age and is longer (showing less teeth) than dentate patients of a similar age. The upper lip often rolls over the incisal edge of the maxillary dentures, which further decreases the size of the vermilion border.

The attachments of the mentalis and buccinator muscles to the body and symphysis of the mandible also are affected by bone atrophy. The tissue sags, producing “jowls” or a “witch’s chin.” This effect is cumulative because of the loss in muscle tone with the loss of teeth, the associated decrease in bite force, and the loss of bone in the regions where the muscles used to attach (Box 1-10). Patients are unaware that these hard and soft tissue changes are from the loss of teeth. Among denture wearers, 39% have been wearing the same prosthesis for more than 10 years.<sup>74</sup> The profession is unable to evaluate patients unless they return yearly. Therefore, the consequences of tooth loss must be explained to partially or completely edentulous patients during the early phases of treatment.

**FIGURE 1-37.** Panoramic radiograph of a complete edentulous patient with severe bone loss. A hydroxyapatite graft in the premaxilla and mandible was attempted to help stabilize a denture.



**FIGURE 1-38.** This patient (same as Figure 1-37) has severe bone loss in the maxilla and mandible. Although she is wearing her 15-year-old dentures, the facial changes are significant. The loss of muscle attachments lead to ptosis of the chin (witch's chin), loss of vermilion border (lipstick is applied to the skin), reverse lip line (decrease in horizontal angles), increased vertical lines in the face and lips, increased lip angle under the nose, and a lack of muscle tonicity in the masseter and buccinator muscles.

### Negative Consequences of Complete Dentures

There are many other negative consequences related to a complete denture and edentulous patients, including masticatory function, systemic consequences, patient satisfaction, and speech and psychologic effects (Box 1-11).

#### Masticatory Function

The difference in maximum occlusal forces recorded in a person with natural teeth and one who is completely edentulous is dramatic. In the first molar region of a dentate person, the average force has been measured at 150 to 250 psi.<sup>80</sup> A patient who grinds or clenches the teeth may exert a force that approaches 1000 psi. The maximum occlusal force in an edentulous patient is reduced to less than 50 psi. The longer patients are edentulous, the less force they are able to generate. Patients

### BOX 1-10 Esthetic Consequences of Bone Loss

- Decreased facial height
- Loss of labiomental angle
- Deepening of vertical lines in lip and face
- Chin rotates forward—gives a prognathic appearance
- Decreased horizontal labial angle of lip—makes patient look unhappy
- Loss of tone in muscles of facial expression
- Thinning of vermilion border of the lips from loss of muscle tone
- Deepening of nasolabial groove
- Increase in columella–philtrum angle
- Increased length of maxillary lip, so less teeth show at rest and smiling—ages the smile
- Ptosis of buccinator muscle attachment—leads to jowls at side of face
- Ptosis of mentalis muscle attachment—leads to “witch’s chin”

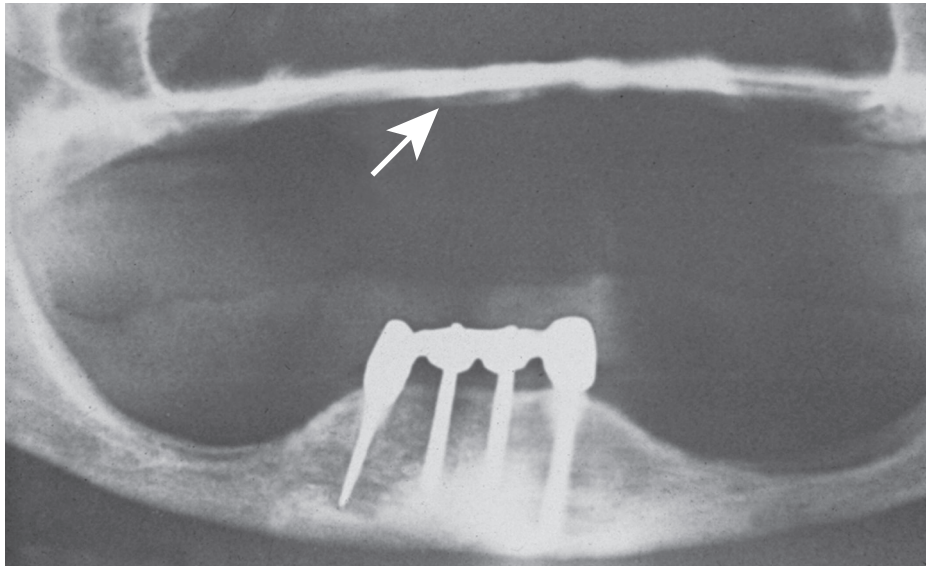
### BOX 1-11 Negative Effects of Complete Dentures

- Bite force is decreased from 200 psi for dentate patients to 50 psi for edentulous patients
- 15-year denture wearers have reduced bite force to 6 psi
- Masticatory efficiency is decreased
- More drugs are necessary to treat gastrointestinal disorders
- Food selection is limited
- Healthy food intake is decreased
- The life span may be decreased
- Reduced prosthesis satisfaction
- Speech difficulty
- Psychologic effects

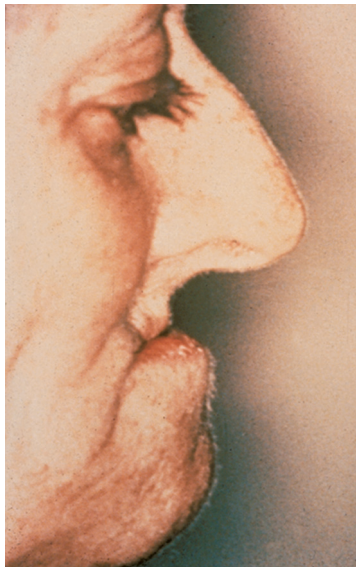wearing complete dentures for more than 15 years may have a maximum occlusal force of less than 6 psi.<sup>81</sup>

As a result of decreased occlusal force and the instability of the denture, masticatory efficiency also decreases with tooth loss. Ninety percent of the food chewed with natural teeth fits through a no. 12 sieve; this is reduced to 58% in the patient wearing complete dentures.<sup>82</sup> A study of 367 denture wearers (158 men and 209 women) found that 47% exhibited a low masticatory performance.<sup>83</sup> The 10-fold decrease in force and





**FIGURE 1-39.** Panoramic radiograph of a 68-year-old woman. The maxillary arch has severe atrophy and almost complete basal bone loss, including most of the nasal spine. Implants were inserted in the anterior mandible 15 years before this film. The anterior bone has been maintained. The posterior mandible has continued to resorb, and the mandibular canal is dehiscence on one side.



**FIGURE 1-40.** Profile view (same patient as in Figure 1-39). Note the maxillary bone loss effect on the lack of vermilion border of the lip, deep labial folds, and the columella–philtrum angle. Yet the lower lip has a normal vermilion border and the muscles to the anterior lower jaw are still attached, providing a normal contour.

the 40% decrease in efficiency affect the patient's ability to chew. In persons with dentures, 29% are able to eat only soft or mashed foods, 50% avoid many foods, and 17% claim they eat more efficiently without the prosthesis.<sup>84</sup> Lower intakes of fruits, vegetables, and vitamin A by women were noted in this group. Denture patients also take significantly more drugs (37%) compared with those with superior masticatory ability (20%), and 28% take medications for gastrointestinal disorders. The reduced consumption of high-fiber foods could induce gastrointestinal problems in edentulous patients with deficient

masticatory performance. In addition, the coarser bolus may impair proper digestive and nutrient extraction functions.<sup>85</sup>

Mandibular discomfort was listed in a study by Misch and Misch with equal frequency as movement (63.5%), and surprisingly, 16.5% of the patients stated they never wear the mandibular denture.<sup>84</sup> In comparison, the maxillary denture was uncomfortable half as often (32.6%), and only 0.9% were seldom able to wear the prosthesis. Function was the fourth most common problem reported by these 104 denture wearers. Half of the patients avoided many foods, and 17% claimed they were able to masticate more effectively without the prostheses. The psychological effects of the inability to eat in public can be correlated with these findings. Other reports agree that the major motivating factors for patients to undergo treatment were related to the difficulties with eating, denture fit, and discomfort.

### Systematic Consequences

The literature includes several reports suggesting that compromised dental function causes poor masticatory performance and swallowing poorly chewed food, which in turn may influence systemic changes favoring illness, debilitation, and shortened life expectancy.<sup>86-90</sup> In a study evaluating the ability to eat fruit, vegetables, and other dietary fiber in edentulous subjects, 10% claimed difficulty, and blood tests demonstrated reduced levels of plasma ascorbate and plasma retinol compared with dentate subjects. These two blood tests are correlated to an increased risk of dermatologic and visual problems in aging adults.<sup>91</sup> In another study, the masticatory performance and efficiency in denture wearers were compared with those of dentate individuals.<sup>92</sup> This report noted that when appropriate corrections were made for different performance norms and levels, the chewing efficiency of a denture wearer was less than one sixth of a person with teeth.

Several reports in the literature correlate a patient's health and life span to dental health.<sup>93-97</sup> Poor chewing ability may be a cause of involuntary weight loss in old age, with an increase

in mortality rate.<sup>98</sup> In contrast, persons with a substantial number of missing teeth were more likely to be obese.<sup>93</sup> After conventional risk factors for strokes and heart attacks were accounted for, there was a significant relationship between dental disease and cardiovascular disease, the latter still remaining as the major cause of death.<sup>86-100</sup> It is logical to assume that restoring the stomatognathic system of these patients to a more normal function may indeed enhance the quality and length of their lives.<sup>93,99-102</sup>

### Satisfaction of Prosthesis

A dental survey of edentulous patients found that 66% were dissatisfied with their mandibular complete dentures. Primary reasons were discomfort and lack of retention causing pain and discomfort.<sup>103</sup> Past dental health surveys indicate that only 80% of the edentulous population are able to wear both removable prostheses all the time.<sup>104</sup> Some patients wear only one prosthesis, usually the maxillary; others are only able to wear their dentures for short periods. In addition, approximately 7% of patients are not able to wear their dentures at all and become “dental cripples” or “oral invalids.” They rarely leave their home environment, and when they feel forced to venture out, the thought of meeting and talking to people when not wearing their teeth is unsettling.

### Speech Effects

A report of 104 completely edentulous patients seeking treatment was performed by Misch and Misch.<sup>84</sup> Of the patients studied, 88% claimed difficulty with speech, with one fourth having great difficulty. The lower prosthesis rests upon the buccinator muscle and mylohyoid muscle when the posterior mandible resorbs. When the patient opens his or her mouth, the contraction of these muscles acts like a trampoline and propels the lower denture off the ridge. As a result, the teeth often click when the patient talks, not from too much of the vertical dimension restored but from the lack of stability and retention of the prosthesis. Speech problems may be associated with a concern for social activities. Awareness of movement of the mandibular denture was cited by 62.5% of these patients, although the maxillary prosthesis stayed in place most of the time at almost the same percentage.

### Psychological Aspects of Tooth Loss

The psychological effects of total edentulism are complex and varied and range from very minimal to a state of neuroticism (Box 1-12). Although complete dentures are able to satisfy the esthetic needs of many patients, some believe their social lives are significantly affected.<sup>105,106</sup> They are concerned with kissing and romantic situations, especially if a new partner in a relationship is unaware of their oral handicap. Fiske et al., in a

#### BOX 1-12 Psychological Effects of Tooth Loss

- Range from minimal to neuroticism
- Romantic situations affected (especially in new relationships)
- “Oral invalids” unable to wear dentures
- More than \$200 million each year is spent on denture adhesive to decrease embarrassment
- Dissatisfaction with appearance; low self-esteem
- Avoidance of social contact

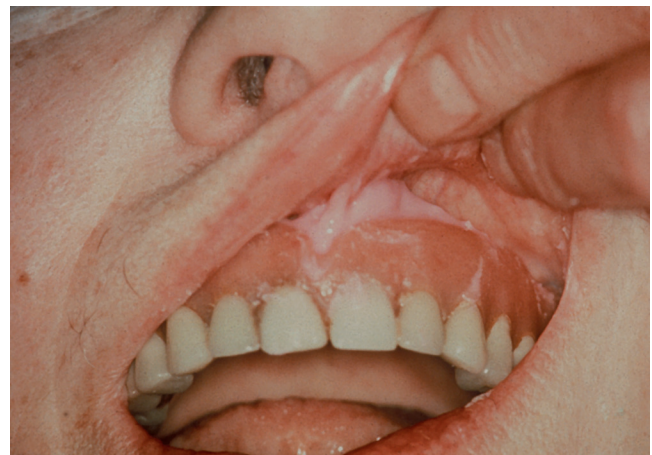study of interviews with edentulous subjects, found tooth loss was comparable to the death of a friend or loss of other important parts of a body in causing a reduction of self-confidence ending in a feeling of shame or bereavement.<sup>105</sup>

The psychological needs of edentulous patients are expressed in many forms. For example, in 1970, Britons used approximately 88 tons of denture adhesive<sup>107</sup> (Figure 1-41). In 1982, more than 5 million Americans used denture adhesives (Ruskin Denture Research Associates: AIM study, unpublished data, 1982), and a report shows that in the United States, more than \$200 million is spent each year on denture adhesives, representing 55 million units sold.<sup>108</sup> The patient is willing to accept the unpleasant taste, need for recurring application, inconsistent denture fit, embarrassing circumstances, and continued expense for the sole benefit of increased retention of the prosthesis. Clearly, the lack of retention and psychological risk of embarrassment in the denture wearer with removable prostheses is a concern the dental profession must address.

### Advantages of Implant-Supported Prostheses

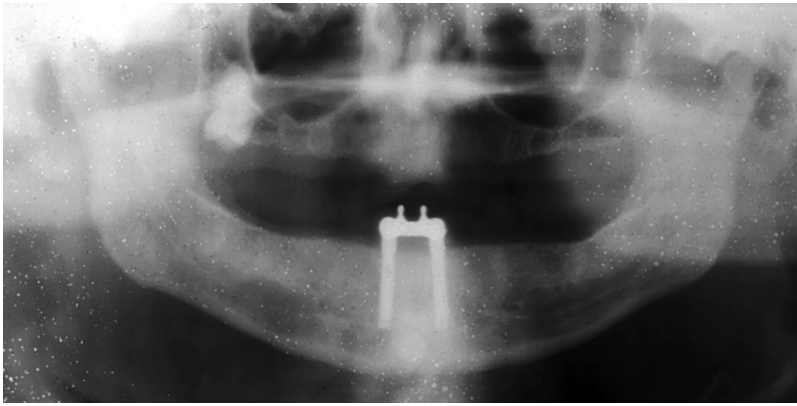
The use of dental implants to provide support for prostheses offers many advantages compared with the use of removable soft tissue-borne restorations (Box 1-13). A primary reason to consider dental implants to replace missing teeth is the maintenance of alveolar bone. Dental implants placed in the anterior mandible help retain a lower denture and are a benefit over a complete denture (Figure 1-42). But the posterior bone loss will continue and may eventually lead to significant complications. Instead, when enough implants are inserted, the restoration is not only retained, but it also is completely supported and stabilized off the tissue and bone. The implants also stimulate and maintain the bone of the entire mandibular as well as serve as an anchor for the prosthetic device. As a result, dental implants are one of the better preventive maintenance procedures in dentistry (Figure 1-43).

Stress and strain may be applied to the bone surrounding the implant. As a result, the decrease in trabeculation of bone that occurs after tooth extraction is reversed. There is an increase in bone trabeculae and density when the dental implant is inserted and functioning. The overall volume of bone is also maintained with a dental implant. Even grafts of iliac bone to



**FIGURE 1-41.** Denture adhesive is often used to help retain a denture. It does not provide support or stability but only helps retain a denture. It does not prevent bone loss.





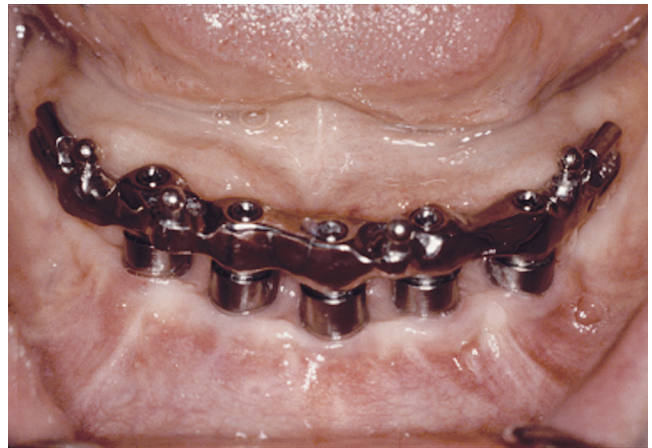**FIGURE 1-42.** A panoramic radiograph with two anterior implants. Although retention and oral stability are gained for the denture, it does not stop the posterior bone loss. The bone loss in the maxilla will also continue.

### BOX 1-13 Advantages of Implant-Supported Prosthesis

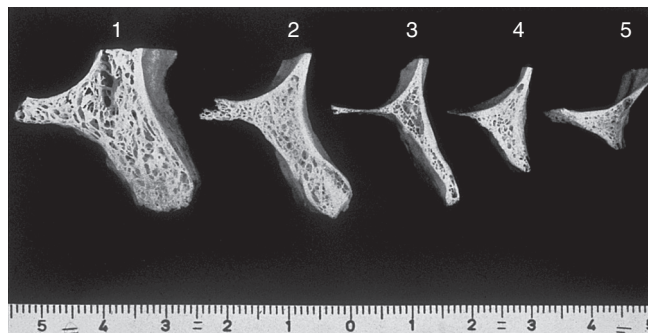
- Maintain bone
- Restore and maintain occlusal vertical dimension
- Maintain facial esthetics (muscle tone)
- Improve esthetics (teeth positioned for appearance vs. decreasing denture movement)
- Improve phonetics
- Improve occlusion
- Improve or regain oral proprioception (occlusal awareness)
- Increase prosthesis success
- Improve masticatory performance or maintain muscles of mastication and facial expression
- Reduce size of prosthesis (eliminate palate, flanges)
- Provide fixed versus removable prostheses
- Improve stability and retention of removable prostheses
- Increase survival times of prostheses
- No need to alter adjacent teeth
- More permanent replacement
- Improve psychological health
- Improved health related to diet

the jaws, which usually resorb without dental implant insertion within 5 years, are instead stimulated and maintain overall bone volume and implant integration. An endosteal implant can maintain bone width and height as long as the implant remains healthy.<sup>109</sup> As with a tooth, periimplant bone loss may be measured in tenths of a millimeter and may represent a more than 20-fold decrease in lost structure compared with the resorption that occurs with removable prostheses.

The benefit of bone maintenance is especially noteworthy in the maxillary edentulous arch. Rather than using implants only in the edentulous mandibular arch, because the primary mechanical denture problems and complaints are in this arch, the maxillary arch should also be addressed. After implant prostheses are placed to support and retain the mandibular restoration, the bone in the maxillary region continues to be lost, and eventually the patient may complain of loss of retention and inability of the maxillary denture to function<sup>110</sup> (Figure 1-44). The loss of facial esthetics is most often first noted in the maxillary arch, with the loss of vermilion border of the lip, increased length of the maxilla lip, and lack of facial bone support. Implants should be used to treat the continued bone loss and



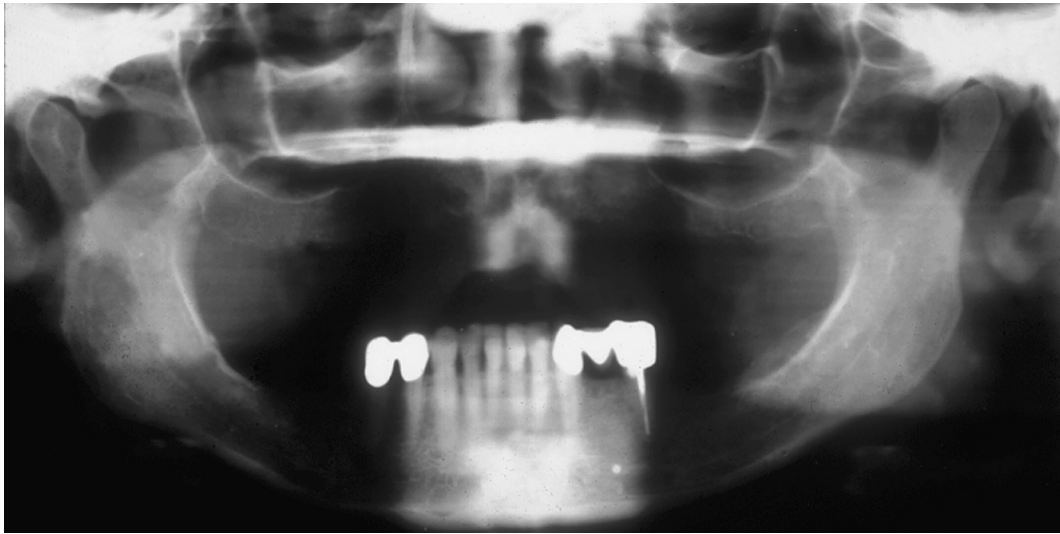
**FIGURE 1-43.** Bone loss in an edentulous patient may be dramatically stopped by using enough implants to completely support, retain, and stabilize the prosthesis.



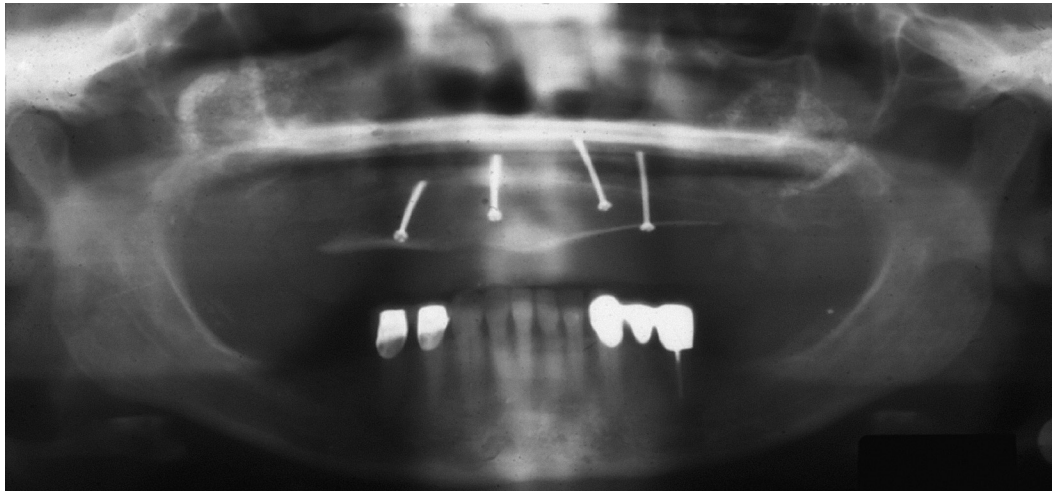
**FIGURE 1-44.** The maxillary bone also continues to resorb over time. The bone on the far right will have difficulty supporting a maxillary denture.

prevent the later complications found in the maxillary arch (Figures 1-45 to 1-50).

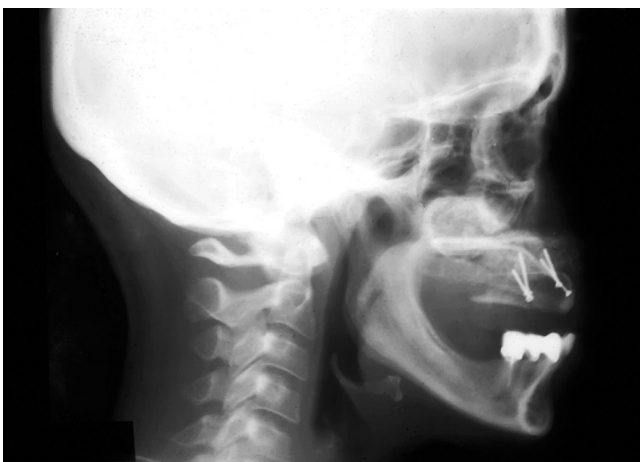A mandibular denture often moves when the mylohyoid and buccinator muscles contract during speech or mastication. The maxillary teeth are often positioned for lower denture stability rather than where natural teeth usually reside. With implants, the maxillary teeth may be positioned to enhance esthetics and phonetics rather than in the neutral zones dictated by traditional denture techniques to improve the stability of a lower prosthesis.



**FIGURE 1-45.** A panoramic radiograph of an edentulous maxillary arch with moderate-size sinuses and a resorbed anterior maxilla.



**FIGURE 1-46.** An iliac crest bone graft was inserted into the maxilla, and bilateral sinus grafts were also made to the posterior regions.

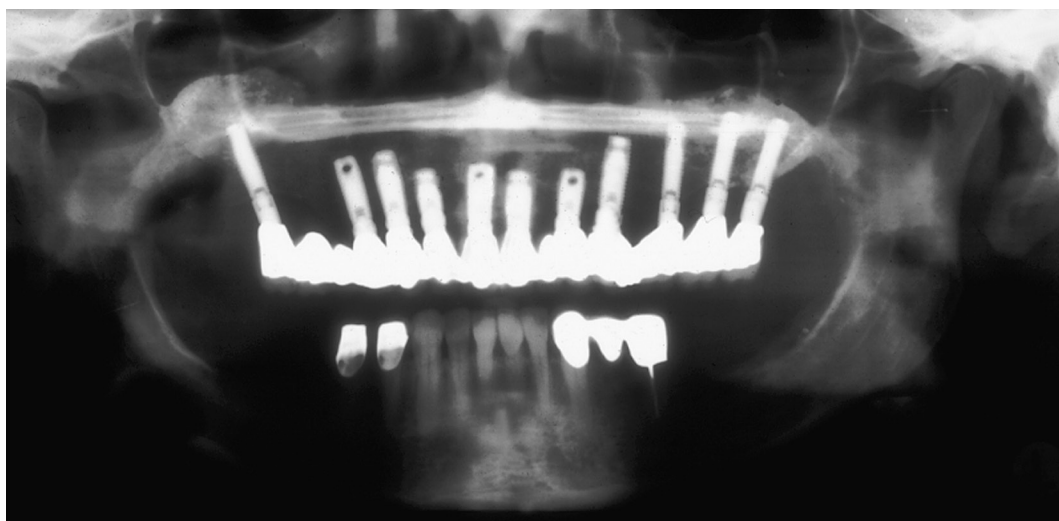


**FIGURE 1-47.** The lateral cephalometric radiograph of the patient shown in Figure 1-44. Note the gain in bone height from the graft.

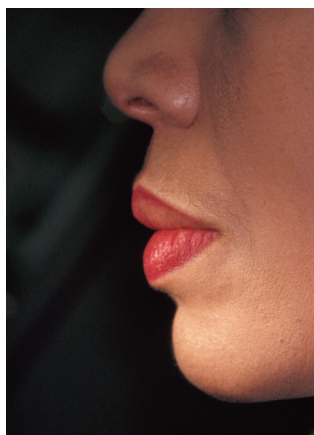The features of the inferior third of the face are closely related to the supporting skeleton. When vertical bone is lost, the dentures only act as “oral wigs” to improve the contours of the face. The dentures become bulkier as the bone resorbs, making it more difficult to control function, stability, and retention. With implant-supported prostheses, the vertical dimension may be restored, similar to natural teeth. In addition, the implant-supported prosthesis allows a cantilever of anterior teeth for ideal soft tissue and lip contour and improved appearance in all facial planes. This happens without the instability that usually occurs when an anterior cantilever is incorporated in a traditional denture. The facial profile may be enhanced for the long term with implants rather than deteriorating over the years, as can occur with traditional dentures.

Occlusion is difficult to establish and stabilize with a completely soft tissue-supported prosthesis. Because the mandibular prosthesis may move as much as 10 mm or more during function,<sup>111,112</sup> proper occlusal contacts occur by chance, not by





**FIGURE 1-48.** Maxillary implants were inserted after the graft matured, and a maxillary fixed prosthesis was fabricated.



**FIGURE 1-49.** A profile of the patient after restoration. Note the support of the maxillary lip and presence of the vermilion border of the lip.



**FIGURE 1-50.** The high smile line of the patient with the final restoration in place.

design. But an implant-supported restoration is stable. The patient can more consistently return to centric relation occlusion rather than adopt variable positions dictated by the prosthesis' instability. Proprioception is awareness of a structure in time and place. The receptors in the periodontal membrane of the natural tooth help determine its occlusal position. Although endosteal implants do not have a periodontal membrane, they provide greater occlusal awareness than complete dentures. Whereas patients with natural teeth can perceive a difference of 20 microns between the teeth, implant patients can determine a 50-micron differences with rigid implant bridges compared with 100 microns in those with complete dentures (either one or two).<sup>113</sup> As a result of improved occlusal awareness, the patient functions in a more consistent range of occlusion. With an implant-supported prosthesis, the direction of the occlusal loads is controlled by the restoring dentist. Horizontal forces on removable prostheses accelerate bone loss, decrease prosthesis stability, and increase soft tissue abrasions. Therefore, the decrease in horizontal forces that are applied to implant restorations improves the local parameters and helps preserve the underlying soft and hard tissues.

In a randomized clinical trial by Kapur et al., the implant group of patients demonstrated a higher level of eating enjoyment and improvement of speech, chewing ability, comfort, denture security, and overall satisfaction.<sup>114</sup> The ability to eat several different foods among complete denture versus mandibular overdenture patients was evaluated by Awad and Feine.<sup>115</sup> The implant overdenture was superior for eating not only harder foods, such as carrots and apples, but also softer foods, such as bread and cheese. Geertman et al. evaluated complete denture wearers with severely resorbed mandibles before and after mandibular implant overdentures. The ability to eat hard or tough foods significantly improved.<sup>116,117</sup>

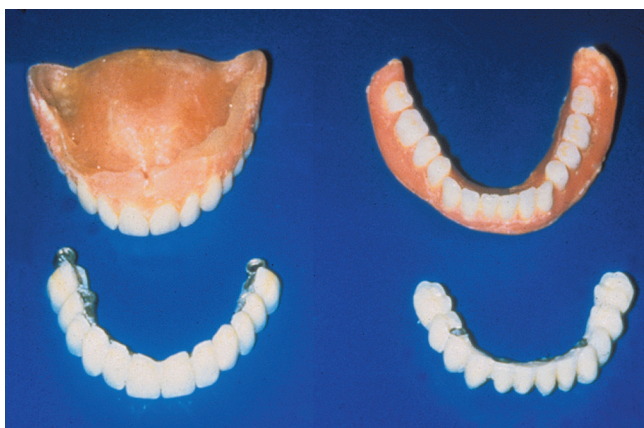
Researchers at McGill University evaluated blood levels of patients who had complete dentures and 30 maxillary dentures and mandibular implant prostheses 6 months after treatment. Within this rather short period, implant patients had higher vitamin B<sub>12</sub> hemoglobin (related to iron increase) and albumin levels (related to nutrition). These patients also had greater

body fat in their shoulders and arms, with decreased body fat in their waists.<sup>118</sup>

The success rate of implant prostheses varies, depending on a host of factors that change for each patient. However, compared with traditional methods of tooth replacement, the implant prosthesis offers increased longevity, improved function, bone preservation, and better psychological results. According to 10-year survival surveys of fixed prostheses on natural teeth, decay is indicated as the most frequent reason for replacement; and survival rates are approximately 75%.<sup>27</sup> In a partially edentulous patient, independent tooth replacement with implants may preserve intact adjacent natural teeth as abutments, further limiting complications such as decay or endodontic therapy, which are the most common causes of fixed prosthesis failure. A major advantage of the implant-supported prosthesis is that the abutments cannot decay and never require endodontics. The implant and related prosthesis can attain a 10-year survival rate of more than 90%.

The maximum occlusal force of a traditional denture wearer ranges from 5 to 50 lb. Patients with an implant-supported fixed prosthesis may increase their maximum bite force by 85% within 2 months after the completion of treatment. After 3 years, the mean force may reach more than 300% compared with pretreatment values. As a result, an implant prosthesis wearer may demonstrate a force similar to that of a patient with a fixed restoration supported by natural teeth. Chewing efficiency with an implant prosthesis is greatly improved compared with that of a soft tissue-borne restoration. The masticatory performance of dentures, overdentures, and natural dentition was evaluated by Rissin et al.<sup>82</sup> The traditional denture showed a 30% decrease in chewing efficiency; other reports indicate a denture wearer has less than 60% of the function of people with natural teeth. The tooth-supported overdenture loses only 10% of chewing efficiency compared with natural teeth. These findings are similar with implant-supported overdentures. In addition, rigid, implant-supported fixed bridges may function the same as natural teeth. Beneficial effects such as a decrease in fat, cholesterol, and the carbohydrate food groups have been reported, as well as significant improvement in eating enjoyment and social life.<sup>119-127</sup>

Stability and retention of an implant-supported prosthesis are great improvements over soft tissue-borne dentures (Figure 1-51). Mechanical means of implant retention are far superior



**FIGURE 1-51.** Implant prostheses (*bottom*) can maintain bone, improve function and psychologic health, and reduce the bulk of the soft tissue-borne prostheses (*top*).

to the soft tissue retention provided by dentures or adhesives and cause fewer associated problems. The implant support of the final prosthesis is variable, depending on the number and position of implants; yet all treatment options demonstrate significant improvement.

Phonetics may be impaired by the instability of a conventional denture. The buccinator and mylohyoid muscles may flex and propel the posterior portion of the denture upward, causing clicking, regardless of the vertical dimension.<sup>112</sup> As a result, a patient in whom the vertical dimension already has collapsed 10 to 20 mm may still produce clicking sounds during speech. Often the tongue of the denture wearer is flattened in the posterior areas to hold the denture in position. The anterior mandibular muscles of facial expression may be tightened to prevent the mandibular prosthesis from sliding forward. The implant prosthesis is stable and retentive and does not require these oral manipulations. The implant restoration allows reduced flanges or palates of the prostheses. This is of special benefit to new denture wearers, who often report discomfort with the bulk of the restoration. The extended soft tissue coverage also affects the taste of food, and the soft tissue may be tender in the extended regions. The palate of a maxillary prosthesis may cause gagging in some patients, which can be eliminated in an implant-supported overdenture.

Patients treated with implant-supported prostheses judge their overall psychological health as improved by 80% compared with their previous state while wearing traditional, removable prosthodontic devices. They perceived the implant-supported prosthesis as an integral part of their body.<sup>116,128-132</sup> For example, Raghoobar et al. evaluated 90 edentulous patients in a randomized multicenter study.<sup>131</sup> Five years after treatment, a validated questionnaire targeted patient esthetic satisfaction, retention, comfort, and the ability to speak and eat with either a complete mandibular denture, complete mandibular denture with vestibuloplasty, or mandibular two-implant overdenture. Implant overdentures had significantly higher ratings, but no significant difference was found between the two complete-denture groups. Geertman et al. reported similar results comparing chewing ability of conventional complete dentures with mandibular implant overdentures.<sup>116,117</sup>

## Summary

The goal of modern dentistry is to return patients to oral health in a predictable fashion. Partial and complete edentulous patients may be unable to recover normal function, esthetics, comfort, or speech with a traditional removable prosthesis. The patient's function when wearing a denture may be reduced to one sixth of that level formerly experienced with natural dentition; however, an implant prosthesis may return the function to near normal limits. The esthetics of edentulous patients are affected as a result of muscle and bone atrophy. Continued bone resorption leads to irreversible facial changes. An implant prosthesis allows normal muscle function, and the implant stimulates the bone and maintains its dimension in a manner similar to healthy natural teeth. As a result, the facial features are not compromised by lack of support as often required for removable prostheses. In addition, implant-supported restorations are positioned in relation to esthetics, function, and speech, not in neutral zones of soft tissue support. The soft tissues of the edentulous patients are tender from the effects of thinning mucosa, decreased salivary flow, and unstable or unretentive prostheses. The implant-retained restoration does not

require soft tissue support and improves oral comfort. Speech is often compromised with soft tissue–borne prostheses because the tongue and perioral musculature may be compromised to limit the movement of the mandibular prosthesis. The implant prosthesis is stable and retentive without the efforts of the musculature.

Implant prostheses often offer a more predictable treatment course than traditional restorations. Thus, the profession and the public are becoming increasingly aware of this dental discipline. Manufacturers' sales have increased from a few million dollars to more than several billion dollars per year. Almost every professional journal now publishes refereed reports on dental implants. All U.S. dental schools now teach implant dentistry to all interfacing specialties. Implant dentistry has finally been accepted by organized dentistry. The current trend to expand the use of implant dentistry will continue until every restorative practice uses this modality for abutment support of both fixed and removable prostheses on a regular basis as the primary option for all tooth replacement.<sup>133</sup>

## References

1. Tatum OH: *The Omni implant system*, Birmingham, AL, 1988, Alabama Implant Congress.
2. Millennium Research Group: *U.S. markets for dental implants, 2006*, USDI 06, Toronto, June 2006.
3. Implant based dental reconstruction. The worldwide implant and bone graft market, September 2005. Available at <http://www.kaloramainformation.com>. Accessed July 14, 2007.
4. National Institutes of Health consensus development conference statement on dental implants, *J Dent Educ* 52:686–691, 1988.
5. Stillman N, Douglass CW: Developing market for dental implants, *J Am Dent Assoc* 124:51–56, 1993.
6. Watson MT: Implant dentistry: a 10-year retrospective report, *Dental Products Report* 30:26–32, 1996.
7. Watson MT: Specialist's role in implant dentistry rooted in history: a survey of periodontists and maxillofacial surgeons, *Dental Products Report* 31:14–18, 1997.
8. Bernstein Research, London, July 14, 2011, Sanford L. Bernstein and Col., LLC., p. 104.
9. Marcus SE, Drury JF, Brown LS, et al: Tooth retention and tooth loss in the permanent dentition of adults: United States, 1988–1991, *J Dent Res* 75(spec issue):684–695, 1996.
10. Meskin LH, Brown LJ: Prevalence and patterns of tooth loss in U.S. employed adult and senior populations, 1985–86, *J Dent Educ* 52:686–691, 1988.
11. Murdock SH, Hogue MN: Current patterns and future trends in the population of the United States: implications for dentists and the dental profession in the 21st century, *J Am Coll Dent* 65:29–38, 1998.
12. Census 2000 data on aging. Available at <http://www.aoa.gov/prof/statistics/census2000/census2000.asp>. Accessed July 14, 2007.
13. Hellmich N: Extra weight shaves years off lives, *USA Today A1*, January 7, 2003.
14. Dychtwald K: *Age wave: the challenges and opportunities of an aging America*, New York, 1988, St. Martin's Press.
15. *A profile of older Americans*, Washington, DC, 1993, American Association of Retired Persons.
16. Health, United States, 2004: life expectancy at 65 and 75 years. Available at <http://www.cdc.gov/nchshus.htm>. Accessed July 14, 2007.
17. U.S. Census Bureau 2000: Summary file 1, matrices P13 and PCT12. Available at <http://www.factfinder.census.gov>. Accessed July 14, 2007.
18. Aschenbrener CA: The future is in the present: the implant of generations, *J Am Coll Dent* 65:23–28, 1998.
19. Meskin LH, Berg R: Impact of older adults on private dental practices, 1988–1998, *J Am Dent Assoc* 131:1188–1195, 2000.
20. Cohen BD, Milobsky SA: Monetary damages in dental-injury cases, *Trial Lawyers Quarterly* 29:80–81, 1989.
21. Schwartz NL, Whitsett LD, Berry TG: Unserviceable crowns and fixed partial dentures: life-span and causes for loss of serviceability, *J Am Dent Assoc* 81:1395–1401, 1970.
22. American Dental Association Survey Center: Changes in dental services rendered 1959–1990. In *1990 Survey of Dental Services Rendered*, Chicago, 1994, American Dental Association, pp 24–38.
23. Cheung GSP, Dimmer A, Mellor R, et al: A clinical evaluation of conventional bridgework, *J Oral Rehabil* 17:131–136, 1990.
24. Priest GF: Failure rates of restorations for single tooth replacements, *Int J Prosthodont* 9:38–45, 1996.
25. Creugers NH, Kayser HE, Van't Hof MA: A meta analysis of durability data on conventional fixed bridges, *Community Dent Oral Epidemiol* 22:448–452, 1994.
26. Shugars DA, Bader JD, White BA, et al: Survival rates of teeth adjacent to treated and untreated posterior bounded edentulous spaces, *J Am Dent Assoc* 129:1085–1095, 1998.
27. Walton JN, Gardner FM, Agar JR: A survey of crown and fixed partial denture failures, length of service and reasons for replacement, *J Prosthet Dent* 56:416–421, 1986.
28. Goodacre CJ, Bernal G, Rungcharassaeng K: Clinical complications in fixed prosthodontics, *J Prosthet Dent* 90:31–41, 2003.
29. Schillenburg HT, Hobo S, Whitsett LD, et al: *Fundamentals of fixed prosthodontics*, ed 3, Chicago, 1997, Quintessence.
30. Palmqvist S, Swartz B: Artificial crowns and fixed partial dentures 18 to 23 years after placement, *Int J Prosthodont* 6:279–285, 1993.
31. Hirschfeld L, Wasserman B: A long term survey of tooth loss in 600 treated periodontal patients, *J Periodontol* 49:225–237, 1978.
32. Bloom B, Gaft HC, Jack SS: *National Center for Health Statistics. Dental Services and Oral Health. United States, 1989 Vital Health Stat 10(183)*, DHHS Pat No (PAS) 93-1511. Washington, DC, 1992, U.S. Government Printing Office.
33. Priest GC: Single tooth implants and their role in preserving remaining teeth: a 10 year survival study, *Int J Oral Maxillofac Implants* 14:181–188, 1999.
34. Misch CE, Misch-Dietsh E, Silc J, et al: Posterior implant single tooth replacement and status of abutment teeth. Multi Center 10 year retrospective report, *J Periodontol* 79(12):2378–2382, 2008.
35. Goodacre CJ, Bernal G, Rungcharassaeng K, et al: Clinical complications with implants in implant prostheses, *J Prosthet Dent* 90:121–132, 2003.
36. Haas R, Mensdorff-Pouilly N, Mailath G, et al: Brånemark single tooth implants: a preliminary report of 76 implants, *J Prosthet Dent* 73:274–279, 1995.
37. Fugazzotto PA: Success and failure rates of osseointegrated implants in function in regenerated bone for 72 to 133 months, *Int J Oral Maxillofac Imp* 20:77–83, 2005.
38. Priest G, Priest J: The economics of implants for single missing teeth, *Dent Econ* May:130–138, 2004.
39. Misch CE: Implants and the general practitioner, *Dentistry Today* 26(8):48–54, 2007.
40. Misch CE: An evidence-based review of posterior single tooth replacement: implant vs fixed partial dentures, *Dentistry Today* 19(4):86–95, 2000.
41. Centers for Disease Control and Prevention: Surveillance for dental caries, dental sealants, tooth retention, edentulism and enamel fluorosis—United States, 1988–1994 and 1999–2002. In Beltram-Aguilar ED, Bazker LK, Canto MT, editors: *Surveillance summaries*, August 26, 2005, *MMWR* 2015–2054 (No. SS3).
42. Ramus TE, Misch CE, Brown IJ: Estimated dental implant treatment potential in United States adults, *J Public Health Dent* 852, 2006.



43. Weintraub JA, Bret BA: Oral health status in the United States: tooth loss and edentulism, *J Dent Ed* 49:368–378, 1988.
44. Meskin LH, Brown LJ, Brunelle JA: Patterns of tooth loss and accuracy of prosthodontic treatment potential in U.S. employed adults and seniors, *Gerodontology* 4:126–135, 1988.
45. Redford M, Drury TF, Kingman A, et al: Denture use and the technical quality of dental prostheses among persons 18–74 years old in the United States between 1988 and 1991, *J Dent Res* 75(spec issue):714–725, 1996.
46. Koivumaa KK, Hedegard B, Carlsson GE: Studies in partial denture prostheses: I. An investigation of dentogingivally-supported partial dentures, *Suom Hammaslaak Toim* 56:248–306, 1960.
47. Carlsson GE, Hedegard B, Koivumaa KK: Studies in partial denture prosthesis: IV. A 4-year longitudinal investigation of dentogingivally-supported partial.
48. Wetherell J, Smales R: Partial dentures failure: a long-term clinical survey, *J Dent* 8:333–340, 1980.
49. Wilding R, Reddy J: Periodontal disease in partial denture wearers—a biologic index, *J Oral Rehab* 14:111–124, 1987.
50. Vermeulen A, Keltjens A, Van't hof M, et al: Ten-year evaluation of removable partial dentures: survival rates based on retreatment, not wearing and replacement, *J Prosthet Dent* 76:267–272, 1996.
51. Roberts BA: Survey of chrome cobalt partial dentures, *N Z Dent J* 74:203–209, 1978.
52. Waerhaug J: Periodontology and partial prosthesis, *Int Dent J* 18:101–107, 1968.
53. Aquilino SA, Shugars DA, Bader JD, et al: Ten-year survival rates of teeth adjacent to treated and untreated posterior bounded edentulous spaces, *J Prosthet Dent* 85:455–460, 2001.
54. Rissin L, House JE, Conway C, et al: Effect of age and removable partial dentures on gingivitis and periodontal disease, *J Prosthet Dent* 42:217–223, 1979.
55. Takala L, Utriainen P, Alanen P: Incidence of edentulousness, reasons for full clearance, and health status of teeth before extractions in rural Finland, *Community Dent Oral Epidemiol* 22:254–257, 1994.
56. Steele JG, Treasure E, Pritts NB, et al: Total tooth loss in the United Kingdom in 1998 and implications for the future, *Br Dent J* 189:598–603, 2000.
57. Mojon P: The world without teeth: demographic trends. In Feine JS, Carlsson GE, editors: *Implant overdentures: the standard of care for edentulous patients*, Carol Stream, Ill, 2003, Quintessence.
58. Health Promotion Survey Canada: Statistics Canada, 1990, record number 3828. Available at <http://www.statcan>. Accessed July 14, 2007.
59. Doug CW, Shih A, Ostry L: Will there be a need for complete dentures in the United States in 2020? *J Prosthet Dent* 87:5–8, 2002.
60. Misch CE: Dental implants as a profit center: prosthetics and surgery, *Dental Economics* April:88–90, 2008.
61. Freeman E, Ten Cate AR: Development of the periodontium: an electron microscopic study, *J Periodontol* 42:387–395, 1971.
62. Wolff J: *The laus of bone remodeling*, Berlin, 1986, Springer (Translated by Maquet P, Furlong R; originally published in 1892).
63. Murray PDF: *Bones: a study of the development and structure of the vertebrae skeleton*, Cambridge, 1936, Cambridge University Press.
64. Misch J: *Lehrbuch der Grenzgebiete der Medizin und Zahnheilkunde*, Leipzig, Germany, 1922, FC Vogel.
65. Roberts WE, Turley PK, Brezniak N, et al: Implants: bone physiology and metabolism, *Cal Dent Assoc J* 15:54–61, 1987.
66. Bassett CA: Biologic significance of piezoelectricity, *Calcif Tissue Res* 1:252–272, 1968.
67. Pietrovski J: The bony residual ridge in man, *J Prosthet Dent* 34:456–462, 1975.
68. Carlsson G, Persson G: Morphologic changes of the mandible after extraction and wearing of dentures: a longitudinal clinical and x-ray cephalometric study covering 5 years, *Odont Revy* 18:27–54, 1967.
69. Tallgren A: The reduction in face height of edentulous and partially edentulous subjects during long-term denture wear: a longitudinal roentgenographic cephalometric study, *Acta Odontol Scand* 24:195–239, 1966.
70. Gruber H, Solar P, Ulm C: Maxillomandibular anatomy and patterns of resorption during atrophy. In Watzek G, editor: *Endosseous implants: scientific and clinical aspects*, Chicago, 1996, Quintessence.
71. Atwood DA: Postextraction changes in the adult mandible as illustrated by microradiographs of midsagittal section and serial cephalometric rootenograms, *J Prosthet Dent* 13:810–824, 1963.
72. Misch CE: What you don't know can hurt you (and your patients), *Dentistry Today* 19(12):70–73, 2000.
73. Brodeur JM, Laurin P, Vallee R, et al: Nutrient intake and gastrointestinal disorders related to masticatory performance in the edentulous elderly, *J Prosthet Dent* 70:468–473, 1993.
74. Marcus P, Joshi A, Jones J, et al: Complete edentulism and denture use for elders in New England, *J Prosthet Dent* 76:260–265, 1996.
75. Sassouni V: A classification of skeletal facial types, *Am J Orthod* 55:109–123, 1969.
76. Mercier P, Lafontant R: Influence of facial morphology classes on residual alveolar ridge atrophy, *J Prosthet Dent* 41:90–100, 1979.
77. Gabriel AC: Some anatomical features of the mandible, *J Anat* 92:580–589, 1958.
78. Hickey JC, Zarb GA, Bolender CL, editors: *Boucher's prosthodontic treatment for edentulous patients*, ed 10, St Louis, 1990, Mosby, pp 3–27.
79. Sutton DM, Lewis BRK, Patel M, et al: Changes in facial form relative to progressive atrophy of the edentulous jaw, *Int J Oral Maxillofac Surg* 33:676–682, 2004.
80. Howell AW, Manley RS: An electronic strain gauge for measuring oral forces, *J Dent Res* 27:705, 1948.
81. Carr A, Laney WR: Maximum occlusal force levels in patients with osseointegrated oral implant prostheses and patients with complete dentures, *Int J Oral Maxillofac Implants* 2:101–110, 1987.
82. Rissin L, House JE, Manly RS, et al: Clinical comparison of masticatory performance and electromyographic activity of patients with complete dentures, overdentures and natural teeth, *J Prosthet Dent* 39:508–511, 1978.
83. Carlsson GE, Haraldson T: Functional response. In Brånemark PI, Zarb GA, Albrektsson T, editors: *Tissue integrated prostheses: osseointegration in clinical dentistry*, Chicago, 1985, Quintessence.
84. Misch LS, Misch CE: Denture satisfaction: a patient's perspective, *Int J Oral Implant* 7:43–48, 1991.
85. Hildebrandt GH, Dominguez BL, Schock MA, et al: Functional units, chewing, swallowing and food avoidance among the elderly, *Prosthet Dent* 77:588–595, 1997.
86. Chen MK, Lowenstein F: Masticatory handicap, socio-economic status and chronic conditions among adults, *J Am Dent Assoc* 109:916–918, 1984.
87. Joshipura KJ, Wilkett WC, Douglass CW: The impact of edentulousness on food and nutrient intake, *J Am Dent Assoc* 127:459–467, 1996.
88. Sheiham A, Steele JC, Marcenes W, et al: The impact of oral health on stated ability to eat certain food; findings from the National Diet and Nutrition Survey of Older People in Great Britain, *Gerontology* 16:11–20, 1999.
89. Krall E, Hayes C, Garcia R: How dentition status and masticatory function affect nutrient intake, *J Am Dent Assoc* 129:20–23, 1998.
90. Sheiham A, Steele JG, Marcenes W, et al: The relationship among dental status, nutrient intake, and nutritional status in older people, *J Dent Res* 80:408–413, 2001.
91. Sheiham A, Steele J: Does the condition of the mouth and teeth affect the ability to eat certain foods, nutrient and dietary intake

- and nutritional status amongst older people? *Public Health Nutr* 4:797–803, 2001.
92. Kapur KK, Soman SD: Masticatory performance and efficiency in denture wearers, *J Prosthet Dent* 14:687–694, 1964.
  93. Sheiham A, Steele JG, Marcenes W, et al: The relationship between oral health status and body mass index among older people: a national survey of older people in Great Britain, *Br Dent J* 192:703–706, 2002.
  94. Agerberg G, Carlsson GE: Chewing ability in relation to dental and general health, *Acta Odontol Scand* 39:147–153, 1981.
  95. Hildebrandt GH, Loesche WJ, Lin CF, et al: Comparison of the number and type of dental functional units in geriatric populations with diverse medical backgrounds, *J Prosthet Dent* 73:253–261, 1995.
  96. DeStefano F, Anda RF, Kahn HS, et al: Dental disease and risk of coronary heart disease and mortality, *Br Med J* 306:688–691, 1993.
  97. Syrjonen J, Peltola J, Valtonen V, et al: Dental infections in association with cerebral infarction in young and middle-aged men, *Intern Med* 225:179–184, 1989.
  98. Sullivan D, Walls R, Lipschitz D: Protein-energy undernutrition and risk of mortality within 1 year of hospital discharge in a select population of geriatric rehabilitation patients, *Am J Clin Nutr* 43:559–605, 1991.
  99. Mattila KJ, Nieminen MS, Valtonen V, et al: Association between dental health and acute myocardial infarction, *Br Med J* 298:779–782, 1989.
  100. Loesche WJ: Periodontal disease as a risk factor for heart disease, *Compend Contin Educ Dent* 15:976–992, 1994.
  101. Carlsson GE: Masticatory efficiency: the effect of age, the loss of teeth, and prosthetic rehabilitation, *Int Dent J* 34:93–97, 1984.
  102. Gunne HS, Wall AK: The effect of new complete dentures on mastication and dietary intake, *Acta Odontol Scand* 43:257–268, 1985.
  103. Berg E: The influence of some anamnestic demographic and clinical variables on patient acceptance of new complete dentures, *Acta Odontol Scand* 42:119–127, 1984.
  104. Bergman B, Carlsson GE: Clinical long term studies of complete denture wearers, *J Prosthet Dent* 53:56–61, 1985.
  105. Fiske J, Davis DM, Frances C, et al: The emotional effects of tooth loss in edentulous people, *Br Dent J* 184:90–93, 1998.
  106. Slade GD: *Measuring oral health and quality of life*, Chapel Hill, NC, 1997, University of North Carolina Department of Dental Ecology.
  107. Stafford GD: Denture adhesives: a review of their use and composition, *Dent Pract* 21:17–19, 1970.
  108. Pinto D, editor: *Chain Drug Review* 20:46, 1998.
  109. Zarb G, Schmitt A: Edentulous predicament. I. A prospective study of the effectiveness of implant supported fixed prostheses, *J Am Dent Assoc* 127:59–72, 1996.
  110. Narhi TO, Geertman ME, Hevinga M, et al: Changes in the edentulous maxilla in persons wearing implant-retained mandibular overdentures, *J Prosthet Dent* 84:43–49, 2000.
  111. Sheppard IM: Denture base dislodgement during mastication, *J Prosthet Dent* 13:462–468, 1963.
  112. Smith D: The mobility of artificial dentures during comminution, *J Prosthet Dent* 13:834–856, 1963.
  113. Lundqvist S, Haraldson T: Occlusal perception of thickness in patients with bridges on osseointegrated oral implants, *Scand J Dent Res* 92:88, 1984.
  114. Kapur KK, Garrett NR, Hamada MO, et al: Randomized clinical trial comparing the efficacy of mandibular implant supported overdentures and conventional dentures in diabetic patients. Part III: comparisons of patient satisfaction, *J Prosthet Dent* 82:416–427, 1999.
  115. Awad MA, Feine JJ: Measuring patient satisfaction with mandibular prostheses, *Community Dent Oral Epidemiol* 26:400–405, 1998.
  116. Geertman ME, Boerrigter EM, van't Hof MA, et al: Two-center clinical trial of implant-retained mandibular overdentures versus complete dentures—chewing ability, *Community Dent Oral Epidemiol* 24:79–84, 1996.
  117. Geertman ME, Van Waas MA, van't Hof MA, et al: Denture satisfaction in a comparative study of implant-retained mandibular overdenture: a randomized clinical trial, *Int J Oral Maxillofac Implants* 11:194–200, 1996.
  118. McGill University: *Health and Nutrition Letter* (2):21, April 2003.
  119. Humphries GM, Healey T, Howell RA, et al: The psychological impact of implant-retained mandibular prostheses: a cross-sectional study, *Int J Oral Maxillofac Implants* 10:437–444, 1995.
  120. Meijer HJ, Raghoebar GM, van't Hof MA, et al: Implant-retained mandibular overdentures compared with complete dentures: a 5 years' follow up study of clinical aspects and patient satisfaction, *Clin Oral Implants Res* 10:238–244, 1999.
  121. Harle TH, Anderson JD: Patient satisfaction with implant supported prostheses, *Int J Prosthodont* 6:153–162, 1993.
  122. Wismeijer D, van Waas MA, Vermeeren JI, et al: Patient satisfaction with implant-supported mandibular overdentures: a comparison of three treatment strategies with ITI-dental implants, *Int J Oral Maxillofac Surg* 26:263–267, 1997.
  123. Leung AC, Cheung LK: Dental implants in reconstructed jaws: patients' evaluation of functional and quality of life outcomes, *Int J Oral Maxillofac Implants* 18:127–134, 2003.
  124. Grogono AL, Lancaster DM, Finger IM: Dental implants: a survey of patients' attitudes, *J Prosthet Dent* 62:573–576, 1989.
  125. Kapur KK: Veterans Administration cooperative dental implant study: comparisons between fixed partial dentures supported by blade-vent implants and removable partial dentures. Part II. Comparisons of mastication performances between two treatment modalities, *J Prosthet Dent* 65:272–283, 1991.
  126. Kapur KK: Veterans Administration cooperative dental implant study. Part IV. Comparisons of patient satisfaction between two treatment modalities, *J Prosthet Dent* 66:517–530, 1991.
  127. Garrett NR, Kapur KK, Hasse AL: Veterans Administration cooperative dental implant study. Part V: Comparisons of pretreatment and posttreatment dietary intakes, *J Prosthet Dent* 77:153–161, 1997.
  128. Blomberg S: Psychological response. In Brånemark PI, Zarb GA, Albrektsson T, editors: *Tissue integrated prostheses: osseointegration in clinical dentistry*, Chicago, 1985, Quintessence.
  129. Albrektsson T, Blomberg S, Brånemark A, et al: Edentulousness: an oral handicap. Patient reactions to treatment with jawbone-anchored prosthesis, *J Oral Rehab* 14:503–511, 1987.
  130. Blomberg S, Lundquist S: Psychological reactions to edentulousness and treatment with jawbone-anchored bridges, *J Prosthet Dent* 50:262–270, 1983.
  131. Raghoebar GM, Meijer HJ, Steigenga B, et al: Effectiveness of three treatment modalities for the edentulous mandible: a five year randomized clinical trial, *Clin Oral Implants Res* 11:195–201, 2000.
  132. Al-Omiri M, Hantash RA, Al-Wahadni A: Satisfaction with dental implants: a literature review, *Implant Dent* 14:399–406, 2005.
  133. Misch CE: Dental education: meeting the demands of implant dentistry, *J Am Dent Assoc* 121:334–338, 1990.

## Generic Root Form Component Terminology

Carl E. Misch

An *endosteal* implant is an alloplastic material surgically inserted into a residual bony ridge, primarily as a prosthodontic foundation.<sup>1</sup> The prefix *endo* means “within,” and *osteal* means “bone.”<sup>2</sup> The major subcategory of endosteal implants covered in this text are root form implants. The term *endosseous* is also used in the literature, and because the term *osseous* also indicates bone, either term is acceptable. However, *endosteal*, *periosteal*, and *transosteal* are preferred. Many endosteal implant designs have been used in the past, including tapered pegs, pin shapes, and plate forms.<sup>3,4</sup> Today an endosteal implant in the shape of a single rooted tooth is the design most often used in the restoration of partial or complete edentulous patients.

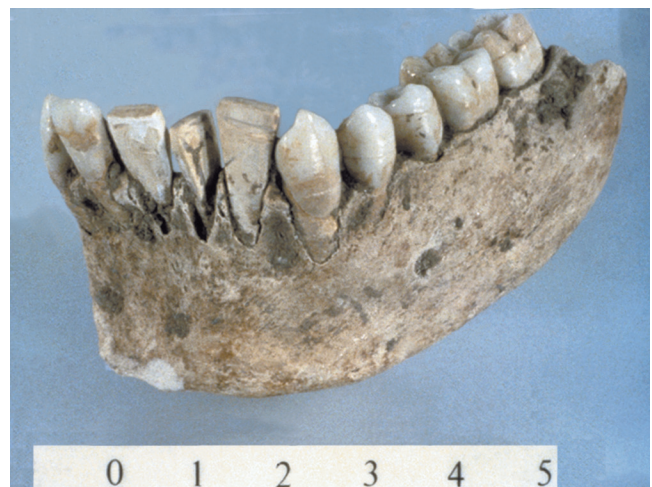Implant dentistry is the second oldest discipline in dentistry (oral surgery [exodontia] is the oldest). Root form implant history dates back thousands of years and included ancient civilizations. For example, 4000 years ago the Chinese carved bamboo sticks in the shape of pegs and drove them into the bone for fixed tooth replacement. The Egyptians used precious metals with a similar peg design 2000 years ago. A skull was found in Europe with a ferrous metal tooth inserted into a skull with a tooth peg design that dated back to the time of Christ. Incas from Central America around 600 AD took pieces of sea shells and, similar to the ancient Chinese, tapped them into the bone to replace missing teeth<sup>5</sup> (Figure 2-1). In other words, history demonstrates it has always made sense to replace a tooth with an implant, with the approximate shape of a tooth. In reality, if the lay public were given a choice to replace a missing tooth with an implant or to grind down several adjacent teeth and connect them with a prosthesis to replace a missing tooth and then attempt to make the adjacent teeth look similar to the condition before their preparation, the implant would be the obvious choice.

Maggiolo introduced the more recent history of implant dentistry in 1809 with use of gold in the shape of a tooth root.<sup>6</sup> In 1887, Harris reported the use of teeth made of porcelain into which lead-coated platinum posts were fitted.<sup>7</sup> Many materials were tested, and in the early 1900s, Lambotte fabricated implants of aluminum, silver, brass, red copper, magnesium, gold, and soft steel plated with gold and nickel.<sup>8</sup> He identified the corrosion of several of these metals in body tissues related to electrolytic action. The first root form design that differed significantly from the shape of a tooth root was the Greenfield latticed-cage design in 1909, made of iridoplatinum<sup>9</sup> (Figure 2-2). This was also the first two-piece implant, which separated the abutment from the endosteal implant body at the initial placement. The surgery was designed to use a calibrated trephine bur to maintain an inner core of bone within the implant body. The implant crown was connected to the implant

body with an antirotational internal attachment after several weeks. Reports indicate this implant had a modicum of success. Seventy-five years later, this implant design was reintroduced by Straumann in Europe and later by Core-Vent in the United States.<sup>10,11</sup>

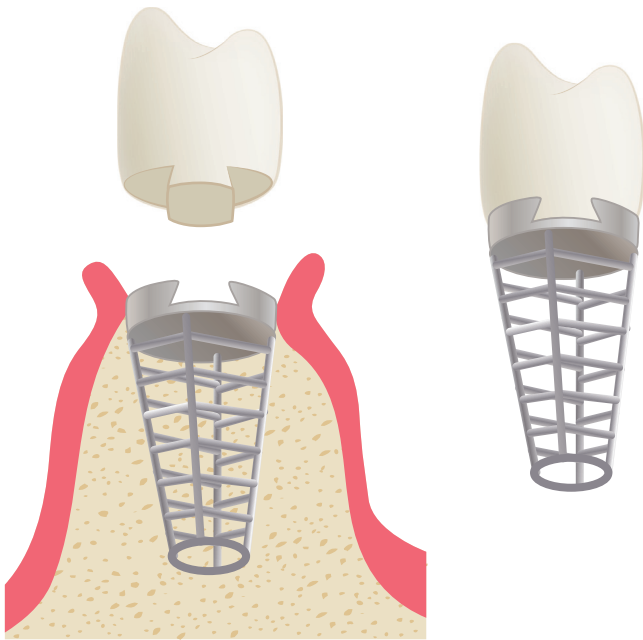
Surgical cobalt-chromium-molybdenum alloy was introduced to oral implantology in 1938 by Strock (Boston, MA) when he replaced a single maxillary left incisor tooth<sup>12</sup> with a root form, one-piece implant that lasted more than 15 years. A direct bone–implant interface to titanium was initially called *bone fusing* and was first reported in 1940 by Bothe and coworkers.<sup>13</sup> In 1946, Strock designed the first titanium, two-piece screw implant that was initially inserted without the permucosal post (Figure 2-3). The abutment post and individual crown were added after complete healing.<sup>14</sup> The desired implant interface described by Strock was a direct bone–implant connection, which was called *ankylosis*. The first submerged implant placed by Strock was still functioning 40 years later.<sup>15</sup>

Brånemark began extensive experimental studies in 1952 on the microscopic circulation of bone marrow healing. These studies led to a dental implant application in the early 1960s in which a 10-year implant integration was established in dogs

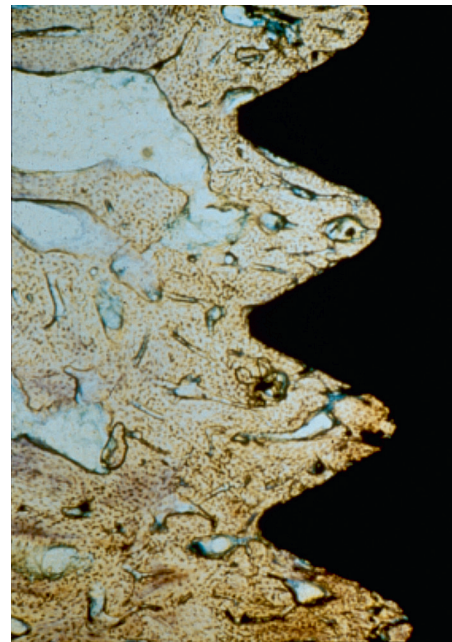


**FIGURE 2-1.** Dated 600 AD, this mandible was found in Central America. The Incas implanted three carved, implanted incisors made from carved sea shells. Calculus formation on these three implants indicate this was not a burial ceremony but a fixed, functional, and esthetic tooth replacement. (Courtesy of the Peabody Museum of Archaeology and Ethnology, Harvard University, 33-19-20/254.0, 95240002.)






**FIGURE 2-2.** Greenfield (Kansas City, KS) developed a two-stage implant insertion. This was also the first antirotational abutment design.



**FIGURE 2-4.** Osseointegration, as coined by Brånemark, described a direct bone–implant interface under the power of a light microscope.



**FIGURE 2-3.** Al Strock (Boston, MA) invented a two-piece cylinder and two-piece screw-type implant in 1938.

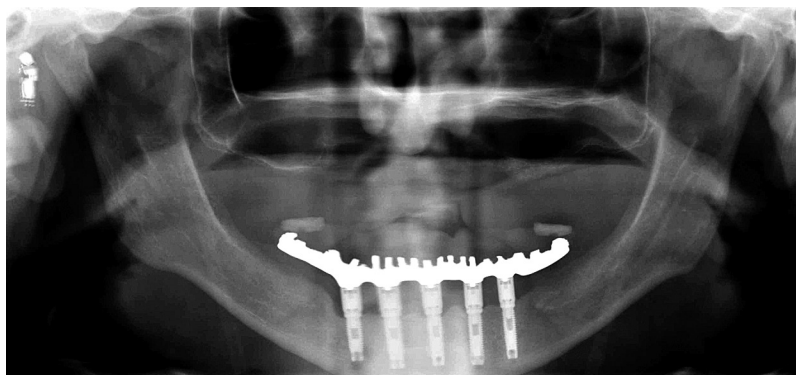
without significant adverse reactions to hard or soft tissues. Implant clinical studies in humans with the Brånemark philosophy began in 1965, were followed for 10 years, and were reported in 1977.<sup>16</sup> The term *osseointegration* (rather than *bone fusing* or *ankylosis*) was defined by Brånemark as a direct contact of living bone with the surface of an implant at the light microscopic level of magnification<sup>17</sup> (Figure 2-4). The terms *bone fusing*, *ankylosis*, and *osseointegration* may be interchangeable and may address the microscopic bone–implant interface. The percentage of direct bone–implant contact was not initially addressed and has been found to be highly variable.

Rigid fixation is the clinical result of a direct bone interface but has also been reported with a fibrous tissue interface.<sup>18</sup> *Rigid fixation* is a clinical term that implies no observable movement of the implant when a force of 1 to 500 g is applied. Today the term *osseointegration* has become common in the implant discipline and describes not only a microscopic condition but also the clinical condition of rigid fixation. The prefix *osteo* (e.g., *osteoblast*, *osteotomy*) also is widely used by the profession and may describe this condition as *osteointegration*.

The osseointegration concepts of Brånemark have been promoted more than those of any other previous person in dental history. The documentation of past clinical case studies, research of surgery and bone physiology, healing of soft and hard tissues, and restorative applications from Brånemark's laboratory were unprecedented. Adell et al. published the Brånemark 15-year clinical case series report in 1981 on the use of implants in completely edentulous jaws.<sup>17</sup> Approximately 90% of the reported anterior mandibular implants that were in the mouths of patients after the first year of loading were still in function 5 to 12 years later. Lower survival rates were observed in the anterior maxilla. In the initial Brånemark clinical reports, no implants were inserted into partially edentulous patients or the posterior regions of the mouth of edentulous patients, and all reported prostheses were cantilevered fixed restorations (Figure 2-5).

The use of dental implants in the treatment of complete and partial edentulism has become an integral treatment modality in restorative dentistry.<sup>19–21</sup> The 1988 National Institutes of Health consensus panel on dental implants recognized that restorative procedures using implants differ from those of traditional dentistry and stressed the necessity for advanced education.<sup>22</sup> During the past 15 years, implant dentistry has become a routine method to replace teeth in a restorative practice.

Many practitioners are taught the use of a specific manufacturer's implant system rather than the theory and



**FIGURE 2-5.** The Brånemark treatment approach placed a cantilevered fixed prosthesis supported by four to six anterior implants.

comprehensive practice of implant dentistry. The increasing number of manufacturers entering the field use trade names for their implant components (often unique to a particular system), and such names have proliferated to the point of creating confusion. Several different terms or abbreviations now exist that describe similar basic components.<sup>23–28</sup>

To make conditions worse, in the team approach to implant treatment, the widening referral base often requires that the restoring practitioner be knowledgeable regarding many implant systems. With the required knowledge of multiple systems and the lack of uniformity in component names, communication is hampered among manufacturers, dentists, staff, laboratory technicians, students, and researchers. In addition, the incorporation of implant dentistry into the curriculum of most predoctoral and postdoctoral programs further emphasizes the need for standardization of terms and components in implant dentistry.<sup>29</sup>

### Generic Prosthetic Component Terminology

A generic language for endosteal implants was developed by Misch and Misch in 1992.<sup>30</sup> The order in which these terms is presented follows the chronology of insertion to restoration. In formulating the terminology, five commonly used implant systems in the United States were referenced. Fifteen years later, the dramatic evolution of the U.S. implant market has resulted in changes in nearly all the implant lines and component designs.<sup>31–33</sup> In 2000, the U.S. market alone had to choose from more than 1300 different implant designs and 1500 abutments in various materials, shapes, sizes, diameters, lengths, surfaces, and connections. More than ever, a common language is needed. In pharmacology, the variety of pharmaceutical components makes it impossible to list them all by proprietary names, but a list by category of drugs is useful. Likewise, implant components still can be classified into broad application categories, and practitioners should be able to recognize a certain component category and know its indications and limitations.

This book incorporates a generic terminology, first introduced by Misch and Misch for endosteal implants, that blends a continuity and familiarity of many implant systems with established definitions from the terms of the *Illustrated Dictionary of Dentistry* and the glossaries from *Terms of the Academy of Prosthodontics*, *American Academy of Implant Dentistry*, and *International Congress of Oral Implantologists*.<sup>1,2,34,35</sup>



**FIGURE 2-6.** An implant body (gray color) is usually separate from the implant abutment (gold color). They are most often connected together with an abutment screw. (Left, internal hex BioHorizons Dental Implants; right, external hex BioHorizons Dental Implants, Birmingham, AL).

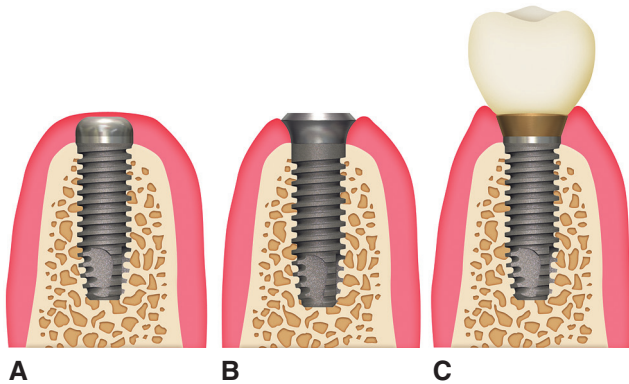
### Generic Implant Body Terminology

Root form implants are a category of endosteal implants designed to use a vertical column of bone, similar to the root of a natural tooth. Although many names have been applied, the 1988 National Institutes of Health consensus statement on dental implants and the American Academy of Implant Dentistry recognized the term *root form*.<sup>1,22,35</sup>

The most common root form design has a separate *abutment and implant body*, which permits only the implant body placement during bone healing (Figure 2-6). A second procedure is required to attach the implant abutment. The design and surgical philosophy is to achieve clinical rigid fixation that corresponds to a microscopic direct bone-to-implant interface without intervening fibrous tissue occurring over any significant portion of the implant body after healing.



Over the years, three different surgical approaches have been used for the two-piece implant systems: one stage, two stage, and immediate restoration (loading) (Figure 2-7). The *two-stage* surgical process places the implant body below the soft tissue until the initial bone healing has occurred. During a *second-stage surgery*, the soft tissues are reflected to attach a *per mucosal element* or *abutment*. During a *one-stage surgical* approach, the implant body and the per mucosal element above the soft tissue are both placed until initial bone maturation has occurred. The abutment of the implant then replaces the per mucosal element



**FIGURE 2-7.** There are three different surgical approaches for two-piece implant systems: **(A)** two stage (healing submerged, then uncover surgery), **(B)** one stage (implant with per mucosal healing, no uncover surgery), and **(C)** immediate restoration (restoration placed at the time of the surgical placement).

without the need for a secondary soft tissue surgery. The *immediate restoration* approach places the implant body and the prosthetic abutment at the initial surgery. A restoration (most often transitional) is then attached to the abutment (often out of occlusal contacts in partially edentulous patients) within 2 weeks of the surgical appointment.

An implant body especially designed for one surgical method may also be selected. For example, a per mucosal element may already be attached to the implant body by the manufacturer to facilitate a one-stage surgical approach. An implant body also may have a prosthetic abutment, which may be part of the implant body, for the one-piece implant to be inserted and restored at the initial surgery. The latter was the original concept first introduced.<sup>12</sup>

There are three primary types of root form body endosteal implants based on design: cylinder, screw, or combination<sup>30</sup> (Figure 2-8). *Cylinder* root form implants depend on a coating or surface condition to provide microscopic retention to the bone. Most often the surface is either coated with a rough material (e.g., hydroxyapatite, titanium plasma spray) or a macro retentive design (e.g., sintered balls). Cylinder implants are usually pushed or tapped into a prepared bone site. They can be a parallel wall cylinder or a tapered implant design. *Screw* root forms are threaded into a slightly smaller prepared bone site and have the macroscopic retentive elements of a thread for initial bone fixation. They may be machined, textured, or coated. There are three basic screw-thread geometries: V-thread, buttress (or reverse buttress) thread, and power (square) thread designs.<sup>36</sup> Threaded implants are primarily available in a parallel cylinder or tapered design. Micro or macro thread features; variable



**FIGURE 2-8.** Implant body designs generally relate to three different categories: cylinder implants (*first six in top row*); screw design implants (*middle row*); or a combination (*bottom row*), which usually are pressed into position and have a macro body design similar to a thread form. (Courtesy Charles English.)



thread pitch, depth, and angle; and self-tapping features can be combined to create a myriad of implant designs in this category. The threaded implants may also have a microscopic connection to the bone as a result of its surface condition. *Combination* root forms have macroscopic features from both the cylinder and screw root forms. The combination root form designs also may benefit from microscopic retention to bone through varied surface treatments (machined, textured, and the addition of coatings).<sup>37-45</sup> As a general rule, the combination implant designs have a press-fit surgical approach (as the cylinder implants) and a macroscopic implant design for occlusal loads (as a series of plateaus or holes in the body). Root forms also have been described by their means of insertion, healing, surgical requirements, surface characteristics, and interface.<sup>28,46</sup>

## Implant Body Regions

The implant body may be divided into a crest module (cervical geometry), a body, and an apex (Figure 2-9). Each section of an implant body has features that are of benefit in the surgical or prosthetic application of the implant.

### Implant Body

An *implant body* is primarily designed for either surgical ease or prosthetic loading to the implant–bone interface. Years ago, the implant body was the primary design feature. A round implant permits round surgical drills to prepare the bone. A smooth-walled cylinder or combination implant allows the implant to be pressed or tapped into position, similar to a nail into a piece of wood. A tapered cylinder fits into the top section of the osteotomy before engagement of the bone for further ease of placement.

A cylinder or press-fit implant design system offers the advantage of ease of placement even in difficult access locations. The cover screw of the implant also may be attached to the implant before implant placement. For example, in the very soft D4 bone of the posterior regions of the maxilla, the surgeon must rotate a threaded implant design into place. Very soft bone may strip during a threaded implant insertion. This may result in lack of initial fixation, and the implant will not be rigid. A tapered cylinder implant may be pressed by hand into soft bone and can be initially fixated more easily. The speed of implant rotation during insertion and the amount of apical force in implant insertion in soft bone are less relevant for a press-fit

cylinder. The cylinder system also presents some benefits for the single-tooth implant application, especially if adjacent to teeth with tall clinical crowns. Thread extenders are needed for the screw implant placement in these situations, as well as additional tools to insert the cover screw of the implant. In dense bone, cylinder systems also are easier and faster to place because bone tapping is not required.

Most cylinder implants are essentially smooth-sided and bullet-shaped implants that require a bioactive or increased surface area coating for retention in the bone. When these materials are placed on an implant, the surface area of bone contact increases more than 30%. The greater the functional surface area of the bone–implant contact, the better the support system for the prosthesis.


A solid screw implant body is the most common design reported in the literature. A *solid screw body* is defined as an implant of a circular cross-section without penetrating any vents or holes. A number of manufacturers provide this design (e.g., Nobel Biocare, Biomet, Zimmer, Straumann, BioHorizons). The thread may be V-shaped, buttress, reverse buttress, or square (power thread) in design. The V-shaped threaded screw has the longest history of clinical use.<sup>16,17</sup> The most common outer thread diameter is 3.75 mm, with a 0.38-mm thread depth and a 0.6-mm thread pitch (distance). The various body lengths usually range from 7 to 16 mm, although lengths from 5 to 56 mm are available. Similar body designs are offered in a variety of diameters (narrow, standard, wide) to respond to the mechanical, esthetic, and anatomical requirements in different regions of the mouth.<sup>31</sup>

A solid screw implant body permits the osteotomy and placement of the implant in dense cortical bone as well as in fine trabecular bone. However, surgery may be modified to accommodate both extremes in bone density. For example, a bone tap may be required in the hardest bone types. The solid screw permits the implant removal at the time of surgery if placement is not ideal. It also permits implant removal at the stage II surgery if angulation or crestal bony contours are not deemed adequate for long-term prosthesis success. The solid screw implant body may be machined or roughened to increase the functional surface area or to take advantage of biochemical properties related to the surface coating (e.g., bone bonding or bone growth factors).

A threaded implant body is primarily designed to increase the bone–implant surface area and to decrease the stresses at the interface during occlusal loading compared with a cylinder implant body design. The functional surface area of a threaded implant is greater than a cylinder implant by a minimum of 30% and may exceed 500%, depending on the thread geometry.<sup>36</sup> This increase in functional implant surface area decreases the stress imposed on the implant–bone interface. The threaded implant body also increases the mechanical retention in the bone at the initial implant insertion. This is especially noteworthy in the softest bone types or when the implant is less than 10 mm long.

### Crest Module

The *crest module* of an implant body is that portion designed to retain the prosthetic component in a two-piece implant system. It also represents the transition zone from the implant body design to the transosteal region of the implant at the crest of the ridge. The abutment connection area usually has a platform on which the abutment is seated; the platform offers physical resistance to axial occlusal loads. An antirotation feature also is included on the platform (external hex) or extends within the



**FIGURE 2-9.** An implant body is the portion of the dental implant that is designed to be placed into the bone to anchor prosthetic components. The implant body has a crest module, a body, and an apex.