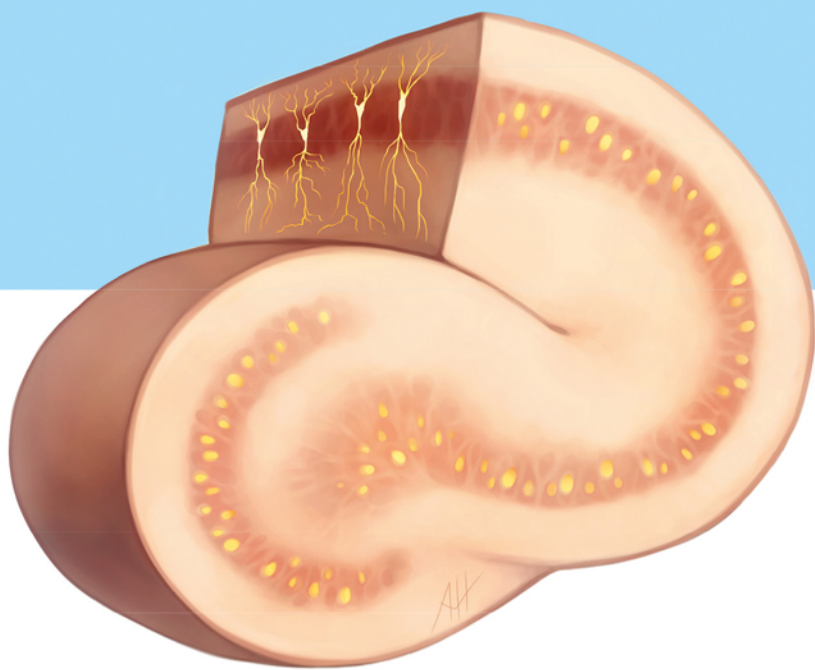


Neurosurgical Intensive Care

Javed Siddiqi

Second Edition



Thieme

mebooksfree.net



Thieme

mebooksfree.net

Neurosurgical Intensive Care

Second Edition

Javed Siddiqi, HBSc, MD, DPhil (Oxon), FRCSC, FAANS, FACS

Chair of Neurosurgery

Riverside University Health System Medical Center

Moreno Valley, California

Chief of Neurosurgery

Arrowhead Regional Medical Center

Colton, California

Neurosurgery Residency Program Director

Desert Regional Medical Center

Palm Springs, California

31 illustrations

Thieme

New York • Stuttgart • Delhi • Rio de Janeiro

Executive Editor: Timothy Hiscock
Managing Editor: Sarah Landis
Editorial Assistant: Nikole Connors
Director, Editorial Services: Mary Jo Casey
Production Editor: Torsten Scheihagen
International Production Director: Andreas Schabert
International Marketing Director: Fiona Henderson
International Sales Director: Louisa Turrell
Director of Sales, North America: Mike Roseman
Senior Vice President and Chief Operating
Officer: Sarah Vanderbilt
President: Brian D. Scanlan
Printer: Sheridan Books, Inc.

Library of Congress Cataloging-in-Publication Data

Names: Siddiqi, Javed, 1962- editor.
Title: Neurosurgical intensive care / [edited by] Javed Siddiqi.
Other titles: Neurosurgical intensive care (Siddiqi)
Description: Second edition. | New York : Thieme, [2017] | Includes bibliographical references and index.
Identifiers: LCCN 2016057427 | ISBN 9781626232341 (softcover) | ISBN 9781626232358 (ebook)
Subjects: | MESH: Critical Care | Neurosurgical Procedures
Classification: LCC RC350.N49 | NLM WL 368 | DDC 616.8/0428-dc23 LC record available at <https://lccn.loc.gov/2016057427>

Copyright © 2017 by Thieme Medical Publishers, Inc.

Thieme Publishers New York
333 Seventh Avenue, New York, NY 10001 USA
+1 800 782 3488, customerservice@thieme.com

Thieme Publishers Stuttgart
Rüdigerstrasse 14, 70469 Stuttgart, Germany
+49 [0]711 8931 421, customerservice@thieme.de

Thieme Publishers Delhi
A-12, Second Floor, Sector-2, Noida-201301
Uttar Pradesh, India
+91 120 45 566 00, customerservice@thieme.in

Thieme Publishers Rio de Janeiro,
Thieme Publicações Ltda.
Edifício Rodolpho de Paoli, 25º andar
Av. Nilo Peçanha, 50 – Sala 2508
Rio de Janeiro 20020-906 Brasil
+55 21 3172-2297 | +55 21 3172-1896

Cover illustration: Andrea Hines
Typesetting by DiTech Process Solutions

Printed in the U.S. by Sheridan Books Inc. 5 4 3 2 1


ISBN 978-1-62623-234-1

Also available as an e-book:
eISBN 978-1-62623-235-8

Important note: Medicine is an ever-changing science undergoing continual development. Research and clinical experience are continually expanding our knowledge, in particular our knowledge of proper treatment and drug therapy. Insofar as this book mentions any dosage or application, readers may rest assured that the authors, editors, and publishers have made every effort to ensure that such references are in accordance with the **state of knowledge at the time of production of the book.**

Nevertheless, this does not involve, imply, or express any guarantee or responsibility on the part of the publishers in respect to any dosage instructions and forms of applications stated in the book. **Every user is requested to examine carefully** the manufacturers' leaflets accompanying each drug and to check, if necessary in consultation with a physician or specialist, whether the dosage schedules mentioned therein or the contraindications stated by the manufacturers differ from the statements made in the present book. Such examination is particularly important with drugs that are either rarely used or have been newly released on the market. Every dosage schedule or every form of application used is entirely at the user's own risk and responsibility. The authors and publishers request every user to report to the publishers any discrepancies or inaccuracies noticed. If errors in this work are found after publication, errata will be posted at www.thieme.com on the product description page.

Some of the product names, patents, and registered designs referred to in this book are in fact registered trademarks or proprietary names even though specific reference to this fact is not always made in the text. Therefore, the appearance of a name without designation as proprietary is not to be construed as a representation by the publisher that it is in the public domain.



This book, including all parts thereof, is legally protected by copyright. Any use, exploitation, or commercialization outside the narrow limits set by copyright legislation without the publisher's consent is illegal and liable to prosecution. This applies in particular to photostat reproduction, copying, mimeographing or duplication of any kind, translating, preparation of microfilms, and electronic data processing and storage.

This second edition of Neurosurgical Intensive Care is dedicated to my wife, Seema, and to my children Amman and Saira, who inspire me to keep doing my best. It is also dedicated to my sisters, Shahina and Zarina, who always kept me on track, and represent the earliest and most enduring source of support in my life.

Contents

Foreword	x
Preface	xi
Acknowledgments	xiii
Contributors	xiv
1. Bedside Neurologic Exam	1
<i>Robert Dahlin, Dan E. Miulli, and Javed Siddiqi</i>	
2. Altered Mental Status and Coma: Pathophysiology and Management	25
<i>Jason Duong, Shokry Lawandy, Jeffery M. Jones, Dan E. Miulli, and Javed Siddiqi</i>	
3. Neuroimaging and the Neurosurgical Intensive Care Unit Patient	46
<i>Christopher Elia, Blake Berman, and Dan E. Miulli</i>	
4. Diagnostic Laboratory Studies in the ICU Patient: What, When, and How Often?	59
<i>John Ogunlade, Dan E. Miulli, and Jon Taveau</i>	
5. Team Management of the Multisystem-Injured Neurosurgical Intensive Care Unit Patient	94
<i>Mark Krel, Javed Siddiqi, Silvio Hoshek, Rosalinda Menoni, Vladimir Adriano Cortez, Jeff W. Chen, and David T. Wong</i>	
6. The Spinal Cord Injury Patient	103
<i>Christopher Elia, Blake Berman, Jeffery M. Jones, Shokry Lawandy, Yancey Beamer, and Dan E. Miulli</i>	
7. Delayed Intracerebral Hemorrhage	116
<i>Tyler Carson, Marc Billings, Todd M. Goldenberg, Vladimir Adriano Cortez, and Dan E. Miulli</i>	
8. Sedation and Pain Management in the Neurosurgical Intensive Care Unit Patient	138
<i>Gohar Majeed and Dan E. Miulli</i>	
9. Homeostatic Mechanisms in the Neurosurgical Intensive Care Unit Patient	168
<i>Jerry Noel, Dan E. Miulli, Gayatri Sonti, and Javed Siddiqi</i>	

10. Neurophysiology in the Neurosurgical Intensive Care Unit: Options, Indications, and Interpretations.....	177
<i>Tyler Carson, Dennis Cramer, and Dan E. Miulli</i>	
11. Cerebral Perfusion	194
<i>Deependra Mahato, Kevin Ray, Dan E. Miulli, and Javed Siddiqi</i>	
12. Cerebrospinal Fluid Dynamics and Pathology.....	213
<i>Deependra Mahato, Kevin Ray, John D. Cantando, Dan E. Miulli, and Javed Siddiqi</i>	
13. Intracranial Pressure Fundamentals	225
<i>Tyler Carson, Dan E. Miulli, and Javed Siddiqi</i>	
14. Cerebral Protection Measures	235
<i>Tyler Carson, Dennis Cramer, Dan E. Miulli, and Javed Siddiqi</i>	
15. Neuropharmacology	248
<i>John Ogunlade, Nicholas Qandah, and Dan E. Miulli</i>	
16. Nutrition.....	276
<i>Jerry Noel, Silvio Hoshek, Rosalinda Menoni, and Dan E. Miulli</i>	
17. Fluid Management	300
<i>Samir Kashyap, Robert Dahlin, Raed Sweiss, James Berry, and Dan E. Miulli</i>	
18. Ventilator Management.....	329
<i>Justen Watkins, Dan E. Miulli, James Berry, Glenn Fischberg, and Javed Siddiqi</i>	
19. Seizure Disorders: Diagnosis and Management	349
<i>Vivek Ramakrishnan, Margaret Wacker, Dan E. Miulli, and Glenn Fischberg</i>	
20. Infections.....	358
<i>Marc Cabanne and Dan E. Miulli</i>	
21. Cerebral Microdialysis in the Neurosurgical Intensive Care Unit.....	388
<i>Jeff W. Chen, Daniella Abrams-Alexandru, and Javed Siddiqi</i>	
22. Anticoagulation and Antiplatelet Therapy in the Neurosurgical Intensive Care Unit	401
<i>Bo-Lin Liu and Javed Siddiqi</i>	
23. Restraints in the Neurosurgical Intensive Care Unit Patient.....	410
<i>Colleen Rose and Justen Watkins</i>	
24. Unique Pediatric Neurosurgical Intensive Care Unit Issues.....	420
<i>Tanya Minasian, Daniel J. Won, and Dan E. Miulli</i>	

25. Systemic Complications and Disease-Specific Phenomena Leading to Ischemic Injury	434
<i>Hammad Ghanchi and Dan E. Miulli</i>	
26. Acute Ischemic Stroke	463
<i>Robert J. Claycomb, Luis T. Arangua, Vladimir Adriano Cortez, Glenn Fischberg, and Javed Siddiqi</i>	
27. Brain Death	473
<i>Omid R. Hariri and Dan E. Miulli</i>	
28. Family Communication	490
<i>Mark Krel and Dan E. Miulli</i>	
29. Spiritual Care of the Neurosurgical Intensive Care Unit Patient and Family	516
<i>John Spitalieri, Marc Billings, and Javed Siddiqi</i>	
30. Medical-Legal Issues in the Neurosurgical Intensive Care Unit	527
<i>Bailey Zampella, Dan E. Miulli, Silvio Hoshek, Rosalinda Menoni, and Yancey Beamer</i>	
31. Discharge Planning for the Neurosurgical Intensive Care Unit Patient	539
<i>Dan E. Miulli, Jacob Bernstein, and Paula Snyder</i>	
Index	546

Foreword

Neurosurgical intensive care is a multispecialty and multidisciplinary field dedicated to improving the care and outcomes of patients with neurologic conditions. Over the past 20 years I have watched the field grow in terms of perceived need, knowledge, and acceptance across a growing number of medical specialties and disciplines. It is clearly evident in this text, which includes contributors from the specialties of neurology, vascular neurology, neurosurgery, interventional neuroradiology, anesthesiology, and critical care as well as the disciplines of nutrition and advanced practice nursing. This change has been driven as much by advances in medical knowledge and techniques as by the vision of its practitioners, such as the editor and contributors to this second edition of *Neurosurgical Intensive Care*.

By bringing together this breadth of expertise to update this concise and focused handbook, Javed Siddiqi has created a tool for practitioners from a wide range of specialties and disciplines who take care of critical neurological patients.

The format of this handbook lends itself to being easy to read, concise, and to the point. While it is not meant to be comprehensive, it captures the most important key points that are necessary for thoughtful clinical decision making. The tables and figures provide easy-to-use tools that facilitate rapid evaluation and decision making, both for trainees in neurocritical care as well as for experienced practitioners in related fields.

Dr. Siddiqi's *Neurosurgical Intensive Care* is a succinct and highly practical handbook for understanding the basics of patient management in the neurosurgical intensive care unit setting. Whether the reader is a nurse, medical student, resident, fellow or an attending physician, it is the best quick reference for managing critically ill neurosurgical patients.

Yan Qu, MD, PhD

Professor

Director of the Division of Neurosurgery

The Fourth Military Medical University

Xi'an, Shaan Xi, China

Preface

With the obvious exception of primary brain trauma, cerebral ischemia appears to be the final common pathway for most brain damage, whether from stroke, vasospasm, secondary brain injury, or tumor proliferation. Interestingly, the cornu ammonis 1 (CA1) pyramidal neurons of the hippocampus appear to be the most vulnerable to global cerebral ischemia, being the first to die, whereas motor cortex neurons appear to be relatively resistant to the same ischemia.¹ The fact that CA 1 neurons are essential for cognitive (“higher”) functions, such as spatial learning and memory, versus motor cortex neurons serving movement, raises interesting questions about the evolutionary priority of memory over muscle, and learning over locomotion. While evolutionary biologists theorize about the fragility of higher brain functions over gross motor ability, the neurointensivist understands very clearly what is at stake—the patient who is physically intact, but cannot formulate new memories, concentrate, or analyze complex situations is also devastated in a way not always clinically self-evident. In short, if we can rescue CA1 neurons from the shadow of death, perhaps we stand a chance to preserve all other brain functions.²

The critical care of neurosurgical patients has evolved also over the recent two decades from an emphasis on pulmonary care (ventilation and oxygenation) to a more nuanced understanding of cerebral protection measures necessary to manage a disrupted blood-brain barrier. The advances in neuro-monitoring methods are leading the way toward a more directed and individualized care plan for the neurocritical care patient. For example, the use of intracranial pressure monitors, external ventricular devices, brain tissue oxygen monitoring devices, and cerebral microdialysis are opening up a new frontier for tailoring interventions to the uniqueness of

each patient’s condition; the increasing use of continuous electroencephalography in the intensive care unit (ICU) has also rendered the invisible, silent status epilepticus, visible. Now, the traditional ICU management of fluid and electrolyte correction, as well as ventilator manipulation, has become dramatically more complex.

For the neurosurgeon involved in neurocritical care, decompression is still the mainstay of surgical intervention. For example, we still evacuate traumatic hematomas, perform hemicraniectomies for malignant edema from ischemic stroke, and resect malignant brain tumors causing mass effect; however, decompression is often insufficient as a stand-alone measure, and a large proportion of neurocritical care patients never go to the operating room. Whether our patients need open surgery or not, a nuanced understanding of neurophysiology is the best approach to neuron rescue. An evolution away from a mechanistic approach has rendered neurocritical care a multidisciplinary effort.

In this age of cerebral monitoring, after the ABCs of resuscitation, the key principles to neurocritical care follow age-old maxims of sound clinical practice: prompt diagnosis; compassionate communication with the patient and family; frequent neurologic exams to guide care; high-quality nursing; multidisciplinary collaboration; titration of therapies to avoid over- or undershooting desired goals; prudent use of blood work and neuroimaging to determine etiology of any neurological fluctuation or decline; and aggressive and early use of surgical intervention when necessary.

Finally, there is an ongoing debate among intensivists whether, when compared to general medical intensive care units, dedicated neurocritical care units improve outcomes for typical neurologic and neurosurgical patients with head injury, hydrocephalus, ischemic or

hemorrhagic stroke, status epilepticus, intracranial hypertension, and the like. Although the answer to this question may be intuitive to neurointensivists, the evidence for this conclusion is becoming increasingly clear if we consider individual categories of diseases or conditions treated in a typical neurocritical care unit. For example, in their study of outcome after intracerebral hemorrhage, Diringer and Edwards reported that treatment in dedicated neurocritical care units was associated with a 3.4-fold reduction in hospital mortality rate compared with management of similar patients in general ICUs.³ Other authors have shown similar findings for traumatic brain injury.^{4,5} Perhaps the best example of the advantage of dedicated neurocritical care units comes from the management of ischemic stroke in the United States, where the highest level of national stroke accreditation for any hospital, “comprehensive stroke center,” is not permitted without a dedicated neurocritical care unit. Certainly, the neurocritical care unit is the hub of stroke care in

any comprehensive stroke center, involving real-time collaboration between stroke neurologists, neurointerventionalists, neurosurgeons, and neurointensivists.

Every credible trauma or stroke center should aspire to establishing a high-caliber neurocritical care unit, which is the ideal place for protocol-driven treatment of neurologic and neurosurgical diseases and conditions that may otherwise suffer from “ad hocery”; they are also uniquely equipped with specialty trained neurospecialists who can work and learn together. Another clear value of dedicated neurocritical care units is their ability to advance the frontiers of clinical neuroscience research and training in a way not hitherto possible in other venues. The presence of dedicated neurocritical care units attracts talented neurosurgeons and neurologists interested in advancing the frontiers of this expanding specialty. Luckily for the neurologic and neurosurgical patients who are their greatest beneficiaries, neurocritical care units are here to stay.

Javed Siddiqi, MD, DPhil (Oxon)

1. Zhu H, Yoshimoto T, Imajo-Ohmi S, Dazortsava M, Mathivanan A, Yamashima T. Why are hippocampal CA1 neurons vulnerable but motor cortex neurons resistant to transient ischemia? *J Neurochem* 2012;120(4):574–585
2. Bendel O, Bueters T, von Euler M, Ove Ogren S, Sandin J, von Euler G. Reappearance of hippocampal CA1 neurons after ischemia is associated with recovery of learning and memory. *J Cereb Blood Flow Metab* 2005;25(12):1586–1595
3. Diringer MN, Edwards DF. Admission to a neurologic/neurosurgical intensive care unit is associated with reduced mortality rate after intracerebral hemorrhage. *Crit Care Med* 2001;29(3):635–640
4. Patel HC, Menon DK, Tebbs S, Hawker R, Hutchinson PJ, Kirkpatrick PJ. Specialist neurocritical care and outcome from head injury. *Intensive Care Med* 2002;28(5):547–553
5. Clayton TJ, Nelson RJ, Manara AR. Reduction in mortality from severe head injury following introduction of a protocol for intensive care management. *Br J Anaesth* 2004;93(6):761–767

Acknowledgments

First and foremost, I want to thank all the patients and families who have inspired this second edition of *Neurosurgical Intensive Care*, and the pursuit of life-long learning and improvement it represents. I want to express my immense gratitude to Dr. Dan Miulli, who has been my right hand in this venture, and whose fingerprints are on every part of this book. Thanks also to all my residents, fellows,

colleagues, and other contributors to this second edition for an outstanding job, as well as to my staff (Dr. Fadi Andraos, Madeline Castorena, Maryann Duran), who assisted with various critical logistics. I am eternally grateful to my Thieme editors, Sarah Landis and Timothy Hiscock, who patiently kept me on track despite multiple detours.

Contributors

Daniella Abrams-Alexandru, MD

Neurosurgeon
Cape Fear Valley Medical Center
Fayetteville, North Carolina

Luis T. Arangua, MD

Stroke Neurologist and NeuroInterventionalist
Desert Regional Medical Center
Palm Springs, California

Yancey Beamer, MD

Neurosurgeon
Riverside University Health System Medical
Center
Moreno Valley, California

Blake Berman, DO

Neurosurgeon
Desert Regional Medical Center
Palm Springs, California

Jacob Bernstein, DO, MS

Neurosurgery Resident
Riverside University Health System Medical
Center
Moreno Valley, California

James Berry, DO

Neurosurgery Resident
Riverside University Health System Medical
Center
Moreno Valley, California

Marc Billings, DO

Neurosurgery Resident
Riverside University Health System Medical
Center
Moreno Valley, California

Marc Cabanne, DO

Neurosurgery Resident
Riverside University Health System Medical
Center
Moreno Valley, California

John D. Cantando, DO

Neurosurgeon
Jupiter Medical Center
Jupiter, Florida

Tyler Carson, DO

Neurosurgery Resident
Riverside University Health System Medical
Center
Moreno Valley, California

Jeff W. Chen, MD

Neurosurgeon, Associate Clinical Professor
Department of Neurological Surgery
UC Irvine Health
Irvine, California

Robert J. Claycomb, MD, PhD

Stroke Neurologist
Desert Regional Medical Center
Palm Springs, California

Vladimir Adriano Cortez, DO

Neurosurgeon and NeuroInterventionalist
Desert Regional Medical Center
Palm Springs, California

Dennis Cramer, DO

Neurosurgeon
Riverside University Health System Medical
Center
Moreno Valley, California

Robert Dahlin, DO

Neurosurgery Resident
Riverside University Health System Medical
Center
Moreno Valley, California

Jason Duong, DO

Neurosurgery Resident
Riverside University Health System Medical
Center
Moreno Valley, California

- Christopher Elia, DO**
Neurosurgery Resident
Riverside University Health System Medical Center
Moreno Valley, California
- Glenn Fischberg, MD**
Stroke Neurologist and Neurointensivist
Desert Regional Medical Center
Palm Springs, California
- Hammad Ghanchi, DO, MS**
Neurosurgery Resident
Riverside University Health System Medical Center
Moreno Valley, California
- Todd M. Goldenberg, MD**
Chief of Neurosurgery
Kaiser Permanente
Fontana, California
- Omid R. Hariri, DO, MS**
Neurosurgery Resident
Riverside University Health System Medical Center
Moreno Valley, California
- Silvio Hoshek, MD**
Neurosurgeon
Arrowhead Regional Medical Center
Colton, California
- Jeffery M. Jones, DO**
Neurosurgeon
Memorial Hospital of Carbondale
Carbondale, Illinois
- Samir Kashyap, DO**
Neurosurgery Resident
Riverside University Health System Medical Center
Moreno Valley, California
- Mark Krel, DO**
Neurosurgery Resident
Riverside University Health System Medical Center
Moreno Valley, California
- Shokry Lawandy, DO**
Neurosurgeon
Riverside University Health System Medical Center
Moreno Valley, California
- Bo-Lin Liu, MD, PhD**
Neurosurgeon
Department of Neurosurgery
Tangdu Hospital, Fourth Military Medical University
Xi'an, China
- Deependra Mahato, DO, MS**
Neurosurgery Fellow
Mayo Clinic
Jacksonville, Florida
- Gohar Majeed, DO, MS**
Neurosurgery Resident
Riverside University Health System Medical Center
Moreno Valley, California
- Rosalinda Menoni, MD**
Neurosurgeon
Desert Regional Medical Center
Palm Springs, California
- Tanya Minasian, DO**
Pediatric Neurosurgery Fellow
Children's Hospital
Los Angeles, California
- Dan E. Miulli, DO, MSc, FACOS**
Neurosurgeon & Residency Program Director
Riverside University Health System Medical Center
Moreno Valley, California
- Jerry Noel, DO**
Neurosurgeon
Desert Regional Medical Center
Palm Springs, California

John Ogunlade, DO

Neurosurgery Resident
Riverside University Health System Medical
Center
Moreno Valley, California

Nicholas Qandah, DO

Neurosurgeon
Mohawk Valley Health System Medical Group
New Hartford, New York

Vivek Ramakrishnan, DO

Spine Fellow
UC San Diego
San Diego, California

Kevin Ray, DO

Neurosurgery Resident
Riverside University Health System Medical
Center
Moreno Valley, California

**Colleen Rose, RN, BSN, MS, CNRN, SCRNP,
APRN, NP-C**

Neurosurgery & Neurocritical Care Nurse
Practitioner
Desert Regional Medical Center
Palm Springs, California

**Javed Siddiqi, HBSc, MD, DPhil (Oxon),
FRCS, FAANS, FACS**

Chair of Neurosurgery
Riverside University Health System Medical
Center
Moreno Valley, California
Chief of Neurosurgery
Arrowhead Regional Medical Center
Colton, California
Neurosurgery Residency Program Director
Desert Regional Medical Center
Palm Springs, California

Paula Snyder, RN, CCRN

ICU Nurse Manager
Riverside University Health System Medical
Center
Moreno Valley, California

John Spitalieri, DO

Neurosurgeon
NC Neurosurgery and Spine Clinic
Fayetteville, North Carolina

Gayatri Sonti, DO, MS, PhD

Neurosurgeon
Neuro & Headache Center
Rockford, Illinois

Raed Sweiss, DO

Skull Base Neurosurgery Fellow
Oregon Health and Science University
Portland, Oregon

Jon Taveau, DO

Neurosurgeon
Mount Vernon, Illinois

Margaret Wacker, MD, MS

Neurosurgeon
Arrowhead Regional Medical Center
Colton, California

Justen Watkins, DO

Neurosurgery Resident
Riverside University Health System Medical
Center
Moreno Valley, California

Daniel J. Won, MD

Neurosurgeon
Kaiser Permanente
Fontana, California

David T. Wong, MD, FACS

Chief of Trauma and Critical Care Services
Arrowhead Regional Medical Center
Colton, California

Bailey Zampella, DO

Neurosurgery Resident
Riverside University Health System Medical
Center
Moreno Valley, California

1 Bedside Neurologic Exam

Robert Dahlin, Dan E. Miulli, and Javed Siddiqi

Abstract

The bedside neurologic exam is the most sensitive test to determine the condition of the patient in the neurosurgical intensive care unit. It should be conducted frequently and consistently, whether the person is in a coma or not. Each part of the neurologic exam, from higher mentation to the cranial nerve exam and motor, sensory, and reflex exam, pinpoints the astute clinician to a specific pathology and anatomy.

Keywords: aphasia, coma, cortical exam, cranial nerve exam, eye exam, Glasgow Coma Scale, motor testing, verbal testing

Case Presentation

A 46-year-old woman presented to the emergency room with a spontaneous unilateral third nerve palsy manifested as a large, nonreactive pupil and minimal or no eye movement abnormalities. The patient had had a severe, and uncharacteristic, headache 2 days earlier, and she came to the emergency room only because of blurred vision. Other than the eye finding, the patient was awake and alert and in no acute distress, with a normal neurologic exam.

See end of chapter for Case Management.

1.1 Introduction

Patients admitted to the neurosurgical intensive care unit (NICU) are among the most critically ill and unstable. Many are admitted for traumatic brain injury, aneurysmal subarachnoid hemorrhage, spinal cord injury, postoperative craniotomies, stroke, and much more. With the advent of improved laboratory data and advanced imaging techniques, the physical examination has become less emphasized in training. While imaging and laboratory data augment our clinical decision making, the decision to order these tests and their interpretation should be influenced by the patient's physical exam. A detailed physical examination, with attention to all of the subtleties, is necessary to guide the treatment of a patient and the decision to order tests. Knowledge of the physical examination and its terminology also allows for more effective communication among health care workers whose clinical decision making will rely on the information passed down to them.

1.2 The Power of Observation

In the NICU, as elsewhere, the art of medicine should never be underestimated. While in many NICU patients, the neurologic exam is rendered more difficult by sedation, intubation, and paralytics, leaving the neurosurgeon and his or her team to rely on invasive monitoring data, serial neuroimaging, and intermittently withholding sedation to assess the patient, observation is still an important component of the patient’s examination. For example, the obtunded or comatose patient breathing rhythmically in a specific pattern offers important lesion-localizing clues to the astute neurosurgeon (► Table 1.1). Observation of asymmetric spontaneous movements of the extremities, or change in their frequency, can be another clue to evolving brain or spinal cord lesions.

In the smaller number of awake patients in the NICU, the neurosurgeon has greater leeway to observe and converse with the patient. In these patients, observing whether they show any subtle localizing signs may betray early and enlarging focal lesions in the brain. For example, the patient who complains of

Table 1.1 Breathing patterns in brain injury

Breathing with rostral to caudal progression of lesions	Pattern	Location of lesion
Cheyne–Stokes	Periodic crescendo–decrecendo amplitude longer than variable pause, then repeat, yielding respiratory alkalosis	Generalized cerebral forebrain or midbrain lesion, metabolic encephalopathy without brainstem injury; impending herniation, congestive heart failure
Reflex hyperventilation	Hyperventilation with hypocapnia	Pons tegmentum, midbrain, reticular formation; psychiatric, metabolic acidosis, pulmonary congestion, hepatic encephalopathy
Apneustic	Irregular full inspiration then irregular pause	Pons, dorsal medulla, metabolic coma, transtentorial herniation
Cluster	Rapid irregular then pause	Pons, upper medulla, posterior fossa lesion; greatly increased intracranial pressure
Ataxic	No pattern	Medulla, acute posterior fossa lesion
No autonomic respiration (Ondine’s curse)	Loss of autonomic respirations—awake normal breathing, no breathing during sleep or distraction	Reticular nucleus of medulla (respiratory center)
Apnea	No breathing	Bilateral damage to caudal medulla reticular nucleus
Kussmaul	Deep regular inspiration	Metabolic acidosis

a focal headache and who holds his hand over his head in the same area repeatedly, and on request is able to point to a specific area of his head as the site of most discomfort, may be helping the neurosurgeon with localization of an existent or developing lesion (tumor, hematoma, abscess, edema, etc.). This ability of the awake patient to localize the lesion for the neurosurgeon by effectively putting a finger on where it hurts the most, or showing the “Siddiqi sign,” constitutes an observation and communication component of the neurologic exam with significant interobserver reliability (in patients without the confounding variables of recent soft tissue bruising or incision on the head). The value of focality of the Siddiqi sign is lost when the patient complains of a global headache, or pain “all over.” A conscious attempt should be made in the NICU to not dismiss the initial observation of the patient in favor of exhaustive analyses of numerous data sets generated by an ever-increasing number of invasive monitoring techniques.

1.3 Coma

1.3.1 Glasgow Coma Scale

First published in 1974 by Graham Teasdale and Bryan Jennett, the Glasgow Coma Scale (GCS) has become a universally used tool for measuring a patient's overall state of alertness. Its score often guides medical decision making in neurointensive care. Despite its seeming simplicity there exists significant interrater variability. In an attempt to decrease this variability, a discussion will follow detailing the subtleties of this scale.

The GCS is calculated by adding up the points from each category, with motor receiving 6 points, verbal receiving 5, and eyes receiving 4. During an examination, the best scores for all three categories will be added together (► Table 1.2, ► Table 1.3). Patients are considered to be in a coma with a GCS of 8 or less.

Table 1.2 Glasgow Coma Scale (age 4 or more)

Points	Motor best response	Verbal/speech best response	Eyes best response
6	Obeys commands	–	–
5	Localizes to pain	Oriented conversation	–
4	Withdraws from pain	Confused conversation	Opens spontaneous
3	Decorticate—flexes abnormally	Inappropriate words	Opens to name or verbal stimuli
2	Decerebrate—rigid extension	Incomprehensible sounds	Opens to pressure/pain
1	No movement	No speech response	No eye opening
3–15	Add the totals of best responses from each column		

Table 1.3 Children’s Coma Scale (age less than 4)

Points	Motor best response	Verbal/speech best response	Eyes best response
6	Obeys commands	–	–
5	Localizes to pain	Oriented, smiles, follows objects	–
4	Withdraws from pain	Confused but consolable	Opens spontaneous
3	Decorticate—flexes abnormally	Inappropriate, moaning	Opens to name or verbal stimuli
2	Decerebrate—rigid extension	Incomprehensible sounds, inconsolable	Opens to pressure/pain
1	No movement	No speech response	No eye opening
3–15	Add the totals of best responses from each column		

1.3.2 Motor Score

The motor score is measured out of a total of 6 points. A score of 6 points is given when a patient follows commands. Standard commands include asking patients to give a thumbs up, show two fingers, stick out their tongue, or wiggle their toes. Caution should be given when asking a patient to squeeze the examiner’s hand during this part of the exam because this can often represent a frontal release sign in patients with lesions of the frontal lobe and may not indicate true command following.¹ Because of this, it is not recommended to use hand squeeze as a command. A score of 5 is given for localization. This can be interpreted as any purposeful movement performed by the patient, such as a limb crossing the midline to reach for painful stimuli or an endotracheal tube, to scratch an itch, or to fix the blanket. A score of 4 is given for withdrawal from painful stimuli. This can be given for a patient who tries to move away from a painful stimulus or who grimaces with pain. It is important not to confuse withdrawal with a spinal reflex. Withdrawal is held, whereas spinal reflexes return to a normal position while the stimulus is still being applied. The best location to perform a painful stimulus to determine withdrawal versus reflex is on the inner aspect of the upper arm. In withdrawal, the patient will move the arm away from the torso, or abduct the arm. In a reflex response, the patient will bring the arm closer to the torso, or adduct the arm. A score of 3 is given for abnormal flexion in response to painful stimuli. This is called the decorticate response and can include flexion at the biceps, wrist, or thighs or dorsiflexion without localizing to the stimuli. Decorticate posturing localizes the lesion in the brain to be above the red nucleus. Special attention should be given to the triple flexion response, which is often misinterpreted. It occurs in response to painful stimuli of the toes when a patient will dorsiflex the foot, flex at the knee, and flex at the thigh and is a form of decorticate posturing. A

score of 2 is given for extensor posturing, also known as decerebrate posturing. In decerebrate posturing, there is disruption between the superior colliculi or the decussation of the rubrospinal pathway and the rostral portion of the vestibular nuclei. Decerebrate posturing consists of extension of the upper or lower extremities in response to painful stimuli. A score of 1 is given for no motor response to stimulation.

1.3.3 Verbal Score

The verbal score is measured with a total of 5 points. A score of 5 is given to patients who are oriented to name, where they are at, the date or year, and the reason they are in the hospital. Inability to answer these questions reliably constitutes a disoriented patient. A score of 4 is given when a patient is unable to answer all questions regarding orientation. However, the patient must be able to attempt to answer questions with a response that is appropriate to the question being asked. A score of 3 is given when a patient's response to a question is inappropriate to what was asked. A score of 2 is given when a patient's verbal responses are inaudible. This is constituted by mumbling, grunts, or other produced sounds. A score of 1 is given when a patient is nonverbal despite stimulation or questioning. All intubated patients receive a score of 1. However, to signify that their poor GCS score is a reflection of intubation and not neurologic injury a *T* will be placed at the end of the score to signify the patient cannot receive those points.

1.3.4 Eye Score

The eye score is measured with a total of 4 points. A score of 4 is given to patients who can open their eyes spontaneously or who, after being awakened, continue to keep their eyes open. It is important that patient not be given a score of 4 if the patient's eyes are stuck open. A score of 3 is given to patients who are able to open their eyes to voice or their name. A score of 2 is given to patients who are able to open their eyes only when stimulated with pain. A score of 1 is given to patients who do not open their eyes despite the level of stimulation given.

1.4 Cranial Nerves

The neurosurgical patient's cranial nerves may be examined quickly at bedside. Cranial nerve examination is important in identifying and localizing lesions. Multiple pathologies result in cranial neuropathies, including stroke, Chiari malformations with or without syringobulbia, fungal meningitis, posterior

fossa surgery, cerebellopontine angle surgery, microvascular decompression of the trigeminal nerve, glomus jugulare tumors, and leptomeningeal carcinomatosis.

1.4.1 Cranial Nerve I: Olfactory Nerve

Olfaction is tested by supplying the patient with different odors and asking the patient to identify them. Each nostril should be tested individually. Allergic rhinitis is the most common cause of a loss or a decrease in smelling capacity. The most common neurologic cause results from significant head trauma that causes shearing of the olfactory bulb/fibers off the cribriform plate. Other causes include congenital diseases, such as Kallman syndrome, or tumors causing local compression.

1.4.2 Cranial Nerve II: Optic Nerve

Pupillary Light Reflex

The pupillary light reflex is perhaps the single most important neurologic reflex and the quickest way to get a neurosurgeon's attention. The reflex arc involved in the pupillary light reflex starts as light enters the retina and is transmitted along the optic nerve and synapses in the pretectal nucleus. Fibers from the pretectal nucleus then travel bilaterally to each Edinger–Westphal nucleus. From there, preganglionic parasympathetic fibers arise and travel with the oculomotor nerve and synapse in the ciliary ganglion and then travel in the short ciliary nerve to the sphincter muscle of the iris, leading to constriction of the pupil.

Afferent Pupillary Defect: Marcus Gunn Pupil

Afferent pupillary defect is caused by damage to the optic nerve. It can be identified by using the swinging light test. When light is directed toward the functional optic nerve the contralateral pupil will constrict normally. However, when the light is switched to the affected optic nerve, the pupil will dilate due to the pretectal nucleus receiving less light input from the damaged optic nerve.

Anisocoria

Differing pupillary diameters is termed anisocoria and is defined as a difference in pupillary size of at least 0.4 mm.² Anisocoria is present in 20% of the population and is generally not pathological until the difference is greater than 1 mm.³

Papilledema

Papilledema can be best viewed by funduscopic exam with pupillary dilation and is graded from 0 to 5 using the Frisen scale. Papilledema is characterized by haloing around the optic disc, elevation of the borders of the optic disc, and, at more severe stages, obscuration of the vessels at the optic disc. In studies it has been found to have a sensitivity of 100% and specificity of 98% for elevated intracranial pressure. However, this finding is age dependent, and in patients younger than 8 years old it indicates increased intracranial pressure in only 22% of patients.⁴

Visual Fields

Checking the visual fields is part and parcel of the cranial nerve II examination (see the discussion later in this chapter on this topic).

1.4.3 Cranial Nerve III: Oculomotor Nerve

The oculomotor nerve originates in the midbrain just anterior to the periaqueductal gray matter. The oculomotor nerve is responsible for innervation of the levator palpebrae superioris, medial rectus, inferior rectus, superior rectus, inferior oblique, and iris sphincter muscles. Loss of function of the oculomotor nerve can lead to pupillary dilation and an eye that deviates downward and laterally.

Pupil-Sparing Third Nerve Palsy

The nerve fibers that innervate the extraocular muscles travel on the periphery of the nerve and are subject to damage by microvascular pathology, such as hypertension, diabetes, or dyslipidemia. These palsies are typically incomplete and temporary, usually resolving within 3 months.⁵

Non-Pupil-Sparing Third Nerve Palsy

Multiple etiologies exist that result in unilateral dilation of a pupil, ranging from benign to life threatening and requiring emergent intervention. Although it is more typical of a neurocritical care patient to have malignant underlying pathologies, knowledge of the other causes is important to keep in mind when composing a differential diagnosis.

Mass Lesion

A mass lesion that results in uncal herniation and compression of the oculomotor nerve will lead first to a dilated pupil, followed by a nonreactive pupil.

Causes include intracerebral hemorrhage, cytotoxic edema from a stroke, subdural or epidural hematomas, and tumor. A special circumstance involving unilateral pupil dilation includes a posterior communicating artery aneurysm exerting local pressure on the oculomotor nerve.

Traumatic Mydriasis

Traumatic mydriasis arises from traumatic injury to the globe and results from either tearing of the iris sphincter muscle fibers or its nerve fibers innervating it.

Horner's Syndrome

Horner's syndrome consists of unilateral miosis, ptosis, enophthalmos, and anhidrosis. This is caused by a disruption at any point in the sympathetic innervation to the eye. Ptosis and enophthalmos are due to paralysis of Müller's muscles of the tarsal plates. Anhidrosis is due to sympathetic chain disruption in the carotid sheath.⁶ Etiologies are numerous, but include Pancoast's tumor, lower cervical cord lesion, carotid injury/dissection, posterior inferior cerebellar artery occlusion (as a part of Wallenberg's syndrome), syringobulbia, and others.⁷

Adie's Pupil

Adie's pupil presents as a dilated pupil that is slow to react with light, but with almost normal response to accommodation. Adie's tonic pupil is thought to be caused by either a viral or a bacterial infection that leads to damage of the ciliary ganglion. Because patients with an Adie's pupil have damage only to the ciliary ganglion, the pupil will respond to parasympathomimetics, such as pilocarpine.

1.4.4 Cranial Nerve IV: The Trochlear Nerve

The trochlear nerve (CN IV) supplies the superior oblique muscle of the eyeball. It completely decussates in the superior medullary velum at the level of the inferior colliculus before exiting the brainstem posteriorly. Patients with trochlear nerve palsy will complain of double vision with downward gaze. On exam, the patient's pathological eye will be slightly more superior on downward medial gaze. Asking the patient to tilt the head to the contralateral side will improve the diplopia, whereas tilting the head to the ipsilateral side will worsen the diplopia.⁸

1.4.5 Cranial Nerve V: Trigeminal Nerve

The trigeminal nerve (CN V) is the largest nerve and exits the midlateral pons to supply sensation to the face and dura of the anterior and middle fossae (portio major nervi trigemini). Motor function is subserved by the motor root (portio minor nervi trigemini) supplying the muscles of mastication, tensor veli palatini, tensor tympani, and anterior belly of the digastric and mylohyoid muscles.

Corneal Reflex

The corneal reflex is elicited by stimulation of the cornea or eyelid with reflexive blinking of the eye. The afferent limb is conducted by the trigeminal nerve to the spinal trigeminal nucleus. The efferent limb is conducted by the facial nerve to elicit blinking. The V1 distribution of the trigeminal nerve can be tested by brushing either the upper eyelid or the sclera. The V2 distribution can be tested by brushing the lower eyelid.

Sensation

To test sensation each distribution of the trigeminal nerve should be checked for intact light touch, pinprick, and temperature. Each side should be compared to the patient's contralateral side because this can elucidate subtle deficiencies in sensation.

Motor

Motor can be tested by touching the cheeks and asking the patient to bite down and the examiner feels for the strength of the muscles of mastication.

1.4.6 Cranial Nerve VI: Abducens Nerve

The abducens nerve (CN VI) supplies the lateral rectus muscle of the eye. Malfunction of this cranial nerve can lead to double vision for the patient, with the affected eye being incapable of moving laterally past midline, resulting in the two eyes becoming dysconjugate.

1.4.7 Cranial Nerve VII: Facial Nerve

The facial nerve (CN VII) provides innervation to the facial muscles, platysma, and taste sensation to the anterior tongue. Motor function of CN VII to the face is tested by testing the platysma, smiling, pursing the lips, closing the eyes, and raising the eyebrows. Distinction of whether unilateral facial weakness is

forehead sparing is pertinent to localization of the lesion. The cortex supplies innervation to the frontalis muscle bilaterally, and a stroke or mass lesion of the primary motor cortex will lead to a forehead-sparing paralysis on the contralateral side. Destruction of the facial nucleus or nerve will lead to complete paralysis of the ipsilateral side. Sensation of the facial nerve is assessed by taste to the anterior two-thirds of the tongue.

1.4.8 Cranial Nerve VIII: Vestibulocochlear Nerve

The vestibulocochlear nerve (CN VIII) provides sensation for sound and balance. Testing these nerves in an awake patient requires detailed assessment of each testable division of each nerve.

Oculocephalic Reflex: Doll's Eye Reflex

The oculocephalic reflex is important for the stabilization of images on the retina as the body and head move through space. As the semicircular canals change in orientation, signals are sent to the vestibular nuclei and through the medial longitudinal fasciculus to stabilize the eyes. Movement of the head in a patient with a functional reflex will cause the eyes to move to the contralateral side. Absence of this will result in no reflexive movement of the eyes. The absence of movement of the eyes is referred to as the doll's eye reflex because, at the time when the reflex was discovered, the eyes of dolls were painted on and would hence not move with movement of the head.

Vestibulo-ocular Reflex

The vestibulo-ocular reflex is tested by instilling approximately 30 to 100 mL of ice water into the external auditory canal (with an intact tympanic membrane) with the head of the bed at approximately 30 degrees. Patients with intact function will have a slow, tonic gaze toward the side of stimulation. Those without this reflex continue to stare ahead. This test evokes severe nausea and vomiting in an awake patient. This is most often performed on deeply comatose patients or those with suspected brain death.

1.4.9 Cranial Nerve IX: Glossopharyngeal Nerve

Gag Reflex

Glossopharyngeal (CN IX) and vagus (CN X) nerve function can be assessed with the gag reflex. This may be performed in an awake patient by stimulating the posterior pharynx with a tongue blade. The afferent sensory limb of the

reflex stems from the glossopharyngeal nerve, and the motor limb from the vagus nerve.

1.4.10 Cranial Nerve X: Vagus Nerve

Cough Reflex

This reflex involves deep bronchial suctioning of an intubated patient. Sensory nerves within the bronchi respond to mechanical stimulation, sending afferents along the superior laryngeal nerve to the medulla. The efferents travel back along the vagus nerve to initiate a cough.

1.4.11 Cranial Nerve XI: Accessory Nerve

The accessory nerve is responsible for innervation of the sternocleidomastoid and trapezius muscles. The sternocleidomastoid can be tested by having patients rotate their head against the examiner's hand. The trapezius can be tested by having patients shrug their shoulders against resistance.

1.4.12 Cranial Nerve XII: Hypoglossal Nerve

The hypoglossal nerve innervates the muscles of the tongue and can be tested by having a patient stick the tongue out. Injury to this nerve can be visualized when a patient's tongue deviates to the ipsilateral side of injury. Caution should be exerted in a patient with facial paralysis because it can give the illusion of tongue deviation. To avoid this, the physician can ask the patient to touch the tongue to the nose.

1.5 Cortical Examination

1.5.1 Broca's Aphasia

Broca's aphasia results from damage to the dominant hemisphere's pars opercularis and pars triangularis. It is an expressive aphasia in which patients can comprehend what is said and they know what they would like to say in return, but they are unable to form the words. Patients are often able to use simple words, such as *yes* or *um*, or their name. Patients are often visibly frustrated. Patients with this aphasia are said to not have fluent speech.

1.5.2 Wernicke's Aphasia

Wernicke's aphasia results from damage to the dominant hemisphere's superior frontal gyrus. In this aphasia, patients are unable to comprehend what is

heard and are unable to respond appropriately. They are unaware of their deficit and produce speech that either is inappropriate to the question or is composed of nonsensical words. This is considered an aphasia with fluent speech.

1.5.3 Conduction Aphasia

Conduction aphasia results from damage to the arcuate fasciculus, which is involved in direct transfer of information from the Wernicke's to the Broca's area. Patients with conduction aphasia are able to comprehend speech and string together novel sentences but are unable to repeat a phrase given to them. A way to test this would be to ask a patient to repeat "no ifs, ands, or buts."

1.5.4 Gaze Deviation

Prévost's Sign

Also known as Vulpian's sign, this refers to the acute and transient gaze palsy in a frontal lesion (e.g., infarct), which is toward the side of the lesion and away from the concurrent hemiparesis. The eyes can be brought to the other side with the oculoccephalic maneuver or caloric testing. In contrast, thalamic and basal ganglia hemorrhages produce forced deviation of the eyes to the side contralateral to the lesion (wrong-way eyes).

Setting Sun Sign

The setting sun sign is defined as tonic downward deviation of the eyes and may include downbeating nystagmus. This results from midbrain compression of the interstitial nucleus of Cajal. It may exist with a constellation of other symptoms in Perinaud's syndrome. Perinaud's syndrome results from significant midbrain compression and presents with the setting sun sign, loss of pupillary light reflex, loss of convergence, and upper eyelid retraction.

1.5.5 Visual Fields

In order to understand deficits to the visual fields and how to localize the lesion within the brain, knowledge of the anatomy is crucial. The retina can be divided into the nasal hemiretina and the temporal hemiretina. Once light impacts the retina, impulses travel down the optic nerve where nerve fibers from the nasal hemiretina decussate at the optic chiasm to become the optic tract. Nerves of the optic tract synapse at the lateral geniculate ganglion. Nerve impulses then travel via the optic radiations to the primary visual cortex. Nerve

fibers pertaining to the contralateral superior quadrant travel to the visual cortex via Meyer's loop, which travels in the temporal lobe.

The visual fields can be tested by either kinetic or static perimetry at an ophthalmologist's office or at the bedside by a confrontational field exam. A bedside confrontational examination is difficult to perform and must be carried out in a specific way, and in experienced hands it is capable of detecting only approximately 40% of lesions.⁹ First a patient must cover one eye, then the physician will place a number of fingers in the right and left superior fields. A patient can then either state the number of fingers seen or note which ones appear blurrier or dimmer. The physician then can move to the inferior visual fields for testing. This is repeated for the contralateral eye and then without either eye being covered.

Monocular Blindness

Monocular blindness occurs from damage to the visual pathway anterior to the optic chiasm, which includes damage to the retina or the optic nerve. This typically occurs as a result of an embolic phenomenon from atherosclerotic disease. Temporary loss of vision as a result of embolic disease is termed amaurosis fugax.

Bitemporal Hemianopsia

Bitemporal hemianopsia results from damage to the central portion of the optic chiasm. This leads to bilateral loss of the temporal visual fields. The classic cause of this is a sellar mass, typically a pituitary adenoma.

Homonymous Hemianopsia

Homonymous hemianopsia results from damage to the visual pathway posterior to the optic chiasm. A complete lesion to the pathway leads to complete loss of vision of the contralateral visual fields. Typical causes include hemorrhagic stroke, ischemic stroke, or a mass lesion.

1.5.6 Hemineglect

Tactile Extinction

Tactile extinction is tested by applying a tactile stimulation bilaterally at the same time and asking the patient which side the stimulus occurred on. This can detect even subtle neglect at times. This can localize the lesion to the contralateral hemisphere.

Visual Extinction

Visual extinction is tested by asking a patient to add up the number of fingers simultaneously displayed bilaterally. The number of fingers on the side of neglect will often not be counted or recognized as present. This can localize the lesion to the contralateral hemisphere.

Hippus

This exam finding is characterized by irregular rhythmic dilation and contraction of the pupillary sphincter muscles. Hippus is often a normal phenomenon and may be seen in recovery from oculomotor nerve injury. It has been suggested by studies as an indication of underlying nonconvulsive status epilepticus.^{10,11,12}

1.6 Cerebellar Examination

1.6.1 Dysdiadochokinesia

Dysdiadochokinesia represents a patient's difficulty with performing rapid alternating movements. This can be assessed by either rapid pronation/supination of the arms or hands, or by having patients tap their foot on the floor as fast as possible. This can localize the lesion to the ipsilateral cerebellar hemisphere.

1.6.2 Dysmetria

Dysmetria is also referred to as past-pointing sign. Patients are asked to touch their index finger to the examiner's finger, which is placed at the far end of the patient's reach. Patients with dysmetria will reach for a point that exists past the examiner's finger. This can localize the lesion to the ipsilateral cerebellar hemisphere.

1.6.3 Heel to Shin

This maneuver is performed by asking a patient to run the heel up and down the contralateral shin. Jerky performance or poor coordination can localize the lesion to the ipsilateral cerebellar hemisphere.

1.7 Spinal Cord Examination

Patients presenting to the emergency room or trauma bay with a spinal cord injury require special consideration in their initial management. This initial

management and the potential need for immediate versus delayed surgical management will depend on the neurological findings on presentation and subsequent examinations during the patient's hospital stay.

The first indication that a patient may have a spinal cord injury occurs during the primary survey with the assessment of the ABCs. A patient presenting with hypotension and bradycardia may be the first indication of spinal cord injury and is suggestive of the patient being in either spinal shock or neurogenic shock.

Spinal shock must be differentiated from neurogenic shock during the initial evaluation to guide further management. Neurogenic shock results from a disruption of the autonomic pathways of the spinal cord above the level of T6¹³ and can last from 24 hours to 6 weeks. Neurogenic shock presents as a distributive shock with warm extremities, hypotension, and often bradycardia. Spinal shock is a complete loss of all spinal cord functions, reflexes, and autonomic support. Therefore all patients with spinal shock are also in neurogenic shock. The end of spinal shock is heralded by the return of spinal cord reflexes, with the deep plantar response typically being the first to return, followed by the bulbocavernosus reflex, the cremasteric reflex, the ankle jerk, Babinski's reflex, and finally the knee jerk.¹⁴

The degree of injury is classified using the American Spinal Injury Association (ASIA) grading system. Ten muscle groups (the deltoid or biceps, wrist extensors, triceps, flexor digitorum profundus, hand intrinsic, iliopsoas, quadriceps, tibialis anterior, extensor hallucis longus, and gastrocnemius) are tested individually and graded on a scale of 0 to 5, and a detailed sensory exam with a pin must be conducted to define the sensory level of the patient.

Injuries that lead to spinal cord injury typically require significant forces and high mechanisms of injury. As such it is not uncommon to have patients with concurrent brain injury who may be unresponsive or unable to participate in an examination. In such patients, as long as they are not in spinal shock, localization of the level of injury by physical exam will rely heavily on the spinal reflex portion of the exam because this will be unaffected by level of consciousness.

1.7.1 Strength Exam

Muscle strength is graded using the Royal Medical Research Council of Great Britain Scale. It is scored on a range from 0 to 5 (► Table 1.4), and muscle groups that are unable to be assessed secondary to casting or other immobilization must be recorded as not testable.

A knowledge of which nerves innervate a muscle or at which level they leave the spinal canal is also necessary for localization of a lesion and can be seen in ► Table 1.5.

Table 1.4 Muscle strength grading

The most caudal segment of the spinal cord with *normal* sensory and motor function on both sides of the body denotes the intact level.

Motor level is the caudal key muscle with at least grade 3 provided the key muscles above that level are judged to be normal

0	Total paralysis
1	Palpable or visible contraction
2	Active movement, gravity eliminated
3	Active movement against gravity
4-	Active movement against less resistance
4	Active movement against some resistance
4+	Active movement against more resistance
5	Active movement against full resistance
NT	Not testable

Table 1.5 Muscle innervation

Dermatome	Nerve	Action	Muscle	Reflex
XI	Spinal accessory	Shoulder shrug	Trapezius	
C2-C4		Neck flexion	Sternocleidomas-toid	
C3-C4	Spinal accessory	Fixes scapula	Trapezius	
C3-C5	Phrenic	Inspiration, tV, FEV1	Diaphragm	
C4-C5	Dorsal scapular	Hand behind back and palm resistance	Rhomboids	
C5	Suprascapular	Lateral rotate arm at shoulder	Infraspinatus	
C5	Suprascapula	Arm abduction 0-15 degrees	Supraspinatus	
C5	Axillary	Arm abduction > 90 degrees	Deltoid	
C5	Musculocutaneous	Flex supinated elbow	Biceps, brachialis	Biceps C5
C5-C6	Subscapular	Medial rotate arm at shoulder	Subscapularis	
C6-C7	Posterior interosseus	Supination	Supinator	
C5-C7	Long thoracic	Push at wall, scapula and back	Serratus anterior	

Table 1.5 continued

Dermatome	Nerve	Action	Muscle	Reflex
C6	Radial	Flex 1/2 supinated elbow	Brachioradialis	Brachioradialis C6
C6	Radial	Wrist extension 2–3	Extensor carpi radialis brevis/longus	
C5–T1	Anterior thoracic	Adduct arm	Pectoralis major	Pectoral
C6–C7	Median	Pronation	Pronator teres	
C6–C7	Median	Flex palm at wrist and hold 2–3 digit	Flexor carpi radialis	
C5–C7	Subscapular	Adduct horizontal arm	Teres major	
C7	Thoracodorsal	Adduct horizontal arm cough scapula > contract	Latissimus dorsi	
C7	Radial	Extend forearm	Triceps	Triceps C7
C7	Interosseous	Thumb away 1st digit in plane of palm	Abductor pollicis longus	
C7	Posterior interosseus	Finger extension at MP joint	Extensor digitorum	
C7	Posterior interosseus	Extend thumb	Extensor pollicis	
C7–C8	Ulnar	Flex palm at wrist and hold 4–5 digit	Flexor carpi ulnaris	
C8	Median	Flex fingers at DIP, 2–3 digit	Flexor digitorum profundus	
C8	Ulnar	Flex fingers at DIP, 3–4 digit	Flexor digitorum profundus	
C8	Median	Flex fingers at MP	Flexor digitorum superficial	
T1	Median	Extend fingers at PIP	Lumbricals	
T1	Median	Thumb at little finger	Opponens pollicis	
T1	Median	Thumb away (MC) from index plane palm	Abductor pollicis brevis	

(continued)