

# Textbook of Neuroanesthesia and Neurocritical Care

Volume I - Neuroanesthesia

Hemanshu Prabhakar  
Zulfiqar Ali  
*Editors*

 Springer

---

# Textbook of Neuroanesthesia and Neurocritical Care

---

Hemanshu Prabhakar • Zulfiqar Ali  
Editors

# Textbook of Neuroanesthesia and Neurocritical Care

Volume I - Neuroanesthesia

 Springer

*Editors*

Hemanshu Prabhakar  
Department of Neuroanaesthesiology  
and Critical Care  
All India Institute of Medical Sciences  
New Delhi  
India

Zulfiqar Ali  
Division of Neuroanesthesiology  
Department of Anesthesiology  
Sher-i-Kashmir Institute of Medical  
Sciences  
Soura, Srinagar  
Jammu and Kashmir  
India

ISBN 978-981-13-3386-6      ISBN 978-981-13-3387-3 (eBook)

<https://doi.org/10.1007/978-981-13-3387-3>

Library of Congress Control Number: 2019934709

© Springer Nature Singapore Pte Ltd. 2019

This work is subject to copyright. All rights are reserved by the Publisher, whether the whole or part of the material is concerned, specifically the rights of translation, reprinting, reuse of illustrations, recitation, broadcasting, reproduction on microfilms or in any other physical way, and transmission or information storage and retrieval, electronic adaptation, computer software, or by similar or dissimilar methodology now known or hereafter developed.

The use of general descriptive names, registered names, trademarks, service marks, etc. in this publication does not imply, even in the absence of a specific statement, that such names are exempt from the relevant protective laws and regulations and therefore free for general use.

The publisher, the authors, and the editors are safe to assume that the advice and information in this book are believed to be true and accurate at the date of publication. Neither the publisher nor the authors or the editors give a warranty, express or implied, with respect to the material contained herein or for any errors or omissions that may have been made. The publisher remains neutral with regard to jurisdictional claims in published maps and institutional affiliations.

This Springer imprint is published by the registered company Springer Nature Singapore Pte Ltd. The registered company address is: 152 Beach Road, #21-01/04 Gateway East, Singapore 189721, Singapore

---

## Foreword

Neuroanaesthesia and neurocritical care continue to evolve and develop as specialities, presenting those of us responsible for patient care with ever more challenges. Within the operating theatre, technological advances in surgical techniques and imaging have necessitated changes both in the way we work and also where we work. Advances in interventional neuroradiology have led to a greater demand for anaesthetic and critical care input outside of the operating theatre, often in remote sites, with all the associated challenges. An ever-increasing number of surgical procedures of greater complexity alongside an aging population have led to increased demands on the neurocritical care unit. Fortunately, advances in neuroanaesthesia, neurocritical care and neuromonitoring have recognised and facilitated these changes.

It has often been said that neuroanaesthesia is a speciality where the knowledge and skill of the anaesthetist directly influences patient outcome. This remains true today. To this end, the *Textbook of Neuroanaesthesia and Neurocritical Care* edited by Hemanshu Prabhakar covers all aspects of patient care. Volume I rightly begins with the fundamentals of neuroanaesthesia including anatomy, physiology and pharmacology, an understanding of which is essential to underpin good care. There is detailed guidance on the process of anaesthesia for neurosurgery including coexisting problems, special considerations, pain management and near misses. A special topics section includes recent innovations such as robotic surgery, gene delivery and expression, intra-arterial drug delivery and simulation in neuroanaesthesia. In volume II, the complexities of critical care are thoroughly addressed, starting with the fundamentals of neurocritical care through to the intensive care management of specific conditions, neuromonitoring, pain management, ethical considerations and near misses. Again, there is a special topics section on recent advances including research and evidence-based practice.

This comprehensive textbook is an authoritative and practical clinical text. It covers the breadth and depth of the complex specialities of neuroanaesthesia and critical care and includes chapters by many leading names in neuroanaesthesia who have lent their expertise to this work. It will be essential reading for trainees, clinicians and researchers involved in neurosciences. Despite the ever-increasing challenges facing us, this book should provide the reader with the necessary knowledge to enhance their practice and provide optimal neuroanaesthesia and neurocritical care.

Consultant Neuroanaesthetist,  
Department of Anaesthesia  
St George's University Hospitals NHS Foundation Trust,  
London, UK

Judith Dinsmore

---

## Preface

The editors feel pleased to present the first edition of *Textbook of Neuroanesthesia and Neurocritical Care*. This book has tried to cover the basic concepts of neuroanaesthesia and neurocritical care along with the major changes that have evolved in the field of neurosciences in the last decade. An attempt has been made by the authors to present an updated presentation of the subject. The book is available in two volumes: volume I focuses on the foundation of neuroanaesthesiology, and volume II focuses on the understanding of the neurocritical care. We hope that this book will be of immense use for readers, who are more focused on gaining an advanced understanding in the field of neurosciences.

We thank the authors for doing an outstanding job of producing authoritative chapters. We feel privileged to have compiled this first edition and are enthusiastic about everything it offers to our readers. We learned much in the process of editing this textbook and hope that you will find this textbook a valuable source of educational resource in the field of neurosciences.

New Delhi, India  
Srinagar, India

Hemanshu Prabhakar  
Zulfiqar Ali

---

# Contents

## Part I Fundamentals of Neuroanesthesia

- 1 Neuroanatomy** ..... 3  
Ravi K. Grandhi and Alaa Abd-Elseyed
- 2 Physiology for Neuroanesthesia** ..... 17  
Thomas M. Price, Catriona J. Kelly, and Katie E. S. Megaw
- 3 Pharmacological Considerations in Neuroanesthesia** ..... 33  
Sabine Kreilinger and Eljim P. Tesoro

## Part II Neuromonitoring

- 4 Intraoperative Monitoring of the Brain** ..... 43  
Hironobu Hayashi and Masahiko Kawaguchi
- 5 Intraoperative Neuromonitoring for the Spine** ..... 63  
Dhritiman Chakrabarti and Deepti Srinivas

## Part III Anesthesia for Neurosurgery

- 6 Anesthesia for Supratentorial Brain Tumor (SBT)** ..... 77  
Fenghua Li and Reza Gorji
- 7 Anesthesia for Infratentorial Lesions** ..... 95  
Barkha Bindu and Charu Mahajan
- 8 Anesthesia for Aneurysmal Subarachnoid Hemorrhage** ..... 115  
Nicolas Bruder, Salah Boussen, and Lionel Velly
- 9 Anesthesia for Cerebrovascular Lesions** ..... 131  
Shiwani Jain and Manish Kumar Marda
- 10 Anesthesia for Pituitary Lesions** ..... 145  
Tullio Cafiero
- 11 Anesthesia for Epilepsy Surgery** ..... 159  
Sujoy Banik and Lashmi Venkatraghavan
- 12 Anesthesia for Functional Neurosurgery** ..... 171  
Zulfiqar Ali and Hemanshu Prabhakar

<b>13</b>	<b>Anesthesia for Endoscopic Third Ventriculostomy</b> . . . . .	<b>177</b>
	Abdelazeem Ali El-Dawlatly	
<b>14</b>	<b>Anesthesia for Spine Surgery</b> . . . . .	<b>189</b>
	Andres Zorrilla-Vaca, Michael C. Grant, and Marek A. Mirski	
<b>15</b>	<b>Anesthesia for Traumatic Brain Injury</b> . . . . .	<b>201</b>
	Rachel Kutteruf	
<b>16</b>	<b>Anesthesia for Traumatic Spine Injury</b> . . . . .	<b>225</b>
	Onat Akyol, Cesar Reis, Haley Reis, John Zhang, Shen Cheng, and Richard L. Applegate II	
 <b>Part IV Co-existing Problems</b>		
<b>17</b>	<b>Co-Existing Hypertension in Neurosurgery</b> . . . . .	<b>235</b>
	Ramamani Mariappan and Rajasekar Arumugam	
<b>18</b>	<b>Co-existing Diabetes Mellitus in Neurosurgical Patients</b> . . . . .	<b>253</b>
	Manikandan Sethuraman	
 <b>Part V Special Considerations</b>		
<b>19</b>	<b>Pregnancy and Neuroanesthesia</b> . . . . .	<b>265</b>
	Monica S. Tandon and Aastha Dhingra	
<b>20</b>	<b>Pediatric Neuroanesthesia</b> . . . . .	<b>291</b>
	Jue T. Wang and Craig McClain	
<b>21</b>	<b>Geriatric Neuroanesthesia</b> . . . . .	<b>311</b>
	Kiran Jangra and Shiv Lal Soni	
 <b>Part VI Allied Considerations</b>		
<b>22</b>	<b>Interventional Neuroradiology</b> . . . . .	<b>327</b>
	Ravi Bhoja, Meghan Michael, Jia W. Romito, and David L. McDonagh	
<b>23</b>	<b>Anesthesia for Gamma Knife Surgery</b> . . . . .	<b>341</b>
	Summit Dev Bloria, Ketan K. Kataria, and Ankur Luthra	
<b>24</b>	<b>Infection Control in Operating Rooms: Sterilization and Disinfection Practices</b> . . . . .	<b>351</b>
	Purva Mathur	
<b>25</b>	<b>Intravenous Thrombolysis</b> . . . . .	<b>359</b>
	Vasudha Singhal and Jaya Wanchoo	



**Part VII Transfusion Practice**

- 26 Fluid Management in Neurosurgical Patients . . . . . 373**  
Wojciech Dabrowski, Robert Wise, and Manu L. N. G.  
Malbrain
- 27 Blood Transfusion in Neurosurgery . . . . . 383**  
Kavitha Jayaram and Shibani Padhy

**Part VIII Near Misses**

- 28 Near Misses in Neuroanesthesia . . . . . 403**  
Zakir Hajat and Zoe Unger
- 29 Near Misses in the Intraoperative Brain Suite. . . . . 413**  
Cory Roeth, Nicoleta Stoicea, and Sergio D. Bergese
- 30 Complications of Neuroanesthesia . . . . . 419**  
Emily Farrin, Brett J. Wakefield, and Ashish K. Khanna

**Part IX Pain Management**

- 31 Pain Management Following Craniotomy . . . . . 437**  
Chia Winchester and Alexander Papangelou
- 32 Post-operative Pain Management in Spine Surgery . . . . . 447**  
Ravi K. Grandhi and Alaa Abd-Elsayed
- 33 Trigeminal Neuralgia . . . . . 457**  
Nidhi Gupta

**Part X Special Topics**

- 34 Postoperative Cognitive Dysfunction . . . . . 483**  
Suparna Bharadwaj and Sriganesh Kamath
- 35 Enhanced Recovery After Neurosurgical Procedures  
(Craniotomies and Spine Surgery) . . . . . 493**  
Juan P. Cata, Katherine Hagan, and Mauro Bravo
- 36 Robot-Assisted Neurosurgery . . . . . 503**  
Indu Kapoor, Charu Mahajan, and Hemanshu Prabhakar
- 37 Gene Therapy for Neuroanesthesia . . . . . 511**  
Ellen S. Hauck and James G. Hecker
- 38 Intra-arterial Drug Delivery for Brain Diseases . . . . . 523**  
Jason A. Ellis and Shailendra Joshi

---

## Contributors

**Alaa Abd-Elseyed** Department of Anesthesiology, UW Health Pain Services, University of Wisconsin-Madison, Madison, WI, USA

**Shiwani Agarwal** Department of Neuroanaesthesia and Critical Care, Max Super Specialty Hospital Vaishali, Ghaziabad, India

**Onat Akyol** Department of Physiology and Pharmacology, Loma Linda University School of Medicine, Loma Linda, CA, USA

Department of Anesthesiology, Bağcılar Training and Research Hospital, İstanbul, Turkey

**Zulfiqar Ali** Division of Neuroanesthesiology, Department of Anesthesiology, Sher-i-Kashmir Institute of Medical Sciences Soura, Srinagar, Jammu and Kashmir, India

**Richard L. Applegate II** Anesthesiology and Pain Medicine, University of California Davis Health, Sacramento, CA, USA

**Rajasekar Arumugam** Surgical Intensive Care Unit, Christian Medical College Vellore, Vellore, India

**Sujoy Banik** Department of Anesthesia and Pain Medicine, Toronto Western Hospital, University of Toronto, Toronto, ON, Canada

**Sergio D. Bergese** Department of Anesthesiology, The Ohio State University Wexner Medical Center, Columbus, OH, USA

Department of Neurological Surgery, The Ohio State University Wexner Medical Center, Columbus, OH, USA

**Suparna Bharadwaj** Department of Neuroanaesthesia and Neurocritical Care, National Institute of Mental Health and Neurosciences, Bengaluru, India

**Ravi Bhoja** Department of Anesthesiology and Pain Management, University of Texas Southwestern Medical Center, Dallas, TX, USA

**Barkha Bindu** Department of Neuroanaesthesiology and Neuro-Critical Care, All India Institute of Medical Sciences, New Delhi, India

**Summit Dev Bloria** Department of Anaesthesia and Intensive Care, Postgraduate Institute of Medical Education and Research, Chandigarh, India

**Salah Boussen** Department of Anesthesiology and Intensive Care, CHU Timone, AP-HM, Aix-Marseille University, Marseille, France

**Mauro Bravo** Department of Anesthesiology and Perioperative Medicine, The University of Texas MD Anderson Cancer Center, Houston, TX, USA  
Anesthesiology and Surgical Oncology Research Group, Houston, TX, USA

**Nicolas Bruder** Department of Anesthesiology and Intensive Care, CHU Timone, AP-HM, Aix-Marseille University, Marseille, France

**Tullio Cafiero** Department of Anesthesia and Postoperative Intensive Care, Antonio Cardarelli Hospital, Napoli, Italy

**Juan P. Cata** Department of Anesthesiology and Perioperative Medicine, The University of Texas MD Anderson Cancer Center, Houston, TX, USA  
Anesthesiology and Surgical Oncology Research Group, Houston, TX, USA

**Dhritiman Chakrabarti** Department of Neuroanaesthesiology and Neurocritical Care, National Institute of Mental Health and Neuro Sciences, Bangalore, India

**Shen Cheng** Department of Neurosurgery, Second Affiliated Hospital, School of Medicine, Zhejiang University, Hangzhou, China

**Wojciech Dabrowski** Department of Anaesthesiology and Intensive Therapy, Medical University of Lublin, Lublin, Poland

**Aastha Dhingra** Department of Anaesthesia, Max Super-specialty Hospital, Ghaziabad, India

**Abdelazeem Ali El-Dawlatly** College of Medicine, King Saud University, Riyadh, Saudi Arabia

**Jason A. Ellis** Department of Neurosurgery, Hofstra Northwell School of Medicine, Lenox Hill Hospital, New York, NY, USA

**Emily Farrin** Anesthesiology Institute, Cleveland Clinic, Cleveland, OH, USA

**Reza Gorji** Department of Anesthesiology, SUNY Upstate Medical University, Syracuse, NY, USA

**Ravi K. Grandhi** Department of Anesthesiology, Maimonides Medical Center, Brooklyn, NY, USA

**Michael C. Grant** Department of Anesthesiology and Critical Care Medicine, The Johns Hopkins Hospital, Baltimore, MD, USA

**Nidhi Gupta** Department of Neuroanaesthesia, Indraprastha Apollo Hospitals, New Delhi, India

**Katherine Hagan** Department of Anesthesiology and Perioperative Medicine, The University of Texas MD Anderson Cancer Center, Houston, TX, USA

Anesthesiology and Surgical Oncology Research Group, Houston, TX, USA

**Zakir Hajat** Department of Anesthesia, University Health Network, Toronto Western Hospital, Toronto, ON, Canada

**Ellen S. Hauck** Department of Anesthesiology, Lewis Katz School of Medicine at Temple University, Philadelphia, PA, USA

**Hironobu Hayashi** Department of Anesthesiology, Nara Medical University Hospital, Kashihara, Japan

**James G. Hecker** Department of Anesthesiology and Pain Medicine, Harborview Medical Center, Seattle, WA, USA

**Kiran Jangra** Department of Anaesthesia and Intensive Care, Postgraduate Institute of Medical Education and Research, Chandigarh, India

**Kavitha Jayaram** Department of Anesthesiology and Critical Care, Nizams Institute of Medical Sciences, Hyderabad, India

**Shailendra Joshi** Department of Anesthesia, Columbia University Medical Center, New York, NY, USA

**Sriganesh Kamath** Department of Neuroanaesthesia and Neurocritical Care, National Institute of Mental Health and Neurosciences, Bengaluru, India

**Indu Kapoor** Department of Neuroanaesthesiology and Critical Care, All India Institute of Medical Sciences, New Delhi, India

**Ketan K. Kataria** Department of Anaesthesia and Intensive Care, Postgraduate Institute of Medical Education and Research, Chandigarh, India

**Masahiko Kawaguchi** Department of Anesthesiology, Nara Medical University Hospital, Kashihara, Japan

**Catriona J. Kelly** Department of Neuroanaesthesia, Royal Victoria Hospital, Belfast, Belfast, UK

**Ashish K. Khanna** Anesthesiology Institute, Cleveland Clinic, Cleveland, OH, USA

Wake Forest University School of Medicine, Winston-Salem, NC, USA

**Sabine Kreilinger** Department of Anesthesiology, University of Illinois at Chicago, Chicago, IL, USA

**Rachel Kutteruf** Department of Anesthesiology, U.S. Anesthesia Partners—Washington, Seattle, WA, USA

**Fenghua Li** Department of Anesthesiology, SUNY Upstate Medical University, Syracuse, NY, USA

**Ankur Luthra** Department of Anaesthesia and Intensive Care, Postgraduate Institute of Medical Education and Research, Chandigarh, India

**Charu Mahajan** Department of Neuroanaesthesiology and Neuro-Critical Care, All India Institute of Medical Sciences, New Delhi, India

**Manu L. N. G. Malbrain** Intensive Care Unit, University Hospital Brussels (UZB), Jette, Belgium

Faculty of Medicine and Pharmacy, Vrije Unoversiteit Brussel (VUB), Brussels, Belgium

**Manish Kumar Marda** Department of Neuroanaesthesia and Critical Care, Max Super Specialty Hospital Vaishali, Ghaziabad, India

**Ramamani Mariappan** Department of Anaesthesia, Christian Medical College Vellore, Vellore, India

**Purva Mathur** JPNA Trauma Center, All India Institute of Medical Sciences, New Delhi, India

**Craig McClain** Department of Anesthesiology, Critical Care and Pain Medicine, Harvard Medical School, Boston Children's Hospital, Boston, MA, USA

**David L. McDonagh** Department of Anesthesiology and Pain Management, University of Texas Southwestern Medical Center, Dallas, TX, USA

**Katie E. S. Megaw** Department of Neuroanaesthesia, Royal Victoria Hospital, Belfast, Belfast, UK

**Meghan Michael** Department of Anesthesiology and Pain Management, University of Texas Southwestern Medical Center, Dallas, TX, USA

**Marek A. Mirski** Department of Anesthesiology and Critical Care Medicine, The Johns Hopkins Hospital, Baltimore, MD, USA

**Shibani Padhy** Department of Anesthesiology and Critical Care, Nizams Institute of Medical Sciences, Hyderabad, India

**Alexander Papangelou** Department of Anesthesiology, Emory University Hospital, Atlanta, GA, USA

**Hemanshu Prabhakar** Department of Neuroanaesthesiology and Critical Care, All India Institute of Medical Sciences, New Delhi, India

**Thomas M. Price** Department of Neuroanaesthesia, Royal Victoria Hospital, Belfast, Belfast, UK

**Cesar Reis** Department of Physiology and Pharmacology, Loma Linda University School of Medicine, Loma Linda, CA, USA

Department of Preventive Medicine, Loma Linda University Medical Center, Loma Linda, CA, USA

**Haley Reis** Loma Linda School of Medicine, Loma Linda, CA, USA

**Cory Roeth** Boonshoft School of Medicine, Dayton, OH, USA

Department of Anesthesiology, The Ohio State University Wexner Medical Center, Columbus, OH, USA

**Jia W. Romito** Department of Anesthesiology and Pain Management, University of Texas Southwestern Medical Center, Dallas, TX, USA

**Manikandan Sethuraman** Division of Neuroanesthesia, Department of Anesthesiology, Sree Chitra Tirunal Institute for Medical Sciences and Technology, Trivandrum, Kerala, India

**Vasudha Singhal** Department of Neuroanesthesiology and Critical Care, Medanta, The Medicity, Gurgaon, India

**Shiv Lal Soni** Department of Anaesthesia and Intensive Care, Postgraduate Institute of Medical Education and Research, Chandigarh, India

**Deepti Srinivas** Department of Neuroanaesthesiology and Neurocritical Care, National Institute of Mental Health and Neuro Sciences, Bangalore, India

**Nicoleta Stoicea** Department of Anesthesiology, The Ohio State University Wexner Medical Center, Columbus, OH, USA

**Monica S. Tandon** Department of Anesthesiology and Intensive Care, G. B. Pant Institute of Postgraduate Medical Education and Research, New Delhi, India

**Eljim P. Tesoro** Department of Pharmacy Practice, University of Illinois at Chicago, Chicago, IL, USA

**Zoe Unger** Department of Anesthesia, University Health Network, Toronto Western Hospital, Toronto, ON, Canada

**Lionel Velly** Department of Anesthesiology and Intensive Care, CHU Timone, AP-HM, Aix-Marseille University, Marseille, France

**Lashmi Venkatraghavan** Department of Anesthesia and Pain Medicine, Toronto Western Hospital, University of Toronto, Toronto, ON, Canada

**Brett J. Wakefield** Anesthesiology Institute, Cleveland Clinic, Cleveland, OH, USA

**Jaya Wanchoo** Department of Neuroanesthesiology and Critical Care, Medanta, The Medicity, Gurgaon, India

**Jue T. Wang** Department of Anesthesiology, Critical Care and Pain Medicine, Boston Children's Hospital, Boston, MA, USA

**Chia Winchester** Department of Anesthesiology, Emory University Hospital, Atlanta, GA, USA

**Robert Wise** Department of Anaesthetics, Critical Care and Pain Management, Pietermaritzburg Metropolitan, Pietermaritzburg, South Africa  
Discipline of Anaesthesiology and Critical Care, Clinical School of Medicine, University of KwaZulu-Natal, Durban, South Africa

**John Zhang** Department of Physiology and Pharmacology, Loma Linda University School of Medicine, Loma Linda, CA, USA

**Andres Zorrilla-Vaca** Department of Anesthesiology, Universidad del Valle, School of Medicine, Cali, Colombia

---

## About the Editors

**Hemanshu Prabhakar** is a professor in the Department of Neuroanaesthesiology and Critical Care at All India Institute of Medical Sciences (AIIMS), New Delhi, India. He received his training in neuroanesthesia and completed his PhD at the same institute. He is a recipient of the AIIMS Excellence award for notable contributions in academics and has more than 200 publications in peer-reviewed national and international journals to his credit.

Dr. Prabhakar serves as a reviewer for various national and international journals. He is also a review author for the Cochrane Collaboration and has a special interest in evidence-based practice in neuroanesthesia. Dr. Prabhakar is a member of several national and international neuroanesthesia societies and is past secretary of the Indian Society of Neuroanesthesia and Critical Care. He serves on the editorial board of the *Indian Journal of Palliative Care* and is the executive editor of the *Journal of Neuroanaesthesiology and Critical Care*.

**Zulfiqar Ali** is an associate professor in the Division of Neuroanesthesiology and Neurocritical Care at Sher-i-Kashmir Institute of Medical Sciences, Srinagar, India. He received his training in neuroanesthesia from All India Institute of Medical Sciences, New Delhi, and the National Institute of Mental Health and Neurosciences, Bengaluru. His areas of interest include neurocritical care and chronic pain management. He has many publications in peer-reviewed national and international journals to his credit.

Dr. Ali is a member of various national and international neuroanesthesia societies and is a past executive committee member of the Indian Society of Neuroanesthesia and Critical Care. He serves as an associate editor of the *Indian Journal of Anesthesia* and co-editor of *Northern Journal of ISA*. In addition, he is a reviewer for several national and international journals.

---

**Part I**

**Fundamentals of Neuroanesthesia**





## 1.1 Overview

The nervous system is made up of two parts: the central nervous system (CNS) and the peripheral nervous system (PNS). The brain and spinal cord form the majority of the CNS. The CNS integrates, processes, and coordinates incoming sensory data and outgoing motor functions that alter the activities of the end organs or muscles. The brain is also the part of the body where higher cognitive activities occur, while the cranial and spinal nerves form the majority of the PNS. The PNS delivers sensory information to the CNS and carries motor commands from the CNS to the peripheral tissues and systems. The two systems are in close communication with each other. And when one of the two systems is altered in any fashion, the other one may be affected. This chapter will review the significant anatomical considerations in each of the two systems (Fig. 1.1).

---

R. K. Grandhi (✉)  
Department of Anesthesiology, Maimonides Medical  
Center, Brooklyn, NY, USA

A. Abd-Elseyed  
Department of Anesthesiology, UW Health Pain  
Services, University of Wisconsin-Madison,  
Madison, WI, USA

## 1.2 Central Nervous System

### 1.2.1 Brain

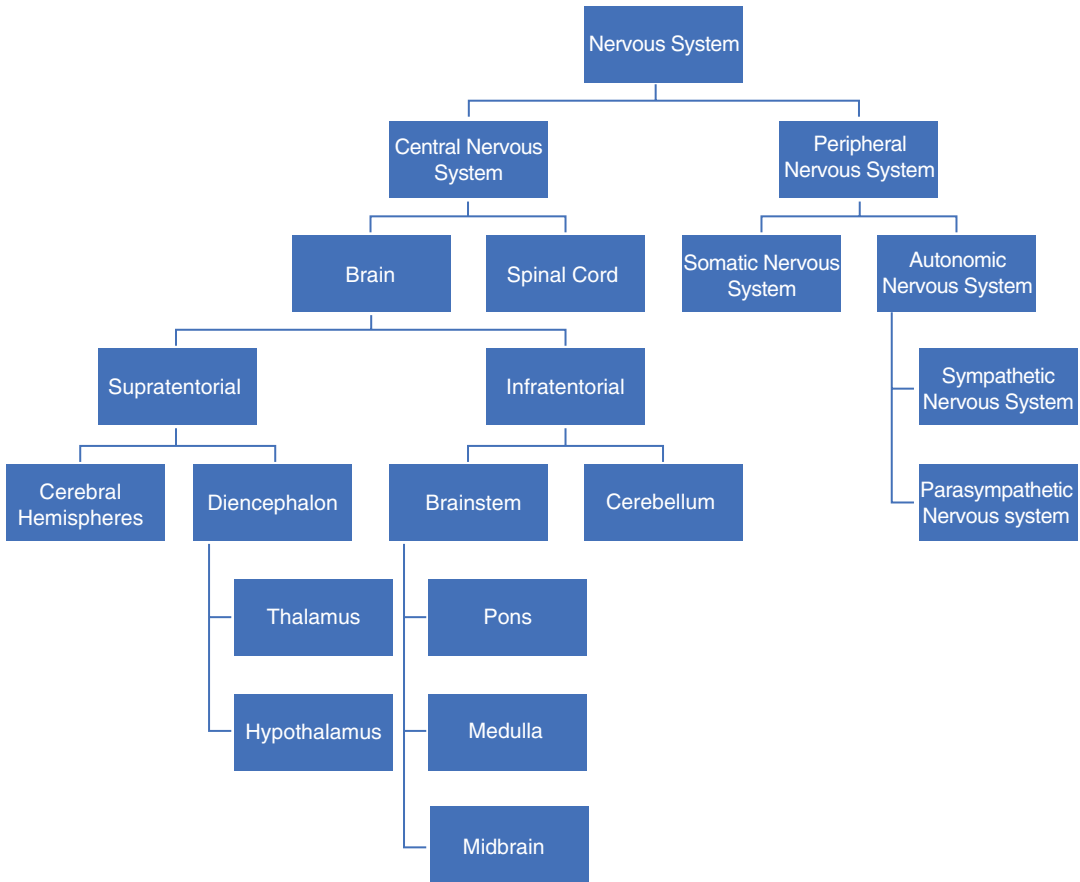
The brain can be divided into the supratentorial and the infratentorial compartments. The supratentorial compartment contains the cerebral hemispheres and the diencephalon (thalamus and hypothalamus). The infratentorial compartment is made up of the brain stem and the cerebellum.

#### 1.2.1.1 Supratentorial Compartment

##### Cerebrum

The cerebrum makes up the largest part of the brain. It is made up of a right and left hemisphere. The hemispheres are made up of numerous sulci or fissures and gyri or folds. The two sides of the brain are connected via the corpus callosum, which is a collection of white matter fibers. Based on functional differences, the cerebrum is divided into four lobes: frontal, parietal, temporal, and occipital lobes. The frontal lobe is separated from the parietal lobe via the central sulcus (Rolandic fissure). The frontal lobe is separated from the temporal lobe via the lateral sulcus (Sylvian fissure). The frontal and parietal lobes are separated from the temporal lobe via the lateral sulcus. And finally, the parieto-occipital sulcus divides the parietal lobe from the occipital lobe.

The cerebrum is made up of numerous functional areas that each provide a particular activity



**Fig. 1.1** Overall anatomical organization of the nervous system

essential to survival. The frontal lobe, which is made up of primary motor cortex, executes actions. Adjacent to this cortex is also the premotor cortex and other supplementary motor areas, which are involved in selecting voluntary movements. There are also sensory areas within the cortex, which help integrate the different stimuli from the senses. These areas work closely with the thalamus. Each of the hemispheres receives information about the contralateral side of the body. The primary somatosensory cortex located in the lateral parietal lobe, which integrates the touch signal, is often illustrated as a homunculus. The homunculus is a deformed human, where there are different sized body parts reflecting the relative density of their innervation. Areas with lots of innervation such as the fingertips and lips require more cortical processing compared to

other areas. Also, within the cerebrum are Broca's and Wernicke's areas, which are responsible for speech and comprehension. Broca's area is located in the frontal lobe, while Wernicke's is located at the temporoparietal junction. These two areas are closely linked by arcuate fibers. Damage to any one of these parts can cause problems either with speech or comprehension. The cerebrum also works closely with the hippocampus to form memories. Neurodegenerative diseases such as Alzheimer's affect the cerebrum.

### Cortex

The outermost surface of the cerebrum is the cortex that has a gray appearance and, as a result, is called gray matter. The cortex is a folded structure, and each one of these folds is referred to as a gyrus. Each one of the grooves is called a

sulcus. These folds allow the brain to occupy a smaller cranial volume and store increased functional areas [1]. Below the cortex are myelinated axons, which give the characteristic appearance and often referred to as white matter.

### **Limbic System**

The limbic system is the medial portion of the temporal lobe. It is vital in forming memories, emotions, and behaviors. The limbic system coordinates actions between different parts of the brain including the cortex, brain stem, thalamus, and hypothalamus. The limbic system is made up of the amygdala, hippocampus, fornix, mammillary bodies, cingulate gyrus, and parahippocampal gyrus. These structures communicate with each other via the Papez circuit. The amygdala is a collection of the nuclei that receives multiple sensory nerve signals. The amygdala integrates this information, ignores some stimuli, and creates outputs via the hypothalamus, thalamus, hippocampus, brain stem, and cortex. The amygdala also plays a role in mediating emotional responses associated with memories particularly the fear response [2]. The hippocampus is most important to memory formation, particularly declarative memory. Declarative memory is the ability to recall previous life events. Overtime, certain declarative memories can be independently recalled without the hippocampus [3]. The hippocampus is also important in learning [4].

### **Basal Ganglia**

The basal ganglia (or basal nuclei) are made up of the caudate nucleus, putamen, globus pallidus, nucleus accumbens, olfactory tubercle, ventral pallidum, subthalamic nucleus, and substantia nigra [5]. The basal ganglia work with the motor cortex, premotor cortex, and motor nuclei of the thalamus. It modulates voluntary movements, procedural learning, and routine behaviors or habits [6]. The substantia nigra forms the dopamine necessary for basal ganglia function. The subthalamic nucleus is the only part of the basal ganglia to produce the excitatory neurotransmitter glutamate. A number of motor-related diseases have pathology in the basal ganglia, including Parkinson's and Huntington's disease.

### **Diencephalon**

The diencephalon is made up of the thalamus, epithalamus, subthalamus, and hypothalamus.

### **Thalamus**

The thalamus integrates sensory and motor inputs and transmits the information to the ipsilateral cerebral cortex. There is reciprocal feedback that projects to the thalamic subnuclei. It receives significant inputs from all the senses except for smell. The thalamus may also serve as a filter, trying to simplify the information received and process it to convey the best overall impression. There are a number of nuclei in the thalamus that play key roles in the functioning of the body. The anterior thalamic nuclei work closely with the limbic system, which is also connected with the cingulate gyrus and mammillary bodies. Medial nuclei are associated with the frontal association cortex and premotor cortex. Ventral anterior and lateral nuclei have inputs from the globus pallidus and project to the motor cortex. Ventral posteromedial and ventral posterolateral nuclei function as sensory transmitters associated with the face and body, respectively. Another part of the thalamus is the medial and lateral geniculate bodies, which process auditory and visual information [7]. Finally, the thalamus is also the primary entrance through which additional information from the reticular formation reaches the cerebral cortex. Animals with a damaged thalamus often suffer in a permanent coma.

### **Epithalamus**

The epithalamus connects the limbic system to the rest of the brain. The pineal gland is a part of the epithalamus. The pineal gland secretes melatonin, which is involved in the regulation of the circadian rhythm.

### **Subthalamus**

The subthalamus has efferent connections to the striatum (caudate nucleus and putamen), dorsal thalamus, substantia nigra, and red nucleus. It also has afferent connections from the substantia nigra and striatum. It is often involved in movement control.

## Hypothalamus

The hypothalamus mediates the endocrine, autonomic, visceral, and homeostatic functions. It is the highest center for regulation of visceral functions. The hypothalamus connects the nervous system to the endocrine system via the pituitary gland. The hypothalamus is made up of a number of nuclei, each of with particular nuclei that function to regulate the body. Anterior nuclei include preoptic, supraoptic, and paraventricular. Anterior nuclei function in thermoregulation via sweating or panting, vasopressin release, oxytocin release, thyroid-releasing hormone release, and corticotropin-releasing hormone release. Middle nuclei include infundibular, tuberal, dorsomedial, ventromedial, and lateral. They function in the regulation of blood pressure, heart rate, gastrointestinal stimulation, satiety, growth hormone-releasing hormone release, and feeding. Posterior nuclei include supramammillary, mammillary, intercalate, and posterior. They function in arousal, learning, memory, energy balance, and sleep. Lateral nuclei are the location where hypocretin is released, which functions in arousal, temperature regulation, blood pressure, hunger, and wakefulness. Anterior and medial nuclear groups provide parasympathetic control, whereas sympathetic control is performed by the posterior and lateral nuclei. The hypothalamus is also connected with other areas in the brain to help coordinate different functions.

## Pituitary

Pituitary gland is located below the hypothalamus at the base of the brain. The hypothalamus works closely with the pituitary to initiate endocrine responses. The pituitary regulates the majority of body functions, including blood pressure, water balance, thyroid levels, breast milk production, sexual organ function, and growth. The pituitary has three parts: anterior, intermediate, and posterior. The anterior pituitary synthesizes and secretes prolactin, growth hormone, adrenocorticotropic hormone, thyroid-stimulating hormone, luteinizing hormone, and follicle-stimulating hormone. The anterior and intermediate pituitary together release melanocyte-releasing hormone. The poste-

rior pituitary does not synthesize but secretes antidiuretic hormone and oxytocin.

### 1.2.1.2 Infratentorial Compartment

The infratentorial compartment is the area under the tentorium cerebelli. The primary component is the cerebellum. Nerves C1–C3 innervate this area.

## Cerebellum

The cerebellum is made up of tightly folded layer of the cortex, with several deep nuclei embedded in the white matter underneath and a fluid-filled ventricle in the middle. Signals in the cerebellum flow in a unidirectional fashion. The cerebellum plays a major role in motor functions, in particular coordination, posture, and balance [8]. Damage to the cerebellum leads to motor disturbances. There is decreased muscle tone ipsilateral to the lesion site. The cerebellum is an anatomically distinct portion from the cerebrum. It is made up of fine grooves, with several different types of neurons in a very regular distribution. The most important types of cells in the cerebellum are the Purkinje and granule cells. All of the output from the cerebellum passes through a couple of small deep nuclei lying within the white matter.

The three lobes of the cerebellum are flocculonodular lobe, anterior lobe, and posterior lobe. The latter two lobes are also split into the midline cerebellar vermis and lateral cerebral hemispheres. The flocculonodular lobe regulates balance and eye movements. It receives vestibular input from both the semicircular canals and the vestibular nuclei and sends fibers back to the medial and lateral vestibular nuclei. It also receives visual input from the superior colliculus and from the visual cortex.

The cerebellar vermis and paravermis regulate body and limb movements. It receives proprioception input from the dorsal columns of the spinal cord and trigeminal nerve, as well as visual and auditory systems. It also sends fibers to the deep cerebellar nuclei which in turn project to both the cerebral cortex and brain stem, thus providing modulation of the descending motor systems. This area also has sensory maps because it

receives data on the position of various body parts in space. This information is also used to anticipate the future position of the body (also known as “feed forward”).

The lateral hemispheres are involved in the planning movement and evaluating sensory information for action. It receives input from the cerebral cortex particularly the parietal lobe via the pontine nuclei and dentate nucleus and sends fibers to the ventrolateral thalamus and red nucleus. This area is also involved in planning the movement that is about to occur.

### Blood Supply

Cerebral blood flow to the brain makes up about 15% of cardiac output. The brain is vulnerable to factors that acutely decrease perfusion; as a result the brain has many safeguards including autoregulation and redundancy within the blood supply. Autoregulation is the phenomenon of maintaining a constant blood flow despite a change in perfusion pressure. The consequence of a compromise in blood flow, which is known as a stroke, can be devastating [9]. The arterial blood supply is divided into anterior and posterior portions. The anterior part is via the left and right internal carotid arteries, while the posterior portion is the vertebrobasilar artery. The anastomosis of these systems forms the circle of Willis and helps to create a redundant system of blood supply to help protect against ischemia. However, it is important to note that the system doesn't always protect against ischemia and is not completely redundant. Once the internal carotid arteries enter the cranial vault, they branch into the anterior cerebral artery (ACA) and eventually form the middle cerebral artery (MCA). The anterior cerebral arteries are connected via the anterior communicating artery (ACOM). The ACA supplies the majority of the midline portions of the frontal and superior medial parietal lobes. The MCA supplies most of the lateral portions of the hemispheres. The ACA, MCA, and ACOM form the anterior circulation of the circle of wills. The posterior circulation begins when the basilar artery, which is formed from the right and left vertebral arteries, branches into the left and right posterior cerebral artery (PCA). The

vertebral arteries are formed from the subclavian artery. The posterior communicating arteries (PCOM) connect the PCAs and also connect to the anterior circulation. The PCA supplies most of the blood to the occipital lobe and inferior portion of the temporal lobe [7].

Three arteries perfuse the cerebellum: superior cerebellar arteries (SCA), anterior inferior cerebellar artery (AICA), and posterior inferior cerebellar artery (PICA). The SCA branches off the lateral portion of the basilar artery, just inferior to its bifurcation into the posterior cerebral artery. It also supplies blood to the pons before reaching the cerebellum. The SCA supplies blood to most of the cerebellar cortex, the cerebellar nuclei, and the superior cerebellar peduncles. The AICA branches off the lateral portion of the basilar artery, just superior to the junction of the vertebral arteries.

Symptoms associated with infarctions vary based on the artery infarcted in the brain and the area of the brain supplied by that particular artery. MCA infarctions or strokes are the most common. MCA infarctions present with sensory and motor disturbances of the contralateral face, arm, and leg. They can also present with aphasias if the dominant hemisphere is affected. If the ACA is infarcted, it can present with leg weakness more than arm weakness. If the PCA is infarcted, then it presents with visual field abnormalities. Lacunar strokes present with pure sensory or pure motor abnormalities. Vertebrobasilar infarctions present with brain stem dysfunction, which can include vertigo, ataxia, and dysphagia.

The venous drainage system helps remove the blood from the brain. It is made up of two parts: the superficial and deep sinuses. The superficial system is composed of the sagittal sinuses and cortical veins that are located on the surface of the cerebrum. The most prominent of these sinuses is the superior sagittal sinus, which is located midline along the fal x cerebri. The deep venous drainage system is composed of the lateral sinuses, sigmoid sinuses, straight sinus, and draining deep cerebral veins. All the veins in the deep venous drainage system combine to form the vein of Galen. Both of these systems combine to drain into the internal jugular veins.

## Brain Stem

The brain stem is considered the most ancient part of the brain. It is made up of three parts: the medulla oblongata, pons, and midbrain. The brain stem primarily provides motor and sensory innervation to the face and neck via the cranial nerves. It also plays a key role in connecting the motor and sensory systems of the brain, which includes the corticospinal tract, posterior column-medial lemniscus pathway, and the spinothalamic tract. Finally, the brain stem plays a key role in the regulation of cardiac and respiratory function. It also regulates the CNS helping to maintain consciousness and regulating the sleep cycle [10].

### Medulla Oblongata

The medulla oblongata is a structure that is located superior to the cervical spinal cord. On the external surface, the prominent structure is the anterior median fissure. On either side of this are the medullary pyramids. The pyramids are made up of the corticospinal and corticobulbar tracts originating from the spinal cord. At the caudal part of the medulla, these tracts cross over to form the decussation of the pyramids. The anterior external arcuate fibers lie on top of this. The area between the anterolateral and posterolateral sulcus is the olivary bodies. These bodies are formed by the inferior olivary nuclei. The posterior medulla contains the gracile fasciculus and the cuneate fasciculus. Together, they make up the posterior funiculi. Just above these tubercles is the triangular fossa, which forms the lower floor of the fourth ventricle. The fossa is bound by the inferior cerebral peduncle, which connects the medulla to the cerebellum.

The medulla plays an important role in controlling the autonomous nervous system. The medulla regulates respiration via interaction with the carotid and aortic bodies. These receptors detect changes in pH; thus, if the blood is acidic, the medulla sends signals to the respiratory musculature to increase the respiratory rate to reoxygenate blood. The medulla also plays an important role in regulating the parasympathetic and sympathetic nervous systems, which play a key role in the cardiovascular system [11]. It also plays as

a baroreceptor. And finally, the medulla is important in managing the reflex centers of vomiting, coughing, sneezing, and swallowing [12].

### Pons

The pons is located between the medulla and midbrain. The pons contains the tracts that carry signals that travel from the cerebrum to the medulla and on to the cerebellum. It also contains the tracts that carry important sensory signals up to the thalamus. Posteriorly, there are cerebellar peduncles that connect the pons to the cerebellum and midbrain. The pons also has the respiratory pneumotaxic center and apneustic centers, which are vital in maintaining respiration and transitioning from inspiration to expiration. The pons also has the nuclei that coordinate with sleep, swallowing, respiration, and bladder control. The pons also coordinates the activities of the cerebral hemispheres. It also plays an important role in control of cranial nerves of 5–8, which includes hearing, equilibrium, taste, and facial sensations.

### Midbrain

The midbrain is made up of four parts: tectum, cerebral peduncles, tegmentum, and cerebral aqueduct. The tectum forms the upper border of the midbrain. It is comprised of the superior and inferior colliculi. The inferior colliculi are the principal midbrain nuclei of the auditory pathway. Above the inferior colliculi are the superior colliculi, which are involved in vision, in particular the vestibulo-ocular reflex. Together they form the corpora quadrigemina. These structures help to decussate the fibers of the optic nerve. Of note, the trochlear nerve comes out of the posterior midbrain below the inferior colliculi. The dorsal covering of the cerebral aqueduct is also part of the midbrain.

The tegmentum, which forms the floor of the midbrain, is made up of several nuclei, substantia nigra, and reticular formation. The ventral tegmentum is composed of cerebral peduncles, which serve as the transmission axons of the upper motor neurons. The reticular formation is a large area of the midbrain that has multiple regulatory functions. It plays a key role in arousal,



sleep-wake cycling, and maintaining consciousness [13, 14]. It also contains the locus coeruleus, which is involved in alertness modulation and autonomic reflexes. Serotonin is also made in the reticular formation, which is a key regulator of mood. The reticular formation also plays a key role in regulation of the cardiovascular system, along with the medulla. Finally, the reticular formation is important in habituation, which is the process by which the brain begins to ignore repetitive meaningless stimuli, but remains vigilant to new sounds. The red nucleus is closely involved in motor coordination. Another important part of the tegmentum is the substantia nigra, which is closely associated with the basal ganglia. Dopamine produced in the substantia nigra and ventral tegmental area plays a role in excitation, motivation, and habituation. Dysfunction is associated with Parkinson's disease.

The cerebral aqueduct is involved with the movement of CSF. It is surrounded by gray matter, which is known as the periductal gray. In this area, there are neurons involved in the pain desensitization pathway that interact with the reticular activating system. When the neurons here are stimulated, they cause activation of the nucleus raphe magnus. The neurons project into the posterior gray column of the spinal cord and prevent pain sensitization transmission [15].

### Development

In utero, the brain starts to develop at the beginning of the third week as the ectoderm forms the neural plate. By the fourth week, the neural plate has widened to give a broad cephalic end and a narrower caudal end. The swellings represent the beginning of the forebrain, midbrain, and hindbrain. Neural crest cells make up the lateral edge of the plate at the neural folds. By the end of the fourth week, the neural plate folds and closes to form the neural tube, which brings together the neural crest cells. Cells at the cephalic end give rise to the brain, while cells at the caudal end give rise to the spinal cord. With time the tube flexes giving rise to the crescent-shaped cerebral hemispheres. These cerebral hemispheres first appear on day 32. During this fourth week, the cephalic part bends forward forming the cephalic flexure,

which becomes the forebrain. The forebrain divides into two parts: the telencephalon and diencephalon. The telencephalon goes on to form the cerebral cortex, basal ganglia, and other structures. The diencephalon forms the thalamus and hypothalamus. The hindbrain goes on to develop into the metencephalon and myelencephalon. The metencephalon forms the cerebellum and pons. The myelencephalon forms the medulla oblongata [7]. The developing brain is more vulnerable to injury in comparison to the developed or adult brain. When the development of the brain is delayed by an external influence or toxin, there is virtually no regeneration or repair. This can lead to lifelong disability. As a result, minimizing exposures to a developing brain is vital.

One of the most defining features of the brain is the gyri that define the outer surface. In womb, the brain starts off smooth, but with time the fissures start to form. The fissures form because of the rapidly growing hemispheres, which rapidly increase in size due to the expansion of the gray matter. The underlying white matter does not grow at the same rate as the hemispheres [7].

### 1.2.1.3 Spinal Cord

The spinal cord is a bundle of nervous tissue that extends from the medulla oblongata in the brain stem to the lumbar region of the vertebral column. The spinal cord connects the brain to the peripheral nervous system. The spinal cord is encased in a bony shell made up of the cervical vertebrae. The spinal cord transmits nerve signals from the motor cortex to the musculature and from the afferent fibers of the sensory neurons to the sensory cortex. The spinal cord also plays a key role in coordinating reflexes and contains numerous reflex arcs (ankle jerk, knee jerk, biceps jerk, forearm jerk, triceps jerk). The spinal cord is made up of 31 segments; at each level there are 1 pair of sensory nerve roots and 1 pair of motor nerve roots.

The spinal cord and brain are covered by three protective layers of the meninges. The dura mater is the outermost layer and forms a tough protective coating. Between the vertebrae and dura mater is the epidural space. The epidural space is

made up of adipose tissue and has numerous blood vessels. The arachnoid mater is the middle layer that is located underneath the dura mater. The arachnoid mater is named for its open, spiderlike appearance. The space between the arachnoid mater and pia mater is the subarachnoid space. The subarachnoid space has cerebrospinal fluid (CSF), which is accessed in neuraxial anesthesia. The CSF is made in the brain's lateral ventricles and flows through the foramen of Monro into the third ventricle and through the cerebral aqueduct to the fourth ventricle. It passes into the subarachnoid space through three openings in the roof of the fourth ventricle. The two lateral openings are the foramen of Luschka and a median opening called the foramen of Magendie. The CSF then flows through the subarachnoid space around the brain and drains into the superior sagittal sinus through the arachnoid granulations [7].

The pia mater is tightly adhered to the spinal cord. The cord is stabilized within the dura mater by connecting denticulate ligaments, which extend from the enveloping pia mater laterally between dorsal and ventral roots. The dural sac ends at the level of the second sacral vertebrae.

### Spinal Cord Segments

The gray column (matter) at the center of the spinal column is shaped like a butterfly and consists of cell bodies of interneurons, motor neurons, neuroglia cells, and unmyelinated axons. The gray matter consists of longitudinal columns of cells, with a segmental relationship to the spinal nerve fibers. These columns are grouped into the dorsal (posterior) horn, ventral (anterior) horn, and intermediate gray. The dorsal roots are afferent fascicles, receiving sensory information. The roots terminate in dorsal root ganglia, which are made up of the respective cell bodies. The ventral nerve roots are made up of efferent fascicles that arise from motor neurons whose cell bodies are found in the ventral horns of the spinal cord [7]. The ventral horn also includes interneurons, which are involved in the processing of motor information. The intermediate gray contains the interneurons for primitive connections.

The white matter is located adjacent to the gray matter and is made up of myelinated motor

and sensory axons. The columns of white matter carry information up or down the spinal cord [7]. The white matter is made up of the dorsal white matter, ventral white matter, and lateral white matter. The dorsal white matter has the ascending tracts, while the ventral white matter has the descending tracts. The dorsal column below T6 has the gracile fasciculus, which has input from the lower body. And above T6, there is both input from the lower body and upper body, which is also known as the cuneate fascicle. The lateral white matter has both and is mainly involved with pain and movement. The absolute amount of white matter decreases as you progress caudally through the spinal cord. Lesions at the dorsal and ventral roots present as strictly sensory or motor deficits; while lesions at the peripheral nerves more often present with deficits in both the sensory and motor pathways.

The spinal cord terminates at the conus medullaris, while the pia mater continues via the filum terminale, which anchors the spinal cord to the coccyx. The cauda equina is a collection of nerves below the conus medullaris that travel in the vertebral column to the coccyx. The cauda equina forms because the spinal cord stops elongating at about age 4, even though the vertebral column continues to lengthen until adulthood.

There are 31 spinal cord segments in the spinal cord – 8 cervical segments, 12 thoracic segments, 5 lumbar segments, 5 sacral segments, and 1 coccygeal segment. In the fetus, vertebral segments correspond with spinal cord segments. In adults, the spinal cord ends around the L1/L2 vertebral level, which corresponds to the conus medullaris. As a result, the spinal cord segments do not correspond with the vertebral segments especially in the lower spinal cord. The cervical enlargement, stretching from the C5 to T1 vertebrae, is the location for the sensory and motor output associated with the arms and trunk. This enlargement corresponds with the brachial plexus. The lumbar enlargement, located between L1 and S3, handles sensory input coming from and going to the legs. This corresponds with the lumbosacral enlargement [7].



## Development

There are four stages of spinal cord development: neural plate, neural fold, neural tube, and spinal cord. At the end of the third week, the ectoderm located at the midline of thickens to form the neural plate. Slowly, the lateral edges of the neural plate began to move dorsally and medially. When the edges meet, they form the neural tube. As the neural tube begins to develop, the notochord begins to secrete sonic hedgehog (SHH) [16]. This helps to establish the ventral pole in the developing fetus [16]. As a result, the floor plate also begins to secrete SHH, which induces the basal plate to develop motor neurons. During the maturation of the neural tube, lateral walls thicken and form the longitudinal groove of the sulcus limitans. This extends the length of the spinal cord into dorsal and ventral portions. At the same time, the ectoderm secretes bone morphogenetic protein (BMP). These two opposing gradients help the cells divide along the dorsal ventral axis [17]. This release of the BMP also induces the roof plate to secrete BMP, which leads to the formation of the sensory neurons. Simultaneously, the lumen of the neural tube begins to narrow to help form the central canal of the spinal cord. Further, the floor plate secretes netrins. The netrins act as chemoattractants, which lead to the decussation of pain and temperature sensory neurons in the alar plate across the anterior white commissure. These fibers ascend toward the thalamus. Once the caudal neuropore and formation of the brain's ventricles with the choroid plexus is completed, the central canal of the caudal spinal cord is filled with CSF. Closure of the neural tube progresses both cranially and caudally. Malformations of the neural tube closure can lead to abnormal development of the central nervous system. Failure of the cranial tube to close completely at the cranial end may manifest as exencephaly, anencephaly, or cranioschisis. The complete closure of the lumbar region of the neural tube may lead to rachischisis or myeloschisis, which is where the spinal cord is exposed to the outside. More mild defects may present as spina bifida, which is the result of an incomplete vertebral arch.

Over the course of the cell division process, groups of cells break off from the neural plate and become a part of the mesoderm. Slowly, these neural crest cells migrate away from the neural tube and form a number of different tissues including the neurons of the dorsal root ganglion and post-synaptic cells of the sympathetic and parasympathetic nervous systems. When these cells fail to appropriately migrate, it forms diseases such as Hirschsprung's disease. Hirschsprung's occurs when there is a portion of the digestive system that can't perform peristalsis.

## Blood Supply

The blood supply of the spinal cord is made of three longitudinal arteries, which are the anterior spinal artery, right posterior spinal artery, and left posterior spinal artery. The anterior spinal artery provides blood flow to the anterior 2/3 of the spinal cord [7]. These arteries travel in the subarachnoid space and send branches into the spinal cord. They form connections via the anterior and posterior segmental medullary arteries, which enter the spinal cord at various points. The blood flow through these arteries provides sufficient blood supply primarily to the cervical spinal cord. Beyond that region, the spinal cord derives much of its blood supply from the anterior and posterior radicular arteries, which run into the spinal cord alongside the dorsal and ventral nerve roots. The largest of the anterior radicular arteries is the artery of Adamkiewicz, which usually arises between L1 and L2. Impaired blood flow to these radicular arteries can result in spinal cord infarction and paraplegia [18].

## Somatosensory Organization

The somatosensory system is primarily concerned with transmitting the sensory information from the integumentary and musculoskeletal systems of the body. This system can be divided into the dorsal column-medial lemniscus (DCML) and the anterolateral system (ALS). The DCML plays the main role in the touch, proprioception, and vibration, while the ALS plays the key role in pain and temperature. Both sensory pathways use three different nerves to transmit the information from the sensory receptors in the periphery to the