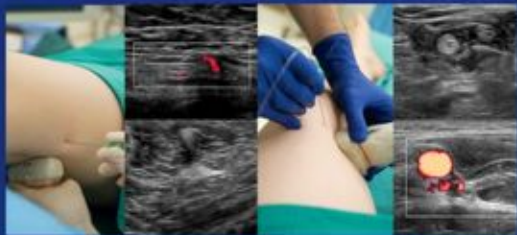

Get Full Access and More at

ExpertConsult.com

ATLAS OF ULTRASOUND-GUIDED REGIONAL ANESTHESIA

Second edition



ANDREW T. GRAY

ATLAS OF Ultrasound-Guided Regional Anesthesia

SECOND EDITION

Andrew T. Gray, MD, PhD

Professor of Clinical Anesthesia
Department of Anesthesia and Perioperative Care
University of California, San Francisco
School of Medicine;
Staff Anesthesiologist
San Francisco General Hospital
San Francisco, California

ELSEVIER
SAUNDERS

1600 John F. Kennedy Blvd.
Ste 1800
Philadelphia, PA 19103-2899

ATLAS OF ULTRASOUND-GUIDED REGIONAL ANESTHESIA ISBN: 978-1-4557-2818-3

Copyright © 2013, 2010 by Saunders, an imprint of Elsevier Inc.

No part of this publication may be reproduced or transmitted in any form or by any means, electronic or mechanical, including photocopying, recording, or any information storage and retrieval system, without permission in writing from the Publisher. Details on how to seek permission, further information about the Publisher's permissions policies and our arrangements with organizations such as the Copyright Clearance Center and the Copyright Licensing Agency, can be found at our website: www.elsevier.com/permissions.

This book and the individual contributions contained in it are protected under copyright by the Publisher (other than as may be noted herein).

Notices

Knowledge and best practice in this field are constantly changing. As new research and experience broaden our understanding, changes in research methods, professional practices, or medical treatment may become necessary.

Practitioners and researchers must always rely on their own experience and knowledge in evaluating and using any information, methods, compounds, or experiments described herein. In using such information or methods, they should be mindful of their own safety and the safety of others, including parties for whom they have a professional responsibility.

With respect to any drug or pharmaceutical products identified, readers are advised to check the most current information provided (i) on procedures featured or (ii) by the manufacturer of each product to be administered to verify the recommended dose or formula, the method and duration of administration, and contraindications. It is the responsibility of practitioners, relying on their own experience and knowledge of their patients, to make diagnoses, to determine dosages and the best treatment for each individual patient, and to take all appropriate safety precautions.

To the fullest extent of the law, neither the Publisher nor the authors, contributors, or editors assume any liability for any injury and/or damage to persons or property as a matter of products liability, negligence or otherwise, or from any use or operation of any methods, products, instructions, or ideas contained in the material herein.

Library of Congress Cataloging-in-Publication Data

Gray, Andrew T.

Atlas of ultrasound-guided regional anesthesia / Andrew T. Gray. – 2nd ed.

p. ; cm.

Includes bibliographical references and index.

ISBN 978-1-4557-2818-3 (hardcover : alk. paper)

I. Title.

[DNLM: 1. Anesthesia, Conduction–Atlases. 2. Ultrasonography, Interventional–Atlases.

WO 517]

617.9'640222–dc23

2012026981

Executive Content Strategist: William Schmitt
Senior Content Development Specialist: Anne Snyder
Publishing Services Manager: Anne Altepeter
Senior Project Manager: Cheryl A. Abbott
Design Direction: Ellen Zanolle

Printed in China

Last digit is the print number: 9 8 7 6 5 4 3 2 1

Working together to grow
libraries in developing countries

www.elsevier.com | www.bookaid.org | www.sabre.org

ELSEVIER

BOOK AID
International

Sabre Foundation

To my family, who love to write

Preface

This new edition highlights developments within the rapidly changing field of ultrasound-guided regional anesthesia. We hope to provide concise review of techniques that will improve our clinical practice along with the background that forms the foundation for these approaches. Now included are summary tables of the more common regional blocks, with step-by-step instruction for quick reference. Admittedly, approaches to regional anesthesia with ultrasound are somewhat arbitrary, but it is good education to have a starting point and some reasons why such an approach is successful and safe. The figure labeling has been revised to be less intrusive so as not to obscure underlying details. One of the biggest challenges when learning ultrasound-guided regional anesthesia is to understand the structures that lie near but outside the plane of imaging. Long-axis views and 3-D imaging are used to give the big picture of the surrounding anatomy.

Chapters from the first edition have been extensively revised. Several have been rewritten (infraclavicular, neuraxial, and cervical plexus blocks) to reflect advances from the most important articles in the past 3 years. There are four new chapters of blocking techniques (fascia iliaca, anterior sciatic nerve, transversus abdominis plane, and stellate ganglion) that are increasingly popular and guided by the soft tissue information that ultrasound imaging provides. In addition to the ten videos of the first edition, there are five new online videos (cervical plexus, infraclavicular, fascia iliaca, transversus abdominis plane (TAP), and neuraxial blocks) that accompany the atlas. Ultrasound is a wonderful tool for discovery, and the atlas strives to convey the essentials for safe and effective regional anesthesia.

Special thanks and gratitude are due to Robin Stackhouse, MD, who worked on the photography for blocks; Susan Yoo, MD, who worked on video production; Armando Leiva, who organized materials for print; and Tanya Domingo, who worked on the equipment for direct nerve imaging.

Andrew T. Gray, MD, PhD

Video Contents

INTRODUCTION TO ULTRASOUND IMAGING

Introduction

Chapters 1-15, Video 1—Andrew T. Gray

UPPER EXTREMITY BLOCKS

Interscalene and Supraclavicular Blocks

Chapter 27, Video 1—Andrew T. Gray

Infraclavicular Block

Chapter 31, Video 1—Andrew T. Gray and Susan S. Yoo

Axillary Block

Chapter 32, Video 1—Andrew T. Gray

LOWER EXTREMITY BLOCKS

Fascia Iliaca Block

Chapter 39, Video 1—Andrew T. Gray and Susan S. Yoo

Femoral Nerve Block

Chapter 40, Video 1—Andrew T. Gray

Saphenous Nerve Block

Chapter 41, Video 1—Andrew T. Gray

Obturator Nerve Block

Chapter 42, Video 1—Andrew T. Gray

Sciatic Nerve Block

Chapter 43, Video 1—Andrew T. Gray

Popliteal Block

Chapter 45, Video 1—Andrew T. Gray

TRUNK BLOCKS

Truncal Blocks

Chapters 52 and 53, Video 1—Andrew T. Gray

Transversus Abdominis Plane (TAP) Block

Chapter 54, Video 1—Andrew T. Gray and Susan S. Yoo

Neuraxial Block

Chapter 55, Video 1—Andrew T. Gray and Susan S. Yoo

HEAD AND NECK BLOCKS

Cervical Plexus Block

Chapter 60, Video 1—Andrew T. Gray and Susan S. Yoo

SAFETY ISSUES

Safety

Chapters 62-65, Video 1—Andrew T. Gray

1



Ultrasound

Ultrasound waves are high-frequency sound waves generated in specific frequency ranges and sent through tissues.¹ How sound waves penetrate a tissue depends on the range of the frequency produced. Lower frequencies penetrate deeper than high frequencies. The frequencies for clinical imaging (1-50 MHz) are well above the upper limit of normal human hearing (15-20 KHz). Wave motion transports energy and momentum from one point in space to another without transport of matter. In mechanical waves (e.g., water waves, waves on a string, and sound waves), energy and momentum are transported by means of disturbance in the medium because the medium has elastic properties. Any wave in which the disturbance is parallel to the direction of propagation is referred to as a longitudinal wave. Sound waves are longitudinal waves of compression and rarefaction of a medium such as air or soft tissue. *Compression* refers to high-pressure zones, and *rarefaction* refers to low-pressure zones (these zones alternate in position).


As the sound passes through tissues, it is absorbed, reflected, or allowed to pass through, depending on the echodensity of the tissue. Substances with high water content (e.g., blood, cerebrospinal fluid) conduct sound very well and reflect very poorly and thus are termed *echolucent*. Because they reflect very little of the sound, they appear as dark areas. Substances low in water content or high in materials that are poor sound conductors (e.g., air, bone) reflect almost all the sound and appear very bright. Substances with sound conduction properties between these extremes appear darker to lighter, depending on the amount of wave energy they reflect.

Audible sounds spread out in all directions, whereas ultrasound beams are well collimated. The frequency of sound does not change with propagation unless the wave strikes a moving object, in which case the changes are small. The product of the frequency and wavelength of sound waves is the wave speed. Because the speed of sound in soft tissue is nearly constant, higher-frequency sound waves have shorter wavelengths. Two adjacent structures cannot be identified as separate entities on an ultrasound scan if they are less than one wavelength apart. Therefore, sound wave frequency is one of the main determinants of spatial resolution of ultrasound scans.

Reference

1. Aldrich JE. Basic physics of ultrasound imaging. *Crit Care Med* 2007;35:S131-7.

2



Speed of Sound

The speed of sound is determined by properties of the medium in which it propagates. The sound velocity equals $\sqrt{B/\rho}$, where B equals the bulk modulus, and ρ equals density. The bulk modulus is proportional to stiffness. Thus stiffness (change in shape) and wave speed are related. Density (weight per unit volume) and wave speed are inversely related. The speed of sound in a given medium is essentially independent of frequency.

Because the velocity of sound in soft tissue is 1540 m/sec, 13 microseconds elapse for each centimeter of tissue the sound wave must travel (the back-and-forth time of flight). Speed of sound artifacts relates to both time of flight considerations and refraction that occurs at the interface of tissues with different speeds of sound.¹⁻³

References

1. Scanlan KA. Sonographic artifacts and their origins. *AJR Am J Roentgenol* 1991;**156**:1267-72.
2. Fornage BD. Sonographically guided core-needle biopsy of breast masses: the "bayonet artifact". *AJR Am J Roentgenol* 1995;**164**:1022-3.
3. Gray AT, Schafhalter-Zoppoth I. "Bayonet artifact" during ultrasound-guided transarterial axillary block. *Anesthesiology* 2005;**102**:1291-2.

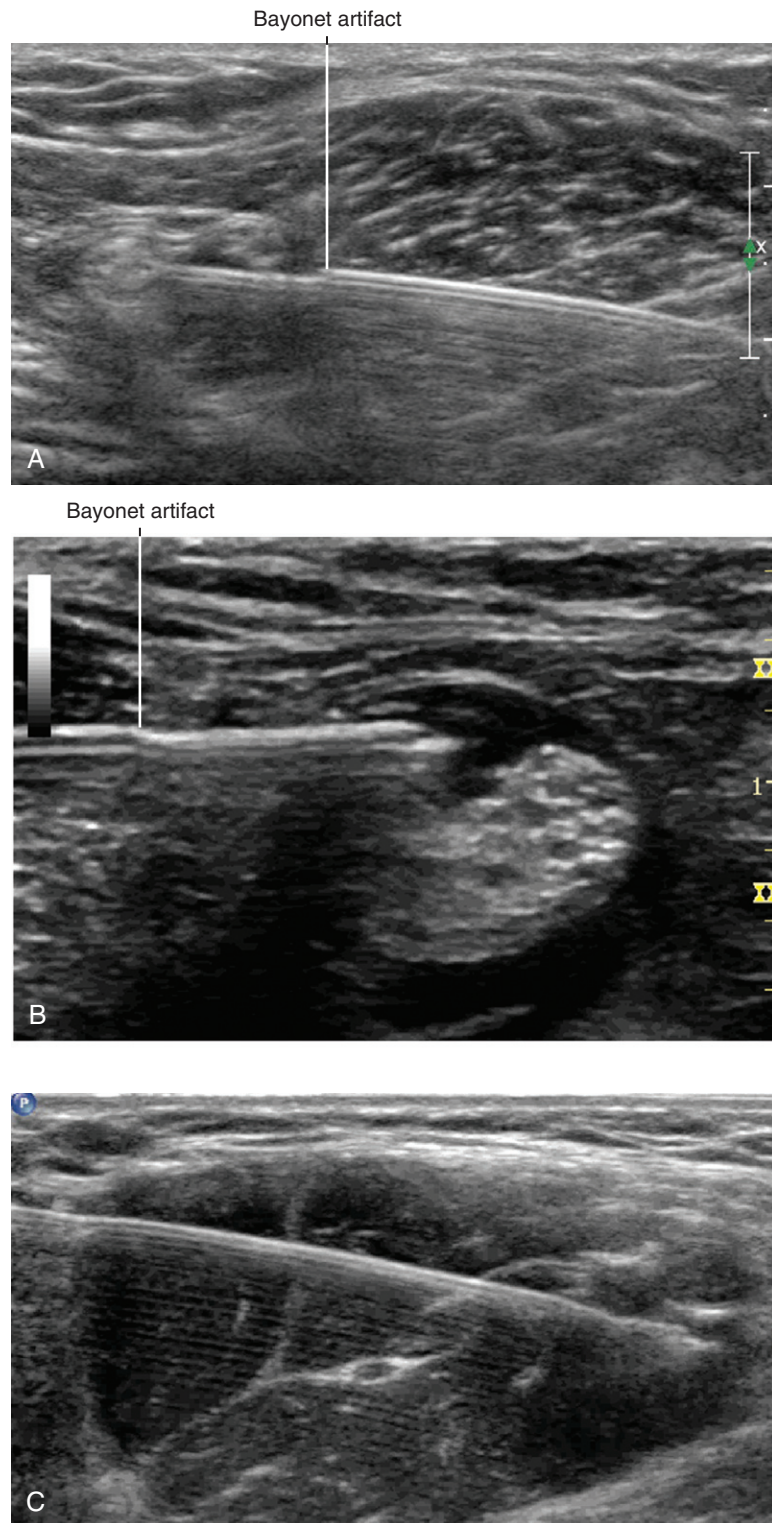



FIGURE 2-1. Bayonet artifacts during popliteal block (A and B). Because the speed of sound is not necessarily homogeneous in soft tissue, the needle can sometimes appear to bend, similar to a bayonet. Actual mechanical bending of the needle typically appears as gentle bowing of the needle (C).



Attenuation

Attenuation is a decrease in wave amplitude as it travels through a medium. The attenuation of ultrasound in soft tissue is about 0.8 dB/(MHz-cm), indicating that the extent of attenuation depends on the distance traveled and the frequency of insonation. The units of the attenuation coefficient directly show the greater attenuation of high-frequency ultrasound beams. In soft tissue, 80% or more of the total attenuation is caused by absorption of the ultrasound wave, thereby generating heat.

Time gain compensation (TGC) adjusts for attenuation of an ultrasound beam as a function of depth. When TGC is properly adjusted, images of similar reflectors appear the same regardless of depth.

An acoustic shadow is said to exist when a localized object reflects or attenuates sound to impede transmission. Bone is a strong absorber of ultrasound waves. Therefore, shadowing occurs deep to bony structures (“bone shadow”).

When a nonattenuating fluid (e.g., blood or injected local anesthetic) lies within an attenuating sound field (e.g., soft tissue), enhancement of echoes deep to the fluid occurs. This phenomenon, originally described as *posterior acoustic enhancement* (also called *increased through-transmission*), is due to lack of absorption of the sound waves by the fluid.¹ This attenuation artifact is a potential source of problems, especially during regional blocks where nerves are situated close to blood vessels.

CLINICAL PEARLS

- In general, the highest frequency capable of adequate penetration to the depth of interest should be used for imaging.
- Decibels (dB) are a relative logarithmic measure of sound wave intensity.

Reference

1. Filly RA, Sommer FG, Minton MJ. Characterization of biological fluids by ultrasound and computed tomography. *Radiology* 1980;134:167–71.

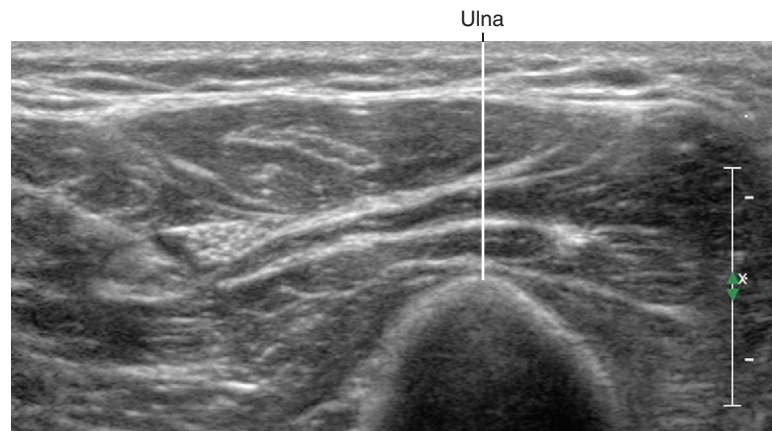



FIGURE 3-1. Acoustic shadowing by bone. In this sonogram from the forearm, the acoustic shadowing by the ulna is evident. The bright cortical line of the surface of the bone is followed by extinction of the sound wave below.

4



Reflection

Ultrasonography measures the amplitude of the return echo as a function of time.¹ Sound waves are reflected at the interface of tissues with different acoustic impedances. The acoustic impedance (kg/[m²-sec]) is the product of the density (kg/m³) and velocity (m/sec). The extent of reflection is governed by the reflection coefficient: $R = (Z1 - Z2)/(Z1 + Z2)$. If $Z1 = Z2$, there is no reflected wave.² Ultrasound characteristics of biologic tissue and interventional materials are summarized in Table 4-1.

Reflections off a smooth surface are called *specular*. If two specular reflectors are close to each other, reverberation within the sound field can result, displayed as parallel, equally spaced lines deep to the reflectors. Comet-tail artifact, which is a form of reverberation artifact, is caused by multiple internal reflections from a small, highly reflective interface.^{3,4}

CLINICAL PEARLS

- The normal pleural line is thin and smooth, which generates a few comet-tail artifacts (between one and six artifacts per intercostal space scan). In the presence of parenchymal lung disease, the pleural line is irregular and thickened, generating many more comet-tail artifacts.⁵
- No comet-tail artifact is observed from the lung when pneumothorax is present.
- Hyperechoic reverberation artifacts are seen with metallic foreign bodies such as block needles.

Table 4-1 **Ultrasound Characteristics of Biologic Tissue and Interventional Materials**

Substance	Velocity (m/sec)	Attenuation (dB/[MHz-cm])	Impedance (mrayls × 10 ⁻⁶)
Air	330	7.5	0.0001
Water	1480	0.0022	1.5
Soft tissue	1540	0.75	1.7
Blood	1575	0.15	1.6
Bone	4080	15	8
Stainless steel	5790	0.2	47

Data from Ziskin MC. Fundamental physics of ultrasound and its propagation in tissue. *Radiographics* 1993;**13**:705–9; Ziskin MC, Thickman DI, Goldenberg NJ, et al. The comet tail artifact. *J Ultrasound Med* 1982;**1**:1–7; Gawdzinska K. Investigation into the propagation of acoustic waves in metal. *Metalurgija* 2005;**44**:125–8; Smith SW, Booi RC, Light ED, et al. Guidance of cardiac pacemaker leads using real time 3D ultrasound: feasibility studies. *Ultrasound Imaging* 2002;**24**:119–28.

References

1. Ziskin MC. Fundamental physics of ultrasound and its propagation in tissue. *Radiographics* 1993;13:705–9.
2. Ziskin MC. Equation governing the transmission of ultrasound. *J Clin Ultrasound* 1982;10:A21.
3. Ziskin MC, Thickman DI, Goldenberg NJ, et al. The comet tail artifact. *J Ultrasound Med* 1982;1:1–7.
4. Thickman DI, Ziskin MC, Goldenberg NJ, et al. Clinical manifestations of the comet tail artifact. *J Ultrasound Med* 1983;2:225–30.
5. Reissig A, Kroegel C. Transthoracic sonography of diffuse parenchymal lung disease: the role of comet tail artifacts. *J Ultrasound Med* 2003;22:173–80.

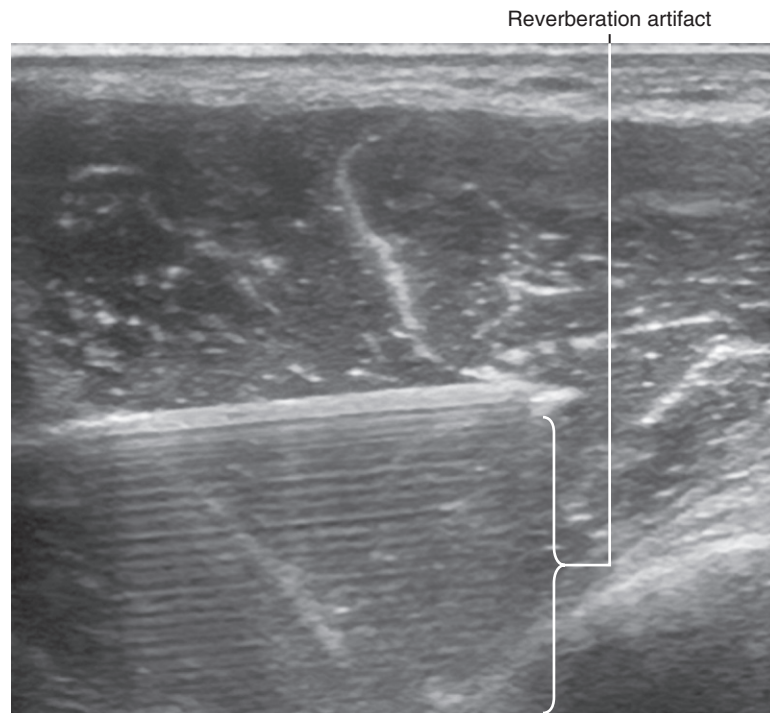


FIGURE 4-1. Reverberation artifact from a block needle placed nearly parallel to the active face of the transducer.

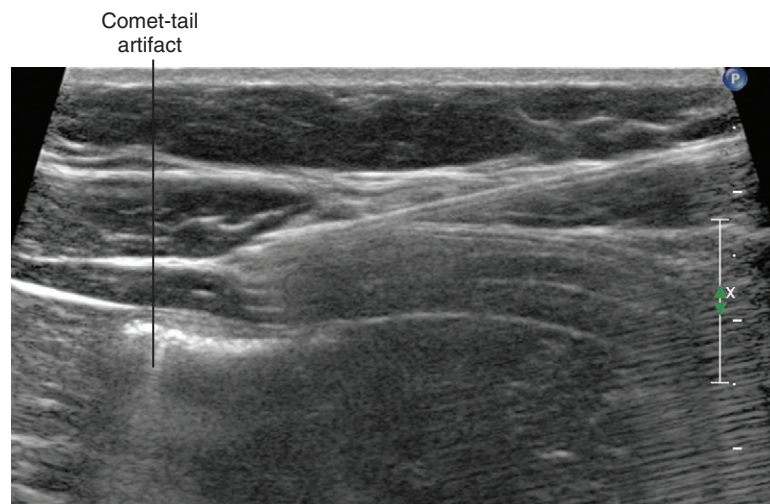


FIGURE 4-2. Comet-tail artifact from the peritoneum during rectus sheath block. The peritoneum and pleura have similar appearances on ultrasound scans.

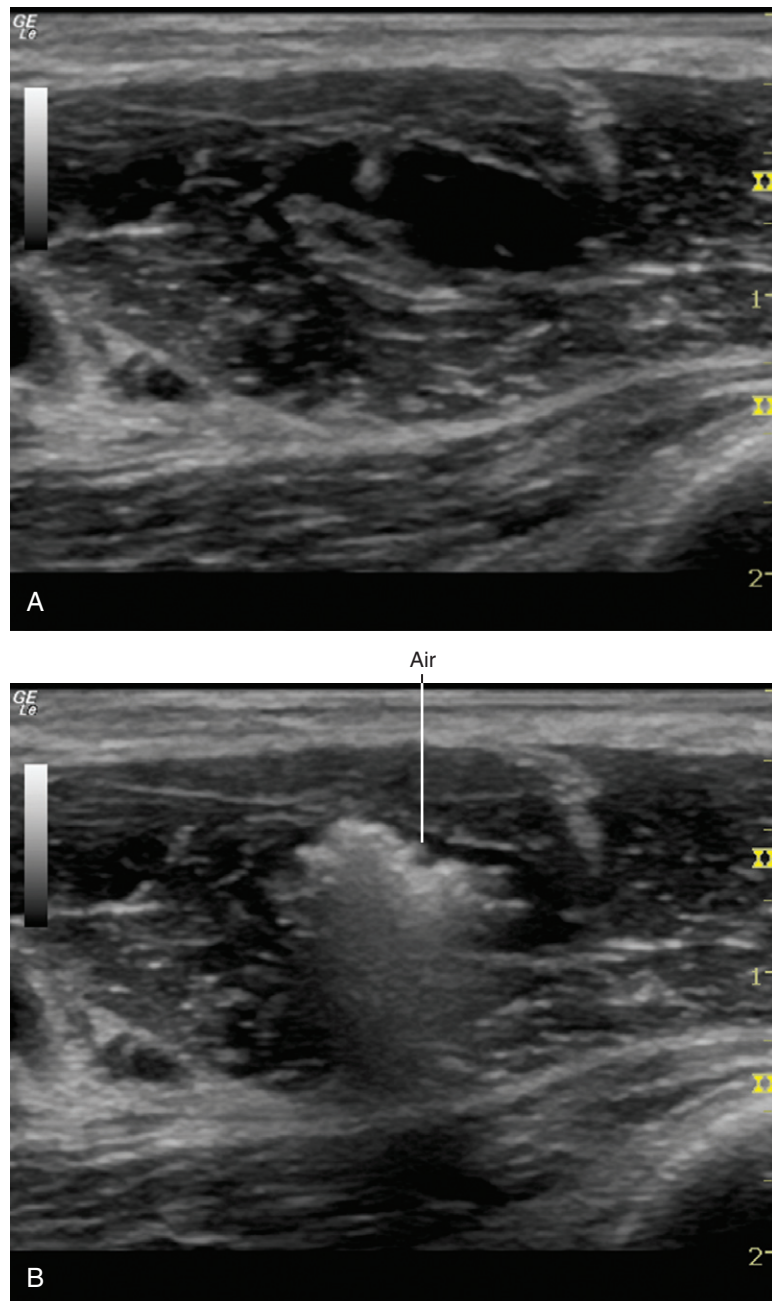


FIGURE 4-3. A strong echo and acoustic shadowing are observed when air is inadvertently injected during musculocutaneous nerve block in the axilla. Sonograms before injection (A) and after injection (B) are shown.

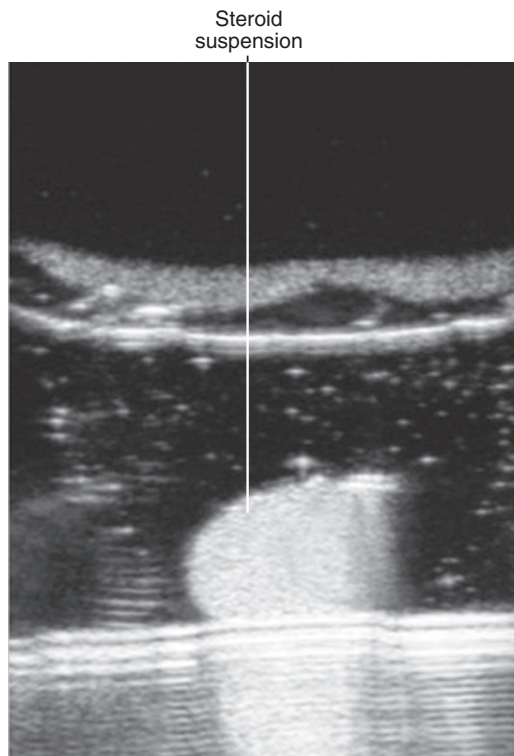


FIGURE 4-4. Acoustic properties of a steroid suspension. Although the local anesthetic injected for most regional blocks is anechoic, the particles of this steroid suspension are sufficiently large to produce a strong echo.