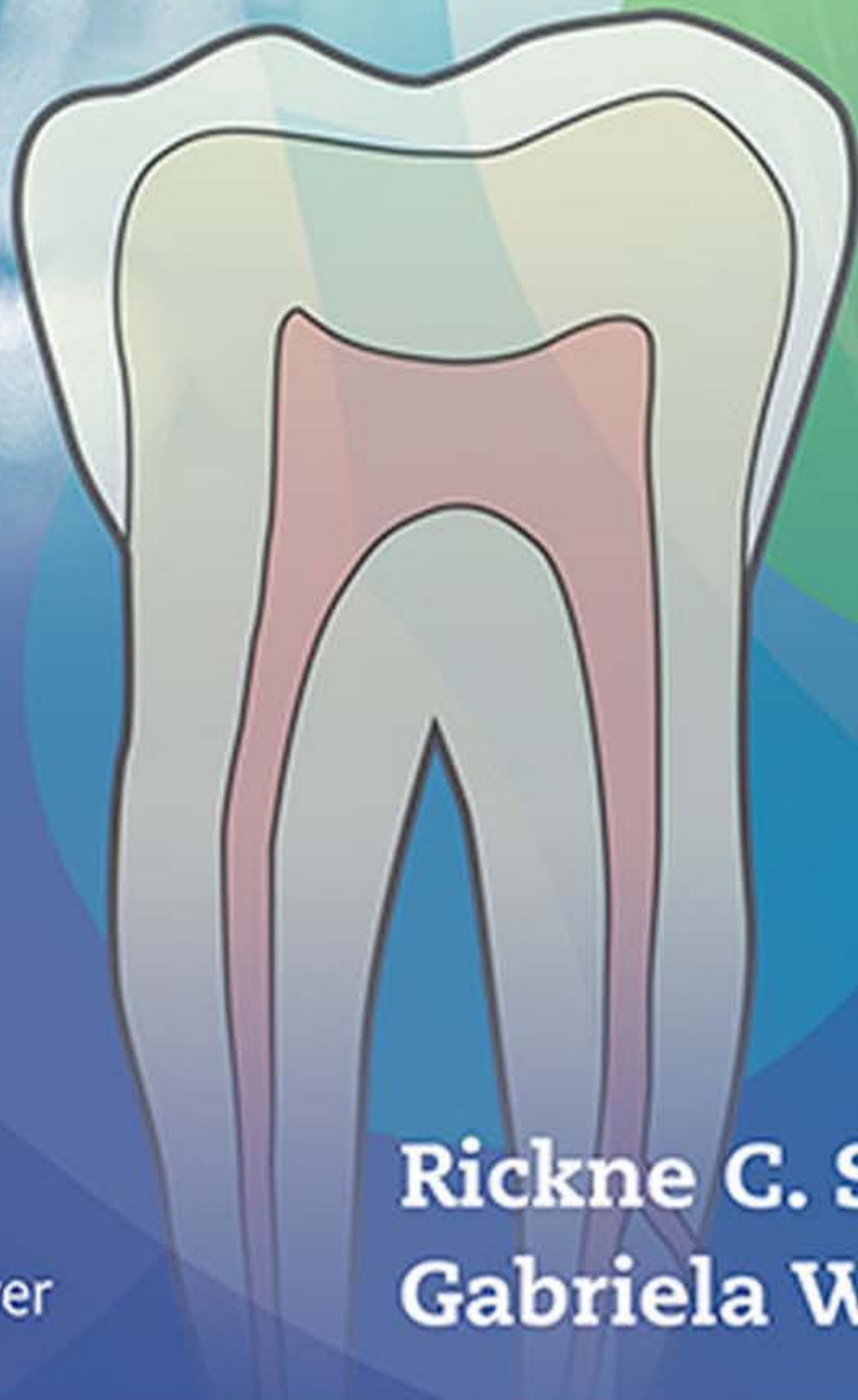
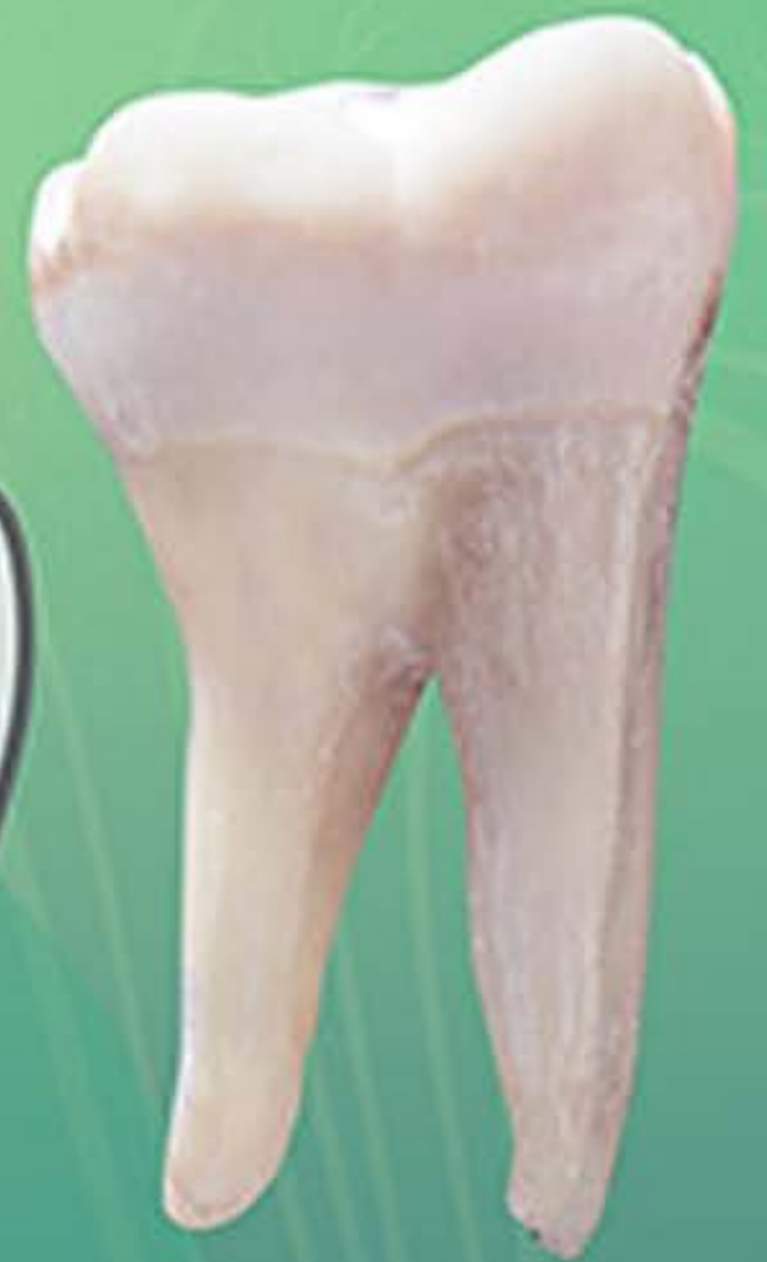
NINTH EDITION

WOELFEL'S

# Dental Anatomy



**Rickne C. Scheid**  
**Gabriela Weiss**

 Wolters Kluwer



**WOELFEL'S**

# **Dental Anatomy**



**NINTH EDITION**



**WOELFEL'S**

# **Dental Anatomy**

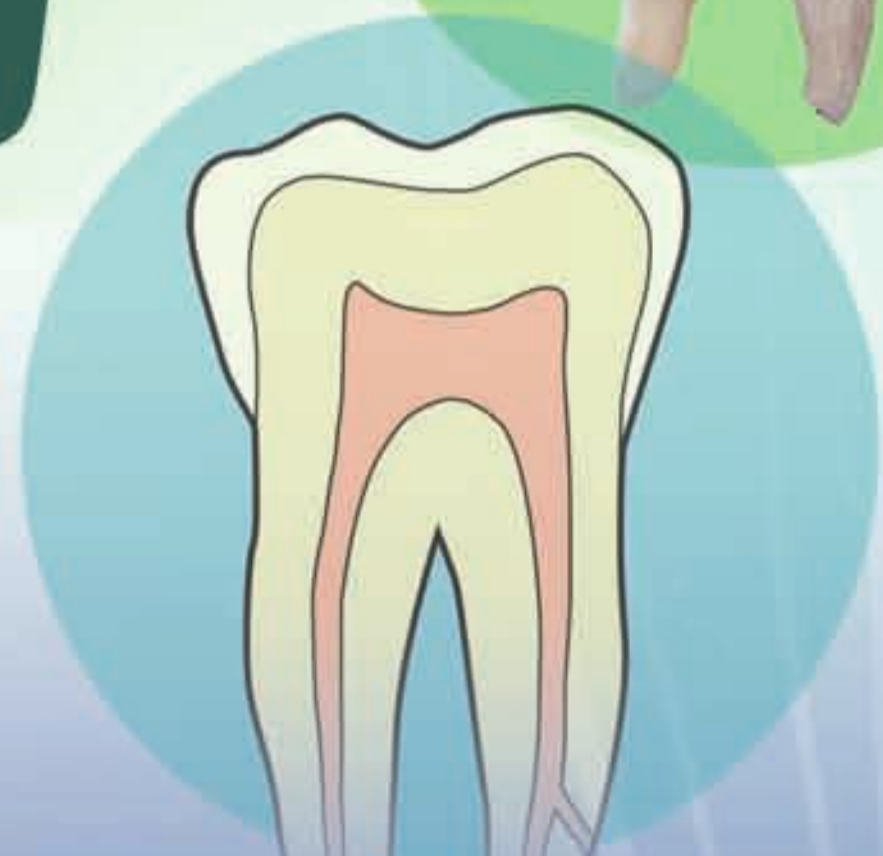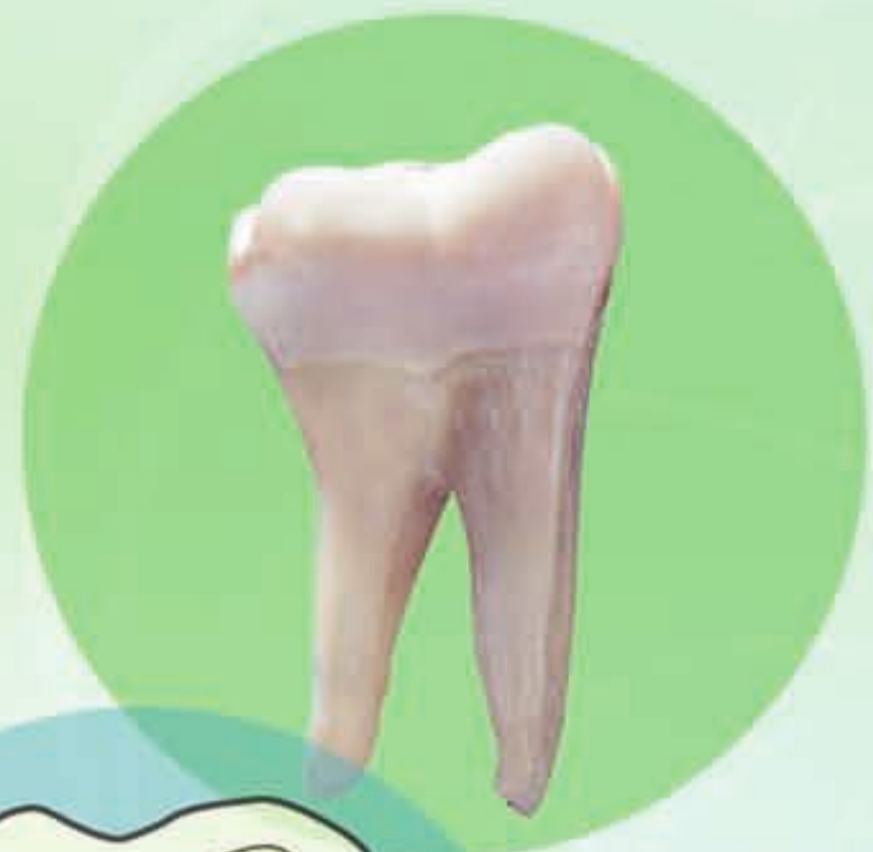**NINTH EDITION**

**Rickne C. Scheid, DDS, MEd**

Associate Professor Emeritus  
The Ohio State University College of Dentistry  
Columbus, Ohio

**Gabriela Weiss, DDS**

Associate Professor  
The Ohio State University College of Dentistry  
Columbus, Ohio



**Wolters Kluwer**

Philadelphia • Baltimore • New York • London  
Buenos Aires • Hong Kong • Sydney • Tokyo

Acquisitions Editor: Jonathan Joyce  
Product Development Editor: John Larkin  
Editorial Assistant: Tish Rogers  
Marketing Manager: Leah Tomson  
Production Project Manager: David Saltzberg  
Design Coordinator: Steve Druding  
Manufacturing Coordinator: Margie Orzech  
Prepress Vendor: SPi Global

Ninth Edition

**Copyright © 2017 Wolters Kluwer**

Copyright © 1998, 2002, 2008, 2012 Wolters Kluwer Health / Lippincott Williams & Wilkins. All rights reserved. This book is protected by copyright. No part of this book may be reproduced or transmitted in any form or by any means, including as photocopies or scanned-in or other electronic copies, or utilized by any information storage and retrieval system without written permission from the copyright owner, except for brief quotations embodied in critical articles and reviews. Materials appearing in this book prepared by individuals as part of their official duties as U.S. government employees are not covered by the above-mentioned copyright. To request permission, please contact Wolters Kluwer at Two Commerce Square, 2001 Market Street, Philadelphia, PA 19103, via email at [permissions@lww.com](mailto:permissions@lww.com), or via our website at [lww.com](http://lww.com) (products and services).

9 8 7 6 5 4 3 2 1

Printed in China (or the United States of America)

---

**Library of Congress Cataloging-in-Publication Data**

Names: Scheid, Rickne C., author. | Weiss, Gabriela (Gabriela Alejandra), author.

Title: Woelfel's dental anatomy / Rickne C. Scheid, Gabriela Weiss.

Other titles: Dental anatomy

Description: Ninth edition. | Philadelphia : Wolters Kluwer, [2016] | Includes bibliographical references and index.

Identifiers: LCCN 2015038917 | ISBN 9781496320223 (paperback)

Subjects: | MESH: Tooth—anatomy & histology—Outlines. | Jaw—anatomy & histology—Outlines. | Mouth—anatomy & histology—Outlines.

Classification: LCC QM311 | NLM WU 18.2 | DDC 611/.314—dc23 LC record available at <http://lccn.loc.gov/2015038917>

---

This work is provided “as is,” and the publisher disclaims any and all warranties, express or implied, including any warranties as to accuracy, comprehensiveness, or currency of the content of this work.

This work is no substitute for individual patient assessment based upon healthcare professionals' examination of each patient and consideration of, among other things, age, weight, gender, current or prior medical conditions, medication history, laboratory data and other factors unique to the patient. The publisher does not provide medical advice or guidance and this work is merely a reference tool. Healthcare professionals, and not the publisher, are solely responsible for the use of this work including all medical judgments and for any resulting diagnosis and treatments.

Given continuous, rapid advances in medical science and health information, independent professional verification of medical diagnoses, indications, appropriate pharmaceutical selections and dosages, and treatment options should be made and healthcare professionals should consult a variety of sources. When prescribing medication, healthcare professionals are advised to consult the product information sheet (the manufacturer's package insert) accompanying each drug to verify, among other things, conditions of use, warnings and side effects and identify any changes in dosage schedule or contraindications, particularly if the medication to be administered is new, infrequently used or has a narrow therapeutic range. To the maximum extent permitted under applicable law, no responsibility is assumed by the publisher for any injury and/or damage to persons or property, as a matter of products liability, negligence law or otherwise, or from any reference to or use by any person of this work.

LWW.com

# About the Authors

## Rickne c. Scheid, d d S, Med



Dr. Rickne Scheid received his DDS in 1972 at The Ohio State University and was inducted into the dental honorary fraternity, Omicron Kappa Upsilon. After serving in the U.S. Navy Dental Corps, he practiced part-time practice and taught at his alma mater from 1974 until 2006 when he retired with Emeriti status. His appointments at the

College of Dentistry were in the Division of Dental Hygiene, the Section of Restorative and Prosthetic Dentistry, and the Section of Primary Care. While teaching, he earned his Masters in Education with honors in 1980. Throughout his teaching career, he authored or coauthored nearly 50 scientific papers and abstracts and developed and directed 12 courses, including the Dental Anatomy course. He directed this course for 10 years, lecturing to both dental and dental hygiene students. Further, he helped develop and annually co-direct numerous continuing education courses including a review course for dental hygienists returning to practice, a dental anatomy review course for dentists and dental auxiliaries, and an expanded functions course for dental auxiliaries. He was inducted into the dental hygiene honorary, Sigma Phi Alpha, in 1989 and has received numerous dental and dental hygiene student teaching awards as well as the peer-evaluated Postle Teaching Award in 1996. In retirement, he has presented continuing education courses at the university and has served as an evaluator for the Commission on Dental Testing for Expanded Functions Dental Auxiliaries in Ohio.

## GabRiel a WeiSS, d d S



Dr. Gabriela Weiss received her DDS in 1986 from the National University of Tucuman, Argentina, where she graduated as Valedictorian. After graduation, she completed a clinical fellowship in Occlusion and Oral Rehabilitation in Argentina. The following year she was awarded the F.A.M.U., an honor given to the Outstanding Professional Female. In 1988, she moved to California in the

United States where she worked in a private practice. Then, in 1994, she moved to Michigan to pursue her passion for teaching at the University of Michigan Dental School where she taught Operative and Prosthetic Dentistry courses and became director of Dental Anatomy and Occlusion. She continued teaching these courses and directing dental anatomy at two other dental schools, first at University of Pittsburgh and later at The Ohio State University College of Dentistry where she is currently an Associate Professor. She recently developed a course designed to improve the hand skills of prospective dental students. Students have recognized her passion and talent for teaching by presenting her with 14 Student Government Teaching Awards over the years.

# Reviewers

- Nancy Andrews, RDH, BSHRP, MEd, Assistant Professor, William Rainey Harper College, Palatine, Illinois
- Kimberly Beistle, PhD, RDH, CDA, Program Coordinator, Professor, Dental Hygiene and Medical Imaging, Ferris State University, Big Rapids, Michigan
- Amy Booth, CDA, RDH, MEd, School of Dental Hygiene, Quinsigamond Community College, Worcester, Massachusetts
- Lynn Ann Bryan, BSDH, RDH, MEd, Clinical Associate Professor, School of Dentistry, Marquette University, Milwaukee, Wisconsin
- Joanna Campbell, RDH, MA, MA, Associate Professor, Health Professions Division, Dental Hygiene, Bergen Community College, Paramus, New Jersey
- Alison Collins, CDA, MS, Director, Dental Assistant Program, Northwestern Michigan College, Traverse City, Michigan
- Daniel Collins, DDS, Instructor, Allied Health Professions, Dental Hygiene Program, Columbus State Community College, Columbus, Ohio
- Deborah Corning-Hamilton, RDH, Ontario Dental Education Institute, Ancaster, Ontario, Canada
- Michelle Cummins, RDH, BSDH, Faculty Instructor, Department of Health Professions, Lane Community College, Eugene, Oregon
- Pam Davidson, RDH, MEd, Executive Director, Dental Hygiene Program, University of Arkansas–Fort Smith, Fort Smith, Arkansas
- Indu Dhir, AAS, BS, RDH, MS, Dip Dist Educ, Program Director, Canadian Academy of Dental Hygiene, Mississauga, Ontario, Canada
- Ann Dickinson, CDA, RDH, BS, MS, School of Dental Hygiene, Remington College, Nashville, Tennessee
- Candida Ditzler, CDA, RDA BBA, Dental Assistant Program Coordinator/instructor, Cape May County Technical School, Cape May, New Jersey
- Eric Dixon, DMD, Dental Assisting and Dental Hygiene Integrated Program, Big Sandy Community and Technical College, Prestonsburg, Kentucky
- Donna Eastabrooks, CDA, RDH, MA, PhD, College of Health Science & Public Health, Dental Hygiene, Eastern Washington University, Cheney, Washington
- Cinda Fife, LDH, BGS, Clinical Assistant Professor, Dental Education, College of Health and Human Services, Indiana University Northwest, Gary, Indiana
- Tammy Fisher, RDH, BS, Concorde Career College, Dallas, Texas,
- Deborah Hoxea, RDH, BS, MAEd, Dental Hygiene Program Director, Mesa Community College, Mesa, Arizona
- Teresa Roma Jasinevicius, DDS, MEd, Associate Professor, School of Dental Medicine, Case Western Reserve University, Cleveland, Ohio
- Marlaina Lantzy, RDH, BAS, MSDH, Instructor, Dental Programs Department, Hagerstown Community College, Hagerstown, Maryland
- Judith E. Romano-DiLorenzo, RDH, BS, MA, Department Chair, Dental Hygiene Program, Hudson Valley Community College, Rochester, New York
- Jose Vivas, DDS, Clinical Associate Professor, School of Dentistry, University Of Michigan, Ann Arbor, Michigan



# Preface to the Ninth Edition

Woelfel's Dental Anatomy is primarily intended as a study guide for dental students, dental hygiene students, dental assistants, and dental laboratory technicians as they master the details of tooth morphology and their usefulness in the dental office. The book provides dental and dental hygiene students with basic knowledge required when answering dental anatomy questions on the national board examinations, but it goes well beyond by discussing the application of tooth morphology and terminology as it relates to the practice of dentistry. Five chapters provide an introductory overview to periodontics, endodontics, occlusion, restorative dentistry, and forensic dentistry. The book with its Power Point lecture slides and test items for teachers and its many learning exercises was designed for instructors of dental anatomy courses as a teaching manual during lectures, discussion periods, and laboratory sessions, as well as during early clinical experiences. It is also useful as a reference in the dental office.

## new in This edition

Over 120 new color illustrations were added in this edition, especially in the first six chapters where unique traits of each type of each tooth are best learned by visualizing multiple examples of teeth from different views. Further, to facilitate learning, many existing illustrations were reorganized and improved by adding new labels, arrows, color highlights, and tooth numbers.

Chapters that provide the introduction to the specialty areas of dentistry were updated to include the most current terminology and new topics including the description of healthy tissues surrounding dental implants. The chapter on forensic dentistry was expanded to include more current examples of the relevance of forensic dentistry. Further, several new examples of anomalies were added, as well as several new anatomical structures of the head including the location and clinical relevance of paranasal sinuses.

Finally, the authors developed numerous critical thinking exercises that require the learner to search the Internet for specific images and answer questions that serve to expand the learner's appreciation of topics covered within the book.

## book Features

The book is organized into three parts. Part I, **Comparative Tooth Anatomy**, includes six chapters. The first chapter begins with an introduction to terminology and concepts related to tooth morphology that provides the foundation for the next four chapters on adult tooth traits. In these chapters, the authors present similarities and differences using drawings, photographs, and many summary tables. Primary teeth and their eruption patterns are discussed in Chapter 6.

Part II, **Application of Tooth Anatomy in Dental Practice**, has seven chapters. The first two chapters include a discussion of roots of the adult teeth related to the external surfaces and supporting tissues involved in periodontal therapy and the internal anatomy of the roots involved in endodontic therapy. Other chapters include a contemporary overview of ideal occlusion, operative and restorative dentistry, and forensic dentistry. Finally, there is an extensive discussion about many commonly encountered dental anomalies as well as a chapter designed to help students draw, carve, and sketch teeth.

Part III, **Anatomical Structures of the Oral Cavity**, includes two chapters. One chapter presents the relationship of the teeth to landmarks of the skull, the temporomandibular joints, and the muscles, nerves, blood supply, and lymph drainage associated with the oral cavity. The other chapter includes a description of normal oral structures observed during a head and neck cancer screening examination and shows sites for injections for local anesthetic relative to the underlying nerve locations.

Each chapter includes methods designed to help you, the reader, master the content, and put it to practice immediately.

- **Topic list:** Each chapter begins with a list of topics presented in the same order as the sections within that chapter.
- **Learning objectives:** In each chapter, learning objectives are presented to help you appreciate what you can expect to learn as you read and that you can reference after you study to ensure that you have mastered the specified knowledge and skills.
- **New terms:** As each new term is encountered for the first time, it is highlighted in **bold print** and is defined within the text at that time, often with references to figures, diagrams, and tables to improve understanding. The bold print is helpful when searching for important terms that are listed alphabetically in the index at the end of the book.
- **Glossary:** New in this edition is an extensive glossary providing brief definitions of all important terms presented in this edition. However, many terms in dentistry are best appreciated by referring to illustrations or photographs for a complete understanding. Terms in the index include the page where you can find the term (in bold) along with its definition, and often, a reference to an associated illustration for the best learning.
- **Pronunciations:** New terms that may be difficult to pronounce have phonetic suggestions placed within brackets [like this] immediately after the word is first encountered.
- **Review questions with answers:** Many chapters or sections end with a series of review questions to test the learner's mastery of the objectives. These questions, in

many cases, cover concepts similar to those included on past dental and dental hygiene national examinations. For the convenience of quick and convenient feedback, the answers are presented immediately following the questions.

- **Learning exercises:** Most chapters include a number of learning exercises. These exercises are presented at intervals where the authors feel an active learning experience would be helpful for you to understand and/or apply the topic. These exercises may suggest that you examine extracted teeth or tooth models, or skulls (or skull models), or perform specific self- or partner examinations. New in this edition are many guided searches on the Internet designed to expose the learner to many examples of concepts discussed in that chapter. More advanced exercises (as in Chapter 13) provide methods for drawing and sketching teeth, and carving teeth from wax, thus helping you to become intimately familiar with tooth shape and terminology.
- **Summary tables:** Throughout the text, the authors have included numerous tables to summarize the many facts presented within the text. These tables are helpful when reviewing the highlights of content found within each section.
- **Original illustrations and drawings:** For complete understanding and clinical application of each topic, the authors have included a variety of photographs, illustrations, and original colorized drawings selected and designed to illustrate key points and improve learning. Over 120 new color illustrations have been added to this edition. Also, on [thePoint](#)® companion Web site, there is an image bank for instructors containing all of the illustrations and drawings in the text that can be used when lecturing.
- **Appendix of comparative dental anatomy:** This text's unique Appendix is designed to help the learner visualize the many tooth similarities and differences that are often difficult to understand with words alone. Each adult tooth class is referenced on two separate appendix pages. The first page includes traits (each trait is identified with a different letter) that are common to all teeth within that class. The second page is devoted to the differences (each identified with a letter) between the types of teeth within each class and differences between teeth in each arch. In addition, two appendix pages illustrate the unique characteristics of anterior and posterior primary teeth. The layout on these pages makes it easy to compare the differences between teeth because views of each tooth type are lined up on the same page next to other teeth in that class. As each tooth characteristic is described within the chapters on tooth morphology (Chapters 1 to 6), reference is frequently made to the illustrated representation of that characteristic on an appendix page as follows: The word "Appendix" is followed by the page number and letter denoting items being discussed (e.g., "Appendix 1a" refers you to the Appendix, page 1, item "a"). The authors recommend that you copy each

Appendix page (front and back sides) or print out these pages from the online source [thePoint](#)® provided for this book, and place them in a separate loose-leaf notebook to facilitate study and minimize page turns as you read chapters two through six. When used in this fashion, these pages provide you with increased convenience (since fewer page turns are required when referencing all of the tooth characteristics within each chapter), easier learning (since the complex terminology used to describe each characteristic is best learned by visualizing that characteristic and comparing it to other similar teeth), and a separate study guide (since all lettered traits for each type of tooth are described on the back of each appendix page).

- **Research data:** This text is unique since it includes both original and reviewed research findings based on the study of thousands of teeth, casts, and mouths. Information on crown and root dimensions was obtained from measurements of a convenient sample of 4572 teeth extracted by Ohio dentists and studied by Dr. Julian Woelfel and his dental hygiene students at The Ohio State University between 1974 and 1979. The data from these studies are presented throughout the text by using superscript letters like this (data<sup>A</sup>) that refer to the data listed by letters at the end of the chapters. For example, the text states that a mesial marginal groove is a distinguishing characteristic of the maxillary first premolar,<sup>A</sup> and at the end of the chapter under A, you are told that this occurred in 97% of the 600 premolars studied, which means that, on the average, 3% may not have this groove, whereas only 37% of maxillary second premolars are likely to have this groove.

### SUGGESTIONS FOR STUDYING THE

Spend time thinking about and comprehending each new concept as you read. After all, you are learning the "foreign" language of dental anatomy that you will be using for the rest of your professional lives. Have fun looking at teeth as though you were a tooth detective. Take notes, sketch different views of each tooth, and take advantage of all learning exercises, references to figures, and the appendix. Ask questions until your curiosity is satisfied. The authors hope this book will stimulate your interest and involvement in the wonderful and fascinating field of dentistry and that you will consider this book to be a worthwhile addition to your library even after your formal education is complete.

As you begin learning the characteristics that differentiate each type of tooth as described in Part I, you need to be aware of the considerable variation in tooth morphology that can occur from one person to the next. Keep in mind that tooth sizes and characteristics cited within the text do not apply to all patients' teeth but are based on average sizes or particular morphology occurring with the greatest frequency. Observe the similarities and differences between each type of tooth by comparing the many photos of teeth included in this book.

Since a picture is worth a thousand words, it is very important that you refer to all figures whenever they are referenced in order to maximize learning. In most cases, important traits are emphasized or clarified in the illustration legends, so read the legends as you study each figure. Also, try covering the labels on each illustration in order to test yourself on the terms you are learning. Be sure to test your knowledge by participating in all learning exercises, and answer all test items included in each chapter to make sure you do not need to review the material before proceeding. When studying each table, try to list as many traits as you can for each tooth and see how many traits you have not remembered. Finally, it is imperative that you refer to the Appendix items as they are discussed to make sure that you can visualize each trait that is being discussed, and later, review the traits listed on the back of each appendix page to assure that you understand each concept. If a description of a trait is not clear, turn the page over in order to visualize the trait. After studying each chapter, refer back to the objectives presented at the beginning of the chapter and ask yourself if you have mastered each one. As you become familiar with the many similarities and differences of tooth morphology, you can later apply your knowledge during patient treatment, evaluation, and education.

As you read the description of tooth morphology, it would be ideal to use a dental explorer on an actual tooth or model to “feel” the contours being described since you will eventually be required to evaluate, reproduce, and/or clean the surfaces of these tooth contours with specific dental instruments. The best resource for learning about teeth is a collection of as many intact extracted teeth as you are able to acquire. A dentist, if presented with a quart jar of bleach, will remember his or her own student days and will probably be glad to put extracted teeth in the jar. Do not expect these teeth to be clean or sorted out; sorting is your job. While handling these teeth, it is critical to follow the guidelines for infection control presented here:

### Guidelines For Sterilizing and Studying Extracted Teeth

Using protective gloves and a mask, tooth specimens should be scraped clean with a knife. Soaking for several hours in

hydrogen peroxide before scraping is helpful. After scraping to remove hard deposits and soft tissue, tooth specimens should be further cleansed by soaking for 20 minutes in 4 ounces of household bleach containing 2 tablespoons of Calgon (a water softener). Teeth can then be placed in water (in a beaker covered with tin foil) to be autoclaved for 40 minutes at 121°C and 15 psi (Pantera E, Schuster G. *J Dent Ed* 1990;54(5):284). Once prepared, teeth should be kept moist, either by soaking in water or, as suggested by Dr. Kim Loos, DDS, by soaking in 25% glycerin and 75% water (parentsplace.com, February 28, 2001).

### Additional Resources

Woelfel's Dental Anatomy includes additional resources for both instructors and students that are available on the book's companion Web site at <http://thePoint.lww.com/Scheid9e>

#### Instructor Resources

Approved adopting instructors will be given access to the following additional resources:

- PowerPoint Presentations
- Interactive image bank with the option of displaying images with or without labels
- Test Generator
- Answers to end-of-chapter Critical Thinking Questions

#### Student Resources

Students who have purchased Woelfel's Dental Anatomy have access to the following additional resources:

- Image labeling exercises
- Interactive image bank with the option of displaying images with or without labels
- PowerPoint Presentations

In addition, purchasers of the text can access the searchable Full Text Online by going to the Woelfel's Dental Anatomy Web site at <http://thePoint.lww.com/Scheid9e>

See the inside front cover of this text for more details, including the passcode you will need to gain access to the Web site.


# Acknowledgments

During my first year teaching at The Ohio State University College of Dentistry in 1974, I was fortunate to be assigned to teach in a laboratory for dental anatomy where I worked with and was mentored by, Dr. Julian Woelfel. He asked me to contribute the chapter on Operative Dentistry in the third edition in 1984. Little did I realize that in 1994, he would select me to coauthor the fifth edition of a text on the very topic I began teaching in 1974: dental anatomy. During the preparation for the fifth and sixth editions, Julian permitted me great latitude in reorganizing the text to reflect my teaching style since I used this text as I taught over 135 dental and dental hygiene students each year. During this major reorganization, I was careful to maintain the unique aspects that he had incorporated into previous editions. This includes the results of his personal, science-based research, which formed the basis for many of the conclusions presented within this text: on everything from the average mandibular hinge opening to the frequency of Carabelli cusp formation and the comparative sizes of primary and permanent teeth. In the seventh edition, Dr. Woelfel entrusted me to take over the text.

I would like to express my appreciation to all of the contributors to this and previous editions of this book. My thanks goes to Dr. Woelfel for selecting me to take over the book and teaching me to be meticulous, and for his many contributions to this text; to his wife, Marcile, who helped tremendously in typing and editing previous editions; and to the following colleagues who updated chapters in this edition: Dr. Binnaz Leblebicioglu and Dr. Lewis Claman (Periodontal anatomy), Dr. D. Stanley Sharples, II (Restorative dentistry), and Dr. Shereen Azer (Occlusion), Dr. John Nusstein (Endodontics), and Dr. Daniel Jolly (Forensic Dentistry) and Dr. Burak Yilmaz (who helped with the photography for this edition). I would also like to recognize Ms. Dorothy Permar, who conceived and wrote the first edition in 1974, and Dr. Robert Rashid, Dr. Theodore Berg, Jr., Dr. Al Reader, and Ms. Connie Sylvester, who contributed to previous editions. Finally, a special thanks goes to my co-author, Dr. Gabriela Weiss, who collaborated with me to incorporate the many improvements and additional teaching exercises and test items, and in the daunting task of editing and proofing each chapter.

Rickne C. Scheid, DDS, MEd

## about Dr. Julian Woelfel



Professor Emeritus Julian Woelfel, known primarily for his expertise in complete dentures, research, and occlusion, has taught clinical dentistry for 40 years in the College of Dentistry at The Ohio State University, Columbus, Ohio. He served as an Army prosthodontist in Texas for 2 years, conducted clinical research for

the American Dental Association at the National Bureau of Standards in Washington, District of Columbia, for 3 years, and was a visiting professor in Japan, Taiwan, England, and Brazil. Dr. Woelfel has lectured in 18 foreign countries. He has published 85 scientific articles, 8 editions of this Dental Anatomy textbook, and chapters in 5 other dental books. Dr. Woelfel also has published scientific dental articles in Japan, Bulgaria, and Brazil. He holds patents on two inventions that are used in Europe and the United States for accurately recording jaw relation. In addition to Dr. Woelfel's love for students and teaching, he had a part-time dental practice limited to partial and complete dentures for 33 years. One of his proudest accomplishments has been this textbook. In 1967, he was the first recipient of the International Association of Dental Research Award for Research in Prosthodontics and was awarded a Life Membership in the Japanese Nihon University Dental Alumni Association. In 1972, the New York Prosthodontic Society selected him for the Jerome and Dorothy Schweitzer Award for Outstanding and Continuing Research in Prosthodontics. In 1992, the Ohio Dental Association chose Dr. Woelfel for the prestigious Callahan Award, and in 2004, he was the recipient of the Distinguished Alumnus Award from the Ohio Dental Alumni Association. He is a Life Member of Sigma Xi, the International Association for Dental Research, the American Prosthodontic Society, Sigma Phi Alpha Dental Hygiene Honor Society, and the ADA, AES, FDI, FICD, and FACD.

Comments or suggestions may be submitted to Dr. Scheid on e-mail ([scheid.2@osu.edu](mailto:scheid.2@osu.edu)).

# Contents

About the Authors	v
Reviewers	vi
Preface to the Ninth Edition	vii
Acknowledgments	x

## Part 1 c o M P a R a T i V e T o o T h a n a T o M y 1

1	Basic Terminology for Understanding Tooth Morphology . . . . .	3
2	Morphology of the Permanent Incisors . . . . .	49
3	Morphology of the Permanent Canines . . . . .	78
4	Morphology of Premolars . . . . .	96
5	Morphology of Permanent Molars . . . . .	135
6	Primary (and Mixed) Dentition . . . . .	182

## Part 2 a P P l i c a T i o n o F T o o T h a n a T o M y i n d e n T a l P R a c T i c e 213

7	Periodontal Anatomy . . . . .	215
8	Application of Root and Pulp Morphology Related to Endodontic Therapy . . . . .	249
9	Functional Occlusion and Malocclusion . . . . .	268
10	Treating Decayed, Broken, and Missing Teeth . . . . .	304
11	Dental Anomalies . . . . .	336
12	Forensic Dentistry . . . . .	358
13	Guidelines for Drawing, Sketching, and Carving Teeth . . . . .	375

## Part 3 a n a T o M i c S T R u c T u R e S o F T h e o R a l c a V i T y 389

14	Structures That Form the Foundation for Tooth Function . . . . .	391
15	Oral Examination: Normal Anatomy of the Oral Cavity . . . . .	449

Appendix	481
Glossary for Woelfel's Dental Anatomy	503
Index	523



PART

1

# Comparative Tooth Anatomy

The six chapters in this part of the book provide a detailed description of each type of tooth in an adult and in a child.





# 1

## Basic Terminology for Understanding Tooth Morphology

The background terminology and tooth morphology concepts presented in this chapter are divided into 10 sections as follows:

- I. **Naming teeth based on location within the normal, complete human dentition**
  - A. Complete primary dentition
  - B. Complete permanent dentition
- II. **Tooth identification systems: Universal, World Dental Federation (International), and Palmer Numbering Systems**
- III. **Terminology used to describe the tissues of a tooth (and definition of anatomic crown and root)**
- IV. **Introduction to the periodontium (and definition of clinical crown and root)**
- V. **Terminology used to define tooth surfaces**
  - A. Terms that identify outer surfaces (toward the cheeks or lips) of anterior versus posterior teeth
  - B. Terms that identify inner surfaces (toward the tongue) of maxillary versus mandibular teeth
  - C. Terms that differentiate biting surfaces of anterior versus posterior teeth
  - D. Terms that differentiate approximating surfaces of teeth
  - E. Terms to denote tooth surface junctions or dimensions
  - F. Divisions (thirds) of the crown or root (for purposes of description)
  - G. Root-to-crown ratio
- VI. **Terminology used to describe the morphology of a tooth**
  - A. Morphology of an anatomic crown
  - B. External morphology of the anatomic root
  - C. Cervical line (cemento-enamel junction or CEJ) curvature
  - D. Relative size
- VII. **Terminology related to the ideal tooth alignment of teeth in dental arches**
  - A. Midroot axis line and tooth alignment
  - B. Crest of curvature (height of contour) on the facial and lingual surface
  - C. Contact areas (or proximal crests of curvature)
  - D. Embrasure spaces
- VIII. **Ideal occlusion: inter (between) arch relationship of teeth**
- IX. **Tooth development from lobes**
- X. **Interesting variations in animal teeth compared to human teeth using dental formulae**

### Objectives

This chapter is designed to prepare the learner to perform the following:

- Based on location in the normal, complete primary dentition, name all 20 teeth by arch, quadrant, type (when applicable), and class.
- Based on location in the normal, complete permanent dentition, name all 32 teeth by arch, quadrant, type (when applicable), and class.

(Continued)

- Use the Universal Numbering System to identify permanent and primary teeth.
- Use the Palmer and International Tooth Numbering Systems to identify teeth, and “translate” them to the Universal System.
- Identify and describe the supportive structures of the teeth (periodontium).
- Identify and describe the four tissues of a tooth and their location, mineral content, and function.
- Differentiate an anatomic crown and root from a clinical crown and root.
- Name each tooth surface on anterior and posterior teeth.
- From all views, divide a tooth crown and root into thirds and label each third.
- Define terms used to describe a specific dimension of a tooth.
- Describe and identify (by name) common tooth rounded elevations, ridges, depressions, and grooves for each type of tooth.
- Describe and recognize the parts of a root.
- Describe and identify the attributes of ideal tooth alignment and embrasure spaces relative to other teeth within the arch, including the cusp or incisal edge position relative to the tooth’s midroot axis line (proximal views), location of crests of curvature and proximal contacts (facial or lingual views), and relative sizes of embrasure spaces (facial, lingual, or occlusal/incisal views).
- Describe and identify the ideal interarch relationship of teeth in class I occlusion, especially the relationship of first molars and canines.
- Identify the number of developmental lobes that form each tooth, and recognize the anatomic landmarks of a tooth that form from these lobes.

Just as you need to learn a new vocabulary before you can speak a foreign language, you need to learn a new vocabulary before you can begin to understand the “foreign language” of dental anatomy. Therefore, you need to understand each new word defined in this introductory chapter (highlighted in **bold**) in order to be able to discuss and appreciate the numerous traits that differentiate each type of tooth that are presented in the next five chapters. Without this understanding, you can neither understand others nor make yourself

understood when discussing teeth. Do you comprehend what is meant when someone says “In ideal class I occlusion, the mesiobuccal cusp of the maxillary first molar occludes with the mesiobuccal groove of the mandibular first molar”? If not, study each term in this chapter, carefully analyze each figure when it is referenced, perform all of the learning exercises, and answer each study question. Then you should be able to comprehend and picture exactly what was said in that statement.

## SECTION I

### NAmING TEETH BaSEd ON LOCaTION wITHIN ThE NOrmaL, COMpLETE hUMAN dENTITION

This section is designed to introduce you to terms used when naming teeth based on their normal location in the mouth. All of the teeth in the mouth together are referred to as our **dentition** [den TISH un]. Humans have two sets of teeth throughout life: one during childhood, called the **primary dentition**, and one that will hopefully last throughout adulthood, called the **permanent** (also known as **secondary**) **dentition**.

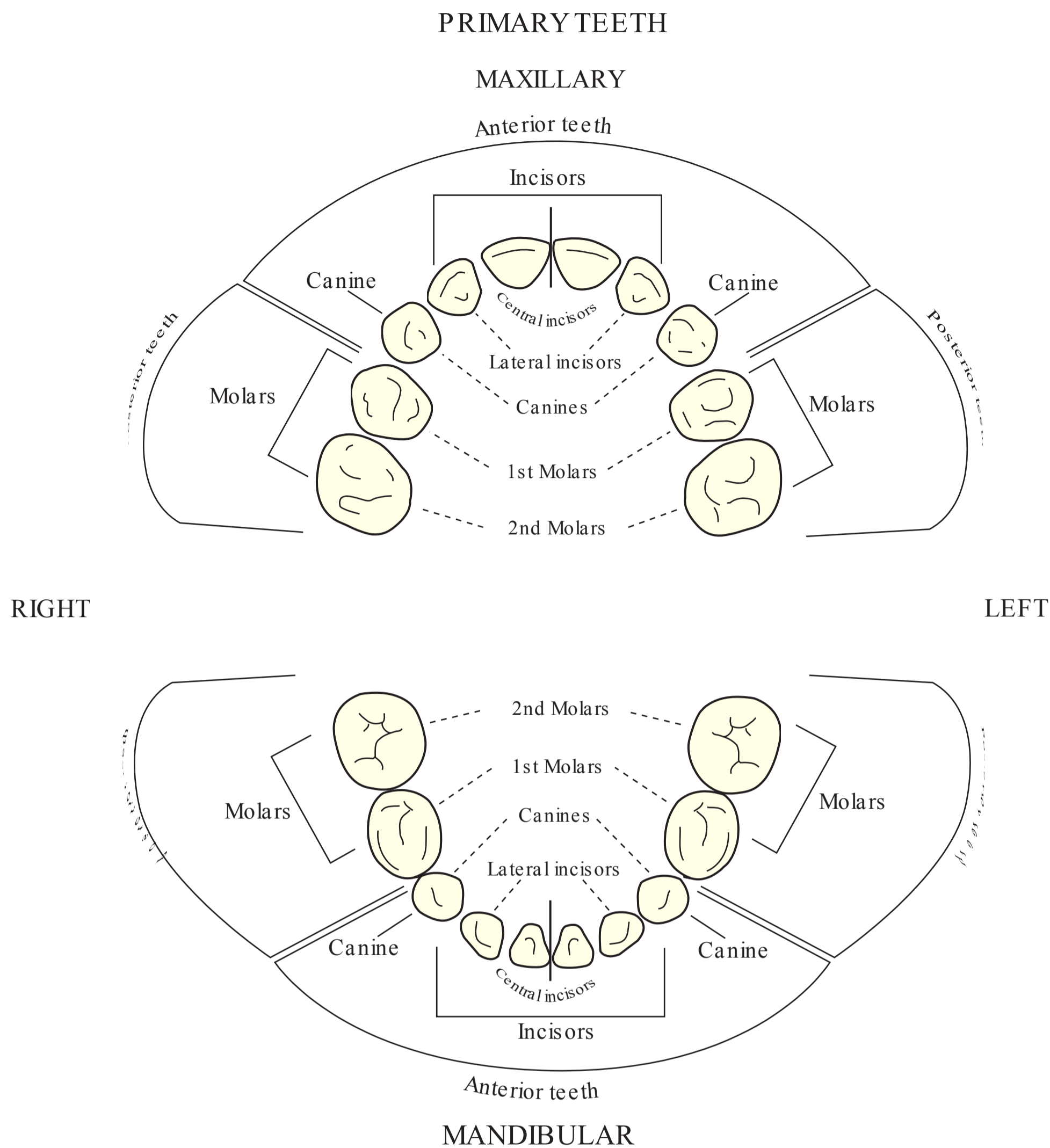
The teeth in the upper jawbones (called the maxillae [mak SIL ee]) collectively form an arch shape known as the **maxillary** [MACK si lair ee] **arch**, and those teeth in the lower jawbone (called the mandible) collectively form the **mandibular** [man DIB yoo ler] **arch**. Each arch can further be divided into the left and right halves, also known as left and right quadrants since each **quadrant** contains one fourth of all teeth in that dentition.

#### a. COMpLETE prImarY dENTITION

There are 20 teeth in the complete primary dentition (shown in Fig. 1-1). There are ten in the upper (maxillary) arch and ten in the lower (mandibular) arch. The complete primary

dentition has five teeth in each quadrant. The primary teeth in each quadrant are further divided into three **classes** based on their unique shape and function during chewing. Incisors [in SI zerz] are shaped to incise and cut off pieces of food, canines are shaped to pierce and hold on to food, and molars are shaped to grind food. Starting on either side of the arch **midline**, that is, the demarcation between the right and left quadrants, the two front teeth in each quadrant of the primary dentition are **incisors**, followed by one **canine**, and then two **molars**.

Two classes of primary teeth, incisors and molars, contain more than one tooth per quadrant and are subdivided into **types** within each class. Each type can be defined by its normal location within the complete quadrant. The type of primary incisor closest to the arch midline separating the right and left quadrants is called a **central incisor**. The type of incisor next to, or lateral to, the central incisor is called a **lateral incisor**. Next in each quadrant is a canine, followed by two types of molars: a **first molar** behind the canine and then a **second molar** (Fig. 1-1).



**Figure 1-1.** Maxillary and mandibular primary dentition. The midline of each arch is denoted by a line between the right and left central incisors.

The primary dentition is also called the **deciduous** [de-SIDJoo-us] **dentition**, referring to the fact that all of these teeth are eventually shed (like a deciduous tree loses its leaves), being replaced by teeth of the permanent dentition. The **mixed dentition** is the term used to describe the dentition where there is a mix of secondary and primary teeth visible in the mouth at the same time, during that time after permanent teeth have begun to replace primary teeth, but before all primary teeth have been lost.



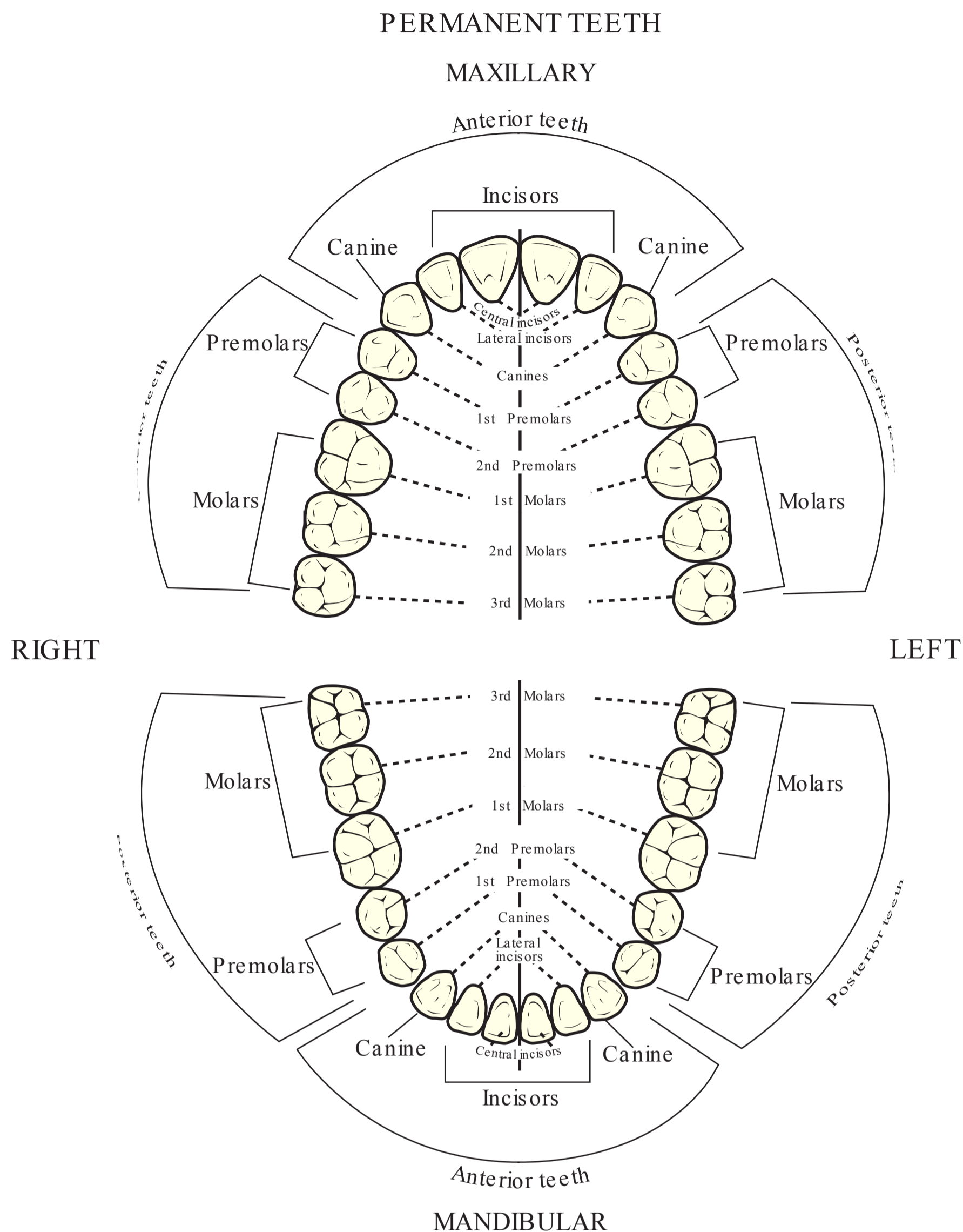
### LEARNING EXERCISE

Using either models of the complete primary dentition or Figure 1-1 while covering up the labels, identify each primary tooth based on its location in the arch. Include, in order, the dentition (primary), arch (maxillary or mandibular), quadrant (right or left), type (if applicable), and class. For example, the tooth next to the midline in the lower left quadrant would be identified as the primary mandibular left central incisor.

### B. COMPLETE PERMANENT DENTITION

The complete permanent (or secondary) dentition is present in the adult. It is composed of 32 teeth: 16 in the upper maxillary arch and 16 in the lower mandibular arch (shown in Fig. 1-2). The permanent dentition has eight teeth in each quadrant, which are divided into four **classes**: incisors that incise food; canines that pierce and hold food; **premolars**, a new class for permanent teeth shaped to chew food; and molars, also shaped to chew food. Based on location, the two permanent front teeth in each quadrant are incisors, followed by one canine, then two premolars, and finally three molars.

The classes of permanent teeth containing more than one tooth per quadrant (namely, incisors, premolars, and molars) are subdivided into **types** within each class. Each type can be identified by its normal location within the quadrant. As in the primary dentition, the permanent incisor closest to the midline between the right and the left quadrants is called a central incisor; the incisor next to, or lateral to, the central incisor is called a lateral incisor. Next in the arch is a canine,



**Figure 1-2.** Maxillary and mandibular permanent dentition. The midline of each arch is denoted by a line between the right and left central incisors.

followed by a **first premolar**, and then a **second premolar**. Continuing around toward the back in each quadrant are three molars: a first molar, a second molar, and finally a **third molar** (sometimes referred to as a **wisdom tooth**).

In summary, when comparing the teeth in primary and permanent dentitions, be sure to notice the differences. Although central incisors and lateral incisors and canines are similarly positioned in both dentitions, permanent dentitions have a new class of teeth called **premolars**, which are located between permanent canines and permanent molars. Premolars erupt into the spaces left where the primary molars were located earlier in life. Also, there are three permanent molars in each quadrant, whereas there are only two primary molars in each quadrant. These three permanent molars erupt behind the premolars where no primary teeth were previously located.

There are two other terms used to categorize or distinguish groups of teeth by their location: anterior and posterior

teeth. **Anterior teeth** are those teeth in the front of the mouth, specifically, the incisors and the canines. **Posterior teeth** are those in the back of the mouth, specifically, the premolars and the molars.



### LEARNING EXERCISE

Using either models of the complete permanent dentition or Figure 1-2 while covering up the labels, identify each permanent tooth based on its location in the arch. To identify each tooth accurately, include, in order, the dentition (permanent), arch (maxillary or mandibular), quadrant (right or left), type (if applicable), and the class. For example, the last adult tooth in the lower right quadrant is correctly identified as the permanent mandibular right third molar.



## r EvIEW Questions

These questions were designed to help you confirm that you understand the terms and concepts presented in this section. Select the one best answer.

1. How many teeth are present in one quadrant of a complete adult (permanent) dentition?
  - a. 5
  - b. 8
  - c. 10
  - d. 20
  - e. 32
2. What class of teeth is present in the permanent dentition that is NOT present in the primary dentition?
  - a. Incisors
  - b. Canines
  - c. Premolars
  - d. Molars
3. In a permanent dentition, the fifth tooth from the midline is a
  - a. Canine
  - b. Premolar
  - c. Molar
  - d. Incisor
4. The posterior teeth in the permanent dentition include which of the following?
  - a. Premolars only
  - b. Molars only
  - c. Premolars and molars only
  - d. Canines, premolars, and molars
5. Which permanent tooth erupts into the space previously held by the primary second molar?
  - a. First molar
  - b. Second molar
  - c. First premolar
  - d. Second premolar
6. How many teeth are present in one arch of the adult dentition?
  - a. 5
  - b. 8
  - c. 10
  - d. 12
  - e. 16
7. How many teeth are present in one arch of the primary dentition?
  - a. 5
  - b. 8
  - c. 10
  - d. 16
  - e. 20
8. How many incisors are present in the complete adult dentition?
  - a. 2
  - b. 4
  - c. 6
  - d. 8
  - e. 12
9. How many molars are present in the primary dentition?
  - a. 2
  - b. 4
  - c. 8
  - d. 10
  - e. 1
10. How many molars are present in each arch of the adult dentition?
  - a. 2
  - b. 3
  - c. 6
  - d. 8
  - e. 12
11. What is the fourth tooth from the midline in the primary dentition?
  - a. Canine
  - b. First premolar
  - c. Second premolar
  - d. First molar
  - e. Second molar

## SECTION II

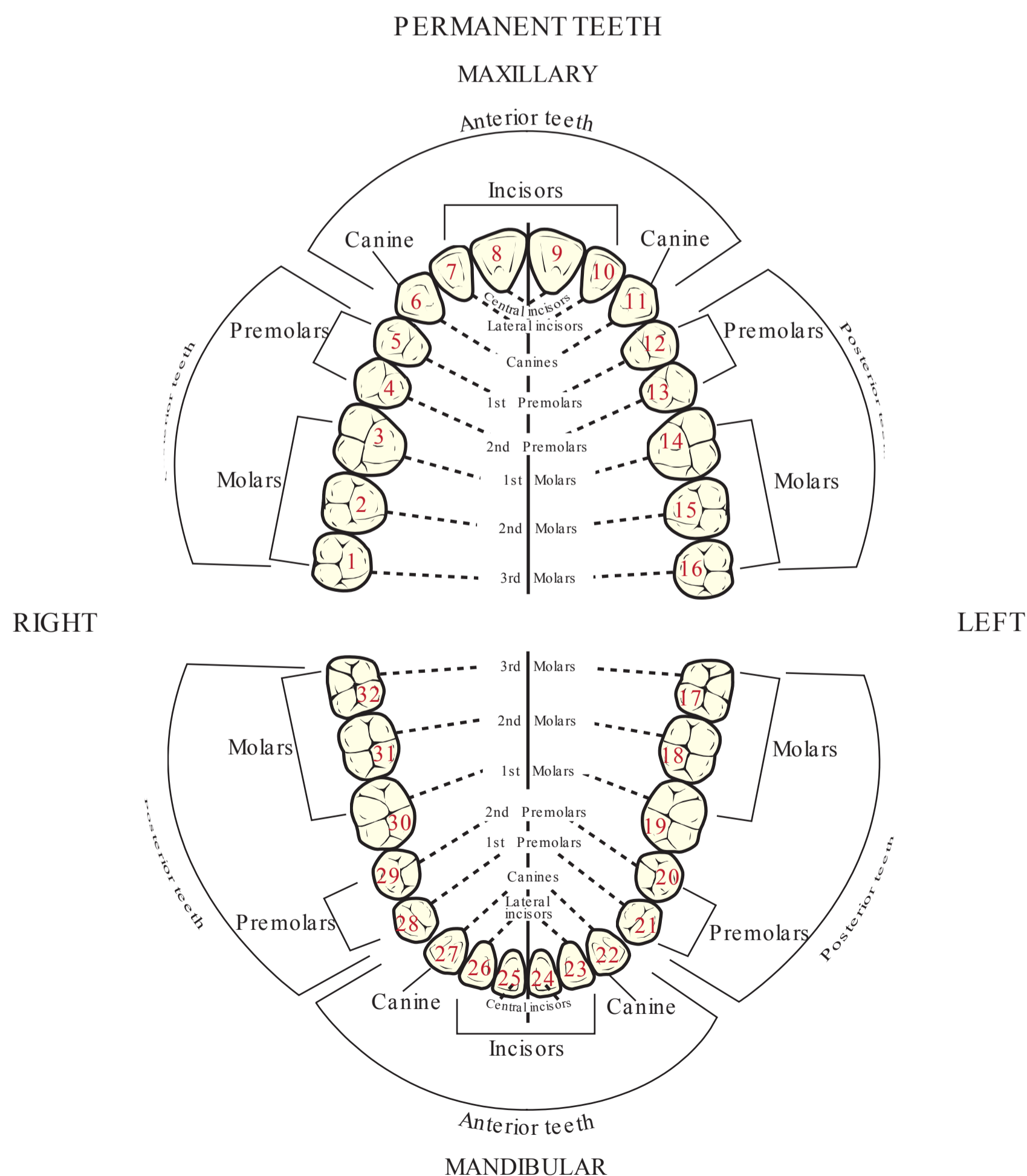
## TOOTH IDENTIFICATION SYSTEMS: UNIVERSAL, WORKLDDENTAL FEDERATION (INTERNATIONAL), AND PALMER NUMBERING SYSTEMS

Documenting patient treatment with accurate dental records is an important task in any dental practice. To do so expeditiously, it is necessary to adopt a code or numbering system for teeth. Otherwise, for each tooth being charted, one must record the dentition, arch, side, type (if applicable), and class. For example, describing a permanent maxillary right second molar requires five words, but it can be simplified by using the Universal Numbering System, identifying this same tooth with the number 2 (only one number).

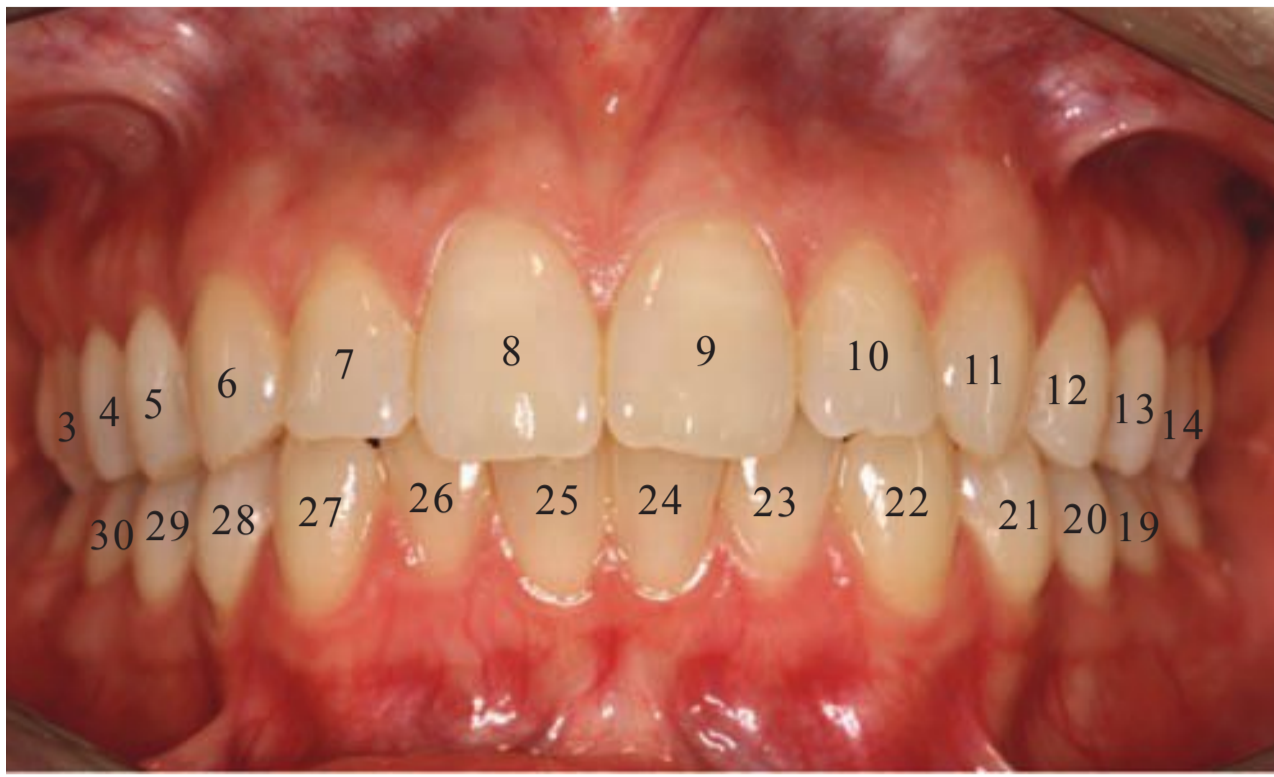The **Universal Numbering System** was first suggested by Parreidt in 1882 and officially adopted by the American Dental Association in 1975. It is accepted by third-party providers in the United States and is endorsed by the American Society of Forensic Odontology. Basically, the Universal Numbering System uses numbers 1 through 32 for the 32 teeth in the permanent dentition, starting with 1 for the

maxillary right third molar, going around the arch to the maxillary left third molar as 16; dropping down on the same side, the left mandibular third molar becomes 17, and then the numbers increase around the lower arch to 32, which is the lower right third molar. This numbering system is used for each permanent tooth in the illustration in Figure 1-3 and seen in the mouth in Figure 1-4.

For the 20 teeth in the primary dentition, 20 letters of the alphabet are used from A through T. The letter A represents the maxillary right second molar, sequentially around the arch and through the alphabet to J for the maxillary left second molar, then dropping down on the same side to K for the mandibular left second molar, and then clockwise around the lower arch to T for the mandibular right second molar. This system is used to identify each primary tooth in Figure 1-5 and in the mouth in Figure 1-6.



**Figure 1-3.** The numbers 1 through 32 on the permanent teeth identify each tooth using the Universal Numbering System, which is commonly used for record keeping in the United States and used in this book.



**Figure E 1-4.** In the mouth of an adult, the permanent teeth that are visible are numbered using the Universal Numbering System.

There are also two other numbering systems: the World Dental Federation (International) System used in other countries and the Palmer Tooth Notation System. The **World Dental Federation** notation (also known as the **Federation Dentaire Internationale** or **FDI System**) uses two digits for each permanent or primary tooth. The first digit denotes a specific quadrant (right or left), arch (maxillary or mandibular), and dentition (permanent or primary) as follows:

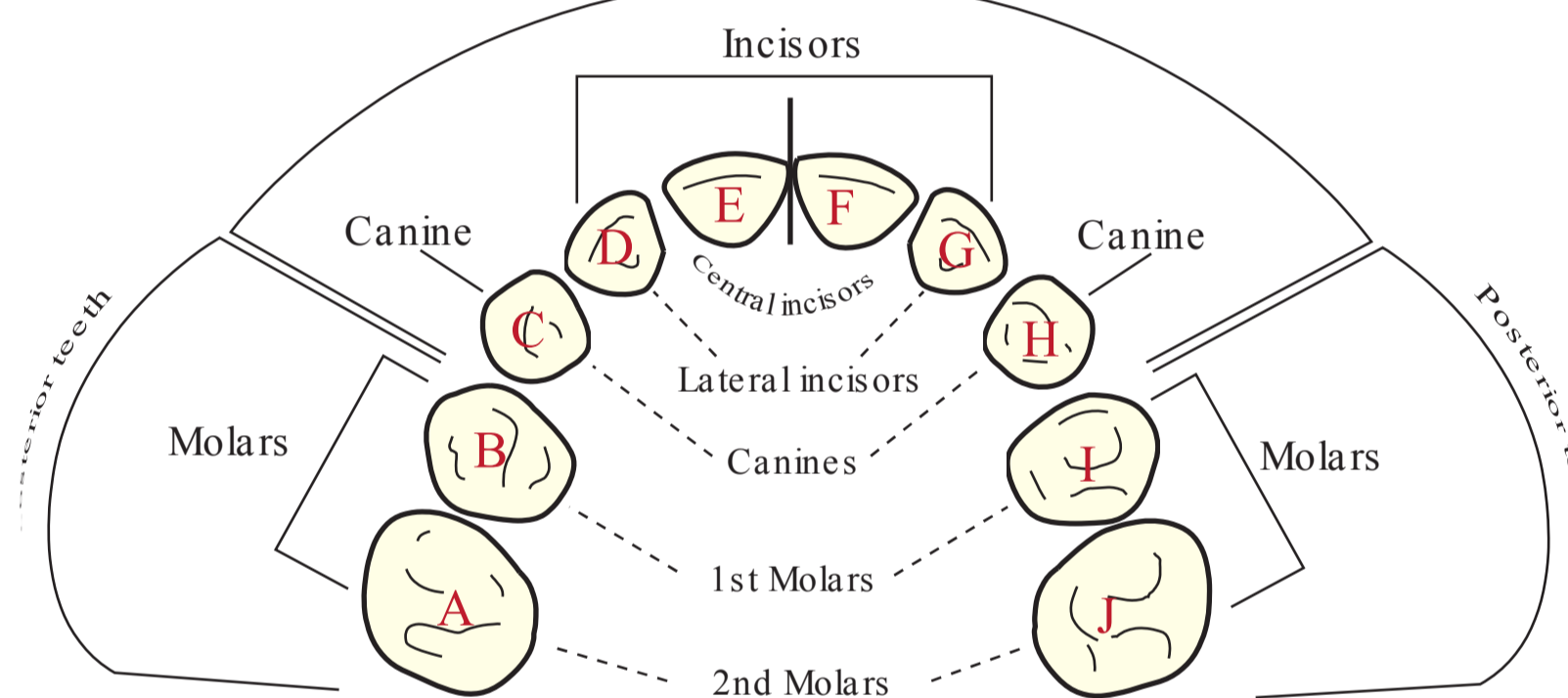
#### PERMANENT DENTITION

- 1 = Permanent dentition, maxillary, right quadrant
- 2 = Permanent dentition, maxillary, left quadrant
- 3 = Permanent dentition, mandibular, left quadrant
- 4 = Permanent dentition, mandibular, right quadrant

### PRIMARY TEETH

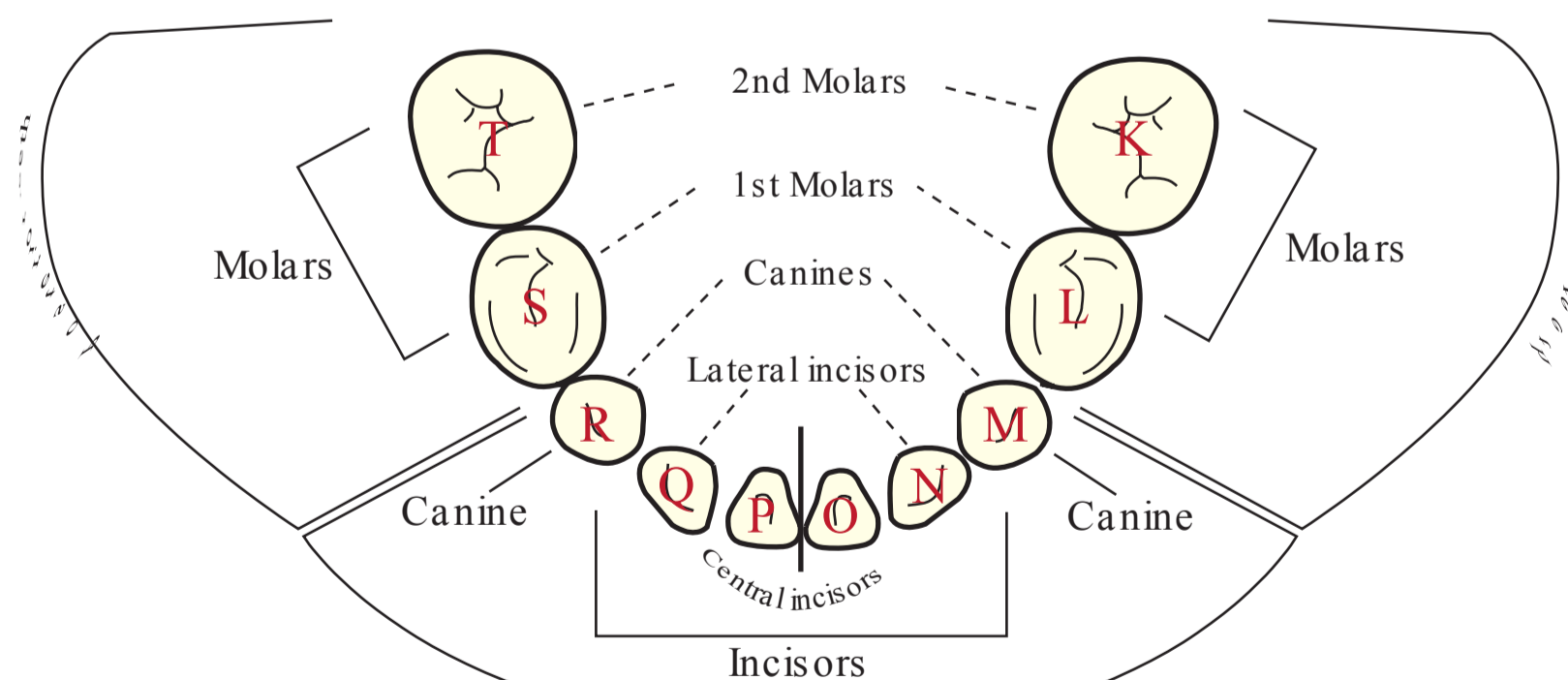
#### MAXILLARY

Anterior teeth



RIGHT

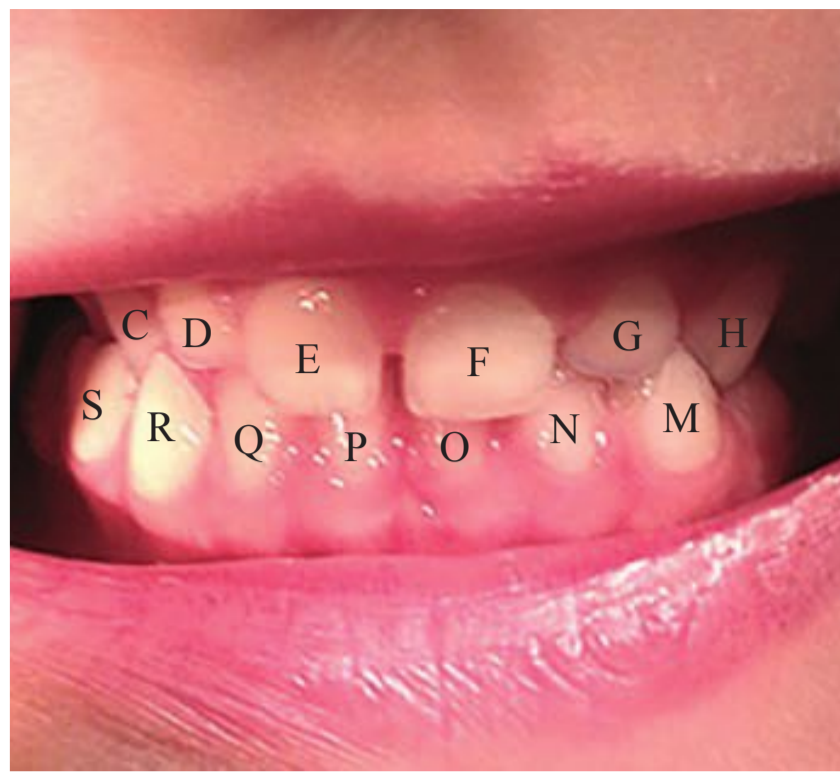
LEFT



Anterior teeth

#### MANDIBULAR

**Figure E 1-5.** The letters A to T on the primary teeth identify each tooth using the Universal System, which is commonly used for record keeping in the United States.

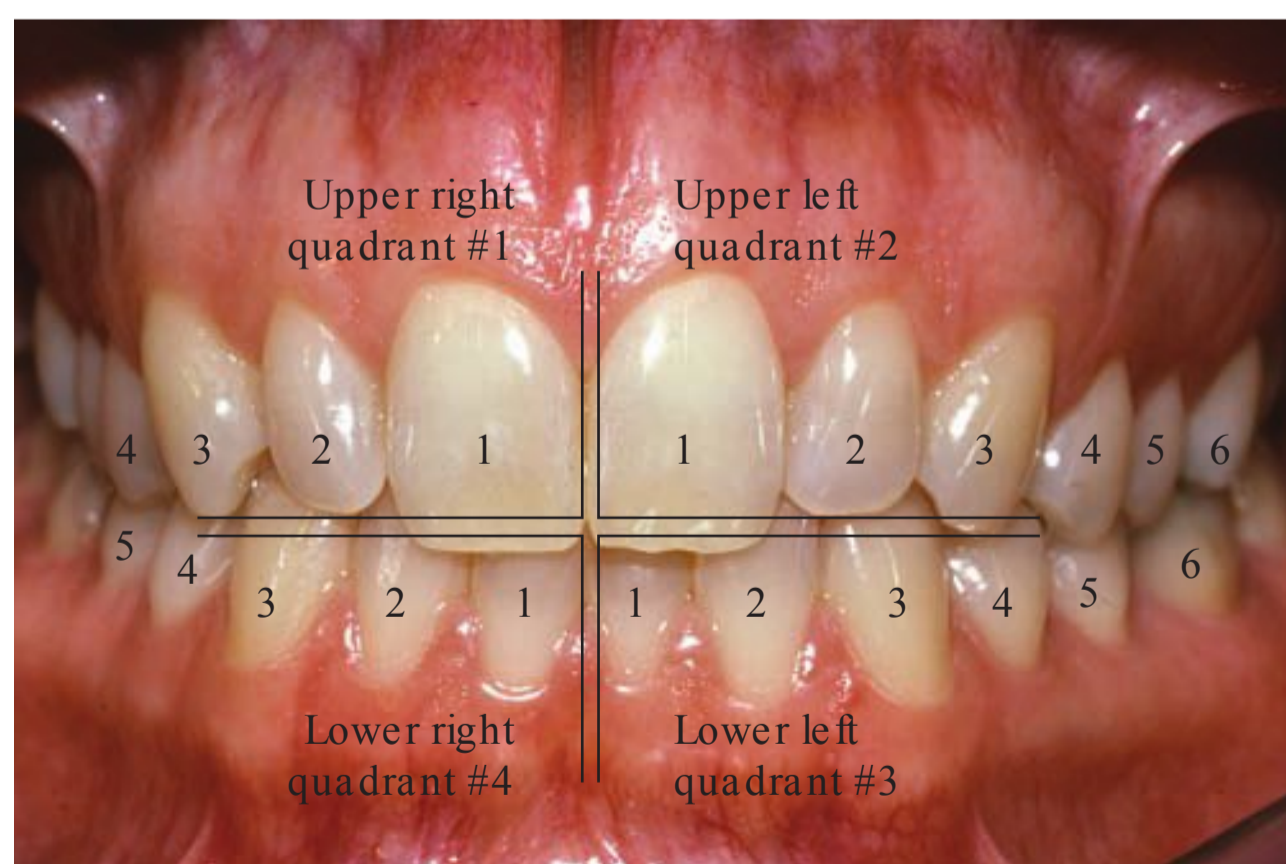


**Figure E 1-6.** In the mouth of a child, the primary teeth that are visible are identified using letters as used in the Universal System.

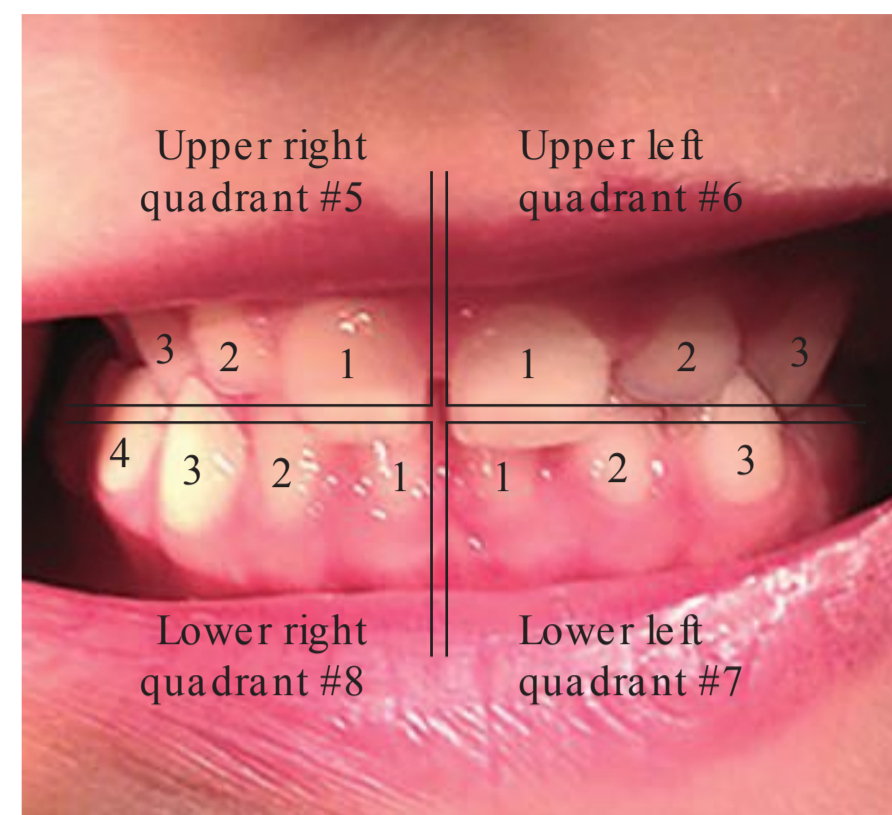
### PRIMARY DENTITION

- 5 = Primary dentition, maxillary, right quadrant
- 6 = Primary dentition, maxillary, left quadrant
- 7 = Primary dentition, mandibular, left quadrant
- 8 = Primary dentition, mandibular, right quadrant

The second digit denotes the tooth position in each quadrant relative to the midline, from closest to the midline to farthest away. Therefore, in the permanent dentition with 8 teeth in each quadrant, 1 is a central incisor closest to the midline, 2 is a lateral incisor, 3 is a canine, and so forth through 8, the permanent third molar, farthest from the midline. In the primary dentition with only 5 teeth in each quadrant, the number 1 represents the tooth closest to the midline or the primary central incisor, and the number 5 represents the tooth farthest from the midline or the primary second molar. In summary, each adult quadrant is numbered 1 through 4 and each adult tooth within that quadrant is numbered 1 to 8 (Fig. 1-7), while



**Figure E 1-7.** Two methods are shown for denoting each quadrant in the permanent dentition. The Palmer System uses a different “bracket” shape for each quadrant as you face the person, whereas the FDI International System uses the numbers 1 through 4 to denote each adult quadrant. The numbers on each tooth denote the method for identifying teeth within each quadrant beginning at the midline with number 1 for the central incisors, number 2 for lateral incisors, etc.



**Figure E 1-8.** When identifying each primary tooth using the World Dental Federation or FDI International System, each quadrant is numbered 5 through 8 as indicated, and each tooth within that quadrant is identified using numbers 1 through 5 with number 1 for the central incisors, number 2 for lateral incisors, etc.

each primary quadrant is numbered 5 to 8 and each tooth within that quadrant is numbered 1 to 5 (Fig. 1-8). (Using this system, tooth numbers within the range 11 through 48 represent permanent teeth, whereas tooth numbers within the range 51 through 85 represent primary teeth.) To cite an example, 45 is a permanent mandibular right second premolar since the first digit, 4, indicates the mandibular right quadrant in the permanent dentition, and the second digit, 5, indicates the fifth tooth from the midline in that quadrant, namely, the second premolar. Using this numbering system for the primary dentition, tooth 63 is a primary maxillary left canine since the first digit, 6, indicates maxillary left quadrant in the primary dentition, and the second digit, 3, indicates the third tooth from the midline, namely, the canine. To cite another example, 51 is a primary maxillary right central incisor since the first digit, 5, indicates the maxillary right quadrant for a primary tooth, and the second digit, 1, indicates the first tooth from the midline in that quadrant, namely, the central incisor. Finally, if the Universal number for a tooth was 32, the World Dental Federation number would be 48. If the Universal letter for a primary tooth was A, the World Dental Federation number would be 55. All tooth numbers and letters using both systems are shown in Table 1-1.

The **Palmer Notation System** is used by many orthodontists and other practitioners especially in the United Kingdom. It utilizes four different bracket shapes ( $\lrcorner$ ,  $\llcorner$ ,  $\lrcorner$ , and  $\llcorner$ ) to denote each of the four quadrants. The specific bracket surrounds a number (or letter), which denotes the specific tooth within that quadrant. The specific brackets are designed to represent each of the four quadrants of the dentition, as if you were facing the patient as seen in Figure 1-7.

- $\lrcorner$  is upper right quadrant.
- $\llcorner$  is upper left quadrant.
- $\lrcorner$  is lower right quadrant.
- $\llcorner$  is lower left quadrant.



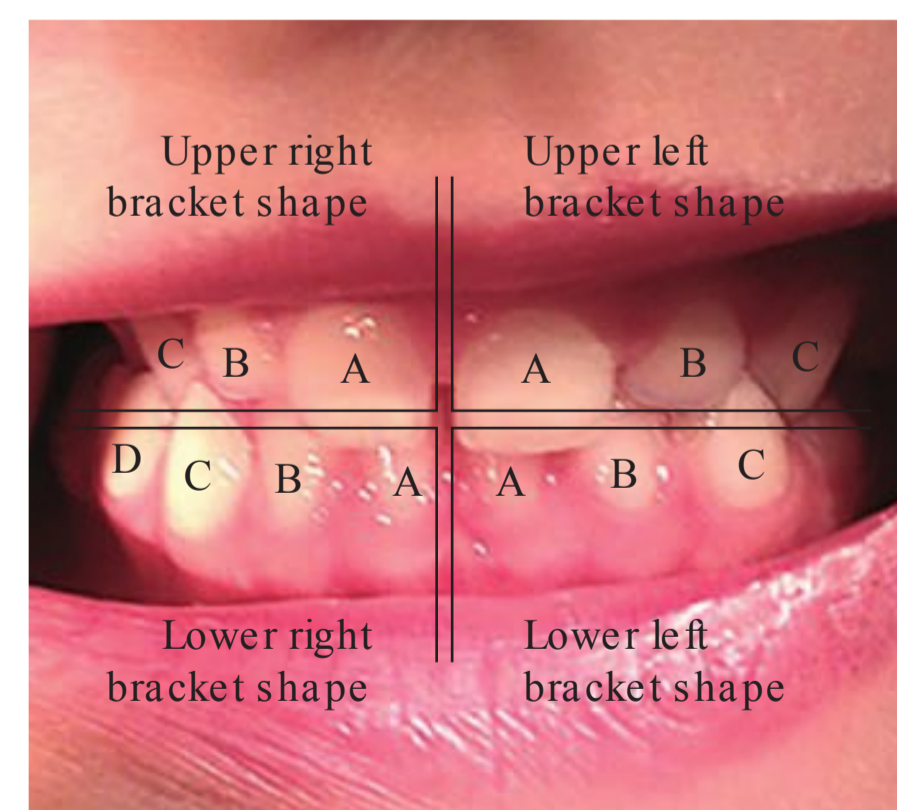
TABLE 1-1 major Tooth Identification Systems

Tooth	UNIVERSAL		PALMER NOTATION		INTERNATIONAL (FDI)	
	RIGHT	LEFT	RIGHT	LEFT	RIGHT	LEFT
Central incisor	E	F	<u>A</u>	<u>A</u>	51	61
Lateral incisor	D	G	<u>B</u>	<u>B</u>	52	62
Canine	C	H	<u>C</u>	<u>C</u>	53	63
First molar	B	I	<u>D</u>	<u>D</u>	54	64
Second molar	A	J	<u>E</u>	<u>E</u>	55	65
Central incisor	P	O	<u>A</u>	<u>A</u>	81	71
Lateral incisor	Q	N	<u>B</u>	<u>B</u>	82	72
Canine	R	M	<u>C</u>	<u>C</u>	83	73
First molar	S	L	<u>D</u>	<u>D</u>	84	74
Second molar	T	K	<u>E</u>	<u>E</u>	85	75
Central incisor	8	9	<u>1</u>	<u>1</u>	11	21
Lateral incisor	7	10	<u>2</u>	<u>2</u>	12	22
Canine	6	11	<u>3</u>	<u>3</u>	13	23
First premolar	5	12	<u>4</u>	<u>4</u>	14	24
Second premolar	4	13	<u>5</u>	<u>5</u>	15	25
First molar	3	14	<u>6</u>	<u>6</u>	16	26
Second molar	2	15	<u>7</u>	<u>7</u>	17	27
Third molar	1	16	<u>8</u>	<u>8</u>	18	28
Central incisor	25	24	<u>1</u>	<u>1</u>	41	31
Lateral incisor	26	23	<u>2</u>	<u>2</u>	42	32
Canine	27	22	<u>3</u>	<u>3</u>	43	33
First premolar	28	21	<u>4</u>	<u>3</u>	44	34
Second premolar	29	20	<u>5</u>	<u>5</u>	45	35
First molar	30	19	<u>6</u>	<u>6</u>	46	36
Second molar	31	18	<u>7</u>	<u>7</u>	47	37
Third molar	32	17	<u>8</u>	<u>8</u>	48	38

The permanent tooth in each quadrant is numbered from 1 (nearest to the arch midline) to 8 (farthest from the midline) as in the International System. To record a specific tooth, place the correct number of the tooth in that quadrant within the bracket shape that identifies the correct quadrant (Fig. 1-7). For example, the lower left central incisor would be  $\overline{1}$ , the lower left second premolar would be  $\overline{5}$ , and the upper right canine would be  $\overline{3}$ . For primary teeth, the same four brackets are used to denote the quadrants, but five letters of the alphabet, A through E, represent the primary teeth in each quadrant (with A being a central incisor, B a lateral incisor, C a canine, etc.) (Fig. 1-9). For example, the primary upper right first molar would be  $\overline{D}$ . Comparing the Universal System with the Palmer System, the permanent maxillary right second molar would be tooth 2 using the Universal System, but would be  $\overline{7}$  using the Palmer System. If you are confused, study Table 1-1 and the figures that illustrate the quadrant brackets.

Unless otherwise stated, the **Universal System of tooth numbering is used throughout this text**. To master the Universal System, it may be helpful to memorize the

number or letters for key teeth, possibly the central incisors (numbers 8, 9, 24, and 25) or the first molars (numbers 3, 14, 19, and 30).



**Figure 1-9.** When identifying each primary tooth using the **Palmer System**, each quadrant is denoted by bracket shapes as indicated, and each tooth within that quadrant is identified using letters A through E with letter A for the central incisors, letter B for lateral incisors, etc.