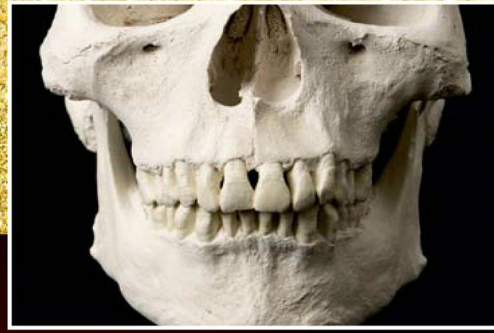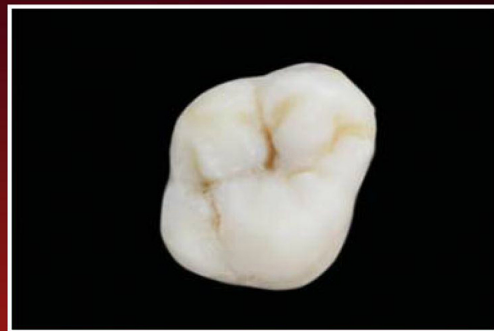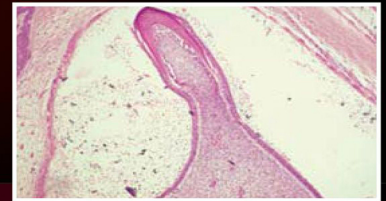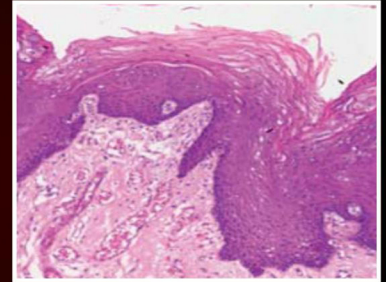


2ND EDITION



Textbook of
**ORAL ANATOMY,
HISTOLOGY,
PHYSIOLOGY and
TOOTH
MORPHOLOGY**



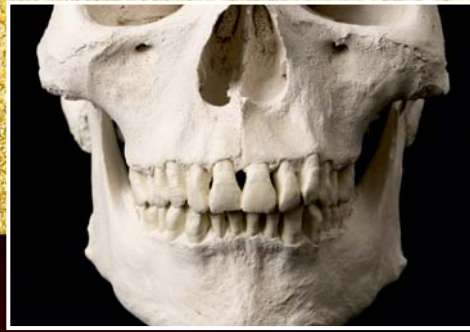K Rajkumar | R Ramya



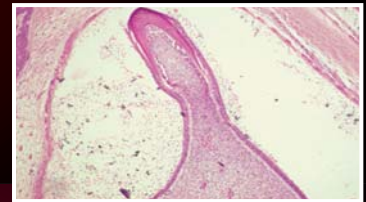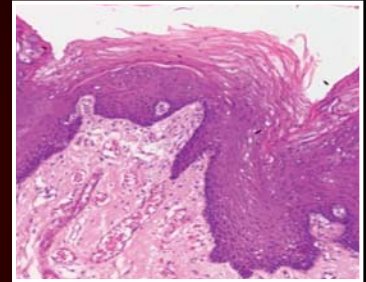
 Wolters Kluwer

Textbook of
Oral Anatomy,
Histology, Physiology
and Tooth Morphology

2ND EDITION



Textbook of
**ORAL ANATOMY,
HISTOLOGY,
PHYSIOLOGY and
TOOTH
MORPHOLOGY**

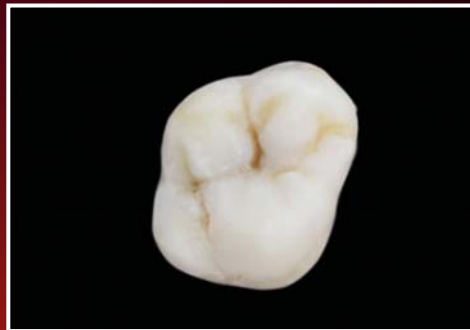

K. Rajkumar BSc, MDS, PhD

Vice-Principal, Professor and Head
Department of Oral and Maxillofacial
Pathology and Microbiology
SRM Dental College, Chennai

R. Ramya MDS

Professor
Department of Oral and Maxillofacial
Pathology and Microbiology
SRM Dental College, Chennai



Sr Publisher: Dr. Binny Mathur
Publishing Manager: P Sangeetha
Development Editor: Dr. Sahil Handa
Production Editor: Tamali Deb
Manager Manufacturing: Sumit Johry

Copyright © 2017 by Wolters Kluwer Health (India)

10th Floor, Tower C, Building No. 10, Phase – II, DLF Cyber City
Gurgaon, Haryana - 122002

All rights reserved. This product, consisting of the printed book and the accompanying DVD, is protected by copyright. No part of this book may be reproduced in any form or by any means, including photocopying, or utilized by any information storage and retrieval system without written permission from the copyright owner.

The publisher is not responsible (as a matter of product liability, negligence, or otherwise) for any injury resulting from any material contained herein. This publication contains information relating to dental anatomy and its clinical application that should not be construed as specific instructions for individual patients. Manufacturers' product information and package inserts should be reviewed for current information, including contraindications, dosages, and precautions. All products/brands/names/processes cited in this book are the properties of their respective owners. Reference herein to any specific commercial products, processes, or services by trade name, trademark, manufacturer, or otherwise is purely for academic purposes and does not constitute or imply endorsement, recommendation, or favoring by the publisher. The views and opinions of authors expressed herein do not necessarily state or reflect those of the publisher, and shall not be used for advertising or product endorsement purposes.

Care has been taken to confirm the accuracy of the information presented and to describe generally accepted practices. However, the authors, editors, and publishers are not responsible for errors or omissions or for any consequences from application of the information in this book and make no warranty, expressed or implied, with respect to the currency, completeness, or accuracy of the contents of the publication. Application of this information in a particular situation remains the professional responsibility of the practitioner. Readers are urged to confirm that the information, especially with regard to drug dose/usage, complies with current legislation and standards of practice. Please consult full prescribing information before issuing prescription for any product mentioned in the publication.

The publishers have made every effort to trace copyright holders for borrowed material. If they have inadvertently overlooked any, they will be pleased to make the necessary arrangements at the first opportunity.

First Edition, 2012
Second Edition, 2017

ISBN: 978-93-86691-16-3

Published by Wolters Kluwer (India) Pvt. Ltd., New Delhi
Compositor: SourceHOV

For product enquiry, please contact – Marketing Department (marketing@wolterskluwerindia.co.in) or log on to our website www.wolterskluwerindia.co.in.

Dedication

To my parents, my wife Dr. Shanthi, my children Divya and Karthik
K. Rajkumar

To the Creator, my parents, my loving daughter Pooja
R. Ramya

for their constant love, support and encouragement

and

To our students, who inspire us to be teachers

Foreword

A comprehensive book on Oral Anatomy and Oral Histology is the expectation of the first-year students of dentistry. In this book, the authors have, however, gone a step further and included Oral Physiology and Tooth Morphology, making it a handy single-volume book that suits the needs of the students. This book is simple to comprehend and at the same time exhaustive in its coverage. I consider the following features to be the highlights of the book:

- Subject is written and presented in a simple, lucid style, which makes it easy to understand and interesting to read.
- Appropriate schematic diagrams enhance grasping of knowledge.
- Tooth carving procedure presented in the book and demonstrated in the DVD is an additional feature that renders a practical approach to the subject and makes self-learning possible.
- Oral Histology slides with explanations provide for easy reference during practical sessions.

The authors have conceived this book with a broad vision so that it serves as a sound text for undergraduates in the first year and a useful supplement for the subsequent courses on preclinical and clinical conservative dentistry and prosthodontia. I am confident that undergraduate students will benefit immensely from this valuable textbook and even postgraduate exam aspirants would find it very useful.



Dr. T.R. Saraswathi

MDS, MSc (LONDON)

Professor

Department of Oral and Maxillofacial Pathology
Vishnu Dental College, Bhimavaram, Andhra Pradesh

Preface to the Second Edition

Knowledge of the basics of oral cavity and the craniofacial complex forms the basis of dental curriculum. This textbook serves as a single source reference of Oral Anatomy, Tooth Morphology, Oral Physiology and Oral Histology to cover the fundamental biology of the oromaxillofacial region. This textbook has been a bestseller from the time of its launch for its lucid contents which favours immersive reading.

The second edition has been updated with the latest advances and other features to aid easy learning and better retention. With the advent of compulsory competitive examinations for entry into post-graduate examinations, students need to keep themselves updated for effective performance. All possible proven learning tools have been added for easy learning. These features aim to cater to the needs of students with varied levels of learning skills.

In the light of the above, the salient features of the second edition are:

- *Five new chapters* to enrich the knowledge base and understanding of students
- *Applied aspects* to enhance the clinical understanding of the subject
- An *Overview* at the beginning of each chapter to sensitize students with the contents of the chapter
- *Mind Maps* at the end of each chapter, an amazing learning tool to aid easy, coherent and organized recall
- *Flash cards*, an online resource which includes essentials of the chapter in a tabular form for quick revision

Preparation of this edition has involved tremendous efforts to ensure that all recent advances have been updated. Above all, the constant urge to make learning easy to the student community has been addressed by addition of proven learning tools. However, understanding the limitations of human efforts, we would be grateful to receive comments and suggestions for further improvement.

K. Rajkumar

R. Ramya

Preface to the First Edition

The oral cavity and the craniofacial complex contain a unique combination of varied tissue types and functions. Understanding the structure and functions of dental, oral and relevant extraoral tissues in depth forms the basis of the dental curriculum. A thorough knowledge of the anatomy, histology and the role of normal tissues in the physiology of the oral anatomical structures will aid in a better understanding of the pathology of these tissues and organs. Therefore, in this book we have explained Oral Anatomy, Tooth Morphology, Oral Physiology and Oral Histology together in order to present a comprehensive account of the fundamentals of biology of the oromaxillofacial region.

A first-year undergraduate usually finds it difficult to understand the overlapping concepts of the above-mentioned four subjects from different books and sources. We have attempted to address this difficulty by comparing and correlating the various topics in one handy volume. We hope this approach enables the students to acquire a more stable foundation upon which they can subsequently build their clinical knowledge.

While this book presents a holistic approach to Oral Anatomy, Tooth Morphology, Oral Histology and Oral Physiology, it specially emphasises Histology since an understanding of this subject is crucial for undergraduates. In addition to this, the book provides the following features to help undergraduates acquire a better understanding of the subject.

Salient Features

- Though a first-year textbook, it incorporates a 'clinical overview' of the various topics in each chapter. This will help students in appreciating the clinical applications of the concerned topics.
- A visual representation of 'step-by-step tooth carving techniques' in the ancillary DVD and instructions in the Tooth Morphology chapters will assist the students in their practical sessions.
- Key points and multiple choice questions at the end of each chapter will help the students in quickly revising the subject and assessing their understanding.
- The appendix on summary of histologic slides with lucid images and appropriate identification points will assist the students in their preparation for practical examinations.
- To arouse more interest in the subject, additional reading has been added for some of the Oral Histology topics. This will be useful for students seeking more detailed knowledge.

It has been our sincere endeavour to present a textbook which will serve as a sound foundation for the subsequent study of oral pathology and medicine. We hope that faculties and students find this approach useful. We would appreciate their comments and suggestions for further improvement and would gratefully acknowledge the same.

K. Rajkumar
R. Ramya

Acknowledgements

The thought of second edition sounded simple and undemanding. Nonetheless, we understood that it was an arduous task from the time the new edition was proposed. A whirlwind of activities by a diligent team made this possible.

At this juncture, we bow to the benevolence of the divine for giving us this noble opportunity. With a feeling of utmost gratitude, we extend our warmest thanks to Chancellor Dr. T.R. Pachamuthu, SRM University; Chairman Dr. R. Shivakumar; and Dr. K. Ravi, Dean, SRM Dental College, for providing us with the positive academic environment to sustain this dream run. We extend our deepest thanks to Dr. T.R. Saraswathi who accepted to write the *Foreword* for the book.

We would like to express our heartfelt thanks to all the contributors who have helped to make this book complete. We sincerely thank Dr. K. Ravi, Dr. Krishnakumar Raja, Dr. H. Murali, Dr. Alex Varghese, Dr. Vidya, Dr. A. Ramesh Kumar, Dr. K.T. Mahesh, Dr. Rema Krishnan, Dr. K. Vanaja, Dr. P. Elavenil, Dr. Sangeetha Duraisamy, Dr. Eapen Cherian, Dr. Sudheerkanth, Dr. Dinesh Kumar, Dr. G. Nandhini, Dr. Vaishnavi Vedam, Dr. Sivasdas G, Dr. R. Janani, Dr. R. Bharanidharan, Dr. A.H. Harini Priya, Dr. Arulmozhi. N and Dr. Kaushik Muppala Ramakrishnan for their untiring efforts in giving their valuable contributions.

We are grateful to Dr. R. Muthusamy and Mr. P. Ravishankar, Department of General Anatomy, for helping us with photographs of the anatomical specimens for the Oral Anatomy section. We would like to thank Dr. Archana Jain and Dr. Nisha for helping us with the schematic diagrams, keying in the manuscript and proofreading. We thank Dr. Sabitha, Dr. Teena and Dr. Roopesh for having volunteered to contribute to the clinical photographs. Many thanks to Dr. K. Karunya, Dr. Ashwini Ajay, Dr. Shanaz. P. Ahmed, Dr. T.P. Mary Preethi Celsia for helping in natural teeth collection and segregation. We extend our thanks to Dr. Rini, Dr. Ramya and Dr. Sahana for helping us taking photography of natural teeth.

Our sincere thanks to Dr. Komal Nagendra Prasad, Dr. Merin Jacob, Dr. S. Kanmani Bharathi, Dr. Lakshmi C. Marar and Mr. P. Saravanan for their artistic contributions. We extend our sincere thanks to M/s Med Aid India, New Delhi, for having permitted us to use the photomicrographs for publication in this textbook.

We would like to sincerely appreciate the team at Wolters Kluwer India, Ms. P. Sangeetha, Publishing Manager, for the unstinted support to all our print aspirations, Mr. M. S. Mani, Managing Director; Dr. Binny Mathur, Senior Publisher; Dr. Sahil Handa, Development Editor; and Ms Tamali Deb, Asst. Manager-Production Editorial, for their guidance and suggestions.

K. Rajkumar
R. Ramya

Publisher's Acknowledgements

The publisher would like to thank the following reviewers for providing valuable suggestions:

Manpreet Arora, MDS

Professor

Department of Oral Pathology and Microbiology
and Forensic Odontology

SGT Dental College

Gurugram, Haryana

Nitul Jain, MDS

Associate Professor and Head

Department of Oral and maxillofacial Pathology
Eklavya Dental College and Hospital

Kotputli, Jaipur, Rajasthan

Contributors

K. Ravi MDS

Dean
Professor and Head
Department of Orthodontia and Dentofacial
Orthopedics
SRM Dental College
Chennai

K. Rajkumar BSC, MDS, PHD

Vice-Principal, Professor and Head
Department of Oral and Maxillofacial Pathology
and Microbiology
SRM Dental College
Chennai

Krishnakumar Raja MDS

Professor and Head
Department of Oral and Maxillofacial Surgery
SRM Dental College
Chennai

H. Murali MDS

Professor and Head
Department of Conservative Dentistry
and Endodontics
D.A. Pandu Memorial R.V. Dental College
Bangalore

Alex Varghese MDS

Former Professor and Head
Department of Oral and Maxillofacial Pathology
and Microbiology
Adhiparashakthi Dental College
Melmaruvathur

M. Vidya MDS

Former Professor
Department of Oral and Maxillofacial Pathology
and Microbiology
A B Shetty Memorial Institute of Dental Sciences
Mangalore

K.T. Mahesh MDS

Vice-Principal, Professor and Head
Department of Oral and Maxillofacial Pathology
and Microbiology
SRM Kattankulathur Dental College
Kattankulathur

A. Ramesh Kumar MDS

Professor
Department of Oral and Maxillofacial Pathology
and Microbiology
SRM Dental College
Chennai

Vanaja Krishna Naik MDS, MFDS RCPS (Glasg)

Professor
University of Leeds
United Kingdom

P. Elavenil MDS

Associate Professor
Department of Oral and Maxillofacial Surgery
SRM Dental College
Chennai

Sangeetha Duraisamy MDS

Associate Professor
Department of Orthodontia and Dentofacial
Orthopedics
SRM Dental College
Chennai

Rema Krishnan BDS

Reader
Department of Oral and Maxillofacial Pathology
and Microbiology
SRM Dental College
Chennai

Eapen Cherian MDS

Professor
Department of Oral and Maxillofacial Pathology
and Microbiology
St. Gregorious Dental College
Kothamangalam

R. Ramya MDS

Professor
Department of Oral and Maxillofacial Pathology
and Microbiology
SRM Dental College
Chennai

K. Sudheerkanth MDS

Professor and Head
Department of Oral and Maxillofacial Pathology
and Microbiology
GSL Dental College, Rajahmundry
Andhra Pradesh

G. Nandhini MDS

Reader
Department of Oral and Maxillofacial Pathology
and Microbiology
SRM Dental College
Chennai

T. Dinesh Kumar MDS

Reader
Department of Oral and Maxillofacial Pathology
and Microbiology
SRM Dental College
Chennai

Vaishnavi Vedam MDS (Oral & Maxillofacial
Pathology)

Lecturer
Department of Oral Pathology
Faculty of Dentistry
Asian Institute of Medicine, Science and Technology
(AIMST) University
Malaysia

Sivadas G MDS (Pedodontics & Preventive Dentistry)

Lecturer
Department of Pedodontics & Preventive Dentistry
Faculty of Dentistry
Asian Institute of Medicine, Science and Technology
(AIMST) University
Malaysia

R. Janani

Senior Lecturer
Department of Oral Pathology
SRM Dental College
Chennai

R. Bharanidharan

Senior Lecturer
Department of Oral Pathology
SRM Dental College
Chennai

A.H. Harini Priya

Post-graduate Student
Department of Oral Pathology
SRM Dental College
Chennai

Arulmozhi N.

Post-graduate Student
Department of Oral Pathology
SRM Dental College
Chennai

Kaushik Muppala Ramakrishnan

Intern
SRM Dental College
Chennai

Table of Contents at a Glance

| | |
|--------------------------------------|-------------|
| <i>Foreword</i> | <i>vii</i> |
| <i>Preface to the Second Edition</i> | <i>ix</i> |
| <i>Preface to the First Edition</i> | <i>xi</i> |
| <i>Acknowledgements</i> | <i>xiii</i> |
| <i>Contributors</i> | <i>xv</i> |

SECTION I ORAL ANATOMY 1

| | | |
|-----------|----------------------------------|-----|
| Chapter 1 | Introduction to Oral Anatomy | 3 |
| Chapter 2 | Osteology of Skull | 21 |
| Chapter 3 | Musculature of the Head and Neck | 43 |
| Chapter 4 | Nerves of the Head and Neck | 62 |
| Chapter 5 | Vasculature of the Head and Neck | 114 |
| Chapter 6 | Lymphatics of the Head and Neck | 135 |
| Chapter 7 | Anatomy of Salivary Glands | 148 |

SECTION II TOOTH MORPHOLOGY 169

| | | |
|------------|---|-----|
| Chapter 8 | Evolution of Teeth and Comparative Dental Anatomy | 171 |
| Chapter 9 | Terminologies in Tooth Morphology | 182 |
| Chapter 10 | Nomenclature of Human Teeth | 203 |
| Chapter 11 | Chronology of Dentition | 216 |
| Chapter 12 | Differences Between Deciduous and Permanent Teeth | 222 |
| Chapter 13 | Deciduous Dentition | 232 |
| Chapter 14 | Permanent Maxillary and Mandibular Incisors | 305 |
| Chapter 15 | Permanent Maxillary and Mandibular Canines | 327 |
| Chapter 16 | Permanent Maxillary and Mandibular Premolars | 340 |
| Chapter 17 | Permanent Maxillary and Mandibular Molars | 371 |
| Chapter 18 | Morphology of Pulp Chambers and Canals | 409 |
| Chapter 19 | Alignment and Occlusion | 421 |
| Chapter 20 | Functional Occlusion and Malocclusion | 444 |
| Chapter 21 | Guidelines for Drawing Tooth Morphology Diagrams | 460 |

| | | |
|---|--|------------|
| SECTION III ORAL PHYSIOLOGY | | 465 |
| Chapter 22 | Somatosensory System | 467 |
| Chapter 23 | Pain | 480 |
| Chapter 24 | Taste | 485 |
| Chapter 25 | Smell | 490 |
| Chapter 26 | Mastication | 497 |
| Chapter 27 | Deglutition | 504 |
| Chapter 28 | Speech | 511 |
| Chapter 29 | Calcium and Phosphorus Metabolism | 519 |
| Chapter 30 | Theories of Mineralization | 526 |
| SECTION IV ORAL HISTOLOGY | | 531 |
| Chapter 31 | Introduction to Histology | 533 |
| Chapter 32 | General Embryology | 560 |
| Chapter 33 | Embryology of the Head, Face and Oral Cavity | 582 |
| Chapter 34 | Development of Teeth | 600 |
| Chapter 35 | Enamel | 621 |
| Chapter 36 | Dentin | 644 |
| Chapter 37 | Pulp | 663 |
| Chapter 38 | Periodontal Ligament | 678 |
| Chapter 39 | Cementum | 693 |
| Chapter 40 | Bone | 704 |
| Chapter 41 | Oral Mucous Membrane | 715 |
| Chapter 42 | Histology of Salivary Glands | 740 |
| Chapter 43 | Eruption | 755 |
| Chapter 44 | Shedding | 763 |
| Chapter 45 | Temporomandibular Joint | 769 |
| Chapter 46 | Maxillary Sinus | 779 |
| Chapter 47 | Tissue Processing for Microscopic Study | 786 |
| Chapter 48 | Histochemistry of Oral Tissues | 795 |
| <i>Appendix: Microscopic Slides for Practical Examination</i> | | 804 |
| <i>Answers to Multiple Choice Questions</i> | | 815 |
| <i>Glossary</i> | | 817 |
| <i>Index</i> | | 821 |

Detailed Table of Contents

| | | | |
|---|-------------|--|-----------|
| <i>Foreword</i> | <i>vii</i> | Parietal Bone | 30 |
| <i>Preface to the Second Edition</i> | <i>ix</i> | Temporal Bone | 30 |
| <i>Preface to the First Edition</i> | <i>xi</i> | Occipital Bone | 30 |
| <i>Acknowledgements</i> | <i>xiii</i> | Sphenoid Bone | 31 |
| <i>Contributors</i> | <i>xv</i> | Ethmoid Bone | 31 |
| | | Facial Bones | 32 |
| | | Facial Buttresses | 37 |
| | | Articulation | 37 |
| | | Blood Supply and Innervation of Bone | 38 |
| | | <i>Key Points</i> | 39 |
| | | <i>Mind Map</i> | 40 |
| | | <i>Bibliography</i> | 41 |
| | | <i>Multiple Choice Questions</i> | 41 |
| SECTION I ORAL ANATOMY | 1 | | |
| 1. Introduction to Oral Anatomy | 3 | 3. Musculature of the Head and Neck | 43 |
| <i>Krishnakumar Raja • P. Elavenil</i> | | <i>P. Elavenil</i> | |
| Definition of Oral Anatomy | 3 | Introduction | 43 |
| Introduction to Oral Anatomy | 3 | Classification of Muscles | 43 |
| Significance of Oral Anatomy | 3 | Blood and Nerve Supply to Skeletal Muscle | 44 |
| Organization of the Oral Cavity | 5 | Muscles of the Head Region | 44 |
| Boundaries of the Oral Cavity | 5 | Muscles of Facial Expression | 44 |
| Divisions of the Oral Cavity | 5 | Muscles of Mastication | 47 |
| Basic Terminology | 6 | Muscles of the Soft Palate | 51 |
| Components of the Oral Cavity | 8 | Muscles of the Tongue | 53 |
| Hard Tissues | 8 | Muscles of the Eye | 55 |
| Soft Tissues | 11 | Muscles of the Floor of the Mouth | 57 |
| Subdivisions of Anatomy | 12 | <i>Key Points</i> | 58 |
| Macroscopic Anatomy | 12 | <i>Mind Map</i> | 58 |
| Microscopic Anatomy | 12 | <i>Bibliography</i> | 60 |
| Approaches to Studying Anatomy | 13 | <i>Multiple Choice Questions</i> | 60 |
| Implications of Oral Anatomy in Dentistry | 14 | 4. Nerves of the Head and Neck | 62 |
| <i>Key Points</i> | 15 | <i>P. Elavenil</i> | |
| <i>Mind Map</i> | 15 | Introduction | 62 |
| <i>Bibliography</i> | 19 | Importance of Neuroanatomy in Dentistry | 62 |
| <i>Multiple Choice Questions</i> | 20 | Components of the Nervous System | 62 |
| 2. Osteology of Skull | 21 | | |
| <i>P. Elavenil</i> | | | |
| Introduction | 21 | | |
| Classification of Bones | 21 | | |
| Components of the Skeletal System | 25 | | |
| Cranial Bones | 29 | | |
| Frontal Bone | 30 | | |

| | | | |
|--|------------|---|------------|
| Microanatomy of Neurons | 62 | Pterygoid Plexus | 129 |
| Nerves | 63 | Lingual Vein | 129 |
| Autonomic Nervous System | 69 | External Jugular Vein | 130 |
| Sympathetic Nerves of the Head | 71 | Ophthalmic Veins | 130 |
| Parasympathetic Nerves of the Head | 73 | <i>Key Points</i> | 131 |
| Spinal Nerves | 75 | <i>Mind Map</i> | 132 |
| Formation | 76 | <i>Bibliography</i> | 133 |
| Branches of Spinal Nerves | 77 | <i>Multiple Choice Questions</i> | 133 |
| Cervical Spinal Nerves (C1–C4) | 77 | 6. Lymphatics of the Head and Neck | 135 |
| Cranial Nerves | 78 | <i>Krishnakumar Raja • P. Elavenil</i> | |
| Origin of Cranial Nerves | 78 | Introduction | 135 |
| Olfactory Nerve (CN I) | 80 | Structural Components of the Lymphatic System | 135 |
| Optic Nerve (CN II) | 80 | Significance of the Lymphatic System | 137 |
| Oculomotor Nerve (CN III) | 83 | Anatomy of Lymph Nodes | 137 |
| Trochlear Nerve (CN IV) | 83 | Gross Anatomy | 137 |
| Trigeminal Nerve (CN V) | 83 | Microscopic Anatomy | 137 |
| Abducent Nerve (CN VI) | 92 | Classification of Lymph Nodes | 138 |
| Facial Nerve (CN VII) | 92 | Lymphatic Drainage of the Head and Neck | 139 |
| Auditory/Vestibulocochlear Nerve (CN VIII) | 96 | Submandibular Lymph Nodes | 140 |
| Glossopharyngeal Nerve (CN IX) | 96 | Submental Nodes | 140 |
| Vagus Nerve (CN X) | 98 | Jugulodigastric Nodes | 140 |
| Spinal Accessory Nerve (CN XI) | 100 | Jugulo-Omohyoid Nodes | 140 |
| Hypoglossal Nerve (CN XII) | 103 | Facial Nodes/Nodes of Stahr | 140 |
| Regional Nerve Supply | 105 | Mastoid Nodes | 141 |
| Sensory Innervation of the Face | 105 | Occipital Nodes | 141 |
| <i>Key Points</i> | 108 | Superficial and Deep Parotid Nodes | 142 |
| <i>Mind Map</i> | 110 | Superficial Cervical Nodes | 142 |
| <i>Bibliography</i> | 111 | Retropharyngeal Nodes | 142 |
| <i>Multiple Choice Questions</i> | 112 | Waldeyer's Ring | 143 |
| 5. Vasculature of the Head and Neck | 114 | Clinical Considerations | 144 |
| <i>Krishnakumar Raja • P. Elavenil</i> | | <i>Key Points</i> | 144 |
| Introduction | 114 | <i>Mind Map</i> | 145 |
| Components of the Vascular System: | | <i>Bibliography</i> | 146 |
| The Vascular Tree | 115 | <i>Multiple Choice Questions</i> | 146 |
| Importance of Vasculature | 115 | 7. Anatomy of Salivary Glands | 148 |
| Differences Between Artery and Vein | 116 | <i>Krishnakumar Raja • P. Elavenil</i> | |
| Arterial Supply of the Face | 117 | Introduction | 148 |
| External Carotid Artery | 117 | General Characteristics of Salivary Glands | 149 |
| Internal Carotid Artery | 119 | Classification of Salivary Glands | 149 |
| Venous Drainage of the Face | 127 | Embryology | 150 |
| Features of Facial Veins | 127 | Gross Anatomy of the Salivary Glands | 151 |
| Internal Jugular Vein | 127 | Major Salivary Glands | 151 |
| Facial Vein | 128 | Minor Salivary Glands | 162 |
| Retromandibular Vein | 129 | | |
| Maxillary Vein | 129 | | |

| | | | |
|---|------------|---|------------|
| Radiographic Anatomy | 162 | Parts of a Tooth | 182 |
| Age-Related Changes | 163 | Crown | 182 |
| Clinical Considerations | 163 | Root | 182 |
| <i>Key Points</i> | 165 | Cervical Line | 183 |
| <i>Mind Map</i> | 166 | Structure of the Tooth | 183 |
| <i>Bibliography</i> | 167 | Enamel | 183 |
| <i>Multiple Choice Questions</i> | 167 | Dentin | 184 |
| | | Cementum | 184 |
| | | Pulp | 184 |
| | | Supporting Structures of the Tooth | 184 |
| | | Alveolar Bone | 184 |
| | | Periodontal Ligament | 184 |
| | | Gingiva | 184 |
| | | Surfaces of the Teeth | 185 |
| | | Facial Surface | 185 |
| | | Palatal Surface | 185 |
| | | Lingual Surface | 185 |
| | | Proximal Surface | 185 |
| | | Masticatory Surface | 186 |
| | | Division of the Surfaces of the Teeth | 186 |
| | | Division of the Crown Into Thirds | 187 |
| | | Division of the Root Into Thirds | 187 |
| | | Line Angles | 188 |
| | | Point Angles | 188 |
| | | Anatomical Landmarks on the Tooth Surface | 189 |
| | | Anatomical Landmarks on the Crown Surface | 190 |
| | | Anatomical Landmarks on the Root Surface | 199 |
| | | <i>Key Points</i> | 199 |
| | | <i>Mind Map</i> | 200 |
| | | <i>Bibliography</i> | 201 |
| | | <i>Multiple Choice Questions</i> | 201 |
| | | 10. Nomenclature of Human Teeth | 203 |
| | | <i>G. Nandhini</i> | |
| | | Introduction | 203 |
| | | Classes of Human Teeth | 203 |
| | | Types of Human Dentition and Dental Formulae | 203 |
| | | Primary Dentition | 203 |
| | | Permanent Dentition | 204 |
| | | Tooth Identification Systems/Tooth Numbering Systems | 205 |
| | | Universal System | 206 |
| SECTION II TOOTH MORPHOLOGY 169 | | | |
| 8. Evolution of Teeth and Comparative Dental Anatomy | 171 | | |
| <i>K. Rajkumar • R. Ramya</i> | | | |
| Introduction | 171 | | |
| Evolution of Teeth | 171 | | |
| Phylogenetic Classification of Dentition and Cusp Forms | 172 | | |
| Origin and Evolution of Molars in Mammals | 173 | | |
| Structure of Cusps in the Posterior Teeth | 173 | | |
| Tribophenic Type | 174 | | |
| Quadrate Type | 174 | | |
| Secodont Type | 174 | | |
| Bunodont Type | 174 | | |
| Brachydont Type | 174 | | |
| Hypsodont Type | 174 | | |
| Selenodont Type | 175 | | |
| Lophodont Type | 175 | | |
| Dental Formula | 176 | | |
| Man (Adult) | 176 | | |
| Dog | 176 | | |
| Cat | 176 | | |
| Horse | 176 | | |
| Cattle | 176 | | |
| Sheep | 176 | | |
| Pig | 177 | | |
| <i>Additional Reading</i> | 177 | | |
| <i>Key Points</i> | 177 | | |
| <i>Mind Map</i> | 178 | | |
| <i>Bibliography</i> | 181 | | |
| <i>Multiple Choice Questions</i> | 181 | | |
| 9. Terminologies in Tooth Morphology | 182 | | |
| <i>G. Nandhini</i> | | | |
| Introduction | 182 | | |

| | | | |
|--|------------|--|------------|
| Zsigmondy/Palmer System | 207 | Deciduous Canines | 249 |
| FDI System | 209 | Deciduous Maxillary Canine | 250 |
| <i>Key Points</i> | 212 | Deciduous Mandibular Canine | 254 |
| <i>Mind Map</i> | 212 | Deciduous Maxillary Molars | 259 |
| <i>Bibliography</i> | 214 | Deciduous Maxillary First Molar | 260 |
| <i>Multiple Choice Questions</i> | 214 | Deciduous Maxillary Second Molar | 268 |
| 11. Chronology of Dentition | 216 | Deciduous Mandibular Molars | 275 |
| <i>G. Nandhini</i> | | Deciduous Mandibular First Molar | 275 |
| Introduction | 216 | Deciduous Mandibular Second Molar | 281 |
| Chronology of Primary Teeth | 216 | Clinical Considerations | 288 |
| Sequence of Eruption | 217 | <i>Key Points</i> | 288 |
| Chronology of Permanent Teeth | 218 | <i>Mind Maps</i> | 289 |
| Sequence of Eruption | 218 | <i>Bibliography</i> | 303 |
| Clinical Considerations | 219 | <i>Multiple Choice Questions</i> | 303 |
| <i>Key Points</i> | 219 | 14. Permanent Maxillary and Mandibular Incisors | 305 |
| <i>Mind Map</i> | 220 | <i>R. Ramya • K. Sudheerkanth</i> | |
| <i>Bibliography</i> | 221 | Introduction | 305 |
| <i>Multiple Choice Questions</i> | 221 | Maxillary Central Incisors | 305 |
| 12. Differences Between Deciduous and Permanent Teeth | 222 | Labial Aspect | 306 |
| <i>G. Nandhini</i> | | Lingual Aspect | 307 |
| Introduction | 222 | Mesial Aspect | 307 |
| General Features | 222 | Distal Aspect | 308 |
| Morphological Differences | 223 | Incisal Aspect | 308 |
| Differences in Crown Morphology | 223 | Maxillary Lateral Incisors | 309 |
| Differences in Root Morphology | 226 | Labial Aspect | 309 |
| Differences in Pulp Morphology | 227 | Lingual Aspect | 310 |
| Histologic Differences | 228 | Mesial Aspect | 310 |
| <i>Key Points</i> | 229 | Distal Aspect | 311 |
| <i>Mind Map</i> | 230 | Incisal Aspect | 311 |
| <i>Bibliography</i> | 231 | Mandibular Central Incisors | 312 |
| <i>Multiple Choice Questions</i> | 231 | Labial Aspect | 312 |
| 13. Deciduous Dentition | 232 | Lingual Aspect | 313 |
| <i>G. Nandhini</i> | | Mesial Aspect | 313 |
| Introduction | 232 | Distal Aspect | 314 |
| Importance of Deciduous Dentition | 232 | Incisal Aspect | 314 |
| Life Cycle of Deciduous Dentition | 233 | Mandibular Lateral Incisors | 315 |
| Deciduous Incisors | 233 | Labial Aspect | 315 |
| Deciduous Maxillary Central Incisor | 233 | Lingual Aspect | 316 |
| Deciduous Maxillary Lateral Incisor | 237 | Mesial Aspect | 316 |
| Deciduous Mandibular Central Incisor | 241 | Distal Aspect | 316 |
| Deciduous Mandibular Lateral Incisor | 245 | Incisal Aspect | 317 |
| | | Steps for Carving a Maxillary Central Incisor | 318 |

| | | | |
|---|------------|--|------------|
| Steps for Carving a Maxillary Lateral Incisor | 319 | Buccal Aspect | 345 |
| <i>Key Points</i> | 320 | Lingual Aspect | 346 |
| <i>Mind Maps</i> | 321 | Mesial Aspect | 346 |
| <i>Bibliography</i> | 325 | Distal Aspect | 346 |
| <i>Multiple Choice Questions</i> | 325 | Occlusal Aspect | 347 |
| 15. Permanent Maxillary and Mandibular Canines | 327 | Clinical Considerations: Maxillary Premolars | 348 |
| <i>R. Ramya</i> | | Mandibular First Premolar | 348 |
| Introduction | 327 | Buccal Aspect | 348 |
| Maxillary Canine | 327 | Lingual Aspect | 349 |
| Labial Aspect | 327 | Mesial Aspect | 350 |
| Lingual Aspect | 329 | Distal Aspect | 350 |
| Mesial Aspect | 329 | Occlusal Aspect | 351 |
| Distal Aspect | 330 | Variation | 352 |
| Incisal Aspect | 330 | Mandibular Second Premolar | 352 |
| Variations | 330 | Buccal Aspect | 352 |
| Clinical Considerations: Maxillary Canines | 331 | Lingual Aspect | 353 |
| Mandibular Canine | 331 | Mesial Aspect | 353 |
| Labial Aspect | 331 | Distal Aspect | 354 |
| Lingual Aspect | 332 | Occlusal Aspect | 354 |
| Mesial Aspect | 333 | Variation | 355 |
| Distal Aspect | 333 | Clinical Considerations: Mandibular Premolars | 355 |
| Incisal Aspect | 333 | Steps for Carving a Maxillary First Premolar | 356 |
| Variation | 334 | Steps for Carving a Mandibular First Premolar | 357 |
| Clinical Considerations: Mandibular Canines | 334 | Steps for Carving a Mandibular Second Premolar | 358 |
| Steps for Carving A Maxillary Canine | 334 | <i>Key Points</i> | 359 |
| <i>Key Points</i> | 335 | <i>Mind Maps</i> | 361 |
| <i>Mind Maps</i> | 336 | <i>Bibliography</i> | 369 |
| <i>Bibliography</i> | 338 | <i>Multiple Choice Questions</i> | 369 |
| <i>Multiple Choice Questions</i> | 338 | 17. Permanent Maxillary and Mandibular Molars | 371 |
| 16. Permanent Maxillary and Mandibular Premolars | 340 | <i>R. Ramya</i> | |
| <i>R. Ramya</i> | | Introduction | 371 |
| Introduction | 340 | Maxillary First Molar | 371 |
| Maxillary First Premolar | 340 | Buccal Aspect | 371 |
| Buccal Aspect | 341 | Lingual/Palatal Aspect | 372 |
| Lingual/Palatal Aspect | 342 | Mesial Aspect | 373 |
| Mesial Aspect | 342 | Distal Aspect | 374 |
| Distal Aspect | 343 | Occlusal Aspect | 374 |
| Occlusal Aspect | 343 | Maxillary Second Molar | 376 |
| Variations | 344 | Buccal Aspect | 376 |
| Maxillary Second Premolar | 345 | Lingual Aspect | 377 |
| | | Mesial Aspect | 378 |

| | | | |
|--|------------|--|------------|
| Distal Aspect | 378 | Intracoronal and Intraradicular | |
| Occlusal Aspect | 379 | Anatomy | 410 |
| Maxillary Third Molar | 380 | Anatomical Variations | 418 |
| Buccal Aspect | 380 | <i>Key Points</i> | 418 |
| Lingual Aspect | 380 | <i>Mind Map</i> | 419 |
| Mesial Aspect | 381 | <i>Bibliography</i> | 419 |
| Distal Aspect | 381 | <i>Multiple Choice Questions</i> | 420 |
| Occlusal Aspect | 381 | | |
| Variations in Maxillary Molars | 381 | 19. Alignment and Occlusion | 421 |
| Mandibular First Molar | 382 | <i>K. Ravi • Sangeetha Duraisamy</i> | |
| Buccal Aspect | 382 | Introduction | 421 |
| Lingual Aspect | 384 | Development of Occlusion | 421 |
| Mesial Aspect | 385 | Gum Pad Stage | 421 |
| Distal Aspect | 385 | Precociously Erupted Primary Teeth | 422 |
| Occlusal Aspect | 386 | Deciduous Dentition Stage | 422 |
| Mandibular Second Molar | 388 | Mixed Dentition Stage or | |
| Buccal Aspect | 388 | Transitional Stage | 424 |
| Lingual Aspect | 389 | Permanent Dentition | 425 |
| Mesial Aspect | 389 | Relationship of the Maxillary and | |
| Distal Aspect | 390 | Mandibular Teeth | 429 |
| Occlusal Aspect | 391 | Centric Occlusion Coinciding | |
| Mandibular Third Molar | 392 | with the Centric Jaw Relation | 430 |
| Buccal Aspect | 392 | Occlusion | 430 |
| Lingual Aspect | 393 | Occlusal Relationship of the | |
| Mesial Aspect | 394 | Upper and Lower Teeth | 432 |
| Distal Aspect | 394 | Occlusal Contacts of the Posterior Teeth | 434 |
| Occlusal Aspect | 395 | Occlusal Contacts During Centric and | |
| Variations in Mandibular Molars | 395 | Eccentric Positions of the Mandible | 436 |
| Clinical Considerations: Mandibular Molars | 395 | Centric Occlusion Contacts | 436 |
| Steps for Carving A Maxillary First Molar | 397 | Centric Relation Contacts | 436 |
| Steps for Carving A Mandibular First Molar | 398 | Working Contacts | 436 |
| <i>Key Points</i> | 399 | Non-Working Contacts | 437 |
| <i>Mind Maps</i> | 400 | Protrusive Contacts | 438 |
| <i>Bibliography</i> | 406 | Determinants of Occlusal Morphology | 438 |
| <i>Multiple Choice Questions</i> | 406 | Occlusal Stability: Factors That | |
| | | Determine Tooth Position | 438 |
| 18. Morphology of Pulp Chambers | | <i>Key Points</i> | 440 |
| and Canals | 409 | <i>Mind Map</i> | 441 |
| <i>H. Murali</i> | | <i>Bibliography</i> | 442 |
| Introduction | 409 | <i>Multiple Choice Questions</i> | 442 |
| Morphology of Pulp Chambers and | | 20. Functional Occlusion | |
| Canals in Deciduous Teeth | 409 | and Malocclusion | 444 |
| Deciduous Incisors and Canines | 409 | <i>Sivadas G.</i> | |
| Deciduous Molars | 410 | Introduction | 444 |
| Morphology of Pulp Chambers and | | Occlusion | 444 |
| Canals in Permanent Teeth | 410 | Concept of Occlusion | 444 |