

Shingo Fujii  
Kentaro Sekiyama

# Precise Neurovascular Anatomy for Radical Hysterectomy

 Springer

EXTRAS ONLINE

---

# Precise Neurovascular Anatomy for Radical Hysterectomy

---

Shingo Fujii • Kentaro Sekiyama

# Precise Neurovascular Anatomy for Radical Hysterectomy

 Springer

Shingo Fujii  
Department of Gynecology and Obstetrics  
Kyoto University  
Kyoto  
Japan

Kentaro Sekiyama  
Department of Obstetrics and Gynecology  
Kitano Hospital  
Kita-ku  
Osaka  
Japan

ISBN 978-981-13-8097-6      ISBN 978-981-13-8098-3 (eBook)  
<https://doi.org/10.1007/978-981-13-8098-3>

© Springer Nature Singapore Pte Ltd. 2020

This work is subject to copyright. All rights are reserved by the Publisher, whether the whole or part of the material is concerned, specifically the rights of translation, reprinting, reuse of illustrations, recitation, broadcasting, reproduction on microfilms or in any other physical way, and transmission or information storage and retrieval, electronic adaptation, computer software, or by similar or dissimilar methodology now known or hereafter developed.

The use of general descriptive names, registered names, trademarks, service marks, etc. in this publication does not imply, even in the absence of a specific statement, that such names are exempt from the relevant protective laws and regulations and therefore free for general use.

The publisher, the authors, and the editors are safe to assume that the advice and information in this book are believed to be true and accurate at the date of publication. Neither the publisher nor the authors or the editors give a warranty, expressed or implied, with respect to the material contained herein or for any errors or omissions that may have been made. The publisher remains neutral with regard to jurisdictional claims in published maps and institutional affiliations.

This Springer imprint is published by the registered company Springer Nature Singapore Pte Ltd.  
The registered company address is: 152 Beach Road, #21-01/04 Gateway East, Singapore 189721, Singapore

---

## Preface

Since Ernst Wertheim reported the first systematic data on radical hysterectomy in 1911, radical hysterectomy has been considered the most interesting and challenging operation in gynecologic surgery. Naturally, many surgeons have endeavored to improve on Wertheim's radical hysterectomy. Among them, the most pioneering modifications might be by Latzko in 1919 and by Okabayashi in 1921. Okabayashi's radical hysterectomy became popular by 1930 and has been performed as a standard technique for the treatment of Stage Ib and IIb cervical cancer patients in Japan. In contrast, radical hysterectomy was not popular in Western countries until 1954, when Meigs established radical hysterectomy as a safe and effective treatment modality for the cervical cancer patient with early invasive lesion.

In order to accomplish a safe radical hysterectomy, knowledge of the precise anatomical female pelvis is essential. Many advances in our understanding of anatomy have been necessary for further development of techniques in radical hysterectomy. Until recently, the exact anatomy of the bilateral cardinal and the vesicouterine ligaments in the retroperitoneal space at the level of the uterine cervix and upper vagina was a black box for many years. Moreover, quality of life after radical hysterectomy, particularly the bladder function, has been pursued by many doctors under the name of nerve-sparing radical hysterectomy, and the precise neurovascular anatomical knowledge of the pelvic cavity has been elucidated.

This book is focused on the detailed neurovascular anatomy during the open-abdominal radical hysterectomy. Color illustrations are used as much as possible to depict each surgical step during a radical hysterectomy. For the introduction of radical hysterectomy, illustrated figures from the early twentieth century describe each original surgical step of Okabayashi's radical hysterectomy. This is followed by a step-by-step guide to radical hysterectomy without nerve-sparing, illustrating the precise neurovascular anatomy of the retroperitoneal space of the uterine cervix and upper vagina (the cardinal ligament and the vesicouterine ligament). The last chapter of the book is focused on nerve-sparing radical hysterectomy, illustrating the detailed anatomical relationship between the vascular system of the vesicouterine ligament and the nerve plane of the inferior hypogastric plexus formed by the hypogastric nerve, the pelvic splanchnic nerve, the uterine branch, and the bladder branch. Five video disks are provided, with these titles: (1) Radical Hysterectomy, performed by Okabayashi himself; (2) Nerve-Sparing Radical Hysterectomy, by Shingo Fujii; (3) Mibayashi's Original Super-radical Hysterectomy; (4)–(5) Live Surgical Videos of Step-by-Step Nerve-Sparing Radical Hysterectomy, by Shingo Fujii.

With the benefit of magnified views during laparoscopic surgery, surgeons have a greater appreciation of the clear anatomy of the blood vessels in the connective tissues in the female pelvis. Laparoscopy is now well established in the surgical management of gynecological malignancies, with laparoscopic and robotic approaches becoming commonplace in radical hysterectomy. A sound understanding of the neurovascular anatomy is a necessity for emerging gynecological oncology surgeons for open-abdominal and laparoscopic radical hysterectomy.

We hope the book will be a helpful and valuable addition for surgeons who would like to brush up their surgical skills to perform a safe and comprehensive radical hysterectomy.

Kyoto, Japan  
Osaka, Japan

Shingo Fujii  
Kentaro Sekiyama

---

## Acknowledgments

I would like to acknowledge Kenji Takakura, M.D., Noriomi Matsumura, M.D., Toshihiro Higuchi, M.D., Sigeo Yura, M.D., Masaki Mandai, M.D., Tsukasa Baba, M.D., Shinya Yoshioka, M.D., Kentaro Sekiyama, and colleagues of the Department of Gynecology and Obstetrics at Kyoto University for their sincere support during the clarification of the precise anatomy of the vesicouterine ligament and the inferior hypogastric plexus.

Kentaro Sekiyama and I would like to express our gratitude to Dr. Ranjit Manchanda, Clinical Senior Lecturer and Consultant Gynecological Oncologist, Barts Cancer Institute, Queen Mary University of London, and his associate Dr. Dhivya Chandrasekaran for editing this textbook.

Shingo Fujii

---

# Contents

<b>1</b>	<b>Brief History of Surgical Treatment for Cervical Cancer</b> .....	1
1.1	Cervical Amputation and Simple Total Hysterectomy .....	1
1.2	Extended Hysterectomy with Lymph Node Resection as a Radical Approach for Cervical Cancer Patients .....	2
1.3	Modification of Wertheim's Radical Hysterectomy with Pelvic Lymphadenectomy .....	3
1.4	Situation of Radical Hysterectomy in Mid-Twentieth Century .....	4
1.5	Recent Novel Findings and Methods on Radical Hysterectomy .....	5
1.6	Super-Radical Hysterectomy .....	6
1.7	Notes .....	8
1.7.1	Surgical Novel Concepts and Anatomical Findings on Radical Hysterectomy .....	8
1.7.2	History of Radical Hysterectomy in Western Countries and in Japan .....	9
	References .....	10
<b>2</b>	<b>Classification of Radical Hysterectomy</b> .....	11
2.1	Piver–Rutledge–Smith's Classification (1974) .....	11
2.2	Querler & Morrow's Classification (2008) .....	12
2.3	Classification of Radical Hysterectomy and Corresponding Surgical Treatment Modalities .....	13
	References .....	14
<b>3</b>	<b>Concept of the Original Okabayashi's Radical Hysterectomy</b> .....	15
3.1	Principles of Okabayashi's Radical Hysterectomy .....	15
<b>4</b>	<b>Atlas of the Original Okabayashi's Transabdominal Radical Hysterectomy</b> .....	19
4.1	Surgical Steps of Original Okabayashi's Radical Hysterectomy .....	19
4.1.1	Opening of the Abdominal Cavity .....	19
4.1.2	Exposure of the Pelvic Cavity .....	19
4.1.3	Visual and Manual Examination of the Spread of the Disease and Judgment of Operability .....	19
4.1.4	Traction of the Uterus .....	19
4.2	Illustrated Surgical Steps of Original Okabayashi's Radical Hysterectomy .....	20
4.2.1	Ligation and Division of the Round Ligament to Reveal the Connective Tissue of the Broad Ligament .....	20
4.2.2	Ligation and Division of the Ovarian Ligament (Propria Ovarii) and the Fallopian Tube for the Preservation of the Ovary .....	21
4.2.3	Isolation, Ligation, and Division of the Uterine Artery .....	22
4.2.4	Separation of the Ureter from the Dorsal Peritoneal Layer of the Broad Ligament .....	23
4.2.5	The Same Procedures on the Opposite Side .....	23
4.2.6	Separation of the Peritoneal Layer of the Pouch of Douglas .....	24

4.2.7	Development of the Retrovaginal Space and Dissection of the Uterosacral Ligament . . . . .	25
4.2.8	Further Division of the Uterosacral Ligament and the Development of Okabayashi's Pararectal Space . . . . .	26
4.2.9	Further Development of the Pararectal Space . . . . .	31
4.2.10	Development of the Paravesical Space and Separation of the Connective Tissue of the Base of the Cardinal Ligament . . . . .	32
4.2.11	Clamp the Cardinal Ligament . . . . .	33
4.2.12	Dissection of the Cardinal Ligament . . . . .	35
4.2.13	The Procedures on the Opposite Side . . . . .	35
4.2.14	Separation of the Peritoneum Between the Urinary Bladder and the Uterus . . . . .	36
4.2.15	Separation of the Connective Tissue Between the Urinary Bladder and the Ventral-Side of the Cervical Fascia (the Vesicocervical Space) . . . . .	37
4.2.16	Separation of the Anterior (Ventral) Leaf of the Vesicouterine Ligament (Left Side) . . . . .	38
4.2.17	Clamp and Dissect the Anterior (Ventral) Leaf of the Vesicouterine Ligament . . . . .	39
4.2.18	Separation of the Posterior (Dorsal) Leaf of the Vesicouterine Ligament and the Paravaginal Space . . . . .	40
4.2.19	Separation of the Posterior (Dorsal) Leaf of the Vesicouterine Ligament Through the Paravaginal Space . . . . .	41
4.2.20	Division of the Posterior (Dorsal) Leaf of the Vesicouterine Ligament from the Paracolpium . . . . .	42
4.2.21	The Same Procedures on the Opposite Side . . . . .	42
4.2.22	Treatment of the Rectovaginal Ligament . . . . .	43
4.2.23	A Figure of the Both Cut-Ends of the Cardinal Ligament, the Uterosacral Ligaments, and the Rectovaginal Ligaments . . . . .	44
4.2.24	Ligation and Dissection of the Paracolpium . . . . .	45
4.2.25	A View of the Pelvic Cavity After the Removal of the Uterus and Lymphadenectomy and Closure of the Abdominal Cavity . . . . .	47
<b>5</b>	<b>Novel Points of Okabayashi's Radical Hysterectomy . . . . .</b>	<b>49</b>
5.1	Novel Points of the Okabayashi's Radical Hysterectomy . . . . .	49
5.1.1	Clarification of the Anatomy of the Paravaginal Space Between the Posterior (Dorsal) Leaf of the Vesicouterine Ligament and the Paracolpium . . . . .	49
5.1.2	Clarification of the Anatomy of the Posterior (Dorsal) Leaf of the Vesicouterine Ligament . . . . .	53
<b>6</b>	<b>Step-by-Step Radical Hysterectomy with Pelvic Lymphadenectomy (Without Nerve-Sparing) . . . . .</b>	<b>55</b>
6.1	Surgical Process of the Step-by-Step Radical Hysterectomy . . . . .	55
6.1.1	Open the Abdominal Cavity . . . . .	55
6.1.2	Exposure of the Pelvic Cavity . . . . .	55
6.1.3	Visual and Manual Examination of the Spread of the Disease and Operability . . . . .	55
6.1.4	Traction of the Uterus . . . . .	55
6.1.5	Ligation and Division of the Round Ligament . . . . .	56
6.1.6	Ligation and Division of the Suspensory Ligament of the Ovary (Ovarian Vessels) . . . . .	57
6.1.7	Confirmation of the Ureter . . . . .	58
6.1.8	Isolation of the Ureter . . . . .	59



---

6.1.9	Application of a Vessel Tape for a Marker of the Ureter. . . . .	60
6.1.10	Tentative Development of the Pararectal Space . . . . .	61
6.1.11	Definition of the Pararectal Space. . . . .	62
6.1.12	The Ureter and the Hypogastric Nerve Are on the Same Connective Tissue Plane. . . . .	64
6.1.13	Division of the Peritoneum at Pouch of Douglas . . . . .	65
6.1.14	Separation of the Peritoneum of the Vesicouterine Pouch . . . . .	66
6.2	Pelvic Lymphadenectomy . . . . .	67
6.2.1	Lymph Nodes in the Pelvis . . . . .	67
6.2.2	Exposure of the Adipose Tissue in the Supra-Inguinal Area. . . . .	68
6.2.3	Exposure of the Iliopsoas Muscle . . . . .	69
6.2.4	Separation of the External Supra-Inguinal Nodes from the Ventral Surface of the External Iliac Artery . . . . .	70
6.2.5	Tentative Development of the Paravesical Space . . . . .	71
6.2.6	Separation of the Connective Tissue Between the External Iliac Artery and Iliopsoas Muscle . . . . .	72
6.2.7	Separation of the Uterine Side Connective Tissue of the External Iliac Artery and Vein. . . . .	73
6.2.8	Lymphadenectomy of the External Iliac Nodes of the Uterine Side. . . . .	74
6.2.9	Separation of the Connective Tissue Between the Iliopsoas Muscle and the External Iliac Vessels Toward the Pelvic Floor. . . . .	75
6.2.10	Dissection of the External Iliac Nodes . . . . .	76
6.2.11	Separation of the Connective Tissue on the Internal Iliac Artery . . . . .	77
6.2.12	Confirmation of the Obturator Nerve in the Obturator Fossa . . . . .	78
6.2.13	Lymphadenectomy of the Obturator Fossa . . . . .	79
6.2.14	Lymphadenectomy of the Obturator Fossa . . . . .	80
6.2.15	Lymphadenectomy of the Obturator Fossa . . . . .	81
6.2.16	En Bloc Removal of the Lymph Nodes in the Obturator Fossa . . . . .	82
6.2.17	Lymphadenectomy for the Dorsal Side of the Obturator Nerve . . . . .	83
6.2.18	Confirmation of the Base of the Cardinal Ligament . . . . .	85
6.2.19	The Lymphadenectomy of the Common Iliac Nodes . . . . .	86
6.2.20	Lymphadenectomy of the Sacral Nodes . . . . .	88
6.2.21	Removal of the Common Iliac Nodes . . . . .	89
6.2.22	A View of the Pelvic Cavity After the Pelvic Lymphadenectomy . . . . .	90
6.3	Treatment of the Cardinal Ligament. . . . .	91
6.3.1	A View of the Pelvis After the Lymphadenectomy . . . . .	91
6.3.2	Separation of the Loose Connective Tissue Between the Uterine Artery and the Superior Vesical Artery. . . . .	92
6.3.3	Development of the Paravesical Space and Confirmation of the Uterine Artery . . . . .	93
6.3.4	Definition of the Cardinal Ligament . . . . .	94
6.3.5	Isolation and Division of the Uterine Artery. . . . .	95
6.3.6	Separation of the Superficial Uterine Vein . . . . .	96
6.3.7	Clamp, Divide, and Ligate the Superficial Uterine Vein . . . . .	97
6.3.8	Separation of the Deep Uterine Vein . . . . .	98
6.3.9	Clamp, Divide, and Ligate the Deep Uterine Vein . . . . .	99
6.3.10	Confirmation and Division of the Pelvic Splanchnic Nerve . . . . .	100
6.4	Development of the Rectovaginal Space and Division of the Uterosacral Ligament. . . . .	101
6.4.1	Separation and Division of the Peritoneum of the Douglas' Pouch . . . . .	101
6.4.2	Development of the Rectovaginal Space. . . . .	102
6.4.3	Division of the Uterosacral Ligament. . . . .	103

6.4.4	Further Division of the Uterosacral Ligament and Development of the Okabayashi's Pararectal Space . . . . .	104
6.4.5	Development of the Pararectal Space . . . . .	105
6.5	Separation of the Urinary Bladder and the Vesicouterine Ligament . . . . .	106
6.5.1	Separation of the Urinary Bladder from the Cervical Fascia . . . . .	106
6.5.2	Anatomy of the Vesicouterine Ligament. . . . .	107
6.5.3	Anatomy of the Anterior (Ventral) Leaf of the Vesicouterine Ligament . . . . .	108
6.5.4	Anatomy of the Posterior(Dorsal) Leaf of the Vesicouterine Ligament . . . . .	109
6.5.5	Cross-Sectional Pelvic View of the Blood Vessels in the Vesicouterine Ligament with Each Surgical Step . . . . .	110
6.5.6	Lateral(Right) Side View of the Treatment of the Anterior (Ventral) Leaf of the Vesicouterine Ligament with Each Surgical Step . . . . .	115
6.5.7	Step-by-Step Separation of the Anterior (Ventral) Leaf of the Vesicouterine Ligament. . . . .	121
6.6	Treatment of the Posterior (Dorsal) Leaf of the Vesicouterine Ligament . . . . .	124
6.6.1	Step-by-Step Separation of the Posterior (Dorsal) Leaf of the Vesicouterine Ligament. . . . .	124
6.6.2	Division of the Rectovaginal Ligament. . . . .	132
6.6.3	Further Division of the Rectovaginal Ligament . . . . .	134
6.6.4	Division of the Paracolpium (Vaginal Blood Vessels). . . . .	135
6.6.5	Incision to the Vaginal Wall. . . . .	136
6.6.6	Amputation of the Vaginal Wall and Closure of the Vaginal Cuff. . . . .	137
6.6.7	Partial Suture to the Pelvic Peritoneum and Insertion of Drains into the Retroperitoneal Space . . . . .	138
6.6.8	Closure of the Abdominal Cavity . . . . .	139
	References. . . . .	140
<b>7</b>	<b>What Is Nerve-Sparing Radical Hysterectomy?</b> . . . . .	<b>141</b>
7.1	Severe Bladder Dysfunction/Colorectal Motility Disorders Are Common Complications of Radical Hysterectomy. . . . .	141
7.1.1	Nerve Supply to the Uterus, Rectum, and Urinary Bladder . . . . .	142
7.1.2	Locations of Nerve Damages During Radical Hysterectomy . . . . .	143
7.1.3	Efforts on Nerve-Sparing Radical Hysterectomy . . . . .	144
7.1.4	Principle of Nerve-Sparing Radical Hysterectomy . . . . .	145
7.1.5	The Description of Anatomy for Nerve-Sparing Radical Hysterectomy . . . . .	146
7.1.6	Indication of Nerve-Sparing Radical Hysterectomy . . . . .	147
	References. . . . .	148
<b>8</b>	<b>Step-by-Step Nerve-Sparing Radical Hysterectomy with Pelvic Lymphadenectomy</b> . . . . .	<b>149</b>
8.1	The Surgical Process of the Step-by-Step Nerve-Sparing Radical Hysterectomy Is Listed in the Following Pages . . . . .	149
8.2	The Following Are Described in Chap. 6. . . . .	149
8.3	Contents in Chap. 8 . . . . .	149
8.4	Treatment of the Cardinal Ligament. . . . .	150
8.4.1	A View of Pelvis After the Lymphadenectomy . . . . .	150
8.4.2	Separation of the Loose Connective Tissue Between the Uterine Artery and Superior Vesical Artery. . . . .	151
8.4.3	Development of the Paravesical Space and Confirmation of the Uterine Artery . . . . .	152

8.4.4	Confirmation of the Cardinal Ligament . . . . .	153
8.4.5	Isolation and Division of the Uterine Artery . . . . .	154
8.4.6	Separation of the Superficial Uterine Vein . . . . .	155
8.4.7	Clamping and Division of the Superficial Uterine Vein . . . . .	156
8.4.8	Separation of the Deep Uterine Vein . . . . .	157
8.4.9	Division of the Deep Uterine Vein Reveals the Pelvic Splanchnic Nerve . . . . .	158
8.5	Treatment of the Hypogastric Nerve . . . . .	159
8.5.1	Isolation of the Hypogastric Nerve . . . . .	159
8.5.2	Apply a Vessel Tape to the Isolated Hypogastric Nerve . . . . .	160
8.5.3	Separation of the Ureter from the Connective Tissue Plane and Application of a Vessel Tape to the Isolated Ureter . . . . .	161
8.6	Development of the Rectovaginal Space and Division of the Uterosacral Ligament . . . . .	162
8.6.1	Separation and Division of the Peritoneum of the Douglas' Pouch . . . . .	162
8.6.2	Development of the Rectovaginal Space . . . . .	163
8.6.3	Division of the Uterosacral Ligament . . . . .	164
8.7	Separation of the Urinary Bladder and Anatomy of the Vesicouterine Ligament . . . . .	165
8.7.1	Separation of the Urinary Bladder from the Cervical Fascia . . . . .	165
8.7.2	Anatomy of the Vesicouterine Ligament . . . . .	166
8.7.3	Anatomy of the Anterior (Ventral) Leaf of the Vesicouterine Ligament . . . . .	167
8.7.4	Anatomy of the Posterior (Dorsal) Leaf of the Vesicouterine Ligament . . . . .	168
8.7.5	Skeletonized View of the Blood Vessels and the Ureter in the Vesicouterine Ligament . . . . .	169
8.8	Treatment of the Anterior(Ventral) Leaf of the Vesicouterine Ligament . . . . .	170
8.8.1	Isolation of the Ureteral Branch of the Uterine Artery . . . . .	170
8.8.2	Division of the Ureteral Branch of the Uterine Artery . . . . .	171
8.8.3	Separation of the Superficial Uterine Vein from the Ureter and Isolation of the Superior Vesical Vein . . . . .	172
8.8.4	Division of the Superior Vesical Vein . . . . .	173
8.8.5	Complete Separation of the Uterine Side of the Uterine Artery and the Superficial Uterine Vein from the Ventral Side of the Ureter . . . . .	174
8.8.6	Separation of the Anterior (Ventral) Leaf of the Vesicouterine Ligament . . . . .	175
8.8.7	Isolation and Division of the Cervicovesical Vessels . . . . .	176
8.9	Treatment of the Posterior (Dorsal) Leaf of the Vesicouterine Ligament . . . . .	177
8.9.1	Mobilize the Ureter to the Symphysis Side and Confirm the Posterior (Dorsal) Leaf of the Vesicouterine Ligament . . . . .	177
8.9.2	Isolation of a Vein Connecting the Ureter with the Cervix . . . . .	178
8.9.3	Division of a Vein Connecting the Ureter with the Cervix . . . . .	180
8.9.4	Separation of the Cut-End of the Deep Uterine Vein from the Pelvic Splanchnic Nerve . . . . .	182
8.9.5	Importance of the Removal of the Adipose Tissues in the Posterior (Dorsal) Leaf of the Vesicouterine Ligament . . . . .	184
8.9.6	Clamp and Divide the Middle Vesical Vein . . . . .	185
8.9.7	Clamp and Divide the Inferior Vesical Vein . . . . .	187
8.10	Confirmation of the Inferior Hypogastric Plexus (IHP) . . . . .	189
8.11	The Concept of the Pelvic Nerve Plane . . . . .	191
8.12	Separation of the Rectovaginal Ligament . . . . .	192
8.13	Separation of the Bladder Branch from the Paracolpium . . . . .	193

---

8.14 Separation of the Uterine Branch from the IHP . . . . .	195
8.15 Division of the Uterine Branch . . . . .	197
8.16 Separation of the Rectovaginal Ligament Preserving T-Shaped Nerve Plane . . . . .	199
8.17 Clamp of the Paracolpium . . . . .	201
8.18 Ligation and Division of the Paracolpium . . . . .	203
8.19 Incise the Vaginal Wall for Amputation of the Vagina . . . . .	205
8.20 Removal of the Uterus Preserving T-Shaped Nerve Plane . . . . .	206
8.21 Closure of the Vaginal Cuff . . . . .	207
8.22 Partial Suture to the Pelvic Peritoneum and Insertion of Drains into the Retroperitoneal Space . . . . .	207
8.23 Closure of the Abdominal Cavity . . . . .	207
8.24 Management After Nerve-Sparing Radical Hysterectomy . . . . .	207

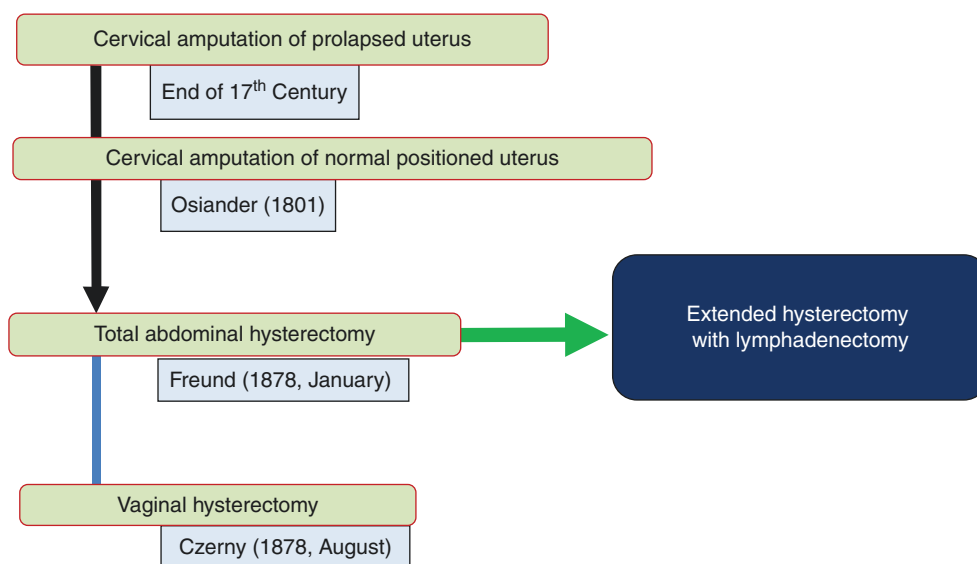
# Brief History of Surgical Treatment for Cervical Cancer

## 1.1 Cervical Amputation and Simple Total Hysterectomy (Figure 1.1)

Cervical cancer that was visible from the vagina enabled the vaginal resection of the lesion in the prolapsed uterus. The amputation of the cervix of the prolapsed uterus for the surgical treatment of cervical cancer started in the early seventeenth century. However, due to the poor outcomes following local excision, clinicians began to postulate that removal of the uterus may be necessary for the treatment of invasive cervical cancer. By the end of the nineteenth century, simple

total hysterectomy was developed either transabdominally (Freund 1878 January) and transvaginally (Czerny 1878 August) for the treatment of cervical cancer. Nevertheless, the outcome of these surgical treatments was still very poor. Consequently, wider resection of the paracervical tissues (the uterine supportive tissues), termed the *radical* approach (extended hysterectomy) was introduced for the treatment of cervical cancer.

**Figure 1.1** History of surgical treatment for cervical cancer



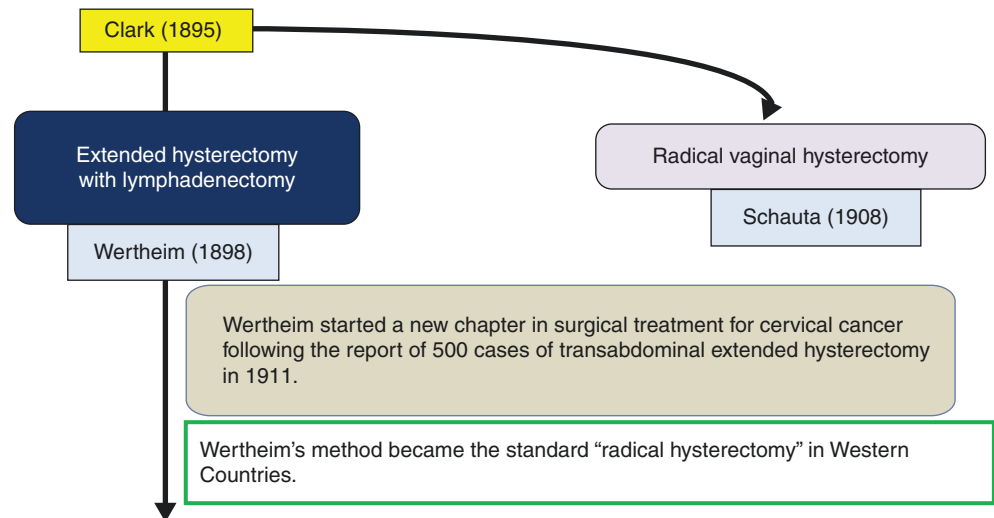
**Electronic Supplementary Material** The online version of this chapter ([https://doi.org/10.1007/978-981-13-8098-3\\_1](https://doi.org/10.1007/978-981-13-8098-3_1)) contains supplementary material, which is available to authorized users.

## 1.2 Extended Hysterectomy with Lymph Node Resection as a Radical Approach for Cervical Cancer Patients (Figure 1.2)

In 1895, JG Clark [1] reported the surgery of wider resection of the paracervical tissues with the uterus, (with bougie insertion into the ureters) as a novel cervical cancer surgery in Johns Hospital Bulletin (USA). Each of the 12 surgeries performed by Clark et al. differed slightly. In some cases the lymph nodes were removed, and in others the parametrium and a vaginal cuff were removed. This is considered as the first report of radical hysterectomy.

In 1898, Ernst Wertheim in Vienna developed a novel procedure of total hysterectomy; removal of the uterus with the parametrium, longer vaginal cuff, and lymph nodes. Then, he reported his improved technique and pathological findings of the removed uterus and lymph nodes with the prognosis of 500 cervical cancer patients in 1911 [2]. Since then, Wertheim's method was accepted as the "radical hysterectomy" and it became a representative method of radical hysterectomy in Western countries.

**Figure 1.2** Introduction of extended hysterectomy



### 1.3 Modification of Wertheim's Radical Hysterectomy with Pelvic Lymphadenectomy (Figure 1.3)

After the Wertheim's publication, many doctors attempted to modify the techniques of Wertheim's radical hysterectomy. Two novel surgical approaches were reported from Europe and East-Asia. In 1919, Wilhelm Latzko [3] published novel and more anatomically reasoned radical hysterectomy than that of Wertheim's. Latzko's surgery develops the paravesical space and the pararectal space and divides three ligamentous structures such as the uterosacral ligament (retinaculum posterior), cardinal ligament (retinaculum medial), and paracervical/vaginal tissues (retinaculum anterior).

In Japan, Wertheim's radical hysterectomy was introduced in Kyoto Imperial University. Shohei Takayama [4], Professor and Chairman (1906–1921) of the Department of Gynecology and Obstetrics at Kyoto Imperial University considered that Wertheim's method was not radical enough for the treatment of cervical cancers. Consequently, he endeavored to improve the technique of the Wertheim's operation to a more radical removal of the parametrial tissues, and reported his new tech-

nique at the meeting of the Japanese Gynecological Association in 1917. Moreover, Takayama's student, Hidekazu Okabayashi published the novel radical hysterectomy in 1921 [5]. Okabayashi's surgery opens the paravesical space and pararectal space and divides three ligamentous structures: the uterosacral ligament (retinaculum posterior), cardinal ligament (retinaculum medial), and paracervical/vaginal tissues (retinaculum anterior), which is line with that of Latzko's surgery. However, Okabayashi's radical hysterectomy contained novel steps on the division of the paracervical/vaginal tissues. Although the paracervical/vaginal tissues are clamped and divided as a mass in Latzko's surgery, Okabayashi's surgery separates the paracervical tissues into the vesicouterine ligament (anterior (ventral) leaf and posterior (dorsal) leaf) and the blood vessels of the vaginal wall (paracolpium), and divides independently [5, 6]. In order to get an appropriate length of the vaginal cuff, Okabayashi's surgery was much more extensive than that of Latzko's surgery.

**Figure 1.3** Modification of Wertheim's radical hysterectomy

