

THIEME

Latin Nomenclature

Atlas of Anatomy

Volume 3
Head, Neck,
and Neuroanatomy

Michael Schuenke
Erik Schulte
Udo Schumacher

Consulting Editors
Brian R. MacPherson
Cristian Stefan
Hugo Zeberg

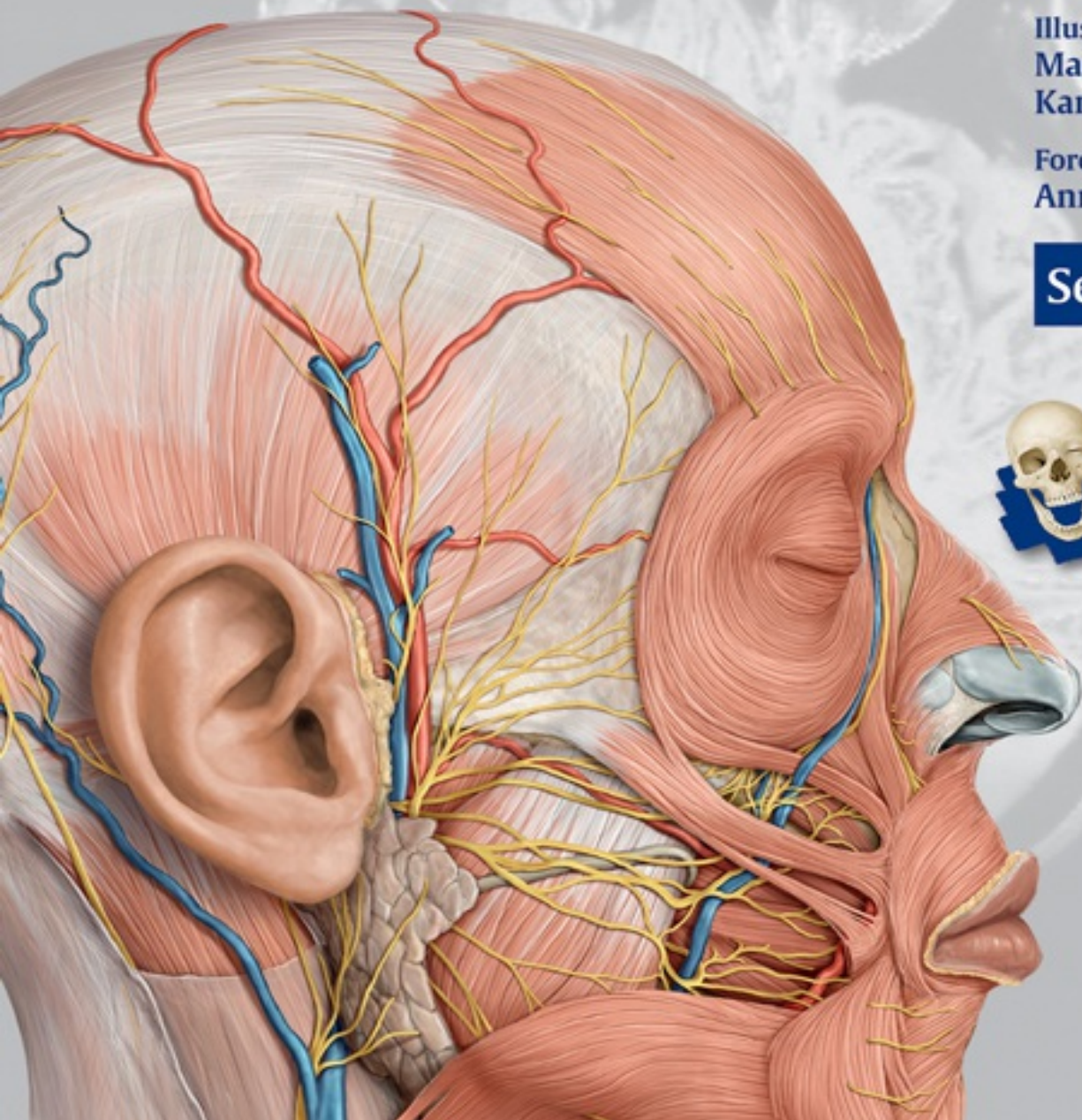
Illustrations by
Markus Voll
Karl Wesker

Foreword by
Anne M. Gilroy

Second Edition



Includes online
self-testing tool!
www.winkingskull.com



 Thieme

To access additional material or resources available with this e-book, please visit <http://www.thieme.com/bonuscontent>. After completing a short form to verify your e-book purchase, you will be provided with the instructions and access codes necessary to retrieve any bonus content.

Volume 3

Head, Neck, and Neuroanatomy

THIEME Atlas of Anatomy

Second Edition

Latin Nomenclature

Authors

Michael Schuenke, MD, PhD

Institute of Anatomy

Christina Albrecht University, Kiel

Erik Schulte, MD

Department of Anatomy and Cell Biology

Johannes Gutenberg University, Mainz

Udo Schumacher, MD

FRCPath, CBiol, FIBiol, DSc

Institute of Anatomy II: Experimental Morphology

University Medical Center, Hamburg-Eppendorf

Consulting Editors

Brian R. MacPherson, PhD

Department of Anatomy and Neurobiology

University of Kentucky College of Medicine

Lexington, Kentucky

Cristian Stefan, MD
Medical College of Georgia at Georgia
Regents University
Augusta, Georgia

Consulting Editor, Latin Nomenclature

Hugo Zeberg, MD, PhD
Lecturer
Department of Neuroscience
Karolinska Institutet
Stockholm, Sweden

Illustrations by

Markus Voll
Karl Wesker

Thieme
New York · Stuttgart · Delhi · Rio de Janeiro

Editorial Director, Educational Products: Anne M. Sydor
Editorial Assistant: Tony Paese
Managing Editor: Judith Tomat
Director, Editorial Services: Mary Jo Casey
International Production Director: Andreas Schabert
Vice President, Editorial and E-Product Development: Vera Spillner
International Marketing Director: Fiona Henderson
International Sales Director: Louisa Turrell
Director of Sales, North America: Mike Roseman
Senior Vice President and Chief Operating Officer: Sarah Vanderbilt
President: Brian D. Scanlan
Illustrations: Markus Voll and Karl Wesker
Compositor: Agnieszka & Martin Waletzko, Leonberg, Germany

Library of Congress Cataloging-in-Publication Data is available from the publisher upon request.

Copyright ©2016 by Thieme Medical Publishers, Inc

Thieme Publishers New York
333 Seventh Avenue, New York, NY 10001 USA
+1 800 782 3488, customerservice@thieme.com

Thieme Publishers Stuttgart
Rüdigerstrasse 14, 70469 Stuttgart, Germany
+49 [0]711 8931 421, customerservice@thieme.de

Thieme Publishers Delhi
A-12, Second Floor, Sector-2, Noida-201301
Uttar Pradesh, India
+91 120 45 566 00, customerservice@thieme.in

Thieme Publishers Rio de Janeiro, Thieme Publicações Ltda.
Edifício Rodolpho de Paoli, 25º andar
Av. Nilo Peçanha, 50 – Sala 2508,
Rio de Janeiro 20020-906 Brasil
+55 21 3172-2297 / +55 21 3172-1896

Printed in China by Everbest Printing Ltd 5 4 3 2 1

ISBN 978-1-62623-169-6

Also available as an e-book:

eISBN 978-1-62623-170-2

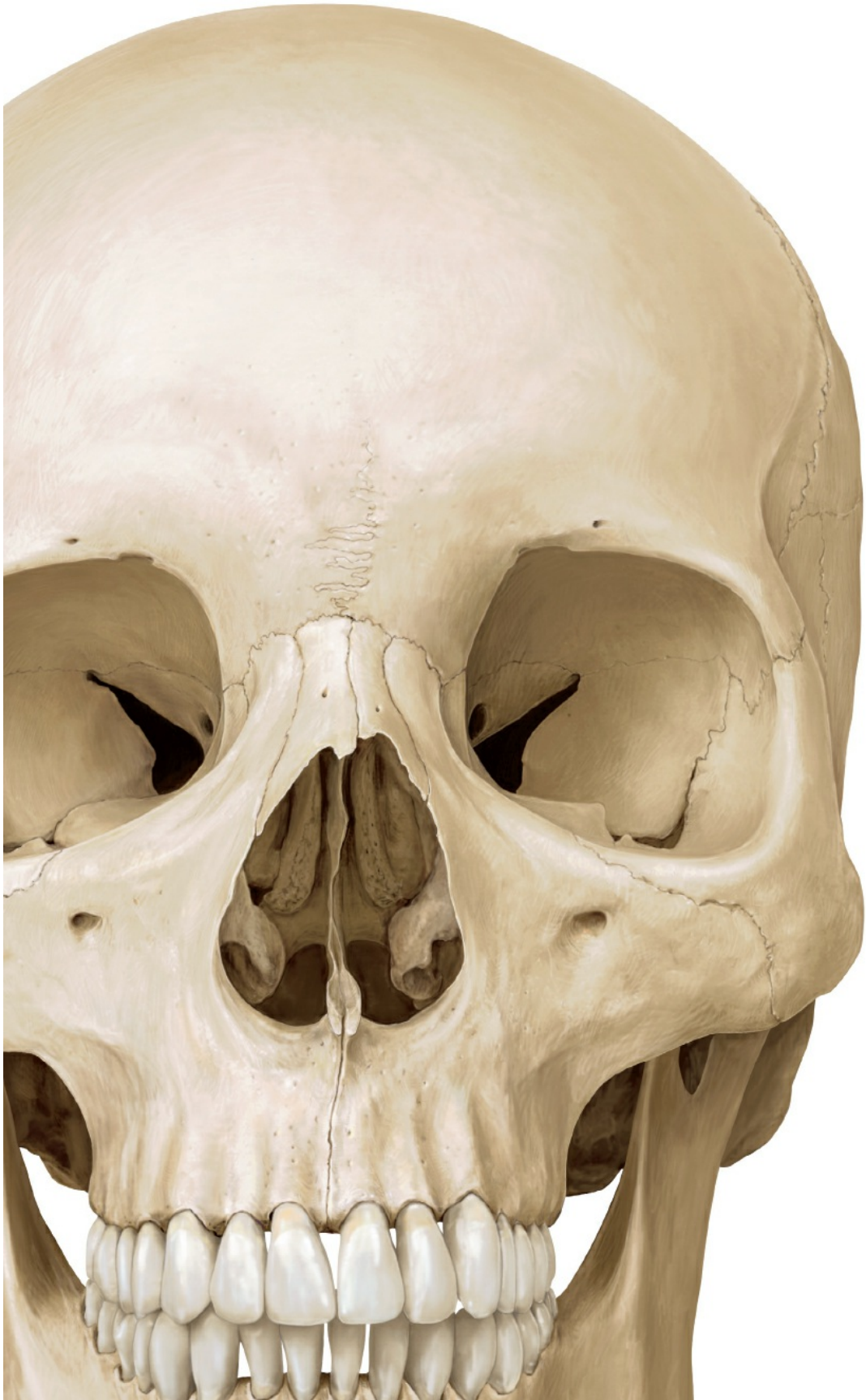Important note: Medicine is an ever-changing science undergoing continual development. Research and clinical experience are continually expanding our knowledge, in particular our knowledge of proper treatment and drug therapy. Insofar as this book mentions any dosage or application, readers may rest assured that the authors, editors, and publishers have made every effort to ensure that such references are in accordance with **the state of knowledge at the time of production of the book.**

Nevertheless, this does not involve, imply, or express any guarantee or responsibility on the part of the publishers in respect to any dosage instructions and forms of applications stated in the book. **Every user is requested to examine carefully** the manufacturer's leaflets accompanying each drug and to check, if necessary in consultation with a physician or specialist, whether the dosage schedules mentioned therein or the contraindications stated by the manufacturers differ from the statements made in the present book. Such examination is particularly important with drugs that are either rarely used or have been newly released on the market. Every dosage schedule or every form of application used is entirely at the user's own risk and responsibility. The authors and publishers request every user to report to the publishers any discrepancies or inaccuracies noticed. If errors in this work are found after publication, errata will be posted at www.thieme.com on the product description page.

Some of the product names, patents, and registered designs referred to in this book are in fact registered trademarks or proprietary names even though specific reference to this fact is not always made in the text. Therefore, the appearance of a name without designation as proprietary is not to be construed as a representation by the publisher that it is in the public domain.



This book, including all parts thereof, is legally protected by copyright. Any use, exploitation, or commercialization outside the narrow limits set by copyright legislation, without the publisher's consent, is illegal and liable to prosecution. This applies in particular to photostat reproduction, copying, mimeographing, preparation of microfilms, and electronic data processing and storage.



Contents

Foreword by Lawrence M. Ross, Brian R. MacPherson, and Anne M. Gilroy
Preface to the Second Edition
Preface to the First Edition
A Note on the Use of Latin Terminology
Acknowledgments

Head and Neck

1 Overview

- 1.1 Regions and Palpable Bony Landmarks
- 1.2 Head and Neck and Cervical Fasciae
- 1.3 Clinical Anatomy
- 1.4 Embryology of the Face
- 1.5 Embryology of the Neck

2 Bones, Ligaments, and Joints

- 2.1 Skull, Lateral View
- 2.2 Skull, Anterior View
- 2.3 Skull, Posterior View and Cranial Sutures (Suturae Cranii)
- 2.4 Exterior and Interior of the Calvarium
- 2.5 Base of the Skull (Basis Cranii), External View
- 2.6 Base of the Skull (Basis Cranii), Internal View
- 2.7 Orbit (Orbita): Bones and Openings for Neurovascular Structures
- 2.8 Orbita and Neighboring Structures
- 2.9 Nose: Nasal Skeleton
- 2.10 Nose: Paranasal Sinuses (Sinus Paranasales)
- 2.11 Temporal Bone (Os Temporale)
- 2.12 Sphenoid Bone (Os Sphenoidale)

- 2.13 Occipital Bone (Os Occipitale) and Ethmoid Bone (Os Ethmoidale)
- 2.14 Hard Palate (Palatum Durum)
- 2.15 Mandible (Mandibula) and Hyoid Bone (Os Hyoideum)
- 2.16 Teeth (Dentes) in situ
- 2.17 Terminology, Dental Schema, and Dental Characteristics
- 2.18 Position of Teeth in Permanent Dentition: Orientation of the Skull and Dental Occlusion
- 2.19 Permanent Teeth (Dentes Permanentes) Morphology
- 2.20 Periodontium
- 2.21 Deciduous Teeth (Dentes Decidui)
- 2.22 Tooth Development (Odontogenesis)
- 2.23 Dental Radiology
- 2.24 Dental Local Anesthesia
- 2.25 Temporomandibular Joint (Articulatio Temporomandibularis)
- 2.26 Biomechanics of the Temporomandibular Joint (Articulatio Temporomandibularis)
- 2.27 The Cervical Spine
- 2.28 Overview of the Ligaments of the Cervical Spine
- 2.29 The Ligaments of the Upper Cervical Spine (Articulationes Atlantooccipitalis and Atlantoaxialis)
- 2.30 The Uncovertebral Joints of the Cervical Spine

3 Classification of the Muscles

- 3.1 Muscles of Facial Expression (Musculi Faciei): Overview
- 3.2 Muscles of Facial Expression: Actions.
- 3.3 Muscles of Mastication (Musculi Masticatorii): Overview and Superficial Muscles
- 3.4 Muscles of Mastication (Musculi Masticatorii): Deep Muscles
- 3.5 Muscles of the Head: Origins and Insertions
- 3.6 Neck Muscles: Overview and Superficial Muscles
- 3.7 Neck Muscles: Suprahyoid and Infrahyoid Muscles
- 3.8 Neck Muscles: Prevertebral and Lateral (Deep) Muscles

4 Classification of the Neurovascular Structures

- 4.1 Classification of the Arteries Supplying the Head and Neck
- 4.2 Arteria Carotis Interna and Classification of the Branches of the Arteria Carotis Externa
- 4.3 Arteria Carotis Externa: Anterior, Medial, and Posterior Branches
- 4.4 Arteria Carotis Externa: Terminal Branches
- 4.5 Arteria Carotis Interna: Branches to Extracerebral Structures
- 4.6 Veins of the Head and Neck: Superficial Veins
- 4.7 Veins of the Head and Neck: Deep Veins
- 4.8 Veins of the Neck
- 4.9 Lymph Nodes (Nodi Lymphoidei) and Lymphatic Drainage of the Head and Neck
- 4.10 Overview of the Nervi Craniales
- 4.11 Cranial Nerves: Brainstem (Truncus Encephali) Nuclei and Peripheral Ganglia
- 4.12 Nervi Craniales: Nervus Olfactorius (CN I) and Nervus Opticus (CN II)
- 4.13 Nervi Craniales of the Extraocular Muscles: Nervus Oculomotorius (CN III), Nervus Trochlearis (CN IV), and Nervus Abducens (CN VI)
- 4.14 Nervi Craniales: Nervus Trigemini (CN V), Nuclei and Distribution.
- 4.15 Nervi Craniales: Nervus Trigemini (CN V), Divisions
- 4.16 Nervi Craniales: Nervus Facialis (CN VII), Nuclei and Distribution
- 4.17 Nervi Craniales: Nervus Facialis (CN VII), Branches
- 4.18 Nervi Craniales: Nervus Vestibulocochlearis (CN VIII)
- 4.19 Nervi Craniales: Nervus Glossopharyngeus (CN IX)
- 4.20 Nervi Craniales: Nervus Vagus (CN X)
- 4.21 Nervi Craniales: Nervus Accessorius (CN XI) and Nervus Hypoglossus (CN XII)
- 4.22 Neurovascular Pathways through the Base of the Skull, Synopsis
- 4.23 Overview of the Nervous System in the Neck and the Distribution of Spinal Nerve Branches
- 4.24 Nervi Craniales and Autonomic Nervous System in the Neck

5 Organs and their Neurovascular Structures

- 5.1 Ear (Auris): Overview and Supply to the External Ear (Auris Externa)
- 5.2 External Ear: Auricula, Auditory Canal (Meatus Acusticus Externus)

- and Tympanic Membrane (Membrana Tympanica)
- 5.3 Middle Ear (Auris Media): Tympanic Cavity (Cavitas Tympani) and Pharyngotympanic Tube (Tuba Auditiva)
- 5.4 Middle Ear: Auditory Ossicles (Ossicula Auditoria) and Tympanic Cavity (Cavitas Tympani)
- 5.5 Inner Ear (Auris Interna): Overview
- 5.6 Ear: Auditory Apparatus
- 5.7 Inner Ear: Vestibular Apparatus
- 5.8 Ear: Blood Supply
- 5.9 Eye: Orbital Region, Eyelids, and Conjunctiva
- 5.10 Eye: Lacrimal Apparatus (Apparatus Lacrimalis)
- 5.11 Eyeball (Bulbus Oculi)
- 5.12 Eye: Lens and Cornea
- 5.13 Eye: Iris and Ocular Chambers
- 5.14 Eye: Retina
- 5.15 Eye: Blood Supply
- 5.16 Orbita: Extraocular Muscles (Musculi Externi Bulbi Oculi)
- 5.17 Orbita: Subdivisions and Neurovascular Structures
- 5.18 Orbit: Topographical Anatomy
- 5.19 Nose: Overview
- 5.20 Nasal Cavity (Cavitas Nasi): Neurovascular Supply
- 5.21 Nose and Paranasal Sinuses (Sinus Paranasales): Histology and Clinical Anatomy
- 5.22 Oral Cavity (Cavitas Oris): Overview
- 5.23 Tongue (Lingua): Muscles and Mucosa
- 5.24 Tongue: Neurovascular Structures and Lymphatic Drainage
- 5.25 Oral Floor
- 5.26 Oral Cavity: Pharynx and Tonsils (Tonsillae)
- 5.27 Pharynx: Muscles
- 5.28 Pharynx: Surface Anatomy of the Mucosa and its Connections with the Skull Base
- 5.29 Pharynx: Topographical Anatomy and Innervation
- 5.30 Pharynx: The Parapharyngeal Space and its Clinical Significance
- 5.31 Pharynx: Neurovascular Structures in the Parapharyngeal Space (Superficial Layer)

- 5.32 Pharynx: Neurovascular Structures in the Parapharyngeal Space (Deep Layer)
- 5.33 Salivary Glands (Glandulae Salivariae)
- 5.34 Larynx: Location, Shape, and Laryngeal Cartilages
- 5.35 Larynx: Internal Features and Neurovascular Structures
- 5.36 Larynx: Muscles
- 5.37 Larynx: Topographical and Clinical Anatomy
- 5.38 Endotracheal Intubation
- 5.39 Thyroid Gland (Glandula Thyroidea) and Parathyroid Glands (Glandulae Parathyroideae)
- 5.40 Topography and Imaging of the Glandula Thyroidea

6 Topographical Anatomy

- 6.1 Face: Nerves and Vessels
- 6.2 Neck, Ventral View: Superficial Layers
- 6.3 Neck, Ventral View: Deep Layers
- 6.4 Head, Lateral View: Superficial Layer
- 6.5 Head, Lateral View: Middle and Deep Layers
- 6.6 Infratemporal Fossa (Fossa Infratemporalis)
- 6.7 Pterygopalatine Fossa (Fossa Pterygopalatina)
- 6.8 Posterior Cervical Triangle (Trigonum Cervicale Posterius)
- 6.9 Deep Lateral Cervical Region, Carotid Triangle (Trigonum Caroticum), and Thoracic Inlet (Apertura Thoracis Superior)
- 6.10 Posterior Cervical and Occipital Regions (Regiones Cervicalis Posterior and Occipitalis)

7 Sectional Anatomy

- 7.1 Coronal Sections: Anterior Orbital Margin and Retrobulbar Space
- 7.2 Coronal Sections: Orbital Apex and Hypophysis.
- 7.3 Transverse Sections: Orbits (Orbitae) and Optic Nerve (Nervus Opticus)
- 7.4 Transverse Sections: Sphenoid Sinus (Sinus Sphenoidalis) and Middle Nasal Concha (Concha Nasalis Media)

- 7.5 Transverse Sections: Nasopharynx (Pars Nasalis Pharyngis) and Median Atlantoaxial Joint (Articulatio Atlantoaxialis Mediana)
- 7.6 Transverse Sections: C5–C6
- 7.7 Transverse Sections: Anatomy of the Neck from the T1/T2 to C6/C7 Levels
- 7.8 Midsagittal Sections: Nasal Septum (Septum Nasi) and Medial Orbital Wall
- 7.9 Sagittal Sections: Inner Third and Center of the Orbit

Neuroanatomy

8 Introduction to Neuroanatomy

- 8.1 Organization and Basic Functions of the Nervous System
- 8.2 Cells, Signal Transmission, and Morphological Structure of the Nervous System
- 8.3 Overview of the Entire Nervous System: Morphology and Spatial Orientation
- 8.4 Embryological Development of the Nervous System
- 8.5 Nervous System in situ
- 8.6 Overview of the Brain: Telencephalon and Diencephalon
- 8.7 Overview of the Brain: Brainstem (Truncus Encephali) and Cerebellum.
- 8.8 Overview of the Spinal Cord (Medulla Spinalis)
- 8.9 Blood Supply of the Brain and Spinal Cord
- 8.10 Somatic Sensation
- 8.11 Somatomotor Function
- 8.12 Sensory Organs
- 8.13 Principles of the Neurological Examination

9 Histology of Nerve and Glial Cells

- 9.1 Neurons
- 9.2 Neuroglia and Myelination

10 Autonomic Nervous System

- 10.1 Sympathetic and Parasympathetic Nervous Systems, Organization
- 10.2 Autonomic Nervous System, Actions and Regulation
- 10.3 Parasympathetic Nervous System, Overview and Connections
- 10.4 Autonomic Nervous System: Pain Conduction
- 10.5 Enteric Nervous System (Plexus Entericus)

11 Meninges of the Brain and Spinal Cord

- 11.1 Brain and Meninges in situ
- 11.2 Meninges and Dural Septa
- 11.3 Meninges of the Brain and Spinal Cord

12 Ventricular System and Cerebrospinal Fluid

- 12.1 Ventricular System, Overview
- 12.2 Cerebrospinal Fluid (Liquor Cerebrospinalis), Circulation and Cisternae
- 12.3 Circumventricular Organs and Tissue Barriers in the Brain
- 12.4 In Situ Projection of the Ventricular and Dural Venous Sinus Systems in the Cranial Cavity

13 Telencephalon

- 13.1 Telencephalon, Development and External Structure
- 13.2 Gyri and Sulci of the Telencephalon: Convex Surface of the Cerebral Hemispheres and Base of the Brain
- 13.3 Gyri and Sulci of the Telencephalon: Medial Surface and Insula
- 13.4 Cortex Cerebri, Histological Structure and Functional Organization
- 13.5 Neocortex, Cortical Areas
- 13.6 Allocortex, Overview
- 13.7 Allocortex: Hippocampus and Amygdala
- 13.8 The White Matter (Substantia Alba)
- 13.9 Basal Nuclei (Nuclei Basales)

14 Diencephalon

- 14.1 Diencephalon, Overview and Development
- 14.2 Diencephalon, External Structure
- 14.3 Diencephalon, Internal Structure
- 14.4 Thalamus: Thalamic Nuclei
- 14.5 Thalamus: Projections of the Thalamic Nuclei
- 14.6 Hypothalamus
- 14.7 Glandula Pituitaria (Hypophysis)
- 14.8 Epithalamus and Subthalamus

15 Brainstem

- 15.1 Brainstem (Truncus Encephali), Organization and External Structure
- 15.2 Truncus Encephali: Nuclei Nervi Craniales, Nucleus Ruber, and Substantia Nigra
- 15.3 Truncus Encephali: Reticular Formation (Formatio Reticularis)
- 15.4 Truncus Encephali: Descending and Ascending Tracts
- 15.5 Mesencephalon and Pons, Transverse Section
- 15.6 Medulla Oblongata, Transverse Section

16 Cerebellum

- 16.1 Cerebellum, External Structure
- 16.2 Cerebellum, Internal Structure
- 16.3 Cerebellar Peduncles and Tracts
- 16.4 Cerebellum, Simplified Functional Anatomy and Lesions

17 Blood Vessels of the Brain

- 17.1 Arteries of the Brain: Blood Supply and the Circle of Willis
- 17.2 Arteries of the Cerebrum
- 17.3 Arteries of the Cerebrum, Distribution
- 17.4 Arteries of the Truncus Encephali and Cerebellum
- 17.5 Dural Sinuses (Sinus Durae Matris), Overview
- 17.6 Sinus Durae Matris: Tributaries and Accessory Draining Vessels
- 17.7 Veins of the Brain: Superficial and Deep Veins

- 17.8 Veins of the Truncus Encephali and Cerebellum: Deep Veins
- 17.9 Blood Vessels of the Brain: Intracranial Hemorrhage
- 17.10 Blood Vessels of the Brain: Cerebrovascular Disease

18 Spinal Cord

- 18.1 Spinal Cord (Medulla Spinalis): Segmental Organization
- 18.2 Medulla Spinalis: Organization of Medulla Spinalis Segments
- 18.3 Medulla Spinalis: Internal Divisions of the Substantia Grisea
- 18.4 Medulla Spinalis: Reflex Arcs and Intrinsic Circuits
- 18.5 Ascending Tracts of the Medulla Spinalis: Tractus Spinothalamici
- 18.6 Ascending Tracts of the Medulla Spinalis: Fasciculus Gracilis and Fasciculus Cuneatus
- 18.7 Ascending Tracts of the Medulla Spinalis: Tractus Spinocerebellares
- 18.8 Descending Tracts of the Spinal Cord: Tractus Pyramidales (Corticospinales)
- 18.9 Descending Tracts of the Medulla Spinalis: Extrapyrmidal and Autonomic Tracts
- 18.10 Tracts of the Medulla Spinalis, Overview
- 18.11 Blood Vessels of the Medulla Spinalis: Arteries
- 18.12 Blood Vessels of the Medulla Spinalis: Veins
- 18.13 Medulla Spinalis, Topography

19 Sectional Anatomy of the Brain

- 19.1 Coronal Sections: I and II (Frontal)
- 19.2 Coronal Sections: III and IV
- 19.3 Coronal Sections: V and VI.
- 19.4 Coronal Sections: VII and VIII.
- 19.5 Coronal Sections: IX and X
- 19.6 Coronal Sections: XI and XII (Occipital)
- 19.7 Transverse Sections: I and II (Cranial)
- 19.8 Transverse Sections: III and IV
- 19.9 Transverse Sections: V and VI (Caudal)
- 19.10 Sagittal Sections: I–III (Lateral)

- 19.11 Sagittal Sections: IV–VI
- 19.12 Sagittal Sections: VII and VIII (Medial)

20 Functional Systems

- 20.1 Somatosensory System: Synopsis of the Pathways
- 20.2 Somatosensory System: Stimulus Processing
- 20.3 Somatosensory System: Lesions
- 20.4 Somatosensory System: Pain Conduction.
- 20.5 Somatosensory System: Pain Pathways in the Head and the Central Analgesic System
- 20.6 Motor System, Overview
- 20.7 Motor System: Tractus Pyramidalis (Corticospinalis)
- 20.8 Motor System: Motor Nuclei
- 20.9 Motor System: Extrapyrarnidal Motor System and Lesions
- 20.10 Radicular Lesions: Sensory Deficits
- 20.11 Radicular Lesions: Motor Deficits
- 20.12 Lesions of the Plexus Brachialis
- 20.13 Lesions of the Plexus Lumbosacralis
- 20.14 Lesions of the Medulla Spinalis and Peripheral Nerves: Sensory Deficits
- 20.15 Lesions of the Medulla Spinalis and Peripheral Nerves: Motor Deficits
- 20.16 Lesions of the Medulla Spinalis, Assessment
- 20.17 Visual System: Overview and Geniculate Part
- 20.18 Visual System: Lesions and Nongeniculate Part
- 20.19 Visual System: Reflexes
- 20.20 Visual System: Coordination of Eye Movement
- 20.21 Auditory Pathway
- 20.22 Vestibular System
- 20.23 Gustatory System (Taste)
- 20.24 Olfactory System (Smell)
- 20.25 Limbic System
- 20.26 Brain: Functional Organization
- 20.27 Brain: Hemispheric Dominance
- 20.28 Brain: Clinical Findings

CNS: Glossary and Synopsis

21 Glossary

- 21.1 Substantia Grisea (Gray Matter)
- 21.2 Substantia Alba (White Matter)
- 21.3 Sensory and Motor Functions; Overview of the Medulla Spinalis and Tracts in the Medulla Spinalis

22 Synopsis

- 22.1 Sensory Tracts of the Medulla Spinalis
- 22.2 Motor Tracts of the Medulla Spinalis
- 22.3 Sensory Trigeminal Pathway
- 22.4 Auditory Pathway
- 22.5 Gustatory Pathway
- 22.6 Olfactory Pathway
- 22.7 Control of Motor Nuclei of Nervi Craniales
- 22.8 Ocular Motor Control
- 22.9 Truncus Encephali Pathways
- 22.10 Retinal Projections
- 22.11 Autonomic and Sensory Ganglia of the Head
- 22.12 Motor System Connectivity
- 22.13 Cerebellar Connectivity
- 22.14 Functional Cortical Areas
- 22.15 Association and Projection Pathways
- 22.16 Nuclei Olivares Superior and Inferior as well as the Four Lemnisci
- 22.17 Left to Right Connections in the CNS: Commissures and Decussations
- 22.18 Diencephalic Nuclei and Thalamic Nuclear Regions
- 22.19 Nuclei of Nervi Craniales and Autonomic Nuclei

Appendix

References

Subject Index

Foreword

Each of the authors of the single-volume *Thieme Atlas of Anatomy* was impressed with the extraordinary detail, accuracy, and beauty of the illustrations that were created for the Thieme three-volume series of anatomy atlases. We felt these images were one of the most significant additions to anatomic education in the past 50 years. The effective pedagogical approach of this series, with two-page learning units that combined the outstanding illustrations and captions that emphasized the functional and clinical significance of structures, coupled with the numerous tables summarizing key information, was unique. We also felt that the overall organization of each region, with structures presented first systemically—musculoskeletal, vascular, and nervous—and then topographically, supported classroom learning and active dissection in the laboratory.

This series combines the best of a clinically oriented text and an atlas. Its detail and pedagogical presentation make it a complete support for classroom and laboratory instruction and a reference for life in all the medical, dental, and allied health fields. Each of the volumes—*General Anatomy and Musculoskeletal System*, *Internal Organs*, and *Head, Neck, and Neuroanatomy*—can also be used as a stand-alone text/atlas for an in-depth study of systems often involved in the allied health/medical specialty fields.

We were delighted when Thieme asked us to work with them to create a single-volume atlas from this groundbreaking series, and we owe a great debt to the authors and illustrators of this series inasmuch as their materials and vision formed the general framework for the single-volume *Thieme Atlas of Anatomy*.

We thank the authors and illustrators for this very special contribution to the teaching of anatomy and recommend it for thorough mastery of anatomy and its clinically functional importance in all fields of health care-related specialties.

Lawrence M. Ross, Brian R. MacPherson, and Anne M. Gilroy

Preface to the Second Edition

Six years have passed since the first edition of the *THIEME Atlas of Anatomy: Head, Neck, and Neuroanatomy* was published. It has passed its first test and met the needs of students and practitioners everywhere, as evidenced by the many letters and e-mails we have received. We thank you for your praise and constructive criticism, which helps us keep improving this atlas.

Clinical knowledge presented in conjunction with anatomy is increasingly important earlier and earlier in the study of medicine. This has been further strengthened in this edition with the inclusion of about 30 new two-page spreads across the book devoted to

- osteoarthritis of the hip joint,
- compression syndromes of peripheral nerves,
- conduction anesthesia of peripheral nerves,
- shoulder arthroscopy and degenerative changes of the shoulder joint,
- functions of individual muscles and the symptoms associated with shortening or weakening of these muscles, and
- diagnostic imaging of the large joints, such as the shoulder, elbow, and wrist, and the hip, knee, and ankle.

In addition, we have added spreads on important foundational information on the common imaging planes for plain film, MRI, and CT scans, the structure of skeletal muscle fibers, the structure and chemical composition of hyaline cartilage, and the regeneration of peripheral nerves.

We have also checked, corrected, and updated all the information in this atlas.

With these improvements, this atlas is even better suited to students of medicine in what the World Health Organization (WHO) is again calling the “Decade of Bones and Joints” (first 2000 to 2010 and now 2010 to 2020) to draw attention to the continuing prominence and dramatic rise of diseases of

the musculoskeletal system with the rise in average life expectancy worldwide. Today more than half the chronic diseases of those over 60 involve the bones (e.g., osteoporosis) and joints (e.g., osteoarthritis), with tremendous economic consequences. One of the main reasons WHO is publicizing this is so that the world's universities appropriately prepare physicians, physical therapists, and other health care workers to address the growing global burden of these diseases due to the aging population.

This atlas emphasizes the correlations between physiologic changes in the course of life, the frequency of certain pathologic phenomena, and effective diagnostics while teaching the anatomy, better preparing students to treat patients with musculoskeletal diseases when they meet them in the clinic or in practice. When an elderly person suffers a fracture, it is not sufficient to just address the fracture. The doctor must learn why the fracture happened and address the underlying cause. Does, for example, the patient have osteoporosis, or is he or she so inflexible that any unexpected need to move leads to a fall? Interdisciplinary cooperation is needed to address these causes and provide appropriate preventive and rehabilitative care. The older we get, the more important it is for us to keep the musculoskeletal system in motion to curb degenerative disease and prevent injury.

We hope that this atlas continues to meet your needs in the classroom and clinic, helps you attain a more nuanced understanding of the anatomy of the musculoskeletal system, and brings the fascination of anatomy in motion home to you.

Our special thanks to Prof. Dr. Cristoph Viebahn, Georg-August University, Göttingen, and Prof. Dr. Thilo Wedel, Christian-Albrechts University, Kiel, for their commitment to and constructive help on the new edition.

*Michael Schuenke, Erik Schulte, Udo Schumacher,
Markus Voll, and Karl Wesker
Kiel, Mainz, Hamburg, Munich, and Berlin*

Preface to the First Edition

When Thieme started planning this atlas, they sought the opinions of students and instructors in both the United States and Europe on what constituted an “ideal” atlas of anatomy—ideal to learn from, to master extensive amounts of information while on a busy class schedule, and, in the process, to acquire sound, up-to-date knowledge. The result of our work in response to what Thieme learned is this atlas. The *Thieme Atlas of Anatomy*, unlike most other atlases, is a comprehensive educational tool that combines illustrations with explanatory text and summary tables, introducing clinical applications throughout, and presenting anatomic concepts in a step-by-step sequence that includes system-by-system and topographical views.

Because the *Thieme Atlas of Anatomy* is based on a fresh approach to the underlying subject matter, it was necessary to create an entirely new set of illustrations for it—a task that took eight years. Our goal was to provide illustrations that would compellingly demonstrate anatomic relations and concepts, revealing the underlying simplicity of human anatomy without sacrificing detail or aesthetics.

With the *Thieme Atlas of Anatomy*, it was our intention to create an atlas that would guide students in their initial study of anatomy, stimulate their enthusiasm for this intriguing and vitally important subject, and provide a reliable reference for experienced students and professionals alike.

“If you want to attain the possible, you must attempt the impossible”
(Rabindranath Tagore).

*Michael Schuenke, Erik Schulte, Udo Schumacher,
Markus Voll, and Karl Wesker*

A Note on the Use of Latin Terminology

To introduce the Latin nomenclature into an English textbook is a delicate task, particularly because many Latin loanwords have passed into general use. Some loanwords are so common that fluency of the text would be disturbed if they were to be translated back into Latin. These Latin loanwords have typically undergone several adaptations before becoming part of the English language. A term such as *sympathetic trunk* (lat. *truncus sympaticus*) has undergone morphological adaptation (through the loss of masculine suffix *-us*), orthographical adaptation (through the substitution of a "Germanic" *k* for a Latin *c*), and phonological adaptation (*th* and *e* instead of *t* and *i*). In addition, the word order has been reversed. The Latin term *sympaticus* is in fact borrowed from the late Greek word *sympathetikos* (from *sympathes* "having a fellow feeling, affected by like feelings"), thereby illustrating that terms move between languages when cultures meet.

Other anatomical terms are so colloquial (e.g., *hand*), that a Latin term (e.g., *manus*) would be inappropriate to use at all occasions. Clearly, the text would easily become unreadable if a strict translation of all English terms into Latin were imposed.

As a result, Latin has been used as long as it does not disrupt the flow of the text and whenever possible in figures and tables. In some cases, dual terminology has been used, with either the English or Latin word in parenthesis. As much as possible, the terminology of *Terminologia Anatomica* (1998) has been followed.

Hugo Zeberg, M.D., Ph.D.
Lecturer
Karolinska Institutet

Acknowledgments

First, we wish to thank our families. This atlas is dedicated to them.

We also thank Prof. Reinhard Gossrau, M.D., for his critical comments and suggestions. We are grateful to several colleagues who rendered valuable help in proofreading: Mrs. Gabriele Schünke, Jakob Fay, M.D., Ms. Claudia Dücker, Ms. Simin Rassouli, Ms. Heinke Teichmann, and Ms. Sylvia Zilles. We are also grateful to Dr. Julia Jürns-Kuhnke for helping with the figure labels.

We extend special thanks to Stephanie Gay and Bert Sender, who prepared the layouts. Their ability to arrange the text and illustrations on facing pages for maximum clarity has contributed greatly to the quality of the atlas.

We particularly acknowledge the efforts of those who handled this project on the publishing side: Jürgen Lüthje, M.D., Ph.D., executive editor at Thieme Medical Publishers, has “made the impossible possible.” He not only reconciled the wishes of the authors and artists with the demands of reality but also managed to keep a team of five people working together for years on a project whose goal was known to us from the beginning but whose full dimensions we only came to appreciate over time. He is deserving of our most sincere and heartfelt thanks.

Sabine Bartl, developmental editor, became a touchstone for the authors in the best sense of the word. She was able to determine whether a beginning student, and thus one who is not (yet) a professional, could clearly appreciate the logic of the presentation. The authors are indebted to her.

We are grateful to Antje Bühl, who was there from the beginning as project assistant, working “behind the scenes” on numerous tasks such as repeated proofreading and helping to arrange the figure labels.

We owe a great debt of thanks to Martin Spencker, managing director of Educational Publications at Thieme, especially to his ability to make quick

and unconventional decisions when dealing with problems and uncertainties. His openness to all the concerns of the authors and artists established conditions for a cooperative partnership.

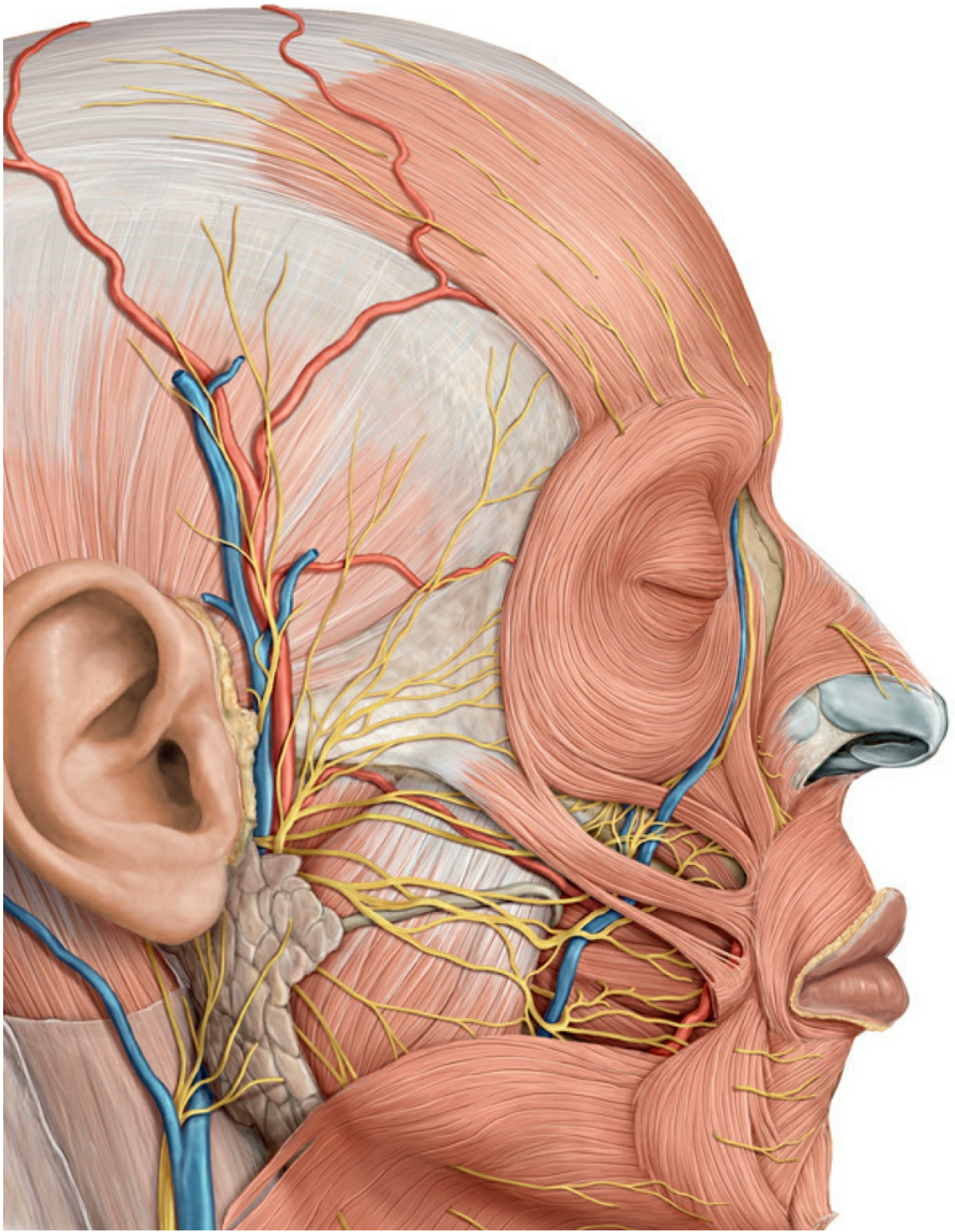
Without exception, our collaboration with the entire staff at Thieme Medical Publishers was consistently pleasant and cordial. Unfortunately, we do not have room to list everyone who helped in the publication of the *Atlas*, and we must limit our acknowledgments to a few colleagues who made a particularly notable contribution: Rainer Zepf and Martin Waletzko for support in all technical matters; Susanne Tochtermann-Wenzel and Manfred Lehnert, representing all those who were involved in the production of the book; Almut Leopold for the index; Marie-Luise Kürschner and her team for creating the cover design; to Liesa Arendt, Birgit Carlsen, and Anne Döbler, representing all those who handled marketing, sales, and promotion.

The Authors

It has been a great honor to act as a consulting editor, with responsibility for the Latin nomenclature, for *Thieme Atlas of Anatomy: Head, Neck, and Neuroanatomy*, Second Edition. There were several people from whom I received a great deal of assistance and guidance, and must express my gratitude towards. I would wish to thank Professor Eugene Flamm, M.D., for having given me the opportunity to study clinical neuroanatomy and for sharing his great knowledge in anatomy. Regarding the discussion of nomenclature, I would wish to thank my mentor Prof. Peter Århem, Ph.D., my father Lennart Zeberg, M.D., and Prof. Jonas Broman, Ph.D. In addition, I would also like to express my gratitude to Prof. Björn Meister, M.D., Ph.D., and Prof. Kaj Fried, Ph.D. Moreover, I am deeply grateful to the staff at Thieme Medical Publishers that I have been in close contact with, in particular, the Editorial Director Anne Sydor, Ph.D., Managing Editor Judith Tomat, Editorial Assistant Tony Paese, and Marketing Agent David Towle.

I would also like to acknowledge the Federative International Programme for Anatomical Terminology (FIPAT) for their work towards a standard nomenclature in the field of anatomy.

Hugo Zeberg



Head and Neck

1 Overview

2 Bones, Ligaments, and Joints

3 Classification of the Muscles

4 Classification of the Neurovascular Structures

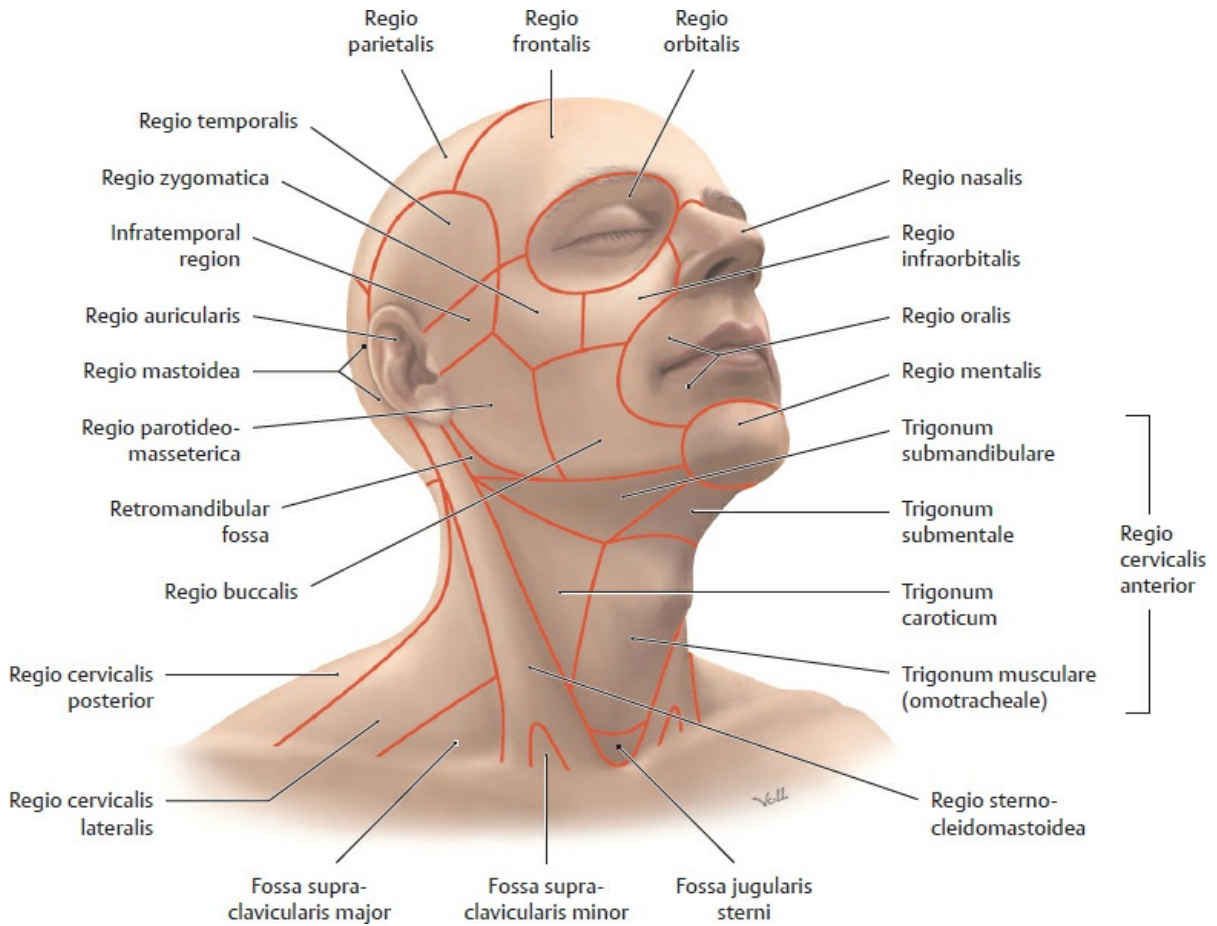
5 Organs and their Neurovascular Structures

6 Topographical Anatomy

7 Sectional Anatomy

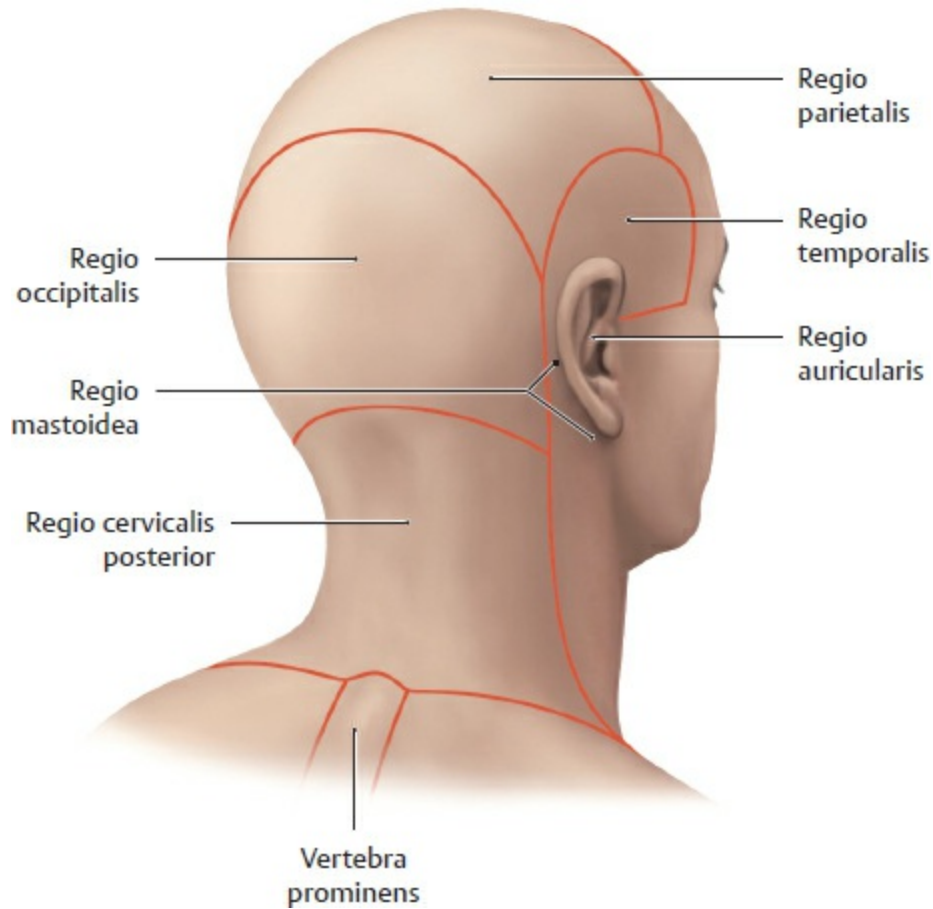
1. Overview

1.1 Regions and Palpable Bony Landmarks



A Head and neck regions

Right anterior view.



B Head and neck regions

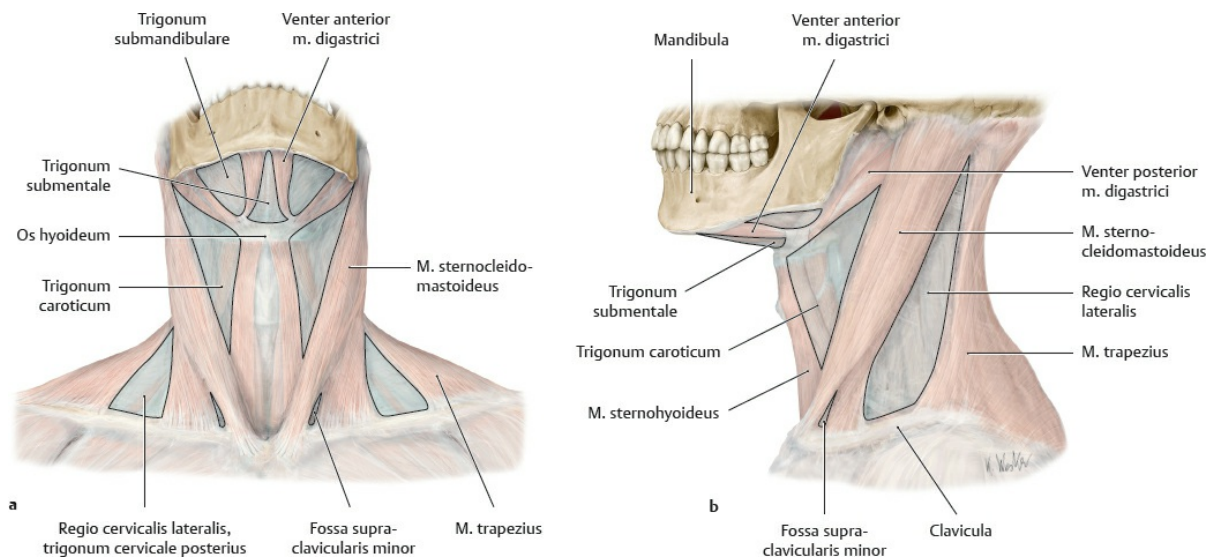
Right posterior view.

C Head and neck regions

Head regions	Neck regions
<ul style="list-style-type: none"> • Regio frontalis • Regio parietalis • Regio occipitalis • Regio temporalis • Regio auricularis • Regio mastoidea • Regio facialis <ul style="list-style-type: none"> – Regio orbitalis – Regio infraorbitalis – Regio buccalis – Regio parotideomasseterica – Regio zygomatica 	<ul style="list-style-type: none"> • Regio cervicalis anterior <ul style="list-style-type: none"> – Trigonum submandibulare – Trigonum caroticum – Trigonum musculare (omotracheale) – Trigonum submentale • Regio sternocleidomastoidea <ul style="list-style-type: none"> – Fossa supraclavicularis minor • Regio cervicalis lateralis <ul style="list-style-type: none"> – Trigonum omoclaviculare (fossa supraclavicularis major) • Regio cervicalis posterior

- Regio nasalis
- Regio oralis
- Regio mentalis

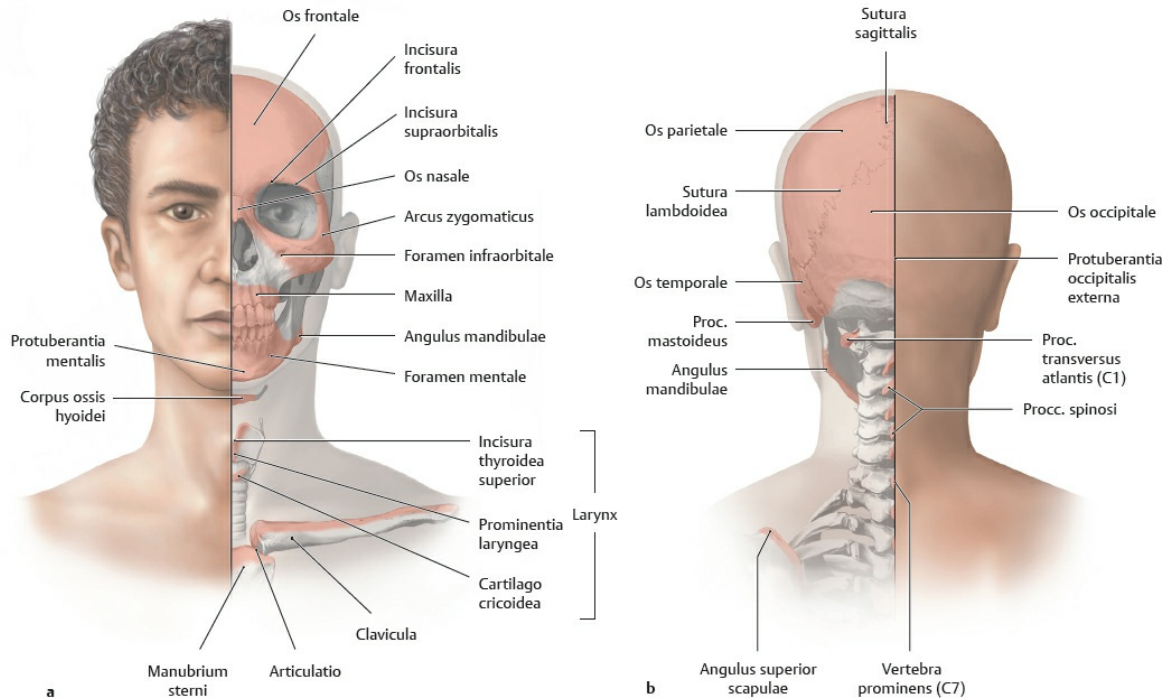
The regions of the head and neck are clinically important since they can exhibit many skin lesions, the location of which must be precisely described. This is particularly important for skin cancer given that the tissue fluid, through which the tumor cells spread, drains into different groups of lymph nodes named for their location.



D Regions of the neck (cervical regions)

a Right lateral view; **b** Left posterior oblique view.

These neck muscles are easily visible and palpable, making them suitable as landmarks for a topographical classification of the neck.



E Palpable bony landmarks at the head and neck

a Frontal view; b Dorsal view.

1.2 Head and Neck and Cervical Fasciae

The head and neck form an anatomical and functional unit with the neck connecting the head and the trunk. The neck contains many pathways to which the cervical viscera are indirectly attached. In the head however, there is only visceral fascia around the glandula parotidea but no general fasciae. Multiple fascial layers subdivide the neck into compartments which will be referred to when describing the location of structures within the neck.

A Sequence of topics in this chapter about the head and neck

Overview

- Regions and palpable bony landmarks
- Head and neck with cervical fasciae
- Clinical anatomy of the head and neck
- Embryology of the face
- Embryology of the neck

Bones

- Cranial bones
- Teeth
- Cervical spine

	<ul style="list-style-type: none"> • Ligaments • Joints
Muscles	<ul style="list-style-type: none"> • Muscles of facial expression • Mm. masticatorii • Neck muscles
Classification of pathways	<ul style="list-style-type: none"> • Arteries • Veins • Lymphatics • Nerves
Organs and their pathways	<ul style="list-style-type: none"> • Ear • Eye • Nose • Cavitas oris • Pharynx • Gl. parotidea • Larynx • Gl. thyroidea and gl. parathyroidea
Topographical anatomy	<ul style="list-style-type: none"> • Anterior facial region • Neck, anterior view, superficial layers • Neck, anterior view, deep layers • Lateral head: superficial layer • Lateral head: middle and deeper layer • Fossa infratemporalis • Fossa pterygopalatina • Regio cervicalis lateralis • Apertura thoracis superior, trigonum caroticum, and trigonum omoclaviculare • Regio cervicalis posterior and regio occipitalis • Cross-section of the head and neck

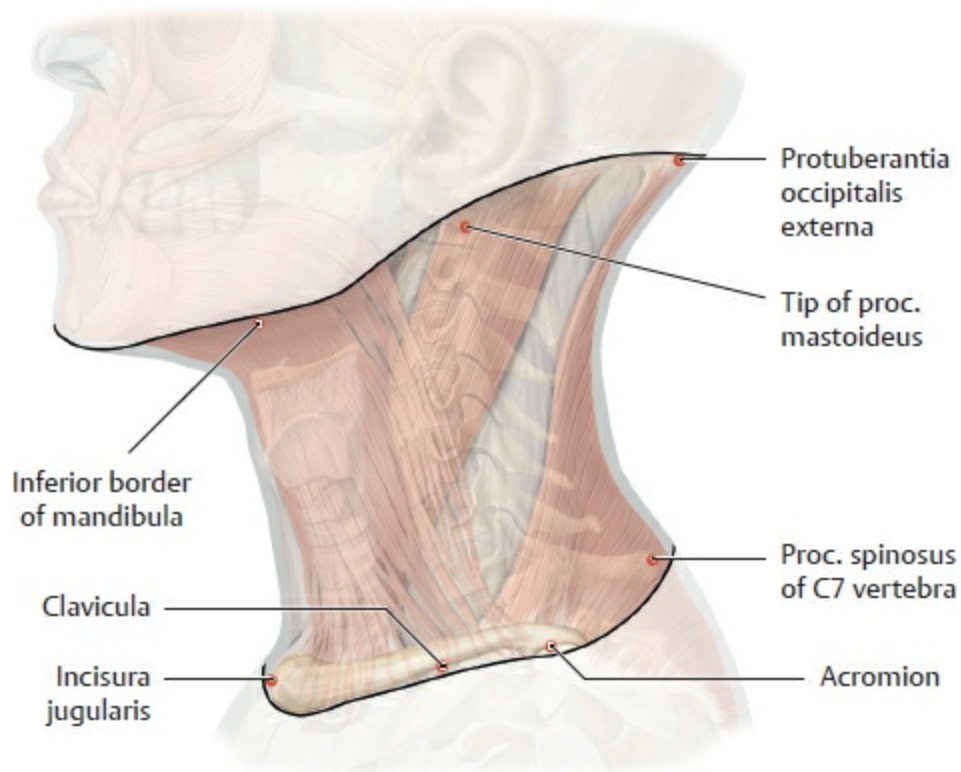
B Fascia cervicalis

Deep to the skin is the superficial cervical fascia (subcutaneous tissue) which contains the platysma muscle anterolaterally. Deep to the superficial are the following layers of fascia cervicalis:

1. Lamina superficialis: envelops the entire neck, and splits to enclose the m. sternocleidomastoideus and m. trapezius.
2. Lamina pretrachealis: the muscular portion encloses the mm. infrahyoidei, while the visceral portion surrounds the gl. thyroidea,

larynx, trachea, pharynx, and oesophagus.

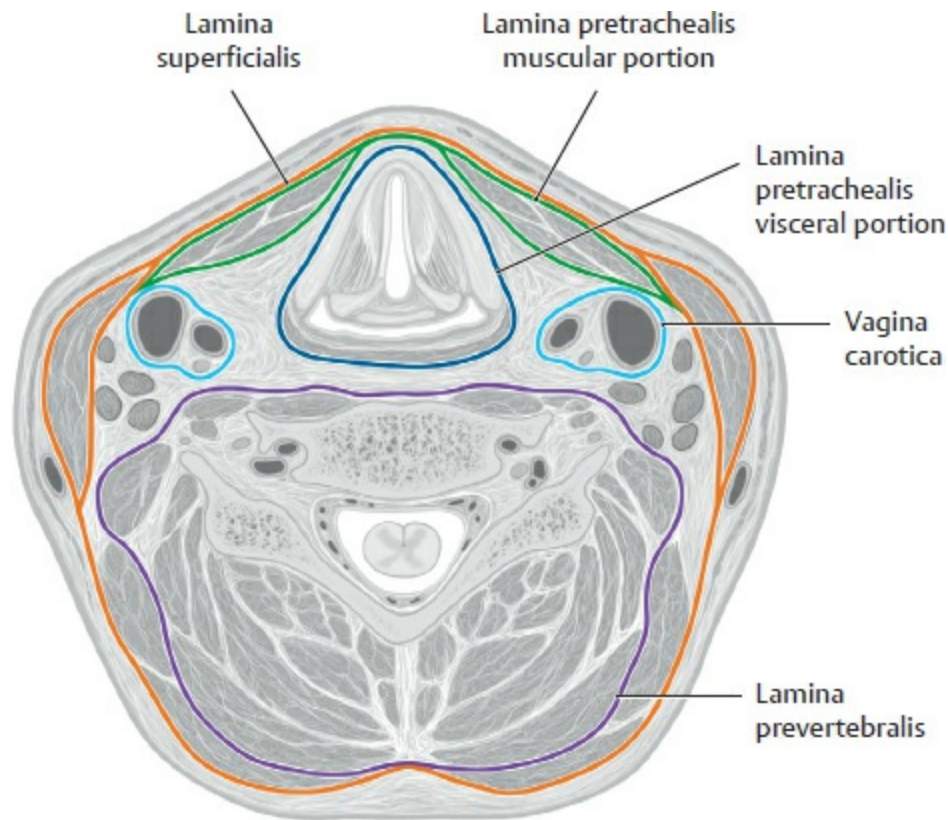
3. Lamina prevertebralis: surrounds the cervical column vertebralis, and the muscles associated with it.
4. Vagina carotica: encloses the a. carotis communis, v. jugularis interna, and n. vagus.
5. Visceral fascia: encloses the larynx, trachea, pharynx, oesophagus, and gl. thyroidea.



C Superficial and inferior boundaries of the neck

Left lateral view. The following palpable structures define the superior and inferior boundaries of the neck:

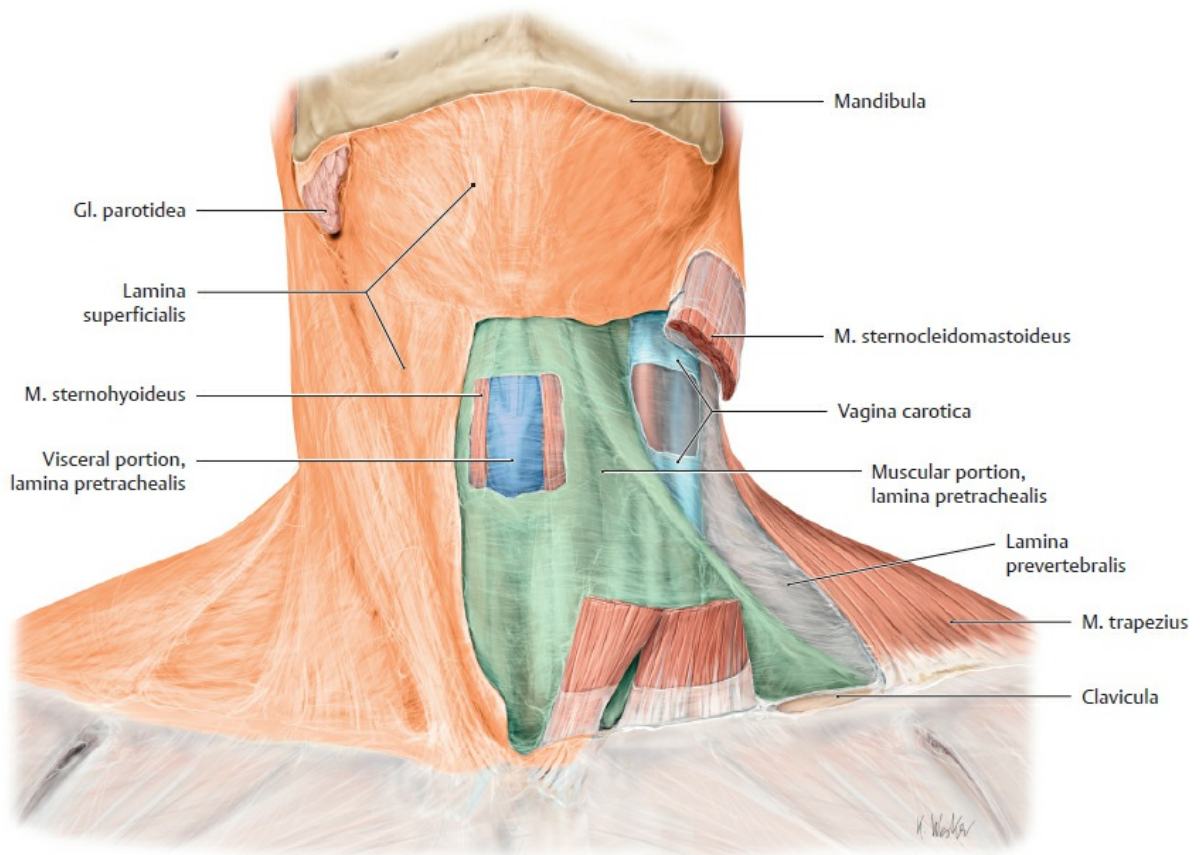
- Superior boundaries: inferior border of the mandibula, tip of the proc. mastoideus, and protuberantia occipitalis externa
- Inferior boundaries: incisura jugularis, clavicula, acromion, and proc. spinosus of the C 7 vertebra.



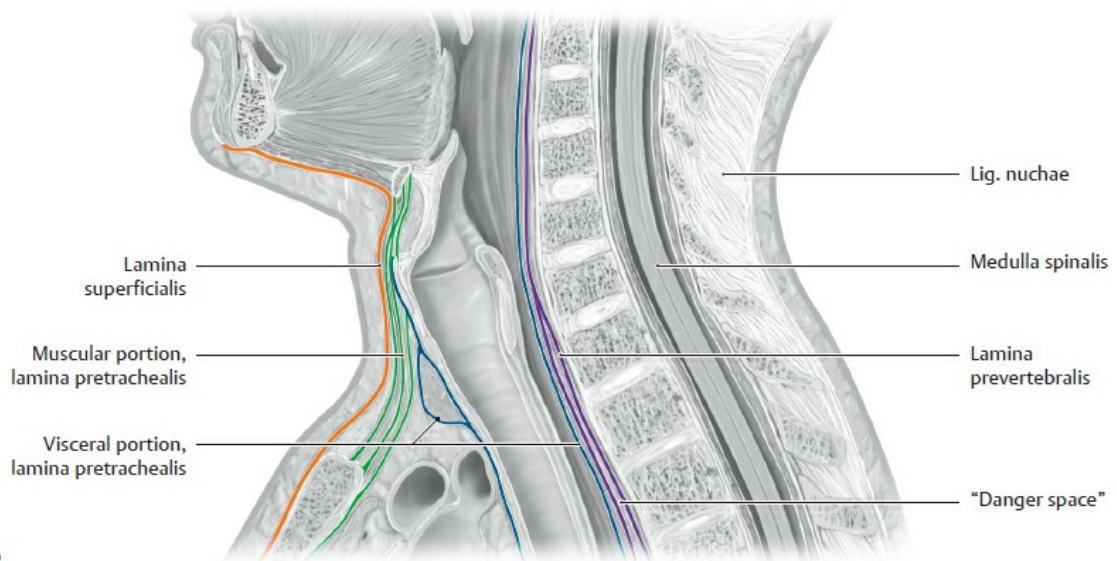
D Relationships of the fascia cervicalis in the neck. Transverse section at the level of the C 5 vertebra

The full extent of the fascia cervicalis is best appreciated in a transverse section of the neck:

- The *muscle fascia* splits into three layers:
 - Lamina superficialis (orange),
 - Lamina pretrachealis (green), and
 - Lamina prevertebralis (violet).
- There is also a neurovascular fascia, called the *vagina carotica* (light blue), and
- a *visceral fascia* (dark blue).



a



b

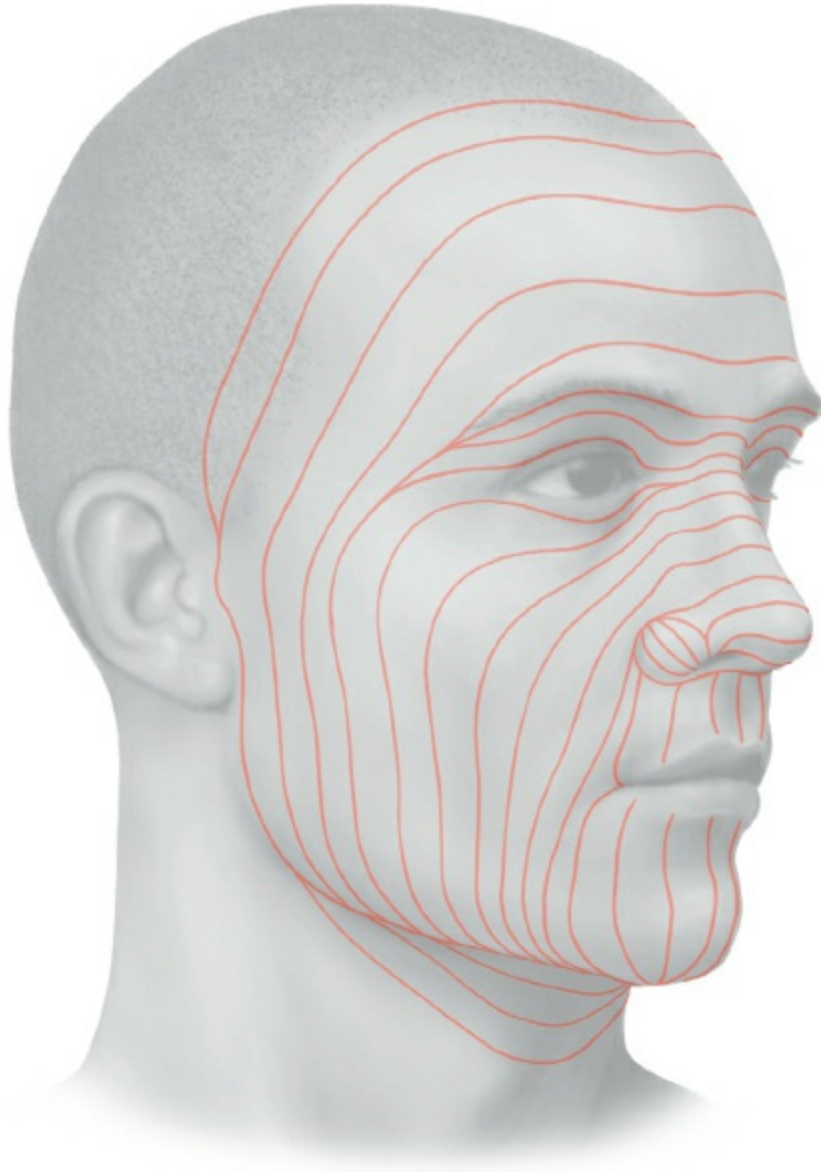E Fascial relationships in the neck

a **Anterior view.** The cutaneous muscle of the neck, the platysma, is highly

variable in its development and is subcutaneous in location, overlying the superficial cervical fascia. In the dissection shown, the platysma has been removed at the level of the inferior mandibular border on each side. The cervical fasciae form a fibrous sheet that encloses the muscles, neurovascular structures, and cervical viscera (see **B** for further details). These fasciae subdivide the neck into spaces, some of which are open superiorly and inferiorly for the passage of neurovascular structures. The *lamina superficialis* of the fascia superficialis has been removed at left center in this dissection. Just deep to the lamina superficialis is the *muscular portion of the lamina pretrachealis*, part of which has been removed to display the *visceral portion of the lamina pretrachealis*. The neurovascular structures are surrounded by a condensation of the fascia cervicalis called the *vagina carotica*. The deepest layer of the fascia cervicalis, called the *lamina prevertebralis*, is visible posteriorly on the left side. These fascia-bounded connective-tissue spaces in the neck are important clinically because they provide routes for the spread of inflammatory processes, although the inflammation may (at least initially) remain confined to the affected compartment.

b Left lateral view. This midsagittal section shows that the deepest layer of the fascia cervicalis, the lamina prevertebralis, directly overlies the columna vertebralis in the median plane and is split into two parts. With tuberculous osteomyelitis of the cervical spine, for example, a gravitation abscess may develop in the “danger space” along the lamina prevertebralis (retropharyngeal abscess). This fascia encloses muscles laterally and posteriorly (see **D**). The vagina carotica is located farther laterally and does not appear in the midsagittal section.

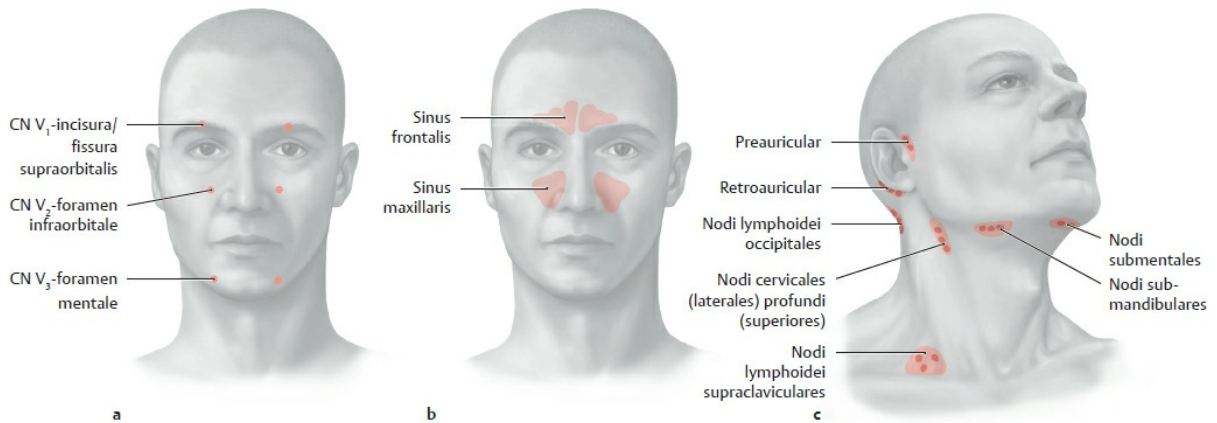
1.3 Clinical Anatomy



A Cleavage or tension lines

Anterior oblique view.

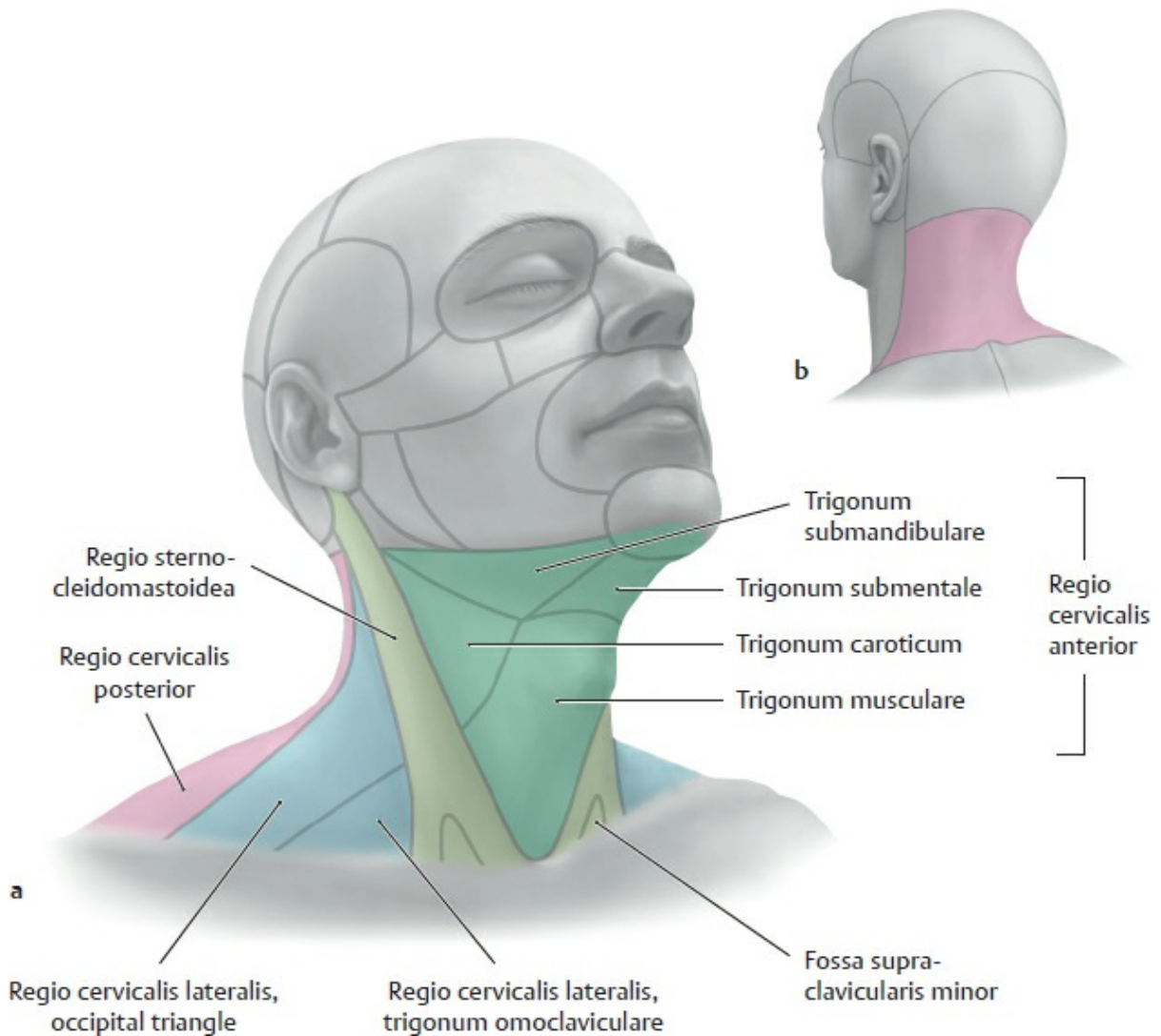
Skin and its subcutaneous tissue are under tension, explaining why a small, round needle hole can result in a small longish slit in the skin aligned along the tension lines in the area around the incision. To promote swift healing and reduce visible scarring, incisions in the head region are aligned along these tension lines. Knowledge of the tension line patterns in the face and neck are critically important in plastic surgery to minimize scarring in these highly visible areas.



B Projection of clinically important structures onto the head and neck

Frontal view (**a** and **b**) and right lateral view (**c**).

- a** Exit points of the n. trigeminus (CN V-sensory): These points are important for sensory testing of the head. If the pressure of a fingertip placed at these exit points causes pain, the respective branch of the n. trigeminus is stimulated.
- b** Skin areas above the sinus paranasales: When sinus paranasales are inflamed, the skin areas above them are sensitive to pressure, causing pain.
- c** Superficial lymph nodes at the junction between head and neck: The most important of lymph node groups are shown here. If the lymph nodes are enlarged, the cause can be related to inflammation or a tumor in the tributary area of the nodes. During a clinical examination of the head, these lymph node groups are always palpated.



C Regions of the neck (cervical regions)

a Right lateral view; **b** Left posterior view.

Certain deeper structures of the neck project onto other regions. Conversely, pathological changes in one region can be referred to the underlying anatomical structure.

Regio cervicalis anterior

- Trigonum submandibulare
 - Nll. submandibulares
 - Gl. submandibularis
 - N. hypoglossus
 - Gl. parotidea (posterior)

- Trigonum caroticum
 - Bifurcatio carotidis
 - Glomus caroticum
 - N. hypoglossus
- Trigonum musculare
 - Gl. thyroidea
 - Larynx
 - Trachea
 - Oesophagus
- Trigonum submentale
 - Nll. submentales

Regio sternocleidomastoidea

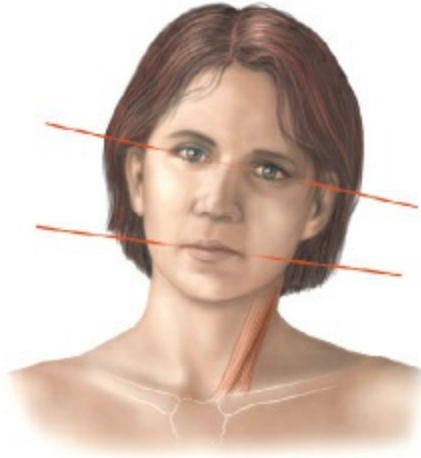
- M. sternocleidomastoideus
- A. carotis
- V. jugularis interna
- N. vagus
- Nll. cervicales laterales

Regio cervicalis lateralis

- Nll. cervicales laterales
- N. accessorius
- Plexus cervicalis
- Plexus brachialis

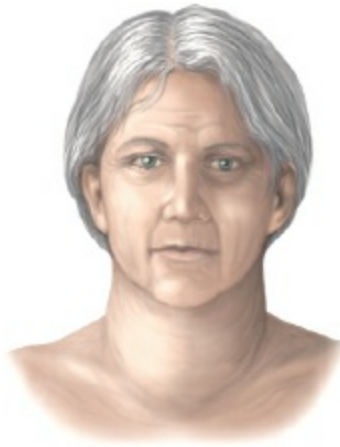Regio cervicalis posterior

- Mm. colli
- Trigonum arteriae vertebralis



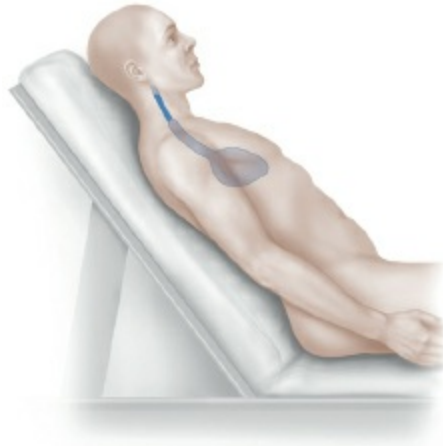D Left-sided muscular torticollis (after Anschütz)

Torticollis and struma (swellings of the neck see **E**) can be readily diagnosed by visual examination. In the case of torticollis, the m. sternocleidomastoideus is shortened—most commonly as a result of intrauterine malposition in infants. The head is tilted toward the affected side and is slightly rotated toward the opposite side. Without therapy (physical therapy/surgery) torticollis secondarily leads to asymmetrical growth of spinal column and facial skeleton. The effects of the cranial asymmetry may include a convergence of the facial planes toward the affected side (see lines).



E Retrosternal goiter (after Hegglin)

A goiter that arises from the inferior poles (see [p. 214](#)) of the gl. thyroidea may extend to the apertura thoracis superior and compress the cervical veins at that level. The result of this is venous congestion and dilation in the head and neck region.



F Assessing the central venous pressure in the neck in a semi-upright position

Normally the cervical veins are collapsed in the sitting position. But in a patient with right-sided heart failure, there is diminished venous return to the right heart, causing distention of the vv. jugulares. The extent of the venous congestion is indicated by the level of pulsations in the v. jugularis externa (the “venous pulse,” upper end of the blue line). The higher the level of jugular pulsation, the greater the backup of blood into the vein. This provides a means of assessing the severity of right-sided heart failure.

1.4 Embryology of the Face